NISHTAR
PUBLICATIONS (Pvt). Ltd.

Volume 1

FOURTH EDITION

DOUBLE "A" NOTES

for FCPS 1

Dr. M Khan Rai

Complete Book for FCPS-1 MD/MS and NLE, NRE Basic Sciences

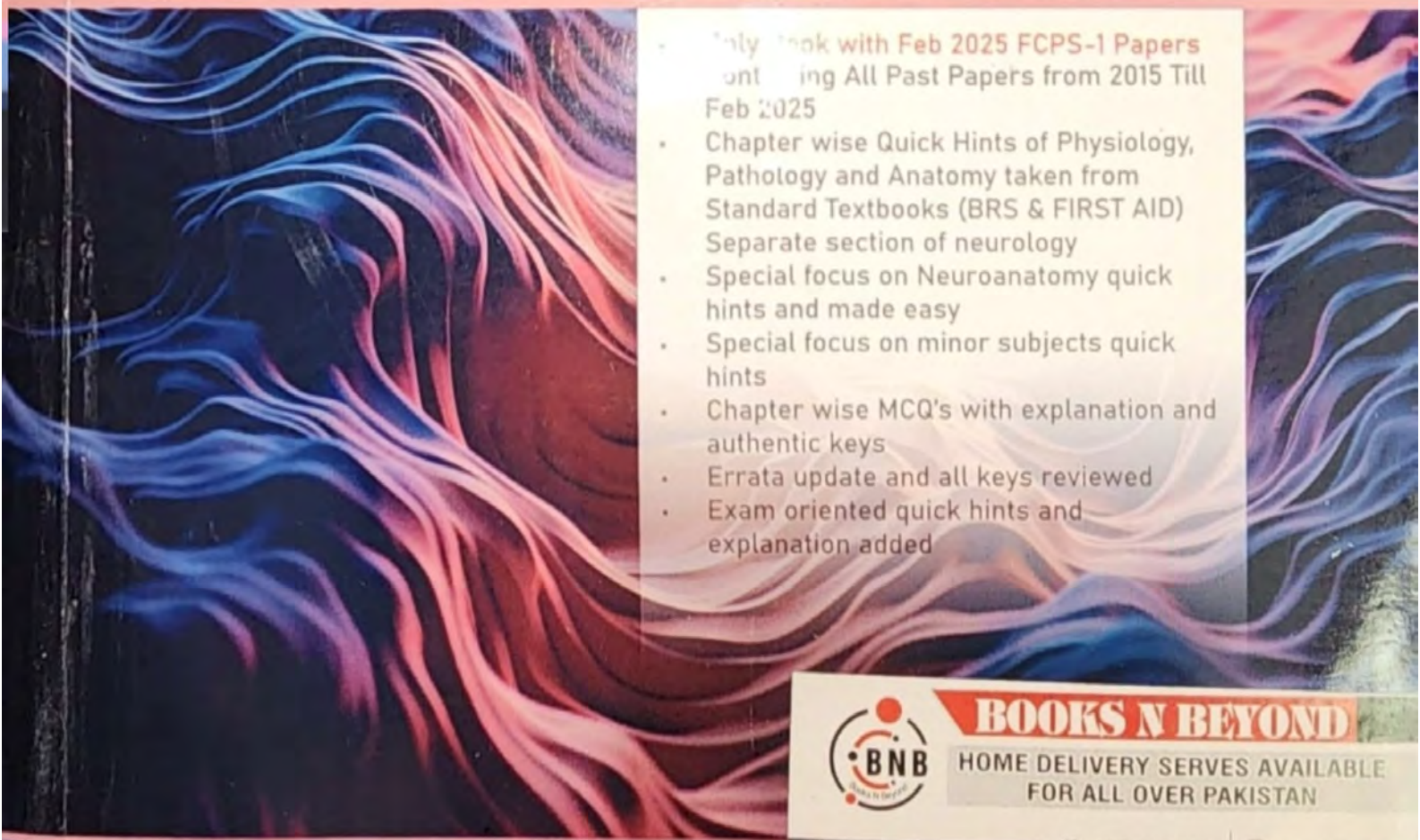

- Only book with Feb 2025 FCPS-1 Papers containing All Past Papers from 2015 Till Feb 2025
- Chapter wise Quick Hints of Physiology, Pathology and Anatomy taken from Standard Textbooks (BRS & FIRST AID) Separate section of neurology
- Special focus on Neuroanatomy quick hints and made easy
- Special focus on minor subjects quick hints
- Chapter wise MCQ's with explanation and authentic keys
- Errata update and all keys reviewed
- Exam oriented quick hints and explanation added

BNB

BOOKS N BEYOND

HOME DELIVERY SERVES AVAILABLE FOR ALL OVER PAKISTAN

MEDICAL BOOKS | DR. COAT / SCRUBS
SCHOOL BOOKS | STATIONARY
UNIFORM | BAGS

0311-1134466
0309-7271940
www.booksnbeyond.pk
booksnbeyond
booksnbeyond

MCB Bank Road, 146-B, Near Chughtai Lab, Baba Tower, Gulgasht Colony, Multan.

By:
Dr. Atif Afzal (AA)

CamScanner

This PDF has been provided by Dr. M Khan

Remember in Prayers

VOLUME-1

Double "A" Notes

For FCPS -1

(Complete Book for FCPS-1, MD/MS and Basic Sciences)

- Only Book with Feb 2025 FCPS-1 papers
- Containing All Past Papers from 2015 Till Feb 2025
- Chapter wise Quick Hints of Physiology , Pathology and Anatomy Taken From Standard Textbooks(BRS & FIRST AID)
- Separate Section of Neurology
- Special Focus on Neuroanatomy Quick Hints and Made easy
- Special Focus on Minor Subjects Quick Hints
- Chapter wise Mcq with Explanations and Authentic Keys
- Errata Updated and All Keys Reviewed
- Exam oriented Quick Hints and Explanations added

BOOKS N BEYOND
061-6217975 0311-1134466
MCB Bank Road , 148-B,Near Chugtai Lab
& Baba Tower, Gulgasht Colony, Multan.

By

Dr. Atif Afzal (AA)

NISHTAR
PUBLICATIONS (Pvt). Ltd.

Visit us: www.nishtarpublications.com | 0341 4300684

CamScanner

TABLE OF CONTENTS

Dr M.Khan

Sr No.	Topic	Page
	SECTION 1	
PHYSIOLOGY		
1.	CELL PHYSIOLOGY	02
2.	CVS PHYSIOLOGY	28
3.	GIT PHYSIOLOGY	70
4.	RENAL PHYSIOLOGY	88
5.	RESPIRATORY PHYSIOLOGY	132
6.	ENDO PHYSIOLOGY	167
7.	REPRODUCTION PHYSIOLOGY	199
	SECTION 2	
GENERAL PATHALOGY		
8.	CELL PATHOLOGY	220
9.	INFLAMMATION & REPAIR	233
10.	HEMODYNAMICS	255
11.	NEOPLASIA	268
12.	GENETICS	298
13.	IMMUNOLOGY	319
SPECIAL PATHALOGY		
14.	CVS PATHOLOGY	355
15.	GIT PATHOLOGY	410
16.	RENAL PATHOLOGY	451
17.	RESPIRATORY PATHOLOGY	474
18.	HEMATOLOGY (Physio & Patho)	508
19.	MUSKULOSKELETAL PATHOLOGY	570
20.	ENDO PATHOLOGY	588
21.	REPRODUCTION PATHOLOGY	623
22.	DERMATOLOGY	654
	SECTION 3	
ANATOMY		
23.	UPPER LIMB	663
24.	LOWER LIMB	703
25.	THORAX	738

M.K

CamScanner

CELL PHYSIOLOGY QUICK HINTS

- ✓ Common feature between smooth and skeletal muscle -Increase intracellular Ca before contraction
- ✓ Common feature between cardiac and skeletal muscle -Transverse striation
- ✓ Difference between Skeletal and smooth muscle -Ca Calmodulin complex in Smooth muscle
- ✓ Smooth muscles cause Slow sustained prolong contraction
- ✓ Cardiac muscle don't get tetanized because of long refractory period
- ✓ Smooth muscle has inner circular and outer longitudinal layer
- ✓ Common muscle contraction protein for Smooth muscle and skeletal muscle - Actin
- ✓ Actin attach to Z line through Actin
- ✓ Cell Membrane Bond – Hydrophobic+ Hydrogen > Hydrophobic +Covalent
- ✓ Integral Protein in cell membrane joined by – Hydrogen > Hydrogen + Hydrophobic
- ✓ Integral protein in cell membrane joined to Lipid of membrane – Hydrophobic
- ✓ Peripheral Protein by – Electrostatic Interactions
- ✓ Micro filament function – Muscle contraction
- ✓ Intermediate filaments – Maintain cell structures
- ✓ Microtubules – Cell division and movement
- ✓ Actin and microvilli are microfilaments
- ✓ Desmin , vimentin , GFAP , Cytokeratin and neurofilaments are intermediate filaments
- ✓ Centriole, Cilia, Flagella , Mitotic spindles are examples of Microtubules
- ✓ Permeability of substance depends upon – Total cross-sectional area
- ✓ Diffusion is inversely related to thickness of membrane
- ✓ Diffusion of gas is directly proportional to – Surface area of Alveolocapillary membrane
- ✓ Osmotic pressure depends upon- increase no. of particles
- ✓ While calculating plasma osmolality Na is multiplied by - Anions
- ✓ Water enters into cell through – Pores
- ✓ Water absorption across cell membrane through – Pores
- ✓ Water from cells enter extracellular space through – Filtration
- ✓ Water goes from plasma to interstitial fluid through – Filtration
- ✓ Permeability of membrane increases in – Polycythemia
- ✓ Mean transportation rate of mucus in Nasal Mucosa is – 12mm/min
- ✓ Normal fluid loss in 24 hours through perspiration is - 200-400ml
- ✓ Flow through Orifice depends upon – Density
- ✓ Flow through medium depends upon – Viscosity

Organelles

- ✓ Detoxification of drugs – **SER**
- ✓ Detoxification of Alcohol in **Toxic Dose** – **SER**
- ✓ Detoxification of Alcohol in **Normal Dose** – **Peroxisomes (Oxidase and H_2O_2)**
- ✓ Lysosomes Contain – **Hydrolytic enzyme**
- ✓ Peroxisome Originate from **-SER**
- ✓ Lysosome Originate from – **Golgi Body**
- ✓ Continue with Nuclear membrane – **RER**
- ✓ Nissle Substance in –**RER**
- ✓ Lydeg Cell Has – **SER**
- ✓ **Mitochondria** – Power house + self-replicating + Short chains Fatty acids Metabolism
- ✓ Double membrane bounded organelles – **Nucleus and Mitochondria**
- ✓ Golgi bodies – **Packaging of cells**
- ✓ Production of proteins – **Ribosomes > RER**
- ✓ Centrioles make – **Basal body (basal body makes cilia and flagella)**

Transport

- ✓ **Active transport-**
- Carrier mediated
- Against concentration gradient from low to high
- Use Energy in form of ATP
- E.g, Na+K+Atpase pump , Exo and endocytosis

- ✓ **Facilitated diffusion** –
- Passive (moves in direction of chemical gradient)
- From high to low
- Carrier is required
- E.g, Glucose transporters

- ✓ **Simple diffusion**
- Passive
- Carrier not required
- Eg Diffusion of lipid soluble drugs

- ✓ **Glucose** is absorbed in **renal** tubules through – **2ndry Active Transport**
- ✓ **Glucose** transport across membrane due to its **concentration difference** – **Facilitated Diffusion**
- ✓ **Amino acids** are absorbed from **kidney** to blood by – **2ndry Active Transport**
- ✓ **Glucose** transported to **placenta** by – **Facilitated Diffusion**
- ✓ **Chloride and Urea** transported by – **Passive Diffusion**
- ✓ **Oxygen** taken up to lung through – **Simple Diffusion > Passive Diffusion**
- ✓ **Local Anasthesia** crosses **Placenta** by – **Simple Diffusion > Passive Diffusion**
- ✓ The membrane protein **Clathrin** is involved in – **Receptor mediated Endocytosis**
- ✓ Transport through cell membrane involving **Actin, Myosin and clathrin** – **Pinocytosis**
- ✓ If a drug molecular weight is **less than 1000** Transport occurs via -- Diffusion
- ✓ If a drug molecular weight is **more than 1000** Transport occurs via --**Pinocytosis**

Heat Production

1) **Resting Heat:** Heat Given off at Rest
2) **Initial Heat:** Heat produced in Excess of resting Heat during Muscle Contraction. It is made up of Activation Heat and Shortening Heat
   a) Activation Heat: Heat Produced whenever muscle Contracts
   b) Shortening Heat: Heat Produced when Muscle shortens (Change in Structure)
3) **Recovery Heat:** Heat Produced when return to its Pre contraction state muscle. It is equal to Initial Heat.
4) **Relaxation Heat:** Extra Heat produced in addition to Recovery Heat.

Measurement of body fluid volumes

Total body water – Antipyrine , Deuterium oxide
Plasma volume – Albumin , Evans blue eye
Extracellular fluid – Na,Insulin , Sucrose , Thiosulphate, Iothalamate
Intracellular fluid – Total body water – Extracellular fluid volume
Interstitial fluid – Extracellular fluid volume – Plasma volume

CamScanner

CELL PHYSIOLOGY

1- IGGO dome receptors collections are:
A- Pacini
B- Ruffini
C- Merkels
D- Meissners
Ans: C

2- Plateau phase in the action potential is due to:
A. Influx of sodium
B. Influx of calcium and efflux of potassium
C. Efflux of calcium and influx of potassium
D. Efflux of potassium only
Ans: B

3- All or none action potential is initiated at:
A- Axon hillock
B- Node of renvier
C- Axon terminal
D- Soma
Ans: A

4- Factor for exercising muscle blood supply by:
A- Local metabolite
B- Sympathetic
C- Parasympathetic
D- Oxygen
Ans: A(BRS)
Explanation:
- During Exercise blood flow to **Exercising muscles** is maintained by – **Local Metabolites**
- During Exercise blood flow to **Non-Exercising Muscle** is maintained by – **Sympathetic Cholinergic (Guyton)**

5- Which one is controlled by sympathetic rather than local metabolites?
A- Muscle
B- Skin
C- Brain
D- Liver
Ans: B

6- Glucose transport in intestine is:
A- Na-Glucose Co transport
B- Na-K Co transport
C- NA-Uran Co transport
D- None
Ans: A(BRS +FA)
Explanation:
- Glucose transport across membrane due to its concentration difference – Facilitated diffusion.
- Glucose is absorbed in renal tubules through – 2ndry active transport (Na-glucose Co).
- Glucose transported to placenta by – Facilitated diffusion.
- Amino acids are absorbed from kidney to blood by – 2ndry Active Transport
- . Chloride and Urea transported by – Passive diffusion.
- Oxygen taken up to lung through – Simple Diffusion > Passive diffusion.
- Local Anasthesia crosses Placenta by – Simple diffusion > Passive diffusion.
- Primary Active transport uses – Pump.
- Glucose transported to placenta by – Facilitated diffusion.
- Chloride and Urea transported by – Passive diffusion.
- Oxygen taken up to lung through – Simple Diffusion > Passive diffusion.
- Local Anasthesia crosses Placenta by – Simple diffusion > Passive diffusion.
- Primary Active transport uses – Pump.

7- Inactivation gates of Na are closed during:
A- Depolarized state
B- Repolarized state
C- Hyperpolarized state
D- Partially depolarized state
Ans: A

8- Permeability of the molecule across cell membrane depends on its size following has relatively higher permeability across cell membrane:
A- Glucose
B- Insulin
C- Urea
D- Albumin
E- Water
Ans: E

9- Secondary active transport requires:
A- Pump
B- Carrier
C- Down hill
D- Energy
Ans: B

10- Oxidase enzyme and H_2O_2 present in:
A- Lysosomes
B- Mitochondria
C- Peroxisomes
D- SER
Ans: C
Explanation:
- Peroxisomes – Oxidase & H_2O_2
- Lysosomes – Hydrolytic Enzymes

11: Diffusion depends on size of particles which one has relatively high diffusion capacity?
A- Water
B- Glucose
C- Sodium
D- Potassium
E- Chloride
Ans: A

12: When sodium channels are completely blocked by drugs, what will happen?
A- Decreased action potential
B- No action potential
C- Increased action potential
D- No change in action potential
Ans: B

13- Main function of cell membrane:
A- Synthesis of cholesterol
B- Synthesis of protein
C- Selective permeability
D- Maintain electrolytes imbalance
Ans: C

14- Nissle substance related to:
A- RER
B- SER
C- Peroxisome
D- Ribosome
Ans: A

15- Resting Membrane potential achieved by:
A- Na K pump
B- NA Influx
C- K efflux
D- K influx
Ans: C
Explanation:
- Achieved by – K efflux
- Maintained by – Na/K pump

16- RER is involved in the formation of:
A- Steroids
B- Lipids
C- Proteins
D- Enzymes
Ans: C
Explanation:
- **Mitochondria** – formation of ATP
- **Golgi bodies** – Lysosome formation, processing / packaging of proteins, synthesize carbohydrates which not produced by ER
- **Lysosomes** – Contains Hydrolases to digest proteins, lipids and carbohydrates.
- **Peroxisomes** – contains oxidases
- **SER** – Synthesis of lipids and steroids, Peroxisomes formation
- **RER** – Synthesis of Proteins
- **Ribosomes** – Synthesis of proteins
- **Nucleolus** – Ribosomes synthesis

17- Transport of solute in active transport:
A- Passive Diffusion
B- Down hill
C- Require energy
D- No energy needed
Ans: C

18- Glucose Transport to fetus through:
A- Simple diffusion
B- Facilitated diffusion
C- Active transport
D- Osmosis
Ans: B
Explanation:
- Glucose transport across membrane due to its concentration difference – facilitated diffusion
- Glucose is absorbed in renal tubules through – 2ndry active transport.
- Glucose transported to placenta by – Facilitated diffusion.

19- Local anesthesia cross placenta through:
A- Active transport
B- Bulk flow
C- Facilitated diffusion
D- Simple diffusion
Ans: D

CamScanner

20- Nerve fibers placed in sodium free solution, what will happen to action potential?
A- No action potential
B- Increase Threshold of potential
C- Depolarization
D- Repolarization
Ans: A

21- Action potential in neuron originates at:
A- Proximal Dendrites
B- Axon Hillock
C- Stroma
D- Distal Dendrites
Ans: B

22- Regarding smooth muscle which is true?
A- Each fiber is innervated by nerve
B- Has slow and sustained contraction
C- Multiple cells joined together
D- Get Fatigue
Ans: B

23- Which of the following substances must be further digested before it can be absorbed by specific carriers in intestinal cells?
A- Fructose
B- Sucrose
C- Alanine
D- Dipeptides
E- Tripeptides
Ans: B (BRS)

Explanation:
Only monosaccharides can be absorbed by intestinal epithelial cells. Disaccharides, such as sucrose, must be digested to monosaccharides before they are absorbed. On the other hand, proteins are hydrolyzed to amino acids, dipeptides, or tripeptides, and all three forms are transported into intestinal cells for absorption

24- Other than nucleus DNA exist in:
A- Golgi
B- Ribosomes
C- Mitochondria
D- Lysosomes
E- Peroxisomes
Ans: C

25- Which structure connects 2 epithelial cells?
A- Integrins
B- Gap junctions
C- Tight junctions
D- Desmosome
E- Hemi desmosomes
Ans: C

26- Distribution of pain receptors on fingertips involve:
A- Pacinian
B- Merkels disc
C- Meissners
D- Free nerve endings
E- Krause
Ans: D

27: Cardiolipin Phospholipid is present in which of following?
A- RER
B- Mitochondria
C- SER
D- Plasma membrane
E- Golgi bodies
Ans: B

28: Sympathetic cholinergic stimulation causes which effect?
A- Vasodilation in skeletal muscle
B- Relaxation of ciliary muscle
C- Pupillary Constriction
D- Accommodation reflex for near vision
E- Increase GIT motility
Ans: A

29: Hydrolytic enzymes are found in which of following?
A- Lysosomes
B- Mitochondria
C- Golgi bodies
D- Peroxisomes
E- Centriole
Ans: A

Explanation:
- Lysosome – Hydrolytic enzymes
- Peroxisomes – Oxidases + H_2O_2

30: During exercise blood flow to which of the following decreases?
A- Skin
B- Splanchnic
C- Skeletal muscle
D- Heart
E- Lung
Ans: B

Explanation:
- During Exercise blood flow increased to – **Exercising skeletal muscle**
- During exercise decreased blood flow to – **Kidneys > splanchnic vessels**
- During **strenuous exercise** decreased

31: Transport depends on thickness is:
A- Diffusion
B- Osmosis
C- Endocytosis
D- Exocytosis
Ans: A

32: Very long chain fatty acids are catalyzed in:
A- Peroxisomes
B- Mitochondria
C- ER
D- Lysosomes
Ans: A

33: Which of following has transport maximum?
A- Urate
B- Lactate
C- Phosphate
D- Ammonia
Ans: B

Explanation: Glucose >**PAH** > Lactate

34: Type of endocytosis that occur in lysosome:
A- Phagocytosis
B- Pinocytosis
C- Apoptosis
D- Cell lysis
E- Pseudopod mediated
Ans: A

35: In cell membranes bond between integral protein and lipid is:
A- Hydrophobic and covalent bond
B- Covalent bonds
C- Hydrogen bonding
D- Ionic bonds
Ans: A

36: Cell organelle containing double membrane:
A- Lysosomes
B- Nucleus
C- Golgi apparatus
D- Peroxisomes
E- Ribosomes
Ans: B

Explanation: Nucleus and mitochondria have double membrane.

37: Regarding skeletal muscles what is true?
A- Fleshy belly throughout
B- Aponeurosis is fibrous
C- Distal insertion is fixed
D- Origin causes movement
Ans: A

38: Student examining a slide, visualize a tumor of muscle of GIT, a protein which connect cells together is missing. Protein is?
A- Titin
B- Collagen
C- Fibronectin
D- Actinin
Ans: C

39: Hyper excitability of neurons is due to decrease level of:
A- Chloride
B- Potassium
C- Sodium
D- Calcium
E- Magnesium
Ans: D

Explanation:
- Hypocalcemia – Increase excitability
- Hypercalcemia – Decrease excitability
- Hypokalemia – Decrease nerve
- excitability in RMP & difficult to create AP
- Hyperkalemia – Increase nerve excitability in RMP
- Hyponatremia – Decrease height of action potential.
- Hypernatremia – Increase height of action potential

40- During prolong surgery of 8 hours the temperature of patient is monitored by:
A- Probe in Axilla
B- Probe in Rectum
C- Probe in Esophagous
D- Probe in Tympanic membrane
E- By Hamstring muscle
Ans: C

Explanation:
- Probe in distal esophagous is easy and reliable method specially in children.
- Probe in tympanic membrane also good method but it is invasive can perforate tympanic membrane and may give initial false reading.
- Pulmonary artery catheter with distal tip thermistor is invasive and gold standard method for measuring core body temperature.

41- Body metabolic response to trauma Skeletal muscle responds by:
A- Decreased proteolysis
B- Increase glucose loss
C- Increase proteolysis
D- No metabolic change
E- Decrease Protein loss
Ans: C

CamScanner

42- Which of the following is the communication between cells which prevented unwanted materials from passing through them?
A- Gap junctions
B- Tight junctions
C- Desmosomes
D- Hemidesmosomes
Ans: B

43- Hyperpolarization of nerve fibers is due to:
A- Efflux of potassium
B- Influx of potassium
C- Low Na/K ATpase
D- Efflux of Sodium
E- Efflux of Calcium
Ans: A

44- In normal healthy person, sympathetic activity is increased to increase blood flow to:
A- Heart
B- Skin
C- Muscle
D- Lungs
Ans: C

45- A naked person in AC room with temperature 21, humidity 80%, heat loss will be through:
A- Increase loss by perspiration
B- Radiation and conduction
C- Radiation
D- Conduction
Ans: B (Prefer radiation + Conduction + Convection)

Explanation:
- Patient naked heat loss by – Radiation
- Patient naked and lying on surface (Table) heat loss by – Conduction
- Patient naked and temp mention heat loss by – Radiation + Conduction
- Patient naked and humidity mention heat loss by – Convection

46- Increase no. of mitochondria is present in apical layers of which cells?
A- Cardiac muscle
B- Skeletal muscle
C- Smooth muscles
D- Ciliated cells
Ans: D

47- The concept of conduction of one sensation modality in sensor nerve fibers at a time is called:
A- Dales law
B- Powers law
C- Weber Fechner law
D- All or none
E- Labelled line principle
Ans: E

48- In axonal membrane constant membrane depolarization depends on:
A- Membrane capacitance
B- Axonal transport
C- Resistance
D- Velocity
Ans: A

49- Actin is bound to Z line by:
A- Myosinin
B- Laminin
C- Capsinin
D- Actinin
Ans: D

Explanation:
Actinin is a microfilament protein that's Necessary for the attachment of Actin filament to the Z-Lines in Skeletal muscle cells & to the dense bodies in smooth muscle cells.

50- 2/3rd of Body fluid:
A- ICF
B- ECF
C- Plasma
D- Interstitial Fluid
Ans: A

Explanation:
- 2/3rd of total body fluid is ICF
- 1/3rd of total body fluid is ECF

51- Cytokeratin is made up of:
A- Glycoproteins
B- Intermediate filaments
C- Microfilaments
D- Microtubules
Ans: B

52- Secretory vesicles are formed by:
A- Golgi
B- ER
C- Lysosomes
D- Mitochondria
E- Nucleus

53- Statement true about cell is:
A- Nucleolus is floating in cytoplasm
B- Hematoxylin stains nucleus blue
C- Golgi bodies forms proteins
D- Ribosome is powerhouse of cell
Ans: B

54- Regarding phospholipids:
A- Insoluble in Water
B- Soluble in Water
C- Backbone is made by Lipids
D- Backbone is made by Chloride
Ans: A

55- Statement true about gap junctions:
A- Absent in cardiac muscles
B- Present in cardiac muscles
C- Absent in smooth muscles
D- Present in skeletal muscles
Ans: B

Explanation:
- Present in smooth muscles and cardiac muscles.
- Absent in skeletal muscles

56: True regarding action potential:
A- Subsequent action potential can Summate
B- With more stimulation action potential can occur above threshold
C- More amplitude of stimulus can increase amplitude of action potential
D- None of the above
Ans: A

57: Drug receptors are:
A- Protein in nature
B- Fixed in number
C- Decreased in old age
D- Variable
Ans: A

58: CO_2 passes through which of the following:
A- Passive diffusion
B- Active Transport
C- Secondary Transport
D- Facilitated
Ans: A

59: On H & E staining a student sees the hallow structure around the nucleus. What it could be?
A- Golgi Apparatus
B- Lysosome
C- Ribosome
D- Endoplasmic Reticulum
Ans: B

60: Phospholipid is an important component of cell membrane due to:
A- It is insoluble in water
B- It has both polar & non polar ends
C- It is covalently bond to protein
D- It only has polar ends
Ans: B

61: Connected to desmosomes are
A- Tubulin
B- Microfilaments
C- Microtubules
D- Intermediate filaments
Ans: D

62: What is an Anion gap?
A- Measured cations and measured anions
B- Unmeasured cations and unmeasured anions
C- Unmeasured cations and measures anions
D- Measured cations and unmeasured anions
Ans: A

63: Most important component of lipid:
A- Phosphorus
B- Carbon
C- Potassium
D- Sodium
Ans: B

64: Osmosis depends on:
A- Number of solute particles
B- Osmoreceptors
C- Concentration gradient
D- Electrical gradient
Ans: A

65: Which of the following muscles do not tetanize?
A- Skeletal muscles
B- Smooth muscles
C- Both skeletal and smooth muscles
D- Cardiac muscles
Ans: D

66: The fluidity of the cell membrane is caused by:
A- Integrins
B- Lipopolysacharride
C- Glucose
D- Cholesterol
Ans: D

67- True about euchromatin:
A- Densely condensed
B- Lightly condensed
C- Contains histone protein only
D- 8% of the human genome
Ans: B

CamScanner

68- Most growth factors have receptors on which organelle?
A- Plasma membrane
B- Cytoplasm
C- Lysosomes
D- Golgi complex
Ans: A

69- The intracellular structure composed of microtubules:
A- Centromere
B- Centrioles
C- Golgi Apparatus
D- Endoplasmic reticulum
Ans: B

70- The facilitated diffusion in intestine suits with which one of the following?
A- Glucose
B- Galactose
C- Sucrose
D- Fructose
Ans: D

71- Striated muscle that rhythmically myogenically contract is synchronized fashion:
A- Skeletal muscles
B- Smooth muscles
C- Cardiac muscle
D- Ciliary body
Ans: C

72- Cell swelling that occurs in reversible injury is owing to:
A- Fat accumulation
B- Inward water flow
C- Calcium entrance to cells
D- Na-K Pump malfunctioning
Ans: B

73- Transfer of O_2 from alveoli to capillaries involves which mechanism?
A- Active transport
B- Passive diffusion
C- Facilitated diffusion
D- Secondary diffusion
Ans: B

74- Regarding sarcomere of muscle fiber it's between:
A- Two Z-lines
B- Transverse tubules
C- H-Band
D- A-Band
Ans: A

75- Chom...
A- Sphingomyelin
B- Phsophotidicholine
C- Cephalic
D- Glycerol
Ans: A

76- Albumin does not pass basement membrane due to:
A- Negative charge
B- Large size
C- Positive charge
D- Medium size
Ans: A

77- Structure produced by basal bodies:
A- Cilia
B- Microtubules
C- Microfilaments
D- Cell wall
E- Cell membrane
Ans: A

78- Lipid bilayer of cell membrane have cholesterol in its structure. Function of this cholesterol in membrane is:
A- Intercellular attachment
B- Permits Ion movement
C- Solubility
D- Phagocytosis
Ans: B

Explanation:
Cholesterol is made up of Sterol a type of Lipid and embedded in Lipid Bilayer thus allowing Ion movement across it.

79- Basement membrane possess negative charge due to:
A- Cadherin
B- Desmosomes
C- Elastin
D- Laminin
Ans: D

80- O_2 and CO_2 diffuse through cell membrane because:
A- Their size is small
B- They are lipid soluble
C- They are water soluble
D- Do not cross cell membrane
E- Carrier mediated movement across cell membrane
Ans: A

81- Skeletal muscles seen on light microscopy. What is likely to appear?
A- Mononuclear
B- Have branching fibers
C- Light and dark stripes
D- No light and dark stripes
Ans: C

82- Initiation of action potential in skeletal muscle by stimulating its motor nerve:
A- Require the release of acetylcholine
B- Require temporal facilitation
C- Require spatial facilitation
D- Require the release of NE
Ans: A

83- During exercise blood flow to which organ increases?
A- Skeletal muscle
B- Kidney
C- Heart
D- Brain
Ans: A

84- Calcium in skeletal muscle ER is bound with:
A- Desmin
B- Myosin
C- Calmodulin
D- Calsequestrin
Ans: D

85- Out of the following characteristics the most similar between pulmonary & skeletal muscle capillaries is:
A- Capillary hydrostatic pressure
B- Capillary oncotic pressure
C- Capillary permeability
D- Interstitial hydrostatic pressure
E- Interstitial protein concentration
Ans: E

86- Energy house of cell:
A- SER
B- RER
C- Mitochondria
D- Golgi bodies
E- Nucleus
Ans: C

87- Maximum no. of sodium channels are present in:
A- Nodes of ranvier
B- Axon
C- Dendrites
D- Myelin sheath
Ans: A

88- Equalization of gases on both side of membrane:
A- Active transport
B- Simple diffusion
C- Pinocytosis
D- Facilitated diffusion
Ans: B

89- Actively dividing cells have:
A- Prominent Nuclei
B- Pale nuclei
C- Prominent Cytoplasm
D- Prominent Cell membrane
Ans A

90- A cell that has no potential for division is:
A- Liver cells
B- Heart
C- Gastric mucosa
D- Kidney
Ans: B

91- How the number of mitochondria is increased?
A- Fragmentation
B- Self-replication
C- Protein synthesis
D- Lipid synthesis
Ans: B

92- Drugs detoxification done by:
A- SER
B- RER
C- Golgi
D- Mitochondria
E- Cell membrane
Ans: A

93- Cells that do not regenerate:
A- Stable cells
B- Permanent cells
C- Labile cells
D- Germ cells
Ans: B

94- Chromosomes are paired in:
A- Prophase
B- Telophase
C- Metaphase
D- Anaphase
Ans: A

95- Cell organelle which can replicate on i own?
A- Golgi apparatus
B- Lysosomes
C- Mitochondria
D- Peroxisome
Ans: C

96- Potential recorded after stimulati

CamScanner

nerve trunk depolarization is:

A- Peak potential
B- After depolarization
C- Spike potential
D- Compound potential
Ans: D

97- Fastest speed of conduction:

A- Alpha
B- Delta
C- Beta
D- Gamma
Ans: A

98- Axoneme of cilia contains how many microtubules:

A- 15
B- 20
C- 25
D- 30
Ans: B

99- Absorption of glucose in kidney:

A- Passive transport
B- Primary active
C- Facilitated
D- Secondary active transport
Ans: D

100- A band in sarcomere consists of:

A- Myosin only
B- Actin only
C- Myosin and some actin
D- Actin and some myosin
Ans: C

101- Eaten lambert syndrome autoantibodies are present against:

A- Voltage gated Na channels
B- Voltage gated Ca channels (presynaptic)
C- Nicotinic receptors
D- Voltage gated K channel
Ans: B

102- Similarity between Cardiac and skeletal muscles:

A- Transverse striations
B- Mononucleated
C- Intercalated disc
D- Lacks T tubules
Ans: A

103- A girl holding 3 books. 4th book added upon causing falling of books. Reflex involved is

A- Inverse stretch reflex
B- Flexor reflex
C- Extensor reflex
D- Crosses extensor reflex
Ans: A

104- Which of the following is true?

A- Heterohromatin is transcriptionally active to form mRNA
B- Nucleolus helps in the formation of ribosomal RNA
C- Nuecleolus form DNA
D- None
Ans: B

105- Similarity between Cardiac and smooth muscles:

A- Transverse striations
B- Mononucleated
C- Contains T tubules
D- Shows rapid contractions
Ans: B

106- RPE and sensory retina bound together by:

A- Carbohydrates
B- Proteins
C- Lipids
D- GAG's
Ans: D

107- Which of the following muscles have highest no. of Mitochondria?

A- Cardiac muscle
B- Skeletal muscle
C- Smooth muscle
D- None
Ans: A

108- True regarding smooth muscle:

A- They Are Striated
B- They Are Multi Nucleated
C- They Are Mononucleated
D- Contains T tubules
Ans: C

Explanation:

Skeletal muscle	Cardiac muscle	Smooth muscle
Striated	Striated	Non - striated
No intercalated disc	Intercalated disc	No intercalated disc
Voluntary	Involuntary	Voluntary
Multinucleated	Mononucleated	Mononucleated
Troponin to bind calcium	Troponin to bind calcium	Calmodulin to binds calcium
T tubules forms Triadic contacts with reticulum at A-I junctions	T tubules forms Dyadic contacts with reticulum near Z lines	Lacks T tubules
Surface memberane lacks calcium channels	Voltage gated Calcium channels	Voltage gated Calcium channels

109- Which of following decreases the neuronal excitability in RMP?

A- Hyperkalemia
B- Hypokalemia
C- Hypocalemia
D- Hyponatremia
Ans: B

110- Patient with vomiting developed hypokalemia with some gastric problems, patient has given IV potassium. How will it enter intracellularly?

A- H-K pump
B- Na- K pump
C- Leaky channels
D- Na-cl pump
Ans: B

111- Which of following increases the neuronal excitability in RMP?

A- Hyperkalemia
B- Hypokalemia
C- Hypocalemia
D- Hyponatermia
Ans: A

112- G protein phospholipase C increases intracellular concentration of:

A- Calcium ions
B- Chloride ions
C- Potassium ions
D- Magnesium ions
Ans: A

113- Which intracellular junction is like a spot weld between 2 cell?

A- Hemidesmosome
B- Adhering junction
C- Desmosome
D- Gap junction
Ans: C

114- Which of the following is responsible for actin and myosin bridging?

A- Na
B- K
C- Na & K
D- Ca
Ans: D

115- A weight lifter was lifting weight in a competition. Suddenly his arms gave up and he dropped the weight. What is responsible for that?

A- Golgi tendon organs
B- Muscle spindles
C- Ruffini corpuscle
D- None
Ans: A

116- Alcohol detoxification occurs through:

A- Endoplasmic reticulum
B- Mitochondria
C- Nucleus
D- Peroxisomes
Ans: D

117- Hyperexcitablity of neuron due to deficiency of which of the following in ECF:

A- Na
B- Mg
C- Ca
D- K
E- Cl
Ans: C

Explanation:

CA guarded Na channels on neuronal membrane → Less Ca means → Less guarding → Increase Na influx into neuron → Hyper excitability.

118- Action potential transfer from once cell to another through:

A- Desmosomes
B- Tight junction
C- Gap junction
D- Intercalated disc
Ans: C

119- Clearance of defective protein is the function of:

A- Proteosome
B- Endoplasmic reticulum
C- Golgi bodies
D- Nucleus
E- Cell membrane
Ans: A

CamScanner

120- **Rigor mortis is due to:**
A- Decrease ATP
B- Decrease phosphocreatine
C- Increase ATP
D- Increase intracellular calcium
Ans: A

Explanation:
When muscle fibers are completely depleted of ATP and phosphoryl creatine, they develop a state of rigidity called rigor mortis. **Ref:** BRS physiology

121- **Which of the following cell has no nucleus?**
A- RBC
B- Lymphocytes
C- Monocytes
D- Plasma cells
E- Neutrophils
Ans: A

122- **If a drug is absorbed by simple diffusion then?**
A- Requires energy
B- Requires carrier
C- Lipid soluble
D- Against concentration gradient
Ans: C

Explanation:
- Carrier – Facilitated diffusion, Active transport.
- Energy – Active transport
- Fat solubility / Hydrophobic substances – Simple diffusion. **Ref:** BRS physiology

123- **Cross bridges in skeletal muscles formed by:**
A- Actin
B- Myosin
C- Troponin
D- Tropomyosin
Ans: B

124- **Feature of Glycocalyx:**
A- Glucose containing
B- Protein rich
C- Fatty coat
D- All of the above
Ans: A

125- **Longest phase:**
A- G1
B- M phase
C- G2 phase
D- S phase
Ans: A
Explanation
- S – 5 to 6 hours
- G2 – Short (3 to 4 hours)
- M – Shortest (2 hours)

126- **Sarcomere is present between which of the following?**
A- Two A lines
B- Two M lines
C- Two Z lines
D- Two I lines
Ans: C

127- **Which adhesion belongs to CAM family responsible for adhesion during embryonic development?**
A- Nerve cell adhesion
B- Cadherin
C- Integrin
D- Selectin
E- Adhesion cell of subclass of IgG family
Ans: B

Explanation:
The cell adhesion molecule E-cadherin is ultimately necessary for the transition from compacted morula to the formation of the blastocyst to ensure correct establishment of adhesion junctions in the trophectoderm.

128- **Cell producing Granulomatous and fibrous tissue is**
A- Collagen
B- Elastin
C- Glial cells
D- Fibroblast
Ans: D

129- **Which one is phagocytic**
A- Juxtaglomerular cell
B- Erythropoietin
C- Mesangial cell
D- Peritubular cell
Ans: C

130- **Characteristic feature of platelets**
A- Non nucleated
B- Aggregate when bound to collagen fiber
C- Granulated
D- Derived from bone marrow
Ans: B

131- **Diffusion of gas directly proportional to**
A- Available surface area
B- Thickness
C- Decrease surface area
D- Sarcoidosis
E- Decrease temperature
Ans: A

132- **A patient with severe diarrhea. What infusion will be given to increase ECF and decrease ICF causing plasma expansion after osmotic equilibrium?**
A- 1 liter of 3 percent Nacl
B- 1 liter of 5 percent dextrose water
C- 1 liter Ringer lactate
D- 1 liter of 0.45 Nacl
Ans: A

133- **Mutation is defined as**
A- Permanent change in DNA
B- Change in mitochondia
C- Temporary Change in DNA
D- Permanent Change in RNA
E- Damage peroxisome
Ans: A

134- **Which play active part in phagocytosis**
A- Monocytes
B- Neutrophills
C- Lymphocytes
D- Basophil
E- Plasma cell
Ans: B

135- **Negative charge of basement membrane is due to:**
A- Elastin
B- Laminin
C- Cadherin
D- Heparan sulphate
Ans: D (BRS) D> B

136- **In healthy adult the amount of ICF is:**
A- 42L
B- 28L
C- 11L
D- 14L
E- 5L
Ans: B

137- **Peroxisomes produced by**
A- Lysosome
B- Golgi body
C- Mitochondria
D- SER
Ans: D

Explanation:
- Peroxisome Originate from – SER
- Lysosome Originate from – Golgi Body

138- **Flow through Orifice depends on**
A- Viscosity
B- Length
C- Density
D- Pressure
Ans: C

Explanation:
- Flow through Orifice – Density
- Flow through medium – Viscosity

139- **Basal bodies are formed by:**
A- Centrioles
B- Centrosome
C- Precentrioles
D- Lysosomes
E- Peroxisomes
Ans: A

140- **Extracellular and intracellular potassium maintenance**
A- Aldosterone
B- Na/K Pump
C- Cortisol
D- GH
Ans: B

141- **Transport of D-and L-glucose proceeds at the same rate down an electrochemical gradient by which of the following processes?**
A- Simple diffusion
B- Facilitated diffusion
C- Primary active transport
D- Cotransport
E- Counter transport
Ans: A(BRS Mcq)

142- **Patient with 3rd degree burn lost so much of water and electrolytes; he will have low voltage action potential due to deficiency of which electrolytes?**
A- Hyponatremia
B- Hypocalcemia
C- Hypomagnesemia
D- Hyperkalemia
E- Hypernatremia
Ans: A

Explanation:
- **Hypokalemia** – Decrease nerve excitability in RMP & difficult to create AP
- **Hyperkalemia** – Increase nerve excitability in RMP
- **Hyponatremia** – Decrease height or Slop of action potential
- **Hypernatremia** – Increase height or Slop of action potential.
- **Hypocalcemia** – Increase excitability
- **Hypercalcemia** – Decrease excitability

CamScanner

143- 0.5 gram of albumin/100 ml is present in which fluid?
A- Lymph
B- Blood
C- Urine
D- Serum
Ans: A

144- Man uncovered lying in room at 28 temp heat loss by:
A- Conduction
B- Convection
C- Radiation
D- Convection
Ans: C

Explanation:
- Patient naked heat loss by – Radiation
- Patient naked and lying on surface (table) heat loss by – Conduction
- Patient naked and temp mention heat loss by – Radiation + Conduction
- Patient naked and humidity mention heat loss by — Convection

145- Posture maintenance by muscle spindle is done by:
A- Increase in muscle spindle length
B- Muscle stretch by alpha motor neurons
C- Muscle stretch by gamma motor neurons
D- Progressive lengthening and shortening of Muscle fiber
Ans: D

146- Normal fluid loss in 24 hours through perspiration is:
A- 200-400ml
B- 400-500ml
C- 500-600ml
D- 600-800ml
Ans: A

147- Mean transportation rate of mucus in Nasal Mucosa?
A- 6mm/min
B- 12mm/min
D- 14 mm/min
E- 20 mm/min
Ans: B

148- What is quick way to lose heat?
A- Cutaneous vasodilation
B- Vasoconsteiction
C- Shivering
D- Catecholamines
Ans: A

149- Sarcomere is seen on H zone , What will be seen on relaxed muscle
A- Thin filaments
B- Thick filaments
C- Thin filaments arranged on array
D- Thick filaments arranged in array
E- Thin filaments surrounded by thick filaments
Ans: B

150- In which condition permeablity of the membrane increase?
A- Polycythemia
B- Increase size particle
C- Decrease temperature
D- Increase solubility in fat
Ans: A

151- Nuclear membrane differ from plasma membrane because it is:
A- Associated with SER
B- Has Large pores
C- Continue with mitochondria
D- Derived from golgi
Ans: A

152- Which part of intermediate filaments involve in cell repair?
A- Desmin
B- Vimentin
C- Cytokeratin
D- Microtubulin
Ans: C

Explanation:
Desmin: Maintain structural and functional integrity
Vimentin: Attachments, cell migration, cell signaling
Cytokeratin: Resist mechanical stress
Microtubulin: Cell division

153- Action potential in cardiac cells increase in extracellular by?
A- Na and calcium
B- K and calcium
C- Na and K
D- Mg and K
Ans: A

154- Function of macrophages include
A- Produce cytokine
B- Activate T cell
C- Present antigen to CD4 T cell
D- Produce antibodies
Ans: C

155- A girl doing exercise heavily to maintain fitness there will be decrease In
A- HR
B- Skeletal muscle Vascular resistance
C- Blood pressure
D- N2O
Ans: B

156- Contraction of skeletal muscle involve activity of large number of proteins. Protein required for relaxation of muscle is
A- Calciquesterin
B- Actin
C- Mysoin
D- Tropomyosin
Ans: D

157- Ribosome composition isFeb - –
A- DNA
B- RNA +Proteins
C- Lipids
D- Fats
E- Glycogen phosphorylase
Ans: B

158- Transport of glucose across cell —— membrane occurs by——
A- Active transport
B- Facilitated difusion
C- Simple difusion
D- Passive transport
Ans: B

159- Microtubules are present in–
A- Mitochondria
B- Centrioles
C- Golgi body
D- Lysosomes
E- Peroxisomes
Ans: B

160- Pregnant lady delivered a baby after - parturition regression of enlarged uterus & breast is –done by which of these? -
A- Mitochondria
B- Lysosomes
C- Golgi apparatus
D- Ribosomes
E- Endoplasmic reticulum
Ans: B

161- Nissle granule present in:
A- Granular endoplasmic reticulum
B- Smooth endoplasmic reticulum
C- Golgi bodies
D- Lysosomes
Ans: A

162- Students are asked to observe dead body after 10h of death; dead body is in rigor mortis it is due to:
A- Increase phosphate
B- Separation of Actin-Myosin bridges
C- Failure of separation actin myosin crosses bridges
D- Failure to contract troponin
Ans: C

Explanation:
- For Separation of Actin-Myosine cross bridges ATP is needed to cause muscle relaxation.
- When death occurs No aerobic respiration no ATP Will be produced so no Separation of actin-myosin bridges

163- Soon after excitation there will be coupling of:
A- Break of actin and myosin
B- Cross linkage of actin and myosin
C- Cross linkage of tropomyosin and myosin
D- Cross linkage of actin and tropomyosin
Ans: B

164- Positive feedback results in?
A- Harmone regulation
B- Child birth
C- CO2 transport
D- O2 transport
Ans: B

Explanation:
Positive Feedback
- Child Birth
- Blood clotting

Negative feed back
- CO2 transport
- Control of optimal internal environment
- Regulation of Hormones

165- In 60% of body fluid how much of it will be present in interstitial fluid?
A- 11L
B- 42L
C- 28L
D- 42L
E- 52L
Ans: A

166-Most Abundant ion in ICF is:
A- Cl ions
B- Na ions
C- K ions
D- Phosphorus ions
E- Ca ions
Ans: C

CamScanner

167- Ion present in large amount in ECF is:
A- Na
B- Cl
C- K
D- Ca
Ans: A

168- Laminar flow relationship
A- Directly to length
B- Inverse to Viscosity
C- Directly to radius
D- Direct to volume
Ans: B

169- Which ion is required for secretory substance through exocytosis?
A- Cl
B- Mg
C- Ca
D- Na
E- K
Ans: C

170- Neurophysiologist while stimulating a nerve is unable to generate action potentional due to
A- Hypernatremia
B- Hyponatremia
C- Hyperchloremia
D- Hypokalemia
Ans: D

171- Percentage of Plasma in ECF is:
A- 40%
B- 30%
C- 15%
D- 10%
Ans: B

172- Local cell response to action potential is:
A- All or none
B- Increase amplitude with increase stimulus
C- No amplitude with stimulus
D- Decrease amplitude with increase stimulus
Ans: B

173- Which substance when exposed to cell membrane form phospholipase C?
A- Camp
B- Cgmp
C- Tyrosine receptor
D- ANP
Ans: C

174- Calcium reabsorbed from sarcomere via:
A- Facilitated diffusion
B- Active transport
C- Passive diffusion
D- Osmosis
Ans: B

175- Cell arrested in diplotene which is phase of?
A- Metaphase
B- Telophase
C- Anaphase
D- Prophase
E- Interphase
Ans: D

Explanation:
All primary oocytes are formed by the fifth month of fetal life and remain dormant in prophase (Diplotene stage) of meiosis I until puberty.

176- Which of the following is a direct consequence of the malfunction or inhibition of the Na+/K+ pump in cells?
A- Increased intracellular potassium (K+) concentration
B- Decreased intracellular sodium (Na+) concentration
C- Increased intracellular calcium (Ca2+) concentration
D- Hyperpolarization of the cell membrane
E- Inhibition of action potential propagation
Ans: C

177- The size of the drug is more than 1000, so the drug will move into cells via:
A- Osmotic pressure
B- Carrier protein
C- Simple diffusion
D- Pinocytosis
Ans: D

Explanation:
- Transport through cell membrane involving Actin, Myosin and clathrin -- Pinocytosis
- If a drug molecular weight is less than 1000 Transport occurs via -- Diffusion
- If a drug molecular weight is more than 1000 Transport occurs via --Pinocytosis

178- Basophilic staining of cell is due to:
A- Nucleus
B- SER
C- Ribosomes and HB
D- Mitochondria
E- Peroxisomes
Ans: C

179- What is seen in A band when muscle is relaxed?
A- Thin filament
B- Thick filament
C- Thick with few thin filament
D- No filament
Ans: C

180- Which one is required to initiate muscle contraction?
A- ATP
B- Calcium released from Sarcoplasmic reticulum
C- Stimulus in the form of Action potential
D- Tropomyosin
Ans: B

181- When a firm stroke with a pointed object is applied on the skin, there is spreading redness due to arteriolar dilatation (flare), the response is due to?
A- Axon reflex
B- Mechanical stimulation
C- Tissue injury
D- Nerve block
Ans: A

182- Which of following is essential for skeletal muscle contraction?
A- Tropomyosin
B- Depolarization of membrane
C- Repolarization of membrane
D- Na ions
E- ATP
Ans: E

183- Internal homeostasis is maintained by:
A- Positive Feed back
B- Negative Feed back
C- Passive
D- Immune response
E- Primary inhibition
Ans: B

184- Increased Amplitude and increased frequency of potential energy causes:
A- Increased refractory period of action potential
B- Decrease refractory period of action potential
C- No effect on action potential
D- High voltage complexes
Ans: A

185- Facilitated diffusion of glucose in PCT is increased by:
A- Decrease level of Na+/K+ ATPase
B- Increased levels of Na+/K+ ATPase
C- Increase Na+/CA ATPase
D- Increase Intracellular Na
Ans: B

186- A patient having temperature of 99F, cold clammy skin, sweating profusely, and working on a hot day, brought to the hospital in semiconscious state is most likely due to:
A- Heat Stroke
B- Heat Exhaustion
C- Excessive Sweating
D- Normal Phenomenon
Ans: B

Explanation:
Heat exhaustion is characterized by excessive Sweating and cold, clammy skin
Heat Stroke is characterized by Temperature above 100 & absence of sweating with loss of Consciousness

187- In mitochondria proteins generated by:
A- Golgi apparatus
B- Nucleus genes
C- Na k ATPase
D- Endoplasmic reticulum
Ans: D

188- Excess normal saline infused this will lead to:
A- Increase blood volume
B- Increase osmolarity
C- Decrease Na excretion
D- Increase renin
E- Increase angiotensin
Ans: A

189- Mitochondrial can generate energy because it:
A- Has RNA
B- Has self-replication
C- Double stranded
D- Can't generate energy
Ans: B

190- Exosecretion is caused by which ion:
A- Sodium
B- Calcium
C- Potassium
D- Chloride
Ans: B

191- ECF is measured by following:
A- Mannitol & Inulin
B- Antipyrene
C- Evan blue
D- PAH
E- RISA
Ans: A

Explanation:
- TBW-Radioactive water (Tritiated water in pure form called Tritium, 3H2O)
- Heavy water (Deutrium 2D2O) and Antipyrene
- ECF – Mannitol, Inulin and sulfate
- Plasma – Evan Blue and RISA
- Interstitial fluid – ECF – Plasma
- ICF – TBW – EC

CamScanner

192- Regarding cilia consist of:
A- 9 doublets microtubules plus 2 singlets.
B- 9 doublets only
C- 9 triplets only
D- 9 triplets plus 2 singlets
Ans: A

193- No action potential occur in:
A- Hyperkalemia
B- Hypercalcemia
C- Hyponatremia
D- Hypernatremia
Ans: C

194- Regarding Facilitated diffusion & cotransport:
A- No ATP needed
B- Carriers independent
C- Carried dependent
D- Down gradient
Ans: C

195- If temperature of set point increase, then there will be decrease in:
A- Shivering
B- Sweating
C- BP
D- Vasoconstriction
E- Permeability
Ans: B

Explanation:
- If temperature of set point increase (Hypothermic state) then dec. in sweating and Inc. in shivering.
- If temperature of body increase (Hyperthermic state) above set point decrease in shivering and increase in sweating.

196- ICF as compared to ECF has:
A- Increase glucose
B- Increase bicarbonates
C- Increase chloride
D- 1/3rd of volume
E- Increase amino acids
Ans: A

197- NA channel inactivation occurs in:
A- Depolarization
B- Repolarization
C- Absolute refractory period
D- Partial refractory period
Ans: C

198- Primary active transport use:
A- Na/K ATPase
B- H/K ATPase in parietal cell
C- Need no energy
D- Down the electrochemical gradient
Ans: B

199- From Lower to higher gradient by carrier mediator is:
A- Simple diffusion
B- Passive diffusion
C- Osmosis
D- Facilitated diffusion
Ans: D

200- Man waiting for the bus from 60 minutes in moderate hot environment. How body will regulate temperature:
A- Shivering
B- Errection of erector pili
C- Posterior hypothalamus activation
D- Cutaneous Hyperemia
E- Vasoconstriction
Ans: D

201- With rapidly repeated stimulus to a skeletal muscle activation of contractile mechanism occur repeatedly before any relaxation has occurred (Continuous contraction without relaxation) and individual response run into one another such response is called:
A- Tetanic contraction
B- Tetanus
C- Tetany
D- Spasm
Ans: A

Explanation:
Tetanic contraction – No relaxation period
Tetany – Has some relaxation in between

202- Feature common in simple and facilitated diffusion of glucose?
A- Occur against gradient
B- Occurs Down an electrochemical gradient
C- They need energy
D- Simple diffusion use carrier and facilitated without carrier
Ans: B

203- Flexor reflex is carried by:
A- Monosynaptic
B- Muscle spindle
C- Noxious stimulus
D- By tapping with hammer
Ans: C

204- ATP synthesis occurs in:
A- Mitochondria
B- Cytoplasm
C- Nucleus
D- SER
Ans: A

205- Humidity in air is measured by?
A- Hygrometer
B- Monometer
C- Sphygmomanometer
D- Heliometer
Ans: A

206- Infrared Thermometer uses:
A- Thermopile
B- Thermocouple
C- Thermistor
D- Resistance Thermometer
E- Bourdon Tube
Ans: A

207- In healthy man metabolic requirements may exceed the oxygen supply in which?
A- Bain
B- Kidney
C- Heart
D- Skeletal muscle
E- Liver
Ans: D

Explanation:
- Muscle can do anerobic glycosis during heavy exercise that will help them to meet the high metabolic demand

208- Hyperpolarization of neuron due to increase influx of
A- Potassium
B- Sodium
C- Chloride
D- Magnesium
Ans: C

209- Mechanism of chloride reabsorption in later segment of PCT is?
A- Passively due to concentration gradient
B- Active transport
C- Passively due to electric gradient
D- Facilitated diffusion
Ans: A

210- Resting Membrane potential due to
A- Ca influx
B- K efflux
C- Na influx
D- Mg influx
Ans: B

211- What is required for muscle contraction?
A- Tropomyosin
B- Irritant
C- Stretch
D- J receptor
Ans: C

212- In enzymology, the term max refers to the maximum rate of reaction achieved by an enzyme when it is satura with substrate. Which of the following mechanisms of transport is most analogous to Vmax?
A- Simple diffusion
B- Facilitated diffusion
C- Active transportv
D- Endocytosis
E- Exocytosis
Ans: **B**

213- cAMP second messenger system acts through:
A- Protein change
B- Receptors
C- Signals
D- Clearance
E- Enzymes
Ans: **B**

214- What is necessary in G1 for next phase to occur
A- RNA synthesis
B- DNA synthesis
C- Protein synthesis
D- Chromosome duplication
Ans: **B**

215- In case of healing and repair, ATP regeneration and Creatinine kinase synthesis occurs in which phase?
A- Initial heat
B- Heat of relaxation
C- Active phase
D- Passive heat
Ans: **C**

216- Second polar body is formed in which of the following?
A- Meiosis 1
B- Mitosis
C- Meiosis 2
D- Asexual reproduction
Ans: **C**

217- During protein synthesis which of the following features is seen?
A- Pale nuclei
B- Prominent Cytoplasm
C- Prominent Cell membrane
D- Cell has prominent nucleoli
Ans: **D**

CamScanner

218- Regarding action potential in nerve fibers is
A- Decrease after travelling few distance along axon
B- Caused by Na efflux
C- K efflux
D- Na influx reverses conc. gradiant across membrane
E- Terminated by efflux of K
Ans: E

219- Cardiac muscle can't be tetanized due to
A- Long refractory period
B- Gap junction
C- Short refractory period
D- All or none
Ans: A

220- Proerythrocyte have basophilia due to
A- Polyribosomes
B- Heparin & Histamine
C- Mitochondria
D- SER
Ans: A

221- Excitable Cells property is:
A- All or none action potential
B- Short refractory period
C- More amplitude of stimulus can increase amplitude of action potential
D- With more stimulation action potential can occur above threshold
Ans: D

222- Bond btw Actin covered by tropomyosin is between:
A- Actin-tropomyosin
B- Trop I- trop C
C- Actin-I band
D- Actin-Myosin
E- Actin-Troponin
Ans: E

223- Steroid synthesis occur in
A- Lysosones
B- Golgi apparatus
C- SER
D- RER
Ans: C

224- Na/K pump activity is associated with which hormone?
A- Insulin
B- Glucagon
C- Epinephrine
D- Histamine
Ans: A

225- Excitation Contraction coupling in muscle by:
A- Actin+Myosin Cross bridges
B- Hydrolysis of ATP into ADP
C- Ach Release
D- Calcium-Troponin C coupling
Ans: D

226- Patient laying uncovered in OT table heat loss will be by
A- Radiation
B- Convection
C- Conduction
D- Evaporation
Ans: C

Explanation:
- Patient naked heat loss by – Radiation
- Patient naked and lying on surface (table) heat loss by – Conduction
- Patient naked and temp mention heat loss by – Radiation + Conduction
- Patient naked and humidity mention heat loss by — Convection

227- Negative charge of basement membrane is due to:
A- Elastin
B- Laminin
C- Cadherin
D- Proteoglycan
Ans: D (BRS) D> B

Explanation:
- Heparin Sulphate>Proteoglycan>Laminin

228- Increased Potassium levels can cause which of the following?
A- Decrease action potential
B- Tachycardia
C- Flacidity
D- Spasticity
E- Rigidity
Ans: C

229- Patient with ETT heat loss is by
A- Conduction
B- Convection
C- Radiation
D- Evaporation
Ans: D

230- Maximum number of Na+ channels are present in:
A- Internodes
B- Axon Hillock
C- Dendrites
D- Cell body of neuron
E- Axons
Ans: B

231- Fatty acids & glycerol combine to form neutral fats in:
A- Golgi body
B- Lysosome
C- SER
D- Peroxisome
E- Mitochondria
Ans: A

232- Which Filament Joins Intercellular Structures?
A- Fibronectin
B- Elastin
C- Titin
D- Elastases
Ans: A

233- Cell Repolarization occur due to outward movement of
A- Sodium
B- Potassium
C- Chloride
D- Magnesium
Ans: B

234- Cell produce abnormal proteins and fragments degraded by?
A- Peroxisome
B- Lysosome
C- Phagolysosome
D- Proteasome
E- Nucleosome
Ans: D

235- Receptors act as transducers:
A- By increasing response to repeated stimulus
B- Augument the stimuli
C- Locally depolarize channels
D- All or none potential
Ans: A

236- Glucose transported through placenta by:
A- Facilitated diffusion
B- Simple diffusion
C- Co transport
D- Triporter
E- Uniporter
Ans: A

Explanation:
- Glucose transport across membrane due to its concentration difference – Facilitated diffusion.
- Glucose is absorbed in renal tubules through – 2ndry active transport (NA. glucose Co).
- Amino acids are absorbed from kidney to blood by – 2ndry active transport.
- Glucose transported to placenta by – Facilitated diffusion.
- Chloride and Urea transported by – Passive diffusion
- Oxygen taken up to lung through – Simple Diffusion > Passive diffusion.
- Local Anasthesia crosses Placenta by:Simple diffusion > Passive diffusion.
- Primary Active transport uses – Pump.

237- Gate theory of pain
A- Cominnation of different sensory stimuli
B- Specific stimuli from nociceptors
C- Sensory Noxious Receptors
D- Sensory Non-Noxious Stimulus
Ans: D

238- Cells with high steroids synthesis activity have abundant:
A- Mitochondria
A- RER
B- SER
C- Peroxisome
D- Ribosome
Ans: C

239- Two scientists were doing experiment Nerve conduction. Response changes everytime with same stimulation.Which one of the following is correct?
A- Increase Action potential
B- Conduction velocity
C- Directly proportional to Axon diameter
D- Direct to pressure
Ans: B

240- Excitation Contraction Coupling in Muscle by:
A- Actin+Myosin Cross bridges
B- Hydrolysis of ATP into ADP
C- AcetylCholine Release
D- Calcium-Tropinin C Coupling
Ans: D

241- Polychromasia in Erythyrocytes due to?
A- Hb ribosomes
B- Mast cells
C- Microtubules and filaments
D- Basophils
Ans: A

CamScanner

242- Which structure decreases in length during muscle contraction?

A- Actin
B- Myosin
C- A band
D- I band
Ans: D

Explanation:

- I Band Decrease
- Sarcomere Decrease
- A Band Unchanged
- H zone Disappear

243- Gaseous exchange in the lungs primarily occurs via which of the following mechanisms?

A- Passive diffusion
B- Osmosis
C- Active transport
D- Facilitated diffusion
Ans: A

244- Where are ribosomes primarily located in the cell?

A- Smooth Endoplasmic Reticulum
B- Granular Endoplasmic Reticulum
C- Golgi Bodies
D- Mitochondria
Ans: B

245- Which structure helps prevent excessive muscle contraction?

A- Muscle spindle
B- Golgi Tendon Organ (GTO)
C- Alpha motor neurons
D- Neuromuscular junction
Ans: B

246- When skeletal muscle movement stops, which of the following processes is crucial for this cessation?

A- Removal of Ca^{2+} from troponin C
B- Removal of Ca^{2+} from the sarcoplasmic reticulum (SR)
C- Removal of nicotine from the neuromuscular junction (NMJ)
D- Inhibition of the postsynaptic neuron
Ans: A

247- Glucose transport in primary convoluted tubule occurs via:

A. Primary Active Transport
B. Simple diffusion
C. Facilitated Diffusion
D. Secondary active transport
E. Counter transport
Ans: D

248- In burn patient the excitability of cell is reduced with decrease action potential slope due to:

A- Hypocalcemia
B- Hyponatremia
C- Hypokalemia
D- Hypernatremia
E- Hyperkalemia
Ans: B

Explanation:

- Hypokalemia – Decrease nerve excitability in RMP & difficult to create AP
- Hyperkalemia – Increase nerve excitability in RMP
- Hyponatremia – Decrease height or Slop of action potential
- Hypernatremia – Increase height or Slop of action potential.
- Hypocalcemia – Increase excitability
- Hypercalcemia – Decrease excitability

249- Which of the following is false regarding the transmission of the action potential?

A- There are potassium channels located at each Node of Ranvier
B- Myelination increases the speed of transmission exponentially
C- Dendrites are important contributors to the action potential
D - The axon hillock is a Nissl free area
E- Each segment of the myelin sheath is interrupted by a Node of Ranvier
Ans: C

250- Regarding osmosis

A- It is a passive process
B- It is an energy dependent process
C- It occurs through protein channel
D- Osmolality represent number of solute particles.
E- Osmotic pressure is exerted by water molecule
Ans: D

251- Cyclic Amp Pathway is started by which of the following?

A- Receptors
B- Enzyme
C- Carrier Proteins
D- Outer Cell Membrane
E- Inner Cell Membrane
Ans: A

252- Complete termination of single skeletal muscle contraction by:

A- Calcium back into Sarcolemma
B- Calcium back into Neuromuscular Junction
C- Ach degradation by Acetylcholinesterase
D- Blockage of Neuromuscular Junction
Ans: C

253- Oxygen exchange in alveolar membrane occurs through process of

A- Active transport
B- Na/k atpase pump
C- Simple diffusion
D- Facilitated diffusion
Ans: C

254- Responsible for closure of inactivated sodium channels in nerve cells?

A- Refractory period
B- Hyperpolarization
C- Depolarization
D- Post Hyperpolarization
E- Repolarization
Ans: C

Explanation.

- Depolarization makes the membrane potential less negative (the cell interior becomes less negative). Depolarization causes rapid opening of the activation gates of the Na+ channel. Depolarization also closes the inactivation gates of the Na+ channel
- Hyperpolarization makes the membrane potential more negative (the cell interior becomes more negative).
- Hyperpolarization After potential. The K+ conductance remains higher than at rest for some time after closure of the Na+ channels. During this period, the membrane potential is driven very close to the K+ equilibrium potential.
- Absolute Refractory period is the period during which another action potential cannot be elicited, no matter how large the stimulus.

255- Similarity between co- transport and facilitated diffusion?

A- Down concentration gradient
B- Carrier-mediated
C- No ATP needed
D- Carrier Independent
Ans: B

256- Person drinks 600ml fluid, how much will be in plasma:

A- 100ml
B- 500ml
C- 50ml
D- 250ml
E- 200ml
Ans: C

Explanation:

- Total Body Water (TBW). Approximately 60% of body weight.
- Extracellular Fluid (ECF). Accounts for one-third of TBW, composed of:
- Plasma. 1/12th of TBW.
- Interstitial Fluid. 1/4th of TBW.
- Intracellular Fluid (ICF). Accounts for two-thirds of TBW.
- If the total water intake is 600 mL, and plasma constitutes 1/12th of TBW, the amount of water in plasma is calculated as:
- Plasma water= 1/12 Multiply 600 = 50ml
- Thus, 50 mL of the total water intake is distributed into plasma

257- A substance with Tmax means:

A- All of the substance below a threshold level will be absorbed
B- Requires max ATP for absorption
C- Transport across gradient
D- Transport due to concentration gradient
Ans: A

258- Abundant SER in liver at which area?

A- Center
B- Peripheral hiatus
C- Peripheral lobule
D- Central lobule
Ans: D

259- A person is lying on the ground at a temperature of 25°C. What is the primary mode of heat loss between the person and the ground?

A- Convection
B- Conduction
C- Radiation
D- Evaporation
Ans: C

Explanation:

- Patient naked heat loss by – Radiation
- Patient naked and lying on surface (Table) heat loss by – Conduction
- Patient naked and temp mention heat loss by – Radiation + Conduction
- Patient naked and humidity mention heat loss by – Convection

CamScanner

260- Resting membrane potential is achieved due to
A- Passive potassium channels
B- voltage gated potassium channels
C- passive sodium channels
D- voltage gated sodium channels
Ans: A

261- Why do Nerve endings in dendrites far away from cell body generate action potential
A- Causes hyperpolarization
B- Both Na and k Channels opening
C- Generate action potential that travel from backward to axon hillock
D- Inhibition of action potential generation
Ans: C

262- Responsible for closure of inactivated sodium channels in nerve cells?
A- Refractory period
B- Hyperpolarization
C- Depolarization
D- Post Hyperpolarization
E- Repolarization
Ans: C

Explanation.
- Depolarization makes the membrane potential less negative (the cell interior becomes less negative). Depolarization causes rapid opening of the activation gates of the Na+ channel. Depolarization also closes the inactivation gates of the Na+ channel
- Hyperpolarization makes the membrane potential more negative (the cell interior becomes more negative).
- Hyperpolarization Afterpotential. The K+ conductance remains higher than at rest for some time after closure of the Na+ channels. During this period, the membrane potential is driven very close to the K+ euilibrium potential.
- Absolute Refractory period is the period during which another action potential cannot be elicited, no matter how large the stimulus

263- Which of the following factor will help to stimulate the muscular contraction
A- Threshhold stimulus
B- Opening of voltage gated sodium channels
C- Stretch
D- Intracytoplasmic increase in calcium from sarcoplasm reticulum
Ans: D

264- Leptin acts on its receptor to mediate its effects. What is the mechanism of action, and what type of receptor changes occur?
A- Opens ion channels
B- Closes ion channels
C- Enzyme-linked receptor
D- Gs protein-coupled receptor
E- Gi protein-coupled receptor
Ans: C

265- Trained Athlete exercising in Humid Environment. Heat loss will be through?
A- Senseless Perspiration
B- Convection
C- Radiation
D- Conduction
E- Sweating through Evaporation
Ans: B

266- The difference of osmolarity b/w ICF and ECF: (Medicine Feb 2025):
A- 1mosm/l
B- 1.5mosm/l
C- 3 mosm/l
D- 5 mosm/l
E- No difference
Ans: A

267- Enzyme for Calcium enhancement? (Medicine Feb 2025):
A- Dynenin
B- Tubulin
C- Desmin
D- Myosin
Ans: D

268- How facilitated diffusion is different from simple diffusion? (Medicine Feb 2025):
A- It occurs Along the concentration gradient
B- It occurs Along the electrochemical gradient
C- It is a Passive process
D- Energy is not used.
E- It has Vmax
Ans: E

269- Example of positive feedback mechanism: (Medicine Feb 2025):
A- Hormonal Regulation
B- Vicious cycle leading to death
C- CO2 transport
D- Pathway to bring cellular environment back to normal
Ans: B

270- Calsiquestrin holds the calcium in: (Medicine Feb 2025):
A- Sarcoplasm reticulum
B- Transverse tubules
C- Mitochondria
D- Ribosomes
Ans: A

271- Ip3 mechanism in cellular signaling (Medicine Feb 2025):
A- Increase calcium
B- Increase c-AMPlevels
C- Activates protein kinase A
D- Stimulates NO production
E- Inhibits phosphodiestrase
Ans: A

272- In which phase ATP and CPK regenerates (Medicine Feb 2025):
A- Resting phase
B- Rapid contraction phase
C- Aerobic exercise phase
D- Recovery phase
E- Anaerobic exercise phase
Ans: D

273- Protoplasm is primarily composed of water. The second most common constituent is (Medicine Feb 2025):
A- Carbohydrates
B- Nucleic acids
C- Proteins
D- Lipids
Ans: C

274- Which type of system is most effective in maintaining homeostasis? (Medicine Feb 2025):
A- Positive feedback systems
B- High gain systems
C- Negative feedback systems
D- Low gain systems
Ans: C

275- Which molecule has the highest permeability across the cell membrane? (Medicine Feb 2025):
A- CO_2
B- K^+
C- Na^+
D- H_2O
E- O_2
Ans: E > A

276- When perfume is sprayed in a room, its scent spreads throughout the space. What is the primary mechanism responsible for this phenomenon? (Medicine Feb 2025)
A- Osmosis
B- Diffusion
C- Active transport
D- Filtration
Ans: B

277- In the human body, carbohydrates are the most abundant organic compounds. Which of the following is the second most abundant?(Surgery Feb 2025)
A- Fiber
B- Nucleic acids
C- Protein
D- Fats
Ans: C

278- Which of the following causes an increase in extracellular potassium?(Radiology Feb 2025)
A- Beta-2 agonist
B- Severe exercise
C- Excess aldosterone
D- Insulin deficiency
Ans: B

279- Calcium is released from which organelle:(Anesthesia Feb 2025)
A- mitochondria
B- lysosomes
C- peroxisomes
D- SER
Ans: D

280- Flow through Orifice depends on: (Anesthesia Feb 2025)
A- Viscosity
B- Length
C- Density
D- Pressure
Ans: C

Explanation:
Flow through Orifice – Density
Flow through medium – Viscosity

281- A Patient presented with vague symptoms of Cushing Syndrome. The doctor thought that problem is at the level of receptor. Where is the receptor of cortisol located? (Anesthesia Feb 2025)
A- Plasma membrane
B- Nucleus
C- DNA
D- Cytoplasm
Ans: D

CamScanner

CVS PHYSIOLOGY QUICK HINTS

Vessels

- Arteries are under high pressure
- Blood in arteries called **stress volume**
- Arterioles are the site of highest resistance in the cardiovascular system
- α1-Adrenergic receptors are found on the arterioles of the skin, splanchnic, and renal circulations.
- β2-Adrenergic receptors are found on arterioles of skeletal muscle
- Capillaries have the largest total cross-sectional and surface area and are thin walled
- Venules formed from merged capillaries
- Veins are under low pressure
- Blood in veins called **unstress volume** and have highest blood volume
- Veins have α1-adrenergic receptors

Arterial pressure

- The most important determinant of pulse pressure is stroke volume.
- Decreases in capacitance, such as those that occur with the aging process, cause increases in pulse pressure.
- MAP can be calculated approximately as diastolic pressure plus one-third of pulse pressure
- Left atrial pressure is estimated by the pulmonary wedge pressure.

ECG

- **P wave** – Atrial Depolirization
- **PR Interval** – Shows Atrial Depolirization to Ventricular Depolirization. It Represent time needed for impulses to reach from SA Node to Ventricle(From SA node through Atria , AV node , Bundle of His , Bundle branches and Purkinji to ventricle)
- **QRS Complex** – Ventricular depolirization
- **ST Segment** – Complete Ventricular Depolirization
- **QT/RT Interval** – Represent Entire Systolic phase (Ventricle depolarization to repolarization)
- **T Wave** – Ventricular Repolirization
- **U Wave** – Papillary Repolirization

Action potential

Atria ,Ventricles & Purkinji system

Phase 0

- Upstroke due to inward Na current

Phase 1

- Initial repolirization due to K efflux and low Na influx

Phase 2

- Plateau phase Inward Ca current and K efflux

Phase 3

- Repolirization due to K efflux and Low Ca influx

Phase 4

- It is RMP
- Inward and outward K current equal

SA node

Phase 0

- Upstroke due to Inward Ca current
- Same in AV node

Phase 3

- Repolirization due to K efflux

Phase 4

- It is slow depolarization.
- Accounts for the pacemaker activity of the SA node (automaticity).
- It is caused by an increase in inward Na

Conclusion

- Pace Maker activity of SA Node due to – Sodium Chanells
- Action Potential of Pace Maker due to – Calcium Chanells
- Action Potential of Cardiac Muscle due to – Sodium Chanells

Heart rate and location of pacemaker:

- SA node--60-80
- AV node--40-60
- Purkinje fibers --20-40

Speed of Heart Rate

- SA Node > AV Node > Purkinji fibers
- SA node – Slowest pre-potential / Works as synctium as it is able to generate impulses at a faster rate

Speed of conduction :

- Purkinje Fibers have highest speed of conduction due to -- Wide diameter > large no of gap junctions > Large no of sodium Channel >Less no of myofibril > Short refractory period
- Purkinje fibers > Bundle of His > Atria > Ventricles > SA node> AV node

Cardiac structure

- Sarcomere is the contractile unit of the myocardial cell.
- Sarcomere is similar to the contractile unit in skeletal muscle.
- Sarcomere runs from Z line to Z line.
- Sarcomere contains thick filaments (myosin) and thin filaments (actin, troponin, tropomyosin).
- Interclated disc occur at the ends of the cells. And maintain cell-to-cell cohesion. are present at the intercalated disks.
- Gap junction are low-resistance paths between cells that allow for rapid electrical spread of action potentials.
- Gap junctions are reason that the heart behaves as an electrical syncytium
- Preload determine by -- EDV (Depends on Venous return)
- After load determine by-- MAP
- TPR determine by-- Diastolic BP

Cardiac Cycle

Heart sounds

- **First Heart Sound** – Isovolumetric contraction (Closure of mitral and tricuspid valve)
- **Second Heart Sound** – Isovolumetric relaxation (Closure of aortic and Pulmonary valve)
- **Third Heart Sound** – Rapid ventricular filling (Normal in children, pregnancy and athletes)
- **Fourth heart sound** – Atrial Systole

Splitting of S2

Physiological Splitting:

- Delayed Closure of Pulmonary Valve >Early Closure of Aortic Valve
- Inspiration Leads to drop in intrathoracic pressure increase venous return increase RV filling increase RV ejection time cause delayed closure of pulmonary valve

Wide Splitting:

- Heard on Inspiration also
- Conditions leading to delayed RV emptying cause wide splitting by delayed closure of Pulmonary Valve e.g
- Pulmonary Stenosis
- Pulmonary HTN
- RBBB

Reverse Splitting:

- Heard on Expiration
- Conditions that cause delayed Aortic Valve closure e.g
- Aortic Stenosis
- Systemic HTN
- LBBB

Fixed Splitting:

- Heard in ASD
- No effect of respiration

CamScanner

Cardiac Pressures

- R ventricle Pressure during **Systole – 25**
- R ventricle Pressure during **Diastole – 0-8**
- R ventricle Pressure at which **Pulmonary Valve** Open – **8mmhg**
- L ventricle Pressure at which **Aortic Valve** Open – **80mmhg**
- Max Aortic Pressure – **Reduced Ejection**
- Min Aortic Pressure – **Isovolumetric Contraction**
- Max Ventricular Pressure – **Rapid Ejection**
- Min Ventricular Pressure – **Rapid Filling**
- Max Ventricle **Filled – Atrial Systole**
- Max Ventricle **Filling – Rapid Filling**
- Max Pulse Pressure – **Dorsalis pedis > Femoral > Popliteal > Aorta**
- Highest Systolic Pressure – **Renal Artery**

JVP

C Wave

- ✓ **C wave** – Right ventricle contraction (Closed tricuspid valve bulging into atrium)

A Wave

- ✓ **A wave** – Shows Atrial Contraction
- ✓ **Prominent A wave** –Seen in T.S, P.S And Pulmonary HTN
- ✓ **Giant A wave** – Seen in AV Dissociation, Complete Heart block

X Descent

- ✓ **X descent** – Closed Tricuspid Valve downward displacement during rapid ventricular ejection phase
- ✓ **Absent X descent** – Due to RHF and T.R

V Wave

- ✓ **V wave** – Increase Right atrial pressure due to filling against closed tricuspid valve
- ✓ **Prominent V wave** – Seen in T.R

Y Descent

- ✓ **Y descent** – RA emptying into RV
- ✓ **Slow Y descent** – Due to T.S
- ✓ **Rapid Y descent** –Due to Constrictive pericarditis

Absent Y descent – Due to Cardiac temponad

Special Circulation

Cornonary

- It is controlled almost entirely by local metabolic factors.
- It exhibits autoregulation.
- It exhibits active and reactive hyperemia.
- The most important local metabolic factors are hypoxia and adenosine.

Cerebral

- It is controlled almost entirely by local metabolic factors.
- It exhibits autoregulation.
- It exhibits active and reactive hyperemia.
- The most important local vasodilator for the cerebral circulation is CO2. Increases in PCO2 cause vasodilation of the cerebral arterioles and increased blood flow to the brain

Skeletal muscles

- At rest by sympathetic
- Stimulation of a`1 receptors causes vasoconstriction
- Stimulation of a2 receptors causes vasodilation
- During exercise By local metabolite

Skin

- It is entirely controlled by sympathetic

Regulation of arterial pressure

- Baroreceptor respond maximally to – Increasing BP (Ganong).
- Most rapid response to decrease BP – Baroreceptor.
- Most potent response to decrease BP – CNS Ischemic.
- CNS ischemic activate at – 60 or below 60mmHg (Guyton).
- Maintain During Shock – Baroreceptor
- Maintain As a whole – RAAS
- Short Term BP control – Baroreceptor
- Long Term BP control – RAAS

CamScanner

CVS PHYSIOLOGY

1. Female with haemorrhage while standing heart rate increases due to:
A- Increase peripheral resistance
B- Decrease in Venous Return.
C- Increase Venospasm
D- Decrease vasospasm
Ans: B

2. Increase in stroke volume with unchanged peripheral resistance and capacitance results in:
A- Decrease in pulse pressure with increase Mean arterial pressure.
B- Increase in pulse pressure with decrease in Mean arterial pressure
C- Increase in pulse pressure with Increase in Mean Arterial pressure
D- Decrease Heart rate
Ans: C

3. Lady diagnosed to have Mitral stenosis on ECG there will be:
A- Variable R-R interval
B- Irregular P-R
C- Irregular R-R
D- Regular R-R
Ans: C

4. Regarding Cardiac cycle:
A- S2 at start of T wave
B- P wave is followed by T wave
C- 1st heart sound in isovolumic ventricular contraction.
D- 1st heart sound in isovolumic ventricular relaxation
Ans: C

5. Max pressure dissociation occurs at:
A- Artero-Areteriorar junction
B- Arterioles to Capillary junction.
C- Capillary to venule
D- Aorta to arteries
Ans: B

6. Plateau of action potential is due to:
A- Na influx
B- Ca influx
C- K efflux
D- Ca efflux
Ans: B

7. Person with haemorrhage will have:
A- Tachycardia-Hypotension-Increase CVP
B- Tachycardia-Hypotension-decrease CVP
C- Bradycardia-Hypotension-decrease CVP
D- Bradycardia-Hypotension-increase CVP
Ans: B

8. ECG shows prolonged PR interval in
A- 1st Degree Heart Block
B- Bradycardia
C- 2nd degree
D- 3rd degree block
Ans: A

9. Nerve taking afferents from baroreceptors:
A- Glossopharyngeal
B- Facial
C- Trigeminal
D- Vagus
Ans: A

10. Blood flow to tissues is maintained by:
A- Ventricular contraction
B- Pulse pressure
C- Systolic pressure
D- Mean arterial pressure
Ans: D

11. Ventricle maximally filled in:
A- Rapid inflow
B- Atrial systole
C- Isovolumetric relaxation
D- Rapid ejection
Ans: B

12. Cardiac tissue is most vulnerable to ventricular fibrillation at which point:
A- At the start of action potential
B- Just at the end of action potential
C- When the action potential is about to end
D- At peak of action potential
Ans: B

13. When AV conduction velocity is slowed down, what will be seen?
A- Increased heart rate
B- Increased PR interval
C- Decreased PR interval
D- Decrease BP
Ans: B

14. The main circulatory drive of blood flow is:
A- Ventricular contraction
B- MAP
C- Pulse pressure
D- Atrial diastole
Ans: B

15. On ECG of a girl, you see saw tooth waves, with p waves in a ratio of 3:1. Her pulse is regularly irregular. Which of the following has occurred?
A- Atrial flutter
B- Atrial fibrillation
C- Ventricular tachycardia
D- Ventricular fibrillation
E- Ventricular flutter
Ans: A

16. About the chambers of heart:
A- Left ventricle pressure 125/120mmHg
B- Right ventricle pressure 25/5 mmHg
C- Right ventricle pressure 40/10 mmHg
D- Left ventricle pressure 100/25 mmHg
Ans: B

17. Regarding Second heart sound:
A- Low frequency than S1
B- Less duration than S1
C- High duration than S1
D- High frequency than S1
Ans: B

18. RE entry impulse in:
A- Ventricular Hypertrophy
B- A Fib
C- Conduction Block
D- Paroxysmal Ventricular Arrhythmia
Ans: D

19. ECG shows P wave is converted into small waves and QRS comes at irregular interval:
A- Atrial fibrillation
B- Atrial flutter
C- Ventricular fibrillation
D- Wolf Parkinson
Ans: A

20. In cardiac cycle atrial fibrillation occurs:
A- At start of QRS
B- At end of QRS
C- At peak of QRS
D- At the lower end of PR interval
Ans: D

21. Patient after RTA losses 2 liters of blood, which of the following will occur:
A- Increase venous tone
B- Slight stimulation of sympathetic system
C- Increase heart rate
D- Negative feedback compensation
Ans: A

22. Pulmonary capillary wedge pressure is measured by:
A- Rt. atrial
B- Indirect measures of left arterial pressure
C- Pulmonary artery
D- All
Ans: B

23. Cardiac index related to
A- Maximum performance on heart
B- CO to body surface area
C- Less performance of heart
D- None
Ans: B

24. Max heart rate occur during
A- Atropine infusion
B- Exercise
C- Increase body temp.
D- Anxiety
Ans: B

25. Maximum pressure in aorta during:
A- Ventricle systole
B- At the end of diastole
C- Slow ejection phase
D- Isovolumetric contraction
Ans: C
Explanation:
- Max Aortic Pressure -- **Reduced Ejection**
- Min Aortic Pressure -- **Isovolumetric Contraction**
- Max Ventricular Pressure -- **Rapid Ejection**
- Min Ventricular Pressure -- **Rapid Filling**

26. Most potent response in hypovolemic shock:
A. Sympathetic
B. Brain ischemic response
C. Parasympathetic
D- Chemoreceptot
Ans: B

27. Pulse wave velocity can be used to:
A- Detect blood pressure
B- Detect blood flow to the extremity
C- Above 2 were hot favorite
D- Detect HR
Ans: B

28. Baroreceptors detect:
A- Decreased blood pressure
B- Increase blood pressure
C- Change in arterial blood pressure
D- Change in venous blood pressure
Ans: C

CamScanner

29. If right atrial pressure is increased then
A- Increases cardiac output
B- Increases intra thoracic pressure
C- Increased heart rate
D- Variable BP
Ans: C

30. Heart rate is 75, PR interval is 0.3. if heart rate becomes 225, what will be the PR interval:
A- 0.1
B- 0.3
C- 0.05
D- 0.04
Ans: A

31. On ECG, QRS complex represents:
A- Ventricular systole
B- Ventricular depolarization
C- Ventricular diastole
D- Atrial systole
Ans: B

32. Bundle of HIS is supplied by:
A- RCA
B- LCX
C- Right marginal artery
D- Phrenic artery
Ans: A

33. Deep inspiration leads to
A- Increase compliance in pulmonary vasculature
B- S2 splitting
C- Delayed closure of semilunar valves occur
D- None
Ans: A
Explanation:
Deep inspiration leads to
- Decrease Cardiac output
- Increase Venous return
- Splitting of S2
- Increase Pulmonary Compliance

34. C wave shows:
A- Closure of seminar valve
B- Opening of semilunar valve
C- Closure of tricuspid valve
D- 3rd heart sound produced
Ans: C

35. Marked increase in cardiac output is due to:
A- Pregnancy
B- Exercise
C- Anxiety
D- Extreme of environmental temp
Ans: B>A

36. A woman had MI. 48 hours later she died. Now, on ECG there is irregular low voltage ways. What can be the pathophysiology?
A- Decrease CO
B- Decrease ejection fraction
C- Inc. in absolute refractory period
D- Reentry of impulses
E- Increase speed of conduction of impulse
Ans: D

37. Mean systemic filling pressure determined by:
A- CO
B- Venous return
C- TPR
D- Pulse
Ans: B

38. S4 is produced during
A- Ventricular filling
B- Ventricular filing during atrial systole
C- Contraction
D- Atrial flutter
Ans: B

39. Maximum left ventricular pressure in a young healthy individual:
A- 25
B- 50
C- 80-
D- 120
Ans: D

40. Purkinje fibers are fastest in transmitting impulse because:
A- They have wider diameter
B- They have large number of sodium channels
C- Intercalated junction
D- Gap junctions
Ans: A

41. Wave of depolarization passes from endocardium to epicardium related to
A- RR interval
B- QT interval
C- QRS complex
D- Ventricular activation time
Ans: C

42. In which condition atrial repolarization is shown on ECG?
A- Third degree complete heart block
B- Inspiration
C- During exercise
D- Atropine overdose
Ans: A

43. Patient with left ventricular hypertrophy. What is the cause of left axis deviation?
A- RBBB
B- Damaged myocardium of right ventricle
C- LBBB
D- Epicardium block
Ans: C

44. In a standing person, venous return from legs is facilitated by:
A- Contraction of skeletal muscles
B- Valves in veins
C- Increased contractility of heart
D- Veins
Ans: A

45. HR = 70, CO 5.6 L, EDV = 160ml calculate EF?
A- 0.5 L
B- 0.05L
C- 1L
D- 2L
Ans: A

46. Person standing from sitting position, Heart rate increases due to:
A- Decreased firing rate from baroreceptor
B- Increased firing rate from baroreceptors
C- Chemoreceptors.
Ans: A

47. Proteins that escape into tissues from blood vessels:
A- Reabsorbed by lymphatic system
B- Convert to be a part of defense system
C- Involve in metabolic activity
D- Involve arteries
Ans: A

48. Aortic pressure lowest during:
A- Atrial systole
B- Isovolumetric contraction
C- Isovolumetric relaxation
Ans: B

49. BP drops from 100mmHg to 70mmHg, it will result in:
A- Decrease in carotid sinus nerve activity
B- Increased sympathetic efferent effect on heart
C- Increased sympathetic efferent effect on heart
Ans: A

50. Calcium influx via slow channels in ventricle cells causes:
A- Ventricular ejection
B- Atrial systole
C- Rest were relaxation phases of cardiac cells
Ans: A

51. Increased 'a' wave in JVP due to:
A- Mitral stenosis
B- Mitral regurgitation
C- Aortic stenosis
D- Tricuspid stenosis
E- Aortic regurgitation
Ans: D

52. About The measurement of cardiac output by thermo dilution
A- Is accurate and easily repeatable
B- Involves measuring the integral of temperature change over time
C- Involves use of the latent heat of vaporization in the calculations
D- Is also known as the fick technique
E- May be inaccurate due to respiratory changes in the pulmonary artery temperature
Ans: E

53. Baroreceptor firing causes decrease in:
A- Heart rate
B- Venous compliance
C- Coronary blood flow
D- Cardiac Output
Ans: A

54. In shock, most important body response:
A- CNS ischemic response
B- Baroreceptor
C- Chemoreceptors
Ans: B

55. At rest actin is covered in its active site by:
A- Troponin
B- Tropomyocin
C- Myosin
Ans: B

56. Absent A wave due to:
A- Mitral stenosis
B- Aortic stenosis
C- Aortic regurgitation
Ans: A

57. Mitral stenotic ECG changes are
A- P mitrale
B- RR
C- ST
Ans: A

CamScanner

58. Athlete has increased which one in normal state?
A- Inc. cardiac out put
B- Inc. HR
C- Increased peripheral resistance
Ans: A

59. Pulse pressure:
A- Depends upon stroke volume
B- Is the difference of map and TPR
C- Is mainly due to arterial resistance
D- Depends upon diastole only
E- Decreases as the diastolic pressure decreases
Ans: A

60. At the time of shock what happens, what returns to normal after compensation earlier?
A- Heart rate
B- Volume of pulse
C- RBC volume
D- RBC mass
Ans: A

61. On ECG, what correlates with completely depolarized ventricle?
A- ST segment
B- QRS complex
C- PR interval
D- QT interval
Ans: A

62. Decrease in functional hemoglobin as in anemia carbon monoxide poisoning and methemoglobenemia will not causes hyperoxia because:
A- Stimulated by central receptors
B- By carotid body
C- Arterial po2 remains normal
D- Arterial oxygen content is kept in normal range
Ans: C

63. At which point in ECG more Ca ions enter in ventricular muscle cell:
A- P wave
B- R wave
C- S-t segment
D- P-r interval
Ans: C

64. A patient presented with hypotension he is cool and tachycardiac he was asked to stand up on standing his heart rate is increases why?
A- Decrease in total peripheral resistance
B- Decrease after load
C- Decrease venous return
D- Increase venous compliance
Ans: C

65. Second heart sound produced by:
A- Closure of mitral and tricuspid
B- Closure of aortic and pulmonary
C- Rapid filling of ventricles
Ans: B

66. Dec/shortest ventricular muscle fiber length in which one of the following?
A- Inc. venous return
B- Contraction of peripheral muscles
C- Dec. intra thoracic pressure
D- Inc. intra pericardial pressure
Ans: D

67. What is time period of absolute refractory resting period of heart?
A- 100milli sec
B- 150 msec
C- 250 msec
D- 10 – 20msec
Ans: C

68. Normal ECG do not record electrical activity of:
A- AV node
B- SA node
C- Ventricles
D- Left Atrium
E- Right Atrium
Ans: B

69. Blood vessel valve present in:
A- Large size veins
B- Medium size veins
C- Muscular arteries
D- Fenestrated capillaries
Ans: B

70. True about venous return:
A- Will become zero when all circulatory responses abolish
B- Will increase when mean systolic pressure falls
C- Is decrease when right atrium pressure decreases
Ans: A

71. During which phase of the cardiac cycle 2/3 of ventricular filling occurs and 3rd heart sound is produced?
A- Rapid inflow
B- Atrial contraction
C- Slow ejection
D- Isovolumetric relaxation
Ans: A

72. Which heart sound is produced due vibration of the ventricles during rapid inflow?
A- 3rd heart sound
B- 4th heart sound
C- 1st heart sound
D- 2nd heart sound
Ans: A

73. Most potent response in massive haemorrhage:
A- CNS ischemic response
B- Baroreceptors
C- Peripheral chemoreceptors
D- Brain bridge reflex
Ans: A

74. Parasympathetic effect on heart increases permeability in SA node to:
A- Sodium
B- Potassium
C- Calcium
D- Potassium and sodium
E- Sodium and calcium
Ans: B

75. Cardiac output is mainly determined by which of the following?
A- Venous Return.
B- Stroke Volume.
C- Heart Rate
D- EDV in the left ventricle
E- ESV in the left ventricle
Ans: A

76. Best index of preload is:
A- Pulmonary artery wedge pressure
B- Central venous (pressure/volume)
C- EDV in left ventricle
D- ESV in left ventricle
Ans: C (LVEDV)

77. During Inspiration, there is decrease in:
A- Arterial Plus volume
B- Heart rate
C- Negative intrapleural pressure
Ans: C

78. Splitting of 2nd heart sound is enhanced by:
A- Early closure of aortic valve
B- Delayed closure of aortic valve
C- Early closure of pulmonary valve
D- Delayed closure of pulmonary valve
Ans: D

79. Regarding exercise tolerance test. What we need to observe?
A- Heart rate arrhythmia will happen
B- Cardiac output will increase to the level of metabolic demand
C- Cardiac output will decrease to the level of metabolic demand
D- Heart rate decreases
Ans: B

80. Veins keep more volume of blood in them:
A- Veins Have Less Compliance
B- Veins Are Less Elastic
C- Veins Have More Compliance
D- Veins Have Largest Total Cross Section Area
E- Have Highest Resistance
Ans: C

81. How can we increase stroke volume?
A. Increase heart rate by keeping cardiac output constant
B. Increase blood volume
C. Increase venous capacitance
D. Venous dilation
Ans: B

82. Condition that increases pulse pressure?
A- Heart failure
B- Thyrotoxicosis
C- Hemorrhage
Ans: B

83. Athletes heart rate is permanently 50 due to:
A- Increased Cardiac Output
B- Increased Stroke Volume
C- Decreased Stroke Volume
D- Decreased Venous Return
Ans: B

84. Myocardial oxygen demand increased by:
A- Increased heart size
B- Increased Na influx
C- Increased Heart Contractility
D- Tachycardia
Ans: C

85. During moderate exercise what decreases?
A- TPR
B- HR
C- CO
D- SV
Ans: A

CamScanner

86. A wave represented by:
A- QT interval
B- PR segment
C- ST segment
D- QRS complex
E- PR interval
Ans: B

87. Increase in venous blood RBCs Has
A- Chloride
B- HCO_3
C- O_2
D- O_2
E- NO
Ans: A

88. Mechanism for BP less than 50:
A- Baroreceptor
B- Peripheral Chemoreceptors
C- Central Chemoreceptors
D- Cerebral Ischemic Response
Ans: D

89. Normal 200m seconds ventricular plateau is showed by what in ECG?
A- Q Wave
B- ST Segment
C- QRS Complex
D- P Wave
Ans: B

90. Main variable controlled by baroreceptor reflex is:
A- Mean Arterial Pressure
B- Pulse Pressure
C- Blood Pressure
D- Stroke Volume
Ans: A

91. Highest conduction velocity in Purkinje is due to:
A- Scanty Gap Junctions
B- Less Number of Myofibrils
C- Short Refractory Period
D- Tight Junctions
Ans: B

92. Exercising man will have:
A- Decreased Respiration
B- Decreased HR
C- Increase Minute Ventilation
D- Increase Cardiac Output
Ans: C

93. PR interval shows:
A- Depolarization
B- Ventricular depolarization
C- First heart block
D- AV Node conduction
Ans: D

94. During exercise TPR:
A- Increases
B- Decreases
C- Remain Same
Ans: B

95. U wave in ECG shows:
A- Papillary Muscle Repolarization
B- Hyperkalemia
C- Septal Repolarization
D- Hyponatremia
Ans: A

96. Index of TPR:
A- CVP
B- MAP
C- Pulse Pressure
D- Systolic BP
E- Diastolic BP
Ans: E

97. A patient on hypertensive drugs presents with postural hypotension. Increased heart rate while standing is mediated by:
A- Increase fire rate of baroreceptors
B- Decrease fire rate of baroreceptors
C- Increased vagal tone
D- Increased vasomotor tone
Ans: B

98. In normal healthy person the second heart sound:
A- Generates vibrations in the ventricular walls during systole
B- Has a duration of about 0.14 second
C- Is caused by ventricular filling
D- Normally has low frequency
E- Occurs during isovolumetric relaxation phase of cardiac cycle
Ans: E

99. Mean stroke volume is:
A- Stroke Volume × Heart Rate
B- Cardiac Output/Heart Rate
C- Heart Rate/Stroke Volume
D- Heart Rate/Cardiac Output
Ans: B

100. During exercise, blood flow decreases to:
A- Skin
B- Muscle
C- Kidney
D- Heart
Ans: C

101. When balloon cathethar passes into the heart there is an increase in pressure that will cause release of?
A- Ach
B- Dopamine
C- ANP
D- Renin
Ans: C

102. Decrease in HR will:
A- Diastolic pressure decrease
B- Systolic pressure decrease
C- Aldosterone increase
D- Diastolic decreases more than systolic
Ans: D

103. Venous return:
A- Normal in thiamine deficiency
B- Decrease in exercise
C- Decrease in anemia
D- Increase in forceful expiration
E- Increase in inspiration
Ans: E

104. Increased HR will:
A- Effects systole more than diastole
B- Effects diastole more than systole
C- Effect diastole less than systole
D- No effect
Ans: B

105. Mitral valve auscultation:
A- Right 2nd ICS sternal border.
B- Left 2nd ICS sternal border.
C- Left 5th ICS sternal border.
D- Left 5th ICS midclavicular line
Ans: D

106. Parasympathetic effect on Heart causes:
A- Decreased PR Interval
B- Tachycardia
C- Increased Heart Rate
D- Increased PR Interval
Ans: D

107. The extra systolic beat would produce:
A- Increase pulse pressure because contractility is increased.
B- Increase pulse pressure because HR is increased
C- Decrease pulse pressure because ventricular filling is increased
D- Decrease pulse pressure because SV is decreased
E- Decrease pulse pressure because the PR interval is increased
Ans: D

124. Sympathetic activity of heart causes:
A- Increase diastolic SA node rate
B- Increase force of atrial contraction
C- Increase AV nodal delay
D- Decrease AV nodal delay
E- Increase rate of diastolic depolarization at a node
Ans: D

108. Which one is common in pulmonary and skeletal capillaries?
A- Hydrostatic pressure
B- Protein filtration
C- Oncotic pressure
Ans: B

109. Organ least affected if blood supply stops:
A- Pancreases
B- Liver
C- Intestine
D- Kidney
Ans: B

110. Carotid and aortic baroreceptors get activated by:
A- Increased PH
B- Increased PCO_2
C- Decreased CO_2
D- Decreased O_2
Ans: D

111. During exercise blood flow decreases to:
A- Heart
B- Skin
C- Brain
D- Splanchnic circulation
Ans: D

112. Structure of conduction pathway of heart at sulcus terminalis and crista terminalis:
A- SA node
B- AV node
C- Bundle of His
Ans: A

113. A pregnant lady living at hill station presented at term. Ultrasound was done. No anomaly was seen. Which anomaly can still be present at birth:
A- VSD
B- ASD
C- Coarctation of aorta
D- PDA
E- Transposition of aorta over pulmonary trunk
Ans: D

CamScanner

114. Ductus arteriosus closes:
A- Just before birth
B- Middle of 2nd trimester
C- After 12 weeks
D- After 7 months
E- Shortly after birth
Ans: E

115. Signs of water intoxication are:
A- Distended neck veins
B- Pulmonary edema
C- Slow pulse
D- Increased alertness
E- Thirst
Ans: C

116. About 70% of O_2 in arterial blood extracted by the:
A- Kidney
B- Brain
C- Heart/Cardiac muscle
Ans: C

117. Subclass of myosin in cardiac muscle:
A- Alpha
B- Beta
C- Both alpha and beta
Ans: C (Ganong)

118. From end of atrial depolarization to start of ventricular depolarization:
A- ST segment
B- QRS complex
C- PR Segment
D- QT interval
Ans: C

Explanation:
- **PR Interval** – Start of atrial depolarization to start of ventricular depolarization
- **PR Segment** –End of atrial depolarization to start of ventricular depolarization
- **QT Interval** –Entire systolic phase (Ventricle depolarization to ventricle repolarization)

119 Unique property of cardiac muscles:
A- Not easily fatigued
B- Gap junctions
C- 80% O_2 consumption at rest
D- Plateau in Action Potential
Ans: C

120. In trace of jvp the wave produced by atrial filling with tricuspid valves closed Is:
A- C wave
B- V wave
C- X descent
D- Y descent
Ans: B

121. Wheatstone bridge is used to measure:
A- Cardiac output
B- Heart rate
C- TPR
D- Blood Pressure
Ans: A

122. If diameter of the vessel is halved, what happens to resistance?
A- Increases 16 times
B- Increases 8 times
C- Increases 20 times
Ans: A

123. Laminar to turbulent flow isn't affected by:
A- Velocity
B- Density
C- Viscosity
D- Diameter
E- Length
Ans: E

124. Relation b/w alveoli pressure, surface tension and radius:
A- Graham's law
B- Pousilles law
C- Laplace law
Ans: C

125. Patient in emergency with tachycardia sinking of heart pale cold clammy skin ECG show u wave:
A- Hypokalemia
B- Hyperkalemia
C- Hypocalcemia
D- Hypernatremia
Ans: A

126. After RTA blood loss, GFR decreased due to decrease in:
A- Arterial flow
B- Arterial blood pressure
C- Plasma colloid osmotic pressure
Ans: A

127. Aortic valve opens when ventricular pressure rises more than:
A- 8mmhg
B- 80mmhg
C- 100mmhg
D- 120mmhg
Ans: B

Explanation:
- Pulmonic valve 8 mmHg
- Aortic valve 80 mmHg

128. Which of following increases turbulence in blood flow?
A- Dec. in velocity of blood
B- Dec. in density of blood
C- Inc. in diameter of blood vessel
D- Dec. in diameter of blood vessel
E- Reynolds number less than 2000.
Ans: C

129. Which heart sound is felt on left parasternal 3rd intercostal space:
A- Aortic
B- Pulmonary
C- Tricuspid
D- Mitral
Ans: A

130. During exercise, which of the following is caused by sympathetic activity:
A- Bronchodilation
B- Increase in AV nodal delay
C- Bronchoconstriction
D- Decrease Heart rate
Ans: A

131. Ischemic patient took 8 hours to reach hospital which of these organs survive or least likely effected?
A- Heart
B- Hippocampus
C- Retina
D- Skeletal Muscle
Ans: D

132. ECG shows 2 p waves and 1 qrs complex pattern. Diagnosis is:
A- Mobitz type 1
B- Mobitz type 2
C- Mobitz type 3
D- Type 1 Heart Block
Ans: B

133. In type 2 heart block:
A- Ventricular rate slower than atria
B- SV is decreased
C- More chances of ventricular of ventricular arrhythmia
D- HR is increased
Ans: A

134. Sudden rise in pulse pressure is due to:
A- Increase in arterial compliance
B- Decrease in arterial compliance
C- Increase stroke volume
D- Increase heart rate at constant cardiac output.
Ans: C

135. Patient unconscious for 30mins after accident is brought to ER, he is pale with cold clammy skin, pulse rapid and thread, MAP is less than 60mmhg PO_2 below 60mmHg, what will provide rapid response?
A- Cushing reflex
B- Baroreceptor reflex
C- Chemoreceptor reflex
D- CNS ischemic response
E- Brain bridge reflex
Ans: D

136. Fast conduction in heart is of:
A- Bundle of his
B- Purkinji fibers
C- AV Node
D- SA Node
E- Right atrium
Ans: B

Explanation:
Speed of conduction:
Purkinje fibers > Bundle of His > Atria > Ventricles > SA node> AV node
Speed of Rate:
SA Node > AV Node > Purkinji fibers

137. About conducting system true is:
A- Connective tissue
B- Specialized cardiac muscle cells
C- Muscle fibers
D- Nervous tissue
Ans: B

138. In a patient with sympathetic nervous stimulation, what effect will occur on the heart?
A- Decrease rate
B- Coronary constriction
C- Hyperpolarization of SA node
D- Decrease AV nodal delay
E- Decrease stroke volume
Ans: D (BRS + Guyton)

Explanation:
- Sympathetic Increase conduction through AV node thus decrease AV nodal delay
- Parasympathetic Decrease conduction through AV node thus Increase AV nodal delay

139. The pacemaker activity of SA node phase 4 is caused by:
A- Entry of Na
B- Entry of Cl
C- K efflux
D- Ca efflux
E- Cl efflux
Ans: A

CamScanner

Explanation:
- Pace Maker activity of SA Node due to – Sodium Channels
- Action Potential of Pace Maker due to – Calcium Channels
- Action Potential of Cardiac Muscle due to – Sodium Channels

140. Sarcomere is present between which of following?
A- Two A lines
B- Two M lines
C- Two Z lines
D- Two I lines
Ans: C

141. An obese patient wears a tight collar shirt and feels tightness in collar and faint whenever he turns his head which of following is responsible for this?
A- Increase TPR
B- Increase venous compliance
C- Increase CO
D- Increase myocardial contractility
Ans: B

Explanation:
Tight collar put pressure on carotid sinus which increase parasympathetic activity that cause bradycardia, hypotension and vasodilation low blood supply to brain hence syncope occur and due to vasodilation venous compliance increased.

142. EDV depends on which one?
A- Venous return
B- Stretch of ventricle fibers
C- TPR
D- Stretch of Atrium
Ans: A (BRS)

Explanation:
- Preload determine by – EDV (Depends on Venous return)
- After load determine by – MAP
- TPR determine by – Diastolic BP

143. When pressure in carotid sinus decrease it will cause?
A- Decrease peripheral resistance.
B- Increases firing of presser receptors
C- Decrease firing of presser receptors
D- Increase parasympathetic drive
E- Low HR
Ans: C

144. What does PR interval shows?
A- Ventricular repolarization
B- SA node conduction to AV node
C- SA node conduction to ventricles
D- Atrial systole
E- Atrial depolarization
Ans: C

Explanation:
P wave – Atrial depolarization
PR Interval – Shows atrial depolarization to ventricular depolarization. It represents time needed for impulses to reach from SA node to ventricle (from SA node through atria, AV node, bundle of his, bundle branches and purkinji to ventricle)
QRS Complex – Ventricular depolarization
ST Segment – Complete Ventricular depolarization
QT Interval – Represent Entire Systolic phase
T Wave – Ventricular Repolarization
U Wave – Papillary Repolarization

145. Anatomical basis of conduction of heart:
A- Gap junction
B- Intercalated disc
C- Desmin bridges
D- Myosine bridges
E- Short Diameter
Ans: A

146. Sympathetic beta adrenergic effect on heart is:
A- Decrease HR
B- Decrease AV Nodal conduction
C- Increase contractility of heart
D- Decrease contractility of heart
E- Constriction of GIT Sphincter
Ans: C

Explanation:
Heart
B1 Receptor (Sympathetic)
- Increase HR
- Increase Contractility
- Increase AV Node Conduction

M2 Receptor (Parasympathetic)
- Decrease HR
- Decrease Contractility
- Decrease AV Node Conduction

GIT
Sympathetic
- Decrease Motility (a1B2)
- Constrict GIT Sphincter (a1)

Parasympathetic
- Increase Motility (M3)
- Relax GIT Sphincter (M3)

147. Person standing for a long time, what will decrease?
A- CVP
B- ADH
C- Heart Rate
D- Renin
E- GH
Ans: A

148. SA node acts as a pacemaker of heart because of fact that is:
A- Is capable of generating impulses spontaneously
B- Has rich sympathetic stimulation
C- Has poor cholinergic innervation
D- Generates impulses at the faster rate
E- Generate impulses slowly
Ans: D (Guyton)

Explanation:
- SA node generate impulses at faster rate
- AV node generates impulses spontaneously

149. Systolic phase of cardiac cycle correspond to the following component of ECG:
A- QRS complex
B- QR interval
C- ST segment
D- PR Segment
E- QT/RT
Ans: E

150. Sympathetic Stimulation in fight and flight causes which of following?
A- Decrease CO
B- Decrease HR
C- Decrease Airway resistance
D- Decrease cardiac contractility
E- Increase GIT motility
Ans: C

151. Short term regulation of BP is done by:
A- RAAS
B- Baroreceptors
C- CNS ischemic response
D- Aldosterone
E- Cortisol
Ans: B

Explanation:
- Baroreceptor respond maximally to – Increasing BP (Ganong).
- Most rapid response to decrease BP – Baroreceptor.
- Most potent response to decrease BP – CNS Ischemic.
- CNS ischemic activate at – 60 or below 60mmHg (Guyton).
- Maintain During Shock – Baroreceptor
- Mainta As a whole – RAAS
- Short Term BP control – Baroreceptor
- Long Term BP control – RAAS

152. In aircraft, during ascent the pilot have his blood pooled in veins of lower limbs. What will happen initially?
A- Arterial pressure will decrease
B- No change on arterial pressure
C- Decreased cardiac output
D- Venous return increased
E- Increased cardiac output
Ans: A

Explanation:
- Due to pooling of blood initially there will be decrease Arterial pressure which will be detected by baroreceptor and it will discharge less due to which sympathetic outflow start which cause compensatory increase HR and Increase Cardiac output so ultimate effect is by compensation which is necessary for survival because person can't remain on decrease arterial pressure it will be corrected by Baroreceptor immediately.
- Initially – Decrease arterial pressure.
- Compensatory – Increase Cardiac out put

153. Which is responsible for AV nodal delay?
A- Atrial contraction
B- Ventricular filling occurs properly
C- Rapid ejection
D- Slow filling
Ans: D

154. Importance of PR Interval:
A- Atrial systole
B- Ventricle contraction
C- Atrial diastole
D- Ventricular diastole
E- Atrial relaxation
Ans: A

155. Acute decrease in arterial pressure (MAP drops from 100 to 60) elicits which of the following compensatory changes?
A- Increase parasympathetic outflow to the heart
B- Decrease firing rate of carotid sinus
C- Decrease heart rate
D- Decrease contractility
E- Increase Herring nerve activity
Ans: B

Explanation:
When BP falls baroreceptor detect this change and decrease its firing rate which in turn activate sympathetic which will increase HR increase cardiac output and maintain BP back to normal.

CamScanner

156. From sitting to standing there is compensation by which underlying mechanism?

A- Decreased HR
B- Decrease heart rate
C- Increase TPR
D- Increase CO
E- Decrease venous return
Ans: E

Explanation:

- When person stands from sitting venous return decrease which then leads to compensatory things which are increase heart rate and increase cardiac output so basic mechanism underlying compensatory changes is decrease venous return
- **Mechanism for Compensation** – Decrease venous return
- **Compensatory Changes** – Increase heart rate and cardiac output.

157. Which of the following increase Extracellular presence have profound effect on heart?

A- K
B- Na
C- HCO_3
D- Ca
E- Magnesium
Ans: A

158. MAP is related to which of following?

A- TPR
B- CO
C- SV and TPR
D- HR
E- CO and TPR
Ans: E

159. Dicrotic notch is related to which of following?

A- Pulmonic valve closure
B- Aortic valve closure
C- Aortic valve opening
D- Mitral valve closure
E- Mitral valve open
Ans: B

160. Patient came for cardiovascular checkup having heart rate 48 Stroke volume 118 this is seen in:

A- Sympathomimetic drugs
B- Athlete
C- Para Sympathomimetic drugs
D- Rest
Ans: B

161. Aortic pressure is highest at which Phase of cardiac cycle?

A- Rapid ejection phase
B- Slow ejection phase
C- Isovolumetric contraction
D- Isovolumetric relaxation
E- Rapid Filling
Ans: B

162. During contraction of sarcomere length of which of following remain unchanged?

A- I band
B- I band and Sarcomere
C- A Band
D- A Band and I band
E- H zone
Ans: C

Explanation:

- I Band Decrease
- Sarcomere Decrease
- A Band Unchanged
- H zone Disappear

163. Arterial pulse which is palpable on radial artery is due to which of following?

A- Pulse pressure which pushes arterial wall
B- Systolic pressure of left ventricle
C- Diastolic pressure of left ventricle
D- Pressure wave in aorta
E- Blood pumping in aorta
Ans: A

164. A patient injured in RTA bleeding from site of injury with BP of 90/70 heart rate increase from 100 from sitting to standing to 120 due to?

A- Decrease venous return
B- Increase venous return
C- Increase EDV
D- Increase cardiac output
E- Increase preload
Ans: A

165. What is present between gap junctions?

A- Conexant
B- Cellular adhesion
C- Lipid bilayer
D- Protein layer
Ans: A

166. Person present with Central chest pain for 3hr which cardiac enzyme will be raised?

A- Trop I
B- CK-BB
C- CPK
D- ALT
E- AST
Ans: A (Only Suitable option)

167. Main determinant of coronary circulation is:

A- Sympathetic
B- Parasympathetic
C- Local metabolites and oxygen demand
D- K ions
E- H ions
Ans: C

168. 10-year-old girl playing outside felt pain due to cold weather having increase HR increase BP and shivering will cause:

A- Increase Skin blood supply
B- Decrease Skin blood supply
C- Contraction of erector pillae
D- Dilation of erector pillae
Ans: C

169. A Patient having 2 p wave followed by QRS complex due to which of following?

A- Fast SA Node Conduction
B- Decreased AV nodal conduction
C- Decrease conduction in purkinji
D- Slow ventricular pacemaker conduction
Ans: B

170. During cardiac cycle recording monitor will show V wave of atrial pressure occurring in:

A- Atrial systole
B- Diastole
C- Ejection phase
D- Isovolumetric contraction phase
E- Isovolumetric relaxation phase
Ans: E

171. Athletes have enlarged heart size comparatively and increased stroke volume instead their muscles need same amount of energy and having cardiac output approximately same as that in normal individuals. What can be the reason for this phenomenon?

A- Increase SV
B- Increase SV and heart rate
C- Decrease heart rate and increase SV
D- Increase TPR
E- Increase venous return and increase HR
Ans: C

172. An ECG of patient with electrolytes disturbances shows U wave, inverted T wave, prolonged PR interval on ECG due to:

A- Hypokalemia
B- Hyperkalemia
C- Hyponatremia
D- Hypernatremia
E- Hypomagnesemia
Ans: A

173. Which dye is used to measure cardiac output?

A- Cardio green
B- Evans blue
C- Potassium dichromate
D- Congo red
E- Violet
Ans: A

174. Velocity in vessel is inversely proportional to:

A- Surface area
B- Viscosity
C- Basal area
D- Radius
Ans: B

175. Patient move from supine position to standing position compensation by which of these?

A- Decrease heart rate
B- Increase venous compliance
C- Increase heart contractility
D- Decrease TPR
E- Increase venous return
Ans: C

176. Cannon A wave is associated with:

A- Tricuspid regurgitation
B- Pulmonary stenosis
C- Mitral regurgitation
D- Pulmonary embolism
E- Complete heart block
Ans: E

177. S.A node is supplied by:

A- LCA in 90% people
B- RCA in 60% of people
C- RCA in 40% of people
D- LCA in 60%people
E- LCA in 100% people
Ans: B (KLM)

178. Which of the following is increased in deep inspiration?

A- Cardiac output
B- BP
C- Venous return
D- Pulses Paradoxes
Ans: C

Explanation:

Deep inspiration leads to

- Decrease cardiac output
- Increase venous return
- Splitting of S2
- Increase pulmonary compliance

CamScanner

179. Patient stand suddenly, what will increase?
A- Pulse pressure
B- Venous compliance
C- Blood pressure
D- Resistance
Ans: A

180. Which of following pressure measured between venous and arterial side when heart stopped?
A- MAP
B- Diastolic pressure
C- Mean Systemic Filling Pressure
D- Carotid pressure
E- Systolic Pressure
Ans: C (Guyton)

Explanation:
Mean systemic filling pressure is the pressure measured everywhere in the systemic circulation after blood flow has been stopped by clamping the large blood vessels at the heart, so the pressures in the systemic circulation can be measured independently from those in the pulmonary circulation. The mean systemic pressure, although almost impossible to measure in the living animal, is the important pressure for determining venous return.

181. During exercise person feels tired due to subjective feeling of:
A- Increased heart rate
B- Dehydration
C- Lactic acidosis
D- Low Oxygen
E- Low glucose
Ans: A

Explanation:
- **During Exercise subjective** feelings of getting tired is due to – **Increased Heart rate**
- **After Exercise** feeling of getting tired is due to – **Increased Lactic acid**

182. About Sinus arrhythmia true statement is:
A- Abnormal condition
B- Due to increase discharge of impulses from baroreceptor
C- Unaffected by the depth of inspiration
D- Heart rate increase during inspiration and decrease during expiration
Ans: D

183. Maximum ventricular filling in which phase of cardiac cycle
A- 1st third of diastole
B- Middle 3rd of diastole
C- Last third of diastole
D- Slow ejection
E- Rapid ejection
Ans: A

184. Electrical activity conduction in heart is located in which of following?
A- Endocardium
B- Sub epicardium
C- Sub endocardium
D- Myocardium
E- Epicardium
Ans: C

Explanation:
- SA node located in – Sub Epicardium
- AV node located in – Endocardium
- Conducting System – Sub Endocardium

185. Right ventricular diastolic pressure is:
A- 0.5mmHg
B- 30mmHg
C- 8mmHg
D- 100mmHg
Ans: C

Explanation:
- R ventricle Pressure during **Systole** -- **25**
- R ventricle Pressure during **Diastole** – **0-8**
- R ventricle Pressure at which **Pulmonary Valve** Open -- **8mmhg**
- L ventricle Pressure at which **Aortic Valve** Open -- **80mmhg**

186. Myocardium blood supply is regulated mainly by:
A- K ions
B- Hydrogen ions
C- Prostaglandins
D- Local metabolites
Ans: D

187. A person presented with heart rate 200bpm and BP = 80/50 in this state:
A- Diastolic time decreases and systolic remain same
B- Diastolic time increases and systolic remains the same
C- Diastolic decreases more in proportion to systolic
D- Diastolic decreases and systolic increases
E- Diastolic increases and systolic decreases
Ans: C

188. During contraction length of following decrease:
A- A band
B- I band and Sarcomere
C- Acting and A Band
D- A Band and I band
Ans: B

189. S2 Heart sound as compared to S1 Heart sound has:
A- More Frequency
B- More Duration
C- More Dullness
D- Less Frequency
Ans: A

Explanation:
- S1 heart sound has more duration and dullness than S2
- S2 heart sound has more Frequency and pitch than S1

190. C wave in JVP coincides with:
A- Ventricle contraction
B- Ventricle relaxation
C- Atrial systole
D- Atrial relaxation
Ans: A

191. Systolic BP 132 diastolic 66 MAP will:
A- 68
B- 88
C- 78
D- 66
Ans: B

Explanation:
PP = 132-66 =66
1/3rd of PP =66/3=22
MAP = Diastolic BP + 1/3rd of PP
MAP = 66 +22 = 88

192. A patient After RTA Resuscitated earliest sign of successful resuscitation:
A- Decreased heart rate
B- Increased urine output
C- Decrease Urine output
D- Increase BP
Ans: B

193. Ejection fraction is:
A- 0.45
B- 0.55
C- 0.65
D- 0.75
Ans: B

194. Calculate ejection fraction if HR 70, CO 5.6L, EDV160 ml?
A- 0.50
B- 0.55
C- 0.60
D- 0.77
Ans: A

Explanation:
CO = SV * HR.
SV = CO/HR = 0.08 L
Convert it into ml by multiplying 1000 = 80
Now EF = SV/EDV = 0.5

195. Baroreceptors respond maximally to:
A- Rapidly decreasing BP
B- Rapidly increasing BP
C- Low PO_2 in arterial blood
D- Low H^+ in arterial blood
Ans: B (Ganong)

196. Mean arterial pressure is:
A- Systolic - diastolic
B- Systolic + diastolic
C- Diastolic+1/3rd pulse pressure
D- Diastolic+1/3rd systolic pressure
Ans: C

197. SV defined AS:
A- CO/HR
B- EDV/HR
C- ESV/EDV
D- SV/EDV
Ans: A

198. AV nodal delay results in:
A- Prolonged PR interval
B- Short PR interval
C- Long QRS
D- Short QT interval
Ans: A

199. Heart rate double cardiac cycle will complete in?
A- 0.4
B- 0.8
C- 0.12
D- 0.16
Ans: A

200. Cardiac output in heavy exercise is augmented by:
A- Sympathetic stimulation of resistance vessels
B- Dilatation of venous vessels
C- Constriction of venous vessels
D- Increase in ventricular contractility
Ans: D

201. S2 heat sound is due to:
A- Rapid Ejection
B- Slow Ejection
C- Isovoumetric relaxation
D- Isovolumetric contraction
Ans: C

202. Actin attach to z line through:
A- Myosin
B- Troponin
C- Actinin
D- Titin
Ans: C

CamScanner

203. A person went to floor from stairs and increase cardiac output cause of increase cardiac output:
A- Increase preload
B- Decrease Contractility
C- Decrease Sympathetic
D- Increase TPR
Ans: A

204. Heart rate increase it will affect which phase of cardiac cycle effected?
A- Rapid ejection
B- Slow ventricular filling
C- Rapid filling
D- Reduced ejection
Ans: B (BRS)

205. Which phase of cardiac cycle will not occur in absence of p wave on ECG?
A- Atrial systole
B- Atrial diastole
C- Ventricular systole
D- Ventricular diastole
Ans: A

206. Regarding coronary arteries:
A- 2 coronary artery, Auricular, 1 AV nodal, 1 septal
B- 3 coronary arteries
C- 2 coronary, 2 AV nodal, 2 septal
D- 2 coronary artery, 1 AV nodal, 2 septal
Ans: A

207. One with multiple fractures of radius femur with pulse 120 and BP 90/50 comes to ER initially:
A- Fluid replacement
B- Temp monitor
C- Splinting of fractures
D- Tracheostomy
Ans: A

208. In normally functioning myocardium, C wave coincide with:
A- Closure of semilunar valves
B- First heart sound
C- Closure of AV valve
D- Opening of AV valve
Ans: C

209. SA node is located:
A: Upper part of sulcus terminalis
B: Lower part of sulcus terminalis
C: Upper part of crista terminalis
D: Moderator band
Ans: A

210. During exercise sympathetic adrenergic stimulation causes:
A- Vasoconstriction
B- Cardiac circulation regulation
C- Constriction of sphincter urethra
D- Relaxation of sphincter urethra
E- Increase cardiac activity
Ans: E

Explanation:
Sympathetic stimulation of heart improves cardiac output by accelerating heart rate & increase force of contraction.

211. Inverse relation to blood flow:
A: Resistance
B: Radius
C: Vessel length
D: Diameter
Ans: A (Other options are directly related)

212. In basal condition cardiac muscles uses which of the following for energy?
A- Fats
B- Carbohydrates
C- Amino acids
D- Lipids
Ans: A

213. Diameter of Lumen of arteriole is:
A- 0.03mm
B- 1.5mm
C- 2mm
D- 2.5mm
E- 3mm
Ans: A (Ganong)

Explanation:
- Arteriole Lumen diameter – 30 um or 0.03mm
- Arteriole wall thickness – 20um or 0.02mm

214. Highest systolic pressure present in:
A- Aorta
B- Femoeal artery
C- Dorsalis pedis
D- Renal Artery
Ans: D

Explanation:
- Max Pulse Pressure – **Dorsalis pedis > Femoral > Popliteal > Aorta**
- Highest Systolic Pressure – **Renal Artery.**

215- Normal fluid loss in 24 hours through perspiration is:
A- 200-400ml
B- 400-500ml
C- 500-600ml
D- 600-800ml
Ans: A

216. A patient having Tachycardia abdominal distension and hypotension after laparotomy due to which of these
A- Hypovolumic Shock
B- Septic Shock
C- Cardiogenic Shock
D- Anaphylactic Shock
E- Neurogenic Shock
Ans: A

217. A Person taken to siachen 12000 feet from sea level develops dyspnea post 12 hours most likely due to:
A- Secondary
B- Pulmonary edema
C- Airway obstruction
D- Inflammation
E- Infection
Ans: B

Explanation:
- Within 24hr Symptoms – Pulmonary edema.
- After 5-6 months Symptoms on returning – Secondary polycythemia

218. A Patient with localized Circumferential Lateral wall infarct which artery involved
A- RCA
B- LCA
C- LCX
D- Marginal
E- Pulmonary embolism
Ans: C

Explanation:
- Inferior wall MI (RCA) – Leads 2, 3 and AVF
- Anterior wall MI (LAD) – Leads V1-V6
- Lateral wall MI (LCX) – Leads 1, AVL, V5 and V6

219. In Auscultation 3rd intercostal space left to sternum
A- Aortic A2
B- Aortic A1
C- Pulmonary valve sound
D- Mitral valve
Ans: A

220. CVP is increased by
A- Decrease Heart Rate
B- Increase Total Peripheral Resistance
C- Decrease Blood volume
D- Increase Heart Rate
Ans: A

221. Decrease lymphatic flow due to increase of
A- Increase Plasma Oncotic Pressure
B- Decrease Plasma Oncotic Pressure
C- Increase Hydrostatic Pressure
D- Increase Permeability
Ans: A

Explanation:
Increase Lymphatic Flow
- Increase Hydrostatic Pressure
- Decrease Oncotic pressure

Decrease Lymphatic Flow
- Decrease Hydrostatic Pressure
- Increase Oncotic Pressure
- Hemorrhage

222. A patient is having high grade fever, Low BP and Shock like condition Which of the following is the site of septic shock?
A- Gastrointestinal system
B- Cardiovascular system
C- Urinary Track
D- Pulmonary system
E- Renal System
Ans: C

223. Current flow occurs in the heart to produce waves in the ECG when the heart is:
A- Completely depolarized
B- Partially depolarized
C- Completely repolarized
D- In refractory period
E- Partially depolarized and partially polarized
Ans: E

224. 2nd heart sound due to:
A- Isovolumetric contraction
B- Isovolumetric relaxation
C- Atrial systole
D- Ventricular filling
E- Rapid Ejection
Ans: B (FA + BRS)

Explanation:
- **First heart Sound** – Isovolumetric contraction (Closure of mitral and tricuspid valve)
- **Second Heart Sound** – Isovolumetric relaxation (Closure of aortic and Pulmonary valve)
- **Third Heart Sound** – Rapid ventricular filling (Normal in children, pregnancy and athletes)
- **Fourth heart Sound** – Atrial Systole

CamScanner

225. Right ventricular pressure at which pulmonary valve opens is?
A- 0.5mmHg
B- 30mmHg
C- 8mmHg
D- 100mmHg
E- 40mmHg
Ans: C

Explanation:
- R ventricle pressure during systole – 25
- R ventricle pressure during diastole – 0 – 8
- R ventricle pressure at which pulmonary valve open – 8mmHg
- L ventricle pressure at which aortic valve open – 80mmHg

226. In Which Phenomena Increase CO2 , Decrease TPR and Increase Vasodilaton in Skeletal muscle is
A- CO posining
B- Cyanide Poisning
C- Hypoxia
D- Exercise
Ans: D

227. A patient has cardiac cycle of 0.3 seconds at the rate of 75 beats/min. His heart rate is increased to 225 beats/min. What will be the duration of cardiac cycle?
A- 0.1 sec
B- 0.3 sec
C- 0.9 sec
D- 1 sec
E- 2 sec
Ans: A

228. 8% blood loss in 30 min with no change in atrial pressure which of the following has maximum loss of blood
A- Aorta
B- Arteries
C- Arteriole
D- Capillary
E- Veins
Ans: E

229. MI occur due to thrombosis which factor is important and independent of other factors
A- Prolonged immobilization
B- Endothelial injury
C- Stasis
D- Hypercoagubility
E- Turbulence in Blood Flow
Ans: A

230. Which following has most prominent prepotential?
A- SA node
B- Atrial muscle cells
C- Bundle of His
D- Purkinje fibers
E- Ventricular muscle cells
Ans: A

231. In Aortic aneurysm defect will be in
A- Tunica intima
B- Tunica media
C- Tunica spinosa
D- Tunica Granulosa
Ans: B

232. Fastest response to increase BP
A- CNS ischemic
B- RAAS
C- Baroreceptor
D- Renin
E- Adrenergic
Ans: C

233. A person runing in a marathon race blood flow to non exercising muscle by
A- Sympathetic cholinergic
B- Sympathetic adrenergic
C- Parasympathetic
D- Local metabolite
E- Adenosine
Ans: A

234. About S1 heart sound accompanied with
A- a wave on JVP
B- Closure of aortic and pulmonic valve
C- Decrease ventricular pressure
D- Increase atrial pressure
Ans: C

235. Patient loss one liter of blood in 5 mints it will cause
A- Increase heart rate
B- Increase venous tone
C- Decrease Heart rate
D- Bounding pulse
Ans: A

236. The site of murmur for aortic regurgitation is:
A- Neck
B- Apex of heart
C- Left 5th ICS
D- Right 2nd ICS
E- Left 2nd ICS
Ans: D

237. 62 years old patient of congestive heart failure presented with dyspnea and orthopnea, the mechanism of pulmonary edema in case of CHF is which of following
A- Increased plasma colloid osmotic pressure
B- Decreased plasma colloid osmotic pressure
C- Decreased hydrostatic pressure
D- Increased hydrostatic pressure
E- Increased permeability of pulmonary vasculature
Ans: D

238. What is the difference between anaphylactic and hypovolemic shock?
A- Decrease Cardiac output in Anaphylactic
B- Increase Cardiac output in Anaphylactic
C- Increase TPR
D- Increase BP
E- Decrease BP
Ans: B

239. ECG of patient shows progressive prolongation of PR interval in successive beats followed by dropped heart Beat patient is suffering from?
A- Mobitz 1 AV block
B- Mobitz 2 AV block
C- Atrial flutter
D- Complete AV block
E- 1st degree AV block
Ans: A

240. If ejection fraction increase there will be decrease in:
A- Cardiac out put
B- EDV
C- Systolic pressure
D- Heart rate
E- Pulse pressure
Ans: B(Prefer ESV >EDV)

241. After° myocardial injury what biochemical changes will be seen in hypoxia?
A- Aerobic Glycolysis
B- Oxidative Phosphorylation
C- Anaerobic Glycolysis
D- Gluconeogenesis
Ans: C

242. A patient has infarct of left ventricle which is sub endocardial and also infracted intra ventricular septum most likely what is the cause
A- Hypotnesive shock
B- Thrombotic occlusion of LCX
C- Hypovolumic Shock
D- Decrease blood suplly to the wall
Ans: B

243. An old man died after 4 days of RTA he is having femur fracture upon autopsy he was having pulmonary infarcts and vessels was occluded by hematopoietic stem cell origin cells
A- Pulmonary Embolism
B- Air embolism
C- Gas embolism
D- Fat embolism
E- Amniotic fluid embolism
Ans: D

Explanation:
- Air Embolism – History of Passing CVP then SOB
- Pregnant lady + Long bone fracture + Died on way to hospital within 24h or during labour – Amniotic fluid embolism
- Sudden death + Sudden SOB – Pulmonary Embolism
- Long bone fracture – Death after 3-5 days – Fat embolism

244. A young girl is exercising what parameter is decrease in her skeletal muscle
A- Lactate
B- Fats
C- Arteriolar resistance
D- Metabolic waste
Ans: C

245. After RTA a patient has lost blood of 1.5 litres,He will have:
A- Tachycardia, increase CVP Increase BP
B- Bradycardia, increase CVP, decreased BP
C- Brady cardia decrease CVP decrease BP
D- Tachycardia, decrease CVP, decrease BP
Ans: D

246. Hyperkalemia occurs in acute response to
A- Fluid intake
B- Exercise
C- Increase fluid loss
D- CRF
E- CLD
Ans: B

247. Velocity of conduction increased 5-50 folds due to large diameter what will be other reason?
A- Na channel increase permeability
B- Increase Na/K atpase pump
C- Increase length
D- Increase Ca channel
Ans: A

CamScanner

248. Most common site of atherosclerosis:
A- IVC
B- SVC
C- Aorta
D- Femoral artery
E- Radial artery
Ans: C

Explanation:
Following Vessel involved in descending order (LCP-DIC)
- Lower Abdominal aorta
- Coronary artery
- Popliteal artery
- Descending thoracic aorta
- Internal Carotid artery
- Circle of Willis

249. Most imp response in shock as a whole?
A- CNS ischemic response
B- Baroreceptor
C- Sympathoadrenal response
D- Cortisol
Ans: C

250. Largest total cross sectional and surface area is of
A- Artery
B- Arterioles
C- Capillaries
D- Venules
E- Veins
Ans: C

Explanation:
- Maximum total cross section area – **capillaries**
- Minimum total cross section area – **Aorta**
- Maximum blood volume – **Veins**
- Minimum blood volume – **Arterioles**
- Maximum wall thickness – **Aorta**
- Minimum wall thickness – **Capillaries**
- Maximum diameter – **Vena cava**
- Minimum diameter – **Capillaries**
- Maximum blood pressure – **Aorta**
- Minimum blood pressure – **Vena cava**
- Maximum flow rate – **Aorta and Vena cava**
- Minimum flow rate – **Capillaries**
- Maximum blood flow velocity – **Aorta**
- Minimum blood flow velocity – **Capillaries**
- Site of gas exchange – **Capillaries**
- Maximum vascular resistance – **Arterioles > Capillaies**

251. Patient presented in ER after RTA 1-liter blood loss what will be compensatory mechanism?
A- Decrease diastolic bp
B- Decrease TPR
C- Increase Venous tone
D- Decrease BP
Ans: C

252. Heart need 60% energy from which one of these?
A- Carbohydrates
B- Ketones
C- Proteins
D- Fats
Ans: D

253. Female patient after multiple blood transfusion ECG shows tall T waves what is your diagnosis?
A- Hypokalemia
B- Hyperkalemia
C- Hypercalcemia
D- Hypocalcemia
E- Hypomagnesemia
Ans: B

254. Patient came in ER with acute chest pain ECG done what finding will suggest acute MI?
A- T wave peak
B- U wave
C- ST displacement
D- Tall QRS
Ans: C

255. After a road traffic accident massive blood loss patient undergoes shock BP 85/40 what will activate now:
A- RAAS
B- CNS Ischemic response
C- Release of Renin
D- Baroreceptor reflex mechanism
Ans: B

Explanation:
MAP is calculated as
- PP =Systolic -Diastolic =85-40=45
- 1/3rd of PP =15
- MAP=Diastolic BP + 1/3rd PP
- 40 +15=55
- Baroreceptor respond maximally to – Increasing BP (Ganong).
- Most rapid response to decrease BP – Baroreceptor.
- Most potent response to decrease BP – CNS Ischemic.
- CNS ischemic activate at – 60 or below 60mmHg (Guyton).
- Maintain During Shock – Baroreceptor

256. AV Nodal Delay helps in which of following?
A- Atrial filling
B- Ventricle filling
C- Aorta filling
D- Ventricle contraction
E- Atrial contraction
Ans: B

257. After a road traffic accident massive blood loss patient undergoes shock BP 65/40 what will activate now?
A- RAAS
B- CNS Ischemic response
C- Release of Renin
D- Baroreceptor reflex mechanism
E- Chemoreceptor
Ans: B

258. Detached embolus from deep veins of leg will lodge in:
A- Inferior vena cava
B- Lung
C- Heart
D- Femoral veins
E- Superior vena cava
Ans: B

Explanation:
- Emboli first go to – IVC >Right atrium
- Emboli first lodged in – Pulmonary artery (lung)

259. Ventricle pressure rises and Volume remain same in which phase of Cardiac cycle
A- Rapid ejection
B- Rapid ventricle filling
C- Atrial Systole
D- Isovolumetric contraction
Ans: D

260. Membrane potential maintained by which of following
A- Na k ATPase pump
B- Inward sodium
C- Outward potassium
D- Inwards potassium
Ans: A

261. Location of SA node:
A- At the junction of right atrium and ventricle
B- Lower side of atrial septum
C- Top of right atrium
D- B/w the cusps of tricuspid valve
Ans: C

262- Increase extracellular potassium causes which of these?
A- Systolic arrest
B- Diastolic arrest
C- Both arrests
D- No significant effect on heart
Ans: B

Explanation:
- Hypercalcemia and hypokalemia –Systolic heart arrest
- Hypocalcemia and hyperkalemia –Diastolic heart failure

263- Ventricular filling in which ECG-segment
A- TP
B- QT
C- ST
D- QRS
Ans: A

264- Cardiac output measured by thermodilution method record
A- Pulse
B- Temperature
C- Pressure
D- Blood flow
Ans: B

265- A band in sarcomere consist of
A- Myosin only
B- Actine with some myosin
C- Myosin only
D- Myosin and some actin
Ans: D

266- Organ with high atriovenous oxygen difference at rest is:
A- Skeletal muscle
B- Heart
C- Brain
D- Kidney
Ans: B

267. Action potential from cell to cell by
A- Gap junction
B- Intercalated disc
C- Desmin bridges
D- Desmosomes
Ans: A

268- In ECG ventricular depolarization shown by
A- QRS complex
B- ST segment
C- PT interval
D- TP segment
E- PR Interval
Ans: A (BRS Physio)

Explanation:
- Complete ventricular depolarization – ST segment
- Ventricular depolarization – QRS

269- Cardiac output measured by Thermodilution method is called
A- Ficks law
B- Grahams law
C- Starling law
D- Indicator dilution technique
Ans: D(BRS Physio)

CamScanner

270. Systolic phase of cardiac cycle correspond to the following component of ECG
A- QRS complex
B- QR interval
C- ST segment
D- PR Segment
E- RT Interval
Ans: E(BRS Physio)

271- 2 persons sitting in a room ,athlete & other man what former will have increase:
A- HR
B- Blood pressure
C- Cardiac output
D- Ejection fraction
Ans: C

272- Parasympathetic decreases heart rate by effect on
A- Na
B- K
C- Na &K
D- Ca
E- Phosohours
Ans: C(BRS Physio)
Explanation:
- Parasympathetic act on **SA Node** and decrease Heart rate**(Negative Chronotropic)** via
1- Decrease Na Influx(Decrease Pacemaker current)
2- Increase K Efflux(Hyperpolirization)
- Parasympathetic act on **AV Node** and decrease conduction of AV Node**(Negative Dromotropic)**

273. Regarding preferential thorough fare channel correct statement is
A- Small caliber
B- Having smooth muscles
C- Open on demand
D- Present at origin of precapillary Sphinter
E- Increase capillary valve
Ans: B

274. Blood vessel dilation in response to exercise by Sympathetic in which organ
A- Heart
B- Kidney
C- Brain
D- Lung
E- Stomach
Ans: A

275- From sitting to standing there compensation by:
A- Decreased HR
B- Decrease heart rate
C- Increase TPR
D- Increase CO
E- Increase heart rate
Ans: E(BRS Physio)

276- Resting membrane potential reverts back to normal due to:
A- Leaky Na channel
B- Closing of K channel
C- Progressive opening of K channel
D- Opening of Na channel
E- Funny Na channel
Ans: C

277- Common muscle contraction protein for smooth and skeletal muscle - ——
A- Calmodulin
B- Actin
C- Myosin
D- Tropomyosin
Ans: B

278- When blood pressure in carotid sinus decrease it will cause increase of ——
A- Peripheral resistance
B- Firing of pressoreceptors
C- Heart rate
D- Parasympathetic drive
Ans: C

279- Percentage of blood ejected out of end diastolic volume per contraction is
A- Stroke volume
B- Heart rate
C- Ejection fraction
D- MAP
Ans: C

280- An old man collapsed and his ECG shows atrial rate of 75 ventricular rate of 35 bpm what is the cause
A- Adam stokes
B- AV nodal tachycardia
C- WPW syndrome
D- Atrial prematurity
Ans: A

281-In moderate exercise what happen
A- Increase TPR
B- Arterial PO2 decrease
C- Increase PCO2
D- Increase Stroke volume
E- Decrease Stroke volume
Ans: D

282- Distinct feature of cardiac muscle
A- Receive Blood supply from arteries directly arise from aorta
B- Draw 70-80% oxygen from blood of arteries
C- Have single nucleus
D- Have Triangular nucleus
Ans: B

283- Similarity between Cardiac and skeletal muscles is
A- Transverse striations
B- Mononucleated
C- Intercalated disc
D- Lacks T tubules
Ans: A
Explanation:
- Common feature between smooth and skeletal muscle -Increase intracellular Ca before contraction
- Common feature between cardiac and skeletal muscle -Transverse striation
- Difference between Skeletal and smooth muscle -Ca Calmodulin complex in Smooth muscle

284- Increase in viscosity of blood is related to
A- Increase radius of capacitance
B- Increase radius of resistance arteriole
C- Increase mean arterial pressure
D- Decrease mean arterial pressure
Ans: C

285- Decrease height and slope of action potential is due to
A- Hypernatremia
B- Hyperkalemia
C- Hypokalemia
D- Hyponatremia
Ans: D

286- 1st heart sound is due to which of following
A- Rapid ejection
B- Rapid filling
C- Isovolumatric relaxation
D- Isovolumatric contraction
E- Slow filling
Ans: D
Explanation:
- **First heart sound** – Isovolumetric contraction (Closure of mitral and tricuspid valve)
- **Second Heart Sound** – Isovolumetric relaxation (Closure of aortic and Pulmonary valve)
- **Third Heart Sound** – Rapid ventricular filling (Normal in children, pregnancy and athletes)
- **Fourth heart sound** – Atrial Systole

287- Heart works as a syncytium because of
A- Gap junctions
B- Intercalated disc
C- Tight Junction
D- Desmosomes
E- Autonomous
Ans: A

288- Striated muscle that rhythmically myogenically contract in synchronized fashion
A- Skeletal muscles
B- Smooth muscles
C- Cardiac muscle
D- Ciliary body
Ans: C

289 Baroreceptors maintaineb ——
A- Mean arterial pressure
B- Decrease TPR
C- Venous compliance
D- Cardiac output
E- Oxygen
Ans: A

290- Neurophysiologist while stimulating a - nerve is unable to generate action potential due to
A- Hypernatremia
B- Hyponatremia
C- Hyperchloremia
D- Hypokalemia
Ans: D
Explanation:
- **Hypocalcemia** – Increase excitability
- **Hypercalcemia** – Decrease excitability
- **Hypokalemia** – Decrease nerve excitability in RMP & difficult to create AP
- **Hyperkalemia** – Increase nerve excitability in RMP
- **Hyponatremia** – Decrease height of action potential.
- **Hypernatremia** – Increase height of action potential

291- Child playing jungle lion game he got - goosebumps what is mechanism ——
A- Relaxation of erector pilli muscle
B- Constriction of erector pilli muscle
C- Epidermis
D- Eversion of hair follicles
E- Follicle rupture
Ans: B

292- ECG show normal P waves but wide QRS heart rate is 25 Pace Maker in
A- AV node
B- SA node
C- Bundle of His
D- Purkinje Fibers
Ans: D

CamScanner

Explanation:
Heart rate and location of pacemaker:
- SA node--60-80
- AV node--40-60
- Purkinje fibers --20-40

293. 3rd heart sound due to:
A- Rushing of blood rapidly in ventricle
B- Contraction of atria over stenotic valve
C- Opening of Semilunar Valve
D- Closure of Mitral Valve
Ans: A

Explanation:
- First Heart Sound – Isovolumetric contraction (Closure of mitral and tricuspid valve)
- Second Heart Sound – Isovolumetric relaxation (Closure of aortic and Pulmonary valve)
- Third Heart Sound – Rapid ventricular filling (Normal in children, pregnancy and athletes)
- Fourth heart sound – Atrial Systole

294. Increase right atrial pressure increase mean systemic pressure decrease venous resistance cause is
A- Sympathetic
B- Parasympathetic
C- Exercise
D- Stress
E- Fever
Ans: C

295. Na-k ATPase inhibition in cardiac cell leads to?
A- Increased intracellular chloride
B- Increased intracellular calcium
C- Increased intracellular potassium
D- Decreased intracellular calcium
E- Decrease intracellular sodium
Ans: B

296. Neck Veins normally don't distend they distend when right atrial pressure rises above
A- 8+
B- 22+
C- 10-
D- 30-
Ans: A

297. Patient having SVT affect of vagal maneuvers will be
A- Decrease PR interval
B- Increase Heart rate
C- Increase Blood pressure
D- Increase PR interval
Ans: D

298. Increase venous return with increase in
A- Venous compliance
B- Vagal tone
C- TPR
D- Right atrial pressure
Ans: B

299. Beta adrenergic cause which of following effect?
A- Cardiac accelaration
B- Cardiac decelaration
C- Vasocontriction
D- Vasodilation
E- Piloerection
Ans: A

300. Myogenic vascular response to HTN is
A- Vasodilation
B- Vasoconstriction
C- Local metabolite
D- Variable
Ans: B

Explanation:
- High BP leads to Vessel wall vasoconstriction result in Reflex vasoconstriction in organs to prevent end damage to organs

301. In vascular smooth muscle, the myogenic response is:
A- Contraction in response to increased blood pressure
B- Contraction in response to O2
C- Contraction in response to thromboxane, vasopressin, angiotensin II or endothelin
D- Relaxation in response to CO2
E- Relaxation in response to NO, histamine, prostacyclin
Ans: A

302. A patient known case of mitral stenosis is having irregularly irregular pulse most common finding on JVP:
A- Giant a wave
B- Absent a wave
C- Absent c wave
D- Gaint v wave
Ans: B

Explanation:
MS leads to Atrial fibrillation
In Atrial fibrillation
Absent P wave on ECG
Absent a wave on JVP wave form

303. After passing wedge shape catheter pressure increase by 5mmHg which one will increase?
A- ANP
B- BNP
C- Aldosterone
D- Potassium
Ans: A

304. Maximum aortic pressure in which phase of cardiac cycle?
A- Rapid ventricular filling
B- Reduced ventricular filling
C- Isovolumetric contraction
D- Rapid ejection phase
E- Isovolumetric relaxation
Ans: D (No option of reduced ejection)

Explanation:
Max aortic pressure – Reduced Ejection >Rapid ejection
Min aortic pressure – Isovolumetric Contraction
Max ventricular pressure – Rapid Ejection
Min ventricular pressure – Rapid Filling

305. Increase in Mean arterial pressure will cause:
A- Decrease in TPR
B- Increase venous return
C- Increase in TPR
D- Increase blood flow
Ans: C

306. Ventricles recieve impulses directly from?
A- Purkinje
B- Bundle of his
C- Right bundle branch
D- Left bundle branch
Ans: A

307. Normal beat after The extra systolic beat would produce:
A- Increase pulse pressure because contractility is increased.
B- Increase pulse pressure because HR is increased
C- Decrease pulse pressure because ventricular filling is increased
D- Increase pulse pressure because SV is Increased
E- Decrease pulse pressure because the PR interval is increased
Ans: D

Explanation:
Extra systole will cause – Decrease pulse pressure.
Normal beat after extra systole cause – Increase pulse pressure.

308. Which of the following is responsible for preserving organism "as a whole" in fear and shock state??
A- Collateral circulation of CNS
B- Sympatho adrenal discharge
C- Pulmonary circulation
D- CNS ischemic response
Ans: B

309. Aortic valves open during which phase of cardiac cycle?
A- Isovolumetric contraction
B- Isovolumetric relaxation
C- Rapid ejection
D- Slow ejection
Ans: C

310. A student of final year mbbs witnessing surgery for the first time collapsed in OT due to:
A- Decrease in peripheral resistance
B- Increase vascular permeability
C- Decrease CO
D- Sympathetic shock
E- Decrease cardiac output
Ans: A

311. In ECG complete ventricular depolarization:
A- QRS complex
B- ST segment
C- PT interval
D- TP segment
E- PR Interval
Ans: B

Explanation:
- Complete ventricular depolarization – ST segment
- Ventricular depolarization – QRS

312. Effect of Glucagon on heart is like
A- Dopamine
B- Epinephrine
C- Nor epinephrine
D- Cortisol
E- Acetylcholine
Ans: B

313. Atria stretch leading to tachycardia this is
A- Herring Breuer reflex
B- Cushing reflex
C- Brain Bridge reflex
D- Sinus tachycardia
E- Chemoreceptor
Ans: C

CamScanner

314. Third heart sound due to:
A- Isovolumetric contraction
B- Isovolumetric relaxation
C- Atrial systole
D- Rapid Ventricular filling
E- Rapid ejection
Ans: D(FA + BRS)

Explanation:
- First heart Sound – Isovolumetric contraction (Closure of mitral and tricuspid valve)
- Second Heart Sound – Isovolumetric relaxation (Closure of aortic and Pulmonary valve)
- Third Heart Sound – Rapid ventricular filling (Normal in children, pregnancy and athletes)
- Fourth heart Sound – Atrial Systole

315. 5kg infant will have the blood volume:
A- 420 ml
B- 500ml
C- 350ml
D- 320ml
E- 280ml
Ans: A (80-85ml/kg)

Explanation: 85*5 =425 close ans A

316. Normal cerebral blood flow?
A- 50ml/min
B- 150ml/min
C- 600ml/min
D- 750ml/min
Ans: D

Explanation:
- Brain consumes 20% of total Body oxygen
- Brain oxygen consumption is 3.5 ml/min/100gm of tissue
- Cerebral blood flow – 50ml /min/100gm of tissue total 750
- Glucose extraction is 5mg /min/100gm of tissue

317. In normal healthy person Sympathetic activity is increased to increase blood flow to
A- Heart
B- Skin
C- Muscle
D- Lung
Ans: C

318. During exercise No change in blood flow to which organ
A- Heart
B- Brain
C- Skeletal muscles
D- Kidneys
E- Lung
Ans: B

319. Patient with 15-20% blood loss,what should be given via infusion:
A- 3% N/S
B- Ringer lactate
C- Colloid
D- Blood
Ans: A

320. Which of the following is the initial mechanism that stops bleeding after a cut?
A- Platelet aggregation
B- Degranulation
C- Vasoconstriction
D- PGI2 release
E- Vasodilation
Ans: C

321. A patient presents with HR 102bpm, BP 90/60 mmHg and tachypnea. On standing her HR increases to 110bpm. What is the mechanism behind this?
A- Increase venous return
B- Increase vasoconstriction
C- Increase contractility
D- Decrease Venous return
E- Increase ICP
Ans: D

Explanation:
- When Person Stands from Sitting Venous return Decrease which then Leads to Compensatory Things which are Increase Heart Rate and Increase Cardiac Output so basic Mechanism underlying compensatory changes is Decrease Venous Return
- Mechanism for Compensation – Decrease venous return
- Compensatory Changes – Increase heart rate and cardiac output.

322. Action of Norepinephrine on heart
A- Decrease HR
B- Decrease heart contractility
C- Increase AV conduction
D- Increase BP
E- Decrease cutaneous blood flow
Ans: C

323. Ventricles maximally filled at:
A- End of atrial systole
B- Rapid ejection
C- Slow ejection
D- Isovolumic contraction
E- Isovolumic relaxation
Ans: A

Explanation:
- Max Ventricle Filled -- Atrial Systole
- Max Ventricle Filling -- Rapid Filling

324- Venous return decreases in:
A- Skeletal muscle paralysis
B- Femoral arteriovenous fistula
C- Increased BP
D- Increased Cardiac Output
Ans: A

Explanation:
- Skeletal muscle pump in legs contract then open valves in veins of leg so push blood to heart so if skeletal muscle paralysis occur there will be decrease venous return

325- Cardiac output of the right side of the heart is what percentage of the cardiac output of the left side of the heart:
A- 25%
B- 50%
C- 75%
D- 100%
E- 125%
Ans: D

326- Venous return is directly proportional to?
A- Intrathoracic pressure
B- Cardiac output
C- Stiffness of vessel
D- Mean systemic filling pressure
E- Intra-abdominal pressure
Ans: D

327- Fourth heart sound is due to which of following:
A- Rapid ejection
B- Rapid filling
C- Isovolumetric relaxation
D- Atrial depolarization
E- Slow filling
Ans: D

Explanation:
- First heart sound – Isovolumetric contraction (Closure of mitral and tricuspid valve)
- Second Heart Sound – Isovolumetric relaxation (Closure of aortic and Pulmonary valve)
- Third Heart Sound – Rapid ventricular filling (Normal in children, pregnancy and athletes)
- Fourth heart sound – Atrial Systole

328- Pacemaker of heart is
A- SA node
B- AV node
C- Bundle of HIS
D- Purkinje fibers
Ans: A

329- Contraction of valve will be seen on JVP waveform as
A- V wave
B- C wave
C- X descent
D- P wave
Ans: B

330- ANP is released by following mechanisms
A- Ventricular stretch
B- Atrial relaxation
C- Atrial stretch
D- Purkinji fiber contraction
Ans: C

Explanation:
- ANP -Atria
- BNP- Ventricle

331- A young girl in supine position with bp 80/50 and pulse 100 when she stand her pulse rate increase to reason for this increase in pulse?
A- Decrease contractility of heart
B- Decrease venous return to heart
C- Decrease Sympathetic
D- Increase TPR
Ans: B

Explanation:
When a person stand from supine there will be decrease venous return and in compensation baroreceptor will decrease firing rate and sympathetic outflow increase which cause increase HR and increase cardiac output.

332- 60% Ventricles filled at:
A- End of atrial systole
B- Rapid ejection
C- Slow ejection
D- Isovolumic contraction
E- Isovolumic relaxation
Ans: A

Explanation:
- Max Ventricle Filled -- Atrial Systole
- Max Ventricle Filling -- Rapid Filling

333- Persons heart rate is 80, ECG will show
A- R-R interval of 0.65 second
B- R-R interval of 0.75 seconds
C- R-R interval of 0.95 second
D- P-R interval of 0.85 second
Ans: B

Explanation:
R-R interval of 0.75 means 20 small boxes
Each small box is of 0.04 sec
Heart rate = 1500/No of small boxes
= 1500/20
=75
So 75 Heart is near 80 equal to R-R interval of 0.75 Second

CamScanner

334- 1 litre blood loss, which physiological parameter will decrease:
A- BP
B- R/R
C- Stroke volume
D- Venous return
Ans: C (B.P decrease after 1.5L blood loss)

335- After vagal stimulation of heart, heart rate slows down, permeability of SA node increased for:
A- Mg
B- K
C- Cl
D- Ca
E- Phosphorus
Ans: B(BRS Physio)

Explanation:
Parasympathetic act on SA Node and decrease Heart rate (Negative Chronotropic) via
1- Decrease Na Influx (Decrease Pacemaker current)
2- Increase K Efflux (Hyperpolarization)
Parasympathetic act on AV Node and decrease Conduction of AV Node (Negative Dromotropic)

336- Neutrophils granulocytes increased in:
A- Chronic bacterial infection
B- Cardiac infarcts
C- Chronic lymphoma
D- Leukemia
Ans: B

337- A group of students were studying difference between PO2 and PCO2 in different arteries of the body. They find major differences between:
A- Aorta and Pulmonary Artery
B- Skeletal muscle arteriole and venule
C- Aorta and Left ventricle
D- Right and Left Ventricle
E- Aorta and Superior Vena cava
Ans: A

338- Event occuring just before opening of aortic valve:
A- Beginning of diastole
B- Beginning of systole
C- Isovolumetric relaxation
D- Slow ejection
Ans: B

339- Which parameter of heart is checked during exercise:
A- Stroke volume
B- Cardiac output
C- Pulse pressure
D- Ejection fraction
Ans: B

340- Normal EDV is:
A- 60 ml
B- 80 ml
C- 120ml
D- 50ml
Ans: C

341- During hypertension in retina in grade-3 edema what will be damaged:
A- Arteriole
B- Veins
C- Capillaries
D- Venules
Ans: A

342- Hyperaemia is seen in Child speaking loudly what best describes Hyperaemia:
A- Acute infection
B- Chronic infection
C- Active process
D- Passive process
Ans: C

343- Motor bike rider falls from bike with heavy bleeding baroreceptor will diminish:
A- Venous compliance
B- Heart rate
C- TPR
D- Pulse rate
Ans: A

344- Low concentration epinephrine from medulla causes vasodilation via:
A- B1 adrenergic
B- B2 adrenergic
C- Cholinergic
D- M2
Ans: B

345- In a Person having regular exercise has HR of:
A- 80 Beats/min
B- 80 to 100 Beats/min
C- 120 Beats/min
D- 140 Beats/min
Ans: A

346- Slowest speed of conduction velocity is present in which of following?
A- AV Node
B- Purkinje fibers
C- Bundle of His
D- Ventricle
E- Bundle of Kent
Ans: A

Explanation:
Purkinje fibres > Bundle of His > Atria > Ventricles > SA node> AV node.

347- End systolic volume is 50ml and stroke volume is 70ml, what is the end diastolic volume?
A- 140ml
B- 60ml
C- 80ml
D- 120ml
Ans: D

348- Regarding myelinated fibres true is :
A- Low resistance
B- Na/k conductance at node
C- Action potential at internodes
D- H/K conductance at internodes
Ans: C

349- A 25year old female presents with atypical chest pain, dyspnea on exertion and palpitations. Clinical examination shows pulse rate 80/min, B.P 130/80mmhg, and a grade 2 systolic murmur ay 4th sternal border. ECG was normal, chest X-RAY was normal. Which one of the following is most likely diagnosis?
A- Aortic stenosis
B- Atrial septal defect
C- Coarctation of aorta
D- Normal heart
E- Pulmonary stenosis
Ans: D

350- Special feature of cardiac muscle is:
A- Derived 100% energy from proteins
B- Has action potential with plateau
C- Sustained action potential
D- Get easily fatigued
Ans: B

351- During exercise coronary blood flow is maintained by
A- Sympathetic blood stimulation
B- Local metabolites
C- Parasympathetic output
D- Blood pressure
Ans: B

352- A patient was transfused blood after trauma. Most of the replaced blood volume goes to?
A- Veins and venules
B- Arteries and arterioles
C- Venules and arterioles
D- Capillaries and veins
E- Capillaries and arterioles
Ans: A

353- In EKG Heart rate is 120/min it is related to
A- R-R interval will be 0.5 sec
B- QRS complex will be less than 0.02 sec
C- T wave will be greater than 2 mv
D- R-R interval will be 1 sec
Ans: A

Explanation:
1 min = 60 Second
R-R interval = Sec/ Heart rate
= 60/120
= 0.5 Sec

354- S2 Heart Sound is shown on JVP with right atrial waveform appear as
A- C Wave
B- V Wave
C- X Descent
D- Y Descent
E- A Wave
Ans: E

355- The action potential of SA node is caused by:
A- Entry of Na
B- Entry of Cl
C- K efflux
D- Ca ions
E- Cl efflux
Ans: D

Explanation:
- Pace Maker activity of SA Node due to – Sodium Channels
- Action Potential of Pace Maker due to – Calcium Channels
- Action Potential of Cardiac Muscle due to – Sodium Channels

356- During ventricular ejection, the minimum pressure gardient is between:
A- Left atrium and ventricle
B- Left ventricle and aorta
C- Right atrium and ventricle
D- Pulmonary artery and left atrium
Ans: D

357- The semilunar valve opening is seen at which phase?
A- Reduced ejection
B- Isovolumetric contraction
C- Isovolumetric relaxation
D- Slow filling phase
E- Rapid ejection
Ans: E

CamScanner

Explanation:
- Prefer Begning of rapid ejection phase or can be end of Isovolumetric contraction if no other option available.
- At the beginning of Isovolumetric contraction AV valve(Mitral and tricuspid) closes produces first heart sound
- At the end of Isovolumetric contraction Aortic valve(Semilunar valve) closes
- At the beginning of rapid ejection aortic valve (Semilunar valve) open

358- Around 60% Ventricles filling occurs in
A- Aortic systole
B- Rapid filling phase
C- Slow filling phase
D- Isovolumetric relaxation
Ans: B

359- After a road traffic accident massive blood loss patient undergoes shock BP 85/60 what will activate now:
A- RAAS
B- CNS Ischemic response
C- Release of Renin
D- Baroreceptor reflex mechanism
Ans: D

Explanation:
MAP is calculated as
PP =Systolic -Diastolic =85-60=25
1/3rd of PP = 8.3
MAP=Diastolic BP + 1/3rd PP
60 +8.3=68.3

360- At the time of birth what will be seen in child?
A- Increase Systemic vascular resistance
B- Increase Pulmonary vascular resistance
C- Increase pulmonary arterial pressure
D- Increase systemic arterial pressure
Ans: A

361- Left ventricle , LBB and RBB supplied by
A- RCA
B- LCA
C- Posterior interventricular artery
D- Right ventricular artery
Ans: B

362- In trace of jvp the wave produced by Right ventricular contraction is:
A- C wave
B- V wave
C- X descent
D- Y descent
E- A wave
Ans: A

363- Patient presented in shock-like condition after RTA, multiple soft tissue injuries, cause of shock in this condition is?
A- Sepsis
B- Inadequate blood volume
C- Peripheral vasodilation
D- Anaphylaxis
Ans: C

364- Main difference between Pulmonary & Syatemic circulation is:
A- Decreased TPR
B- Increased Compliance in pulmonary circulation
C- Increased TPR
D- Decreased Compliance in Pulmonary circulation
Ans: A

365- A student of Final year MBBS witnessing Surgery for the first time collapsed in OT due to:
A- Dec peripheral resistance
B- Dec Firing rate of baroreceptors
C- Dec venous compliace
D- Dec Map
E- Vasovagal shock
Ans: E (vasovagal >TPR)

366- Pericardiocentesis is best performed bypassing a needle through:
A- Subcostal with needle angle superiorly
B- Supracostal with needle angle inferiorly
C- Left 5th intercostal space inferiorly
D- Subcostal with needle angle inferiorly
Ans: A

367- Along with thermo receptors pain receptors are also stimulated for sensation of:
A- Cold
B- Hot
C- Warmth
D- Freezing cold
E- Crude pressure
Ans: D

368- After myocardial injury what biochemical changes will be seen in hypoxia:
A- Aerobic Glycolysis
B- Oxidative Phosphorylation
C- Anaerobic Glycolysis +Glycogenesis
D- Gluconeogenesis
Ans: C

369- S1 and S2 hearts soundsthe former has
A- More Frequency
B- More Duration
C- Less Dullness
D- More Frequency
E- No difference
Ans: B

Explanation:
- S1 heart sound has more duration and dullness than S2
- S2 heart sound has more Frequency and pitch than S1

370- End left ventricle Diastolic Volume depends on which one
A- Venous return
B- Stretch of ventricle fibers
C- TPR
D- Stretch of Atrium
Ans: A

Explanation:
- Preload determine by – EDV (Depends on venous return)
- After load determine by – MAP
- TPR determine by – Diastolic BP

371- Which one of the follwing wave on jvp is produced by bulging of tricuspid valve during right ventricular contraction
A- A wave
B- Y wave
C- C wave
D- X wave
Ans: C

372- A patient presented with decrease heart rate in ER. On standing her pulse increase due to
A- Decrease in venous return
B- Increase in venous return
C- Increased TPR
D- increase pulse pressure
Ans: A

373- In EKG Heart rate is 120/min it is related to
A- R-R interval will be 0.5 sec
B- QRS complex will be less than 0.02 sec
C- T wave will be greater than 2 mv
D- R-R interval will be 1 sec
Ans: A

Explanation:
- 1 min = 60 Second
- R-R interval = Sec/ Heart rate
  = 60/120
  = 0.5 Sec

374- The best determinant of Preload is:
A- Left Ventricular End Diastolic Volume
B- Left Ventricular End Diastolic Pressure
C- Mean Arterial Pressure(MAP)
D- Venous Return
E- Raised Pulmonary Capillary wedge pressure
Ans: A

375- In trace of jvp the wave produced by Right ventricular contraction is:
A- C wave
B- V wave
C- X descent
D- Y descent
E- A wave
Ans: A

376- A person does heavy exercise regularly. What will be his heart rate at rest?
A- 80bpm
B- Between 100 to 150bpm
C- >150bpm
D- Below 60bpm
E- Between 130 to 150
Ans: D

377- When You run, Venous return increases due to:
A- Increased Contraction of Calf Muscles
B- Decreased TPR
C- Increased contractility of heart
D- Increased Muscle Tone
E- Increased Breathing rate
Ans: A

378- A Patient presented with chest pain. ECG was done which showed irregular heart beat, prominent U waves. What is the likely cause?
A- Hypokalemia
B- Hyperkalemia
C- Hyponatremia
D- Hypermagnesemia
E- Hypocalcemia
Ans: A

379- A patient presented with irregular pulse. On Ecg, Absent P waves and irregular R-R interval. This is corresponding to increased firing from:
A- SA node
B- AV node
C- Purkinje Fibers
D- Atria
E- Bundle of His
Ans: D

CamScanner

380- Beginning of Ventricular contraction displacing the valve upward causes which wave in JVP?
A- C wave
B- A wave
C- X Descent
D- V wave
Ans: A

381- Patient after RTA has chest pain which one will be raised
A- ALT
B- CPK
C- LDH
D- AST
E- CK MB
Ans: B

382- A person went to 3rd floor from stairs and increase cardiac output cause of increase cardiac output:
A- Increase preload
B- Decrease Contractility
C- Decrease Sympathetic
D- Increase TPR
Ans: A

383- Apex beat is located at
A- Left 5th intercostal space
B- Right 4th ics
C- 3rd left intercostal space
D- 5th Right intercostal space
Ans: A

384- Most of left ventricle, LBBB and RBB are supplied by?
A- LCx
B- LCA
C- Post descending artery
D- RCA
E- Marginal Artery
Ans: B

385- Two athletes are sitting in room. One is professional and other is new. Difference in former athlete?
A- Increased Heart Rate
B- Increased Cardiac output
C- Decreased respiratory rate
D- Hypertension
Ans: B

386- Recurrent Syncope with change in posture due to:
A- Aortic stenosis
B- Coronary steal syndrome
C- Vasovagal Stimulation
D- Dilated cardiomyopathy
E- Myxoma
Ans: C

387- Lowest venous pressure in standing person at?
A- Superior sagittal sinus
B- Internal jugular vein
C- SVC
D- IVC
E- Lower leg veins
Ans: C

388- Atrial repolarization is masked on ECG by which wave?
A- QRS complex
B- T Wave
C- P Wave
D- Q wave
Ans: A

389- A patient came to Cardiac ICU 80hrs post MI. Which investigation will u do?
A- LDH2
B- CKMB
C- CKMM
D- MYOGLOBIN
E- LDH1
Ans: E

390- Main arterial supply to interventricular septum:
A- Right coronary artery
B- Left coronary artery
C- LADA
D- Post interventricular artery
E- Anterior interventricular artery
Ans: C

391- Athletes heart rate is permanently 50 due to:
A- Increased Cardiac Output
B- Increased Stroke Volume
C- Decreased Stroke Volume
D- Decreased Venous Return
E- Increased Ejection fraction
Ans: B

392- PR interval shows:
A- Atrial systole
B- Atrial diastole
C- Conduction from SA node to Ventricle
D- Ventricular repolarization
E- Atrial repolarization
Ans: C

393- Acute left ventricular failure drug of choice will be:
A- Infusion nitrates
B- IV Digoxin
C- IV A minophylline
D- IV Amiodarone
E- IV Furosemide
Ans: E (Katzung)

394- After a road traffic accident massive blood loss patient undergoes shock BP 85/40 what will be most important mechanism now:
A- RAAS
B- CNS Ischemic response
C- Release of Renin
D- Baroreceptor reflex mechanism
Ans: B

Explanation:
MAP is calculated as
PP = Systolic – Diastolic = 85-40=45
1/3rd of PP =15
MAP = Diastolic BP + 1/3rd PP
40 + 15 = 55
Baroreceptor respond maximally to – Increasing BP (Ganong).
Most rapid response to decrease BP – Baroreceptor.
Most potent response to decrease BP – CNS ischemiC-
CNS ischemic activate at – 60 or below 60mmHg (Guyton).
Maintain during shock – Baroreceptor
Maintain As a whole – RAAS
Short term BP control – Baroreceptor
Long term BP control – RAAS

395- Contraction of valve will be seen on jvp waveform as?
A- A Wave
B- C Wave
C- V Wave
D- P wave
Ans: B

396- Which of the following is a specialized feature of cardiac muscle?
A- Never gets tetanized
B- Due to the plateau phase
C- Multinucleated
D- Striated
E- Voluntary control
Ans: B

397- Changes in the lengths of the left atrial tracing can be due to which of the following?
A- Changes in heart rate
B- Variations in ventricular filling
C- Changes in left atrial pressure
D- Alterations in cardiac output
Ans: C

398- Increase ICP and increase BP is part of?
A- Virchow's triad
B- Cushing triad
C- HTN crisis
D- Beck's triad
Ans: B

399- Ecg of pt shows progressive prolongation of PR interval in successive beats followed by dropped heartbeat. Problem lies in which part of conducting system?
A- AV node
B- SA node
C- Purkinje fibers
D- Bundle of his
E- Left ventricle
Ans: A

400- 53 years old Pt had chest pain and presented within 4 hours which investigation will be appropriate for this patient
A- CPK
B- CKMB
C- Trop T
D- Myoglobin
E- LDH
Ans: B

Explanation:
- Best Initial Investigation of choice – ECG
- 1-2 hr – Myoglobin
- Within 4hr – CK MB
- After 4hr – Trop
- Sensitive – Trop T
- Specific – Trop I

401- When moving from a supine to a standing position, what is the primary compensatory change observed in cardiovascular physiology?
A- Increase HR
B- Decrease HR
C- Decrease CO
D- Decrease VR
Ans: A

402- In which phase is the maximum flow of oxygen per myoglobin observed, considering its role in muscle tissue?
A- Resting phase
B- Rapid contraction phase
C- Aerobic exercise phase
D- Recovery phase
E- Anaerobic exercise phase
Ans: C

403- Cardiac muscle Unique property:
A- Never get tetanized
B- Action potential with Plateau phase
C- Use 70-80% Oxygen during exercise
D- Increased Nuclei & Mitochondria
E- Pump Oxygenated Blood to the whole body
Ans: B

CamScanner

404- In normally functioning myocardium, C wave coincide with:
A- Closure of semilunar valves
B- First heart sound
C- Closure of AV valve
D- Opening of AV valve
Ans: C

405- After a road traffic accident massive blood loss patient undergoes shock BP 83/60 what will activate now:
A- RAAS
B- CNS Ischemic response
C- Release of Renin
D- Baroreceptor reflex mechanism
Ans: D

Explanation:
- MAP is calculated as
- PP =Systolic -Diastolic =83-60=23
- 1/3rd of PP = 7.6
- MAP=Diastolic BP + 1/3rd PP
- 60 +7.6=67.6

406- ECG features of hypokalemia:
A- U waves
B- Flattened T waves
C- Peaked T waves
D- Tetany
E- Osteomalacia
Ans: A>B

Explanation:
High serum potassium concentration
- Wide QRS
- Peaked T waves on ECG
- Arrhythmias
- Muscle weakness

Low serum potassium concentration
- Uwaves
- Flattened T waves on ECG
- Arrhythmias
- Muscle cramps
- Spasm
- Weakness

407- Increase in right atrial pressure leads to which important Mechanism by atria ?
A- Increased cardiac output
B- Increase in ANP release
C- Increased Vascular Compliance
C- Vagal motor stimulation
D- ADH release
Ans: B

408- "Frank- Starling law" states that Force of Heart Contraction depends upon:
A- ↑ cardiac muscle fiber stretch
B- ↑ cardiac contractility
C- Proportional to initial length of Myocardial Fiber
D- Decreased Cardiac Contractility
E- Calcium Influx
Ans: C(Ganong physiology)

Explanation:
- As the muscle is stretched, the developed tension increases to a maximum and then declines as stretch becomes more extreme.
- Starling pointed this out when he stated that the "energy of contraction is proportional to the initial length of the cardiac muscle fiber" (Starling's law of the heart or the Frank–Star-ling law).
- For the heart, the length of the muscle fibers (ie, the extent of the preload) is proportional to the end-diastolic vol-ume.
- The relation between ventricular stroke volume and end-diastolic volume is called the Frank–Starling curve

409- Percentage of blood pumped out per beat is:
A- Stroke Work
B- Heart rate
C- Ejection fraction
D- MAP
E- Cardiac Output
Ans: C

410- Pulse Pressure Increased by:
A- EDV
B- Stroke Volume
C- Systemic Vascular Resistance
D- Decreased Heart Rate
E- Venous Tone
Ans: B

411- An increase in inspiration will decrease which of the following in cardiovascular system:
A- Gradient from external vessels into Right atrium
B- Right Atrial filling
C- Right Atrial Contraction
D- Left Ventricular Contraction
Ans: D

Explanation:
- During inspiration, negative intrathoracic pressure increases venous return to the right heart, causing right atrial and right ventricular filling to increase. This can transiently reduce left ventricular filling due to the interventricular septum shifting toward the left ventricle, thereby slightly decreasing left ventricular contraction

412- A patient presents with mild hemorrhage and a blood pressure of 90/60 mmHg. Compensation occurs through baroreceptor activation, which induces various physiological changes to restore blood pressure. Which of the following is least likely to change during this compensation?
A- Stroke Volume (SV)
B- Heart Rate (HR)
C- Venous Return
D- Ejection Fraction
Ans: D

413- Effect of Carotid massage on Parasympathetic Nervous system(Medicine Feb 2025:
A- Increased PR interval
B- Decreased RR interval
C- Decreased QRS complexes
D- Increased Heart Rate
E- Increased Blood Pressure
Ans: A

Explanation:
- Carotid massage stimulates the baroreceptors in the carotid sinus, which activates the parasympathetic nervous system (via the vagus nerve) and inhibits the sympathetic nervous system. This results in:
- Increased PR interval due to slowed conduction through the AV node.
- Prolonged RR interval (not decreased. due to a lower heart rate.
- Decreased heart rate (bradycardia), not increased.
- No significant effect on the QRS complexes or direct increase in blood pressure; in fact, it may cause a transient decrease in blood pressure due to reduced heart rate and cardiac output.

414- The left Circumflex artery supplies which of the following structures (Medicine Feb 2025):
A- Posterior surface of left ventricle
B- Anterior surface of left ventricle
C- Left and right ventricle
D- Anterior interventricular septum
F- Right atrium and right ventricle
Ans: A

415- Effect of inspiration (Medicine Feb 2025):
A- Dec ventricular filling
B- Dec right ventricular emptying
C- Momentarily inhabited
D- Dec left ventricular ejection
Ans: B

416- Patient sitting in room under normal environmental conditions, heat loss will be by(Medicine Feb 2025):
A- Radiation
B- Conduction
C- Radiation & Conduction
D- Convection
Ans: A

Explanation:
- Patient naked heat loss by – Radiation
- Patient naked and lying on surface (Table) heat loss by – Conduction
- Patient naked and temp mention heat loss by – Radiation + Conduction
- Patient naked and humidity mention heat loss by – Convection

417- Increase in blood viscosity causes increase in(Surgery Feb 2025)
A- Pulse pressure
B- Increase CO
C- Stroke volume
D- Diastolic pressure
Ans: B

418- TPR is related to(Surgery Feb 2025)
A- Vascular compliance
B- Vascular Tone
C- Heart Rate
D- Stroke Volume
Ans: B

419- Cardiac output depends upon(Surgery Feb 2025):
A- Increased heart rate
B- Increased stroke volume
C- Increased Preload
D- Increased Venous Return
E- Increased End Diastolic Volume
Ans: D

CamScanner

420- A 54- year-old male is seen in clinic with complaints of palpitations and light-headedness. Physical examination shows a heart rate of 200 bpm and BP of 75/40 mmHg. The most likely adjustment that has occurred in the cardiac cycle is(Surgery Feb 2025):

A- Diastolic time decreases and systolic remain same
B- Diastolic time increases and systolic remains the same
C- Diastolic decreases more in proportion to systolic
D- Diastolic decreases and systolic increases
E- Diastolic increases and systolic decreases
Ans: C

421- The Sinuatrial Node is supplied by(Surgery Feb 2025):

A- 60% from RCA
B- 40% from RCA
C- 60% from LCA
D- 80% from LCA
E- The Circumflex Artery
Ans: A

Explanation:
- Right coronary artery supply 60% of individuals
- Left circumflex artery supply 40% of individuals

422- Most important determinant of cardiac Output(Surgery Feb 2025)

A- Heart rate
B- Stroke volume
C- EDV
D- Venous return
E- Preload
Ans: B

423- What is the action of norepinephrine on the sympathetic system in the heart? (Surgery Feb 2025)

A- Increases diastolic filling at the SA node
B- Increases AV nodal delay
C- Increases contraction in the atria
D- Decreases heart rate
Ans: C

424- During exercise, blood flow remains unchanged to(Surgery Feb 2025):

A- Skin
B- Skeletal Muscle
C- Brain
D- Heart
Ans: C

425- PR interval on ECG Coincides with Which wave on JVP (Surgery Feb 2025):

A- A-C wave
B- A wave
C- X wave
D- Y descent
E- C & X
Ans: A

426- A young healthy male 25 Years old presented with Heart rate 60 & Stroke volume of 50%.He is most likely suffering from(Gynae & Obs Feb 2025)

A- Athlete
B- Trained individual
C- MI
D- CHF
Ans: A

427- Left atrium supplied by(Gynae & Obs Feb 2025):

A- LAD
B- Left circumflex artery
C- RCA
D- Conus artery
Ans. B

428- Parasympathetic effect on heart increases permeability in SA node to(Gynae & Obs Feb 2025):

A- Sodium
B- Potassium
C- Calcium
D- Potassium and sodium
E- Sodium and calcium
Ans: B

429- Digitalis effect(Gynae & Obs Feb 2025)?

A- Chronotropic
B- Negative Inotropic
C- Increases oxygen demand
D- Increase the force of Contraction
Ans: D

430- Cardiac muscle cannot be tetanized because(Gynae & Obs Feb 2025)

A- Action potential with plateau
B- Pump oxygenated blood to whole body
C- long refractory period
D- Use 70-80% O2 at exercise
E- Highest number of Mitochondria
Ans: C

431- True regarding Heart muscle(Gynae & Obs Feb 2025)

A- Autonomic supply
B- Striated
C- Get Fatigued Easily
D- Somatic Nerve Supply
Ans: A

432- In which of the following cardiac phase semilunar valves open(Radiology Feb 2025)

A- Slow ejection phase
B- Rapid ejection phase
C- Isovolumatric contaction
D- Isovolumatric relaxation
E- Rapid filling phase
Ans: B

433- The PR interval on the ECG corresponds to which of the following on JVP(Radiology Feb 2025)

A- A wave
B- C wave
C- V wave
D- A to C wave
E- Y decent
Ans: D

434- If the radius of a blood vessel is reduced to half of its original size due to a pre-occlusive valve, which parameter will increase 16 times?(Radiology Feb 2025)

A- Resistance
B- Blood flow
C- Viscosity
D- Capillary pressure
Ans: A

435- Increase viscosity of blood causes decrease in: (Anesthesia Feb 2025)

A- Systolic BP
B- Diastolic BP
C- Pulse pressure
D- Capillary Perfusion
Ans: D

436- What is the primary effect of digitalis on the heart?(Anesthesia Feb 2025)

A- Inotropic
B- Chronotropic
C- Bathmotropic
D- Dromotropic
Ans: A

CamScanner

GIT PHYSIOLOGY QUICK HINTS

Autonomic effect

- Myenteric plexus (Auerbach's plexus) - primarily controls the motility of the GI smooth muscle
- Submucosal plexus (Meissner's plexus) - primarily controls secretion and blood flow.

Parasympathetic causes

- Relaxation of GIT sphinter
- Relaxation of Fundus
- Contraction of body of stomach
- Decrease Heart rate
- Increase secretion
- Vice versa for sympathetic

GIT Harmones

CCK

- ✓ Secreted by I Cells duodenum and jejunum
- ✓ Increase Intestinal Motility
- ✓ Decrease Gastric Emptying
- ✓ Increase Pancreatic Secretion
- ✓ Increase Gall Bladder Contraction
- ✓ Increase Sphincter of Oddi relaxation
- ✓ 33 amino acids

Gastrin

- ✓ Secreted by G Cells of stomach
- ✓ Increase Gastric Emptying
- ✓ Increase Growth of Gastric Mucosa
- ✓ Increase Gastric H Secretion
- ✓ Little gastrin 17 amino acid and big gastrin 34 amino acids

Secretin

- ✓ Secreted by S Cells of dudenum
- ✓ Increase pancreatic HCO_3 secretion
- ✓ Increase bile secretion
- ✓ 27 amino acids

Endocrine – Hormone which distributed in blood and bind to target cell e.g. Thyroid harmones, GH, insulin, Epinephrine Estrogen, progesteron and Testosteron
Autocrine – Hormone which has effect on same cell that produce it e.g. Eicosanoids (Prostaglandins, Thromboxanes, Prostacycline and Leukotriens)
Paracrine – Hormone which has affect in local area of production e.g Somatostatin Eicosanoids and Histamine
Neurocrine – Secreted by neuron in presynaptic cleft and affect post synaptic cleft e.g Acetylcholine and Epinephrine , VIP ,Enkephalins and GRP(Bombesin)

Somatostatin

Pancreatic Somatostatin

It inhibits:

- ✓ Insulin
- ✓ Glucagon

Gut Somatostatin

It inhibits:

- ✓ Gastrin
- ✓ Gastric acid Production
- ✓ Bile acid
- ✓ CCK

GIT secretion

Saliva

Saliva is characterized by:

1. High volume (relative to the small size of the salivary glands)
2. High K + and HCO3 – concentrations
3. Low Na+ and Cl– concentrations
4. Hypotonicity
5. Presence of α-amylase, lingual lipase, and kallikrein

Saliva composition changes with salivary flow rate as follows

1. At **the lowest flow rates**, saliva has the lowest osmolarity and lowest Na+, Cl–, and HCO3 – concentrations, but has the highest K+ concentration.
2. At **high flow rates**, saliva is most like the initial secretion from the acinus; it has the highest Na+ and Cl– concentrations and the lowest K+ concentration.

Saliva increased by

- Sympathetic(CAMP) and parasympathetic(IP3)
- Food in mouth , smell and nausea
- Thick saliva by a1B1

Saliva inhibited by

- Atropine , Sleep and dehydration

Pancreatic secretion

Pancreatic juice is characterized by:

1. High volume
2. Virtually the same Na+ and K+ concentrations as plasma
3. Much higher HCO3 – concentration than plasma
4. Much lower Cl– concentration than plasma
5. Isotonicity
6. Pancreatic lipase, amylase, and proteases

Its composition changes with Flow rates as follows

1. At **low flow rates**, the pancreas secretes an isotonic fluid that is composed mainly of Na+ and Cl–
2. At **high flow rates**, the pancreas secretes an isotonic fluid that is composed mainly of Na+ and HCO3
3. Regardless of the flow rate, pancreatic secretions are isotonic

Pancreatic secretion increased by

- Secretin(CAMP mechanism) - Increase HCO3
- CCK(IP3 and Parasympathetic mechanism) - Increase pancreatic secretion
- Acetylcholine

A cells – Glucagon
B cells – Insulin , Amylin
D- cells – Somatostatin
F cells – Pancreatic polypeptide

Gastric secretion

- Parietal cell (Fundus or Body) – produce HCL and Intrinsic factor
- Chief cell (Fundus or Body) – Produce Pepsinogen
- G cell (Antrum) – Gastrin
- D- cell – Somatostatin
- Enterochromaffin cells - Histamine
- Mucous cell (Antrum) – Mucus and Pepsinogen

Random

- ✓ Fat inhibits gastric emptying (i.e., increases gastric emptying time) by stimulating the release of CCK.
- ✓ H+ in the duodenum inhibits gastric emptying via direct neural reflexes.
- ✓ Insulin secretion increased Gip> Secretin
- ✓ Pancreatic enzyme deficiency - Result in decrease triglycerides absorption

CamScanner

- ✓ Miscelle formation caused by Bile
- ✓ Increase Salivary Flow – Cranial Nerve 7 > 9
- ✓ Increase Small intestine Motility and Decrease Gastric motility -- CCK
- ✓ Fundus removed=↓Gastric compliance>>↓Receptive relaxation
- ✓ Antrum removed=↓ Gastric acid production
- ✓ Pylorus removed➡Solids pass easily
- ✓ Intrinsic factor released by Fundus of Stomach
- ✓ Colostomy Result in Secretory Diarrhea
- ✓ Jejunostomy Result in Osmotic Diarrhea
- ✓ illeostomy Result in Osmotic Diarrhea
- ✓ Jejunostomy+illeostomy Result in Secretory+Osmotic Diarrhea
- ✓ Iron and Calcium absorption – Duodenum
- ✓ Max water + electrolytes absorption – Jejunum
- ✓ Passive(Aldosteron independent) water and salt absoprtion -Jejunum
- ✓ Vitamin B12 and Bile Salts Absorption -Terminal ileum
- ✓ Absorption of **Short** chain FA -**Colon**
- ✓ Absorption of **Long** chain FA-**Jejunum**
- ✓ Absorption of folic acid - Juejuneum
- ✓ Active(Aldosteron Dependent) water and salt absorption –Colon Max Fluid loss -Colon
- ✓ For B12 Absorption Needed – Intrinsic Factor
- ✓ For B12 Transport Needed – Transcobalamin 2
- ✓ Part of Gut removed that cause Fluid loss-illium
- ✓ illium Resection—Increase water content of feces > Decrease Bile salt absorption
- ✓ Slow waves are oscillating membrane potential originate in intestinal cells of cajal
- ✓ Involve Ca channel (Depolirization) and K channel (Repolirization)
- ✓ It is lowest in the stomach (3 slow waves/min) and highest in the duodenum (12 slow waves/min)
- ✓ Level of lead in blood is estimated by – Absorption from GIT
- ✓ Most drugs are metabolized in – Liver
- ✓ Substance inhibited by low PH- Gastrin
- ✓ Subtance release from neuron in GIT tract and cause relaxation of smooth muscles – VIP
- ✓ Fat digestion done by – Emulsification
- ✓ Main function of hepatocytes is – Detoxification of Ammonia
- ✓ Slow waves of stomach begin from - Intestinal cells of Kajal
- ✓ **Myenteric plexus (Auerbach's plexus)** - Primarily controls the motility of the GI smooth muscle.
- ✓ **Submucosal plexus (Meissner's plexus)** - Primarily controls secretion and blood flow and Receives sensory information from chemoreceptor and mechanoreceptors in the GI tract.
- ✓ Increased gastric secretion in response to - Proteins
- ✓ **Mainly gluconeogenesis occurred at – Liver**
- ✓ Trypsinogen is activated to trypsin by - Enterokinase
- ✓ Gastic HCL from parietal cells is needed for – Conversion of Pepsinogen to pepsin
- ✓ Pancreatic enzyme deficiency would result in - Decrease absorption of triglycerides
- ✓ Time taken by food to reach large intestine from pylorus - 8 hours
- ✓ Thick saliva involved - Alpha 1 Beta 1 receptors
- ✓ Prostaglandins function in stomach - Decreased parietal cell acid secretion
- ✓ Substance induces the flow of saliva – Acetylcholine >VIP >Substance P
- ✓ Normal waves in basic electrical rhythms of stomach - 3 waves/day

GIT PHYSIOLOGY

1- During pharyngeal ph ase of swallowing what is true

A- Vocal cords adducted
B- Vocal cords abducted
C- Larynx moves upward and forward
D- Larynx moves downward
E- Closure of Epiglotis

Ans: A (Guyton)

Explanation:
During pharyngeal phase of swallowing vocal cord approximation (Adduction) and upward and anterior movement of larynx occur simultaneously. But A is more Imp (Guyton).

2- Increase pancreatic secretions and Calcium level is by which of?

A- Gastrin
B- Secretin
C- CCK
D- Somatostatin
E- Somatomedian

Ans: C

- Secretin increase pancreas secretion
- CCK increase pancreas secretion and calcium (Via IP3 mechanism)

3- Gastric fundus secretes which of?

A- HCL and pepsin
B- HCL and intrinsic factor
C- Mucous and HCL
D- Aspirin
E- Mucous cells only

Ans: B (BRS)

Explanation:

- **Parietal cell** (Fundus or Body) – HCL and Intrinsic factor
- **Chief cell** (Fundus or Body) – Pepsinogen
- **G cell** (Antrum) – Gastrin
- **Mucous cell** (Antrum) – Mucus and Pepsinogen

4- Which of the following neurotransmitter decreases contraction of stomach & gallbladder?

A- Substance P
B- VIP
C- CCK
D- Secretin
E- Motilin

Ans: B

5- Which hormone is responsible for delayed gastric emptying?

A- Glucagon
B- Gastrin
C- Secretin
D- Somatostatin
E- CCK

Ans: E (FA + BRS)

6- Na BILE ACID transporter is present in:

A- Ileum
B- Jejunum
C- Colon
D- Duodenum
E- Sigmoid Colon

Ans: A

7- Most important reflex for defecation

A- Rectoanal
B- Mass movement
C- Parasympathetic
D- Sympathetic
E- Anorectal

Ans: A

Explanation:

- Defecation is initiated by – Mass Movement
- Defecation is carried out by – Sacral Parasympathetic
- Defecation reflex – Recto anal
- Defecation reflex in baby – Gastrocolic

8- Secretion of HCl by gastric parietal cells is needed for:

A- Activation of pancreatic lipase
B- Activation of salivary lipase
C- Activation of intrinsic factor
D- Activation of pepsinogen to pepsin
E- The formation of micelle

Ans: D

9- Enzyme in saliva that prevents iron utilization by bacteria:

A- Lactoferrin
B- IgA protease
C- Lactoperoxidase
D- IgG protease
E- Oxidase

Ans: A

10- Oral glucose load will increase which hormone?

A- Secretin
B- Glucagon
C- Gastrin
D- GIP
E- Somatostatin

Ans: D

CamScanner

11- Which of the following is characteristic of saliva as compared to plasma?
A- Hypotonicity in relation to plasma
B- Lower bicarbonate
C- Duct Change composition by HCO_3 K reabsorption
D- Secretion rate increased by Vagotomy
E- Low Calcium
Ans: A

12- Patient is suspected of pancreatitis with pain in the epigastrium. Histological examination of pancreas shows the cells which are not normally present in the pancreas:
A- Alpha cells
B- Beta cells
C- D cells
D- Mucous cells
E- Serous cells
Ans: D

Explanation:
- Alpha cells secrete – Glucagon
- Beta cells secret – Insulin
- Delta cells secrete – Somatostatin
- Serous cell produce by Exocrine Gland of pancreas

13- While eating dry fruit saliva becomes?
A- Mucinous
B- Serous
C- More HCO_3
D- Less Cl
Ans: B

14- TPN is contraindicated in which of the following condition?
A- Liver Disease
B- Bone disease
C- DM
D- Renal Disease
Ans: A

Explanation:
Un control DM > Liver Disease > DM.

15- Decreased acid in stomach will result in:
A- Pernicious anemia
B- Inhibition of gastric acid secretions
C- Abnormal proteins digestion
D- Decreased stomach emptying
E- Diarrhea
Ans: C

16- The unconjugated bilirubin is transported in the blood in combination with:
A- Albumin
B- Alpha
C- Beta globulin
D- Fibrinogen
E- Pre-albumin
Ans: A

17- After hepatectomy liver regeneration how many days:
A- 10days
B- 16 to 25 days
C- 5 weeks
D- 25 Weeks
Ans: A (7-10days)

18- Intrinsic factor secreted by which of the following?
A- Pylorus
B- Fundus of stomach
C- Antrum
D- Gastric
E- Duodenum
Ans: B (BRS)

Explanation:
Fundus of the stomach by parietal cells

19- Which hormone is responsible for increased intestinal motility?
A- Glucagon
B- Gastrin
C- Secretin
D- Somatostatin
E- CCK
Ans: E (FA + BRS)

20- Surgical removal of the duodenum will enhance:
A- Secretin secretion
B- Gastric emptying
C- Absorption of lipid
D- Contraction of gall bladder
Ans: B

21- Sodium is actively absorbed in which part of GIT?
A- Stomach
B- Jejunum
C- Ileum
D- Colon
E- Duodenum
Ans: D

Explanation:
- Iron and calcium absorption – Duodenum
- Max water + electrolytes absorption – Jejunum
- Passive (Aldosterone independent) water absorption -Jejunum
- Absorption of long chain FA-Jejunum
- Absorption of short chain FA – Colon
- Active (aldosterone dependent) water and Na absorption – Colon

22- Regarding enterokinase true is:
A- Secreted in small intestine & converts trypsinogen to trypsin
B- Secreted in large intestine & converts trypsinogen to trypsin
C- Convert papsinogen to papsin
D- Convert pepsin to pepsinogen
Ans: A

Explanation:
Trypsinogen converted to trypsin by enterokinase / enteropeptidase which is brish border enzyme on duodenal and jeujenal mucosa.

23- Intrinsic factor is released by:
A- Chief cell of stomach
B- Parietal cell of stomach antrum
C- Parietal cell of stomach fundus
D- Mucous cells
E- G cells
Ans: C

Explanation:
- **Parietal cell (Fundus or Body)** – HCL and Intrinsic factor
- **Chief cell (Fundus or Body)** – Pepsinogen G cell (Antrum) – Gastrin
- **Mucous cell (Antrum)** – Mucus and Pepsinogen

24- Pancreatic secretion do not produce which enzyme?
A- Trypsin
B- Chymotrypsin
C- Elastase
D- Carboxypeptidase
E- Aminopeptidase
Ans: E

25- Which hormone is responsible for increased gastric emptying?
A- Glucagon
B- Gastrin
C- Secretin
D- Somatostatin
E- CCK
Ans: B (FA + BRS)

Explanation:
CCK:
- Secreted by I Cells
- Increase Intestinal Motility
- Decrease Gastric Emptying
- Increase Pancreatic Secretion
- Increase Gall Bladder Contraction
- Increase Sphincter of Oddi Contraction

Gastrin:
- Secreted by G Cells
- Increase Gastric Emptying
- Increase Growth of Gastric Mucosa
- Increase Gastric H Secretion

Secretin:
- Secreted by S Cells
- Increase pancreatic HCO_3 secretion
- Increase bile secretion

26- Most potent stimulator of gastric acid (HCl):
A- Protein
B- Ethanol
C- Fat
D- Histamine
Ans: A

Explanation:
- Increase by histamine, vagial stimulation (Ach), gastrin. Most potent – Protein
- Dec by somatostatin, GIP, Prostaglandins and Secretin

27- Liver is the only organ involved in synthesis of?
A- Urea formation
B- Nucleotide
C- Glycogenosis
D- Middle chain fatty acid catabolism
Ans: A

28- Highest alkaline PH is present in:
A- Saliva
B- Gastric secretions
C- Pancreatic secretions
D- Prostae
Ans: C

Explanation:
- Very high PH – Pancreatic juice
- Pancreatic secretion per day – 1500ml
- Pancreatic secretion trypsin, lipase, proteases and amylase
- Pancreatic secretion rich in water and secreted in response to secretin
- Enzyme rich secretion is under control of CCK

CamScanner

29- Gastrin is produced by:
A- Pyloric antrum
B- Fundus
C- Pancreas
D- Jeujenum
E- Illeum
Ans: A

Explanation:
Produced by G cells of antrum of stomach

30- Secretin produced by:
A- S cells
B- K cells
C- I cells
D- D cells
E- G cells
Ans: A

Explanation:
- Secretin – S cells (duodenum)
- GIP – K cells (duodenum, jejunum)
- Cholecystokinin – I cells (duodenum, jejunum)
- Somatostatin – D cells (pancreatic islets, GI mucosa)
- Gastrin – G cells (antrum of stomach, duodenum)

31- Substance which relaxes the muscles in lower esophagus, stomach, gallbladder, intestine?
A- VIP
B- Somatostatin
C- Motilin
D- Gastri
Ans: A

32- Salivary gland secretion increased by:
A- Substance P
B- VIP
C- Epinephrine
D- Serotonin
Ans: B

33- Decrease in gastric secretion by:
A- Somatostatin
B- Secretin
C- Histamine
D- HCL
Ans: A

34- Parasympathetic function is:
A- Increase HR
B- Increase GIT contraction
C- Relaxes GIT Sphincter
D- Inhibit Sweat Gland Secretion
Ans: C

35- Contraction in GIT smooth muscle is due to:
A- Spontaneous Na Channel
B- Spontaneous Ca Channel
C- Hormones and Slow Waves
D- Neuronal and Slow Waves
Ans: B (Guyton)

36- In GIT three layers of muscle on histology:
A- Fundus of stomach
B- Esophagus
C- Colon
D- Jejunum
Ans: A

37- Function of somatostatin:
A- Increase GH secretion
B- Decrease GH secretion
C- Increase secretion of various GI hormones
D- Is necessary for the function of GH
Ans: B

Explanation:
- Decrease in gastric acid and pepsinogen secretion
- Decrease in pancreatic and small intestine fluid secretion
- Decrease gallbladder contraction
- Decrease insulin and glucagon release

38- Gastric pylorus consists of:
A- Mucous cells
B- Zymogen cells
C- Parietal cells
D- Chromaffin cells
Ans: A

Explanation:
- Mucous cells – Gastric pylorus
- Chief cells – Fundus of stomach
- Zymogen cells – Fundus of stomach

39- Slow waves in small intestine smooth muscles are:
A- Action potential
B- Phasic contraction
C- Tonic contractions
D- Oscillating resting membrane potential
E- Oscillating CCK release
Ans: D (BRS)

40- Duodenum acidification will lead to:
A- Decrease gastric emptying
B- Increase gastric secretion
C- Increase HCO_3 secretion
D- Gall bladder contract
E- Sphincter of edi contraction increase
Ans: A

41- Which pancreatic enzyme causes fat digestion?
A- Amylase
B- Lipase
C- Protease
D- Trypsinogen
E- All of the above
Ans: B

Explanation:
- Amylase – Starch digestion
- Lipase – Fat digestion
- Proteases – Protein digestion

42- Activity which pushes the food forward in esophagus?
A- Esophagus myoelectric activity
B- Haustration
C- Primary peristalsis
D- None
Ans: C

43- Fat Digestion is done by:
A- Emulsification, Bile Salt, HCO_3 & Lipase
B- Emulsification & Bile Salt
C- Amylase & Lipase
D- Lipase
Ans: A

44- Atropine inhibits which of the following?
A- Constriction of GIT Sphincters
B- Bronchodilation
C- Pupillary Constriction
D- Sweat Gland Secretion
Ans: D

Explanation:
Sweat Gland secretion is mainly under the control of Post ganglionic cholinergic sympathetic system & Atropine will inhibit it by blocking the cholinergic response.

45- Parasympathetic Action:
A- Opens GIT Sphincters
B- Closes GIT Sphincters
C- Bronchodilation
D- Increase HR
Ans: A

46- Which GI Hormone stimulates HCO_3 and water secretion from liver & bile production?
A- CCK
B- Somatostatin
C- Secretin
D- Histamine
E- None
Ans: C

Explanation:
Functions of secretin:
- Increase pancreatic HCO_3 secretion
- Decrease gastric acid secretion
- Increase bile secretion

47- Which of the following antacid decreases gastric empyting?
A- Magnesium hydroxide
B- Aluminum hydroxide
C- Chloride hydroxide
D- Cadmium
Ans: B

Explanation:
- Aluminium hydroxide is used in upset stomach, indigestion & chronic diarrhea.
- Magnesium hydroxide is used in chronic constipation.

48- Loss of parietal cells due to damage to which of the following area?
A- Fundus
B- Antrum
C- Duodenum
D- Lesser curvature
Ans: A

49- Which of the following decreases Stomach motility and increases intestinal motility?
A- Gastrin
B- Secretin
C- CCK
D- Glucagon
Ans: C

Explanation:
- CCK decreases stomach motility & increases intestinal motility.
- Gastrin increases both gastric & intestinal motility.
- Secretin decreases both Gastric & intestinal motility.

50- Enterokinase acts for conversion of:
A- Trypsin
B- Trypsinogen
C- Amylase
D- Chymotrypsinogen
Ans: B

51- A patient present with anemia post-gastrectomy. Which cells of the stomach are liked involved?
A- G cells
B- S cells
C- Parietal cells
D- Mucous cells
Ans: C

CamScanner

52- Production of saliva mainly increased by:
A- Anti-cholinergic drug
B- Parasympathetic simulation
C- Sympathetic stimulation
D- Somatostatin
Ans: B

53- Which of the following increases absorption of iron in the gut?
A- Green vegetables
B- Citrus fruit
C- Chocolates
D- Apple
Ans: B

54- Cobalamin transported in blood by:
A- Albumin
B- Transcobalamin 1
C- Transcobalamin 2
D- Heptoglobin
E- Transferrin
Ans: C

55- Brunner glands are present in:
A- Cecum
B- Jejunum
C- Sigmoid colon
D- Pylorus
E- Duodenum
Ans: E

56- Most potent stimulus for Gallbladder contraction?
A- CCK
B- Fatty meal in duodenum
C- Gastrin
D- Secretin
Ans: A

57- Pancreatic secretion compromised. What will happen in relation to absorption and digestion?
A- Failure to digest triglycerides
B- Failure to form micelles in the intestine
C- Lactose intolerance
D- Secretory diarrhea
Ans: A

58- Deficiency of brush border enzyme that causes carbohydrates malabsorption?
A- Intestinal amylase
B- Intestinal Lactase
C- Enterokinase
D- Peptidase
Ans: B

59- Intestinal basic electric rhythm:
A- Alters in response to the hormones in circulation
B- Constant in duodenum and and alters in other segments
C- Diminshes during mechanical digestive movements
D- None
Ans: A

60- CCK when secreted by Duodenum causes:
A- Decreases gastric emptying in response to fatty meal
B- Secretes bile in response to fatty meal
C- Decrease sphincter of oddi relaxation
D- Decrease pancreatic secretion
Ans: A

Explanation:
Functions of CCK
- Inc. pancreatic secretion
- Inc. gallbladder contraction
- Dec. gastric emptying
- Inc. sphincter of Oddi relaxation

61- Resection of ileum more than 100cm will cause:
A- Dec. absorption of bile salts
B- Dec. absorption of water
C- Dec. absorption of monosaccharides
D- All of the above
Ans: A

62- Intestinal motility is due to:
A- Na+ influx due to impulses
B- Nervous stimulation of slow wave
C- Spontaneous stimulation of slow wave by Ca^{+}
D- Hormonal stimulation of slow wave
E- Simultaneous summation potential due to Na^{+}
Ans: C

63- Gastric HCL from parietal cells is needed for:
A- Conversion of pepsinogen to pepsin
B- Intrinsic factor activation
C- Conversion of trypsinogen to trypsin
D- Starch digestion
Ans: A

64- Highest potential difference in the wall of stomach is when?
A- Aspirin ingestion
B- HCL is not secreted and gastric mucosa is intact
C- HCL is secreted and gastric mucosa is damaged
D- None
Ans: B

65- Normal waves in basic electrical rhythm of stomach:
A- 12 waves/day
B- 3 waves/day
C- 15 waves / day
D- 1 wave / day
E- 8 wave/ day
Ans: B

66- Secondary peristalsis due to:
A- Esophagus dilatation
B- Only due to achalasia
C- Due to metaplasia
D- All of the above
Ans: A

67- CCK and gastrin are similar due to:
A- Same terminal C group
B- Same function on stomach
C- Both releases by G cells of stomach
D- Both cause decease contraction of gall bladder
Ans: A

68- During peristalsis, lower esophageal sphincter relaxes when:
A- Before bolus reach
B- After bolus reach
C- During meal
D- None of above
Ans: A

69- Secretin is secreted:
A- In response to fatty acids
B- High pH
C- Low pH
D- In response to fasting state
Ans: A

70- Vagal trunk cut what happens:
A- Incomplete gastric emptying
B- Augmented gastrin secretion
C- Augmented pepsin
D- Augmented enterogastric reflex
Ans: A

71- Which of the following does not cause acid secretion?
A- Stretching of antrum
B- Alcohol
C- Acidic antrum
D- Peptides
Ans: C

72- Stomach circular muscle becomes thicker:
A- Fundus
B- Antrum
C- Cardiac
D- Pylorus
Ans: D

73- In pancreatic fistula somatostatin helps by:
A- Decreasing output of secretions
B- Increasing pH of secretions
C- Increasing blood flow of gland
D- Inhibiting enzymes
Ans: A

74- Secretion of gastrin is inhibited by:
A- Acetylcholine
B- Somatostatin
C- Increase PH
D- Stomach distention
E- GRP
Ans: B

75- Substance which induces the flow of saliva?
A- Motilin
B- VIP
C- Substance P
D- Acetylcholine
Ans: D

76- Regarding GIT motility true is:
A- Same as of stomach
B- Is not dependent on hormones only
C- Does not occurs in absence of food
D- Forget about this options are mixed
Ans: B

77- Salivation is formed by:
A- Food in mouth creates unconditioned reflex
B- Smell of food
C- Dec. by bilateral damage to 9th nerve
D- Salivary center located in medulla
Ans: D

78- Regarding exocrine pancreatic secretions:
A- It contains more Cl than plasma
B- Secretion increased by CCK
C- Secretion increased by gastrin
D- Secretion increases by somatostatin
Ans: B

79- Prostaglandins function in stomach:
A- Decreased parietal cell acid secretion
B- Decreased acetylcholine working on parietal cell
C- When aspirin comes, it causes increased permeability
D- Promote ulcer
Ans: A

80- Gastric acid secretion is mediated by:
A- H1
B- H2
C- Pepsin
D- Presence of food in stomach
Ans: B

CamScanner

81- Thick saliva involves which receptors?
A- Alpha 1
B- Alpha 1 Beta 1
C- Beta 1
D- Alpha 2
Ans: B

82- Time taken by food to reach large intestine from pylorus:
A- 4 hours
B- 8 hours
C- 12 hours
D- 10 hours
E- 15 hours
Ans: B

83- Enzyme not present in pancreatic secretion?
A- Trypsin
B- Enterokinase
C- Lipase
D- Elastase
Ans: B

84- Which of them is needed to be broken down before digestion?
A- Tripeptides
B- Dipeptides
C- Monopeptides
D- Sucrose
E- Fructose
Ans: D

85- Oligosaccharide in saliva to which microbes adhere to attach to mucosa?
A- Lactoferrin
B- Mucin
C- Secretory IgA
D- Lactase
Ans: B

86- Saliva is rich in which of the following for digesting carbohydrates?
A- Aminopeptidase
B- Oxylase
C- Lipase
D- Amylase
E- Carboxypeptidase
Ans: D

87- A female presented with Dysphagia to liquid for last 6 months. Laryngoscopy shows normal histology of tract the most likely cause?
A- Glossopharyngeal nerve palsy
B- Loss of Neuromuscular coordination
C- Vagus nerve lesions
D- Plummer Vinson syndrome
Ans: B

88- Meissner plexus function is
A- Volume maintenance
B- Motility
C- Secretory activity
D- Regulate reflexes
Ans: C(BRS)

Explanation:
Myenteric plexus (Auerbach's plexus)
- Primarily controls the motility of the GI smooth muscle.

Submucosal plexus (Meissner's plexus)
- Primarily controls secretion and blood flow.
- Receives sensory information from chemoreceptor and mechanoreceptors in the GI tract.

89- Slow waves of stomach begin from:
A- Intestinal cells of Kajal
B- Myenteric plexus
C- Smooth muscle in Longitudinal layer
D- Smooth muscle in circular layer
Ans: A

90- Main function of hepatocytes is:
A- Detoxification of urea
B- Detoxification of ammonia
C- Accliminazation of drugs
D- Decrease Hb formation
Ans: B

91- Child not allowed on Trip to take street food, He took food Few hrs later he developed abdominal crumps, by Activation of:
A- Splanchnic parasympathetic activation
B- Pudenal activation
C- Decrease parasympathetic
D- Increase Splanchnic sympathetic
Ans: D

92- Fat digestion done by
A- Emulsification
B- Bile salt
C- Lipase
D- HCO_3
E- Phospholipids
Ans: A

93- Which one is Present in saliva that breaks Glycosidic Bond?
A- Lactoperoxidase
B- Lactoferin
C- Mucin
D- Lysozyme
E- IgA
Ans: A

94- Area in Liver containing heptic artery bile duct portal vein with Central Venules at Different angles is
A- Hepatic acinus
B- Complex acinus
C- Hepatic Vein
D- Portal acinus
E- Classical Hepatic lobule
Ans: E

95- Gastric emptying enhances by increase in:
A- Intragastric volume
B- Duodenal osmolarity
C- Ileal osmolarity
D- Secretin
Ans: A

96- Strongest stimulus for gastrin release?
A- Carbohydrates
B- Vitamins
C- Proteins and amino acids
D- Acid
Ans: C

97- Intestinal motility is affected by:–
A- Gastrin
B- Serotonin
C- Histamine
D- Vasoactive intestinal peptide
Ans: D

98- Migratory motor complex is triggered - by
A- Motilin
B- NO
C- CCK
D- Secretin
Ans: A

99- Decreased gastric secretions by:
A- Secretin
B- Protein
C- Gastrin
D- Food
Ans: A(BRS Physio)

100- About iron absorption from gut what – is correct
A- Dietary iron is more readily absorbed
B- Ferric form more readily reabsorbed then ferous form
C- Free iron is more absorbed then bound form
D- Absorbed from distal ileum
Ans: A

101- Fatty diet increases which of these
A- Glucagon
B- Secretin
C- CCK
D- Insulin
E- Somatostatin
Ans: C

102- Hypokalemia due to gastroentritis IV potassium given how will it absorb
A- H/K pump
B- Na/K pump
C- Leaky channel
D- Na channel
Ans: B

103- Which hormone responsible for increase gastric acid secretion
A- Glucagon
B- Gastrin
C- Secretin
D- Somatostatin
E- CCK
Ans: B (FA+BRS)

104- Fastest Regeneration occur in
A- Kidney
B- Spleen
C- Liver
D- Intestine
E- Lungs
Ans: C

105- Saliva helps in digestion and it is secreted by?
A- NO
B- Vagus nerve
C- VIP
D- Abdudent nerve
E- Trigeminal nerve
Ans: C

106- Gastrin secreted by which of following?
A- Pylorus
B- Fundus of stomach
C- Gastric Antrum
D- Gastric
E- Duodenum
Ans: C (BRS)

Explanation:
Parietal cell (Fundus or Body) – HCL and Intrinsic factor
Chief cell (Fundus or Body) – Pepsinogen
G cell (Antrum) – Gastrin
Mucous cell (Antrum) – Mucus and Pepsinogen

CamScanner

107- The H+/K+ pump in parietal cells controlled by
A- Carbonic anhydrase
B- Na +Atpase
C- Renin
D- K+Atpase
E- Cycloxygenase
Ans: D

108- After 100cm illeal resection following will occur:
A- Decrease Bile salt
B- Bile salt Not absorbed properly
C- Decrease Vitamin B12 absorption
D- Decrease Folate absorption
E- Decrease B6 absorption
Ans: B

109- CCK inhibited by:
A- Glucose
B- Gastrin
C- Secretin
D- Somatostatin
Ans: D

110- In vomiting which of following occur?
A- Constriction of LES
B- Relaxation of LES
C- Increase GIT motility
D- Relaxation of Diaphragm
E- Relaxation of abdominal muscles
Ans: B

111- Male has eaten fast food at night and has abdominal problem whole night due to:
A- Increase gastric emptying by CCK
B- Delayed gastric emptying by CCK
C- Delayed gastric emptying by Gastrin
D- Increase Gastric emptying by Pepsin
Ans: B

112- Regarding prostaglandins in stomach:
A- Damage mucosa
B- Protect mucosa by inhibiting HCL
C- Secrete HCL
D- Secrete Bicarbonate
Ans: B

113- Basal electrical rhythm of gut by:
A- Influx of Na+ by slow Ca+/Na+ ATPase
B- Influx of Na+ by slow Ca+/K+ ATPase
C- Influx of K+ by slow Ca+/K+ ATPase
D- Influx of Cl- by slow Ca+/K+ ATPase
Ans: B

114- Pancreatic insufficiency causes steatorrhea due to:
A- Increase lipase
B- Increase amylase
C- Decrease lipase
D- Decrease carbohydrates digestion
Ans: C

115- 2 month old baby cause loose motion after every feed immediately due to
A- Lactose intolerance
B- Gastrocolic reflex
C- IBD
D- Psychogenic
Ans: B

Explanation:
- Lactose intolerance develop usually after 6-8 h of feed
- Gastrocolic reflex cause immediate loose motion after feed

116- Lowest pH in which part of GIT
A- Pancreatic juice
B- Gastric juice
C- Saliva
D- Chyme
Ans: B

Explanation:
Highest – Pancreatic
Lowest – Gastric

117- What happen in oesophageal sphincter when peristaltic wave comes?
A- Doesn't relax
B- Relax ahead of wave
C- Relax after coming of wave
D- Contract ahead of wave
E- Contract always
Ans: B

118- Strongest layer of bowel is:
A- Mucosa
B- Submucosa
C- Lamina propria
D- Serosa or adventitia
Ans: B

119- Rhythm and motility of GIT is maintained by:
A- Na+ /Ca
B- Ca++/K+
C- Na+/K
D- Cl-/Na+
Ans: B

120- Achalasia due to defect in:
A- Sympathetic nervous system
B- Parasympathetic nervous system
C- Myenteric plexuses
D- Mesisser plexuses
E- Mucosa
Ans: C

121- After Fatty food intake digestion required which of the following hormone:
A- GH
B- Catecholamines
C- Somatostatin
D- Glucose
E- CCK
Ans: E

122- During pharyngeal swallowing phase:
A- Vocal cord abduction
B- Transient holding of breath
C- Complete breath stopage
D- Vocal cord contracts
Ans: B

123- Urea forms in:
A- Kidney
B- Lung
C- Liver
D- Spleen
Ans: C

124- Vitamin B12 absorption needs which one of the following:
A- TC-I
B- TC-II
C- TC-III
D- Intrinsic factor
Ans: D

125- Plasma glucose level is determined by
A- Glucostatic activity of liver
B- Rate of gluconeogenesis
C- Serum GH level
D- Serum Cortisol level
Ans: A

126- Histamine causes increase in gastric acid secretion by:
A- Stimulating Vagus nerve
B- Through IP3 Mechanism
C- Through Na+/K+ ATPase
D- Through Camp mechanism
Ans: D

127- A patient presented with complains of burning epigastric pain on & off that improves after meals. This condition is due to persistent release of gastric acid by presence of which of the following in plasma?
A- Gastrin
B- Histamine
C- Pepsinogen
D- Secretin
Ans: A

128- Initiation of interdigestive myoelectric complexes is done by which hormone?
A- Gastrin
B- NO
C- CCK
D- Secretin
E- Motilin
Ans: E

129- Which of following decrease stomach acids
A- Secretin
B- Cholycystokinin
C- Stomach distension
D- Polypepride chain
Ans: A

130- If pyloric sphincter is cut what will happen
A- Increased Gastrin release
B- Increased acid flow
C- Decrease gastric compliance
D- Increased basal acid flow
E- Increased gastric emptying
Ans: E

Explanation:
- Fundus removed=↓Gastric compliance>>↓Receptive relaxation
- Antrum removed=↓ Gastric acid production
- Pylorus removed→Solids pass easily

131- Which of the following secretions are hypotonic , having more bicarb, and decrease after Vagotomy
A- Gastric juice
B- Saliva
C- Pancreatic secretions
D- Gastric secretion
Ans: C

CamScanner

132- Which of the following is responsible for smooth muscles contraction of intestine
A- Neuronal signal
B- Slow spontaneous contraction wave via Ca influx
C- Slow waves via Na influx
D- Hormonal signals
E- Neuronal and slow waves
Ans: B

133- Which intestinal movement help to mix chyme with food
A- Myomyteric reflex
B- Colonic reflex
C- Gastric reflex
D- Fast wave
Ans: A

134- Complete denervation of the small intestine would be expected to:
A- Cause intestinal obstruction
B- Cause peristalsis to become irregular
C- Decrease the resting rate of intestinal peristalsis
D- Have little effect on the resting rate of intestinal peristalsis
E- Increase the resting rate of intestinal peristalsis
Ans: D

135- In GIT, Action potential in Interstitial cells of cajal by:
A- Inc sodium by Na/Ca Pump
B- Inc sodium by Na/K Pump
C- Inc sodium by Ca/Na Pump
D- Inc sodium by K/Ca Pump
E- Inc sodium by Na/K/Ca Pump
Ans: A

136- There is a Distinct role of adrenergic receptors on digestive system they act Through?
A- Gut Musculature
B- Pyloric Sphincter
C- Gastric Fundus
D- Gastro-Oesophageal Junction
Ans: B

137- GIT is thickest at:
A- Gastroesophageal junction
B- Pylorus
C- Antrum
D- Fundus
Ans: A

138- Mixing of chyme with food in small intestine through?
A- Peristaltic waves
B- Haustrations
C- Segmentation contractions
D- Migratory motor complexes
E- Appendices epiploicae
Ans: C

139- A hormone that increase HCO_3 secretion from pancreas
A- CCK
B- Secretin
C- Gastrin
D- Somatostatin
E- Glucagon
Ans: B

140- Main function of hepatocytes is:
A- Detoxification of urea
B- Metabolism of drugs
C- Accliminazation of drugs
D- Decrease Hb formation
Ans: B

141- What is potent stimulus for gastric secretion
A- Fats
B- Proteins
C- Saline
D- Ethanol
E- Carbohydrates
Ans: B

142- Which intestinal movement help to mix chyme with food
A- Myomyteric reflex
B- Colonic reflex
C- Gastric reflex
D- Fast wave
Ans: A

143- How much time a bolus take to reach till colon
A- 4 h
B- 6 h
C- 8 h
D- 10 h
Ans: C

144- After half of liver transplant. Remaining half of liver regeneration occurs in?
A- 2 weeks
B- 6 weeks
C- 5 to 15 days
D- 16 to 25 days
E- 100 to 150 days
Ans: C

145- Which among the following will cause increased gastric emptying?
A- Increased acidity of duodenum
B- Increased Intragastric Volume
C- Cholecytokinin
D- Secretin
Ans: B

146- At 6 months, Baby presented with continuous diarrhea for 10 days. His mother is worried- This may be due to:
A- Ractanal reflex
B- Ano rectal reflex
C- Gastro colic reflex
D- Lactose intolerance
Ans: C

147- Which of the following causes secretory diarrhea when reaches colon in large quantities?
A- Sucrose
B- Lactose
C- Chenodeoxycholic
D- Dipeptides
Ans: B

148- LES tone increased by..
A- Anti muscarinic drugs
B- Gastrin
C- CCK
D- Smoking
E- Secretin
Ans: B

149- Secondary peristalsis induced by:
A- Myentric plexus
B- Aurbach plexus
C- Mass movement
D- Anal reflex
Ans: A

150- H2 blockers are given before surgery primarily to decrease which of the following?(Medicine Feb 2025)
A- Acid in the stomach
B- Volume in the stomach
C- Mucous in the stomach
D- Gastric motility
Ans: B

151- Resection of Upper part of small intestine will will lead to decrease in(Medicine Feb 2025):
A- Basal acid secretion
B- Gastric Emptying of solid food
C- Gastric Emptying of liquid food
D- Pancreatic secretions
Ans: D

152- Increase in gastric emptying is by? (Medicine Feb 2025)
A- Vagotomy
B- Gastric distention
C- Protein in duodenum
D- Fatty Acids
Ans: B

153- Which hormone will increase secretion of biliary duct epithelium? (Medicine Feb 2025)
A- Vagal stimulation
B- CCK
C- Secretin
D- Gastrin
Ans: C

153- Which of the following hypotonic secretions has a high bicarbonate (HCO_3^-) concentration and is affected by vagotomy? (Medicine Feb 2025)
A- Pancreatic secretion
B- Duodenal secretion
C- Gastric secretion
D- Salivary Secretions
Ans: A
Explanation:
- Pancreatic secretions are rich in bicarbonate (HCO_3^-), which neutralizes gastric acid in the duodenum. The secretion is regulated by vagal stimulation via the parasympathetic nervous system. A vagotomy interrupts vagal input, reducing bicarbonate secretion. Other options like duodenal and gastric secretions do not exhibit such high HCO_3^- concentrations, and salivary secretions are not directly regulated by vagal stimulation in this context.

154- Patient underwent Gastrectomy & has now developed pernicious anemia due to deficiency of Vitamin B12. The cells required for the absorption of Vitamin B12 are: (Medicine Feb 2025)
A- Parietal Cells
B- Mucous Cells
C- Serous Cells
D- Brunner Cells
Ans: A

155- Child has decreased enterokinase. What deficiency comes along with it: (Medicine Feb 2025)
A- Trypsin
B- Lactase
C- Pepsin
D- Lipase
E- Amylase
Ans: A

CamScanner

156- Iron absorption occurs in(Medicine Feb 2025)
A- Proximal Jejunam
B- Terminal Ilium
C- Transverse Colon
D- Proximal Duodenum
E- Jejunum
Ans: D

157- Enzyme most important for protein degradation: (Medicine Feb 2025)
A- Trypsin
B- Pepsin
C- Aminopeptidase
D- Amylase
E- Chymotrypsin
Ans: B

158- Which of the following is the function of CCK on stomach(Surgery Feb 2025)
A- Relaxation of sphincter of Oddi
B- Decrease pyloric pump activity
C- Decrease Intestinal motility
D- Relaxation of fundus
E- Hypotonic effect
Ans: B

159- 20 year old male patient presents in emergency department with persistent vomiting which of the following contribute in vomiting process(Surgery Feb 2025)
A- Relaxation of Pyloric sphincter
B- Relaxation of GE junction
C- Contraction of abdominal muscles
D- Concentration of diaphragm
Ans: B

160- Blood vessels dilation in gut is mediated by(Surgery Feb 2025)
A- VIP
B- Secretin
C- Gastrin
D- GIP
Ans: A

161- Gut-brain stimulation of the myenteric plexus primarily occurs through which neurotransmitter? (Surgery Feb 2025)
A- Acetylcholine (Ach)
B- Gamma-Aminobutyric Acid (GABA)
C- Epinephrine
D- NorEpinephrine
E- Epinephrine
Ans: A

162- Which of the following pathways carries sensory afferent fibers from the GIT(Surgery Feb 2025)
A- White rami communicantes
B- Gray rami communicantes
C- Vagus nerve
D- Pelvic splanchnic nerve
Ans: A

163- Esophageal Secondary peristalsis induced by: (Surgery Feb 2025)
A- Myenteric plexus
B- Auerbach plexus
C- Mass movement
D- Anal reflex
Ans: A

165- Parasympathetic effect on GIT is(Surgery Feb 2025)
A- Dilute secretion of git
B- Decrease secretion of git
C- Increase the sphincter tone of git
D- Increase the blood flow
E- Relax GIT sphincter
Ans: E

165- Which of the following is potent stimulus for gastric secretion(Surgery Feb 2025)
A- Fats
B- Protein
C- Saline
D- Ethanol
E- Carbohydrates
Ans: B

166- Which of the following is minimum length of intestine required for effective absorption(Gynae & Obs Feb 2025?
A- 50cm
B- 100cm
C- 150cm
D- 200cm
E- 250cm
Ans: B

167- Carbohydrate metabolism in intestine is done by: (Gynae & Obs Feb 2025)
A- Sucrase
B- Amylase
C- Maltase
D- Lactase
Ans: B

168- A 2-year-old child presents with diarrhea and flattening of the brush border. Deficiency of which enzyme is most likely responsible?(Radiology Feb 2025)
A- Lipase
B- Amylase
C- Enterokinase
D- Peptidase
Ans: C

169- The presence of acidic chyme in the duodenum stimulates the release of which hormone?(Anesthesia Feb 2025)
A- Cholecystokinin (CCK)
B- Secretin
C- Gastrin
D- Vasoactive intestinal peptide (VIP)
Ans: B

170- How do antigens move through the intestinal wall? (Anesthesia Feb 2025)
A- M cells
B- Antigen-presenting dendritic cells
C- Enterocytes
D- Goblet cells
E- Peyer's patches
Ans: A

171- CCK produced by: (Anesthesia Feb 2025)
A- S cells
B- K cells
C- I cells
D- D cells
E- G cells
Ans: C

Explanation:
- Secretin – S cells (duodenum)
- GIP – K cells (duodenum, jejunum)
- Cholecystokinin – I cells (duodenum,jejunum)
- Somatostatin – D cells (pancreatic islets, GI mucosa)
- Gastrin – G cells (antrum of stomach,duodenum)

CamScanner

RENAL PHYSIOLOGY QUICK HINTS

Body Fluids

- ✓ Total body water (TBW) is approximately 60% of body weight.
- ✓ The percentage of TBW is highest in newborns and adult males and lowest in adult females and in adults with a large amount of adipose tissue.
- ✓ TBW is 60% of body weight.
- ✓ ICF is 40% of body weight.
- ✓ ECF is 20% of body weight.
- ✓ Total body fluid – 42L
- ✓ ICF – 28L
- ✓ ECF – 14L (Interstitial 10.5L and Plasma 3.5L)

Body Fluid Compartment Measurements

- ✓ **TBW**-Radioactive water (Tritiated water in pure form called Tritium, 3H2O) Heavy water (Deutrium 2D2O) and Antipyrene.
- ✓ **ECF** – Mannitol, Inulin and sulfate
- ✓ **Plasma** – Evan Blue and RISA
- ✓ **Interstitial fluid** – ECF – Plasma
- ✓ **ICF** – TBW – ECF

GFR and RPF

- ✓ GFR Measured by – Inuline
- ✓ GFR Estimated/Clinically by – Creatinine
- ✓ Endogenous subtance to measure GFR by – Creatinine.
- ✓ Best test for renal failure -- **Creatinine clearance**
- ✓ Renal plasma flow by – PAH

Increase GFR due to:

- ✓ Afferent arteriol dilation
- ✓ Efferent arteriol constriction
- ✓ Decrease plasma proteins

Decrease GFR due to:

- ✓ Afferent arteriole constriction
- ✓ Efferent arteriole dilation
- ✓ Increase plasma proteins
- ✓ Ureter constriction

Dilute vs concentrated Urine

- ✓ Dilute Urine(Decrease Osmolarity) -- **Early DCT(Macula Densa) > Thick Limb**
- ✓ Dilute Urine(Decrease Osmolarity) -- **Thick Limb >> DCT**

Note: Difference between **Early DCT** and **Only DCT**

- ✓ In Dehydraion (ADH) Concentrated Urine(Increase Osmolarity) –**CD (Vasa Racta)**

Buffer

- ✓ Major blood/Extracellular/Interstitium/Plasma Buffer - **Bicarbonate**
- ✓ Major RBCs buffer - **Hemoglobin**
- ✓ Major Intracellular Buffer - **Proteins**
- ✓ Major Renal Buffer – **Phosphate**
- ✓ Exclusive Renal tubular buffer -**Ammonia**
- ✓ Major Urinary Buffer(Quantitatively) - **Ammonium**
- ✓ Major Bone Buffer - **Calcium Carbonate**
- ✓ Ammonia is urinary buffer because renal tubular cells produce Ammonia that interact with Urinary H ions to form NH4 this NH4 cannot reabsorb back so it act as urinary buffer

Na Absorptions

- ✓ **Proximal tubule** reabsorbs **two-thirds, or 67%,** of the filtered Na+ and H2O, more than any other part of the nephron.
- ✓ **In Early proximal tubule** Na+ is reabsorbed by cotransport with glucose, amino acids, phosphate, and lactate. Na+ is also reabsorbed by countertransport via Na+ H+ exchange, which is linked directly to the reabsorption of filtered HCO3
- ✓ **In the late proximal tubule**, Na+ is reabsorbed with Cl–
- ✓ **Thick ascending limb** reabsorbs **25%** of the filtered Na+ It Contains a Na+–K+–2Cl– cotransporter in the luminal membrane.
- ✓ **Early distal tubule** reabsorbs NaCl by a Na+-Cl- cotransporter.
- ✓ **Principal cells of Late distal tubule** reabsorb Na+ and H2O secrete K+ by aldosterone .ADH increase water permeability
- ✓ ***α*-Intercalated cells of Late distal tubule** secrete H+ by an H+(ATPase), which is stimulated by aldosterone. And Reabsorb K+ by an H+,K+-ATPase.

K absorptions

- ✓ **Proximal tubule** reabsorbs **67%** of the filtered K+ along with Na+ and H2O.
- ✓ **Thick ascending limb** reabsorbs **20%** of the filtered K+Reabsorption involves the Na+–K+–2Cl– cotransporter in the luminal membrane of cells in the thick ascending limb.
- ✓ **Distal tubule and CD** either reabsorb or secrete K+, depending on dietary K+ intake.
- ✓ K Reabsoption involves an H+,K+-ATPase in the luminal membrane of the α-intercalated cells.
- ✓ K secretion occurs in the principal cells.

Abnormalities of body volume Regulation

Hypoosmotic dehydration

- ✓ **Cause – Adrenal insufficiency , Overuse of diuretics**
- ✓ plasma sodium concentration - decrease
- ✓ Extracellular fluid volume - decrease
- ✓ Intracellular fluid volume - increase

Hypoosmotic overhydration

- ✓ **Cause – Excess ADH , Bronchogenic tumor**
- ✓ plasma sodium concentration - decrease
- ✓ Extracellular fluid volume - Increase
- ✓ Intracellular fluid volume - Increase

Hyper osmotic dehydration

- ✓ **Cause – Diabetes insipidus , Excessive sweating**
- ✓ plasma sodium concentration - increase
- ✓ Extracellular fluid volume - decrease
- ✓ Intracellular fluid volume - decrease

Hyper osmotic overhydration

- ✓ **Cause – Cushng disease , primary aldosteronism**
- ✓ Plasma sodium concentration - increase
- ✓ Extracellular fluid volume - increase
- ✓ Intracellular fluid volume – decrease

Acid base physiology

Acidosis

- ✓ PH < 7.35
- ✓ PCO2 > 44 mm Hg
- ✓ HCO3 – < 20 mEq/L

Alkalosis

- ✓ PH > 7.45
- ✓ PCO2 < 36 mm Hg
- ✓ HCO3 – > 28 mEq/L

CamScanner

Metabolic acidosis - PH decrease , PCO2 decrease , HCO3 decrease.

Causes

Cause of normal anion gap (HARDASS)

- ✓ Hyperchloremia / Hyperalimentation
- ✓ Addison's disease
- ✓ RTA
- ✓ Diarrhea
- ✓ Acetazolamide
- ✓ Spironolactone
- ✓ Saline infusion

Cause of increase anion gap (MUDPILES)

- ✓ Methanol
- ✓ Uremia
- ✓ Dka
- ✓ Propylene glycol
- ✓ Iron tablets or INH
- ✓ Lactic acidosis
- ✓ Ethylene glycol
- ✓ Salicylates (late)

Cause of decreased anion gap

- ✓ Multiple myeloma
- ✓ Hypoalbuminemia

Metabolic alkalosis - PH increase , PCO2 increase , HCO3 increase.

Causes

- ✓ Loop diuretics
- ✓ Vomiting
- ✓ Antacid use
- ✓ Hyperaldosteronism

Respiratory acidosis - PH decrease , PCO2 increase , HCO3 increase.

Causes

- ✓ Airway obstruction
- ✓ Acute lung disease
- ✓ Chronic lung disease
- ✓ Opioids
- ✓ Sedatives
- ✓ Weakening of respiratory muscles

Respiratory alkalosis - PH increase , PCO2 increase , HCO3 decrease.

Causes

- ✓ Anxiety
- ✓ Hypoxemia (eg, high altitude)
- ✓ Salicylates (early)
- ✓ Tumor
- ✓ Pulmonary embolism
- ✓ Pregnancy

Electrolytes disturbances

Calcium (4.5 – 5 mEq/L)

Hypocalcemia

- ✓ Tetany
- ✓ Seizures
- ✓ QT prolongation
- ✓ Constipation
- ✓ Twitching (eg, Chvostek sign)
- ✓ Spasm (eg, Trousseau sign)

Hypercalcemia

- ✓ Stones (renal)
- ✓ Bones (pain)
- ✓ Groans (abdominal pain)
- ✓ Thrones (inc urinary frequency)
- ✓ Psychiatric overtones (anxiety, altered mental status)

Pottassium (3.5 – 5 mEq/L)

Hypokalemia

- ✓ U waves and flattened T waves on ECG
- ✓ Arrhythmias
- ✓ Muscle cramps
- ✓ Weakness

Hyperkalemia

- ✓ Wide QRS and peaked T waves on ECG
- ✓ Arrhythmias
- ✓ muscle weakness

Magnesium (1.5 – 2.5 mEq/L)

Hypomagnesemia

- ✓ Tetany
- ✓ Torsades de pointes
- ✓ Hypokalemia
- ✓ Hypocalcemia

Hypermagnesemia

- ✓ Dec DTRs
- ✓ Lethargy
- ✓ Bradycardia
- ✓ Hypotension
- ✓ Cardiac arrest
- ✓ Hypocalcemia

Sodium (135 – 145 mEq/L)

Hyponatremia

- ✓ Nausea
- ✓ Malaise
- ✓ Stupor
- ✓ Coma
- ✓ Seizures

Hypernatremia

- ✓ Irritability
- ✓ Stupor
- ✓ coma

Phosphate (2.5 – 4.5 mEq/L)

Hypophosphatemia

- ✓ Bone loss
- ✓ osteomalacia in adults
- ✓ rickets in children

Hyperphosphatemia

- ✓ renal stones
- ✓ metastatic calcifications
- ✓ hypocalcemia

CamScanner

Regarding Thirst

Thirst is increased by

- ✓ Increase in osmolarity
- ✓ Increase in Angiotensin II
- ✓ Decrease in volume
- ✓ Increase in ADH
- ✓ Dryness of mouth

Thirst is decreased by

- ✓ Gastric distention
- ✓ Increase in volume
- ✓ Increase in BP
- ✓ Decrease in ADH

Random

- ✓ Erythropoeitin secreted by – **Peritibular capillaries > Mesangial Cells**
- ✓ **Kidney Podocytes** – At visceral layer of bowman capsule
- ✓ **Cresents** – formed by parietal cells lining bowman capsule
- ✓ **Clearance – PAH >K >Inulin >Urea > Sodium> Amino acid and Glucose**
- ✓ Bicarbonate absorption – **PCT +CD**
- ✓ Concentrating urine in summer or during fasting -- **ADH**
- ✓ Prone to Ischemia -- **PCT**
- ✓ Maximum water & sodium absorption -- **PCT**
- ✓ Maximum water & sodium absorption with any hormone -- **PCT**
- ✓ Maximum potassium absorption -- **PCT**
- ✓ Potassium loss due to dietary irregularities -- **Distal tubules**
- ✓ ADH – **Increase Urea transport to DCT**
- ✓ ADH – **Inhibited by alcohol**
- ✓ ADH – **Regulates plasma volume / urine osmolarity**
- ✓ ADH –**V1 receptors cause vasoconstriction**
- ✓ ADH – **V2 receptors act on kidney**
- ✓ Most potent stimulus hypovolemia – Renin angiotensin
- ✓ Most potent stimulus Osmolarity – ADH
- ✓ Most potent stimulus for aldosterone – K> renin
- ✓ Highest Tubular transport maximum – **Glucose >PAH > Lactate**
- ✓ Threshold for Glucose – **200 (Guyton)**
- ✓ Sodium Absorption -- **Aldosterone**
- ✓ Sodium excretion -- **ANP**
- ✓ Net Sodium Absorption -- **Aldosterone & ANP**
- ✓ Mole to mole which has greatest effect on sodium excretion - **Aldosterone**
- ✓ Renin -- **Produced by JG cells**
- ✓ Renin -- **Long term B.P regulation**
- ✓ Mild Hypomagnesemia Stimulate Parathyroid -- **Hypercalcemia**
- ✓ Severe Hypomagnesemia suppress Parathyroid – **Hypocalcaemia**
- ✓ Hypermagnesemia Cause -- **Hypocalcaemia**
- ✓ Hypokalemia is associated with –**Alkalosis**
- ✓ Hyperkalemia associated with – **Acidosis**
- ✓ Hypokalemia – **Decrease Nerve Excitability In RMP**
- ✓ Hyperkalemia – **Increase Nerve Excitability In RMP**
- ✓ Hyponatremia – **Decrease Hight of Action Potential**
- ✓ Hypernatremia – **Increase Hight of Action Potential**

- ✓ Hypocalcaemia – **Increase Excitability**
- ✓ Hypercalcemia – **Decrease Excitability**
- ✓ Effect of Acidosis on body - **CNS Depression**
- ✓ Response of body to Acidosis – **Increase Respiration**
- ✓ **Fanconi syndrome** - generalized reabsorption **defect in PCT**
- ✓ **Barter syndrome** - reabsorption **defect in thick ascending loop of Henle(Same as loop diuretic)**
- ✓ **Gitelman syndrome** - Reabsorption **defect of NaCl in DCT(Same as Thiazide diuretic)**

CamScanner

RENAL PHYSIOLOGY

1- ECF is measured by which of the following?
A- Evan Blue
B- Inulin
C- Antipyrene
D- Albumin
Ans: B

Explanation:
- TBW-Radioactive water (Tritiated water in pure form called Tritium, $3H_2O$) Heavy water (Deuterium $2D_2O$) and Antipyrene.
- ECF – Mannitol, Inulin and sulfate
- Plasma – Evan Blue and RISA
- Interstitial fluid – ECF – Plasma
- ICF – TBW – ECF

2. Interstitial fluid is about:
A- 42L
B- 28L
C- 14L
D- 11L
E- 3L
Ans: D

Explanation:
- Total body fluid – 42L
- ICF – 28L
- ECF – 14L (Interstitial 10.5L and Plasma 3.5L)

3. Auto regulation of kidney by:
A- Tubular glomerular feedback mechanism.
B- CO_2
C- Local Metabolites
D- Increase blood flow
Ans: A

3. Short transient action of angiotensin 2 is which of these?
A- Thirst
B- Vasoconstriction
C- Salt retention
D- Aldosterone release
E- Vasodilation
Ans: B

4. Which hormone maintains water and electrolytes?
A- Ag2
B- Aldosterone
C- TSH
D- ADH
E- Cortisol
Ans: B

5. Erythropoietin is secreted from which cell?
A- Peritubular capillary cell
B- Interstitial cell of kidney
C- Mesangial cell
D- JG cell
E- Para mesangial
Ans: A (FA)

Explanation:
- Peritubular capillary cell secretes – Erythropoietin
- JG cell secrete – Renin

6. Substance having more properties then inulin is thought to have:
A- Increase filtration rate and absorption
B- Increase filtration rate and net secretion
C- Net absorption
D- Not Filtered
Ans: B

7. Renin is secreted by:
A- Peritubular capillaries
B- PCT
C- Bowman capsule
D- JG Cell
E- Para Capillaries
Ans: D

Explanation:
- Peritubular Capillaries secrete – Erythropoietin
- JG cell Secrete –Renin

8. Which of the following causes increase in renin level?
A- Increase plasma osmolarity
B- Increase sodium delivery to macula densa
C- Decrease stretch on cardiac receptor
D- Exercise
Ans: C

9. Renin is persistently increased in:
A- Malignant phase of Essential HTN
B- Hypotension
C- APKD
D- Benign Essential HTN
E- CCF
Ans: A

Explanation:
Secondary essential hypertension > malignant essential hypertension.

10. In summer, fasting man, has concentrated urine due to:
A- Aldosterone
B- Increase ADH
C- Decrease water intake
D- Increase sweating
E- Cortisol
Ans: B

11. An 8-year-old patient presents to the clinic with periorbital edema. His labs showed protein greater than 3.5g/dl. What is the probable cause?
A- Potassium retention
B- Sodium retention
C- Naturesis
D- Albuminuria and sodium retention
E- Calcium retention
Ans: D

12. After sweating which of the following electrolyte maintain homeostasis?
A- Potassium
B- Calcium
C- Sodium
D- Cadmium
E- Iron
Ans: C

13. Which of the following is found more in ICF as compared to ECF?
A- Potassium
B- Sodium
C- Magnesium
D- Carbon
E- Chloride
Ans: A

Explanation:
- ICF mainly composed of potassium, magnesium, organic phosphates (e.g, ATP)
- ECF mainly composed if sodium, chloride, bicarbonates and albumin

14. After RTA due to haemorrhage a person with 2 liter blood loss, the blood volume restored back by:
A- PCT
B- DCT
C- CD
D- Loop
E- CCD
Ans: B

Explanation:
- In haemorrhage most commonly affected – PCT
- Blood volume bring back by – DCT (Via RAAS)

15. Water travels from plasma to interstitium through?
A- Filtration
B- Diffusion
C- Osmosis
D- Active transport
E- Passive Diffusion
Ans: A

Explanation:
- Water enters into cell or water absorption across cell membrane by - Pores
- Water goes from plasma to interstitial fluid by – Filtration

16. After marathron race a person lost 2 liters of sweating he drinks 2 liters of water what will happen?
A- Decrease ECF Volume
B- Decrease ICF volume
C- Increase Osmolarity of ICF
D- Decrease Osmolarity of ECF
E- No change
Ans: D

17. In dialysis patient accurate Clinical way of monitoring of GFR is:
A- K clearance
B- Creatinine Clearance
C- Inulin Clearance
D- Urea
E- BUN
Ans: B

Explanation:
- GFR Measured – Inulin
- GFR Estimated/Clinically – Creatinine
- Endogenous substance to measure GFR – Creatinine.
- Renal plasma flow – PAH

18. RBC is kept in hypertonic solution containing Urea what will be the result?
A- Swell & lyse
B- Shrink, Swell & lyse
C- Shrink
D- Lyse & Swell
Ans: B

19. Patient presented with decrease BP. Which one of the following will secrete enzyme to normalize the bp of patient?
A- Peritubular Capillaries
B- JG Cells
C- Para Capillaries
D- PCT
E- Glomeeuli
Ans: B

CamScanner

Explanation:
- JG Cells Secrete Renin which will bring Back BP to normal
- Peritubular Capillaries Secrete Erythropoietin

20. ECF is different from ICF in:
A- Large volume
B- Low pH
C- Low Na/k ratio
D- Inorganic ions
E- High K
Ans: D

21. After RTA GFR decrease in patient came with excessive bleeding, Cause of decrease GFR is:
A- Decrease Arterial volume
B- Decrease Arterial blood flow
C- Decrease Arterial pressure
D- Decrease Oxygen in arterial blood
E- Decrease CO2 in Venous blood
Ans: B (Guyton)

22. Buffer found in kidney but not in plasma:
A- Ammonia
B- Phosphate
C- HCO_3
D- Protein
E- Hb
Ans: A

23. Max absorption of glucose occurs from:
A- PCT
B- DCT
C- Collecting tubules
D- TAL
E- Loop
Ans: A

Explanation:
- Potassium is maximally absorbed in PCT
- Bicarbonate is maximally absorbed in PCT
- Maximum absorption of water in PCT
- Principal site if absorption of sodium is PCT

24. Decrease in nerve action potential excitability of RMP is due to:
A- Hypercalcemia
B- Hypokalemia
C- Hypocalcemia
D- Hypernatremia
E- Hypokalemia
Ans: E

Explanation:
- Hypokalemia – Decrease nerve excitability in RMP
- Hyperkalemia – Increase nerve excitability in RMP
- Hyponatremia – Decrease height of action potential
- Hypernatremia – Increase height of action potential
- Hypocalcemia – Increase excitability
- Hypercalcemia – Decrease excitability

25. Most abundant blood buffer is which of following?
A- Ammonia
B- HCO_3
C- Hb
D- Proteins
E- Calcium carbonate
Ans: B

Explanation:
- Major blood / Extracellular / Interstitium / Plasma Buffer – Bicarbonate
- Major RBCs buffer – Hemoglobin
- Major Intracellular Buffer – Proteins
- Major Renal Buffer – Phosphate
- Exclusive Renal tubular buffer –Ammonia
- Major urinary buffer (quantitatively) - Ammonium
- Major bone buffer - Calcium carbonate.

26. GFR increase by which of following?
A- Decrease plasma colloid osmotic pressure
B- Increase plasma colloid osmotic pressure
C- Ureteric constriction
D- Afferent arteriole constriction
E- Efferent arteriole dilation
Ans: A (BRS)

Explanation:
Increase GFR due to:
- Afferent arteriole dilation
- Efferent arteriole constriction
- Decrease plasma proteins

Decrease GFR due to:
- Afferent arteriole constriction
- Efferent arteriole dilation
- Increase plasma proteins
- Ureter constriction

27. Blood flow of renal system is regulated by which of following?
A- Glomerulo feedback
B- Tubulo glomerular Feedback
C- Afferent arteriole constriction
D- CCT
E- Peritubular dilation
Ans: B

28. Renal plasma flow decrease by:
A- Renal artery constriction
B- Increase amount of catecholamine
C- Decrease ICF osmolarity
D- Decrease ECF osmolarity
E- Sympathetic by Renal nerves
Ans: A

29. Which hormone works on kidney?
A- ACTH
B- Aldosterone
C- Cortisol
D- GH
Ans: B

30. Na = 135, HCO_3 = 100, Cl 5 calculate the anion gap:
A- 40
B- 30
C- 50
D- 60
Ans: B

Explanation:
Anion gap = Na – (Cl +HCO3) =135 - (5+100) =135 – 105=30

31. Hyperkalemia leads to which of following?
A- Decrease action potential
B- Tachycardia
C- Flaccidity
D- Spasticity
Ans: C

32. Kidney activates which of the following?
A- Erythropoeitin
B- Cholecalciferol
C- Renin
D- Angiotensin
Ans: B

33- Aldosterone action is:
A- Displace Na from cytoplasm to cell membrane
B- Acts on nucleus
C- Acts on cell membrane
D- Bind glycoprotein
Ans: A

34. A patient with severe diarrhoea what infusion will be given to increase ECF and decrease ICF causing plasma expansion after osmotic equilibrium?
A- 1 liter of 3 percent Nacl
B- 1 liter of 5 percent dextrose water
C- 1 liter Ringer lactate
D- 1 liter of 0.45 Nacl
Ans: A

35. Vasopressin secretion is increased by:
A- Increased pressure in the right ventricle
B- Decreased pressure in the right ventricle
C- Increased pressure in the right atrium
D- Decreased pressure in the right atrium
E- Increased pressure in the aorta
Ans: D

36. A patient ABGs reveals PH 7.54, PCO2 40 and HCO_3 29 what is acid base disorder?
A- Respiratory acidosis
B- Respiratory alkalosis
C- Compensatory Respiratory Acidosis
D- Metabolic acidosis
E- Uncompensated Metabolic alkalosis
Ans: E

37- Ammonia is urinary buffer because:
A- Impermeable to absorb NH4
B- Impermeable to absorb NH3
C- It binds with phosphate
D- It competes with phosphate
Ans: A

38. Diagnostic findings of metabolic alkalosis are:
A- HCO_3>24
B- PCO_2>60
C- PCO_2<40
D- PH>7.4
E- PH<7.4
Ans: A

39. Plasma clearance of PAH is used to measure the renal plasma flow because it?
A- Can be measured in plasma easily
B- Is excreted in urine
C- Is filtered and secreted but not reabsorbed
D- Is only filtered
E- Is only secreted
Ans: C

40. Which of the following hormone regulates osmolarity?
A- Aldosterone
B- ADH
C- ANP
D- Renin
E- Cortisol
Ans: B

41. Which Part of nephron is impermeable to water?
A- PCT
B- Thick Ascending loop of Henley
C- Descending loop of Henley
D- Cortical collecting duct
E- Collecting duct
Ans: B

Explanation:
Early DCT >Thick Limb of loop of Henle

CamScanner

42. The basic function of kidney is:
A- Hydrogen ion homeostasis
B- Metabolic waste removal
C- PH maintenance
D- Blood pressure regulation
E- Sodium Regulation
Ans: B

43. Surgeon more curious about which electrolyte before surgery on serum electrolytes report:
A- Hyperkalemia
B- Hypocalcemia
C- Hyponatremia
D- Hypokalemia
E- Hypomagnesemia
Ans: A

44. Prolong diarrhea will results in:
A- Metabolic alkalosis
B- Metabolic acidosis
C- Hypochloremic metabolic alkalosis
D- Mixed acid base disturbance
E- Respiratory alkalosis
Ans: A
Explanation:
- Acute – Metabolic Acidosis
- Prolong/Chronic – Metabolic Alkalosis

45. Systolic pressure in highest in which of the following vessel?
A- Aorta
B- Pulmonary artery
C- Femoral artery
D- Renal artery
E- Common carotid arteries
Ans: D
Explanation:
- Max pulse pressure – Dorsalis pedis > Femoral > Popliteal > Aorta
- Highest systolic pressure – Renal artery

46. A person loses 2L of sweat while working and drinks 2L pure water, what changes will occur?
A- Decrease ICF osmolarity
B- Increase ECF Volume
C- Decrease ECF osmolarity
D- Increase ICF volume
E- Decrease plasma volume
Ans: D
Explanation:
Increase ICF Volume > Decrease ICF Osmolarity > Increase ECF volume > Decrease ECF osmolarity.

47. Increase sodium uptake in body is due to:
A- Decrease K in body
B- Increase K in body
C- Increase Plasma volume
D- Increase Blood pressure
E- Increase Plasma osmolarity
Ans: B
Explanation:
Increase K in body will stimulate Aldosterone release which will increase absorption of Sodium and excrete potassium.

48. Hypotonic fluid is present in which part?
A- Early DCT
B- Early PCT
C- Early LOH
D- CD
Ans: A
Explanation:
- Dilute Urine (Hypotonic) – Early DCT (Macula Densa) > Thick Limb
- In Dehydration (ADH) Concentrated Urine (Hypertonic) – CD (Vasa Racta)

49- A man was taken to the high altitude where after 10 days patient ABG's sample taken which of the condition ABG's show:
A- Normal acid base status
B- Metabolic alkalosis
C- Metabolic acidosis
D- Respiratory Alkalosis
E- Respiratory acidosis
Ans: C
Explanation:
Acutely respiratory alkalosis which is compensated by metabolic acidosis after 10 days.

50. Thirst is increased by:
A- Renin
B- Increase Angiotensin 2
C- Angiotensin 1
D- ADH
E- Aldosterone
Ans: B (Guyton)

Increase Thirst	Decrease Thirst
Increased plasma osmolarity	Decreased plasma osmolarity
Decreased blood volume	Increase blood volume
Decrease BP	Increase BP
Increase Ag 2	Decrease Ag 2
Dryness of mouth	Gastric distension

51. To calculate plasma osmolality, sodium concentration is multiplied with 2 because of:
A- Cautions
B- Anions
C- Small sized proteins
D- Calcium
Ans: B

52- Which condition leads to hypokalaemia?
A- Increase PH
B- Decrease PH
C- Increase Bicarb
D- Decrease CO_2
E- Negative base excess
Ans: A (BRS)
Explanation:
High PH mean low H ions in blood to compensate these H ions from cell will move to Blood and in exchange K will move from blood to cell result in low K in blood called hypokalaemia.

53. Fluid of choice for third space fluid loss?
A- 5% D/W
B- N/S
C- 10% D/W
D- Ringer lactate
Ans: D

54. Patient with CO_2 44, PH 7.3, HCO_3 16 what is the acid-base abnormality?
A- Metabolic acidosis
B- Metabolic alkalosis
C- Respiratory acidosis
D- Respiratory alkalosis
Ans: A

55- Which of the following decrease the arterial oxygen saturation without decreasing arterial O2 tension?
A- CO poisoning
B- Copd
C- Cyanide poisoning
D- Heart failure
Ans: A

56. Which one decreases plamsa osmolarity?
A- Aldosterone
B- ADH
C- ANP
D- Cortisol
Ans: B

57. Erythropoiesis is mainly stimulated by:
A- Hypoxia
B- Erythropoietin
C- Cobalt
D- Theophylline
Ans: B
Explanation:
- Erythropoiesis stimulated by – Erythropoietin
- Erythropoietin stimulated by – Hypoxia
- Erythropoietin inhibited by – Theophyllin

58. Plasma colloid oncotic Pressure majorly due to:
A- Albumin
B- Globulin
C- Potassium
D- Hydrogen
Ans: A

59. Primary dehydration will have:
A- Increase ECF osmolarity
B- Decrease ECF osmolarity
C- Increase ICF osmolarity
D- Increase urine volume
Ans: A

60. Difference between ICF and ECF?
A- Inorganic ions
B- Less PH of ICF
C- More PH of ICF
D- Less PH of ECF
Ans: B

61. Free water clearance regulated by:
A- ADH
B- Aldosterone
C- ANP
D- Angiotensin 2
Ans: A

62. A patient with urine osmolarity 1200 Serum osmolarity 220 what is the cause?
A- SIADH
B- DI
C- Nephrogenic DI
D- Water deprivation
Ans: A
Explanation:
- Urine osmolarity 1200 mEq/L and plasma osmolarity 300mEq/L – diagnosis = dehydration
- Normal serum osmol = 280v – 290, for SIADH plasma osmolarity less than 280

63. A patient having CO_2 58, PH 7.3 and HCO_3 24 which type of acid base balance?
A- Metabolic Acidosis
B- Metabolic Alkalosis
C- Respiratory Acidosis
D- Respiratory Alkalosis
Ans: C.

64- Renal correction of hyperkalaemia lead to:
A- Alkalosis
B- Acidosis
C- Hypovolemia
D- Low PCO_2
Ans: B

CamScanner

Explanation:
- Hyperkalaemia – Acidosis
- Hypokalaemia – Alkalosis

65- What is the most appropriate test for urine culture?
A- CLED agar with 1ml urine
B- Bacterial dipstick
C- Night urine
D- Urine culture
Ans: A

66- Which of the following factors increases GFR?
A- Efferent arteriolar dilation
B- Afferent arteriolar dilation
C- Ureter blockage
D- Afferent arteriolar constriction
Ans: B

67- Glomerulus is formed by:
A- Vasa recta
B- Capillary tuft
C- Efferent arteriole
D- Afferent arteriole
Ans: D

Explanation:
- Glomerulus is formed by - Afferent arterioles
- Glomerulus gives - Efferent arterioles

68- Patient with 15-20% blood loss, what should be given via infusion:
A- 3% N/S
B- Ringer lactate
C- Colloid
D- Blood
Ans: A

69- Increased GFR due to increase:
A- Oncotic pressure
B- Hydrostatic pressure
C- Venous pressure
D- Haemorrhage
Ans: B

70. Volume of plasma Filtered per unit time:
A- GFR
B- Filtration rate
C- Filter Load
D- Clearance
Ans: A

Explanation:
- Volume of plasma Filtered per unit time – GFR
- Volume of plasma cleared of a substance Per unit Time – Clearance
- Volume of substance filtered per unit time – Filter load
- If Clearance of substance greater than GFR – Tubular secretion

71. Normal value of GFR:
A- 110ml/min
B- 125ml/min
C- 150ml/min
D- 200ml/min
Ans: B

72. Angiotensin 2 shortest function:
A- Arteriolar vasoconstriction
B- Increase thirst
C- Increase aldosterone
D- Decrease Renin
Ans: A

73. Regarding distal convoluted tubule:
A- Confers final composition of urine
B- Generate NH_2 ions
C- Absorbs 60% filtered water
D- Can counter transport k with Cl
Ans: A

74. By increasing specific gravity of urine which functions is tested?
A- Concentration
B- GFR
C- Dilution
D- Filtration
Ans: A

75. A young patient presented with High glucose kusmaul breathing and unconsciousness and urinary ketones positive and Diagnose of DKA made which one act as buffer in this condition?
A- HCO_3
B- Ammonia
C- Phosphate
D- Chlorine
Ans: A

76. What changes are seen in a patient who is given 1L of N/saline?
A- Increased serum osmolarity
B- Decreased urine osmolarity
C- Increased urine osmolarity
D- Increased ICF volume
Ans: B

Explanation:
N/S is isotonic to plasma so no effect on plasma osmolarity however Volume will increase which will be filtered to urine so more volume in urine cause decrease urinary salt so decrease urine osmolarity.

77. Hyperkalemia is associated with:
A- Acidosis
B- Alkalosis
C- Respiratory depression
D- Loss of deep tendon reflexes
Ans: A

Explanation:
- Hypokalemia – Alkalosis
- Hyperkaemia – Acidosis

78. In severe dehydration, the following changes occur:
A- ECF becomes hypotonic
B- ECF becomes hypertonic
C- ICF becomes hypotonic
D- ICF becomes hypertonic
Ans: B

79. Sodium levels in body are regulated by:
A- ADH
B- ACTH
C- Aldosterone
D- Paratharmnone
Ans: C

80. PAH is used to measure:
A- Renal blood flow
B- GFR
C- Renal plasma flow
D- Urine osmolarity
Ans: C

Explanation:
- GFR Measured – Inuline
- GFR Estimated/Clinically – Creatinine
- Endogenous substance to measure GFR – Creatinine.
- Renal plasma flow – PAH

81. Minimum amount of urine should be excreted per day to pass metabolic waste:
A- 100ml
B- 250ml
C- 500ml
D- 50ml
Ans: C

82. Lymph flow decreased by increase of:
A- Increased oncotic pressure
B- Increased arterial pressure
C- Increased venous pressure.
D- Increased capillary permeability.
E- Increased protein leakage
Ans A

83. In chronic respiratory acidosis what is in normal?
A- HCO_3 in plasma
B- CO_2 in plasma
C- PH of plasma
D- PH of venous blood
Ans: C

Explanation:
In chronic respiratory acidosis, renal compensation (increased HCO_3 reabsorption) has occurred So, arterial PH is increased toward normal that is compensation.

84- Ureteric obstruction causes:
A- Increased GFR
B- Decreased GFR
C- Increase hydrostatic pressure
D- Decrease capillary pressure
Ans: B

85. Angiotensin one conversion occurs in:
A- Kidney
B- Liver
C- Lung
D- Stomach
Ans: C

Explanation:
- Conversion of Ag 1 to Ag 2 – Lung
- Activated in Lung – Ag2

86. Counter current exchange mechanism in kidney occurs in:
A- Presence of vasa recta
B- Increase delivery of Na+ to macula densa
C- Decrease delivery of Na+ to macula densa
D- Constriction of afferent arteriole
Ans: A

Explanation:
- Counter current multiplier – Loop of Henle and Juxtaglomerular cells
- Counter current exchanger – Vasa Recta

87. Main action of aldosterone:
A- Maintenance of Na & K in body fluid
B- Vasoconstriction
C- Excretion of Na+
D- Vasodilation of afferent arteriole
Ans: A

CamScanner

88. Amount of substances filtered per minute minus the amount of substance that appears in urine:
A- Tubular secretion
B- Tubular reabsorption
C- Clearance
D- Filtered load
E- GFR
Ans: B

89. Difference between tubular fluid of PCT and DCT is:
A- DCT have brush border as compared to DCT
B- There is increase in H+ secretion in PCT as compared to DCT
C- Increased in H^+ secretion in DCT as compared to PCT
D- Decrease bicarbonate absorption in PCT
Ans: C

90. In syndrome of apparent mineralocorticoid excess (AME) what will be present?
A- Hypertension
B- Hyperkalaemia
C- Acidosis
D- Aciduria
Ans: A

91. Dehydrated patient, which ion immediately help in compensation?
A- Na
B- K^+
C- Cl^-
D- HCO_3
Ans: A

92. Primary adrenal insufficiency will cause:
A- Hyperkalemia
B- Hypokalemia
C- Hypocalcemia
D- Hypernatremia
Ans: A

93. Dehydration doesnot affect?
A- CT
B- DCT
C- CD
D- PCT
Ans: D

94. RBC swell when placed in?
A- 150mmol nacl
B- 100mmol cacl
C- Urea 250mmol
D- Urea 359mmol
Ans: C

Explanation:
Urea 250 is hypotonic solution so water will enter and RBC will swell.

95-. Action potential reduced in:
A- Hypokelmia
B- Hyponatremia
C- Hyperkalemia
D- Hypernatremia
Ans: B

96- Sodium absorption functions of:
A- ANP
B- Aldosterone
C- Cortisol
D- ADH
Ans: B

97. A man smoker, having hyponatremia and hyperosmotic urine most likely have:
A- Addison disease
B- Inappropriate ADH syndrome
C- Decreased ADH
D- Increase aldosterone
Ans: B

98. Kidney best mechanism to preserve volume:
A- Renin secretion
B- Decrease filtration
C- Decrease ADH
D- Decrease aldosterone
Ans: A

99- PH is defined as:
A- Positive log of H
B- Negative log of H
C- Positive log HCO_3
D- Positive log of CO_2
Ans: B

100. In metabolic acidosis how is renal compensation done:
A- Increase urine PH
B- Decrease NH4+ secretion
C- Increase glutamine absorption
D- Increase glutamine secretion
Ans: D

101. What is the role of ECF?
A- Exchange of substances
B- Excrete Gases
C- Maintain Volume
D- Water absorption
Ans: A

102. Erythropoietin is released by which Organ?
A- Lung
B- Liver
C- Bone
D- Kidney
E- Skin
Ans: D

103. The most important mechanism for glomerulo-feedback system is:
A- Increase Peritubular Colloid Pressure
B- Decrease Peritubular Sodium Concentration
C- Decrease Peritubular Colloid Pressure
D- Increase Oncotic pressure
Ans: B

104. Decrease Lymphatic flow due to:
A- Decrease Oncotic Pressure
B- Increase Permeability
C- Haemorrhage
D- Increase Hydrostatic Pressure
Ans: C

105. Decrease Lymphatic flow due to:
A- Increase Plasma Oncotic Pressure
B- Decrease Plasma Oncotic Pressure
C- Increase Hydrostatic Pressure
D- Increase Permeability
Ans: A

106. Nephropathy is diagnosed by:
A- Increase urinary albumin
B- Increase serum albumin
C- Microalbuminuria
D- Increase urinary nitrogen
Ans: C

Explanation:
Microalbuminuria is only in case of DM, but if increase urinary albumin this could be either nephritic or Nephrotic syndrome.

107. Loss of thirst due to:
A- Low Plasma osmolarity
B- High Plasma osmoalrity
C- Vasopressin
D- Angiotensin
Ans: A

108. Juxtaglomerular nephrons most important function is:
A- Counter current multiplier
B- Counter current exchanger
C- Increase renin secretion
D- Decrease renin secretion
Ans: A

109. Estimation of GFR is done via:
A- Inulin clearance
B- Creatinine clearance
C- PAH
D- Glucose
Ans: B

Explanation:
- Best Measure of RPF = PAH
- Best Measure of GFR = Inulin Clearance
- Best Estimate of GFR = Creatinine Clearance

110. Negative free water clearance:
A- Nephrogenic DI
B- Central DI
C- SIADH
D- Carcinoma
Ans: C

111. Regarding DCT which of the following is correct?
A- Glucose absorption occurs here
B- ADH act on DCT
C- Maximum water reabsorption
D- Site of action of Thiazide Diuretics
Ans: D>B

112- BP 160/110 mmHg & increase renin is due to:
A- Sympathetic Renal nerve
B- Parasympathetic Renal Nerve
C- Hypokalemia
D- Hypocalcaemia
Ans: A

113. In haemorrhage patient aldosterone level increased by:
A- ADH
B- Oxytocin
C- AG2
D- Vasopressin
Ans: C

114. Malignant hyperthermia occurs due to change in which of the following?
A- Sodium
B- Potassium
C- Calcium
D- Magnesium
Ans: C

115. Hyperkalemia is caused by:
A- Exercise
B- Beta Agonist
C- Aldosterone
D- Renin
Ans: A

Explanation:
- During exercise more potassium comes out from intracellular to extracellular fluid.

CamScanner

Hyperkalemia factors

- Insulin deficiency (DM)
- Aldosterone deficiency (addison's disease)
- B – adrenergic blockage
- Acidosis cell lysis
- Strenous exercise
- Increase extracefluid osmolarity
- Hypokalemia factors
- Insulin
- Aldosterone
- Beta adrenergic stimulation
- Alkalosis

116- Aldosterone exerts its maximum effect on which of the following site?

A- PCT
B- LOH
C- DCT
D- CCT
Ans: D

Explanation:

- Aldosterone acts on: CCT > DCT > CT
- ADH acts on: CT > DCT > CCT

117. PH = 7.49, PCO = 60, HCO3 =30 which of the following Acid Base abnormality does it indicates?

A- Respiratory acidosis
B- Partially compensated respiratory Acidosis
C- Partially compensated metabolic Alkalosis
D- Mixed acidosis
Ans: C

118-. Which of the following ions is main determinant of plasma osmolarity?

A- Potassium
B- Sodium
C- Magnesium
D- Chloride
E- Calcium
Ans: B

119. Effect of hypernatremia on the body is:

A- Cell swelling
B- Cell shrinkage
C- Apoptosis
D- Difficulty in the generation of action potential
Ans: B

Explanation:

- Hypernatremia means ECF has most sodium that will lead to extravasation of fluid from cells into ECF.
- Action potential will easily generate with hypernatremia.

120. Which of the following is used to calculate total body water:

A- Evans blue dye
B- Antipyreine
C- Inulin
D- Mannitol
Ans: B

Explanation:

- Measurements of body fluid volume
- Total body water - 3H2O, 2H2O, antipyrene
- ECF – 22Na, 125I-iothalamte, thiosulphate, inulin
- ICF – Calculated as total body water - (extracellular fluid volume)
- Plasma volume – 125I – albumin, evans blue eye
- Plasma volume – 51Ce – labelled red blood cells, or calculated as blood volume
- Interstitial fluid – calculated as extracellular fluid volume – plasma volume.

121. Which of the following decreases osmolarity?

A- Vasopressin (ADH)
B- Epinephrine
C- Aldosterone
D- Renin
Ans: A

Explanation:

Vasopressin (ADH) absorbs water & decreases plasma osmolarity.

122. Zona Glomerulosa is linked with:

A- Sodium reabsorption
B- Potassium reabsorption
C- Sex hormone maintenance
D- None of the above
Ans: A

Explanation:

Zona glomerulosa secretes aldosterone that's linked with sodium absorption and Potassium secretion.

123. Albumin & RBCs in urine due to damage of:

A- PCT
B- DCT
C- Glomerulus
D- Tubules
Ans: C

124. Which of the following is prominent feature of RTA?

A- Hyperkalemia
B- Hyponatremia
C- Nitrogen Imbalance
D- Urea Imbalance
Ans: A

125. Which of the following drug is actively secreted by kidneys?

A- Penicillin
B- Streptomycin
C- Rifampin
D- Metronidazole
Ans: A

126. If ICF is increased what will decrease?

A- Heart rate
B- Fluid
C- Blood pressure
D- Tissue Oxygenation
Ans: A

127. Lady after haemorrhage goes into Acute Kidney injury which of the following part of nephron will be most likely affected:

A- PCT
B- DCT
C- LOH
D- CT
Ans: A

128. Protein can't cross the glomerular basement membrane due to:

A- Positive charge
B- Negative charge
C- Neutral
D- None
Ans: B

129. Which of the following is urine output in a 70kg person in 24 hours?

A- 550 ml
B- 1000 ml
C- 1500 ml
D- 3000 ml
Ans: C

Explanation:

Normal Urine output in a 70 kg person is 1500 – 2200 ml.

130. Afferent Renal arterioles form:

A- Glomerulus
B- Efferent arteriole
C- Peritubular capillaries
D- None of the above
Ans: A

Explanation:

Afferent Renal Arterioles leads to Glomerulus that in turn leads to efferent arterioles followed by peritubular capillaries.

131. Which of the following ion has profound effect in ECF?

A- Calcium
B- Sodium
C- Chloride
D- Phosphorous
Ans: B

132. The ability of the kidney to excrete concentrated urine will increase if:

A- The permeability of the proximal tubules to water decreases
B- The rate of blood flow through the medulla decreases
C- The rate of flow through the LOH increases
D- The activity of Na-K pump in the LOH decreases
E- The permeability of the collecting duct to water decreases
Ans: B

Explanation:

The rate of blood flow decreases in hypovolemia through medulla & hence concentrated urine is produced.

133. Which of the following is the function of Erythropoietin?

A- Increase Haemoglobin
B- Decrease Haemoglobin
C- Increase Platelet count
D- Decrease Platelet count
Ans: A

134. Renin is inhibited by:

A- Angiotensin
B- Increase sodium
C- Increase Aldosterone
D- Bradykinin
Ans: A

135. Hemoglobin Saturation increases in which of the following condition?

A- Increase PO2
B- Decrease PO2
C- Increase PCO2
D- Decrease PCO2
Ans: A

136. A person drinks 600 ml of water, how much water of it will be present in plasma:

A- 200 ml
B- 300 ml
C- 50 ml
D- 100 ml
Ans: C

Explanation:

- 600 ml of water, 1/3rd that's 200 ml will be found in ECF.
- Among 200 ml of ECF 1/4th will be found in plasma that's 50ml.

CamScanner

137. Patient having signs of hypoxia with normal breathing, PO_2 95, PCO_2 24 and HCO_3 18 with normal PH:
A- Partially Compensated Metabolic Acidosis
B- Fully Compensated Metabolic Acidosis
C- Respiratory Acidosis
D- Mixed Acidosis
Ans: B

138. Which of the following has same osmolarity to plasma?
A- 25% DW
B- 0.9% N/S
C- 3% NS
D- 10% DW
Ans: B

139. A 60-year-old businessman is evaluated by physician for his high BP which was 185/130mm Hg. Lab revealed increased plasma renin activity. His plasma aldosterone level is high. Left renal Vein Renin level is high and right Renal Vein Renin Level is decreased. Most Likely diagnosis is:
A- Left renal Artery Stenosis
B- Right renal Artery Stenosis
C- Bilateral Renal Artery Stenosis
D- Adrenal Mass
Ans: A
Explanation:
As the patient has hypertension with increased aldosterone & renin level, and after investigation it was found that renin was increased in left renal vein so this is most probably case of Left renal artery stenosis.

140. Mesangial cells have contractile property which helps them to maintain?
A- Renal blood flow
B- Blood pressure
C- Erythropoiesis
D- Aldosterone secretion
Ans: A

141-. Fanconi syndrome, decrease ATP at the PCT linked with:
A- Hyperphosphatemia
B- Glycosuria
C- Metabolic alkalosis
D- Hypermagnesemia
Ans: B

142. Most potent stimulus for release of aldosterone is:
a- Renin
b- Hyperkalaemia
c- Inc. serum glucose level
d- Increase serum sodium level
Ans: B

143. Which of the following causes vasoconstriction?
A- Adrenaline
B- ADH
C- AG2
D- AG1
Ans: B
Explanation:
ADH (Vasopressin) is the most potent vasoconstrictor among the mentioned options.

144-. What is more in dialysis fluid?
A- Potassium
B- Magnesium
C- Sodium
D- Bicarbonate
Ans: D

145. Which of the following substances can be used to measure the volume of plasma?
A- Inulin
B- Para-aminohippurate (PAH)
C- Antipyrene
D- Radiolabelled iodinated globin
E- Evans blue dye
Ans: E

146. Hyponatremia is due to:
A- Increased level of water
B- Increased level of sodium
C- Increase hydrostatic pressure
D- Decreased hydrostatic pressure
E- Increased oncotic pressure
Ans: A

147. The part of nephron that amounts for 60-80% water absorption:
A- DCT
B- PCT
C- Ascending loop of Henle
D- Collecting tubules
E- Descending loop of Henle
Ans: B

148. Concentration of a substance in urine is 2 moles/L. Urine flow rate is 100 m/s and plasma flow rate is 10 m/s. How much substance will be cleared?
A- 10
B- 20
C- 25
D- 30
E- 40
Ans: B
Explanation:
Remember: Clearance = UV/P

149. The PH of urine can't be lowered below 5.4 even after giving Bicarbonates (HCO_3). What is the condition termed as?
A- RTA1
B- RTA2
C- RTA4
D- Both RTA1 & RTA4
Ans: A

150. Renin secretion is increased by:
A- Increased potassium concentration
B- Decrease potassium concentration
C- Increase calcium
D- Hypoxia
Ans: B

151. The elevation of renin level is due to:
A- High parasympathetic activity
B- Hypoxia
C- Decrease stretch over atrial baroreceptor
D- High brain bridge reflex
Ans: C

152. Micturition is controlled by:
A- Mechanoreceptors in bladder wall
B- Inhibited by a centre in pons
C- Stretch of urethral sphincter
D- Condition reflex
E- Processed in cerebral cortex
Ans: A
Explanation:
- Micturition controlled by – Mechanoreceptors in bladder wall
- Micturition centre (stimulatory) – Pons
- Micturition centre (Inhibitory) – Midbrain
- Processing of micturition – Cerebral cortex
- Micturition reflex / integration – Sacral segments of spinal cord
- Voluntarily Inhibition – Activation of Pudendal nerve
- Pain and filling sensations of bladder are carried by – Sympathetic (Guyton).

153. Low depolarization occurs in:
A- Hyponatremia
B- Hypokalaemia
C- Hyperkalaemia
D- Hypercalcemia
Ans: A

154. ECF Volume increases maximum on giving:
A- Hypotonic saline
B- Hypertonic saline
C- Hypertonic dextrose
D- Ringer lactate
Ans: B

155. The slope pertaining to the action potential changes with:
A- Hyponatremia
B- Hypocalcaemia
C- Hypokalaemia
D- Hypo magnesia
Ans: A

156. Severe diarrhea leads to
A- Metabolic acidosis with normal anion gap
B- Metabolic acidosis with high anion gap
C- Metabolic acidosis with low anion gap
D- Metabolic alkalosis
Ans: A

157. The network of arteries inside glomerulus:
A- Tuft of arteries
B- Tuft of Capillaries
C- Tuft of Veins
D- Tuft of Venules
Ans: B
Explanation:
Glomerulus consists of tuft of capillaries those are branches of afferent renal arterioles.

158. 0.5 gram/dl protein is present in which fluid?
A- Lymph
B- CSF
C- Saliva
D- Tears
Ans: A

159. Proliferation of renal system:
A- Mesangium
B- Cortex
C- Medulla
D- Afferent Arteriole
Ans: A

160. An increase in the concentration of plasma potassium causes increase in:
A- Release of renin
B- Secretion of aldosterone
C- Secretion of ADH
D- Release of natriuretic hormone
E- Production of angiotensin II
Ans: B

171- Patient brought in shock in emergency department. Successful fluid replacement will be indicated by?
A- Decrease in tachycardia
B- Increase in BP
C- Increase in urine output
D- Increase in pulse
Ans: C

CamScanner

172. A patient is suffering from Severe Diarrhea K^+ infusion given. K^+ go into cell through which channel?
A- Na-k pump
B- K-ATPase
C- H-pump
D- Ca- pump
Ans: A

173. A man drinks 2 L of water to replenish the fluids lost by sweating during a period of exercise. Compared with the situation prior to the period of sweating:
A- His intracellular fluid will be hypertonic
B- His extracellular fluid will be hypertonic
C- His intracellular fluid volume will be greater
D- His extracellular fluid volume will be greater
E- His intracellular and extracellular fluid volumes will be unchanged.
Ans: C

174. Diabetic patient has increase urination and frequency due to?
A- Glomeral protein defect
B- Decrease water absorption
C- Decrease glucose absorption
D- Increase glucose absorption
Ans: C

175. In hypertensive patient what is cause of edema?
A- Increase Hydrostatic pressure
B- Decreased Hydrostatic pressure
C- Increased oncotic pressure
D- Lymphatic vessel blockage
Ans: A

176. Potassium depletion may cause:
A- Fall in plasma PCO_2
B- Fall in plasma pH
C- Rise in hydrogen ion in plasma
D- Rise in plasma bicarbonate
Ans: D

177. Hyperaldosteronism associated with all except:
A- Hypernatremia.
B- Hypokalemia
C- Hypertension
D- Metabolic acidosis
Ans: D

178. In burn patient succinylcholine isn't given due to which of the following effect:
A- Hyponatremia
B- Hypernatremia
C- Hyperkalemia
D- Hpokalemia
Ans: C

179. Kidney changes in hypovolemic Shock include
A- Acute tubular necrosis
B- Increase concentrated urine
C- Increase dilute urine
D- Increase Renin
Ans: A

180. Renal capillary filtration:
A- Increase with arterial constriction
B- Decease with increase hydrostatic pressure
C- Decrease with dehydration
D- Increase with dehydration
Ans: C

181. Serum sodium is regulated by:
A- Osmoreceptors
B- Baroreceptors
C- Thermoreceptors
D- Baroreptors
Ans: A (BRS)

182. Highest sodium channel concentration in:
A- Initial segment
B- Node of Ranvier
C- Dendrites
D- None
Ans: B

183- Na is major ECF cation. its mostly balanced by which anion:
A- $HCO3^-$
B- Cl
C- Ca
D- Cobalt
Ans: B

184. Which is more in dialysing fluid as compare to plasma?
A- Glucose
B- HCO3-
C- Chloride
D- Urea
E- Potassium
Ans: A

185. 0.85% saline contains how much NACL?
A- 850mg/100ml
B- 85g/L
C- 8500mg/ml
D- 8mg/ml
Ans: A

186. Maximum renal tubular transport maximum (Tm) is for:
A- Sulphate
B- Lactate
C- Urate
D- Phosphate
Ans: B

187. Protiens doesn't appear in urine because of:
A- Basement membrane
B- Mesangium
C- Podocytes
D- Glomerulus
Ans: A

188. In severe dehydration:
A- Whole body fluid will be low
B- ECF will be low
C- ICF will be low
D- Body fluid will be high
Ans: A

189. A patient with COPD and PO_2 55, HCO_3 26, pCO_2 49 and PH 7.3:
A- Type I Respiratory failure with uncompensated Respiratory Acidosis
B- Type II Respiratory failure with uncompensated Respiratory Acidosis
C- Respiratory Acidosis
D- Type II Respiratory Failure with Compensated Respiratory Acidosis
E- Type I Respiratory Failure with Compensated Respiratory Acidosis
Ans: B

190- Intracellular buffer:
A- Bicarbonate
B- Haemoglobin
C- Protein
D- Ammonia
Ans: C

191. ADH is inhibited by:
A- Aldosterone
B- Thirst
C- Alcohol
D- Angiotensin 2
E- Hypovolemia
Ans: C (BRS)

192. Which one is passively absorbed from renal tubules?
A- Cl
B- NH3
C- Glucose
D- Na
Ans: A (BRS)

193. Contraction of smooth muscles by:
A- Atrial nitrutric peptide
B- Oxytocin
C- Renin
D- Antidiuretic hormone
Ans: D

194. What are present at thin loop of Henle?
A- Brush border
B- Mitochondria
C- Flat epithelium
D- Max sodium absorption
Ans: C

195. Urine flow rate 1ml/min lowest osmolarity in which part?
A- Beginning or PCT
B- DCT
C- End of cortical collecting tubule
D- End of cortical papillary collecting duct
E- Tip of loop of Henley
Ans: B

196- For a substance X GFR 125mg/ml, Tm 125mg / mint, plasma concentration is 200mg/100ml, what will be the filtration, reabsorption and excretion of substance X?
A- 250 filtration, 125 reabsorptions and 125 excretions
B- 125 filtration, 125 reabsorptions and 0 excreted
C- 200 filtration, 125 reabsorptions and 75 excreted
D- 125 filtration, 250 reabsorptions, 125 excretions
Ans: A
Explanation:
Plasma Conc. =200mg/100ml =2mg/ml
Tm=125mg/min
GFR=125mg/ml
Filteration=GFR xPlasma Conc.
=125 x 2=250
Excretion=Filteration – Tm
=250-125=125
Reabsorption=Filteration – Excretion
=250-125 =125

197. Formation of Interstitial fluid increases with decreased in?
A- Capillary hydrostatic pressure
B- Capillary permeability
C- Interstitial fluid colloid osmotic pressure
D- Lymphatic flow
E- Plasma colloid osmotic pressure
Ans: E

198. GFR is decreased by:
A- Stone in ureter
B- Angiotensin 2
C- Afferent arterioles dilation
D- Efferent arteriolar constriction
Ans: A

CamScanner

199- Zinc is important essential element in one of the following:
A- Carbonic anhydrase
B- Cellular oxidation
C- Vitamin B12
D- Glycolysis
E- Ketogenesis
Ans: A

200. Renin is inhibited by:
A- Vasopressin
B- Prostaglandins
C- Increase sympathetic activity by renal nerve
D- Increase circulating catecholamine's
Ans: A

201. Which of the following statements is unlikely to be true about H^+ in the renal tubules?
A- It can bind with NH4+
B- It can bind with HPO4-
C- It can bind with HCO3-
D- It is secreted by H+ ATPase pump
E- It can exist as free H+
Ans: A (H^+ can bind with $NH3^+$ not $NH4^+$)

202. Inhibitors of carbonic anhydrase will cause:
A- Reduced urine
B- Increased formation & reabsorption of HCO_3
C- Acidosis
D- Decreased Potassium
E- Increase pH
Ans: C

203- Which of the following substance is more concentrated at the end of proximal convoluted tubule as compared to beginning of proximal tubules?
A- Bicarbonate
B- Glucose
C- Calcium
D- Sodium
E- Creatinine
Ans: E

204. What is the composition of normal saline?
A- 0.9 gm in 10 ml distilled water
B- 9 gm in 1000 ml distilled water
C- 0.9gm in 100 ml distilled water
D- 0.9gm in 10000 ml distilled water
Ans: B

205- How to differentiate between normal from SIADH:
A- Plasma osmolarity
B- Urine osmolarity
C- Adh levels in plasma
D- All of the above
Ans: A

206. Patient has oat cell carcinoma secreting ADH. What he will have?
A- Hyperosmotic over hydration
B- Hyposomotic over hydration
C- Hyperosmotic dehydration
D- Hypo-osmotic dehydration
Ans: B

Explanation:
- Hypo osmotic dehydration – adrenal insufficiency, overuse of diuretics
- Hypo osmotic over hydration – excess ADH, bronchogenic tumor
- Hyper osmotic dehydration – diabetes insipidus, excessive sweating
- Hyper osmotic over hydration – cyshing's disease, primary aldosteroinism.

207. Respiratory acidosis cause is
A- Barbiturate poisoning
B- Aspirin toxicity
C- High altitude
D- Salicylate poisoning
Ans: A

Explanation:
- Respiratory acidosis causes
- Airway obstruction
- Acute lung disease
- Chronic lung disease
- Opioids, sedatives
- Weakening of respiratory muscles

208. Patient with severe dehydration how much minimum urine output daily to eliminate nitrogenous waste product from body:
A- 100 to 200ml
B- 800 t 1000ml
C- 400 to 600ml
D- 600 t0 800ml
Ans: C

209. Cause of raised anion gap:
A- DKA
B- Renal tubular acidosis
C- Diarrhea
D- Multiple myeloma
E- Addison's disease
Ans: A

Explanation:
Cause of normal anion gap (HARDASS)
- Hyperchloremia / Hyperalimentation
- Addison's disease
- RTA
- Diarrhea
- Acetazolamide
- Spironolactone
- Saline infusion

Cause of increase anion gap (MUDPILES)
- Methanol
- Uremia
- Dka
- Propylene glycol
- Iron tablets or INH
- Lactic acidosis
- Ethylene glycol
- Salicylates (late)

Cause of decreased anion gap
- Multiple myeloma
- Hypoalbuminemia

210. Insensible water loss from skin in moderate climate:
A- Less than 200
B- 200-400
C- 400-600
D- 600-80
Ans: B (Guyton)

211. Product of GFR and plasma concentration of substance:
A- Filtration Fraction
B- Filtration Co-efficient
C- Filtration Load
D- Tubular secretion
Ans: C

212. Renal threshold for glucose:
A- 180
B- 200
C- 250
D- 375
Ans: B (Guyton)

213. Which extracellular fluid increase level can cause more effects on heart?
A- Na^+
B- $Ca2^+$
C- $Mg2^+$
D- K^+
Ans: D

214. Primary control of secretion from zona Glomerulsa is by which hormone?
A- Angiotensin 2
B- Renin
C- ACTH
D- PTH
Ans: A

215. Best way to measure high protein level in plasma:
A- Urea
B- Urea and creatinine
C- Urinary nitrogen content
D- All if the above
Ans: C

216. Patient had prolonged vomiting. Metabolic alkalosis in patient is caused by:
A- Decreased Hydrogen
B- Decreased Potassium
C- Decreased Sodium
D- Decreased HCO_3
Ans: A

217. Infusion of 140meq Sodium in 100ml water causes:
A- Increased osmolarity both ICF and ECF
B- Decreased osmolarity of ECF
C- Decreased osmolarity of ICF
D- Increased osmolarity of ICF
Ans: A

Explanation:
- 140meq in 100ml is Hypertonic so it will increase osmolarity of Both ICF and ECF
- 140meq in 1000ml is Hypotonic so it will decrease ICF Osmolarity > decrease ECF Osmolarity

218. Patient has chronic respiratory acidosis. For every 10 rise in pCO_2, the compensatory rise in HCO3 is:
A- 1
B- 4
C- 7
D- 10
Ans: B

Explanation:
- Acute respiratory acidosis – HCO_3 will increase by 1mmol/l for every 10mmHg increase in PCO_2 above 40mmHg
- Chronic respiratory acidosis – HCO_3 will increase by 4mmol/l for every 10mmHg increase in PCO_2 above 40mmHg
- Acute respiratory alkalosis – HCO_3 will increase by 2mmol/l for every 10mmHg increase in PCO_2 above 40mmHg
- Chronic respiratory alkalosis – HCO_3 will increase by 5mmol/l for every 10mmHg increase in PCO_2 above 40mmHg

219. Patient presented with excessive diarrhea and vomiting. Dx Metabolic Alkalosis is made what will have?
A- PH <7.4
B- Hco3 >25
C- K > 6
D- Na <120
Ans: B

CamScanner

220. Regarding Function of lymphatics:
A- Have few valves
B- Take plasma fluid back to body
C- Lymph enter in lymph vessel by contraction of nearby muscle
D- Contain less amount of albumin as compare to blood
Ans: B

221. A patient of chronic nephritis, presented with anemia. What is to give this patient as treatment?
A- Blood transfusion
B- PCV
C- Erythropoietin
D- Iron supplements
Ans: C

222. A patient presented with severe metabolic alkalosis, BP was 190/110 (hypertension) and serum potassium was 1.9 there is increased aldosterone level in his blood:
A- Addison's disease
B- Primary hyperaldosteronism
C- Adrenal hyperplasia
D- Secondary hyperaldosteronism
Ans: B

223- A 45-year-old man fell from roof top presented with Head injury and hyperventilation His Arterial blood gases shows PH 7.134, Po2 69 Pco2 25 Hco3 19 his CT report was normal. What is wrong with this patient?
A- Respiratory alkalosis
B- Metabolic alkalosis
C- Respiratory acidosis
D- Mixed acidosis
E- Metabolic acidosis
Ans: E

224. Total body water in infants:
A- 60%
B- 75 %
C- 80%
D- 65%
Ans: B

225. Gitelman syndrome is defect in which part of kidney?
A- PCT
B- DCT
C- Loop of henle
D- Collecting tubule
Ans: B

Explanation:
- Fanconi syndrome – Defect in PCT
- Bartter syndrome – Defect in thick ascending LOH
- Gentleman syndrome – Defect in DCT
- Liddle syndrome – Defect in collecting tubules

226. Cause of metabolic alkalosis is
A- Chronic lung disease
B- Uremia
C- Diarrhea
D- loop diuretics
E- Acetazolamide
Ans: D

Explanation:
Causes of metabolic alkalosis
- Loop diuretics
- Vomiting
- Antacid use
- Hyperaldosteronism

227. High serum concentration of potassium causes:
A- U waves
B- Flattened T waves
C- Peaked T waves
D- Tetany
E- Osteomalacia
Ans: C

Explanation:
High serum potassium concentration.
- Wide QRS
- Peaked T waves on ECG
- Arrhythmias
- Muscle weakness

Low serum potassium concentration
- Uwaves
- Flattened T waves on ECG
- Arrhythmias
- Muscle cramps
- Spasm
- Weakness

228- Low serum concentration of calcium causes:
A- Tetany
B- Renal stones
C- Bone pain
D- Inc. urinary frequency
Ans: A

Explanation:
Low serum calcium concentration
- Tetany
- Seizures
- QT prolongation
- Twitching (chovstek sign)
- Spasm (trousseau sign)

High serum Calcium concentration
- Stones (renal)
- Bones (pain)
- Groans (abdominal pain)
- Thrones (increase urinary frequency)
- Psychiatric overtones (anxiety, altered mental status)

229. HCO_3 is absorbed at which of the following site?
A- PCT
B- PCT + DCT
C- PCT + CD
D- CT
E- DCT
Ans: C

230- Autoregulation of GFR is by:
A- Tubuloglomerulr mechanism
B- Afferent glomerular constriction
C- Efferent golmerular dilatation
D- Efferent glomerular Constriction
E- Ureteric obstruction
Ans: A

231. ADH decrease sodium level Hyponatremia is caused by
A- Increase water intake
B- Increase Aldosterone
C- Increase Cortisol
D- Decrease Proteins
Ans: A

232- Patient came with generalized edema. Urine complete examination reveal Proteinuria cause is
A- Salt and water retention
B- Hypoalbuminemia
C- Increase hydrostatic pressure
D- Increase oncotic pressure
E- Portal HTN
Ans: B

Explanation:
- Peripheral edema in CLD due to – Loss of albumin (Low oncotic pressure)
- Ascities in CLD due to – Portal HTN
- Renal origin Edema due to – Loss of albumin (Low oncotic pressure) + Can be salt and water retention.
- Nephrotic syndrome edema due to – Hypoalbuminemia
- Nephritis Syndrome edema due to – Salt and water retention
- Pedal edema in CHF and HTN due to – Increase hydrostatic pressure
- In CHF edema woarsen by – Sodium and water retention

233. How much urine should be made to match the osmolarity of 570 when normal is 1440?
A- 0.5
B- 2
C- 0.25
D- 4
Ans: C

234. A young patient blood pressure is 150/95 his serum renin is higher than normal which of the following the stimulus for this increase level of renin is?
A- Essential HTN
B- Increase delivery of Na to renal tubules
C- Sympathetic stimulation via renal nerve
D- Vasodilation of renal arteriole
E- Increase blood flow to kidney
Ans: C

235- Voluntary inhibition of micturition reflex is by activation of
A- Pudendal nerve
B- Detrusor muscle contraction
C- Trigone
D- Sympathetic
E- Parasympathetic
Ans: A

Explanation:
- Initiation of Micturition reflex – **Stretch receptors in bladder wall**
- Micturition centre (stimulatory) – **Pons**
- Micturition centre (Inhibitory) – **Midbrain**
- Processing of micturition – **Cerebral cortex**
- Micturition reflex / integration – **Sacral segments of spinal cord**
- Voluntarily Inhibition – **Activation of Pudendal nerve**
- Pain and filling sensations of bladder are carried by – **Sympathetic (Guyton).**

236. A person is dehydrated from 24 hrs.Increase production of concentrated urine is due to
A- Increase Permeability through CD
B- Decrease permeability through DCT
C- Decrease Salt
D- Increase permeability through PCT
E- Increase ANP
Ans: A

237. Child with generalized body edema cause is ?
A- Hypoproteinemia
B- Increase hydrostatic pressure
C- Decrease Sodium
D- Increase Sodium
E- Decrease Magnesium
Ans: A

238. Drug which has more clearance than insulin will be:
A- Filtered only
B- Secreted
C- Filtered and secreted
D- Absorbed
Ans: C

CamScanner

239. In Nephrogenic diabetes, what will occur?
A- Urine osmolarity increase
B- ECF osmolarity increase
C- ECF volume increase
D- ECF osmolarity decrease
Ans: B

240. What changes are seen in a patient who is given 1L Isotonic N/saline?
A- Increased plasma osmolality
B- Increase Urine volume
C- Increased Plasma Sodium
D- Increased ICF volume
Ans: B

241. GFR increase by decrease in
A- Efferent arteriole Constriction
B- Afferent arteriole Constriction
C- Ureteric constriction
D- Bladder obstruction
Ans: B

Explanation:
Increase GFR due to:
- Afferent arteriole dilation
- Efferent arteriole constriction
- Decrease plasma proteins

Decrease GFR due to:
- Afferent arteriole constriction
- Efferent arteriole dilation
- Increase plasma proteins
- Ureter constriction

242. A child present with proteinuria and edema which is responsive to steroids cause of edema is ?
A- Increase Hydrostatic pressure
B- Increase Plasma volume
C- Low plasma oncotic pressure
D- Low Plasma filtration
Ans: C

243. A patient has following ABGs value PH 7.1 , CO2= 50 and HCO3=7 what is likely acid base disorder
A- Respiratory alkalosis
B- Compensatory respiratory acidosis
C- Compensatort Metabolic acidosis
D- Mixed Acid base disorder
Ans: D

244. Nephron Area with least hyperosmolarity
A- PCT
B- DCT
C- LOH
D- CD
Ans: B

Explanation:
- Dilute Urine (Decrease osmolarity) – Early DCT(Macula Densa) > Thick Limb of loop of henely
- In Dehydraion (ADH) Concentrated Urine (Increase osmolarity) – CD (Vasa Racta)

Ans: B

245. Regarding glomerular capillary Pressure
A- Increases with afferent arteriolar constriction
B- Decrease with decreasing oncotic pressure along membrane.
C- Less then most capillaries at heart level.
D- Decrease by 10 percent when BP decrease by 10 percent
Ans: D

246. Thirst is partially alleviated by
A- Increased plasma osmolarity
B- Increase Ag2
C- SIADH
D- Hypovolemia
E- Dec ECF volume
Ans: C

247. Example of secondary active transport in kidney is:
A- Sodium
B- Glucose
C- Urea
D- Chloride
Ans: B

248. Sodium reabsorption in basolateral membrane occurs due to:
A- Glucose co transport
B- Active transport
C- Na k pump
E- Glucose amino acid transport
Ans: C

249. Change in Renal function to retain maximum blood is
A- Decrease release of renin
B- Increase Cortisol
C- Increase renin secretion
D- Increase Potassium absorption
Ans: C

250. Autoregulation of renal blood flow at what Mean arterial blood pressure is:
A- 40-100
B- 80 -120
C- 40-60
D- 200-220
Ans: B

251. Fluid coming form PCT to loop of henele has which feature:
A- More hco3 than plasma
B- More sodium than plasma
C- is hypertonic
D- More glucose than plasma
E- More urea than plasma
Ans: E

252. Patient presents with unconsciousness in ER blood glucose level = 400mg/dl & PH=7.1. What will be most important buffer in plasma of this patient?
A- HCO3
B- HB
C- Protein
D- Ammonia
E- CO2
Ans: A

Explanation:
- Major blood / Extracellular / Interstitium / Plasma Buffer – Bicarbonate
- Major RBCs buffer – Hemoglobin
- Major Intracellular Buffer – Proteins
- Major Renal Buffer – Phosphate
- Exclusive Renal tubular buffer – Ammonia
- Major urinary buffer (quantitatively) – Ammonium
- Major bone buffer – Calcium carbonate

253- Anion gap increase in:
A- Uncontrolled DM
B- Diabetes insipidus
C- Bronze diabetes
D- Respiratory failure
Ans: A

254- Edema can occur due to decrease oncotic pressure and due to raised hydrostatic pressure.Apart from these 2 being causes for edema what combination can cause edema due obstruction
A- Infection and Neoplasia
B- Renal failure and hypoproteinemia
C- Hematuria and albuminuria
D- Cardiac failure and IHD
E- Arterial obstruction
Ans: A

255. In Respiratory acidosis which of following cause buffering?
A- Bicarbonate system in kidney
B- Ammonium system in kidney
C- Phosphate system in kidney
D- Protein system
Ans: A

256. Secretion of ADH block due to shrinkage of which of following?
A- Pressoceptor
B- Baroreceptor
C- Chemoreceptor
D- Angiotensin
E- Osmoreceptor
Ans: E

257. What is reason of Osmotic pressure
A- Sodium
B- Vitamin
C- Water
D- Potassium
E- Calcium
Ans: A

258. GFR increase by
A- Clonidine
B- Epinephrine
C- Norepinephrine
D- Nitric oxide
Ans: D(BRS)

259. A patient with PH 7.12 CO_2 60 and: HCO_3 19 following acid base Abnormality will be present
A- Metabolic alkalosis
B- Metabolic acidosis
C- Hypochloremic metabolic alkalosis
D- Mixed acid base disturbance
E- Respiratory alkalosis
Ans: D

260. Patient with nephrotic syndrome Which structure in GBM plays major role in perm- selectivity for proteins:
A- Lamina rara interna
B- Lamina rara external
C- Lamina densa
D- Visceral epithelial layer
Ans: B

261. In chronic respiratory acidosis:
A- Increase urinary monohydrogen to dihydrogen phosphate excretion
B- Increase urinary HCO3 formation
C- Decrease urinary ammonium excretion
D- Decrease phosphate excretion
Ans: A

262. What is early response of body in sudden blood loss?
A- Sympatheto adrenegic
B- CNS ischemic response
C- Hyperventilation
D- Baroreceptors
E- Increase Respiration
Ans: D

CamScanner

263- During dehydration ADH:
A- Increase Permeability through CD
B- Decrease permeability through DCT
C- Decrease Salt
D- Increase permeability through PCT
Ans: A

264. A patient Bp 200/110, k 3.2, pulse was 50 Because of which hormonal increase?
A- Aldosterone
B- Ag2
C- Cortisol
D- Norepinephrine
Ans: A

265- Strongest stimuli for erythropoietin are -
A- Hypoxia
B- Injury
C- Inc. PH
D- Dec. PH
E- Lactate
Ans: A

Explanation:
- Erythropoiesis stimulated by – Erythropoietin
- Erythropoietin stimulated by – Hypoxia
- Erythropoietin inhibited by – Theophylline

266- Short term action of aldosterone is
A- Na absorption by dct
B- Decrease permeability of Na in duct
C- Increase permeability of Na+ K in cortical collecting tubule
D- Increase Na reabsorption in duct
E- Decrease absorption of Na+ K in collecting tubule
Ans: C

267- In the presence of ADH maximum —— Water absorption in:
A- CD
B- DCT
C- Loop
D- PCT
Ans: D

268- Patient has history of severe dyspnea — and breathlessness after 1 week other — symptoms resolved except dyspnea. —— ABG's shows PH 7.32, CO2 70mmhg, — HCO3 35mmhg
A- Uncompesated metabolic acidosis
B- Compensated metabolic acidosis
C- Respiratory alkalosis
D- Compensated respiratory acidosis
E- Metabolic alkalosis
Ans: D

269- Fenestrated capillaries mostly found in
A- Skin
B- Spleen
C- Stomach
D- Kidney
E- Brain
Ans: D

Explanation:
- Fenestrated capillaries occur wherever active filtration or absorption occurs e.g. small intestine, kidney, In cillary process of eye, in choroid plexus.

270- GFR increase by which of following —
A- Efferent arteriolar constriction
B- Increase plasma colloid osmotic pressure
C- Ureteric constriction
D- Afferent arteriole constriction
E- Efferent arteriole dilation
Ans: A (BRS)

Explanation:
Increase GFR due to:
- Afferent arteriol dilation
- Efferent arteriol constriction
- Decrease plasma proteins

Decrease GFR due to:
- Afferent arteriole constriction
- Efferent arteriole dilation
- Increase plasma proteins
- Ureter constriction

271- Best way to measure GFR is
A- K clearance
B- Creatinine Clearance
C- BUN Clearance
D- Urea
E- BUN
Ans: B

Explanation:
- GFR measure Clinically / Best Estimated – Creatinine clearance
- GFR best Way to Measure – Inulin
- Best way to Measure RPF – PAH or Hippurate
- Endogenous substance to measure GFR – Creatinine.
- Best test for renal failure – Creatinine clearance
- Clearance – PAH >K >Inulin >Urea > Sodium> Amino acid and Glucose

272- Chloride transport in Loop of henle by
A- Countertransport with K
B- Cotransport with Na K
C- Cotranspirt with Cl
D- Diffusuon with Na
Ans: B

273- 7 years old child having Na110 K 3.5 urine osmolality 620 mosm cause - is
A- Dehydaration
B- SIADH
C- Addison's
D- Cushing disease
Ans: B

274- Difference between PCT and DCT ——
A- Basement membrane
B- PCT has Brush border
C- Pores
D- Posterior to pancreas
Ans: B

275- After strenuous exercise blood volume — maintained by
A- Increase Renin
B- Decrease renin
C- Increase cortisol
D- Decrease sympathetic
Ans: A

276- Hyperkalemia occurs in acute response - to
A- Fluid intake
B- Exercise
C- Increase fluid loss
D- CRF
E- CLD
Ans: B

277- A patient with hyperemesis gravidarum having hypokalemia can present with which of other finding ——
A- Metabolic acidosis
B- Metabolic alkalosis
C- Respiratory alkalosis
D- Respiratory acidosis
E- Mixed acid base
Ans: B

278- 0.9% normal saline means
A- 9g in 1000ml
B- 9g in 100 ml
C- 9 mg in 1000ml
D- 9 mg in 100ml
E- 0.9 mg in 100
Ans: A

279- Minor calyces receive urine from ———
A- Major calyces
B- Renal papilla
C- Renal medulla
D- Renal cortex
Ans: B

280- Which fluid gives isotonic solution
A- 0.9% N/S
B- 0.45%N/S
C- 3%N/S
D- 5%D/W
E- 1%N/S
Ans: A

281- The result of consequence of decrease — volume concentration is
A- Renin increase
B- Renin aldosterone angiotensin system activation
C- Cortisol increase
D- GH increase
Ans: B

282- When CO2 transferred to lungs from —— tissues what happen
A- Acidosis of RBCs
B- Alkalization of RBCs
C- Carbaminoacid
D- Increase HCO3
Ans: A

283- A patient has complaint of headache — - due to high icp Csf is example of
A- ECF
B- Plasma
C- Interstitial fluid
D- Transcellular fluid
E- ICF
Ans: D

284- After infusion of 0.9%N/S what will occur:
A- Decrease urine osmolarity
B- Increase urine osmolarity
C- Same urine osmolarity
D- Increase Plasma osmolarity
Ans: A

Explanation:
- 0.9 %N/S is Isotonic to plasma so no effect on Plasma osmolarity but volume will increase and will be filtered and urine becomes dilute so osmolarity of urine will decrease.

285- Patient on Antihypertensive having increase urine output due to
A- Increase hydrostatic pressure GFR
B- Decrease hydrostatic pressure GFR
C- Afferent arteriol dilation
D- High Bowman space
Ans: A

CamScanner

286- If Patient 25% nephron is working what will happen in remaining nephron
A- Increase GFR in remaining nephron
B- Decrease Blood flow
C- Decrease Urea and Cr ratio
D- Decrease urinary sodium
Ans: A

287- There is no edema due to inc aldosterone because of
A- Increase Na/k activity of thick Ascending limb
B- Decrease thirst mechanism
C- Escape mechanism
D- Increase ADH
E- Decrease ANP
Ans: C

288- Renal compensation for hyperkalemia is:
A- Acidosis
B- Alkalosis
C- Increase H ion secretion
D- Increase HCO3 secretion
Ans: A

289- Deficiency in which of following cause hyperexcitibility:
A- Na
B- K
C- Ca
D- PO4
Ans: C

290- GFR is measured by:
A- Inulin
B- Creatinine
C- PAH
D- Ammonia
Ans: A
Explanation:
GFR Measured – Inuline
GFR Estimated/Clinically – Creatinine
Endogenous subtance to measure GFR – Creatinine.
Renal plasma flow – PAH

291- Prompt response to falling BP is
A- RAAS
B- CNS ischemic
C- Cortisol
D- Baroreceptor
Ans: D

292- Edema in kidney related disease in patient is due to:
A- Salt and water retention
B- Hypoalbuminemia
C- Increase hydrostatic pressure
D- Increase oncotic pressure
E- Portal HTN
Ans: B

293- Concentrated urine is related to which one of the following
A- DM
B- ADH not functioning
C- Increased water abosrption from Distal convulated tubule
D- Diabetes Inspidus
Ans: C

294- Crescents in glomeruli are formed due to proliferation of:
A- Endothelial cells
B- Mesengeal cells
C- Mesengeal and Endothelial cells
D- Parietal cells
Ans: D

295- Which of the following is absorbed maximally from PCT
A- Urea
B- Sodium
C- Glucose
D- Water
E- Nitrogen
Ans: C

296- In hemorrhage which part of nephron is most commonly affected
A- DCT
B- PCT
C- Loop of henle
D- Ascensing loop of henle
E- Late DCT
Ans: B

297- True about thin loop of Henle:
A- Flattened base
B- Cuboidal epithelium
C- Brush border
D- Columnar epithelium
Ans: A

298- A 30-year-old female has persistent asthenuria (dilute urine). The following will indicate a defect of tubular concentration mechanism:
A- Low specific gravity of urine
B- High blood urea
C- Low plasma osmolarity
D- Hypernatremia
E- Low urinary sodium
Ans: E

299- A pregnant lady of 12weeks gestational amenorrhea presented with Flank pain rigors and chills high grade fever this is due to:
A- Pregnancy
B- Acute pyelonephritis
C- UTI
D- Acute cystitis
E- Chronic pyelonephritis
Ans: B
Explanation:
Acute pyelonephritis has Fever , Flank pain and WBC cast in urine

300- A patient ABGs PH 7.37 , PCO2 50 and HCO3 30 what is suitable interpretation
A- Metabolic acidosis
B- Respiratory alkalosis
C- Respiratory acidosis and metabolic alkalosis
D- Metabolic acidosis and Respiratory acidosis
Ans: C (Only Suitable)

301- 100% Glucose absorption occur in
A- DCT
B- PCT
C- Loop of henly
D- Ascensing loop of henly
E- Late DCT
Ans: B

302- Urine concentrated by
A- TSH
B- ADH
C- Cortisol
D- ACTH
Ans: B

303- Which one will be activated below 60mmhg MAP
A- RAAS
B- Baroreceptors
C- CNS ischemic response
D- Aldosterone
E- Cortisol
Ans: C

304- Fluid of choice in paradoxical aciduria?
A- 10%Dextrose
B- Normal saline
C- Ringer lactate
D- 5% dextrose
Ans: B

305- About Fluid absorption from ilium true is
A- It is by Na/K pump
B- Maximum absorption occur here
C- Maximum fluid loss here
D- Iron loss from here
Ans: B

306- Baroreceptors most sensitive to
A- Blood loss
B- Increase Volume
C- Decrease arterial pressure
D- Decrease pH
E- Increase pH
Ans: C

307- Creatinine is found in:
A- Bowman capsule
B- Skeletal muscle
C- Retina
D- Podocytes
Ans: B

308- Glomerular resistance is equal to:
A- Efferent arteriolar resistance
B- Sum of both afferent and efferent arteriolar resistance
C- Glomerular pressure
D- Vasa recta pressure
Ans: B

309- Person is thirsty for 24hour, next response will be:
A- ANP release
B- Decrease renin.
C- Decreased ADH
D- Increase water permeability from proximal and distal tubules
Ans: D

310- Protein filtration occur via:
A- Podocytes
B- Bowman capsule
C- Endothelial cells of kidney
D- Epithelial cells
Ans: C

311- Osmotic diuretic act on:
A- DCT
B- Thick ascending limb
C- CD
D- CCD
E- PCT
Ans: E
Explanation:
- Osmotic diuretics – Mannitol, Urea, Glycerol – PCT
- Carbonic Anhydrase inhibitors - Acetazolamide – PCT
- Loop Diuretic- Furosemide, Ethacrynic acid – Thick ascending limb
- Thiazide Diuretic – Hydrochlorothiazide's – Early DCT
- Potassium sparing diuretics - Spironolactone – CD

CamScanner

312- Loss of thirst due to:
A- Increase ECF volume
B- High Plasma osmolality
C- Aldosterone
D- Angiotensin
Ans: A

313- In dehydration maximum Water absorption occur in:
A- CD
B- DCT
C- Loop
D- PCT
Ans: D

314- GFR decrease by increase in:
A- Efferent arteriole constriction
B- Increase plasma oncotic pressure
C- Ureteric dilation
D- Afferent arteriole dilation
E- Efferent arteriole Constriction
Ans: **B (BRS)**

Explanation:
Increase GFR due to:
- Afferent arteriolar dilation
- Efferent arteriolar constriction
- Decrease plasma proteins(Osmotic pressure)

Decrease GFR due to:
- Afferent arteriole constriction
- Efferent arteriole dilation
- Increase plasma proteins(Osmotic pressure)
- Ureter constriction

315- PCT absorb 45-50% which of following:
A- Urea
B- Glucose
C- HCO3
D- Water
Ans: A

316- In the presence of adh max urine osmolarity will be?
A- 300
B- 600
C- 1500
D- 1200
E- 2000
Ans: D

317- Na absorption from DCT increases when?
A- Plasma osmolarity increase
B- Plasma volume increase
C- Increase K+ concentration in plasma
D- Increase Ca concentration in plasma
Ans: B

318- Na absorption from basal lamina of kidney:
A- K efflux
B- Na influx
C- Na efflux
D- Na/k ATPs pump
Ans: D

319- Patient present with breathlessness, PH 7.35, PCO2 60, O2 75 and HCO3 18 which acid base disorder is?
A- Respiratory acidosis
B- Metabolic alkalosis
C- Uncompensated metabolic acidosis
D- Metabolic acidosis
Ans: A

320- A patient ABGs reveal PH 7.54, PCO2 40 and HCO3 38 what is acid base disorder?
A- Respiratory acidosis
B- Respiratory alkalosis
C- Compensatory Respiratory Acidosis
D- Metabolic acidosis
E- Uncompensated Metabolic alkalosis
Ans: E

321- PCT has brush border which is:
A- Microvilli
B- Cilia
C- Villi
D- Tubules
Ans: A

322- Glucose absorbed in PCT by:
A- Simple diffusion
B- Co transport
C- Secondary active transport
D- Facilitated diffusion
Ans: C

323- Secretion of substance occurs only if:
A- More reabsorption
B- Excretion is greater than reabsorption
C- More absorption then excretion
D- Non
Ans: B

324- Least renal clearance is of:
A- Na
B- Glucose
C- Hco3
D- Urea
Ans: B

325- Greatest blood flow per 100g of tissue:
A- Heart
B- Kidneys
C- Lung
D- Skin
Ans: **B**

Explanation:
- Max blood flow per minute-Liver
- Least blood flow per minute-Heart
- Max blood flow per 100 gram of tissue
- Kidney
- Max O2 consumption-Liver
- Max O2 consumption per 100 gram of tissue
- Heart
- Least O2 consumption-Skin
- Max O2 extraction from blood B-Heart

326- Before deciding for transplant measure of renal function done by:
A- Creatinine clearance
B- Inulin
C- Insulin
D- PAH
E- BUN clearance
Ans: A

327- Renal tubular cell basolateral membrane has:
A- Na k ATPase pump
B- Inward sodium
C- Outward potassium
D- Inwards potassium
Ans: A

328- BUN/Cr ratio greater than 20 cause will be:
A- Post renal Azotaemia
B- Pre renal azotaemia
C- ATN
D- CKD
Ans: B (Kaplan +FA)

329- Patient is dehydrated, osmolarity increased, what will happen?
A- Stimulate volume and osmoreceptors and stimulate ADH secretion
B- Stimulate volume and osmoreceptors and decrease ADH secretion
C- Inhibit volume and osmoreceptors and stimulate ADH secretion
D- Inhibit volume and osmoreceptors and inhibit ADH secretion
Ans: A

330- Which of the following is used to calculate total body water:
A- Evans blue dye
B- Heavy water
C- Inulin
D- Mannitol
Ans: B

331- Which one is Different from plasma in osmolarity
A- Ringer lactate
B- 5% dextrose
C- Normal saline
D- 1.2% Na bicarbonate
Ans: B

332- The part of nephron affected mostly by Ischemia is:
A- DCT
B- PCT
C- Ascending loop of Henle
D- Collecting tubules
E- Descending loop of Henle
Ans: B

333- Sodium active absorption occurs in
A- Jejunum
B- Ilium
C- Colon
D- Duodenum
Ans: C

334- Increase PaCO2 will cause:
A- Hypotension
B- Coma
C- Tachycardia
D- Sweating
E- Tremors
Ans: C

335- In a person of 70kg how much of it will be present in interstitial fluid?
A- 11L
B- 42L
C- 28L
D- 42L
E- 52L
Ans: A

336- Straight vessel along loop of henle that helps in concentrating urine is:
A- Vasa recta
B- Proximal convoluted tubule
C- Peritubular capillaries
D- Interlobular artery
E- Arcuate artery
Ans: A

337- A hypertensive can be managed pharmacologically and surgically, on labs what's the evidence that makes it possible for him to be treated pharmacologically instead of surgery?
A- Increase Catchecholamines
B- Hyperrenemia
C- Hyperaldosteronism
D- Hypercalcemia
E- Inflammatory response to Kidney
Ans: B

CamScanner

338- 30 years old woman is given 0.1g insulin. One hr later the plasma insulin concentration is 1mg/100ml. Which of the following is the extracellular fluid in liters?

A- 10
B- 02
C- 12
D- 14
E- 16

Ans: A

Explanation:

- Amount of Inulin Injected=0.1 g
- Concentration Obtained=1g/100=0.01g
- Simplified Formula :-
- ECF Volume = Amount of Inulin Injected/Concentration Obtained
- ECF Volume = (0.1g/0.01g) Liters
- ECF Volume = 10 Liters

339- Loop diuretics MOA on thick ascending limb of loop of henle is:

A- Inhibit Na/K/2Cl-
B- Inhibit Na/K ATPase
C- inhibit 2Na/K/Cl
D- Inhibit Na/2K/Cl

Ans: A

340- A person is dehydrated & profusely sweating.Percentage of Water absorbed from PCT is?

A- 55-60%
B- 60-70%
C- 70-80%
D- 80-90%
F- 85-95%

Ans: B

341- A patient on anti HTN hydrochlorothiazide says he has good controlled BP with the medicine. His labs show serum Na 119, serum. osmolarity 245 and is hypovolemic clinically. what should initial treatment be:

A- 3% NS
B- 0.9% NS
C- 0.45 % NS
D- IV furosemide with 3% NS

Ans: D

342- Patient unable to excrete co2, what will happen

A- Decrease po2
B- Alkaline urine
C- Increase PH
D- Decrease PH

Ans: D

343- A person in a severe dehydrated state , what percentage of water will be absorbed at PCT

A- 40%
B- 70 - 80%
C- 60 - 65%
D- 30-40%

Ans: C

344- Denervation of kidneys will cause

A- Increase nor adrenaline concentration in kidneys
B- Increase Na absorption
C- Increase urine flow
D- Increaae Renin

Ans: C

Explanation:

- Denervation of kidney renal efferent nerve thus increase renal blood flowleading to increase urinary water excretion.

345- ADH short term action is:

A- Vasodilation of arterioles
B- Vasoconstriction of arterioles
C- Secrete Renin
D- Reabsorption of salts

Ans: B

346- A pt with pH 7.3 , HCO3 16 , CO2 38 , What's the acid base metabolic disorder?

A- Metabolic acidosis
B- Respiratory acidosis
C- Metabolic alkalosis
D- Respiratory alkalosis

Ans: A

347- Which hormone maintains ECF osmolarity??

A- Aldosterone
B- Vasopressin
C- Angiotensin 2
D- ANP
E- BNP

Ans: B

Explanation:

- ECF Volume regulated by -Aldosterone
- Maintain and regulates ECF osmolarity - ADH
- Regulates Serum osmolarity -ADH >Aldosterone
- Total body Water and electrolytes balance regulated by ADH
- Total body Water and electrolytes balance maintained by -Aldosterone
- Maximum Water and Na absorbed by the affect of -Aldosterone

348- If a patient has renal plasma flow 600 and Hct 0.40 calculate blood flow to kidney:

A- 1200 ml/min
B- 400 ml/min
C- 800 ml/min
D- 1200 ml/min
E- 1000 ml /min

Ans: E

Explanation:

RBF = RPF /1-Hct
600/1-0.40
600/0.6 =1000ml/min

349- Active Na absorption occur in which part of kidney

A- LOH
B- DCT
C- CD
D- PCT

Ans: D

350- A person in a marathon race , at the end of the race he drinks water to compensate fluid loss due to sweating . What will be seen in him at the end of Marathon ?

A- Decrease total body water
B- Increase Intracellular osmolarity
C- Decrease plasma osmolarity
D- Decrease ICF Volume

Ans: D

Explanation:

- Here asking what will happen at the end of race he will be depleted in water more in ICF volume
- If asked changes what will be changes after drinking water then follow below sequence
- Increase ICF Volume > Decrease ICF Osmolarity > Increase ECF volume > Decrease ECF osmolarity.

351- Patient having Respiratory alkalosis. Cause is

A- Acetyl salicylic acid
B- Drowning
C- Morphine poisoning
D- Loop diuretics
E- DKA

Ans: A

352- Which of the following is true about plasma proteins?

A- Exert an oncotic pressure of 25mmhg
B- Globulins make a bulk of them
C- Made exclusively in liver
D- Buffer capacity upto 30%

Ans: A

353- Decrease K excretion is due to

A- Aldosterone
B- Metabolic acidosis
C- Prolong vomiting
D- Diarrhea
E- Renal failure

Ans: B >E

Explanation:

- Renal failure is generalized term in this Acute renal failure can cause hyperkalemia
- How ever acute renal failure leads to Metabolic acidosis which will lead to Hyperkalemia as by compensation H ions from blood will start moving to cell and K will move from cell into blood so result in hyperkalemia thus decrease tubular excretion

354- A pregnant lady having hyperemesis gravidum which acid base balance will be present?

A- Metablic Acidosis
B- Respiratory Acidosis
C- Metabolic Alkalosis
D- Respiratory Alkalosis
E- Mixed acid base

Ans: C

355- After RTA, 1.5 liters of blood is lost, there is decrease in GFR and urine output. which part of nephron will bring back GFR to normal?

A- PCT
B- DCT
C- Thin descending loop of henle
D- Thick ascending loop of henle
E- Collecting Ducts

Ans: B(Via RAAS system)

356- A young patient blood pressure is 150/95 his serum renin is higher than normal which of the following the stimulus for this increase level of renin is

A- Increase plasma osmolarity
B- Increase sodium delivery to macula densa
C- Renal artery Vasoconstriction
D- Exercise
E- Parasympathetic stimulation of renal nerve

Ans: C

357- 30 years old woman is given 0.1g insulin. One hr later the plasma insulin concentration is 1 mg/100ml. Which of the following is the extracellular fluid in liters?

A- 10
B- 02
C- 12
D- 14
E- 16

Ans: A

CamScanner

Explanation:
- Amount of Inulin Injected=0.1 g
- Concentration Obtained=1g/100=0.01g

Simplified Formula :-
- ECF Volume = Amount of Inulin
- Injected/Concentration Obtained
- ECF Volume = (0.1g/0.01g) Liters
- ECF Volume = 10 Liters

358- Calculate the GFR when Glomerular Hydrostatic pressure is 60mmhg,Bowman capsule Hydrostatic pressure is 12mmhg & Capillary oncotic pressure is 30mmHg.
A- 18
B- 84
C- 92
B- 112
E- 48
Ans: A

Explanation:
- GFR= (PGC- PBS) – (PiGC-PiBS)
- PiBS is bowman space oncotic pressure, It is usually zero
  =(60-30) -(12)
  =18

359- Negatively charged particles are prevented from entering renal basement membrane. Which of the following component is responsible for prevention of negative compounds?
A- Proteoglycan
B- Laminin
C- Densly packed cells
D- Lamin of lamina interna
E- Fibronectin
Ans: A

360- GBM repels the proteins due to negative charge due to which of the following?
A- Proteoglycan
B- Collagen type 4
C- Fibronectin
D- Endothelium
E- Laminin
Ans: A

361- Respiratory acidosis occurs in
A- High altitude
B- Drowning
C- Aspirin toxicity
D- Diarrhea
E- Hyperaldosteronism
Ans: B

362- If a patient has renal plasma flow 600 and Hct 0.40 calculate blood flow to kidney
A- 1200 ml/min
B- 400 ml/min
C- 800 ml/min
D- 1200 ml/min
E- 1000 ml /min
Ans: E

Explanation:
- RBF = RPF /1-Hct
- 600/1-0.40
- 600/0.6 =1000ml/min

363- 18 years old girl diabetic presented to ER in semiconscious state. Her ABGs done which show a ph level of 7.0, BSR 300mg/dL HCO3 18.Which acid base disorder is this?
A- Mixed metabolic Acidosis
B- Respiratory Acidosis
C- Respiratory Alkalosis
D- Metabolic Acidosis
Ans: D

364- PCT has a brush border that differentiates it from DCT. Which of the following makes the brush border?
A- Microvilli
B- Cilia
C- Stereovilli
D- Lamina
E- Flagella
Ans: A

365- A baby was born to a diabetic mother. Which of the following complications will the baby have?
A- Hypoinsulinimia
B- Hypocalcemia
C- Low birth weight
D- Hyperglycemia
E- Respiratory distress syndrome
Ans: E

366- Creatinine clearance related to
A- GFR/Filtration fraction
B- GFR - Filtration fraction
C- Blood flow /Body weight
D- Filtration fraction - Body weight
Ans: A

367- Identify the Acid base imbalance: Ph: 7.4, PCo2: 31mmHg, HCO3: 22mEq/L
A- Mixed renal and metabolic disorder
B- Metabolic acidosis
C- Metabolic alkalosis
D- Respiratory acidosis
E- Respiratory alkalosis
Ans: A

368- Increase potassium in urine is due to
A- Decrease K secretion in DCT
B- Increase K secretion in DCT
C- Increase tubular absorption of K
D- Increase intestinal absorption of K
Ans: B

369- Renal plasma flow is measured by which of the following?
A- Inulin clearance
B- Hippurate
C- Creatinine clearance
D- Antipyrene
E- Sulfate
Ans: B

Explanation:
- GFR measure Clinically / Best Estimated – Creatinine clearance
- GFR best Way to Measure – Inulin
- Best way to Measure RPF – PAH or Hippurate
- Best test for renal failure – Creatinine clearance
- Clearance – PAH >K >Inulin >Urea > Sodium> Amino acid and Glucose

370- A patient with PH 7.55, PCO2 30 , HCO3 21 disorder is?
A- Metabolic acidosis
B- Respiratory acidosis
C- Metabolic alkalosis
D- Respiratory alkalosis
Ans: D

371- After RTA due to haemorrhage a person with 2 liter blood loss, the blood volume restored back by:
A- PCT
B- DCT
C- CD
D- Loop
E- CCD
Ans: B

Explanation:
- In haemorrhage most commonly affected – PCT
- Blood volume bring back by – DCT (Via RAAS)

372- Sodium absorption from collecting duct via:
A- Activation of RAAS
B- Aldosterone
C- ADH
D- Angiotensin 2
Ans: B

373- A Patient has Ph 7.2, HC03: 16. PCO2 36. Acid base disorder will be:
A- Metabolic acidosis
B- Metabolic alkalosis
C- Respiratory acidosis
D- Respiratory alkalosis
Ans: A

374- A patient ABGs reveals PH 7.54, PCO2 40 and HCO3 29 what is acid base disorder?
A- Respiratory acidosis
B- Respiratory alkalosis
C- Compensatory Respiratory Acidosis
D- Metabolic acidosis
E- Uncompensated Metabolic alkalosis
Ans: E

375- A patient of asthma having following ABGs PH 7.23. HCO3 26 and Hypercapnea likely acid base disorder is:
A- Uncompensated metabolic acidosis
B- Compensated metabolic acidosis
C- Respiratory alkalosis
D- Respiratory acidosis
E- Metabolic alkalosis
Ans: D

376- A patient presented with urine output of 1.4 litre , plasma flow 144mg/100ml. Urine flow 140mg/100ml Calculate creatinine clearance
A- 1.06
B- 168
C- 1
D- 1.63
Ans: B

377- Aldosterone exerts its maximum effect on which of the following site?
A- PCT
B- LOH
C- DCT
D- CT
Ans: C

Explanation:
- Aldosterone acts on: CCT > DCT > CT
- ADH acts on: CT > DCT > CCT

378- I L normal saline given to patient what will be affect on urine
A- Increase & Dilute Urine
B- Decrease & Concentrated Urine
C- Decrease urine Formation
D- None
Ans: A

CamScanner

379- Fluid not isotonic with plasma
A- Normal saline
B- 5% dextrose
C- 1.2% sodium bicarbonate
D- Hartman's solution
Ans: B

380- 3rd space fluid loss. fluid of choice is:
A- Blood and plasma
B- 10%dextrose
C- Ringers lactate
D- Normal saline
Ans: C

381- Dehydration decreases the levels of which of the following?
A- Atrial Natriuretic Peptide
B- Angiotensin II
C- Aldosterone
D- Water
E- Concentration
Ans: A

382- Spironolactone effect on excretion in urine:
A- Increase Na, decrease K
B- Increase Na, no effect on K
C- Decrease Na, Increase K
D- Increase Na, Increase K
Ans: A

383- Arteries coursing around the base of renal pyramids:
A- Arcuate artery
B- Interlobar
C- Interlobular
D- cortical radiate
E- Medullary artery
Ans: A

384- A patient having solute osmolarity 520mg/dl and urine osmolarity 1140mg/dl what is the minimum volume of urine(in liters)required to effectively remove metabolic waste products from the body?
A- 4 liters
B- 1 liters
C- 6 liters
D- 2 liters
E- 0.5 liters
Ans: E

385- A patient has Ph = 7.32, PCO2 = 50, HCO3 = 24, increased anion gap:
A- Partially compensated respiratory acidosis
B- Partially compensated metabolic acidosis
C- Respiratory acidosis
D- Metabolic acidosis
Ans: C

386- Patient with PH =7.12 , PCO2 60 and HCO3 19 cause is:
A- Metabolic acidosis
B- Metabolic alkalis
C- Compensated metabolic alkalis
D- Compensated metabolic acidosis
E- Mixed metabolic acidosis and Respiratory acidosis
Ans: E

387- A person with water deprivation which harmone will increase
A- Aldosterone
B- ADH
C- Cortisol
D- Thyroxin
Ans: B

388- Dehydration will lead to Decreased Plasma Level of:
A- ANP
B- Vasopressin
C- Angiotensin 2
D- Water
E- Aldosterone
Ans: A

389- Sodium reabsorption is a function of:
A- ANP
B- Aldosterone
C- Cortisol
D- ADH
Ans: B

390- What is the primary physiological change associated after alcohol consumption:
A- ↑ ANP
B- ↑ Urine specific gravity
C- ↓ ECF osmolality
D- ↓ Urine specific gravity
D- Increased ECF Osmolarity
Ans: D

Explanation:
After alcohol consumption, the primary physiological change is decreased urine specific gravity, which occurs due to the diuretic effect of alcohol. Alcohol inhibits the secretion of antidiuretic hormone (ADH) from the posterior pituitary, reducing water reabsorption in the kidneys. This leads to increased urine output (diuresis) and dilute urine with a lower specific gravity.

391- Calculate GFR when glomerular hydrostatic pressure = 60 mmHg, Bowman capsule hydrostatic pressure = 12 mmHg, and capillary oncotic pressure = 32 mmHg.
A- 18
B- 48
C- 112
D- 92
E- 84
Ans: A

Explanation:
- Glomerular hydrostatic pressure = 60 mmHg
- Bowman's capsule hydrostatic pressure = 12 mmHg
- Capillary oncotic pressure = 32 mmHg

GFR =(Pgc- Pbs)- (πgc- πbs)
=(60- 12)- (30- 0)
=(48- 30)
=18

392- A patient presents with shortness of breath (SOB) and cough. Arterial Blood Gas (ABG) results are: pO_2: 70 mmHg ,pH: 7.35 HCO_3^-: 16 mmol/L and pCO_2: 60 mmHg. Identify the acid-base abnormality:
A- Compensated Metabolic Acidosis
B- Metabolic Alkalosis
C- Respiratory Acidosis
D- Uncompensated Metabolic Acidosis
E- Partial Respiratory Alkalosis
Ans: C

393- A man was taken to the high altitude where after 10 days patient ABG's sample taken which of the condition ABG's show:?
A- Respiratory Alkalosis
B- Metabolic Acidosis
C- Respiratory Acidosis
D- Metabolic Alkalosis
E- Compensated Metabolic Acidosis
Ans: B

Explanation:
- Acutely respiratory alkalosis which is compensated By metabolic acidosis after 10 days

394- Calculate "Filtration rate" with the given values:
- **Capillary hydrostatic pressure 25**
- **Interstitial hydrostatic pressure was in -5**
- **Plasma oncotic pressure 25**
- **Venous oncotic pressure 5**
- **Interstital oncotic pressure 30**
- **Filtration co efficient 15**

A- 110
B- 150
C- 100
D- 500
E- 80
Ans: B

395- Angiotensin II effect:
A- Increase renal blood flow
B- Increase afferent arteriole compliance
C- Increase efferent arteriole compliance
D- Increased Na absorption in PCT
E- Increased Na absorption in DCT
Ans: D

396- Athlete ran a marathon at 90F.He drank distilled Water. After sweating. What happened at the end of race?
A- Decreased ECF osmolarity
B- Decreased ICF volume
C- Increased total body water(TBW)
D- Decrease ECF volume
E- Increased ICF Osmolarity
Ans: D

397- Urine flow rate 1ml/min lowest osmolarity in which part?
A- Beginning or PCT
B- DCT
C- End of cortical collecting tubule
D- End of cortical papillary collecting duct
E- Tip of loop of Henley
Ans: B

398- A man is a plumber he is having difficulty in breathing from last 1 year he is also short of breath and dyspenic his blood ABGS show PH7.4 HCO3 19 and PCO2 31 he has most likely
A- Metabolic acidosis
B- Metabolic alkalis
C- Compensated metabolic alkalis
D- Compensated metabolic acidosis
E- Mixed metabolic acidosis and alkalosis
Ans: D

CamScanner

399- A patient has following ABGs PH of 7.2, HCO3 levels of 19 and PCO2 of 39 what is likely diagnose is?
A- Metabolic alkalosis
B- Respiratory acidosis
C- Metabolic alkalosis
D- Metabolic acidosis
E- Normal
Ans: D

400- A young patient presents following an accident with no external injuries. The patient is observed to have rapid breathing (tachypnea). Laboratory findings reveal:pCO2: 20 mmHg; HCO3- (bicarbonate): ~20 mEq/L pH: 7.6.What is the most likely acid-base disturbance in this patient?
A- Respiratory acidosis
B- Respiratory alkalosis
C- Metabolic acidosis
D- Metabolic alkalosis
Ans: B

401- A patient present in semiconscious condition with BSR(blood sugar random) 450,PH= 7.2 HCO3=18, and PC02= 40 which is the following is the cause of her condition
A- Retention of Ketone bodies
B- High BSR
C- Hypoglycemia
D- Alkalosis
Ans: A

402- A patient present in emergency department with hypovolemic shock which of the following which conserve the water and Na loss
A- Aldosterone
B- ADH
C- Angiotensin 2
D- Angiotensin I
Ans: A

403- Which renal function is most important for maintaining urine volume
A- Increase renin secretion
B- Increase medullary blood flow
C- Decrease filtration fraction
D- Increase GFR
Ans: D

404- A patient with COPD presents with following ABGs PH 7.23. HCO3 30, PCO2 60 and likely acid base disorder is:
A- Acute respiratory acidosis with compensated HCO3
B- Acute repiratory acidosis with umcompensated renal HCO3
C- Acute respiratory alkalosis with with uncompensated HCO3
D- Metabolic alklosis
E- Metabolic alkalosis
Ans: A

405- 1L N/S was transfused to the normal person what will be change occur : (Medicine Feb 2025)
A- Increase serum osmolarity
B- Decrease serum osmolarity
C- Increase urine osmolarity
D- Decrease urine osmolarity
Ans: D

406- 2L N/S was transfused to dehydrated person what will be changed occur(Medicine Feb 2025)
A- Increase serum osmolarity
B- Decrease serum osmolarity
C- Increase urine osmolarity
D- Increase urinary sodium
Ans: D

407- Difference between PCT and DCT epithelium: (Medicine Feb 2025)
A- PCT forms juxtaglomerular apparatus
B- PCT has thicker basement membrane
C- DCT has thicker BM
D- PCT has more brush border
Ans: D

Explanation:
- The proximal convoluted tubule (PCT) epithelium is characterized by extensive brush borders (microvilli) to increase the surface area for maximum reabsorption of nutrients, electrolytes, and water.
- The distal convoluted tubule (DCT) has fewer microvilli, making the brush border less prominent.
- The juxtaglomerular apparatus is formed by specialized cells of the DCT (not the PCT).
- Basement membrane thickness is not a distinguishing feature between the PCT and DCT.

408- 50 year old woman with normal anion gap acidosis, cause: (Medicine Feb 2025)
A- Diabetic Ketoacidosis
B- Chronic Renal Failure
C- Psychoneurosis
D- Excessive Use of HCO3- Inhibitors
E- Diarrhea
Ans: E

Explanation:
↑ Anion gap
GOLDMARK:
- Glycols (ethylene glycol, propylene glycol)
- Oxoproline (chronic acetaminophen use)
- L- lactate (lactic acidosis)
- D- lactate (exogenous lactic acid)
- Methanol (and other alcohols)
- Aspirin (late effect)
- Renal failure
- Ketones (diabetic, alcoholic, starvation)

Normal anion gap
SHARDS:
- Spironolactone
- Hyperchloremia/Hyperalimentation
- Addison disease, acetazolamide use
- Renal tubular acidosis
- Diarrhea
- Saline infusion

409- Normal Creatinine Clearance/Min: (Medicine Feb 2025)
A- 100-120ml/min
B- 1- 1.5ml/min
C- <50ml/min
D- <15ml/mi
Ans: A

410- Interpret the ABGS with the given values: pH: 7.2 , pCo2:60mmHg, HCO3- : 35mmol/l(Medicine Feb 2025)
A- Acute respiratory acidosis
B- Acute respiratory alkalosis
C- Metabolic acidosis
D- Metabolic alkalosis
Ans: A

411- Normal Creatinine Clearance/Min: (Medicine Feb 2025)
A- 100-120ml/min
B- 1-1.5ml/min
C- <50ml/min
D- <15ml/mi
Ans: A

Explanation:
- Creatinine clearance = × U VP where U = urine concentration of creatinine; V = rate of urine flow in mL/min; P = plasma concentration of creatinine.
- Normal ranges are 90–140 mL/min in men,
- 80–125 mL/min in women.

412- Calculate Anion Gap with the following values: Na=135mEq/L, Cl=5, HCO3=100 pH=7.2(Medicine Feb 2025)
A- 5
B- 10
C- 15
D- 30
Ans: D

Explanation:
The formula to calculate the anion gap is:
Anion gap=Na-(Cl+HCO3)
Given values:
- Na = 135 mEq/L
- Cl = 5 mEq/L
- HCO3 = 100 mEq/L

{Anion Gap} = 135 - (100+5)
{Anion Gap} = 135 -105 = 30
Anion Gap = 30 mEq/L

412- A cross section showed renal cortices with injured glomeruli. Which is the blood supply of these(Medicine Feb 2025)?
A- Interlobular
B- Interlobar
C- Segmental
D- Arcuate
E- Vasa Recta
Ans: A

413- Highest ratio at Distal as compared to proximal in PCT of : (Surgery Feb 2025)
A- Creatinine
B- Sodium
C- Glucose
D- Bicarbonate
E- Phosphate
Ans: A

414- A patient with PH 7.67, PCO2 20 , HCO3 20 disorder is? (Surgery Feb 2025)
A- Metabolic acidosis
B- Respiratory acidosis
C- Metabolic alkalosis
D- Respiratory alkalosis
Ans: D

CamScanner

415- Hyperkalemia associated with which of the following renal mechanism (Surgery Feb 2025)

A- Metabolic acidosis
B- Metabolic alklosis
C- Increase H+ excretion
D- Increase HCO3 excretion
Ans: A

Explanation:

- Hyperkalemia inhibits NH3 synthesis, which produces a decrease in H+ excretion as NH4+(type 4 renal tubular acidosis).
- Hypokalemia stimulates NH3 synthesis,which produces an increase in H+ excretion

416- Effect of Angiotensin II: (Surgery Feb 2025)

A- Vasodilation
B- Constriction of affrerent arterioles of glomerulus
C- Constriction of venules of systemic circulation
D- Renin Release
E- Stimulation of Thirst
Ans: B

417- Structure of renal cortex projecting in medulla called: (Surgery Feb 2025)

A- Medullary cortex
B- Renal column's
C- Vesa recta
D- Papilla
Ans: B

418- Metabolic disorder in excessive vomiting is due to (Surgery Feb 2025)

A- Increase HCO3 levels
B- Decrease HCO3 level
C- Increase CO2 levels
D- Decrease C02 levels
Ans: A

419- Which of the following acid base balance will be present in vomiting(Surgery Feb 2025)

A- Metablic Acidosis
B- Respiratory Acidosis
C- Metabolic Alkalosis
D- Respiratory Alkalosis
Ans: C

420- Which of the following is side effect of loop diuretic(Surgery Feb 2025)

A- Hypoglycemia
B- Hypercalcemia
C- Hyperkelemia
D- Metabolic alkalosis
E- Metabolic acidosis
Ans: D

421- Which of the following determine the total resistance to GFR(Gynae & Obs Feb 2025)

A- Afferent arteriole
B- Efferent arteriole
C- Vasa recta
D- Peritubular capillaries
Ans: A

422- A patient who experienced dehydration was infused with 1000 mL of normal saline (0.9% NaCl). What is the most likely physiological change? (Gynae & Obs Feb 2025)

A- Increase in extracellular fluid (ECF) sodium concentration
B- Increase in intracellular fluid (ICF) volume
C- Increase in urine osmolarity
D- Increase in intracellular fluid (ICF) osmolarity
Ans: A

423- A patient's laboratory results are as follows:

- **Sodium (Na^+): 129 mEq/L**
- **Potassium (K^+): 4.5 mEq/L**
- **Chloride (Cl^-): 107 mEq/L**
- **Bicarbonate (HCO_3^-): 15 mEq/L**

Which of the following is a key characteristic of proteoglycans?(Radiology Feb 2025)

A- No charges
B- Negative charges
C- Neutral charges
D- Positive charges
Ans: B

424- A boy faints during football practice after drinking a large amount of water. Which physiological change likely led to his collapse?(Radiology Feb 2025)

A- Increase in blood osmolality
B- Decrease in intracellular fluid (ICF) tonicity
C- Decrease in extracellular fluid (ECF) tonicity
D- Decrease in plasma volume
E- Decrease in ICF volume
Ans: C

425- Hyperchloremic metabolic acidosis caused by: (Radiology Feb 2025)

A- Acetazolamide
B- Furosemide
C- Thiazide diuretic
D- Spironolactone
Ans: A

426- Which of the following can lead to decreased secretion of concentrated urine? (Anesthesia Feb 2025)

A- Back leak of water into the tubule lumen
B- Increased pressure in the Bowman's capsule
C- Decreased blood pressure in the glomerulus
D- Increased sodium and water reabsorption
Ans: A

CamScanner

RESPIRATORY PHYSIOLOGY QUICK HINTS

Tidal volume (TV) 800ml
- is the volume inspired or expired with each normal breath.

Inspiratory reserve volume (IRV) 3000ml
- is the volume that can be inspired over and above the tidal volume.
- is used during exercise.

Expiratory reserve volume (ERV) 1100ml
- is the volume that can be expired after the expiration of a tidal volume.

Residual volume (RV) 1200ml
- is the volume that remains in the lungs after a maximal expiration.
- cannot be measured by spirometry.

Inspiratory capacity 3500ml
- Sum of tidal volume and IRV.

Functional residual capacity (FRC) 2300ml
- Sum of ERV and RV
- The volume remaining in the lungs after a tidal volume is expired.
- includes the RV so it cannot be measured by spirometry

Vital capacity (VC), or forced vital capacity (FVC) 4600ml
- The sum of tidal volume, IRV, and ERV.
- The volume of air that can be forcibly expired after a maximal inspiration

Total lung capacity (TLC) 5800ml
- The sum of all four lung volumes.
- The volume in the lungs after a maximal inspiration
- Includes RV so it cannot be measured by spirometry.

Surfactant and lung compliance

- Surfactant synthesize by Type 2 alveolar cells and consist of dipalmitoyl phosphatidylcholine
- Surfactant normally decreases surface tension and Increase lung compliance.
- Surfactant deficiency cause increase surface tension and decrease lung compliance
- Increase lung compliance in Emphysema and decrease in fibrosis
- Accelerates maturation of surfactant of lung – Glucocorticoid
- Surfactant maintains – Alveolar integrity

Gas Exchange

Diffusion limited:
- O_2 (Emphysema, Fibrosis & exercise)
- CO

Perfusion limited:
- O_2 (Normal Diffusion)
- CO_2
- N_2O

Dead Space

Pattern of breathing has no effect on dead space but still prefer Shallow breathing > Deep breathing

Increased Dead Space:
- Emphysema , Pneumonia
- ARDS
- Smoking
- ETT intubation
- Bronchitis
- Asthma
- Cardiac Failure
- Pulmonary Embolism
- Neck Extension
- Standing
- Hypotension
- Bronchodilation

Decreased Dead Space:
- Atelectasis
- Tracheostomy
- Sleep
- Maxillectomy
- Hyperventilation
- Neck Flexion
- Supine Position
- Bronchoconstriction

Respiratory system changes in elderly

Increase
- Lung compliance
- RV
- V/Q mismatch
- A-a gradient

Decrease
- Chest wall compliance
- FVC and FEV1
- Respiratory muscle strength
- Ventilatory response to hypoxia / hypercapnia

Hb-O2 Curve

- 100% saturation – 100mmHg(Arterial blood)
- 75% saturation – 40mmHg(Venous blood)
- 50% saturation – 25mmHg

Right Shift:

Right shift mean Decrease affinity for O_2 and increase delivery to tissue **(Bohar effect)** thus increase P50.

Causes:
- Increase CO_2
- Decrease PH
- Increase Temperature
- Increase 2, 3 DPG

Left Shift:

Left shift mean Increase affinity for O_2 and decrease delivery to tissue **(Haldane effect)** thus decrease P50

Causes:
- CO poisoning
- Decrease CO_2

CamScanner

- Increase PH
- Decrease Temperature
- Decrease 2, 3 DPG
- HbF

CO2 transport

- Dissolved CO2 small amount
- Carbaminohemoglobin small amount
- **HCO3 major form**
- Chloride Shift occur by – **Band 3**
- Venous Blood have more – **HCO3 & PCV(PCV >HCO3)**
- RBC Venous Blood Have more – **Chloride Ions**

Pulmonary blood flow and V/Q

- ✓ Pulmonary Blood flow and Ventilation Highest at -- **Base**
- ✓ Pulmonary Blood flow and Ventilation Lowest at – **Apex**
- ✓ V/Q and Arterial PO2 Highest at – **Apex**
- ✓ V/Q and Arterial PO2 Lowest at – **Base**
- ✓ Pulmonary Vasoconstriction **Caused By – Hypoxia**
- ✓ Pulmonary Vasoconstriction **Accentuated by – Increase CO2**
- ✓ Erythropoietin Produced By – **Hypoxia**
- ✓ Erythropoietin Inhibited By – **Theophylline**
- ✓ O2 100 Percent in -- **L-R Shunt**

In Airway Obstruction

1-V/Q is Less than Normal (Guyton) called R-L Shunt
2-Composition of Systemic arterial blood approaches Mixed Venous Blood
3-Increase A-a Gradient

In Pulmonary Embolism

1-V/Q is Infinite Called Dead Space
2-Composition of Alveolar Air approaches Inspired Air

Increase A-a Gradient Seen in

1-Fibrosis
2-V/Q Defect
3-R-L Shunt

- A-a Gradient Normal Value – 0 -10mmhg
- A/a Ratio Normal – 0.8 (> 0.75)

At High Altitude

1-Survival due to – Increase Hb Concentration
2-Pulmonary Vasoconstriction (Due to Hypoxia)
3- Hb-O2 Curve Shift to Right
4- Increase 2,3 DPG Concentration
5-Hyperventilation due to hypoxemia and result in respiratory alkalosis(Increase arterial PH)

Exercise Increase

1-O2 Consumption
2-CO2 Production
3-Increase ventilation rate
4-Increase venous PCO2 and pulmonary blood flow(Cardiac output)
5-PH unchanged during moderate and decrease in severe exercise(Lactic acidosis)

Chemoreceptors

Central Chemoreceptor Respond to(Sequence wise)

1-Decrease CSF PH or Interstitial PH (Increase H ions)
2-Increase PCO2 in Arterial Blood

Peripheral Chemoreceptor(Carotid and Aortic body) Respond to

1-Decrease O2
2-Increase PCO2 in arterial blood
3-Decrease Arterial PH (Increase arterial H ions)

Obstructive vs Restrictive

Feature	Obstructive disease (Asthma & COPD)	Restrictive Disease (Fibrosis)
FEV1	Decrease++	Decrease+
FVC	Decrease+	Decrease++
FEV1/FVC	Decrease	Normal or Increase
FRC	Increase	Decrease

Breathing regulation

1) **Medullary respiratory centre located in reticular formation**

A) **Dorsal respiratory group**

- It is primarily responsible for inspiration and generates the basic rhythm for breathing.

B) **Ventral respiratory group**

- It is primarily responsible for expiration and not active during normal, quiet breathing, when expiration is passive and active in exercise

2) **Apneustic center**

- Is located in the lower pons.
- It stimulates inspiration, producing a deep and prolonged inspiratory gasp (apneusis).

3) **Pneumotaxic center**

- It is located in the upper pons.
- It inhibits inspiration and, therefore, regulates inspiratory volume and respiratory rate.

Random

- Fetal respiratory movements start at – 12 weeks
- Lungs kept dry by – Osmotic pressure in interstitium
- Lung expands due to – Negative pressure
- Normal interstitial pressure: -3 to -5
- Physiological dead space – 150ml
- A-a Gradient Normal Value – 0 -10mmhg
- A/a Ratio Normal – 0.8(>0.75)
- Normal ratio of physiological and anatomical dead space- 1:1
- Most common cause of Acute cor pulmonale – Pulmonary embolism
- Most common cause of chronic cor pulmonale - Embolism
- Neagitive intrapleural pressure is maintain by – Lymphatic drainage of pleura
- Blood is warm at 37 'C for massive transfusion to cause - L-R shift and to avoid R-L shift as high temperature causes right shift.
- Cells present in between inter alveolar septum – Macrophages
- Bronchopulmonary segment are aerated by – Tertiary bronchioles

CamScanner

- FEV1 / FVC ration less than 75% is seen in – Asthma
- Most common fetal response to hypoxia - Bradycardia
- Compensating mechanism in accimilization to altitude – Hyperventilation , Respiratory alkalosis
- Features of accimilization – increase diffusion capacity of lung , polycythemia , increase pulmonary ventilation,pulmonary vasoconstriction
- Cyanosis not seen in – Anemic hypoxia
- Oxygen affinity increase by – Hypothermia , Increase HbF, Alkalosis
- Oxygen affinity not increased by – Hypoxia
- Increase airway resistance causes – Increasesin residual volume
- Hb binds with ferric form of iron – HbM
- Doesn't effect respiratory system – Na
- Exercise Increase - O2 Consumption , CO2 Production
- Tidal volume should be given to Anesthetized individual – Twice than normal
- Air-blood barrier in the lungs consists of - Alveolar type I cells
- Most common cause of physiological hypoxemia – Hypoventilation
- Air humidity in OT – 55%

RESPIRATORY PHYSIOLOGY

1- Person is in Progressive shock and his compensatory mechanisms have failed, what type of acid base imbalance will be present in him?

A- Metabolic acidosis with respiratory alkalosis
B- Metabolic Alkalosis with respiratory acidosis
C- Metabolic acidosis with respiratory acidosis
D- Metabolic acidosis
E- Metabolic alkalosis

Ans: C

Explanation:

- In shock usually Metabolic acidosis occur which is compensated by Respiratory alkalosis
- But in Decompensated progressive shock in which compensatory mechanism fail then it will lead to Metabolic acidosis with respiratory acidosis
- In shock reverse phenomenon – Metabolic acidosis with Respiratory Alkalosis
- In Decompensated shock where reverse phenomenon fail – Metabolic acidosis with Respiratory acidosis

2- A 49 year old man has a pulmonary embolism that completely blocks blood flow to his left lung. As a result which of the following will occur?

A- Ventilation /perfusion ratio in the left lung will be zero.
B- Systemic arterial PO2 will be elevated
C- V/Q ratio in the left lung will be lower than right lung
D- Alveolar PO2 in the left lung will be approximately equal to the po2 in the inspired air
E- Alveolar PO2 in the right lung will be approximately equal to the po2 in venous blood

Ans: D (BRS)

Explanation:

In Airway Obstruction

- V/Q is Less than Normal (Guyton) called R-L Shunt
- Composition of Systemic arterial blood approaches Mixed Venous Blood
- Increase A-a Gradient

In Pulmonary Embolism

- V/Q is infinite or increase called dead space
- Composition of alveolar air approaches inspired air

3- Tb is transmitted by:

A- Inhalational aerosol
B- Sexual
C- Blood transfusion
D- Needle
E- Transplant

Ans: A

4- A patient breathing in decompressed chamber where the barometric pressure is 275mmHg (27000 altitudes, 1/3 atmospheric). The oxygen saturation will be?

A- 20
B- 40
C- 60
D- 80
E- 100

Ans: A

Explanation:

- O2 content = PO2/atm
- Normal PO2 in atm=160mmhg
- Here 1/3rd so 160/3=53
- Oxygen content of blood= 53/250 = 0.21
- 0.21x100 =21 %

5- Blood is warmed at 37 'C for massive transfusion to cause:

A- To decrease infection
B- To avoid reaction
C- To decrease O2 affinity
D- L-R shift

Ans: D

Explanation:

To cause L-R shift and to avoid R-L shift as high temperature causes right shift.

6- Which of following has max diffusion capacity?

A- CO
B- NO
C- CO2
D- Nitrogen
E- Hydrogen

Ans: C

Explanation:

- CO Used to measure diffusion
- CO_2 has max diffusion capacity

7- Majority part of blood CO_2 in the form of:

A- Carbaminohemoglobin
B- HCO_3
C- Dissolved form
D- H_2CO form

Ans: B

CamScanner

Explanation:

CO_2S transported from tissues to lungs in 3 forms:

- HCO_3 (70%)
- Carboxyhemoglobin or HbCO2 (21–25%) Co2 bound to Hb at-terminus of globin (not heme). CO_2 favors deoxygened form 2 unloaded).
- Dissolved CO (5–9%).

8- V/Q ratio pulmonary embolism would be:

A- Zero
B- Increased
C- Decreased
D- Infinity
E- Variable
Ans: D (BRS + Guyton)

9- V/Q decrease in which of following?

A- Dead space
B- Airway Obstruction
C- Embolism
D- Low Blood flow
E- Shunt
Ans: B (BRS)

10- What is the function of dead space?

A- Exchange of gases
B- Blockage of gases
C- Conditioning of air
D- Increase While Standing
E- Increase with age
Ans: C

11- FEV1/FVC increase in which of following?

A- Asthma
B- COPD
C- Obstructive Disease
D- Restrictive Disease
E- Emphysema
Ans: D

Explanation:

Feature	Obstructive disease (Asthma & COPD)	Restrictive Disease (Fibrosis)
FEV1	Decrease++	Decrease+
FVC	Decrease+	Decrease++
FEV1/ FVC	Decrease	Normal or Increase
FRC	Increase	Decrease

12- Extreme left shift of Hb-O2 curve is due to which of Following

A- Hb F
B- CO poisoning
C- Decrease pH
D- Increase 2-3 DPG
E- Increase CO2
Ans: B

13- Parameter that differentiate between obstructive lung disease and restrictive lung disease:

A- FEV1/FVC
B- Lung volume
C- FEV
D- RV
E- VC
Ans: A

14- Inspiratory ramp signals are produced from dorsal respiratory neurons their rate increases in response to impulses from:

A- Stretch receptors in lung
B- Pneumotaxic centre in pons
C- Apneustic centre
D- Mid brain
E- Pons
Ans: B

15- Inspiratory capacity is related to:

A- IRV + TV
B- ERV + TV
C- IRV
D- ERV+IRV
E- TV+IRV+ERV
Ans: A (BRS)

16- Which of following is higher at apex of lung then base?

A- Ventilation
B- V/Q ratio
C- Blood flow
D- Venous O2
Ans: B

Explanation:

- Pulmonary Blood flow and Ventilation Highest at – Base
- Pulmonary Blood flow and Ventilation Lowest at – Apex
- V/Q and Arterial PO2 Highest at – Apex
- V/Q and Arterial PO2 Lowest at – Base

17- Patient ascends to high altitude has increase breathing due to:

A- Decrease arterial PO_2
B- Decrease in CSF PH
C- Respiratory alkalosis
D- Increase Nitrogen
Ans: A (BRS)

Explanation:

At high Altitude decrease Alveolar PO2 And Arterial PO2 (Hypoxemia) result in increased breathing rate that cause Respiratory alkalosis

18- Hyperventilation occurs due to which of the following?

A- Increase PO2
B- Decrease PO2
C- Decrease CO2
D- Increase HCO3
Ans: B

Explanation:

Decrease O2 lead to increase CO2 which result in Hyperventilation to eliminate excess CO2.

19- Which of following Cells present in between inter alveolar septum?

A- Macrophages
B- Clara cells
C- Stellate cells
D- Alveolar cells
E- Goblet cells
Ans: A

20- In zone 1 of the lung what happens?

A- Dead space low
B- Dead space high
C- Shunting high
D- Shunting low
Ans: B (BRS)

Explanation:

In Zone 1 Alveolar pressure is high which compress capillaries and reduce blood flow thus low blood flow with normal ventilation in Zone 1result in High dead space.

21- During Acclimatization at high altitude, following changes will occur:

A- Increase PO2
B- Acidosis
C- Increase in pulmonary ventilation
D- Pulmonary vaso dilatation
E- Decrease Erythropoietin Secretion
Ans: C

22- HB dissociation curve shift to left in which of following Condition?

A- Hyperthermia
B- Hypothermia
C- Decrease PH
D- Increase CO_2
E- Increase H ions
Ans: B

23- Normal A/a ratio is:

A- 0.1
B- 0.65
C- 0.45
D- 0.8
Ans: D (BRS)

Explanation:

- A-a Gradient Normal Value – 0 -10mmhg
- A/a Ratio Normal – 0.8(>0.75)

24- Female develops cough after decrease temperature below freezing point what receptor activated?

A- Peripheral chemoreceptor
B- Central chemoreceptor
C- Irritant receptor
D- J receptor
E- Stretch receptor in lungs
Ans: C

25- Surfactant is produced by:

A- Type 1 pneumocytes
B- Type 2 pneumocytes
C- Clara cells
D- Goblet cells
Ans: B

26- Peak expiratory flow measured:

A- Small airway density
B- Lung Elasticity
C- Predicted value of FEV1 and assess large airway Caliber
D- Stiffness of lung
Ans: C

27- The effect of oxygenation on carboxyhemoglobin is by:

A- Haldane effect
B- Bohr effect
C- Fick law
D- Le chatelier
E- Laplace law
Ans: D

28- Posture is maintained during moderate exercise occurs through:

A- Increased HR
B- Increased venous return
C- Proprioception
D- Rubrospinal tract
E- Decrease pulse
Ans: C

29- Player hiked to mountain, having Low PO2 and developed dyspnea the likely etiology is:

A- Anemic hypoxia
B- Hypoxic hypoxia
C- Decrease Erythropoietin
D- Stagnant Hypoxia
E- Decrease Perfusion
Ans: B

Explanation:

Hypoxic Hypoxia (Decrease O2 tension)

- High altitude
- V/Q mismatch

Anemic Hypoxia (Decrease O2 Carrying)

- Anemia
- CO Poisoning

Stagnant Hypoxia (Low Perfusion)

- Heart failure
- Shock

Histotoxic Hypoxia (Not Able to use O2)

- Cyanide poison

CamScanner

30- Which of the following is detected by peripheral chemoreceptors?
A- Decrease PaO2
B- Increase PaO2
C- CSF PH
D- Arterial CO2
E- Low CO2
Ans: A (BRS)

Explanation:
- **Central Chemoreceptor Respond to (Sequence wise)**

1- CSF PH or Interstitial PH (Increase H ions)
2- Increase CO2 In Arterial Blood

- **Peripheral Chemoreceptor (Carotid and Aortic body) Respond to**

1- Decrease O2
2- Arterial PH (H ions)

31- Patient presented with Fatigue, Dizziness with low Hb and Difficulty in breathing and Diagnosed as Anemic hypoxia which of following statement is true?
A- Not responsive to oxygen therapy
B- Corrected by Platelets
C- Responaive to antibiotics
D- Responsive to Prolong oxygen
Ans: A

32- A lab boy giving demonstration on pulmonary function test He inspires and then forceful expired. Which of following is used for forceful expiration?
A- Diaphragm
B- External Intercostal
C- Elastic recoil
D- Rectus Abdominus
E- Seratous anterior
Ans: D

33- Pressure volume relation of lung shows change in volume per change in pressure this demonstrates which of the following function in lung when volume does not change with change in pressure?
A- FRC
B- Vital Capacity
C- Tidal Volume
D- ERV
E- Lung Compliance
Ans: E

34- VD/VT ratio of Pa oxygen 45mmHg, mixed expired carbon dioxide 30mmHg is
A- 0.2
B- 0.3
C- 0.1
D- 0.4
E- 0.5
Ans: B

35- A group of students were studying difference between PO2 and PCO2 in different arteries of the body. They find major differences between.
A- Aorta and Pulmonary Artery
B- Skeletal muscle arteriole and venule
C- Aorta and Left ventricle
D- Right and Left Ventricle
E- Aorta and Superior Vena cava
Ans: A

36- With increasing age what will decrease?
A- Residual volume
B- Vital capacity
C- Pulse pressure
D- Mean blood pressure
E- Urine output
Ans: B

Explanation:
Respiratory system changes in elderly
Increase
- Lung compliance
- RV
- V/Q mismatch
- A-a gradient

Decrease
- Chest wall compliance
- FVC and FEV1
- Respiratory muscle strength
- Ventilatory response to hypoxia / hypercapnia

37- Lactic acid injection was given to the patient through IV line. The patient respiratory rate increase due to:
A- Chemoreceptor in medulla
B- Aortic baroreceptor
C- Carotid body
D- Dorsal respiratory group
Ans: A

38- Hypoxia causes vasoconstriction instead of vasodilation in which of the following?
A- Heart
B- Peripheral vasoconstriction
C- Lung
D- Kidney
E- Central vasoconstriction
Ans: C

39- Which of the following change occur from sea level to 12000 feet high resident?
A- Right atrial hypertrophy
B- Right ventricular hypertrophy
C- Left ventricular hypertrophy
D- Fall of p50
E- Left shift of oxyhemoglobin dissociation curve
Ans: B

40- Group of neurons that are inactive normally is activated in medulla by increased breathing during exercise:
A- Dorsal
B- Ventral
C- Apneustic
D- Pneumotaxic
E- Chemoreceptor
Ans: B (BRS)

Explanation:
Medullary respiratory center located in reticular formation
Dorsal respiratory group:
- It is primarily responsible for inspiration and generates the basic rhythm for breathing
- Input to the dorsal respiratory group comes from the vagus and glossopharyngeal nerves. The vagus nerve relays information from peripheral chemoreceptors and mechanoreceptors in the lung. The glossopharyngeal nerve relays information from peripheral chemoreceptors
- Output from the dorsal respiratory group travels, via the phrenic nerve, to the diaphragm.

Ventral respiratory group
- It is primarily responsible for expiration and not active during normal, quiet breathing, when expiration is passive
- It is activated for example during exercise, when expiration becomes an active process.

Apneustic center
- is located in the lower pons.
- It stimulates inspiration, producing a deep and prolonged inspiratory gasp (apneusis).

Pneumotaxic center
- It is located in the upper pons.
- It inhibits inspiration and, therefore, regulates inspiratory volume and respiratory rate.

41- In obstructive lung disease, which capacity increases?
A- FRC
B- Vital capacity
C- ERV
D- Tidal volume
E- TLC
Ans: A(BRS)

42- Peripheral chemoreceptors are stimulated by?
A- Increase pCO2
B- Increase H+
C- Decrease O2
D- Decrease PCO2
E- Decrease PH
Ans: C

43- Expiration is carried out with the help of
A- Diaphragm
B- Lung recoil
C- External intercoastal
D- Abdominal muscles
Ans: B

Explanation:
- Quite Expiration – Passive and by Elastic Recoil of Lung
- Muscle of Forced Inspiration – SCM & Serratous Anterior
- Muscle of Forced Expiration -- Internal Intercostal
- Accessory Muscle of Expiration – External Oblique

44- Patient at height dead space of one third of tidal volume. PCO2 of venous blood is 45 what will be EtCO2:
A- 30
B- 40
C- 25
D- 60
Ans: A

45- Regarding bronchopulmonary segment they are aerated by
A- Primary bronchi
B- Secondary bronchi
C- Alveoli
D- Tertiary bronchioles
Ans: D

46- Amount of O2 delivery in 70kg man during delivery in anasthesia
A- 100ml/ min
B- 150ml /min
C- 200 ml / min
D- 250 ml / min
Ans: D

47- Normal atmospheric pressure
A- 760mmhg
B- 500cm oh H2O
C- 760cmhg
D- 0atm
Ans: A

48- The volume which is inhaled maximum then exhaled
A- Vital capacity
B- FEV
C- peak flow
D- Total lung capacity
E- Residual volume
Ans: A

CamScanner

301- A girl presented with persistent cough with thick mucus, wheezing and Repeated lung infections. She is also having petechia all over body and have bleeding tendency. She is diagnosed with cystic fibrosis. Which Vit is deficient in this case?

A- Vitamin A
B- Vitamin k
C- Vitamin D
D- Vitamin C
Ans: B

302- Liver regenerates after partial hepatectomy in how many days:

A- 5-7 Days
B- 6-15 Days
C- 14-21 Days
D- 4-6 Weeks
Ans: A

303- Boy ate street food after which he developed Nausea, Vomiting, Scleral icterus & Jaundice. Which of the following is responsible for this presentation?

A- Hepatitis B
B- Hepatitis A
C- Hepatitis E
D- Hepatitis D
Ans: B

304- A patient with history of chronic foul smelling diarrhea with no history of abdominal pain, no occult bleeding. On stool DR, fatty stools. Biopsy shows villous atrophy, lymphocytes and crypt hyperplasia.What will you advise to the patient?

A- Corticosteroids
B- Antibiotics
C- Gluten free diet
D- Surgery
Ans: C

305- A person presents with abdominal pain for 2 months. On investigations there is a mass in duodenum that is found to be arising from submucosa Which of the following is secreted by this part of duodenum from where mass is arising.

A- Lactase
B- Peptidase
C- Acidic Mucus
D- Urogastrone
E- Gastrin
Ans: D

Explanation:
Brunner gland located in submucosa of duodenum secrete alkaline mucus and urogastrone.

306- An old man with liver mass, HbsAg positive & raised AFP 1000, He might be having?

A- Hepatitis
B- Hepatocellular carcinoma
C- Lymphoma
D- Thymoma
Ans: B

better

307- In alcohlic Patient Steatohepatitis develops due to:

A- Acetate
B- Cholesterol
C- Fatty acids
D- Phospholipid
Ans: C

308- Which of the following vitamin is deficient in chronic pancreatitis?

A- B12
B- B7
C- Vitamin D
D- Vitamin C
E- Thiamine
Ans: C

309- Child having meckel diverticulum is having bleeding per rectum due to:

A- Volvulus
B- Chronic inflammation
C- Ectopic gastric tissue
D- Jejunum
E- Cecum
Ans: C

Explanation:
Rule of 2

- Seen commonly in under 2 year
- 2% Population
- 2Feet proximal to illiocecal valve
- 2 inches long
- 2 types of mucosa (**Ectopic gastric mucosa** which usually bleed and **Pancreatic mucosa**(May cause bleed). These two mucosa are important histological feature of Meckel diverticulum

310- In an adult ileostomy and jejunectomy has been done. He has diarrhea and 15-20 bowel sounds per minute. The most likely cause of this decreased transit time is:

A- Secretory diarrhea
B- Osmotic diarrhea
C- Secretory+Osmotic diarrhea
D- High concentration of Bile Salts in the colon
Ans: C

Explanation:

- **Colostomy** Results in **Secretory** Diarrhea
- **Jejunostomy** Result in **Osmotic** Diarrhea
- **illeostomy** Result in **Osmotic** Diarrhea
- **Jejunostomy+illeostomy** Result in **Secretory+Osmotic** Diarrhea

311- A patient with acute diarrhea has serum Cl = 112, sodium 131, Potassium 2.5, anion gap 10, what is the most likely type of metabolic acidosis?

A- Hypochloremic metabolic acidosis with a normal anion gap
B- Hypochloremic metabolic acidosis with an increased anion gap
C- Hyperchloremic metabolic acidosis with a normal anion gap
D- Hyperchloremic metabolic acidosis with an increased anion gap
Ans: C

312- A patient with abdominal pain has been taking 10 tablets of paracetamol (500 mg each), along with aspirin and other NSAIDs. Considering the potential effects of these medications, which investigation should be ordered first?

A- Liver Function Tests
B- Urea, Creatinine, & Electrolytes
C- CT Scan of the Abdomen
D- Ultrasound of the Abdomen
Ans: A

313- Patient came with a brain lesion and there is formation of ring seen in peripheral cornea on investigation what will be seen

A- Increase Serum Ceruloplasmin in blood
B- Increase serum ceruloplasmin in urine
C- Decrease copper in blood
D- Decrease Serum Ceruloplasmin in blood
Ans: D

314- In a patient with cirrhosis who presents with acquired bleeding abnormalities, which of the following laboratory findings is most consistent with the condition?

A- Prolonged bleeding time
B- Prolonged prothrombin time
C- Prolonged activated partial thromboplastin time
D- Decreased albumin
E- Normal clotting time
Ans: B

315- 30 years old female patient presented with Nausea, vomiting and gastric upset for 5 days. Biopsy of stomach shows lymphocytes neutrophils, macrophages, plasma cells but no ulceration. What is the most probable diagnosis?

A- H pylori
B- Staph aureus septicemia
C- Tb
D- Gastric Ca
E- Gastritis
Ans: A

316- Liver cirrhosis patient with coagulopathy, transfusion before surgery by which fluid?

A. Lymphocyte removed full blood
B. FFP
C. Cryoprecipitate
D. Albumin
Ans: B

317- A patient presents with pain in the right hypochondrium that worsens over time after eating. The pain is aggravated by palpation in the right hypochondrium, and the patient tends to hold their breath during palpation. What is the most likely diagnosis?

A- Acute pancreatitis
B- Acute cholecystitis
C- Cholelithiasis
D- Appendicitis
Ans: B

318- Location of Chylomicrons in liver:

A- Cholangiole
B- Space of disse
C- Sinusoids
D- Herring canal
Ans: B

319- Which of the following plays a mitogenic role in regeneration in early stages after partial hepatectomy:

A- EDGF
B- Hepatocyte growth factor
C- PDGF
D- methionine related drugs
E- TGF-alpha
Ans: B

320- 19 years old child presented with scleral icterus & pale stools. Investigations reveal Decreased Haptoglobin, Total Bilirubin 3.5 Indirect Bilirubin 2.8. Diagnosis?

A- Rotor Syndrome
B- Hereditary Spherocytosis
C- Gilbert Syndrome
D- Dubin Johnson Syndrome
E- Crigler Najjar Syndrome
Ans: B

49- In patient of drowning who is alive following will be found
A- Pulmonary edema
B- Respiratory acidosis
C- Respiratory alkalosis
D- Metabolic acidosis
Ans: D

50- In case of carbon monoxide poisoning why hypercapnia?
A- Retained CO2
B- Normal PO2
C- Decrese PO2
D- Increase PO2
Ans: B

51- Lung volume remains in the lungs after normal expiration:
A- FRC
B- TV
C- RV
D- FLC
Ans: A

52- Mixed blood obtained from:
A- Right atrium
B- Right ventricular
C- Pulmonary vein
D- Pulmonary artery
Ans: D

53- Lung expands due to
A- Chest wall
B- Tracheal air pressure
C- Diaphragm
D- Negative pressure
Ans: D

54- Right Shift of O2 dissociation curve is due to:
A- Increase PH
B- Decrease PH
C- Decrease CO2
D- Decrease Temperature
Ans: B (BRS)

55- Most common feature of pulmonary embolism
A- Clinically silent
B- Pulmonary hypertension
C- sudden death
D- None
Ans: A

56- FEV1 / FVC ratio less than 75% is seen in
A- Bronchitis
B- Pulmonary embolism
C- Asthma
D- Hypertension
Ans: C

57- Which of the following causes patchy atelectasis
A- Loss of water
B- Decrease surfactant
C- Increase surfactant
D- Increase membrane
Ans: B

58- Which one is diffusion limited gas?
A- CO2
B- CO
C- NO
D- N2O
Ans: B (BRS)
Explanation:
Diffusion limited:
- O2 (Emphysema, Fibrosis & exercise)
- CO

Perfusion limited:
- O2 (Normal Diffusion)
- CO2
- N2O

59- Which of the following is common to pulmonary and skeletal blood vessels?
A- Protein permeability
B- Hydrostatic pressure
C- Oncotic pressure
D- Colloid osmotic pressure
Ans: A

60- Pulmonary artery supply:
A- Bronchioles
B- Terminal Bronchiolee
C- Alveoli
D- None
Ans: C
Explanation:
- Plumonary artery supplies – Alveoli
- Left bronchus supplied by – bronchial branches from descending thoracic aorta
- Right bronchus from 3rd post intercostal artery arises from thoracic aorta.

61- In pregnancy respiratory volume increases, which hormone is responsible for that?
A- Estrogen
B- Progesterone
C- Prolactin
D- Thyroid
E- Oxytocin
Ans: B

62- Which of the following is Lactic acid Oxygen debt
A- 3 liters
B- 2.5 liters
C- 2 liters
D- 3.5 liters
E- 8L
Ans: E

Explanation:
- Lactic acid Oxygen Debt – 8L
- Alactoid Oxygen Debt -3.5L

63- Damage to which part of brain will result in central cease of respiration
A- Medulla
B- pons
C- Midbrain
D- Cereberum
E- Cerebellum
Ans: A

64- Diffusion capacity of O2
A- Less than N2
B- More than CO2
C- Decreases in exercise
D- Decrease in lung fibrosis
Ans: D

65- Which if the following will not affect respiration
A- HCO3
B- CO2
C- Na+
D- H+
Ans: C

66- CO2 transport is example of:
A- Positive Feed back
B- Negative Feed back
C- Peripheral receptor
D- None
Ans: B
Explanation:
Positive Feedback
- Child Birth
- Blood clotting

Negative feed back
- CO2 transport
- Control of optimal internal environment
- Regulation of Hormones

67- TLC 6 litre Residual volume 1, calculate the vital capacity
A- 4L
B- 5L
C- 6L
D- 7L
Ans: B
Explanation:
- Vital capacity = TLC - Residual volume
- 6-1 =5

68- Error in reading of pulse oximtere is due to
A- Dark skin
B- Methemoglobimemia
C- Light
D- High CO2
Ans: B

69- Mucous gland absent in:
A- Terminal Bronchioles
B- Alveoli
C- Tertiary Bronchus
D- All of the above
Ans: A

70- Woman was cycling and Reached a height where atmospheric pressure was 700mmHg. Regarding Gases which of Following is true:
A- PaO2 110 and Nitrogen 583
B- PaO2 147 and Nitrogen 553
C- PaO2 92 and Nitrogen 608
D- PaO2 100 and nitrogen 703
Ans: B
Explanation:
- O2 - 0.21*700=147
- N2 - 0.78*700 =553

71- Goblet cells in respiratory tract are present up to:
A- Trachea
B- Primary Bronchus
C- Secondary Bronchus
D- Bronchi
E- Terminal Bronchioles
Ans: D (First Aid)
Explanation:
Goblet cells Present up to Bronchi or tertiary Bronchus and Clara cells in Terminal Bronchioles.

72- V/Q increase in:
A- Dead space
B- Inadequate ventilation
C- Increase perfusion
D- Decrease perfusion
Ans: A

73- Energy used in respiration:
A- 5%
B- 10%
C- 8%
D- 10%
Ans: A (2-5% , Prefer 2%)

74- T taut form of Hb decrease affinity for:
A- CO2
B- CO
C- N2
D- Oxygen
Ans: D

75- Regarding alveoli
A- Surfuctant avoid collapse of alveoli
B- Produce by type 1 pneumocytes
C- Dec compliance
D- Surfuctant increase surface tension
Ans: A

CamScanner

76- What are parasympathetic effects on lungs
A- Increase compliance
B- Increase restrictive work
C- Increase physiological dead space
D- Increase elastic work
Ans: B

77- True about Rodford nomogram
A- Measure tidal volume
B- Measure cardiac output
C- Measure residual volume
D- Measure TLC
Ans: A

78- Diffusion is directly proportional to increased:
A- Surface area
B- Resistance
C- Viscosity
D- Velocity
Ans: A

79- Diffusion capacity of pulmonary capillary increases in:
A- Asthma
B- Pulmonary edema
C- Polycythemia
D- Fibrosis
E- CCF
Ans: C>A

80- Decrease arterial oxygen tension in
A- Decrease HB
B- CO poising
C- Decrease atmospheric oxygen
D- Anemia
Ans: C

81- Exchange of gases from alveoli to blood:
A- Simple diffusion
B- Passive diffusion
C- Facilitated diffusion
D- Pinocytosis
Ans: A

82- O2 saturation at sea level in a young adult is:
A- 100%
B- 80%
C- 97%
D- 94
Ans: C

83- Which hormone is inactivated by lungs?
A- Vasopressin
B- Serotonin
C- Angiotensin
D- GABA
Ans: B (Ganong)

84- What prevents collapse of lung?
A- Residual volume
B- Vital capacity
C- IRV
D- Tidal volume
Ans: A

85- Normal inspiratory capacity
A- 3500 ml
B- 2300 ml
C- 4600 ml
D- 5800 ml
Ans: A

Explanation:
- Inspiratory reserve volume - 3000 ml
- Tidal volume - 800 ml
- Expiratory reserve volume - 1100 ml
- Redidual volume - 1200 ml
- Inspiratory capacity - 3500 ml
- Functional residual capacity - 2300 ml
- Vital capacity - 4600 ml
- Total lung capacity - 5800 ml

86- Increased in PCO2 in non-anesthetized patient in first minute of apnea:
A- 12mmHg
B- 8mmHg
C- 6mmHg
D- 4mmHg
Ans: C

Explanation:
- Non Anesthetize – 6mmHg
- Anesthetize – 12mmHg

87- Posteriorly inferior limit of lung which we called posterior inferior lobe is at level of:
A- T10
B- T11
C- T12
D- T7
Ans: A

88- Vascularity in lung is seen in which phase?
A- Canalicular
B- Alveolar
C- Pseudocanalicular
D- none
Ans: A

89- Terminal bronchiole doesn't have cartilage this feature differentiates it from:
A- Conducting bronchiole
B- Respiratory bronchiole
C- Alveolar duct
D- Trachea
Ans: D

90- Lipid bilayer of cell membrane is highly soluble for:
A- CO_2
B- Glucose
C- Urea
D- Na
Ans: A

Explanation:
Only small uncharged molecules can diffuse freely through phospholipid bilayers (Small nonpolar molecules, such as O2 and CO2, are soluble in the lipid bilayer and therefore can readily cross cell membranes.

91- Patient after having accident and blood loss bicarb 18 O2 curve dissociate to right due to decrease in:
A- 2 3 BPG
B- PH
C- Temperature
D- HBF
Ans: B

92- Patient having decrease PO_2 due to which?
A- Hypoxic hypoxia
B- Anemic hypoxia
C- Cyanide
D- Cardiogenic shock
Ans: A

93- Example of positive feedback mechanism:
A- Child birth
B- Vicious cycle leading to death
C- CO_2 transport
D- Pathway to bring cellular environment back to normal.
Ans: A

94- Compliance is defined as:
A- Change in volume per unit Change in flow
B- Change in volume per unit Change in pressure
C- Change in volume per unit change in resistance
D- Tendency for lungs to collapse inward and chest wall outward
Ans: B

95- Increase compliance in
A- Emphysema
B- Pulmonary fibrosis
C- Pneumonia
D- ARDS
E- Pulmonary edema
Ans: A

Explanation:
Increase compliance
- Emphysema
- Aging

Decrease compliance
- Pulmonary fibrosis
- Pneumonia
- ARDS
- Pulmonary edema

96- Which one is activated in lung?
A- Angiotensin 2
B- Angiotensin 1
C- Serotonin
D- Bradykinin
Ans: A (Ganong)

Explanation:
- Angiotenin 2 is activated form mean already active while angiotensin 1 in inactive form which is converted to 2 in Lung.
- For convertion angiotensin 1.
- Activated in lung – Angiotensin 2.

97- Bradykinin release from lungs will act on which vessel?
A- Internal iliac
B- Ductus arteriosus
C- Umblical
D- External iliac
Ans: B

98- Torr is a unit of:
A- Length
B- Weight
C- Pressure
D- Power
Ans: C

99- While performing bronchoscopy first structure visualized beyond carina is?
A- Upper lobe bronchus
B- Superior segmental bronchus
C- Apical bronchus
D- Middle lobe bronchus
E- Inferior lobe bronchus
Ans: A

100- Single breath nitrogen test is used to measure:
A- Physiological dead space
B- Residual volume
C- Anatomical dead space
D- Cardiac output
Ans: C

101- No. of divisions of lower airways:
A- 17
B- 21
C- 23
D- 26
Ans: C

CamScanner

102- Which of the following is less in fetus than mother?
A- PO2
B- PCO2
C- HB
D- Neutrophils
Ans: A

103- Size of aerosol reaching alveoli in aerolized therapy?
A- <0.5
B- 0.5 to 3
C- 3 to 10
D- 10 to 30
E- >30
Ans: A

104- Lung compliance is increased in:
A- Old Age
B- Bronchoconstriction
C- Fibrosis
D- Negative Pressure
Ans: A

Explanation:
Lung compliance is increased mainly in old age due to loss of elastic tissue while vessel compliance is decreased.

105- Calculate alveolar ventilation, where vital capacity is 350 ml, dead space is 100 ml & rr is 18/min:
A- 3.5 L/Min
B- 4.5 L/Min
C- 5.5 L/Min
D- 6.0 L/Min
Ans: B

Explanation:
- Alveolar Ventilation is equal to (VC – Dead space) * RR
- (350 – 100) * 18
- (250 ml) * 18
- 4500 ml/Min
- 4.5 L/ Min

106- T-Configuration of hemoglobin has decrease affinity for:
A- Oxygen
B- CO2
C- Helium
D- Nitrogen
Ans: A

107- Directly proportional for oxygen diffusion:
A- Alveolar Capillary surface Area
B- Thickness
C- Fibrosis
D- Hemoglobin
Ans: A

Explanation:
Diffusion is directly proportional with Area, differences in partial pressures & indirectly proportional with thickness.

108- Respiratory centre is located in:
A- Medulla
B- Pons
C- Midbrain
D- Cortex
Ans: A

109- Vital capacity less than 80% in:
A- Restrictive Lung disease
B- Normal Person
C- Tension Pneumothorax
D- Heart Failure
Ans: A

110- Alveoli doesn't easily collapse due to the presence of:
A- Surfactant
B- Lipids
C- Steroids
D- Collagen Fibers
Ans: A

111- Terminal Bronchioles have which of the following cells:
A- Goblet Cells
B- Clara Cells
C- Hair Cells
D- Sweat Gland
Ans: B

112- Which of the following volume/capacity in the lungs after normal tidal volume expiration?
A- Residual volume
B- FRC
C- ERV
D- IRV
Ans: B

113- Normal value of FEV1/FVC is:
A- 1
B- 0.8
C- 5
D- 3
Ans: B

Explanation:
Normal Value of FEV1/FVC is 0.8 or 80%.

114- Goblet cells are present in which of the following parts of respiratory system:
A- Conducting zone
B- Alveolar ducts
C- Terminal bronchioles
D- Alveolar sacs
Ans: A

115- Calculate Alveolar Ventilation when Tidal Volume is 500 ml & Respiratory Rate is 10:
A- 2500 ml
B- 3000 ml
C- 3500 ml
D- 4500 ml
Ans: C

Explanation:
- Alveolar Ventilation = (Tidal Volume – Dead Space) RR
- As per normal calculation Dead space is 150 ml
- Alveolar Ventilation = (500-150) * 10
- 350 * 10
- 3500 ml

116- Half-life of carboxyhemoglobin at 100% Oxygen:
A- 20 Minutes
B- 40 – 80 Minutes
C- 6 Hours
D- 8 Hours
Ans: B

Explanation:
- Room Air: 4 – 6 hours
- 100% Oxygen: 40 – 80 Minutes
- Hyperbaric Oxygen: 15 – 30 Minutes

117- Patient expired normally & then inspired maximally which of the following lung volume or capacity does it points toward:
A- Inspiratory Volume
B- Inspiratory Capacity
C- Tidal Volume
D- Expiratory Reserve Volume
Ans: B

Explanation:
Inspiratory capacity indicates TV+IRV that are what the patient just breathed in?

118- Which of the following lung volume/capacity will remain in the lungs after maximum full expiration?
A- Residual volume
B- Functional residual capacity
C- Inspiratory reserve volume
D- Tidal volume
Ans: A

Explanation:
The volume of air remaining in the lungs after maximum full expiration is known as RV (Residual Volume) that's 1200 ml.

119- A/A ratio is more than: 1
A- 25
B- 45
C- 65
D- 75
Ans: D

120- Segment of Lung with bronchus & arterial supply is called:
A- Brochopulmonary Segment
B- Bronchoalevolar Segment
C- Bronchiole
D- Bronchi
Ans: A

121- Oxyhemoglobin curve shifts to left:
A- Haldane effect
B- Bohr effect
C- Ficks effect
D- None of the above
Ans: A

Explanation:
- HaLdane effect: Shift to Left
- BohR effect: Shift to right

122- Decrease in oxygen saturation without change in oxygen tension is seen in:
A- CO poisoning
B- High Altitude
C- Cyanide Poisoning
D- Hypoventilation
Ans: A

123- Surfactant deficiency leads to:
A- Cardiac impairment
B- Renal Impairment
C- RDS
D- GIT Abnormality
Ans: C

124- Pulmonary hypoxic vasoconstriction occurs due to:
A- Increase PO2
B- Decrease PO2
C- Increase PCO2
D- Decrease PCO2
Ans: B

Explanation:
In pulmonary Vasculature Decrease PO2 leads to vasoconstriction while in other vessels of the body decrease PO2 leads to vasodilation.

125- Sudden relief of respiratory distress with oxygen. Patient has apnoea now. What is the cause?
A- Decreased arterial O2
B- Increased arterial O2
C- Venous blood CO2 fall to 45mmg
D- Venous blood CO2 fall less than 25mmHgA
Ans: B

CamScanner

126- A patient who was admitted to a hospital suddenly developed dyspnea?
A- Pulmonary edema
B- Pulmonary embolism
C- Polycythemia
D- Septic shock
Ans: B

127- A patient with anemia and PaO2 is decreased:
A- Anemic hypoxia
B- Hypoxic hypoxia
C- Secondary polycythemia
D- Pulmonary embolism
Ans: B

128- A soldier who was posted at Siachen presents to the emergency with numbness of the fingers and headache. Most probable diagnosis:
A- Primary polycythemia
B- Pulmonary Embolism
C- Secondary Polycythemia
D- Polycythemia Vera
Ans: C

129- At apex of lungs:
A- Increase ventilation
B- Increase V/Q
C- Increase perfusion
D- Decrease V/Q
Ans: B
Explanation:
- **Blood flow** – lowest at apex, highest at base
- **Ventilation** – lower at apex , higher at base
- **V/Q** – Higher at apex , lowest at base
- **Regional arterial PCO2** – lower at apex, higher at base
- **Regional arterial PO2** – highest at apex, lowest at base

130- What is the change that occurs at the 36 weeks of pregnancy?
A- Decrease in FRC
B- Increase in FRC
C- Increase in Hb
D- Decrease blood volume
Ans: A

131- The high altitude would result in:
A- Increase 2,3, BPG
B- Decrease Oxygen affinity
C- Increase oxygen affinity
D- No change shall occur
Ans: B

132- Decrease of which of the following parameters occurs at the apex of lungs?
A- Oxygenation
B- PCO2
C- V/Q
D- Ventilation
Ans: D

133- The normal respiratory drive is dependent on:
A- PaO2
B- PaCO2
C- Nitrogen in air
D- Altitude
Ans: B

134- CO2 diffuses rapidly than O2 through the alveoli due to:
A- High pressure of CO2 in the lungs
B- High lipid solubility
C- High water solubility
D- High diffusion coefficient
Ans: D

135- Segmental bronchus aerates which of the following?
A- Trachea
B- Bronchi
C- Bronchioles
D- Bronchopulmonary Segment of lung
Ans: D

136- Herring bruer reflex prevent which of following?
A- Collapse of lung
B- Deflation
C- Overinflation
D- None
Ans: C

137- Durning transport of oxygen and CO2. Amount of CO2 dissolved in plasma at 45mmhg is:
A- 0.3%
B- 2.7%
C- 23%
D- 70%
Ans: B

138- Hb is 10g, O2 saturation 90%, PaO2 60mmhg, calculate oxygen content:
A- 7
B- 10
C- 13
D- 21
E- 50
Ans: C

Explanation:
- To make it simple use the following formula:
- Oxygen Content = Hb * 1.34
- Oxygen Content = 10 * 1.34
- Oxygen Content = 13.4

139- If ventilation of alveoli is stopped because of bronchiolar blockage what will be PO2 in blood:
A- Equal to mixed venous blood
B- Less than mixed venous blood
C- Equal with arterial blood
D- Equal with atmospheric Oxygen
Ans: A

140- When interpreting a capnogram at?
A- Rise in baseline demonstrates hypocarbia
B- Rise in baseline demonstrates rebreathing
C- Rise in height demonstrates expiratory obstruction
D- Slow fall in height demonstrates expiratory obstruction
E- Slow rise in height demonstrates inspiratory obstruction
Ans: B

141- Alveoli are kept dry because of:
A- Alveolar macrophages
B- Tight junction b/w capillaries
C- Surfactants
D- Negative intrapleural pressure
Ans: D

142- Lung base have high perfusion and ventilation , why?
A- High blood flow
B- Low blood flow
C- High diffusing capacity
D- none
Ans: A

143- Very small particles in respiratory tract are cleared by:
A- Cilia
B- Mass transport
C- Phagocytosis
D- Diffusion
Ans: C

144- Basement membrane of lung alveoli:
A- Comprises of type 2 collagen
B- Contributes in the formation of surfactant
C- Has chondroitin sulphate as a constituent component
D- It is a mucopolysaccharide
E- Separates epithelium from endothelium in alveolar wall
Ans: E

145- Highest oxygen tension in:
A- Pulmonary capillaries
B- Arterial blood
C- Venous blood
D- Left ventricle
E- Right Atrium
Ans: A

146- Deficiency of pulmonary surfactant leads to
A- Increases surface tension, increases compliance
B- Increases surface tension, decreases compliance
C- Decreases surface tension, decreases compliance
D- Decreases surface tension, increases compliance
E- Increases surface tension, no effect on compliance
Ans: B

147- During quite breathing, the expenditure out of total body energy is:
A- 1%
B- 5%
C- 10%
D- 15%
E- 20%
Ans: B

148- Diameter of bronchi & bronchioles is:
A- Mainly under the control of sympathetic nervous system
B- Under muscarinic control
C- Narrowed due to local stimuli
D- All of the above
Ans: A

149- True statement about the physiological dead space is:
A- Is not diffusion dependent.
B- Is equal to anatomical dead space in a normal adult
C- Does not include anatomical dead space
D- Decreases with exercise
Ans: B

150- Left oxygen dissociation curve occur in all except?
A- Fetal hb
B- Increase ph
C- Hyperthyroidism
D- Fall of temperature
Ans: C

CamScanner

151- Physiologic shunt will be present when V/Q is:
A- Infinite
B- Zero
C- Normal
D- One
Ans: B

152- The respiratory zone where gaseous exchange occurs extends beyond:
A- Respiratory bronchioles
B- Terminal bronchioles
C- Alveolar ducts
D- Alveoli
Ans: B

153- During strenuous exercise, the respiratory rate increases, this is because:
A- PCO2 increases
B- PO2 decreases
C- PH of blood increases
D- Hypoglycemia occurs
Ans: A

154- Pulmonary artery pressure raised in:
A- Inspiration upto total lung capacity
B- Starvation
C- Moderate exercise
D- All of the above
Ans: C

155- In strenuous, Increase ventilation is due to:
A- Increase arterial PCO2
B- Decrease arterial PO2
C- Dec Arterial PH
D- Collateral stimulation from higher centers
Ans: D

156- Hypoxemia in blood is sensed by:
A- Chemoreceptors
B- Central receptors
C- Carotid body
D- Carotid sinus
Ans: C

157- V/Q lower than normal in?
A- Aqueous pressure of water
B- Increase of alveolar po2
C- Shunt
D- Pulmonary embolism
Ans: C

158- At 3000 feet barometric pressure should be?
A- 396
B- 344
C- 240
D- 100
E- 226
Ans: E

159- Dead space is increased by
A- Hyperventilation
B- Tracheostomy
C- Intubation
D- Hypotension
E- Neck flexion
Ans: D

160- Physiological dead space
A- 100ml
B- 150 ml
C- 200ml
D- 250 ml
E- 300 ml
Ans: B

161- Normal ratio of physiological and anatomical dead space.
A- 1 : 1
B- 1 : 2
C- 2 : 1
D- 1 : 3
E- 1 : 4
Ans: A

162- O2 dissociation curve is:
A- Sigmoid
B- Hyperbolic
C- Parabola
D- Deltoid curve
E- Helices
Ans: A
Explanation:
- O2 dissociation curve - Sigmoid
- Myoglobin dissociation curve - hyperbola

163- Hering bruer refmex will lead to inhibition of
A- Dorsal neuron of central respiration
B- Apneustic center
C- pneumotaxic center
D- Reticular activating center
Ans: A(Guyton)

164- Regarding right shift of O2 dissociation curve, what will be p50?
A- 26
B- 35
C- 18
D- 22
E- 10
Ans: B
Explanation:
Normal value 26
- Increase HB - oxygen affinity – O2 dissociation curve shift to left cause unloading O2 on hb. So decreases p50 < 26
- Decrease HB - Oxygen affinity – O2 dissociation curve shift to right cause unloading O2 on HB. So increases p50 > 26

165- In third Trimester of pregnancy what will be decreased
A- IC
B- RR
C- Vital Capacity
D- TLC
E- Tidal Volume
Ans: D

166- The PO_2 in blood at which Hb is 50% saturated with oxygen is about:
A- 10mmhg
B- 26mmhg
C- 35mmhg
D- 50mmhg
E- 6mmhg
Ans: B (BRS)
Explanation:
- 100% saturation – 100mmHg
- 75% saturation – 40mmHg
- 50% saturation – 25mmHg

167- Preterm Baby with 2.3 kg weight, tidal volume will be
A- 40
B- 14
C- 17
D- 20
E- 60
Ans: B (4 – 6ml/kg)

168- In isotonic exercise oxygen consumption by respiratory muscle:
A- 5%
B- 20%
C- 100%
D- 80%
Ans: A

169- Muscle of forced expiration
A- Quadratus Lamborum
B- Diaphragm
C- External intercostal
D- Abdominal muscles
E- Elastic Recoil
Ans: D

170- Which muscles are involved in forceful inspiration
A- Diaphragm + SCM + External oblique + Serratus anterior
B- Diaphragm+ Internal intercostal
C- Diaphragm + External intercostal + SCM + Serratus anterior + Scalene muscle
D- Diaphragm +External Oblique
Ans: C (Only Suitable)
Explanation:
- **Muscle of Quite Inspiration** – Diaphram and External Intercostal
- **Muscle of Forced Inspiration** – SCM & Serratous Anterior, Scalenus anterior & Medius and Pect minor
- **Quite Expiration** – Passive and by Elastic Recoil of Lung
- **Muscle of Forced Expiration** – Internal Intercostal
- **Accessory Muscle of Expiration** – Abdominal muscles (External Oblique,
- Rectus abdominis)
- External intercostal can be used in Quite inspiration as well as forceful inspiration.
- After RTA injury to Cervical Region Difficulty in breathing due to damage of - Diaphragm
- After RTA patient is having forceful expiration and Abdomen is moving with respiration due to – External oblique
- Vertical diameter increase by – Diaphragm
- AP diameter increase by – External intercosal assisted by internal and innermost intercosatal.

171- Best Host defense in alveoli is:
A- Nasal Cillia
B- Lymphatics
C- Alveolar macrophages
D- IgA Secretion
Ans: C

172- A boy had a car accident after which he is bed ridden. He develops DVT He came to ER with chest pain and dyspnea. What will be the findings?
A- Increase PO2
B- Ventilation perfusion mismatch
C- Increase pcO2
D- Decrease pO2
Ans: B

CamScanner

Explanations:
It is the case of acute pulmonary embolism causes redistribution of blood in the lungs which impairs the ventilation perfusion ration by increasing pulmonary vascular resistance.

173- Highest oxygen saturation in fetal circulation is seen in:
A- Umbilical artery
B- Umbilical vein
C- Aorta
D- IVC
E- SVC
Ans: B

174- Which of following has max O_2
A- Umbilical artery
B- Pulmonary Capillary
C- Aorta
D- IVC
E- SVC
Ans: B

Explanation:
- Max O2 – Pulmonary Capillaries
- Low O2 – Pulmonary Artery >SVC > Umbilical artery
- Highest O2 Saturation – Umbilical Vein

175- At normal conditions both are equal?
A- Pulmonary blood flow &venous return
B- Venous return and cardiac output
C- Venoun return and MAP
D- Blood pressure and venous return
Ans: A

176- In the last trimester of pregnancy what change in respiratory parameters occurs?
A- Decreased FEV/FVC
B- Decreased vital capacity
C- Increased lung compliance
D- Decrease CO_2
E- Decrease tidal volume
Ans: D

177- Patient after RTA presented with decreased expiration (difficulty in expiration) which muscle is damaged?
A- Diaphragm
B- External intersostal
C- Abdominal muscles
D- Sternocleidomastoid
E- Internal intersostal
Ans: E

178- Lung compliance decrease by?
A- Supine position
B- Increase surface tension
C- Decrease lung volume
D- Increase lung volume
Ans: C

179- In shallow breathing which of the following remains unchanged
A- Alveolar ventilation
B- Dead space
C- Tidal volume
D- Residual volume
Ans: B

180- In obstructive lung disease which one decrease
A- FRC
B- FEV1
C- ERV
D- RV
Ans: B

181- Critical temperature of oxygen is:
A- +30
B- +60
C- -118
D- +45
Ans: C

182- Air humidity in OT
A- 55%
B- 45%
C- 65%
D- 80%
Ans: A

183- As compared to normal person, marathon runner has following changes:
A- Increase SV
B- Increase SV and heart rate
C- Decrease heart rate and increase SV
D- Both are decreased
E- Decrease SV
Ans: C

184- Central and peripheral chemoreceptors sensitive to
A- CO2
B- Arterial PH
C- CSF PH
D- Hypoxia
Ans: A

185- Early stage of asthmatic attack with RR 30/min will shows:
A- Low arterial PCO2
B- High arterial PCO2
C- Low P02
D- Reduced lung compliance
E- Increased airway resistance
Ans: A

186- Ground substance of alveolar duct
A- Basement membrane
B- Collagen
C- Elastic fiber
D- Alveoli
Ans: D

187- Most common cause of physiological hypoxemia is:
A- V/Q mismatch
B- Pulmonary shunt
C- Diffusion defects
D- Increase 2,3 DPG
E- Hypoventilation
Ans: E

188- A patient of asthma having following ABGs PH 7.23. HCO3 26 and Hypercapnea likely acid base disorder is:
A- Uncompesated metabolic acidosis
B- Compensated metabolic acidosis
C- Respiratory alkalosis
D- Respiratory acidosis
E- Metabolic alkalosis
Ans: D

189- A patient with Na 144 PH7.34 HCO3 12 Cl 110 and anion gap 10 will have:
A- Hypercholremic metabolic acidosis with normal anion gap
B- Hypocholemic metabolic acidosis with increase anion gap
C- Hypercholremic metabolic acidosis with increase anion gap
D- Hypocholremic metabolic acidosis withnormal anion gap
Ans: A

190- A patient ABGs reveal PH 7.54, PCO_2 40 and HCO_3 38 what is acid base disorder?
A- Respiratory acidosis
B- Respiratory alkalosis
C- Compensatory Respiratory Acidosis
D- Metabolic acidosis
E- Uncompensated Metabolic alkalosis
Ans: E

191- Decreased physiological dead space by:
A- Pneumothorax
B- Atelectasis
C- Emphysema
D- Pleural effusion
A- Hypertension
Ans: B

192- Patient present with breathlessness, PH 7.35, PCO2 60 , O2 75 And HCO3 16 which acid base disorder is:
A- Respiratory acidosis
B- Metabolic alkalosis
C- Uncompensated metabolic acidosis
D- Metabolic acidosis
Ans: A

193- How much tidal volume should be given to Anesthetized individual?
A- Normal
B- Twice the normal
C- Thrice the normal
D- Half the normal
Ans: B

194- In artifical respiration 60% o2 given and 40% nitrogen given after switching off artifical respiration there is brief apneic episode due to:
A- Low arterial O2 suppresing peripheral chemorecptors
B- Low arterial O2 suppresing central chemoreceptrs
C- Low arterial PH suppressing periphral chemorecptors
D- More O2 activate Central chemoreceptor
Ans: A

195- If a male breaths 7500ml per minut ,have 12preath per minute , if his intrathoracic pressure increase 5cm H2O while breathing , how much energy consumed?
A- 3500 joule/min
B- 4000 joule/min
C- 4500 joule/min
D- 5000 joule/min
Ans: A

196- The air-blood barrier in the lungs consists of:
A- Alveolar type I cells
B- Alveolar type II cells
C- Endothelial cells
D- Pericytes
Ans: A

197- Patient has history of severe dyspnea and breathlessness. After 1 week other symptoms resolved except dyspnea. ABG's shows PH 7.32 , CO2 70mmhg , HCO3 35mmhg
A- Uncompesated metabolic acidosis
B- Compensated metabolic acidosis
C- Respiratory alkalosis
D- Compensated respiratory acidosis
E- Metabolic alkalosis
Ans: D

CamScanner

198- During Exercise there is:
A- O2 Consumption
B- CO2 Consumption
C- Decrease ventilation
D- Increase O2 production
Ans: A(BRS)

Explanation:
Exercise Increase
- O2 Consumption
- CO2 Production

199- In which condition v/q ratio is less than normal?
A- Physiological dead space
B- Shunt
C- Embolism
D- Obtruction of bronchi
Ans: B

Explanation:
In Airway Obstruction
- 1-V/Q is Less than Normal (Guyton) >Zero called R-L Shunt
- 2-Composition of Systemic arterial blood approaches Mixed Venous Blood
- 3-Increase A-a Gradient

In Pulmonary Embolism
- V/Q is Infinite Called Dead Space
- Composition of Alveolar Air approaches Inspired Air

200- In which condition v/q ratio is increased?
A- Physiological dead space
B- Shunt
C- Embolism
D- Obtruction of bronchi
Ans: A

Explanation:
In Airway Obstruction
1- V/Q is Less than normal (Guyton) >Zero called R-L Shunt
2- Composition of systemic arterial blood approaches mixed venous blood
3- Increase A-a Gradient

In Pulmonary Embolism
1- V/Q is Infinite Called Dead Space
2- Composition of Alveolar Air approaches Inspired Air

201- Lung root cut median to branching of primary bronchus how can you identify the side of root
A- Pulmonary artery
B- Alveoli position
C- Position of Pulmonary veins
D- Bronchial varix
Ans: C

202- Normal fluid loss in 24 hours through perspiration is:
A- 200-400ml
B- 400-500ml
C- 500-600ml
D- 600-800ml
Ans: A

203- A girl has bronchial obstruction, but alveoli are still aerated due to:
A- Dispersed cartilage in lamina
B- Intercellular canaliculi
C- Sinusoids
D- Alveolar pores
E- Fenestrations in endothelium
Ans: D

204- The maximum FiO2 which can be administered to mother without raising risk of fibrolental hypoplasia:
A- 1.0
B- 0.8
C- 0.6
D- 0.35
Ans: A

Explanation:
- FiO2 that can be given to mother safely without increase risk of retinopathy - 0.8
- Maximum FiO2 that can be given to mother -1.0
- FiO2 Safe dose in Neonate that don't cause retrolental fibroplasia - 0.35

205- Patient presented with PO2 90mmhg, CO2 20mmhg and HCO3 18 with PH 7.2 what is likely cause
A- Hypoxia
B- Hyperventilation
C- Metabolic alkalosis
D- Respiratory acidosis
Ans: B

206- During inspiration which prevent overstretching of lung
A- Dorsal
B- Ventral
C- Apneustic centre
D- Pneumotaxic centre
E- Chemoreceptor
Ans: D(BRS)

207- COPD no metabolic disturbance pa of 80 what will be PH
A- 7.3
B- 7.4
C- 7.5
D- 7.6
Ans: A

208- Lowest CO_2 tension in:
A- Alveoli in end inspiration
B- Anatomic dead space in end expiration
C- Anatomic dead space in end inspiration
D- Pulmonary veins
Ans: D

209- Embolus in one of branch of pulmonary artery cause:
A- Increase PO_2
B- Increase Alveolar CO_2
C- Increase V/Q
D- Decrease V/Q
Ans: C

210- Pulmonary nodule has which type calcification?
A- Lamellar
B- Eccenteric
C- Nodular
D- Cresenteric
Ans: B

211- A patient with Hb 15 oxygen content of - hemoglobin is 20ml, alveolar pO2 is 40, - venous O2 is 15 what type of hypoxia is this
A- Hypoxemic
B- Anemic
C- Hypoxic
D- Histotoxic
Ans: C

Explanation:
Hypoxic Hypoxia (Decrease O2 tension)
- High altitude
- V/Q mismatch

Anemic Hypoxia (Decrease O2 Carrying)
- Anemia
- CO Poisning

Stagnant Hypoxia (Low Perfusion)
- Heart failure
- Shock

Histotoxic Hypoxia (Not Able to use O2)
- Cyanide poison

212- During inspiration what causes diaphragmatic expansion
A- Increase Arterial PO2
B- Decrease Arterial PCO2
C- Proprioceptor
D- Neural stimulation
E- Increase temperature
Ans: A

213- Regarding HB true is
A- Carry Deoxygenated Blood
B- Has more HbF
C- Act as buffer as it accepts H ions
D- It does not accept H ions
Ans: C

214- FRC consist of
A- IRV -FVC
B- ERV +IRV
C- RV +ERV
D- Only ERV
Ans: C(BRS)

215- Oxygen toxicity occur at
A- 1 atmosphere in 24 hours
B- 100 atmosphere in 24 hours
C- 100 atmosphere in 48 hours
D- 10 atmosphere in 72 hours
Ans: C

216- Pulmonary artery clotted what will increases in affected lung site
A- Ventilation perfusion ratio
B- Incresse PO2 in alveoli
C- Increase CO2 in alveoli
D- Increase CO2 in artery
Ans: A

217- Regarding Fetal HB true is
A- More CO2 binding capacity
B- Less O2 binding capacity
C- More O2 binding capacity
D- Cause tachycardia
Ans: C

218- A patient whose perianal surgery is going on. Patient is in Trendelenburg position what will increase
A- Vital capacity
B- RR
C- Tidal volume
D- Residual volume
E- Lung compliance
Ans: E

219- lung compared to systemic circulation has:
A- Increase resistance
B- Decrease resistance
C- Increase diameter
D- Decrease area
Ans: B

220- Group of neurons that generates basal rhythm for breathing include
A- Dorsal
B- Ventral
C- Apneustic
D- Pneumotaxic
E- Chemoreceptor
Ans: A(BRS)

CamScanner

221- A young female presented with diarrhea and dizziness. HCO3 18 in right shift of HB O2 curve what will be decreased

A- Temperature
B- H ions
C- 2,3BPG
D- PH
E- Pressure

Ans: D

Explanation:

Right Shift:

Right shift mean decrease affinity for O2 and increase delivery to tissue (Bohar effect) thus increase P50

Causes:

- Increase CO2
- Decrease PH
- Increase Temperature
- Increase 2, 3 DPG

Left Shift:

Left shift mean Increase affinity for O2 and decrease delivery to tissue (Haldane effect) thus decrease P50

Causes:

- Decrease CO2
- Increase PH
- Decrease temperature
- Decrease 2, 3 DPG
- HbF
- CO poisoning

222- CO2 transports mainly in the form of -

A- HCO3
B- Free form
C- Bound to Chloride
D- Dissolved in plasma
E- Bound to sodium

Ans: A(BRS)

223- During Inspiration what decreases

A- Systolic Hypertension
B- Right ventricular pressure
C- Left Ventricle contractions
D- Thoracic arterial pressure

Ans: D

224- Patient has emphysema what will be the acid base imbalance present in him:

A- Raised in H ion in plasma
B- Raise in plasma PCO2
C- Decrease in HOC3 in plasma
D- Positive base excess
E- Rise in plasma PH

Ans: B

225- Dead space remained unchanged in:

A- Asthma
B- Deep breathing
C- Bronchoconstriction
D- Bronchiectasis
E- Shallow breathing

Ans: E (E>B)

Explanation:

- Pattern of breathing has no effect on dead space but Here E>B

226- In diabetic patient acidosis is due to:

A- Decrease H
B- Decrease K
C- Decrease Bicarbonate
D- Decrease CO2

Ans: C

227- In asthma patient having crepts, what parameter will decrease

A- Increase FVC
B- Decrease FEV1
C- Increase TLC
D- Decrease TLC

Ans: B

228- The cause of pulmonary edema in IHD and diabetes:

A- Bronchial obstruction.
B- Increase hydrostatic pressure
C- Increase oncotic pressure
D- Vagovagal reflexes
E- Lymphatic obstruction

Ans: B

Explanation:

- Peripheral edema in CLD due to – loss of albumin (Low oncotic pressure)
- Ascites in CLD due to – Portal HTN
- Renal origin edema due to – Loss of albumin (low oncotic pressure) + can be salt and water retention.
- Nephrotic syndrome edema due to - Hypoalbuminemia
- Nephritic syndrome edema due to – Salt and water retention.
- Pedal edema in CHF and HTN due to – Increase hydrostatic pressure.
- In CHF edema worsen by – Sodium and water retention.

229- Complete transection of brainstem above pons would

A- Result in cessation of all breathing movements
B- Prevent any voluntary holding of breath
C- Prevent control of central chemoreceptors from exerting any control over breathing
D- Prevent peripheral chemoreceptors from exerting any control over ventilation
E- Abolish Hering Breuer reflex

Ans: B

Explanation:

- Cerebral cortex control voluntary control of Breathing. If lesion above pons it means cerebral cortex which is above pons is resected and there will be no voluntary control of Breathing

230- Oxygen delivery to tissue decreases by:

A- Cyanide poisoning
B- CO poisoning
C- Anemic hypoxia
D- Stagnant hypoxia

Ans: B

Explanation:

- Decrease O2 delivery to tissue - CO poisoning
- Decrease O2 Utilization by tissue - Cyanide poisoning

231- A patient ABGs reveal PH 7.54, PCO2 40 and HCO3 29 what is acid base disorder?

A- Respiratory acidosis
B- Respiratory alkalosis
C- Compensatory Respiratory Acidosis
D- Metabolic acidosis
E- Uncompensated Metabolic alkalosis

Ans: E

232- Hypoxic Vasoconstriction occur in which of following:

A- Kidney
B- Spleen
C- Lung
D- Liver
E- Stomach

Ans: C

233- Decrease CO2 has occured. What changes will occur

A- Hyperventilation
B- Decrease blood supply to brain
C- Increase blood supply to kidney
D- No change

Ans: B

234- A sea diver after diving ascend rapidly then develops shortness of breath and joint pain. Cause is:

A- Lactic Acidosis
B- Nitrogen bubble
C- Excessive fatigue
D- Excess CO2

Ans: B

235- First line macrophage of defense in lungs is:

A- Histiocytes
B- Dust cell
C- Dendritic cell
D- Histamine
E- Neutrophil

Ans: B

236- Stagnant Hypoxia occurs in

A- Cyanide
B- COPD
C- Polycythemia
D- Severe Anemia
E- Asthma

Ans: C (Prefer MI or Heart failure)

Explanation:

- Stagnant hypoxia occur in - Heart failure , MI and Cardiogenic Shock
- Stagnant hypoxia leads to – Polycythemia

237- What happens in whooping cough?

A- Cotton wool spot
B- Atrophy of respiratory membrane
C- Hyperplasia of respiratory bronchus
D- Degeneration of Alveoli

Ans: C

238- Surfactant production is increased in which of the following;

A- Deep breathing
B- Shallow breathing
C- Prematurity
D- Expiration

Ans: A

239- Absent surfactant leads to which of following?

A- Decrease oxygen tension
B- Increase compliance
C- Decrease compliance
D- Decrease elastic recoil

Ans: C

Explanation:

Surfactant normally decreases surface tension and Increase lung compliance.

Surfactant deficiency cause increase surface tension and decrease lung compliance.

240- CO2 transport is regulated by:

A- Positive feedback
B- Renin angiotensin system
C- Negative feedback
D- Sympathetic regulation
E- Central and peripheral receptors

Ans: C

CamScanner

241- A patient in RTA had head injury after which he has increase respiration and decrease respiration. This type of respiration is known as:
A- Cheyne stokes
B- Laboured
C- Hysterical
D- Kussmaul
E- Apnea
Ans: A

242- CO2 and H ions raised which one will be stimulated:
A- Carotid body
B- Central chemoreceptor
C- Peripheral chemoreceptor
D- Carotid Sinus
Ans: B

243- Metabolic acidosis caused by
A- Increase CO2
B- Decrease CO2
C- Fall in Bicarbonate
D- Increase Bicarbonate
Ans: C

244- Fetal blood leaving placenta having oxygen is:
A- 20mmhg
B- 30mmhg
C- 50mmhg
D- 60mmhg
E- 100mmhg
Ans: B

245- In lung formation canalicular stage what will happen?
A- Increase vasculogenesis
B- Lung bud formed
C- Alveoli formed
D- Bronchioles formation
Ans: A

246- A patient with well differentiated squamous cell Carcinoma of lung, histopathology will show which of the following?
A- Loss of Polarity
B- Pleomorphism
C- Keratin Pearls
D- Loss of Architecture
Ans: C (FA +Pathoma)

247- Deep inspiration leads to
A- Increase compliance in pulmonary vasculature
B- S2 splitting
C- Delayed closure of semilunar valves occur
D- None
Ans: A

Explanation:
Deep inspiration leads to
- Decrease Cardiac output
- Increase Venous return
- Splitting of S2
- Increase Pulmonary Compliance

248- Which of the following lung volumes or capacities can be measured by spirometry?
A- FRC
B- Physiologic dead space
C- RV
D- TLC
E- VC
Ans: E

249- PO2 in arterial blood is less than the pO2 in alveoli because:
A- Mixing of blood of cardiac veins into coronary sinus
B- Oxygen need pressure gradient for diffusion
C- Oxygen need Mix blood
D- CO2 need high pressure
Ans: B

250- Feature of acid fast bacili in TB?
A- Mycolic acids
B- Cell wall made of peptidoglycan
C- Capsule
D- Periplasmic space
Ans: A

251- Increase PaCO2 will cause:
A- Hypotension
B- Coma
C- Tachycardia
D- Sweating
E- Tremors
Ans: C

252- Surfactant decrease surface tension by
A- Increasing elastic recoil of lung
B- Decreasing elastic recoil of lung
C- Decreasing Surface area
D- Decreasing Tension in bronchi
Ans: B

253- If dead space becomes zero it is called:
A- Physiological dead space
B- Physiological Shunt
C- Embolism
D- Obtruction of bronchi
Ans: B

254- Lungs remain open due to
A- Positive intrapleural pressure
B- Vital capacity
C- Negative intrapleural pressure
D- Elastic recoil
E- Pericardial fluid surface tension
Ans: C

255- A man is a plumber he is having difficulty in breathing from last 1 year he is also short of breath and dyspnoeic his blood ABGS show PH7.4 HCO3 19 and PCO2 31 he has most likely:
A- Metabolic acidosis
B- Metabolic alkalis
C- Compensated metabolic alkalis
D- Compensated metabolic acidosis
E- Mixed metabolic acidosis and alkalosis
Ans: D

256- A patient has following ABGs PH of 7.2, HCO3 levels of 19 and PCO2 of 39 what is likely diagnose is?
A- Metabolic alkalosis
B- Respiratory acidosis
C- Metabolic alkalosis
D- Metabolic acidosis
E- Normal
Ans: D

257- Patient has COPD which help reach diagnosis:
A- V/Q=1
B- V/Q=infinity
C- V/Q= 0.1
D- Physiological dead space
E- Physiological shunt
Ans: C

258- Respiratory muscl ..rk against
A- Decrease intrapleural pressure
B- Elastic recoil of lung
C- Volume of lung
D- Residual volume
Ans: B

259- How the Inspiratory Reserve Volume (IRV) is calculated based on lung volumes and capacities measured during a spirometry test?
A- IRV = TV - ERV
B- IRV = VC - TV - IC
C- IRV = ERV – IC
D- IRV = VC – TV - ERV
Ans: D

260- Calculate minute ventilate if dead space is 150 ml , R/R 12 and Tidal volume is 500ml:
A- 4600ml
B- 5200ml
C- 3500ml
D- 4200ml
E- 6200ml
Ans: D

Explanation:
Minute ventilation= Tidal volume x RR
To calculate
Minute ventilation= (500-150)x12

261- Vital capacity is defined as
A- Forceful expiration
B- Forceful inspiration
C- Forceful inspiration than Expiration
D- Exhale maximally then inhale
Ans: C

262- A person after RTA has shallow breathing that will cause
A- Increase PH and increase CO2
B- Decrease O2; increased CO2; Ph decreased and Increased HCO3
C- Increased O2 , Increase PH and Decrease HCO3
D- Decreased O2 Decrease CO2 and Decrease HCO3
Ans: B

263- Diagnostic findings of metabolic alkalosis are:
A- HCO3>24
B- PCO2>60
C- PCO2<40
D- PH>7.4
E- PH<7.4
Ans: A

264- Metabolic acidosis mechanism is:
A- Loss of CO2
B- Gain of Bicarbonates
C- Gain of PH
D- Loss of Bicarbonates
Ans: D

265- A patient has PH: 7.2 , HCO3: 16 & CO2: 50 what is your diagnosis?
A- Mixed metabolic acidosis and respiratory acidosis
B- Respiratory alkalosis
C- Respiratory acidosis compensated
D- Metabolic alkalosis
Ans: A

CamScanner

266- Alveoli are affected by:
A- Pulmonary veins
B- Pores
C- Pulmonary tree
D- Arteries
Ans: C

267- After forced expiration residual volume:
A- 500ml
B- 1000ml
C- 1200ml
D- 2400ml
Ans: C

268- If alveolar ventilation doubles and CO2 production remain constant than arterial PCO2:
A- Does not change
B- Double
C- Increase 4 folds
D- Increase 16 folds
E- Halved
Ans: E

269- Respiratory acidosis occurs in
A- High altitude
B- Drowning
C- Aspirin toxicity
D- Diarrhea
E- Hyperaldosteronism
Ans: B

270- ABG's of a patient advised report shows PH:7.3 HCO3 :15 PCO2:38 diagnosis?
A- Metabolic acidosis
B- Metabolic alkalosis
C- Respiratory alkalosis
D- Respiratory acidosis
E- Mixed acid base
Ans: A

271- On inspiration which cardiovascular parameter decreases?
A- Decrease pleural pressure
B- Decrease abdominal pressure
C- Decreased intrathoracic pressure with dilation of thoracic veins
D- Decrease Vena cava pressure
Ans: C

272- Which of the following occurs in severe diarrhea with normal anion gap?
A- Metabolic alkalosis
B- Metabolic acidosis
C- Respiratory acidosis
D- Respiratory alkalosis
Ans: B

273- Increase Surfactant level leads to:
A- Decrease lung compliance
B- ARDS
C- Decrease lung mass
D- Decrease Surface tension
Ans: D

Explanation:
Surfactant normally decreases surface tension and Increase lung compliance

274- Patient with PH =7.12 , PCO2 60 and HCO3 19 cause is:
A- Metabolic acidosis
B- Metabolic alkalis
C- Compensated metabolic alkalis
D- Compensated metabolic acidosis
E- Mixed metabolic acidosis and Respiratory acidosis
Ans: E

275- Patient is being moved on 02, 6L/min the full tank of oxygen 3.5 kg will finish in:
A- 30min
B- 60 min
C- 90 min
D- 110 min
E- 130 min
Ans: D

276- Girl doing exercise result in increase minute ventilation is due to:
A- Decrease CO2 tension in blood
B- Increase O2
C- Increase CO2 tension in blood
D- Increase N2
Ans: C

277- CO2 and O2 crosses membrane due to (Surgery Feb 2024)
A- Lipid solubility
B- Cross structure
C- Small size
D- Passive diffusion
Ans: C

278- 12 Year old boy breathing, What will happen to Inhaled air in alveoli?
A- Air velocity decreases progressively
B- Maximum velocity at bronchioles
C- Maximum velocity at bronchi
D- Air velocity increases progressively
Ans: D

279- The tidal volume is 500ml and intrapulmonary pressure increased from 0 to 5cm H20. The product of this pressure and volume relationship is an expression of:
A- FRC
B- Lung compliance
B- Work of breathing
C- Vital capacity
D- ERV
Ans: B

280- A female patient has BP 145/90mmhg , She is pale and having cold extremities develop sob and deep breathing . Her HB is 6.7g/dl. What is likely cause
A- Hypoxic hypoxia
B- Anemic hypoxia
C- Decrease Erythropoietin
D- Stagnant Hypoxia
E- Decrease Perfusion
Ans: B

281- During Inspiration what will happen
A- Systolic Hypertension
B- Right ventricular pressure
C- Left Ventricle contractions
D- Thoracic arterial pressure decrease and dilated thoracic veins
Ans: D

282- Lamella forming air blood barrier are
A- Alveolar macrophages
B- Type 1 pnemocytes
C- Type 2 pnemocytes
D- Cillia
Ans: B

283- Right lung has bronchogenic carcinoma, middle lobe removed surgically, segments include:
A- Apical and Lingula
B- Medial and lateral
C- Anterobasal and Lateral basal
D- Mediobasal And lateral
E- Anterobasal and Posterobasal
Ans: B

284- Exercise causes hyper ventilation. What's the increase Respiratory drive during exercise?
A- Central Chemoreceptors
B- Baroreceptors
C- Peripheral Chemoreceptors
D- J receptor
Ans: A

Explanation:
As in exercise there is increase CO2 production which stimulate central chemoreceptors which result in hyperventilation to wash out CO2

285- Lung is distended due to which of the following
A- Intra thoracic pressure
B- Transpulmonary pressure
C- Intrapleural pressure
D- Thoracic volume
Ans: A

286- A pt has severe problem in breathing at room air , 100% oxygen is given after which mix arterial pressure goes to 670 mmHg and pO2 70 mmHg , cause of hypoxia in him is ?
A- High altitude
B- Left to Right shift
C- V/Q mismatch
D- Hypoventilation
E- Diffusion interference
Ans: C

287- During inspiration what decrease
A- Heart rate
B- Venous return
C- Volume of thoracic cavity
D- Negative pleural pressure
Ans: D

288- A patient has hypoxia at high altitude it will be detected by
A- Central chemoreceptors
B- Peripheral chemoreceptors
C- Carotid sinus
D- Aortic body
Ans: B

289- Tissue unable to use oxygen despite normal oxygen
A- Cyanide poisoning
B- CO poisoning
C- Anemic hypoxia
D- Stagnant hypoxia
Ans: A

Explanation:
- Decrease O2 delivery to tissue - CO poisoning
- Decrease O2 Utilization by tissue:Cyanide poisoning

CamScanner

290- Which of the following Lung changes are present in obese persons?
A- Increase in Lung volumes
B- Decreased functional residual capacity
C- Increase in chest wall compliance
D- Increased Residual volume
Ans: B

291- Which one of the following prevents collapse of the lung?
A- Intrapleural pressure
B- Transpulmonary pressure
C- Transthoracic pressure
D- Intrathoracic pressure
E- Intrapulmonary pressure
Ans: A

292- Muscle of forced expiration
A- Quadratus Lamborum
B- Internal intercostal and Diaphragm
C- External intercostal
D- Internal intercostal and Rectus abdominis
E- Elastic Recoil
Ans: D

293- Which of the following represents the pressure difference that acts to distend the lungs?
A- Intrapleural presssure
B- Airway opening pressure
C- Intrathoracic pressure
D- Transpulmonary pressure
E- Esophageal pressure.
Ans: D >C>A

Explanation:
Trans pulmonary pressure is difference between alveolar and intrapleural pressure thus if it increases it is main factor that will cause lung expansion or distension

294- Lamilla forming Minimum air blood barrier is
A- Type 2 pneumocyte
B- Alveolar macrophages
C- Pores of kohn
D- Cillia
Ans: C

295- Residual volume always remain in lung due to as it
A- Increases Alveolar collapse
B- Decreases Alveolar collapse
C- Decrease negative alveolar pressure
D- Increase positive airway pressure
Ans: B

296- Why pulmonary edema mostly happened in basal lobe of lung
A- Resistance to flow
B- Lymph drainage
C- Decrease Arterial PO2
D- Decrease Arterial CO2
Ans: C

Explanation:
- Blood flow – lowest at apex, highest at base
- Ventilation – lower at apex , higher at base
- V/Q – Higher at apex , lowest at base
- Regional arterial PCO2 – lower at apex, higher at base
- Regional arterial PO2 – highest at apex, lowest at base

297- Which type of hypoxia is associated with decreased po2 and increased A a gradient
A- Anemia
B- High altitude
C- Emphysema
D- Right to left shunt
E- Left to right shunt
Ans: D

Explanation:
Increase A- a Gradient Seen in:
- 1-Fibrosis
- 2-V/Q Defect
- 3-R-L Shunt
- TOF has Right to Left Shunt
- a Gradient Normal Value – 0 -10mmhg
- A/a Ratio Normal – 0.8(>0.75)

298- Right shift of oxygen dissociation curve is caused by:
A- Increase PH
B- Increase CO2
C- Decrease PCO2
D- Decrease H+ ions
Ans: B

299- Surfactants decrease Pulmonary surface tension by:
A- Increasing elastic recoil of lung
B- Interspersing between water molecules
C- Decreasing the diameter of alveoli
D- By closing the alveoli
E- Decreased Tension in alveolar walls
Ans: B

300- A patient has alveolar ventilation 6000 and RR 12/min calculate dead space
A- 200ml
B- 100ml
C- 300ml
D- 450 ml
Ans: B

301- A Person Goes to Height of 5000 ft.What will happen?
A- Pulmonary Vasoconstriction
B- Increase in plasma pCo2
C- Decrease in plasma bicarbonate
D- Lung Compliance Increases
E- Pulmonary Capillary Vasodilation
Ans: A

302- Left Pulmonary bronchus occluded by a tumor, what will happen in capillaries supplying the area:
A- Alveolar Po2 will become equal to inspired air
B- Alveolar Po2 will become equal to mixed venous o2
C- Alveolar Po2 will become equal to Arterial oxygen
D- Alveolar Po2 will become less than mixed venous oxygen
Ans: A

303- During exercise blood flow to lung increase to which zone:
A- Zone 1
B- Zone 2
C- Zone 3
D- Combine zone 1 and 2
E- Combine zone 2 and 3
Ans: E

304- Surfactant presence leads to Which of Following:
A- Decrease oxygen tension
B- Increase compliance
C- Decrease compliance
D- Decrease elastic recoil
E- Increase surface tension
Ans: B

Explanation:
- Surfactant normally decreases surface tension and Increase lung compliance

305- Conducting zone of respiratory tract ends after
A- Respiratory bronchioles
B- Terminal bronchiole
C- 19 divisions of tract
D- Alveolar duct
E- Alveolar sac
Ans: B

306- "Hering Breuer Reflex" is due to
A- Stretch receptors in bronchioles
B- Irritants
C- J receptors
D- None of the above
Ans: A

307- Volume is directly proportional to temperature if Pressure is kept constant:
A- Boyle's law
B- Charle's Law
C- Dalton's law
D- Henry law
Ans: B

308- What is the primary function of the O2 FIAL system?
A- To prevent the delivery of hypoxic mixtures
B- To regulate cabin temperature in aircraft
C- To monitor and control fuel levels in engines
D- To adjust cabin lighting based on time of day
Ans: A

309- Macrophages cell in alveoli:
A- Histiocytes
B- Dust cell
C- Dendritic cell
D- epitheloid cells
E- Langhan cells
Ans: B

310- An increase in PCO2 (partial pressure of carbon dioxide) typically leads to which of the following?
A- Hypertension
B- Tachycardia
C- Bradycardia
D- Hypotension
Ans: B

311- When a soldier climbs to high altitudes, which of the following metabolic abnormalities observed in him with passage of time
A- Severe hypercapnia
B- Respiratory acidosis
C- Severe hypoglycemia
D- Removal of HCO3 from body
E- Removal of H+ from body
Ans: D

CamScanner

Explanation:

- At high altitude initially respiratory alkalosis occur due to hyperventilation . but with passage of time as compensation HCO3 excretion occur to produce compensatory metabolic acidosis

312- At which level of spinal cord injury is a patient most likely to experience difficulties with ventilatory function due to impairment of the respiratory muscles?

A- Above C3
B- Between C3 and C5
C- Below C5
D- Between T1 and T5
E- Below T6
Ans: B

313- A student faints after hyperventilating. Arterial blood gases (ABGs) are taken during the episode of hyperventilation. What is the most likely finding in the ABGs?

A- No change
B- Alkalosis
C- Acidosis
D- Elevated PaCO2
E- Decreased PaO2
Ans: B

Explanation:

- During hyperventilation, the rate of breathing increases, leading to a decreased level of carbon dioxide (PaCO2) in the blood. This causes a respiratory alkalosis, reflected in the ABGs as an increased pH

314- Respiratory zone where gaseous exchange occurs includes ?

A- Respiratory bronchioles to alveolar duct
B- Terminal bronchioles to alveoli
C- Alveoli
D- Alveolar duct
E- Acinus
Ans: A

Explanation:

- Respiratory zone extends Beyond terminal bronchioles
- If asked where then From respiratory bronchioles to alveolar duct

315- Respiratory zone where gaseous exchange occurs includes?

A- Respiratory bronchioles to alveolar duct
B- Terminal bronchioles to alveoli
C- Alveoli
D- Alveolar duct
E- Acinus
Ans: A

Explanation:

- Respiratory zone extends Beyond terminal bronchioles
- If asked where then From respiratory bronchioles to alveolar duct

316- A patient with progressive lung disease requires an increasingly higher pressure to fill the same volume of lung. How would this affect the lung's compliance?

A- It would increase.
B- It would stay the same.
C- It would decrease.
D- These variables do not affect lung compliance.
E- First , It increases then decreases
Ans: C

317- During strenous exercise, there is an increase in ventilation rate that matches the increase in o2 consumption. What will happen (Medicine Feb 2025)

A- Normal po2
B- Increase pco2
C- Increase ph
D- Decreased pH
Ans: A

Explanation:

- During strenuous exercise, increased ventilation effectively matches the oxygen consumption and carbon dioxide production. This maintains arterial pO_2 and pCO_2 levels close to normal, and the pH is usually well-regulated due to buffering systems. Hence, the correct answer is Normal pO_2.

318- Calculate Pulmonary ventilation when tidal volume is 500 & respiratory rate is 12, HR 70bpm: (Medicine Feb 2025)

A- 6
B- 8
C- 8.5
D- 3
E- 1
Ans: A

319- Total number of divisions in Lower airway: (Medicine Feb 2025)

A- 21
B- 23
C- 10
D- 19
E- 6
Ans: B

320- Which of the following is typical value of tidal volume? (Medicine Feb 2025)

A- 0.5L
B- 4.6L
C- 5L
D- 1.2L
F- 0.7L
Ans: A

321- Which of the following is muscle of quite breathing (Medicine Feb 2025)

A- Serratus Anterior
B- Rectus abdominus muscles
C- External Intercostal Muscle
D- Internal Intercostal Muscle
E- Pectoralis major muscle
Ans: C

322- Endotracheal intubation of new born done for resuscitation. Upon auscultation absent breath sound on right side .What is the cause of endobrochial intubation? (Medicine Feb 2025)

A- Large tongue
B- Same angulation of Right & Left bronchi
C- High up epiglottis
D- Short neck
E- Small Mouth
Ans: D

323- Sympathetic Stimulation in fight and flight causes which of following? (Surgery Feb 2025)

A- Gluconeogenesis
B- Decrease HR
C- Decreased Respiratory bronchiolar Airway resistance
D- Miosis
E- Increase GIT motility
Ans: C

324- Partial pressure of O2 in blood depends upon which of the following (Surgery Feb 2025)

A- O2 dissolve in plasma
B- Hb concentration
C- O2 in inspired air
D- Alveolar permeability
Ans: A

325- A child is blowing into a paper bag due to hyperventilation. What is the most likely change in their arterial blood gas levels? (Surgery Feb 2025)

A- Increased arterial pCO_2
B- Increased arterial pO_2
C- Increased alveolar pO_2
D- Increased Alveolar pCO_2
Ans: A

326- From where the respiratory zone of the airway Start (Surgery Feb 2025)

A- Terminal bronchiole to alveoli
B- Alveolar duct to alveoli
C- Respiratory bronchiole to alveoli
D- Bronchus to Bronchioles
E- Bronchus to alveoli
Ans: C

327- The respiratory system undergoes changes during pregnancy under the influence of elevated progesterone levels. Which of the following changes is responsible for causing respiratory distress in pregnant women? (Gynae Feb 2025)

A- Decrease in Expiratory Reserve Volume (ERV) by 20%
B- Decrease in Total Lung Capacity (TLC) by 50%
C- Dyspnea due to decreased $PaCO_2$ levels
D- Increase in Minute Ventilation by 30-40%
E- Increase in Tidal Volume by 30- 40%
Ans: A

Explanation:

Physiological changes in lung function during pregnancy:
Functional residual capacity

- (FRC) decreases by approximately 20 to 30 percent or 400 to 700 mL during pregnancy. This capacity is composed of expiratory reserve volume—which decreases 15 to 20 percent or 200 to 300 mL—and residual volume—which decreases 20 to 125 percent or 200 to 400 mL.
- FRC and residual volume decline due to diaphragm elevation, and significant reductions are observed by the sixth month with a progressive decline across pregnancy.
- Inspiratory capacity, the maximum volume that can be inhaled from FRC, increases by 5 to 10 percent or 200 to 250 mL during pregnancy.

CamScanner

- Total lung capacity—the combination of FRC and inspiratory capacity—is unchanged or decreases by less than 5 percent at term
- The respiratory rate is essentially unchanged, but tidal volume .
- Resting minute ventilation increase significantly as pregnancy advances.

The increased minute ventilation is caused by several factors. These include enhanced respiratory drive primarily due to the stimulatory action of progesterone, low expiratory reserve volume, and compensated respiratory alkalosis.

- Regarding pulmonary function,peak expiratory flow rates increase progressively as gestation advances.
- Lung compliance is unaffected by pregnancy.
- Airway conductance is increased and total pulmonary resistance reduced, possibly as a result of progesterone.
- The maximum breathing capacity and forced or timed vital capacity are not altered appreciably

328- A patient with a history of smoking presents with a hilar mass. A biopsy reveals small clusters of cells. What is the most likely diagnosis? (Gynae Feb 2025)

A- Small cell carcinoma
B- Squamous cell carcinoma
C- Large Cell carcinoma
D- Adenocarcinoma
Ans: A

329- A patient sitting in a lawn on a wheelchair reading newspaper relaxed, normal breathing muscle for quiet inspiration? (Gynae Feb 2025)

A- Diaphragm
B- Diaphragm and Internal intercostal
C- Diaphragm and external intercostal
D- Internal Intercostal
E- Scalene & Sternocleidomastoid
Ans: C

Explanation:

- Muscle of Quite Inspiration – Diaphram and External Intercostal
- Muscle of Forced Inspiration – SCM & Serratous Anterior, Scalenus anterior & Medius and Pect minor
- Quite Expiration – Passive and by Elastic Recoil of Lung
- Muscle of Forced Expiration – Internal Intercostal
- Accessory Muscle of Expiration – Abdominal muscles (External Oblique, Rectus abdominis)
- External intercostal can be used in Quite inspiration as well as forceful inspiration.
- After RTA injury to Cervical Region Difficulty in breathing due to damage of - Diaphragm
- After RTA patient is having forceful expiration and Abdomen is moving with respiration due to – External oblique
- Vertical diameter increased by – Diaphragm
- AP diameter increased by – External intercosal assisted by internal and innermost intercostals. Better

330- True regarding Upper Lobe of Lung: (Radiology Feb 2025)

A- Increased Shunt
B- Increased Dead space
C- Increased Circulation
D- No air movement
Ans: B

331- A patient with progressive lung disease requires an increasingly higher pressure to fill the same volume of lung. How would this affect the lung's compliance? (Radiology Feb 2025)

A- It would increase.
B- It would stay the same.
C- It would decrease.
D- These variables do not affect lung compliance.
E- First , It increases then decreases
Ans: C

332- What could be the reason for increased CO_2 transport to cells and tissues? (Anesthesia Feb 2025)

A- Increased oxyhemoglobin (OxyHb)
B- Decreased oxyhemoglobin (OxyHb)
C- Increased CO_2 concentration
D- Increased temperature
E- Increased H^+ concentration
Ans: B

333- Humidity of air in alveoli depends on? (Anesthesia Feb 2025)

A- Ambient temperature
B- Core body temperature
C- Inspired air temperature
D- Absolute Humidity of Inspired Air
Ans: B

ENDO & REPRODUCTION PHYSIOLOGY QUICK HINTS

Insulin/Glucagon

Glucagon(CAMP)

Glucagon increases the blood glucose concentration.

1. It increases glycogenolysis and prevents the recycling of glucose into glycogen.
2. It increases gluconeogenesis

✓ Glucagon increases blood fatty acid and ketoacid concentration.
✓ Glucagon increases urea production.

Increase Glucagon	Decrease Glucagon
Hypoglycemia	Hyperglycemia
Arginine	Insulin
CCK	Somatostain
NE and Epinephrine	Fatty acid and ketoacid
Ach	
Exercise	

Insulin(Tyrosine kinase)

Insulin decreases blood glucose concentration by the following mechanisms:

1. It increases uptake of glucose into target cells
2. It promotes formation of glycogen from glucose in muscle and liver, and simultaneously inhibits glycogenolysis.
3. It decreases gluconeogenesis.

✓ Insulin decrease blood fatty acid and ketoacid concentration
✓ Insulin decease blood amino acid concentration
✓ **Immediate** action of insulin – Entry of potassium into cells
✓ **Intermediate** action of insulin – protein synthesis
✓ **Late** action of insulin – Lipogenesis
✓ Action of insulin at cellular level is – Entry of glucose into cells

Stimuli for Increase Insulin	Stimuli for Decrease Insulin
Increase Blood glucose, Mannose	Decrease Blood Glucose
Increase Amino acids (arginine, lysine, leucine)	2 Deoxyglucose, Somatostatin
Increase Fatty acids	Alpha adrenergic Stimulator (Norepinephrine, Epinephrine)
Intestinal Harmones (GIP, GLP-1, Gastrin, Secretin and CCK)	Beta Blocker (Propanolol)
Beta ketoacid, Ach	Galanin,Thiazide,
Glucagon	Low K,
Beta Adrenergic Stimulator (Theophylline)	Decrease Blood Glucose
Increase Amino acids (arginine, lysine, leucine)	

CamScanner

Growth Harmone

Direct actions of growth hormone

- ✓ ↓ glucose uptake into cells (diabetogenic)
- ✓ ↑ lipolysis
- ✓ ↑ protein synthesis in muscle and ↑ lean body mass
- ✓ ↑ production of IGF

Actions of growth hormone via IGF

- ✓ ↑ protein synthesis in chondrocytes and ↑ linear growth (pubertal growth spurt)
- ✓ ↑ protein synthesis in muscle and ↑ lean body mass
- ✓ ↑ protein synthesis in most organs and ↑ organ size

Stimuli that increase GH secretion	Stimuli decrease GH secretion
sleep	Somatostatins
stress	Somatomendins
starvation	Obesity
Exercise	Hyperglyemia (DM)
hypoglycemia	Pregnancy
Sex steroids (estrogen or testosterone)	IGF-1

PTH/Vitamin D

PTH

- ✓ PTH increases bone resorption, which brings both Ca and phosphate from bone mineral into the ECF.
- ✓ PTH inhibits renal phosphate reabsorption in the proximal tubule and, therefore, increases phosphate excretion (phosphaturic effect)
- ✓ PTH increases renal Ca2+ reabsorption in the distal tubule, which also increases the serum Ca
- ✓ PTH increases intestinal Ca2+ absorption indirectly by stimulating the production of 1,25-dihydroxycholecalciferol in the kidney

Vitamin D

- ✓ Increases intestinal Ca2+ absorption. Vitamin D–dependent Ca2+-binding protein (calbindin D-28K) is induced by 1,25-dihydroxycholecalciferol.
- ✓ Increases intestinal phosphate absorption.
- ✓ Increases renal reabsorption of Ca2+ and phosphate, analogous to its actions on the intestine.
- ✓ Increases bone resorption,

ADH

- ✓ Originates from supraoptic nuclei of hypothalamus
- ✓ Cause constriction of vascular smooth muscles
- ✓ Inc H2O permeability of principal cells of late distab tubules and collecting duct

Factors increase ADH secretion	Factors dec ADH secretion
Inc serum osmolarity	Dec serum osmolarity
Volume contraction	Ethanaol
Pain	Alpha-agonists
nausea	ANP
hypoglycemia	
Nicotine, opiates , Antineoplastic drugs	

Prolactin

- ✓ <1000 -- **Stress or Drugs**
- ✓ Between 1000 – 5000 -- **Microprolactinoma**
- ✓ >5000 – **Macroprolactinom**
- ✓ Prolactin cause – **Milk Production**
- ✓ High Prolactin cause – **Infertility and Glactorrhea**
- ✓ High prolactin cause – **Decrease GnRH so inhibit Ovulation**
- ✓ During Lactation Amenorrhea due to –**Increase Prolactin > Decrease GnRH**

Factors inc prolactin secretion	Factors dec prolactin secretion
Estrogen (pregnancy)	Dopamine
Breast feeding	Bromocriptine
Stress	Somatostatin
Sleep	Prolactin (by neaitive feedback)
TRH	
Dopamine antagonists	

Neurotransmitters and haromones that influence feeding and satiety center

Increase feeding (Orexigenic)

- ✓ Neuropeptide – Y
- ✓ Mch
- ✓ Orexins A and B
- ✓ Endrophins
- ✓ Gelanin
- ✓ Gherlin
- ✓ Aminoacids (glutamate)

Decrease feeding (Anorexigenic)

- ✓ Alpha MSH
- ✓ Leptin
- ✓ Serotinin
- ✓ Norepinephrine
- ✓ Corticotropin releasing harmone
- ✓ Glucagon like peptide
- ✓ CCK
- ✓ Insulin
- ✓ Peptide YY

Estrogen/Progesterone

Progesterone: (1 > 2 > 3)

1. Maintain Endometrial Proliferation(Thickness)
2. Secretory Phase
3. Alveoli and Lobule Development
4. Increase Basal Body Temperature

Estrogen:

1. Endometrial Proliferation

CamScanner

2. Breast Duct Development
3. Development of female Secondary Sex Characteristics
4. Stimulate Prolactin Secretion however it Blocks Prolactin action on Breast(During Pregnancy)
5. Maintain Calcium Homeostasis (Decrease Bone resorption and increase Linear Bone growth)
6. Potency – **Estradiol > Estron >Estriol**
7. Increase Estriol – **Indicates Fetal Well Being**

Testosterone/DHT

Actions of testosterone

- ✓ Differentiation of epididymis, vas deferens, and seminal vesicles
- ✓ Pubertal growth spurt
- ✓ Cessation of pubertal growth spurt (epiphyseal closure)
- ✓ Libido
- ✓ Spermatogenesis in Sertoli cells (paracrine effect)
- ✓ Deepening of voice
- ✓ Increased muscle mass

Actions of dihydrotestosterone

- ✓ Differentiation of penis, scrotum, and prostate
- ✓ Male hair pattern
- ✓ Male pattern baldness
- ✓ Sebaceous gland activity
- ✓ Growth of prostate
- ✓ Most Potent Anabolic – **Testosterone**
- ✓ Potency – **DHT > Testosterone**

Thyroid

- ✓ **Maximum** concentration of thyroid hormone – **T4**
- ✓ Thyroid harmone Enter in **Circulation** – **T4**
- ✓ Thyroid harmone cause fetal **Brain** development – **T3**
- ✓ **Active** form of thyroid hormone – **T3 (Free form or Unbound is Active)**
- ✓ Thyroid gland is enclosed by – **Pretracheal fascia**
- ✓ Metabolism of **TSH** in liver – **Demethylation**
- ✓ Metabolism of **Thyroid Harmones** In Liver – **De-iodination**
- ✓ Thyroglobulin produced from – **Follicular cells**
- ✓ Iodide oxidation occur in –**Follicular cells of thyroid**

Mechanisms of Harmone action

- ✓ **CAMP -** FSH, LH, ACTH, TSH, CRH, hCG, ADH (V2- receptor), MSH, PTH, Calcitonin, Histamine (H2-receptor), Glucagon, GHRH
- ✓ **CGMP -** BNP, ANP, NO
- ✓ **IP3 -** GnRH, Oxytocin, ADH (V1-receptor), TRH, Histamine (H1-receptor), Angiotensin II, Gastrin
- ✓ **Receptor tyrosine kinase -**IGF-1, FGF, PDGF, EGF, Insulin
- ✓ **Intracellular receptor -** Progesterone, Estrogen, Testosterone, Cortisol, Aldosterone, T3/T4,Vitamin D

Random

- ✓ Hypoglycemia increases:-Glucagon > Gastrin > Secretin (Ganong)
- ✓ GH is increased In:-Hypoglycemia > Exercise > NREM (Guyton + Ganong)
- ✓ Potent stimulant of Aldosterone – **Hyperkalemia & Hyponatremia**
- ✓ Potent stimulant of Renin – **Sympathetic > Hyponatremia > Hypokalemia**
- ✓ Potent Stimulant For ADH -- **Nausea > Increase Plama Osmolarity**
- ✓ Renin is Inhibited by – **Increased Angiotensin 2**
- ✓ Thirst center is stimulated by – **Angiotensin 2**
- ✓ Renin **Increase** by Hypokalemia and **Decrease** by Hyperkalemia **(Ganong)**
- ✓ Angiotensin 2 cause -- **Vasoconstriction > Thirst Stimulation (Ganong)**
- ✓ Cortisol main function – **Gluconeogenesis**
- ✓ Glucagon main function -- **Glycogenolysis**
- ✓ Cortisol **Increase** Neutrophil and **Decrease** Lymphocytes
- ✓ ACTH effectively control -- **Cortisol (Hydrocortisone) > Androgens (Guyton)**
- ✓ Lymphocytes production and **turnover** by –**Zona fasciculate(Cortisol)**
- ✓ Excessive Exercise causes – **Hyperkalemia**
- ✓ **Early** Pregnancy Endometrium Sensitive to -- **Progesterone**
- ✓ **Late** Pregnancy Endometrium Sensitive to – **Oxytocin**
- ✓ In Pregnancy Lactation inhibited by – **Estrogen + Progesterone > Estrogen >Progesterone**
- ✓ During Lactation Amenorrhea due to –**Increase Prolactin > Decrease GnRH**
- ✓ Milk **Production -- Prolactin**
- ✓ Milk **Ejaculation – Oxytocin**
- ✓ In Pre-menopausal Breast Atrophy – **Decrease Estrogen +Progesterone**
- ✓ In Post-menopausal Breast Atrophy – **Decrease Estrogen**
- ✓ Most Common Cause of Breast Atrophy – **Decreased Estrogen**
- ✓ **Osteoporosis** – Thin and wide trabeculae + long term use of Steroid
- ✓ **Osteoclasts in** -- Howhship lacunae
- ✓ **Osteoblast** -- Bone making cells + Produce ALP+ Laid Bone Matrix
- ✓ **Osteoclast** – Bone Resorption
- ✓ **Osteocytes** – Maintain Bone Matrix & Integrity
- ✓ **Demineralization of bone done by** – PTH
- ✓ **Bone Remineralization** – Vit D
- ✓ **Bone Remodeling** – Vit C
- ✓ **Osteon Has** -- Concentric lamellae
- ✓ **Patient has cast applied now has Decreased muscle mass** -- Disuse atrophy + Decreased no of actin and myosin
- ✓ Dec insulin will cause – **Ketognesis in liver**
- ✓ 5% dextrose in large amount given will cause – **inhibition of ADH**
- ✓ Harmone causes extrahepatic protein catabolism and intrahepatic protein anabolism – **Cortisol**
- ✓ Activity of osteoclasts in bone is inhibited by – **Calcitonin**
- ✓ Growth harmone synthesis and release is stimulated by – **Arginine**
- ✓ Growth haromne usesmain source for energy production – **Fat**
- ✓ Phosphorylase enzyme raise to cause glycogenolysis due to deficiency of – **Insulin**
- ✓ Concenteration of harmone doesnot change in pregnancy – **GH**
- ✓ Uncoupling of oxidation reaction – **Thyroid harmone**
- ✓ In fetus the insulin secretion is increases in – **3rd month**

CamScanner

- ✓ Half life of insulin – **5 minutes**
- ✓ Hyperkalemia will increase the secretion of – **Aldoasterone**
- ✓ Glucose increasing factor release from pancreas – **Glucagon**
- ✓ Phosphorylase enzyme raised to cause glycogenolysis due to deficienceyof – **Insulin**
- ✓ Milk production – **Prolactin**
- ✓ Milk secretion – **Prolactin**
- ✓ Milk let down or ejection – **Oxytocin**
- ✓ Indirect action of parathyroid hormone - Stimulating conversion of inactive form of vit d to active form
- ✓ harmone cause hypokalemia and Hypernatremia is -**Aldosterone**
- ✓ Receptors for Growth hormones are present on **Plasma memberane**
- ✓ Appropriate test for Growth hormone – **Insulin Stimulation test**
- ✓ **Endocrine** – Hormone which distributed in blood and bind to target cell e.g. Thyroid harmones, GH, insulin, Epinephrine Estrogen, progesterone and Testosterone
- ✓ **Autocrine** – Hormone which has effect on same cell that produce it e.g. Eicosanoids (Prostaglandins, Thromboxanes, Prostacycline and Leukotriens)
- ✓ **Paracrine** - Hormone which has affected in local area of production e.g. Somatostatin eicosanoids and histamine.
- ✓ **Neurocrine** – Secreted by neuron in presynaptic cleft and affect post synaptic cleft e.g acetylcholine and epinephrine.
- ✓ Which hormone maintains water and electrolytes – **Aldosterone**
- ✓ Hormone exhibit relation between weight and puberty – **Leptin**
- ✓ Somatic and lactogenic secretion is function of - **Pitutary**
- ✓ Primary metabolic function of insulin is - Causes to glucose shift intracellular in skeletal and some tissues
- ✓ Highest concentration of ACTH in stress in – Anterior pituitary veins
- ✓ Fetal heart maturation by - **GH**
- ✓ Fetal brain maturation by - **Thyroid hormone(T3)**

ENDO PHYSIOLOGY

1. Which hormone increases activity of lipo protein lipase?

A- Insulin
B- Growth hormone
C- Thyroid hormone
D- Glucagon
E- Cortisol

Ans: A

Explanation:
Insulin increases the activity of lipoprotein lipase and inhibits the activity of hormone sensitive lipase.

2. 6 years old girl presented to OPD with excessive facial and chest hairs" adult size external genitilia and deepening of voice. She also gives history of two siblings death suffering from same condition, which enzyme deficiency leads to this?

A. 17 - alpha hydroxylase deficiency
B. 21 hydroxylase deficiency
C. 11 B - hydroxylase deficiency
D. 22 hydroxylase deficiency

Ans: B

Explanation:
If deficient enzyme starts with 1, it causes hypertension; if deficient enzyme ends with 1, it causes virilization in females.

- 17 alpha hydroxylase cause hypertension, start with 1
- 21-hydroxylase cause virilisation in females, end with 1
- 11β-hydroxylase cause virilization + hypertension both, because start with 1 and also ends with 1

3. Which receives input from hypophysial portal system?

A. Adenohypophysis
B. Neurohypophysis
C. Pars distalis
D. Pars tuberalis
E. Para nervosa

Ans: A

4- Hormone produced by zona glomerulosa:

A. Aldosterone
B. Cortisol
C. DHEA
D. EPI
E. NE

Ans: A

Explanation:
- **Glomerulosa** – mineralocorticoids (Aldosterone)
- **Fasciculata** – Glucocorticoids (Cortisol)
- **Reticulosa** – Androgens (DHEA) GFR corresponds with Salt (mineralocorticoids), sugar (Glucocorticoids), sex (androgens).

5- 6-year-old girl presented to OPD with excessive facial and chest hair adult size external genitalis and deepening of voice, she also gives Hx of two siblings death suffering from same condition, which test would best confirm the DX?

A. Testosterone
B. Dexa - Suppression test
C. 17- Hydoxyprogesterone
D. 17 Alpha hydroxylase

Ans: C

6. CGMP is secondary receptor of:

A- Oxytocin
B- Tyrosine
C- ANP
D- ACTH
E- TSH

Ans: C

Explanation:
CGMP is secondary receptor of BNP, ANP, EDRF (no)

7. Due to stress of surgery what will increase and cause vasoconstriction?

A- ACTH
B- Cortisol
C- Catecholamines
D- Dopamine
E- Dobutamine

Ans: C

Explanation:
- Stress Hormone – Cortisol >ACTH
- Stress + Vasoconstriction – Catecholamine

8. Which of the following hyperglycaemic factor is released by pancreas?

A. Insulin
B. Somatostatin
C. Glucagon
D. Cortisol
E. GH

Ans: C (Guyton + BRS)

Explanation:
- Alpha Cells Secrete – Glucagon (Hyperglycaemic)
- Beta Cells Secrete – Insulin (Hypoglycaemic)
- Delta Cells Secrete – Somatostatin and Gastrin

CamScanner

9. Thyroglobulin is produced from:
A- Chief cells
B- Follicular cells
C- Parafollicular cells
D- Isthmus
E- Tracheal ring
Ans: B (BRS)

10. Hormone which Increases secretion in dark and causing hypogonadism?
A- Cortisol
B- GH
C- Melatonin
D- FSH
E- LH
Ans: C (Ganong + Guyton + BRS)

Explanation:
- Darkness – Melatonin
- Deep Sleep – GH & Prolactin
- Early Morning – Cortisol

11. Metabolic function of thyroid hormone is which of the following?
A- Increased calcium deposition in bones
B- Protein synthesis
C- Increase fatty acid synthesis
D- Decreased fatty acid synthesis
E- Increase Collagen Synthesis
Ans: B

12. At the end of marathon race a person has:
A- High insulin and low glucagon
B- High glucagon .and high insulin
C- High glucagon and low insulin
D- High cortisol
E- Low Cortisol
Ans: C

13. Insulin is released from which cells of pancreas?
A- Alpha cells
B- Beta cells
C- Gamma (Islets of langherhans)
D- Tail of pancreas
Ans: B

14. Single best test for thyroid disorder is:
A- T3
B- T4
C- TSH
D- TRH
E- TSI
Ans: C

15- Growth hormone stimulated by:
A- Exercise
B- Diet
C- Hypoglycaemia
D- REM
E- Catecholamines
Ans: C (Guyton + Ganong)

Explanation:
Hypoglycemia >Exercise >NREM

16. A patient came in ER with BP 160/100 having headache, fatigue and palpitation lab reveals low potassium level. What is likely cause of this condition?
A- MI
B- Hyperaldosteronism
C- Hyperaldosteronisms
D- Addison Disease
Ans: B

17. Cortisol main function is which of following?
A- Lipolysis
B- Gluconeogensis
C- Ketogenesis
D- Glycolysis
E- Protein Synthesis
Ans: B

Explanation:
- Cortisol main function – Gluconeogenesis
- Glucagon main function – Glycogenolysis

18. Which of the following is neurosecretory hormone?
A. T3
B. Cortisol
C. GH
D. Insulin
E. Oxytocin
Ans: E

Explanation:
Oxytocin and ADH are produced in the Hypothalamus and transported to Posterior Pituitary gland and known as Neurosecretory Hormones.

19. A female was taking dopamine and unable to lactate now this is because dopamine inhibits one of the following hormone:
A- Estrogen
B- Progesterone
C- Prolactin
D- NE
E- Cortisol
Ans: C (Dopamine also called prolactin inhibitor factor)

Explanation:
- Dopamine agonists (e.g. bromocriptine) inhibit prolactin secretion and can be used in treatment of prolactinoma.
- Dopamine antagonists (e.g. most antipsychotics, metoclopramide) and estrogens (eg, OCPs, pregnancy) stimulate prolactin secretion.

20. Secretion of GH is decrease by which of following?
Hypoglycaemia
A- Somatostatin
B- Deep sleep
C- Free fatty acids
D- Exercise
E-
Ans: B (Guyton + Ganong)

21- Patient with hyperthyroidism sign and symptoms will also have other problem is:
Vision problem
A- Hearing problem
B- Taste problem
C- Pressure loss
D-
Ans: A

Explanation:
Ophthalmopathy in Graves' disease (including periorbital edema, exophthalmos), lid lag/retraction (increase sympathetic stimulation of levator palpebrae superioris and superior tarsal muscle).

22. What change will be seen first in response to stress?
A- Increase ACTH
B- Increase CRF
C- Increase cortisol
D- Increase epinephrine
E- Increase Glucagon
Ans: B

Explanation:
CRF then ACTH then cortisol

23. Immunity actively works in presence of which hormone?
A- Aldosterone
B- Prolactin
C- Thyroxin
D- Melatonin
Ans: C

24. Hormone ponsible for glycolysis, gluco enesis and ketogenesis:
A- Insulin
B- Glucagon
C- Cortisol
D- Prolactin
E- Thyroid hormone
Ans: B

25- Supporting cells of pars nervosa include:
A- Kuffer cells
B- Pituitocytes
C- Astrocytes
D- Glial cells
E- Oligodendrocytes
Ans: B

26. Glucagon is stimulated by:
A- Increase Glucose
B- Fatty acid
C- Somatostatin
D- Exercise
Ans: D

Explanation:
Increase Glucagon
- Hypoglycemia
- Arginine
- CCK
- NE and Epinephrine
- Ach
- Exercise

Decrease Glucagon
- Hyperglycemia
- Insulin
- Somatostain
- Fatty acid and ketoacid

27. Insulin release is increased by:
A- Epinephrine
B- Thiazide
C- Somatostatin
D- Secretin
E- Low glucose
Ans: D

Explanation:
Factors increase insulin secretion
- Inc blood glucose
- Inc fatty acids
- Inc amino acids
- ACH
- Glucagon
- GIP
- Secretin

Factors decrease insulin secretion
- Somatostatin
- Dec blood glucose
- Nor epinephrine and epinephrine

28. Which of the following has paracrine effect?
A- Oxytocin
B- Thyroid
C- Somatostatin
D- Growth hormone
E- Secretin
Ans: C

Explanation:
- **Endocrine** – Hormone which distributed in blood and bind to target cell e.g. Thyroid hormones, GH, insulin, Epinephrine Estrogen, progesterone and Testosterone
- **Autocrine** – Hormone which has effect on same cell that produce it e.g. Eicosanoids (Prostaglandins, Thromboxane, Prostacyclin and Leukotriene)

CamScanner

- **Paracrine** – Hormone which has affect in local area of production e.g Somatostatin Eicosanoids and Histamine
- **Neurocrine** – Secreted by neuron in presynaptic cleft and affect post synaptic cleft e.g. Acetylcholine and Epinephrine.

29. Circadian Rhythm is controlled by which of the following?
A- Nerve fiber
B- Lateral Hypothalmus
C- Medial Hypothalmus
D- Hormonal Level
Ans: D (Hormone produced by Suprachiasmatic nucleus)

30. Which hormone causes bone and cartilage growth?
A- Thyroid
B- Testosterone
C- Growth hormone
D- PTH
E- Cortisol
Ans: C

31. Lipophilic hormones act through which of the following mechanism?
A- CAMP
B- CGMP
C- IP3
D- Diacylglycerol
E- Messenger RNA
Ans: E

32. Thyroid hormone receptor present in which of following?
A- Inside nucleus
B- Cytoplasm
C- Cell membrane
D- G protein coupled receptor
E- Ion channels
Ans: A (Ganong)

Explanation:
Cytoplasmic receptors
- Glucocorticoids
- Mineralocorticoids
- Androgens
- Estrogens
- Vitamin D3

Nuclear receptors
- Thyroid hormones

33- Cacl2 was given to a Rat in a laboratory which leads to hypercalcemia. Now what will increase?
A- 1,25 Dihydroxycholecalciferol
B- 24,25 Dihydroxycholecalciferol
C- Cortisol
D- Epinephrine
E- Cholecalciferol
Ans: B

Explanation:
Hypercalcemia has following effect
- Polyuria
- Leads to formation of 24,25 DHC
- 24,25 DHC will not be converted to 1,25 DHC so it affect the formation of 1,25 DHC and decrease 1,25 and Increase 24,25 DHC
- Vice versa for Hypocalcaemia

34- A patient is having hypertension on labs high sodium, low potassium in body this is due to:
A- Increase Cortisol
B- Increase Epinephrine
C- Increase Aldosterone
D- Decrease Aldosterone
E- Decrease GH
Ans: C

35. Through which function hormone released at one site, acts locally in near area:
A- Exocrine
B- Paracine
C- Endocrine
D- Neurocrine
E- Autocrine
Ans: B

36. Glucagon increase due to:
A- Epinephrine
B- High Glucose
C- Insulin
D- Somatostatin
E- Fatty Acid
Ans: A (BRS)

37- During 3rd month of embryological period the cell which invade the epidermis originate from the neural crest these cell secrete:
A- Hemosiderin pigment
B- Melatonin
C- Melanin pigment
D- Lipofuscin
Ans: C

Explanation:
Melanocyte is derived from neural crest cell and distributed in epidermis that secretes melanin pigment.

38. About Vitamin D true is:
A- 25 hydroxylation in liver and 1 alpha hydroxylation in kidneys
B- 1 alpha hydroxylation in the kidney followed by 25 hydroxylation in the liver
C- 25 hydroxylation in Lung
D- 1 alpha hydroxylation in Liver and 25 hydroxylation in Kidney
E- 1 alpha hydroxylation in Lung
Ans: A

39- Iodide oxidation to t4 formation occurs in which of following?
A- Parafollicular cells of Thyroid
B- Parathyroid cell
C- Principle cells of Thyroid
D- Parafollicular cells of Parathyroid
E- Follicular cells of Thyroid
Ans: E

40- Insulin and glucagon are released when there is increase in?
A- GH
B- Catecholamines
C- Somatostatin
D- Glucose
E- CCK
Ans: E

Explanation:
- Increase glucose increase insulin and decrease glucagon
- Catecholamine decrease insulin and increase glucagon
- Somatostatin decrease both insulin and glucagon
- CCK increase both insulin and glucagon

41. A female who is not conceiving O/E having discharge from mammary gland due to which of the following hormone?
A- Cortisol
B- Progesterone
C- Estrogen
D- Thyroxin
E- Prolactin
Ans: E

42. Hormone exhibiting relation between weight and puberty is:
A- Leptin
B- Estradiol
C- Ghrelin
D- Progesterone
E- LH
Ans: A (Ganong)

Explanation:
- Leptin and estradiol both can be true but leptin is better choice
- Leptin makes you lean
- Ghrelin makes you giant (obese)

43. Chondrocyte to osteoblast conversion occurs due to which of the following?
A- Thyroxin
B- GH
C- Somatotropin
D- Cortisol
Ans: B

44. What increases calcium absorption from GIT?
A- 1,25 dihydroxycholecalceferol
B- Cholecalciferol
C- PTH
D- Phosphate
Ans: A

45. Vasoconstriction by IP3 mechanism caused by:
A- ADH
B- Aldosterone
C- Angiotensin II
D- ACTH
Ans: A

46 Phosphlolipase C Acts as second messenger for:
A- Oxytoxin
B- Insulin
C- ACTH
D- Aldosterone
Ans: A

47. Shortest half life is of which hormone?
A- GnRh
B- Aldosterone
C- Prolactin
D- Thyroid
E- Testosterone
Ans: A

48. Late effect of insulin:
A- Protein synthesis
B- Lipid synthesis
C- Glucose entry
D- Fatty acid breakdown
Ans: B (Ganong)

Explanation:
- Immediate action of Insulin – Entry of potassium into cells
- Intermediate Action of Insulin – Protein Synthesis
- Late Action of Insulin -- Lipogenesis
- Action of insulin at Cellular level is – Entry of glucose into cells
- Insulin Independent Glucose uptake – Exercising Skeletal Muscle > Brain (Guyton)
- Anti Ketotic – Insulin
- Ketogenic – Glucagon

49. Which one is orexigenic hormone?
A- Alpha MSH
B- Insulin
C- Gherlin
D- Leptin
E- Serotinin
Ans: C

CamScanner

Explanation:

Increase feeding (Orexigenic)

- Neuropeptide – Y
- Mch
- Orexins A and B
- Endrophins
- Gelanin
- Gherlin
- Aminoacids (glutamate)

Decrease feeding (Anorexigenic)

- Alpha MSH
- Leptin
- Serotinin
- Norepinephrine
- Corticotropin releasing harmone
- Glucagon like peptide
- CCK
- Insulin
- Peptide YY

50. Insulin main action to low glucose is on:

A- Glycogenesis
B- Gluconeogenesis
C- Glycogenolysis
D- Protein Synthesis
Ans: A

51- Active thyroid hormone is:

A- T4
b- Free T3
C- Bound T4
D- Bound T3
Ans: B

Explanation:

- Maximum concentration of thyroid hormone – T4
- Thyroid hormone Enter in Circulation – T4
- Thyroid hormone cause fetal Brain development – T3
- Active form of thyroid hormone – T3 (Free form or Unbound is Active).

52- Inulin independent glucose uptake occurs in:

A- Hypothalamus
B- Myocardium
C- Resting skeletal muscle
D- Exercising skeletal muscle
Ans: D (Kaplan +MTB)

Explanation:

Exercising skeletal muscle > hypothalamus

53. Patient suffering from apparent mineralocorticoid excesses what will be present in this patient?

A- Hyponatremia
B- Hypertension
C- Hypovolemia
D- Hyperkalemia
Ans: B

54. Hypercalcemia leads to increase level of:

A- 1, 25 OH2
B- 24, 25 OH D2
C- Phosphorus
D- None
Ans: B

55. Preprohormone is:

A- Cortisol
B- PTH
C- Progesterone
D- T3
E- Thyroxin
Ans: B

56. TSH Act by:

A- CAMP
B- Steroid mechanism
C- IP3
D- CGMP
Ans: A

Explanation:

CAMP acts as a receptor for FSH, LH, ACTH, TSH, CRG, HCG, ADH (V2 receptors), MSH, PTH, GHRH, Glucagon, Calcitonin, Histamine H2 receptors.

57. A patient with urine osmolarity 1200 and serum osmolarity 270 likely diagnose is:

A- Nephrogenic diabetes
B- Central diabetes
C- SIADH
D- Psychogenic
Ans: C

Explanation:

- Normal serum osmolarity - 280-290 , for SIADH pOSm < 280
- If urine osmolarity 1200mEq/L and plasma osmolarity 300mEq/L then its dehydration.

58 Tyrosine kinase receptors are present:

A- Inside the cell
B- Inside nucleus
C- In cell membrane
D- Out of cell
Ans: C

59. During Lactation amenorrhea due to increase in:

A- Oxytosin
A- Prolactin
B- Procalcitonin
C- Progesterone
D-
Ans: B

Explanation:

- In Pregnancy Lactation inhibited by – Estrogen + Progesterone > Estrogen >Progesterone
- During Lactation Amonorrhea due to – Increase prolactin > decrease GnRH

60. 1/2 life of dopamine:

A- 2 min
B- 8 sec
C- 9 min
D- 1/2 hour
Ans: A

Explanation:

- Half-life – 2 min
- Steady state – 9 min

61. Hormone that acts by cyclic AMP:

A- Insulin
B- Aldosterone
C- Glucagon
D- Estrogen
Ans: C

Explanation:

CAMP acts as a receptor for FSH, LH, ACTH, TSH, CRG, HCG, ADH (V2 receptors), MSH, PTH, GHRH, Glucagon, Calcitonin, Histamine H2 receptors.

62. Iodine eliminated from the body via:

A- Urine
B- Sweat
C- Faeces
D- Tears
Ans: A

63- Woman with iodine deficiency cause?

A- Lack in water and food
B- Inborn error of metabolism
C- Poor dietary status
D- None
Ans: C

64. Specific PTH function is:

A- Inhibit excretion of phosphate
B- Inhibit synthesis 1,25 dihydrocholicalcefrol
C- Act through adenyl cyclase
D- Inhibit distal k excretion
E- Increase Calcium reabsorption
Ans: E (Guyton)

65. Hormone released from posterior hypothalamus:

A- Oxytocin
B- Growth hormone
C- LH
D- Progesterone
Ans: A

66 Insulin Dependent GLUT is:

A- GLUT 1
B- GLUT 2
C- GLUT 3
D- GLUT 4
Ans: D

Explanation:

Insulin-dependent glucose transporters:

GLUT4: adipose tissue, striated muscle

Insulin-independent transporters:

- **GLUT1:** RBCs, brain, cornea, placenta
- **GLUT2** (bidirectional): β islet cells, liver, kidney, GI tract (think 2-way street)
- **GLUT3**: brain, placenta
- **GLUT5** (fructose): spermatocytes, GI tract SGLT1/SGLT2 (Na+-glucose cotransporters): kidney, small intestine.

67. Insulin late effect:

A- K into cell
B- Glucose into cells,
C- Protein catabolism
D- Protein transcription for lipogenic enzymes
E- Protein anabolism
Ans: D

68- 34-year female with menorrhagia for last few months. Labs investigation shows increase TSH and low T3-T4 what drug is used to treat hypothyroidism in this patient:

A- Iodide
B- Thyroxine
C- PTU
D- Beta blocker
Ans: B

69. Hyperprolactinemia is due to:

A- Increase Dopamine from Hypothalmus
B- Decrease Dopamine from Hypothalmus
C- Decrease Cortisol from Hypothalmus
D- Increase Cortisole from Hypothalmus
Ans: B

70. Estrogen & Progesterone at 07 months of pregnancy are produced by:

A- Placenta
B- Corpus Luteum
C- Corpus Hemorrhagicum
D- Ovary
Ans: A

CamScanner

71. FSH is inhibited by:
A- LH
B- Testosterone
C- Inhibin
D- Dopamine
Ans: C

72. Which of the following cells are not normally present in pancreas?
A- Alpha Cells
B- Beta Cells
C- D Cells
D- Mucous Cells
E- Serous Cells
Ans: D

73. Vitamin D resistant rickets Occur in
A- Hyperparathyroidism
B- Fanconi's syndrome
C- RTA
D- Hypoparathyroidism
Ans: B

74- Growth hormone needs which of the following to increase maximum effect:
A- Insulin like growth factor
B- Cortisol
C- Aldosterone
D- Steroids
Ans: A
Explanation:
Growth Hormone needs Insulin like growth factor (Somatomedian-C) to exert maximum effect.

75. Which of the following hormone acts on NA-K ATPase?
A- Insulin
B- Glucagon
C- Cortisol
D- GH
Ans: A

76. Increase level of calcium will lead to increase in which of the following?
A- 1,25 cholecalciferol
B- 24,25 cholecalciferol
C- 1 cholecalicferol
D- 25 cholecalciferol
Ans: B

77. Drug used in hyperthyroidism in first trimester of pregnancy:
A- PTU
B- Thyroxin
C- T3
D- Iodine
Ans: A

78. Which of the following hyperglycemic factor is released by pancreas?
A- Insulin
B- Somatostatin
C- Glucagon
D- Cortisol
Ans: C
Explanation:
Glucagon is secreted via pancreas that increases blood sugar level & is hyperglycaemic in nature.

79. Which of the following hormone act on Na-K Pump:
A- Thyroxin
B- GH
C- Cortisol
D- Dopamine
Ans: A
Explanation:
Both Insulin & thyroxine acts on Na-K pump

80. Growth hormone needs which of the following hormone for sufficient and effective function?
A- Cortisol
B- Aldosterone
C- Somatomedin
D- Glucagon
Ans: C
Explanation:
GH needs Somatomedin C (IGF-I) for effective and efficient work

81. Which of the following is the action of Oxytocin?
A- Ejection of Milk
B- Production of Milk
C- Maintenance of pregnancy
D- Growth of fetus
Ans: A
Explanation:
The two main action of Oxytocin in the body are contraction of the uterus during childbirth & ejection of milk.

82. Which of the following is neurosecretory hormone?
A- ADH
B- Cortisol
C- GH
D- Insulin
Ans: A
Explanation:
Oxytocin & ADH are produced in the hypothalamus & transported to posterior pituitary gland & known as neurosecretory hormones.

83. Which of the following is an important hormone for parturition?
A- Fetal Cortisol
B- Fetal ACTH
C- Fetal Adrenals
D- Prostaglandins
Ans: A
Explanation:
For parturition initiation prefer Fetal Cortisol > Fetal ACTH.

84. A 30 years old female presented to OPD with excess hair growth, hypertension, hyperglycemia, hyperpigmentation, increased depression, edematous face, increased fat on chest & trunk, it's likely due to excess of:
A- Cortisol
B- ACTH
C- GnRH
D- LH
Ans: B
Explanation:
This is scenario of Cushing disease as there's pigmentation history and that's due to increase ACTH level.

85. A patient presented with hypertension & raised Sodium, low Potassium &raised PH what could the possible underlying reason:
A- Hyper aldosteronism
B- Pheochromocytoma
C- Increase Cortisol
D- Increases Glucagon
Ans: A

86. Excessive Glucocorticoids causes which of the following?
A- Neutropenia
B- Basopenia
C- Lymphocytopenia
D- Thrombocytopenia
Ans: C

87. Which of the following is important function of progesterone?
A- Lactation inhibition
B- Fetal well being
C- Endometrial thickness maintenance
D- Ripening of cervix
Ans: C

88- Patient having history of weight gain, hoarseness of voice, lab shows high TSH & cholesterol, TRH was administered that leads to an exaggerated increase in TSH level where does the problem lies:
A- Thyroid
B- Hypothalamus
C- Anterior pituitary gland
D- Posterior pituitary gland
Ans: A

89. Which of the following decreases osmolarity?
A- Vasopressin (ADH)
B- Epinephrine
C- Aldosterone
D- Renin
Ans: A
Explanation:
Vasopressin (ADH) absorbs water & decreases plasma osmolarity.

90. Which of the following hormone increases during sleep?
A- GH
B- Cortisol
C- Insulin
D- Glucagon
Ans: A

91. Supraoptic nucleus secretes:
A- ADH
B- Oxytocin
C- AG2
D- Renin
Ans: A
Explanation:
- ADH is mainly secreted by Supraoptic nucleus.
- Oxytocin is mainly secreted by Paraventricular nucleus.

92. Urine examination of a patient with diabetes demonstrates ketone bodies, what is the mechanism of formation of these ketone bodies?
A- Insulin deficiency
B- Hyperglycemia
C- Defective fat metabolism
D- Hyopalbuminemia
E- Defective glucose metabolism
Ans: A

93. Growth hormone increases in which of the following condition?
A- Exercise
B- REM
C- NREM
D- Stress
Ans: A
Explanation:
Hypoglycemia > exercise > sleep

CamScanner

94. Which of the following hormones is of immense importance to assess thyroid function?
A- T3
B- Calcitonin
C- T4
D- TSH
E- T3 & T4
Ans: D

95. Testosterone is synthesized by:
A- Seminiferous tubules
B- Sertoli cells
C- Leydig cells
D- Parenchymal cells
Ans: C

Explanation:
Luteinizing Hormone (LH) causes testosterone synthesis from Leydig cells.

96. Development of breast lobules and alveoli:
A- Estrogen
B- Progesterone
C- FSH
D- LH
Ans: B

Explanation:
- **Progesterone** – Maintain Endometrial Thickness (Proliferation) >Secretory phase > Alveoli and lobule development.
- **Estrogen Function** – Breast duct Development + endometrial proliferation.

97 cAMP second messenger system acts through:
A- Protein change
B- Receptors
C- Signals
D- Clearance
Ans: B

98- A person on exogenous steroids would have:
A- Increase blood levels of ACTH
B- Decrease blood levels of ACTH
C- Increased cortisol
D- Increased insulin
Ans: B

99- A patient present with agalactorrhea and amenorrhea, his labs reveal a prolactin level of 6500ng/ml. This condition best describes:
A- Micro adenoma
B- Macro adenoma
C- Normal condition
D- Pituitary adenoma
Ans: B

100. Which of the following is ketoacidosis?
A- Lactic acid
B- Salicyclic acid
C- Carbonic acid
D- Acetoacetate
Ans: D

101. Blood loss during C-Section would result in:
A- Infarction
B- Atrophy of adrenal cortex
C- Atrophy of medulla
D- Renal atrophy
Ans: B

102- The level of PTH is usually raised in:
A- Precocious puberty
B- Pseudohypoparathyroidism
C- Carcinoma
D- CCF
E- Adrenal failure
Ans: B >C

103. A patient has congestive cardiac disease and secondary hyperaldosteronism. This condition is due to:
A- ACTH
B- Renin
C- Cortisol
D- Insulin
Ans: B

104. Abnormal overgrowth thickening of bone is due to:
A- Chief cells of parathyroid
B- Cells of adenohypophysis
C- Pars intermedia
D- Leydig cells
Ans: B

Explanation:
Cells of adenohypohysis secrete growth hormone & that leads to abnormal growth & thickening of bones as in gigantism & acromegaly.

105- Proliferation of the mammary ducts (lactiferous ducts) and fat deposition in breast is primarily by:
A- LH
B- FSH
C- Estrogen
D- Progesterone
Ans: C

106 Osteoporosis shows which of the following lab values?
A- Normal PTH
B- Increase PTH
C- Decrease PT
D- Increase Calcium
Ans: A

106. A patient having acromegaly & amenorrhea adenoma of:
A- Acidophils
B- Adenohyophysis
C- Basophils
D- Posterior Pituitary
Ans: A

108. Decrease PO4, Increase Calcium will decrease which of the following?
A- 1,25 Vitamin D
B- 24,25 Vitamin D
C- 1,24 Vitamin D
D- Renin
Ans: A

109. Suckling response causes:
A- Decrease GnRH
B- Decrease FSH
C- Decrease LH
D- Decrease Oxytocin
Ans: A

110. Common feature of glucagon and epinephrine?
A- Proteolysis
B- Vasoconstriction
C- Decrease Glucose
D- Phosphorylase kinase activity
Ans: D

111. Cortisol and Fatty acid metabolism. Hormone involved is:
A- Inulin
B- Prolactin
C- Insulin
D- T4
E- GnrH
Ans: C

112. Hormone responsible for development and proliferation of duct, Alveoli and secretion of breast tissues?
A- Prolactin
B- Estrogen
C- Progesterone
D- Oxytocin
Ans: A

Explanation:
Progesterone has no role in Breast Secretion in contrast it inhibits secretion.

113. Which helps in regulation of extracellular potassium?
A- Insulin
B- Glucagon
C- Cortisol
D- Epinephrine
Ans: A

114-. In a young female pt. with prolactin level 28 (normal 26) but no agalactorrhea & any other pathological finding.What will you do?
A- Rule out physiological cause
B- Pituitary profile
C- CT/MRI pituitary
D- Perimetry
Ans: A

115. An 32 years old obese male comes complaining of rapid heart rate, 9kg weight loss in 2 months and heat intolerance. His pulse is 110/min and serum T4 levels are elevated. Upon questioning, he admits to taking thyroxin tablets for losing weight. The parameter which shows an increase is?
A- Serum cortisol
B- Serum free T4
C- Serum TSH
D- Serum T3
Ans: B

116. An old lady with cushing syndrome what will be characteristics?
A- Hyperpigmentation
B- Abdominal striae
C- Pot belly.
D- Amenorrhea
Ans: B

117. What will increase in serum due to vitamin D/function of vitamin D?
A- Increase serum PO4 level
B- Decrease serum PO4 Level
C- Decrease Serum Calcium Level
D- Increase Serum Magnesium Level
Ans: A

118. BMR in resting condition maintained mainly by:
A- Liver
B- Heart
C- Kidney
D- Brain
Ans: A

119. Na/K pump act by:
A- Pump Potassium Against the gradient
B- Throw 3K for 2Na
C- When Ca+ increase intracellularly
D- When Na + increase intracellularly
Ans: A

120. Steroids act by:
A- cAMP activation
B- Gene alteration
C- CGMP activation
D- Tyrosine kinase pathway
Ans: B

CamScanner

121. Lipogenesis, glycolysis is a function of which hormone?
A- Insulin
B- Gh
C- Cortisol
D- PTH
E- Thyroid hormones
Ans: A

122. Hyperfunction thyroid effect on heart:
A- Tachycardia
B- Increase PR interval
C- Vulvular disease
D- Bradycardia
Ans: A

123. Highest concentration of ACTH in stress seen in:
A- Veins of pituitary
B- Hypophysial arteries
C- Antpituitary
D- Posterior pituitary
Ans: A

124. Glucocorticoids cause:
A- Increased amount of collagen
B- Decreased amount of free fatty acids in blood
C- Decreased intracellular utilization of glucose
D- Increased amino acid breakdown in blood
Ans: C

125- Melatonin:
A- Produced by tyrosine
B- Increased in darkness
C- Increase sexual precocity
D- Decreases/inhibits CRH
Ans: B

126- Vasopressin and oxytocin originate in:
A- Hypothalamus
B- Anterior pituitary
C- Cerebellum
D- Medulla
Ans: A

127. Hormone causing increased follicular growth and maturation:
A- LH
B- FSH
C- Estrogen
D- HCG
Ans: B

128- Which hormone is responsible for multiple fractures in patient on dialysis?
A- PTH
B- Cortisol
C- Low Vitamin D
D- Epiandristenedione
Ans: A

129. Breast atrophy in old age due to:
A- Decrease estrogen, progesterone
B- Decrease estrogen
C- Decrease progesterone
D- Increase Oxytoxin
Ans: B

Explanation:
- Breast Atrophy in Young Female – Deficiency of Estrogen & Progesterone
- Breast Atrophy in Elderly Female – Deficiency of Estrogen
- Most Common Cause of Breast Atrophy – Deficiency of Estrogen

130. Increased t3 and t4 in pregnancy due to:
A- Inc. TBG
B- Inc. TSH
C- Inc. TRH
D- All of the above
Ans: A

131. Latent tetany seen in:
A- Hyperparathyroidism
B- Graves' disease
C- Addison disease
D- Conn's disease
E- Cushing disease
Ans: D

132. Which of the following is not directly caused by cortisol in Cushing's syndrome?
A. Buffalo hump
B. Thin lower limb
C. Hirsutism
D. Pendulous Abdomen
Ans: C

133. Not secreted from zona Reticularis:
A- Cortisol
B- Aldosterone
C- Testosterone
D- Cortisone
E- Androstenedione
Ans: A

134. Zona glomerulosa secretion controlled by:
A- Angiotensin
B- Renin
C- Sympathetic
D- K
E- Na
Ans: A > D (Guyton)

135. Thermo genic effect of which hormone?
A- Cortisol
B- Progesterone
C- Estrogen
D- Growth Hormone
Ans: B>D

136. Vit. D3 is called:
A- Plant origin
A- Animal origin
B- 1, 25 (oh)2
C- None
D- B
Ans: B

137. Pars distalis contain:
A- Pituitcytes
A- Acidophils
B- Axons
C- Pinealocytes
D- Herring bodies
E- A
Ans: A

138- C AMP mechanism:
A- Insulim
B- FSH
C- BNP
D- Progesterone
E- Growth hormone
Ans: B

139. A tall young girl (child) with history of secretion from breast on microscopy of anterior pituitary, which cells are abundant?
A- Eosinophilic
B- Basophilic
C- Chromophores
D- Neutrophils
Ans: A

140. In diabetes, which cells have lost their function?
A- Alpha cells
B- Receptors are lost
C- Beta cells
D- Delta cells
Ans: C

141. Which of the following is not essential for normal biosynthesis of thyroid hormones?
A- Iodine
B- Thyroglobulin
C- Ferritin
D- TSH
Ans: C

142. Fetal heart maturation by
A- Growth hormone
B- Thyroid hormone
C- ADH
D- Prolactin
E- TRH
Ans: A

Explanation:
- Fetal heart - GH
- Fetal brain - Thyroid hormone

143. Hormone produced in normal concentration during pregnancy:
A- GH
B- Cortisol
C- PTH
D- Estrogen
Ans: A

144- Patient has puffy skin and hoarse voice. Her plasma TSH concentration is low but increases markedly when she is given TRH she probably has?
A- Hyperthyroidism with problem in thyroid
B- Hyperthyroidism with problem in pituitary
C- Hyperthyroidism with problem in hypothalamus
D- Hypothyroidism with thyroid problem
E- Hypothyroidism with hypothalamus problem
Ans: E (BCQ Ganong)

145. Melatonin and ACTH are involved in circadian rhythms. Which part is responsible for regulating circadian rhythms?
A- Supraoptic nucleus
B- Pre optic nucleus
C- Suprachaismatic nucleus
D- Para optic nucleus
Ans: C

146. Which is an immunostimulatory hormone?
A- GH (before puberty)
B- Cortisol
C- Thyroxine
D- Thyroid hormone
Ans: A

147- A patient has developed bitemporal heminopia. Which structure is compressing on optic chiasma?
A- Pituitary gland
B- Hypothalamus
C- Thalamus
D- Pineal gland
Ans: A

148. Somatic and lactogenic secretion is function of:
A- Thyroid
B- Pituitary
C- Hypothalamus
D- Adrenal
Ans: B

CamScanner

149. Aldosterone acts on:
A- Nucleus
B- PCT
C- Loop of Henley
D- Cell membrane of DCT
E- Cell membrane of collecting tubules
Ans: A

150. Aldosterone deficiency leads to:
A- Low sodium
B- Low potassium
C- High calcium
D- Malignant HTN
Ans: A

151- Insulin secretion increased mainly by:
A- Increased glucose level
B- Increased glucagon
C- Increased ketone bodies level
D- Hypoglycaemia
Ans: A

152. Liver activates glycogen phosphorylase in deficiency of what?
A- Insulin
B- Decreased glucagon
C- Somatomedins
D- Gherlin
Ans: A

153- Primary metabolic function of insulin is:
A- Causes to glucose shift intracellular in skeletal and some tissues
B- Move fatty acid inside the cell
C- Glycogenesis
D- Shift K+ into cells
Ans: A

154. One hour before meal RBS check, it's under control of:
A- Insulin
B- Glucagon
C- cortisol
D- PTH
E- Prolactin
Ans: B

155. During child birth, women suffer a serious haemorrhage and goes into shock after she recovers, she displays symptoms of hypopituitarism, which of following will not expected in this patient?
A- Cachexia
B- Infertility
C- Pallor
D- Intolerance to stress
Ans: A

156. Cortisol causes:
A- Decrease lymphocyte
B- Decrease neutrophils
C- Decrease eosinophil's
D- Decrease RBC
E- Decrease Platelets
Ans: A

Explanation:
Cortisol cause decreased lymphocytes and esinophills and increase neutrophil.

157. Which hormone deficiency causes death in 3 – 4 days?
A- GH
B- Aldosterone
C- Melanin
D- TSH
Ans: B

158. In Thyrotoxicosis (inc. thyroxin) what metabolic activity happens?
A- Gluconeogenesis
B- Lipogenesis
C- Protein synthesis
D- Atherosclerosis
Ans: A

159. Which hormone act via cAMP Mechanism?
A- Glucagon
B- Oxytocin
C- Insulin
D- Estrogen
Ans: A

160. Hormone acts through IP3 mechanism:
A- GnRH
B- iGF-1
C- FSH
D- LH
E- ACTH
Ans: A

161. Hormone that stimulates hunger:
A- Gherlin
B- Leptin
C- Insulin
D- Calcitonin
E- Parathyroid hormone
Ans: A

162. Which one is action of cortisol?
A- Decrease appetite
B- Decrease insulin resistance
C- Increase gluconeogenesis
D- Decrease lipolysis
E- Decrease bone formation
Ans: C

163. Which if the following pituitary hormones is an opioid peptide?
A- Alpha MSH
B- Beta – MSH
C- Growth hormone
D- ACTH
E- Beta endorphin
Ans: E

164- Which of the following is responsible for uncoupling of oxidative phosphorylation?
A- Epinephrine
B- Glucagon
C- Cortisol
D- Thyroxin
E- GH
Ans: D

Explanation: NE > Thyroxin > Epinephrine

165- Mechanism of action of steroid hormones
A- Act on genes
B- Act on cytoplasm
C- Act on receptors in cell membrane
D- Act on Proteins
Ans: A

166- Hormone secreted by anterior pituitary is:
A- Dopamine
B- GnRH
C- TSH
D- ADH
E- Oxytoxin
Ans: C

167- Which hormone always acts through CAMP second messenger system?
A- TSH
B- Dopamine
C- Glucocirticoid
D- ADH
E- ANP
Ans: A

168- Which hormone maintains water and electrolytes?
A- Ag2
B- Aldosterone
C- TSH
D- ADH
E- Cortisol
Ans: B

169- Calcium and phosphorous balance regulated by which of the following?
A- Vitamin D
B- PTH
C- GH
D- Cortisol
E- GH
Ans: B

170- Pathogenesis of Myasthenia gravis defect will be in:
A- Acetylcholine receptors destroyed
B- Acetylecholine receptor increased
C- Acetlycholine release more
D- Acetylecholine act on muscles
E- Acetylecholine receptor over stimulation
Ans: A

171- Appropriate test for Growth hormone
A- Fasting early morning GH
B- 2 hours Post prandial
C- Insulin stimulation test
D- Insulin suppression test
Ans: C

162. Mechanism of action of steroid hormones:
A- Increase cell membrane permeability
B- Act on DNA
C- CAMP
D- Adenylate cyclase
E- IP3
Ans: B

173- In which conditions there is hyponatremia
A- Increase aldosterone.
B- Increase Cortisol
C- Increase ADH
D- Water loss from body
Ans: C

174- Hormone acting nearby area this is example of:
A- Endocrine
B- Exocrine
C- Autocrine
D- Paracrine
A- Neurocrine
Ans: D

Explanation:
- **Endocrine** – Hormone which distributed in blood and bind to target cell e.g. Thyroid harmones, GH, insulin, Epinephrine Estrogen, progesterone and Testosteron
- **Autocrine** – Hormone which has effect on same cell that produce it e.g. Eicosanoids (Prostaglandins, Thromboxanes, Prostacycline and Leukotriens)

CamScanner

- **Paracrine** - Hormone which has affected in local area of production e.g. Somatostatin eicosanoids and histamine.
- **Neurocrine** – Secreted by neuron in presynaptic cleft and affect post synaptic cleft e.g acetylcholine and epinephrine.

175- Receptors for Growth hormones are present in which part?
A- Inside the nucleus
B- On the nuclear membrane
C- Inside Receptor
D- Cytoplasm
E- On Plasma membrane
Ans: E

176- Which hormone causes hypokalemia and Hypernatremia:
A- GH
B- Cortisol
C- TSH
D- Aldosterone
E- Glucagon
Ans: D

177- Indirect action of parathyroid hormone?
A- Ca absorption
B- Phosphate excretion
C- Inactivate vitamin D
D- Stimulating conversion of inactive form of vit d to active form
Ans: D

178- Secretion of milk from breast gland is by:
A- Oxytocin
B- Prolactin
C- Aldosterone
D- GH
E- Thyroxin
Ans: B
Explanation:
- Milk production – Prolactin
- Milk secretion – Prolactin
- Milk let down or ejection – Oxytocin

179- GH increase by
A- REM sleep
B- Cortisol
C- Fed state
D- Fasting
Ans: D

180- A women with the sign and symptoms of cushing syndrome in this female the precursor for the important hormone of cushing syndrome is:
A- Progesterone
B- Estrogen
C- Cholechin
D- Testosterone
Ans: A

181- Which hormone stores carbohydrate protein and fats:
A- Glucagon
B- CCK
C- Serotonin
D- Insulin
E- Thyroxine
Ans: D

182- Hormone sensitive lipase in adipose tissue helps to mobilize fat which act through
A- Insulin activation
B- By Camp activation
C- By Cgmp activation
D- By Gene activation
Ans: B

183- Which hormone is mainly raised in crisis/emergency situation?
A- Catecholamines
B- Cortisol
C- Thyroxine
D- Insulin
E- GH
Ans: B

184- In Dehydration which of following will be raised:
A- GH
B- Cortisol
C- ANP
D- ADH
Ans: D

185- Anti GnRH harmone secreted in Dark is
A- Cortisol
B- Thyroxin
C- Insulin
D- Glucagon
E- Melatonin
Ans: E

186- First step in thyroid hormone synthesis
A- Binding of iodine to tyrosine
B- Deiodination
C- Demythylation
D- Oxidation of free iodide
Ans: D
Explanation:
- In thyroid hormone synthesis 1st step – oxidation of iodide
- In thyroid hormone formation 1st step – Binding of Iodine to Tyrosine

187- Max no of beta cells in Islets of langerhans are present in
A- Neck of pancreas
B- Tail of pancreas
C- Head of pancreas
D- Ampulla of vater
Ans: B

188- A man working in hot environment ---- having sweating lead to ------
A- Hypoosmolar ECF
B- Urine Hypoosmolar
C- ADH release
D- Negative water lose
Ans: C

189- Immediate action of insulin is
A- Protein synthesis
B- K entry into cells
C- Glucose entry in plasma
D- Fatty acid breakdown
E- Ketosis
Ans: B (Ganong)
Explanation:
- Immediate action of insulin – Entry of potassium into cells
- Intermediate action of insulin – protein synthesis
- Late action of insulin – Lipogenesis
- Action of insulin at cellular level is – Entry of glucose into cells
- Insulin independent glucose uptake – Exercising skeletal muscle > Brain(MTB)
- Anti Ketotic – Insulin
- Ketogenic – Glucagon

190- Which factor regulates 1,25 dihydroxycholicalciferol?
A- PTH
B- 25 hydroxycholicalciferol
C- Calcium level
D- Phosphorus level
E- Anions
Ans: C

191- Regarding Zona fasciculata of adrenal glands
A- ACTH act to produce Corticosteroid
B- Produce Androgens
C- Produce Aldosterone
D- Produce Catecholamines
Ans: A

192- Which test to be done to know hypothyroidism?
A- ACTH
B- T3
C- TSH and Free T4
D- Calcitonin
E- Iodine level
Ans: C

193- Hormone causing glycogenolysis and gluconeogenesis in liver secreted from?
A- Alpha pancreatic cells
B- Beta pancreatic cells
C- Gamma cells
D- Tail of pancreas
E- Delta cells
Ans: A

194- In male breast secretion and Gynecomastia is produced by
A- Estrogen
B- Progesterone
C- Prolactin
D- Thyroird harmone
Ans: C

195- Vasopressin secretion is increased by:
A- Increased pressure in the right ventricle
B- Decreased pressure in the right ventricle
C- Increased pressure in the right atrium
D- Decreased pressure in the right atrium
E- Increased pressure in the aorta
Ans: D

196- Glucagon decreases which one of the following:
A- Amino Acids
B- Calcium
C- Ketones
D- Fatty acids
E- Glucose
Ans: D

197- Which of following acts via phospholipase?
A- Prolactin
B- Oxytocin
C- ACTH
D- FSH
E- Aldosterone
Ans: B

198- In hyperaldosteronism there is:
A- Increased urine osmolarity
B- Increased plasma osmolarity
C- Decresed urine sodium
D- Increased urine sodium
Ans: B

199- Hormone required for brain development in fetal life:
A- Thyroid hormone
B- Growth hormone
C- Cortisol
D- Androgen
E- Insulin
Ans: A

CamScanner

200- Which hormone store carbohydrates, proteins and Fats:
A- Glucagon
B- Insulin
C- Cortisol
D- Aldosterone
E- T4
Ans: B

201- ADH level decrease by
A- Angiotensin
B- Hyper osmolarity
C- Diuretic
D- Increase plasma volume
Ans: D

202- Epinephrine causes:
A- Decrease Glycigenolysis
B- Decrease Gluconeogenesis
C- Increase Glycogenolysis
D- Increase Glucose uptake
Ans: C

203- Insulin used in following:
A- Resting skeletal muscle
B- Exercising skeletal muscle
C- Hypothalamus
D- Brain
Ans: A

204- Which hormone is activated in lungs?
A- Vasopressin
B- Serotonin
C- Angiotensin 2
D- GABA
E- Oxytoxin
Ans: C (Ganong)
Explanation:
- Bradykinin and serotonin both inactivated by lung
- Activated in lung – Angiotensin 2

205- In the last trimester of pregnancy what change in respiratory parameters occurs?
A- Decreased FEV/FVC
B- Decreased vital capacity
C- Increased lung compliance
D- Decrease CO2
E- Decrease tidal volume
Ans: D

206- On 4th postpartum day mother wants to feed baby what changes will occur:
A- Decrease Cortisol
B- Increase dopamine
C- Increase prolactin by pituitary
D- Increase Oxytoxin by Hypothalamus
Ans: C

207- The secretory hormones from neurohypophysis are stored in?
A- Pituicytes
B- Herring bodies
C- Pinealocytes
D- Nerve ending
E- Astrocytes
Ans: D

208- Bone demineralization done by:
A- Vitamin D
B- Vitamin E
C- Vitamin C
D- PTH
E- ADH
Ans: D
Explanation:
- Osteoblast – Bone making cells + Produce ALP+ Laid bone matrix
- Osteoclast – Bone resorption
- Osteocytes – Maintain bone matrix & integrity
- Bone remodeling – Osteoblast + Osteoclast
- Demineralization of bone done by – PTH
- Bone Remineralization – Vit. D
- Bone Remodeling Vitamin – Vit. C

209- Which one is used in home pregnancy test?
A- PSA
B- Acid phosphatase
C- B-HCG
D- Fructose
Ans: C

210- Girl with coarse facial features, gap between incisors and spade like hands what happens to muscles involved in this disease?
A- Enlargement
B- Myositis
C- Regression
D- Fibrositis
E- Muscle hyperplasia
Ans: A (Acromegaly)

211- After hemorrhage which one causes increase Sodium and water absorption?
A- ADH
B- Aldosterone
C- ANP
D- Renin
Ans: B

212- Osmoreceptors of ADH inhibited by:
A- Hyponatremia
B- Increase osmotic pressure
C- Shrinkage of osmoreceptors
D- Swelling of cell
E- Overhydration
Ans: E

213- After complete endocrine and gonadal development ovulation starts regularly?
A- After 1 year
B- After 2 year
C- After 3 year
D- Menarche
Ans: D

214- Effect of Angiotensin 3 is:
A- Catecholamine release
B- ADH release
C- Aldosterone release
D- Renin release
E- Stop Renin
Ans: C

215- Action of PTH is
A- Ca excretion
B- Ca Absorption from kidney
C- Activation of Vitamin D
D- Increase phosphate absorption
Ans: B
Explanation:
- Direct action : Ca absorption from Kidney
- Indirect action : Ca absorption from Intestine via Vitamin D

216- Growth hormone increased by:
A- REM
B- Hypoglycaemia
C- Hyperglycaemia
D- Hypercalcemia
Ans: B

217- Effect of insulin on adipose tissue?
A- Causes gluconeogenesis
B- Causes glycogenolysis
C- Stimulate hormone sensitive lipase
D- Inhibit lipoprotein lipase
E- Activate Lipoprotein lipase
Ans: E
Explanation:
- Insulin activate Lipoprotein lipase and inhibit hormone sensitive lipase

218- There is no edem[illegible]e to inc aldosterone because of
A- Increase Na/k activity of thick Ascending limb
B- Decrease thirst mechanism
C- Escape mechanism
D- Increase ADH
E- Decrease ANP
Ans: C

219- Thyroid hormone increase in pregnancy due to
A- Low Thyroid binding globulin
B- High Thyroid binding globulin
C- Fetal thyroid hormone secretion occurs
D- Thyroiditis
Ans: B

220- A patient got trauma and now bleeding his BP 80/60 and Plasma volume is decreasing. Which one of following will increase?
A- ANP
B- Cortisol
C- ADH
D- Growth hormone
Ans: C

221- ADH short term action is:
A- Vasodilation of arterioles
B- Vasoconstriction of arterioles
C- Secrete Renin
D- Reabsorption of salts
Ans: B

222- Hyperkalemia stimulates which one of the following:
A- Cortisol
B- Renin
C- Angiotensin
D- Aldosterone
Ans: D

223- Mechanism of action of insulin:
A- Decrease K inside the cell
B- Inhibit lipoprotein lipase
C- Increase in K inside cell
D- Increase in sodium inside cell
Ans: C

224- Adrenal medulla secrete hormones which function same as
A- Preganglionic sympathetic adrenergic
B- Postganglionic parasympathetic adrenergic
C- Postganglionic sympathetic adrenergic
D- preganglionic parasympathetic adrenergic
Ans: C

225- Osteoporosis occur due to which of following hormone deficiency
A- Cortisol
B- Insulin
C- PTH
D- Estrogen
Ans: D

226- Which hormone causes extra hepatic protein catabolism and hepatic protein anabolism?
A- Thyroid hormone
B- Epinephrine
C- Cortisol
D- Growth hormone
E- Insulin
Ans: C

CamScanner

227- True regarding Growth hormone is:
A- Inhibit growth of Bone
B- Stimulated by somatostatin
C- IGF released from liver and growth harmone interact with it
D- It is monopeptide
Ans: C

228- In Zona glomerulosa aldosterone released under the influence of:
A- Angiotensin 2
B- Renin
C- Sympathetic
D- Ca
E- Na
Ans: A

229- Level of LH peak how many hours before ovulation?
A- 12
B- 15
C- 10
D- 6
Ans: A

230- Fetal brain development by:
A- Growth hormone
B- Thyroid hormone
C- ADH
D- Prolactin
E- TRH
Ans: B
Explanation:
- Fetal heart - GH
- Fetal brain - Thyroid hormone(T3)

231- Amount of oxytocin causing water retention in kidney:
A- 20%
B- 5 IU
C- 20 IU
D- 5 IU
Ans: C
Explanation:
20 IU or 5%

232- PTH indirect action is?
A- Excretion of phosphate
B- Calcium absorption from intestine
C- Osteoclast cell activation
D- Excrete Ca
Ans: B

233- Aldosterone stimulated by:
A- Increase K
B- Decrease K
C- Increase Na
D- Increase Ca
Ans: A

234- Insulin cause glucose entry in which cell:
A- Skeletal muscle
B- Mucosa of small intestine
C- Hypothalamus
D- Cerebrum
Ans: A

235- Adrenal medulla secretes hormones
A- Epinephrine :Cortisole 80:40
B- Epinephrine:Norepinephrine 80:20
C- Epinephrine :GH 40:20
D- Norepinephrine : Cortisole 80:40
Ans: B

236- Which hormone is mainly released early in stress?
A- Catecholamines
B- Melanin
C- Thyroxine
D- ACTH
E- GH
Ans: D(Guyton)
Explanation:
Stress hormone – Cortisol >ACTH
Stress + Vasoconstriction – Epinephrine
Stress Early changes events as – CRF (Hypothalamus) > ACTH (Pituitary) > Cortisol (Adrenal).

237- At puberty testosterone function in?
A- Thickening of laryngeal cartilage and deepening of voice
B- External genitalia appearance
C- Pubic hair distribution upward
D- Sharp voice
Ans: A

238- ECF osmolarity regulated by:
A- Cortisol
B- GH
C- Aldosterone
D- TSH
Ans: C
Explanation:
Water & electrolytes regulated by- Aldosterone
ECF Osmolarity regulated by- ADH/Vasopressin

239- Part of pituitary gland at infundibulum called?
A- Pars nervosa
B- Pars tuberalis
D- Pars distalis
D- Pars intermedia
Ans: B

240- Dopamine regulates which one:
A- GH
B- Cortisol
C- Prolactin
D- TSH
Ans: C

241- Which hormone use phospholipase C as a secondary messenger?
A- Oxytocin
B- Thyroxin
C- GH
D- ADH
Ans: A

242- Thyroid hormones bind with:
A- TSI
B- T4
C- TSH
D- Thyroid binding globulin
Ans: D

243- Almost all of the active thyroid hormone released in circulation is?
A- Reverse t4
B- Thyroxine
C- Triiodothyronine
D- Reverse t3
Ans: B

244- Which hormone converts to its active form by 5 alpha reductase in peripheral tissue?
A- DHT
B- Testosterone
C- Estrogen
D- Estriol
Ans: B

245- Aldosterone Act mainly on:
A- Distal tubule
B- Bowmen capsule
C- PCT
D- JG cell
Ans: A
Explanation:
ADH act on Collecting Ducts > Distal Convoluted Tubules (DCT) > Collecting Tubules (CT)
Aldosterone act on Cortical Collecting Tubules > Distal Convoluted Tubules (DCT) > Collecting Ducts (CD).

246- After Hypophysectomy which cells will be effected?
A- Follicular cells of thyroid
B- Chief cells of parathyroid
C- Principal cell of parathyroid
D- Cells of Adrenal Medulla
E- Beta Cells of Pancreas
Ans: A

247- Thyroid hormone is inactivated in peripheral system by liver through:
A- De methylation
B- De iodination
C- De amination
D- De acetylation
Ans: B
Explanation:
- TSH - Demethylation
- Thyroid hormone - Deiodination

248 Protein anabolism, fat catabolism is done by:
A- GH
B- Insulin
C- HCG
D- Thyroxin
E- Cortisol
Ans: A

249- Insulin mechanism of action via:
A- Transcription factors
B- CAMP pathway
C- Tyrosine kinase pathway
D- CGMP pathway
E- NF-KB pathway
Ans: C

250- Increase Ca level is due to:
A- Increase 25 dihydroxycholicalceferol
B- Increase PTH
C- Decrease PTH
D- Decrease Aldosterone
Ans: B

251- Increase Glucose /Increase fatty acids and increased growth hormone is caused by:
A- Glucagon
B- TSH
C- Insulin
D- Hyperglycaemia
Ans: A

252- Vasoconstriction is caused by:
A- Cortisol
B- GH
C- ADH
D- TSH
Ans: C

253- Gluconeogenesis occur due to decrease in:
A- Glucagon
B- Cortisol
C- Insulin
D- TSH
Ans: C

CamScanner

254- Growth hormone inhibited by which of the following hormone?
A- Cortisol
B- Aldosterone
C- Somatomedin
D- Glucagon
Ans: C

255- In hyperthyroidism, increase heart rate is due to increased sensitivity to?
A- Digoxin
B- Atenolol
C- Adrenaline
D- Amphetamine
Ans: C

256- Most likely for cortisol is:
A- Involved in protein synthesis
B- Involved in lipid synthesis
C- Increase after trauma
D- Decrease after trauma
Ans: C

257- Which of the following metabolite of Vitamin D is used for laboratory assessment
A- 1,25 Vit. D3
B- 24,25 Cholicalciferol
C- Calcium
D- 25 hydroxylase (OH)
Ans: D

258- In acute response of neurogenic trauma what will release
A- Glucagon
B- GH
C- Cortisol
D- TSH
Ans: C

259- Insulin causes glucose uptake in skeletal muscles and fat tissues by
A- GLUT 1
B- GLUT 4
C- GLUT 2
D- GLUT 6
Ans: B

260- L Dopa is given for parkinson disease, which of the following decreases from the Anterior Pituitary ?
A- GH
B- Prolactin
C- Insulin
D- Cortisol
Ans: B

261- Neuroendocrine hormone in Stress
A- CRH
B- ACTH
C- Cortisol
D- GH
Ans: C

262- 60 Years old lady presented with fracture of hip bone. Which supplement might be beneficial for the lady?
A- Ergocalciferol
B- 1,25(OH) 2 Cholecalciferol
C- 24,25 dihyroxycholecalciferol
D- Calcium
Ans: A

263- Which of the following is correct regarding glucagon?
A- Gluconeogenesis in liver
B- Glycogenolysis in skeletal muscle
C- It inhibits insulin secretion
D- It is increased in response to Hyperglycemia
E- Released from Beta cells of Pancreas
Ans: A

264- Thyroid Hormone increase?
A- Triglycerides
B- Cholestrol
C- Free fatty acids
D- Amino acids
Ans: C

265- Insulin release is inhibited by:
A- Epinephrine
B- Theophylline
C- Glucagon
D- Secretin
E- Somatostatin
Ans: E

Explanation:
Factors increasing insulin secretion
- Inc blood glucose
- Inc fatty acids
- Inc amino acids
- ACH
- Glucagon
- GIP
- Secretin

Factors decreasing insulin secretion
- Somatostatin
- Dec blood glucose
- Nor epinephrine and epinephrine

266- Which one of the following is correct?
A- Norepinephrine is derived from epinephrine by decarboxylation
B- Epinephrine acts on both alpha & beta receptors
C- Epinephrine to norepinephrine ratio is 20:80
D- Epinephrine is NMJ neurotransmitter
Ans: B

267- Insulin secretion inhibited by
A- Acetylcholine
B- Theophylline
C- Alpha Stimulator
D- Secretin
E- Glucagon
Ans: C

268- Intrahepatic protein anabolism and extra hepatic catabolism:
A- Insulin
B- Glucagon
C- Cortisol
D- Prolactin
E- Thyroid hormones
Ans: C

269- Common to Glucagon and Epinephrine is:
A- Glycogenesis
B- Glycogenolysis in Liver & Skeletal Muscle
C- Activate Insulin
D- Cause Hypoglycemia
E- Reactivate phosphoryl kinase in liver
Ans: B

270- Glucagon increase due to:
A- Exercise
B- High Glucose
C- Epinephrine
D- Somatostatin
E- Starvation
Ans: A

Explanation:
Increase Glucagon:
- Hypoglycemia
- Arginine
- CCK
- NE and Epinephrine
- Ach
- Exercise

Decrease Glucagon:
- Hyperglycemia
- Insulin
- Somatostain
- Fatty acid and ketoacid

271- Which hormone maintain ecf osmolarity??
A- Aldosterone
B- Vasopressin
C- Angiotensin 2
D- ANP
E- BNP
Ans: B

Explanation:
- ECF Volume regulated by -Aldosterone
- Maintain and regulates ECF osmolarity - ADH
- Regulates Serum osmolarity - ADH >Aldosterone
- Total body Water and electrolytes balance regulated by ADH
- Total body Water and electrolytes balance maintained by -Aldosterone
- Maximum Water and Na absorbed by the affect of -Aldosterone

272- Neuroendocrine hormone in Stress
A- CRH
B- ACTH
C- Cortisol
D- GH
Ans: C

273- Hormone whose secretion increased in dark &Increases Skin pigmentation along with causing hypogonadism as well:
A- Cortisol
B- Neuromelanin
C- Melatonin
D- ACTH
E- LH
Ans: C(Ganong +Guyton + BRS)

Explanation:
- Darkness – Melatonin
- Deep Sleep – GH & Prolactin
- Early Morning – Cortisol

274- Which hormone converts to its active form at target tissues with the help of 5 alpha reductase?
A- Testosterone
B- Estrogen
C- DHT
D- Estradiol
E- GnRH
Ans: A

275- Growth Hormone requires which of the following for its action?
A- Cortisol
B- Glucagon
C- Insulin
D- Estrogen
E- Epinephrine
Ans: C

CamScanner

276- Which of the following is function of insulin?
A- Increase Glycolysis
B- Increase Gluconeogenesis
C- Increase Glycogenolysis
D- Decrease Cellular glucose uptake
Ans: A

277- Patient suffering from apparent mineralocorticoid excesses what will be present in this patient?
A- Hyponatremia
B- Hypertension
C- Hypovolemia
D- Hyperkalemia
E- Hyperglycemia
Ans: B

278- Abnormal over growth and irregular thickening of bone caused by
A- Chief cells of thyroid
B- Cells of adenohypophysis
C- Cells of parsintermedia
D- Leydig cell
Ans: B

279- One effect of androgen is to promote linear bone growth. This is transient because?
A- Androgens cause epiphyseal closure
B- Androgens increase the excretion rate of calcium and phosphate ions
C- Androgens slow the synthesis of collagen
D- Androgens stimulate bone resorption
E- Receptors for androgens are down regulated
Ans: A

280- Androgen effect on linear growth is transient because
A- Receptors are down regulated
B- cause epiphyseal growth plate arrest
C- Effect osteoblast activity
D- Effect absorption from intestine
Ans: A

281- Glucagon release increased by?
A- Cck
B- Secretin
C- Gastrin
D- Exercise
Ans: D

282- Hormone causing increase in Hepatic plasma proteins formation and Extrahepatic proteins degradation:
A- Cortisol
B- Glucagon
C- Epinephrine
D- Growth hormone
Ans: A

283- Which hormone is mainly released early in stress?
A- Catecholamines
B- Melanin
C- ACTH
D- CRH
E- GH
Ans: D(Guyton)
Explanation:
- Stress hormone – Cortisol >ACTH
- Stress + Vasoconstriction – Epinephrine
- Stress Early changes events as – CRF
- (Hypothalamus) > ACTH (Pituitary) > Cortisol (Adrenal)

284- Which of following act via phospholipase IP3 mechanism ? (Medicine Feb 2025)
A- Prolactin
B- Oxytocin
C- ACTH
D- FSH
E- Aldosterone
Ans: B

285- Hormone which produces protein catabolism in extra hepatic tissues and protein synthesis in liver: (Medicine Feb 2025)
A- GH
B- Epinephrine
C- Cortisol
D- Insulin
E- Thyroxine
Ans: C

286- The test of choice for the long term control of diabetes mellitus is? (Medicine Feb 2025)
A- Hemoglobin A1c.
B- Fasting blood sugar level.
C- RBC every 3-weeks duration.
E- Glycosylated albumin.
E- Serum fructosamin
Ans: A

287- High concentrations of epinephrine primarily exert which of the following effects on glucose metabolism? (Medicine Feb 2025)
A- Inhibit gluconeogenesis and stimulate glycogenolysis
B- Stimulate gluconeogenesis and inhibit glycogenolysis
C- Stimulate gluconeogenesis and stimulate glycogenolysis
D- Inhibit gluconeogenesis and inhibit glycogenolysis
E- No effect on glucose metabolism
Ans: C

288- What is one of the primary actions of insulin?(Medicine Feb 2025)
A- Lipolysis
B- Glycogenolysis
C- Glycolysis
D- Gluconeogenesis
Ans: C

289- Which of following act via phospholipase? (Medicine Feb 2025)
A- Prolactin
B- Oxytocin
C- ACTH
D- FSH
E- Aldosterone
Ans: B

290- Which hormone is mainly released early in stress? (Surgery Feb 2025)
A- Catecholamines
B- Melanin
C- ACTH
D- CRH
E- GH
Ans: D(Guyton)
Explanation:
- Stress hormone – Cortisol >ACTH
- Stress + Vasoconstriction – Epinephrine
- Stress Early changes events as – CRF (Hypothalamus) > ACTH (Pituitary) > Cortisol (Adrenal)

291- Secretion of Prolactin and growth hormone affected by: (Surgery Feb 2025)
A- Sleep
B- Pregnancy
C- Phenothiazine
D- Exercise
E- Nursing
Ans: A

292- True regarding Vitamin D: (Surgery Feb 2025)
A- Decrease secretion of calories from kidney
B- Excretion of Calcium from Kidneys
C- Increased Calcium absorption from Intestine
D- Increase production of calories
Ans: C(BRS Physio)
Explanation:
Actions of 1,25-dihydroxycholecalciferol
- are coordinated to increase both [Ca2+] and [phosphate] in ECF to mineralize new bone.
- Increases intestinal Ca2+ absorption
- PTH increases intestinal Ca2+ absorption indirectly by stimulating 1α- hydroxylase and increasing production of the active form of vitamin D.
- b. Increases intestinal phosphate absorption.
- c. Increases renal reabsorption of Ca2+ and phosphate, analogous to its actions on the intestine.
- d. Increases bone resorption, which provides Ca2+ and phosphate from "old" bone to mineralize "new" bone

293- I/V Cacl2 was given to a Rat in a laboratory which leads to (Surgery Feb 2025)
A- Decreased 1,25 Dihydroxycholecalciferol
B- Decreased 24,25 Dihydroxycholecalciferol
C- Increased 1,25 Dihydroxycholecalciferol
D- Increased 24,25 Dihydroxycholecalciferol
E- Cholecalciferol
Ans: D>A
Explanation:
Hypercalcemia has following effect
- Polyuria
- Leads to formation of 24,25 DHC
- 24,25 DHC will not be converted to 1,25
- DHC so it affect the formation of 1,25
- DHC and decrease 1,25 and Increase 24,25 DHC
- Vice versa for Hypocalcaemia

294- In sleep which harmone Level increases with awake (Gynae Feb 2025)
A- Cortisol
B- GH
C- Melatonin
D- FSH
E- LH
Ans: A(Ganong +Guyton + BRS.
Explanation:
Darkness – Melatonin
Deep Sleep – GH & Prolactin
Early Morning – Cortisol

295- Circadian Rhythm hormone? (Gynae Feb 2025)
A- Cortisol
B- TSH
C- Insulin
D- ADH
E- Epinephrine
Ans: A(No option of Melatonin)

296- Physiological action of PTH include all except (Gynae Feb 2025)
A- Decrease excretion of calcium
B- Decrease phosphate reabsorption
C- Increase activation of vitamin D3
D- Increase resorption of bones
E- Increase calcium reabsorption
Ans: A

CamScanner

297- **Anti depressant harmone (Gynae Feb 2025)**
A- Thyoxine
B- Cortisol
C- GH
D- Insulin
E- Glucagon
Ans: A

298- **How prolactin cause amenorrhea (Radiology Feb 2025)**
A- Inhibits Gnrh secretion
B- Stimulates the release of estrogen
C- Stimulates the Gnrh secretion
D- Increase the progesterone secretion
Ans: A

299- **Stress-Related Glycogenolysis in the Liver is Primarily Stimulated By: (Radiology Feb 2025)**
A- Glucagon
B- Cortisol
C- Epinephrine
D- Norepinephrine
F- Insulin
Ans: C

300- **Glucocorticoids are given in shock. Their beneficial role? (Radiology Feb 2025)**
A- Respiratory ways distension
B- Decreased Heart rate
C- Increased vascular responsiveness to catecholamines
D- Reduction in inflammatory cytokines
Ans: C

301- **Patient having high Glucose levels. Low insulin effect on lipid metabolism (Anesthesia Feb 2025)**
A- Ketogenesis
B- Decrease lipolysis
C- Stimulate synthesis of Fatty acids
D- Stimulate synthesis of cholesterol
Ans: A

REPRODUCTION PHYSIOLOGY

1- **Sertoli cells release:**
A- Testosterone
B- Luteinizing hormone
C- Androgen
D- Inhibin
Ans: D

Explanation:
- Androgen produce by Lydig cell.
- Serotil cell produce Androgen binding protein and Inhibin.

2- **In adult male, after removal of testis, what's the patient most likely to suffer?**
A- Hot flushing, irritability and depression
B- Loss of libido and depression
C- Decrease levels of FSH and LH
D- None
Ans: B

3- **FSH is inhibited in males by:**
A- Estrogen
B- Testosterone
C- LH
D- Inhibin
Ans: D

4- **Corpus luteum secrete mainly:**
A- Progesterone
B- Inhibin
C- Estrogen, Progesterone and Inhibin
D- Estrogen
Ans: C

Explanation:
- Corpus luteum secrete – Progesterone, Estrogen and Inhibin
- Corpus luteum secrete to maintain Pregnancy – Progesterone

5- **Development of breast alveoli and lobules by:**
A- Estrogen
B- Progesterone
C- Prolactin
D- Oxytocin
Ans: B

Explanation:
- Estrogen Function – Breast Duct Development + Endometrial Proliferation
- Progesterone Function – Maintain Endometrial Thickness (Proliferation) > Secretory phase > Alveoli and lobule development.

6- **Low testosterone level is present in:**
A- Infant
B- Old age
C- Preschool
D- Neonate
Ans: C

7- **Estrogen effect in adult female:**
A- Thick cervical mucus
B- Development of secondary sexual character
C- Enlargement of breast
D- Alveoli and lobule development
Ans: B

8- **Inhibition of GNRH during lactation is through:**
A- Estrogen
B- Progesterone
C- Prolactin
D- Inhibin
Ans: C

9- **A women on 18th day of menstrual cycle will be in which phase?**
A- Proliferative phase
B- Secretory phase
C- Ovulation
D- Follicular phase
Ans: B

10- **Corpus luteum maintained by:**
A- Progesterone
B- Beta HCG
C- Estrogen
D- Cortisol
Ans: B

11- **Best test to confirm pregnancy before 10 days:**
A- Ultrasound
B- Urine pregnancy test
C- Beta HCG
D- Detailed urine RE
Ans: C

Explanation:
- Before 10 days – Beta HCG
- After 10 days – UPT

12- **Lactation during pregnancy inhibited by:**
A- Progesterone
B- Oxytocin
C- Prolactin
D- Estrogen
Ans: D

CamScanner

Explanation:
Estrogen + Progesterone >Estrogen> Progesterone.

13- In 2nd trimester pregnancy, which hormone will not increase?
A- GH
B- Prolactin
C- Estrogen
D- Progesterone
Ans: A

14- One of the following causes endometrial hyperplasia:
A- Progesterone hormone
B- Clomiphene citrate
C- Estrogens
D- Combined oral contraceptive pills
E- Bromocriptine
Ans: C

15- Sperms store in:
A- Orostate
B- Urethra
C- Ampula
D- Seminal vesicle
E- Epidydmis
Ans: E

16- Androgen cause bone growth up to limit:
A- Cause epiphyseal plate closure
B- Cause atrophy of bone
C- Cause duaphysis closure
D- Decrease radial growth
Ans: A

17- Primigravida taking iron tablets lots of fresh vegetables and juices what deficiency she is at risk of?
A- Ca
B- Viatmin B12
C- Folicacid
D- Vitamin E
E- Vitamin B1
Ans: A

Explanation:
- Iron decreases calcium absorption so most likely its deficiency will occur. B12 has large store.

18- During lactation which of following happen:
A- Ovulation occur
B- Primordial follicle fails to develop
C- Increase follicle development
D- Cause diaphysis closure
Ans: B

19- Which cells produce inhibin to inhibit FSH?
A- Lydig cell
B- Sertoli cell
C- Mullirian cell
D- Endothelial cells
Ans: B

20. A pregnant lady having hyperemesis gravidum which acid base balance will be present?
A- Metablic Acidosis
B- Respiratory Acidosis
C- Metabolic Alkalosis
D- Respiratory Alkalosis
Ans: C

21- Progestrone is precursor of:
A- Aldosterone, Cortisol, Androstenedione
B- Cholesterol, Cortisol, Corticosterone
C- Hydrocortisone, pregnenolone, estriol
D- Cholesterol, Cortisone and cholic acid
Ans: A

Explanation:
Progesterone one, and after conversion to 17α-hydroxyprogesterone, of cortisol and androstenedione. Androstenedione can be converted to testosterone, estrone, and estradiol, highlighting the critical role of progesterone in testosterone synthesis.

22- Most likely for oxytocin:
A- Potentiated by progesterone in pregnancy
B- Potentiated by estrogen in pregnancy
C- Milk formation
D- Development of mammary glands
Ans: B

Explanation:
- Estrogen has been shown to stimulate the release of oxytocin from the hypothalamus and promote receptor binding in the amygdala estrogen is one of the two main hormones that get the pregnancy party started. Produced by the ovaries and later by the placenta, estrogen helps the uterus grow, maintains uterine lining, regulates other key hormones and triggers the development of baby's organs.

23- Which of following has less than 5% contraception failure chances?
A- Iucd, condom, tubal ligation
B- Vesctomy, tubal ligation, OCPS, Iucd
C- Rythm, C.interruptus
D- OCPs
Ans: B

Explanation:
OCPs, IUCD, Vasectomy, Tubal ligation has less than 5% failure rate…Condoms have more. Coitus interuptus has more.

24- Male external genitalia formed by:
A: DHT
B: Testosterone
C: MIF
D: Progesterone
Ans: A

Explanation:
- External ganitalia>DHT
- Internal genitalia>Testosterone
-

25. In pregnancy, respiratory changes that happen?
A- Dec TLC
B- Decrease tidal volume
C- Decrease RR
D- Increase VC
Ans: A

Explanation:
Remains same:
- Respiratory rate
- Vital Capacity

Increase:
- Tidal volume
- Minute ventilation

Decrease:
- TLC
- Residual volume

26- Woman with 24days regular menstrual cycle. When will ovulation occurs in her:
A: 10th day from the beginning (1st day) of her last menstrual period
B: 10th day from the end (last day) of her last menstrual period
C: 14th day from the start of her last menstrual period
D- 14th day from the wnd of her last menstrual period
Ans: A

27- In a woman with 28 days' regular menstrual cycle, blood tests are done and show peak levels of estradiol and no progesterone for the past 3 days. What is likely to occur soon?
A: Ovulation
B: Cessation of menstruation
C: Secretory phase
D: Regression of corpus leuteum
E: Start of menses
Ans: A (Peak level of estradiol>>at ovulation)

28- Patient having menstrual cycle of 32 days will ovulate on:
A- 18th day
B- 16th day
C- 10th day
D- 14th day
Ans: A

Explanation:
- 32 – 14 = 18

29- 25 years old married female came to you with history of amenorrhea for 3 weeks her pregnancy test is negative. What could be the cause?
A- Ectopic pregnancy
B- Anovulation
C- Appendicitis
D- Anorexia Nervosa
E- Normal
Ans: B

30- In females first pubertal change is:
A- Thelarche
B- Menarche
C- Pubarche
D- Adrenarche
Ans: A

Explanation:
Mnemonic TAM
- First – Thelarche
- 2nd – Adrenache
- 3rd – Menarche

31- A 50-year-old women with fungating necrotic growth on cervix Growth on cervix goes for radiation therapy the recommended radiation dose is:
A- 1000-2000rads
B- 7000-8000rad
C- 14000-16000rads
D- 15000-17000rads
Ans: B

32- Most potent anabolic hormone:
A- Testosterone
B- Estrogen
C- Progesterone
D- DHT
Ans: A

Explanation:
- Most Potent Anabolic Hormone – Testosterone.
- Potency – DHT >Testosterone
- Potency – Estradiole>Estrone>Estriole

CamScanner

33- During pregnancy the lumen of uterine cavity is obliterated by fusion of which of following?
A- Decidua basalis & spongy layer
B- Decidua basalis & decidua capsularis
C- Decidua capsularis & decidua parietalis
D- Decidua parictalis& deciduas basalis
E- Decidua capsularis & decidua basalis
Ans: C

34- Which of the following will indicate ovulation has occurred?
A- Mucinous discharge
B- Raised body temperature
C- Corpus luteum secretion
D- Ferning cervical mucos
Ans: D

35- A pregnant lady for antenatal visit having HB 7. She was prescribed iron supplements. This should be given:
A- Before meal
B- With Citrus Fruit
C- After meal
D- Before Bed
Ans: B

36- Which factor is responsible for onset of puberty?
A. Increase estrogen receptors on ovary
B. Increase sensitivity of hypothalamus to estrogen
C. Pulsatile release of GNRH from Anterior pituitary
D. Increase in Progesterone
Ans: C

37- Pregnant lady with a dead fetus labour induced but not responding due to:
A- Decrease oxytocin receptors on myometrium
B- Decrease oxytocin receptor in cervix
C- Increase oxytocin receptor in cervix
D- Decrease Sensation
Ans: A

38- In third trimester of pregnancy what will be increased?
A- IC
B- RR
C- Vital Capacity
D- TLC
E- Tidal Volume
Ans: E

39- FHR is:
A- 40 to 60 beats per minute
B- 60 to 100 beats per minute
C- 120 to 160 beats per minute
D- 100 to 120 beats per minute
Ans: C

40- A young male has azoospermia; which initial investigation will help in diagnosis?
A- Testosterone level
B- FSH Level
C- FSH and LH Levels
D- Sperm Count
E- Antibodies against sperm
Ans: C (FSH, LH and Testosterone)

Explanation:
Hypogonadotropic Hypogonadism
Causes:
- CNS Lesion
- Kallman Syndrome

Labs:
- FSH – Low
- LH – Low
- Testosterone – Low

HypergonadototropicHypogonadism
Causes:
- Turner Syndrome
- Genetic Mosaicism
- Pure Gonadal Dysgenesis

Labs:
- FSh – High
- LH- High
- Testosterone – Low

Obstructive Azoospermia
- All hormones normal

41- A primigravida at 1st trimester of pregnancy was having HB 11 gm/dl with normal physical findings. She presented in late pregnancy with Hb of 9 gm/dl. What could be the cause of this change?
A- Anaemia
B- Normal physiological change
C- Folic acid deficiency anaemia
D- Sickle cell trait
E- Thalassemia
Ans: B

42- Which one of the following is most potent oxidizer?
A- H_2O_2
B- Superoxide
C- Chloride
D- Chlorine
E- Potassium permanganate
Ans: A

Explanation: HOCL > H_2O_2 > Superoxide

43- Corpus luteum maintains pregnancy for:
A- 12-14 weeks
A- 1-8 weeks
B- 10-12 weeks
C- 1-4 weeks
D- 9 weeks
E-
Ans: B

44- Proliferation of the mammary ducts (lactiferous ducts) and fat deposition in breast is primarily by:
A- LH
B- FSH
C- Estrogen
D- Progesterone
E- Prolactin
Ans: C

45- Ejaculation occurs due to which of the following?
A- Pudenal nerve
B- Sympathetic
C- Parasympathetic
D- Obturator nerve
Ans: A

Explanation:
- Over all Ejaculation
- Pudendal nerve > Sympathetic **Ejaculation two parts**
- Emission -Sympathetic
- Ejection - Pudendal
- Erection –Parasympathetic

46- The beta HCG has alpha and beta subunits and each unit has aminoacids:
A- 102 alpha, 210 beta
B- 100 alpha, 160 beta
C- 150 alpha, 250 brta
D- 92 alpha 145 beta
Ans: D

47- Molecular weight of HCG:
A- 39000
B- 9600
C- 5500
D- 2900
E- 28000
Ans: A

48- Which if the following is most important in 2nd stage of labor?
A. Cervix dilatation
B. Placental delivery
C. Effacement
D. Abdominal muscle contractions
Ans: D

Explanation:
- If ask about substance: Oxytocin
- If asked about factor: Abdominal Muscle contraction.

49- Sperm life span is:
A- 50h
B- 30h
C- 60-64h
D- 40-54h
Ans: C

Explanation:
- Life Span of sperm is upto 72 hr
- Sperm stay active upto 48h

50- Seminal fluid has maximum concentration of:
A- Acid Phosphatase
B- Ascorbic Acid
C- Fructose
D- Glucose
Ans: C

51- Female with heavy bleeding since six month on /off, endometrial biopsy shows endometrial hyperplasia cause is:
A- LH
B- FSH
C- Estrogen
D- Progesterone
E- Prolactin
Ans: C

52- Which of following structures show concomitant hypertrophy and hyperplasia?
A- Uterus during pregnancy
B- Exercise induced muscle hypertrophy
C- Breast during post menopause state
D- Barrett esophagus
E- Liver
Ans: A

Explanation:
Uterus during pregnancy > breast during puberty

53- Most likely about mammary glands:
A- Extend vertically from 2 to 6 ribs
B- 15 to 20 lactiferous ducts
C- Sebaceous glands in areola
D- In pregnancy contains lactiferous ducts and secretory alveoli
Ans: B

54- Oocyte at ovulation is which of the following?
A- Secondary oocyte
B- Primary oocyte
C- Tertiary oocyte
D- None of the above
Ans: A

CamScanner

55- Mid luteal phase hormone is:
A- Progesterone
B- Estrogen
C- LH
D- FSH
E- Oxytocin
Ans: A

56- Fertilin at head of sperm helps in:
A- Acrosomial reaction.
B- Adherence of sperm head to ovum membrane
C- Movement of head towards the ovum
D- Acrosome removal
Ans: B
Explanation:
- Fertilin – Adherence of sperm to ovum
- Acrosin – Acrosome reaction

57- How much duration gap should be there between 2 children's in family planning:
A- 2 to 3 years
B- 3 to 4 years
C- Less than 2 years
D- 4 to 5 years
Ans: A

58- Maximum life of sperm in female genital tract:
A- 92 hours
B- 24-48 hours
C- 24-72 hours
D- 24 hours
E- 96 hours
Ans: C

59- Mother milk has more which nutrient vs cow milk:
A- Ca
B- Na
C- Albumin
D- Lactose
Ans: D
Explanation:

	Human milk	Cow milk
Sodium	Less	More
Potassium	Less	More
Magnesium	Less	More
Calcium	Less	More
Lactalbumin	Less	More
Casein	Less	More
Fat	Less	More
Water	More	Less
Lactose	More	Less

60- After a normal delivery in primigravida the alive & healthy new born is given feed:
A- After 1 hour
B- After half hour
C- After 6 hours
D- After 12 hours
E- After 24 hours
Ans: B

61- Uterine artery pulsatility can be detected through doppler US earliest at:
A- 7 week
B- 8 week
C- 9 week
D- 10 week
E- 12 week
Ans: A

62- Estrogen, progesterone action occurs through:
A- Transcription factors
B- CAMP pathway
C- Tyrosine kinase pathway
D- CGMP pathway
E- NF-KB pathway
Ans: A

63- Which organ is important for initiation of labor?
A- Placenta
B- Medulla
C- Maternal pituitary
D- Fetal pituitary
Ans: D

64- Fetal blood leaving placenta having oxygen is:
A- 20mmHg
B- 30mmHg
C- 50mmHg
D- 60mmHg
E- 100mmHg
Ans: B

65- Fallopian tube in female is:
A- Act as Conduit between peritoneal cavity and uterus
B- Attach to ovary through mesosalpinx
C- Approach to ovary from its medial side
D- Fallopian tube epithelium is Cuboidal
Ans: A

66- A female with menstrual cycle of 21-23 days when will ovulation occur?
A- 7-9d
B- 14-19d
C- 13-17d
D- 8-14d
E- 9-7d
Ans: A

67- Endometrium consists of glands and tortuous arteries during:
A- Late secretory phase
B- Early secretory phase
C- Ovulation phase
D- Anovulation
Ans: A

68- Patient having history of recurrent abortion, which of the following enzyme analysis will help in making diagnosis?
A- Estrogen
B- Testosterone
C- HCG
D- Progesterone
Ans: D

69- Mothers milk preferred over cow's milk because of:
A- Calcium
B- Lactate
C- Protein
D- Vitamin D
E- Immunoglobulins
Ans: E

70- Which of the following hormone decreases cholesterol?
A- Progesterone
B- Estrogen
C- Testosterone
D- Oxytocin
E- LH, FSH
Ans: B

71- During intrauterine life testosterone secretion is stimulated by:
A- FSH
B- LH
C- Placental HCG
D- Placental Estrogen
Ans: C

72- Adrenarche starts due to:
A- 17 alphahydroxyprogesterone
B- 17 Alpha hydroxyprenenolone
C- LH
D- FSH
E- Progesterone
Ans: A

73- Feedback by which hormone for LH surge before ovulation?
A- Progesterone
B- Estrogen
C- Oxytoxin
D- LH
E- FSH
Ans: B

74- During Puberty female develop secondary Sexual characters. Androgen peak at which age?
A- 45 years
B- 20-30 years
C- 40 years
D- 5-10 years
Ans: B

75- Lowest maternal mortality in which age group?
A- 10-20
B- 20-30
C- 30-40
D- 40-50
Ans: B

76- Steroid produced by fetal adrenal cortex is:
A- Cortisol
B- Cortocosterone
C- DHEA
D- Epinephrine
E- Progesterone
Ans: C

77- Testosterone is synthesized by which of the following?
A- Seminiferous tubules
B- Sertoli cells
C- LH
D- Parenchymal cells
E- FSH
Ans: C
Explanation:
Leutenizing hormone (LH) causes Testosterone synthesis from leydig cells.

78- Female breast feeds her child what would happen?
A- Failure of primordial follicles to mature
B- Decrease prolactin
C- Increase dopamine
D- Increase primordial cell maturation
Ans: A

79- Sperms after formation in seminiferous tubules stored in?
A- Ampulla of ductus deferens
B- Seminal vesicles
C- Prostate
D- Ejaculatory duct
Ans: A

CamScanner

80- Pregnant lady with 41 weeks 05 days pregnancy anxious requested for induction of labor Post term pregnancy by WHO is called at?
A- 43 weeks
B- 41 weeks completed
C- 42 weeks completed
D- 40 weeks completed
E- 38 weeks
Ans: C

81- Full development and function of the semiferous tubules requires:
A- Somatostatin
B- LH
C- Prolactin
D- FSH and androgens
E- Oxytocin
Ans: D

82- Estrogen is not produced by:
A- Theca cells
B- Ovary
C- Adipose tissue
D- Placenta
Ans: A

Explanation:
Source – Ovary (17β-estradiol), placenta (estriol), adipose tissue (estrone via aromatization).

83- How many days do a full sperm regeneration cycle takes.
A- 20 days
B- 25 days
C- 64 days
D- 80 days
Ans: C

84. Maturation of Seminiferous tubules is done via:
A- Androgen
B- Androgen & FSH
C- Androgen & LH
D- Inhibin
Ans: B

85. LH is increased in just 2 days before ovulation upto how many folds:
A- 1 to 2 folds
B- 2 to 6 folds
C- 6 to 8 folds
D- 8 to 10 folds
Ans: D

86- Which of the following increases in pregnancy?
A- Serum transferring
B- Red cell mass
C- MCH
D- Iron absorption from gut
Ans: B

87- Low level of cholesterol in premenopausal women and protection from thromboembolism is done by:
A- Progesterone
B- HCG
C- FSH
D- LH
E- Estrogen
Ans: E

88. Secretions through vagina during sexual act are effect of:
A- Bombesin
B- Relaxin
C- Prolactin
D- Progesterone
E- Parasympathetic stimulation
Ans: E

89. Hormone involved in conversion of testosterone to 17 Beta estradiol in granulose cells:
A- LH
B- FSH
C- HCG
D- Estradiol
Ans: B (Prefer Aromatase)

90- Menopause occurs due to:
A- Ovarian unresponsiveness
B- Pituitary exhaustion due to LH
C- Pituitary exhaustion due to FSH
D- Hypothalamic unresponsiveness
Ans: A

91. Increase in oxytocin results in:
A- Cervix dilation
B- Cervix contraction
C- No effect on cervix
D- Increase blood supply to cervix
Ans: A

92- The maternal mortality ratio (MMR):
A- The number of maternal deaths during a given time period per 100,000 live births during the same time period.
B- The number of maternal deaths during a year.
C- The number of maternal deaths in a given period per population of women who are of reproductive age.
D- The number of deaths of young women.
Ans: A

Explanation:
- Maternal mortality ratio is the number of maternal deaths per live births.
- Maternal mortality rate is the number of maternal deaths in a given period per population of women who are of reproductive age.

93- Intravaginal administration of prostaglandin initiates cervical ripening by mechanism:
A- Activating oxytocin receptors
B- Hydration of collagen tissue
C- Increase capillary permeability
D- Increase local progesterone concentration
E- Inhibiting thromboxane synthesis
Ans: B

94- A structure with ciliated and non-ciliated epithelium having three layers of muscles & tubular glands is:
A- Ureter
B- Fallopian tube
C- Ovary
D- Uterus
Ans: B

95- Cause of amenorrhea during lactation is:
A- Stimulation of gonadotropin due to nipple stimulation
B- Due to release of prolactin
C- Milk secretion by oxytocin
D- It inhibits goandotropin releasing hormone (GnRH)
Ans: B > D

96- The hormone which triggers onset of parturition in mother is:
A- Fetalestrogen
B- Fetalthyroxine
C- Fetal cortisol
D- None of the above
Ans: C

97- Uterine changes during pregnancy:
A- Hyperplasia
B- Hypertrophy
C- Hypertrophy + Hyperplasia
D- Atrophy
Ans: C

98- Which of following hormone placenta produces in last trimester?
A- Estrogen
B- Progesterone
C- Estrogen + Progesterone
D- Relaxing
Ans: C

99- Which of the following is true hermaphrodite?
A- XXY
B- XXX
C- XYY
D- XO
Ans: A

Explanation: XX > XX/XY > XXY.

100- Which part of the male genital tract has partially motile sperms?
A- Ductus deference
B- Seminal tubercle
C- Epididymis
D- Rete testes
Ans: C

101- Pregnancy which of the following occurs?
A- Increase peripheral resistance
B- Decrease Tidal volume
C- Decrease FRC
D- Decrease Respiratory rate
Ans: C

102- In pregnancy:
A- Increase Tidal volume
B- Increase TLC
C- Decrease FRC
D- VC remains unchanged
Ans: D

103- Ovulation occurs on which day of menstrual cycle?
A- 10th
B- 14th
C- 18th
D- 19th
Ans: B

104- Most common site of fertilization in humans?
A- Ovary
B- Uterus
C- Cervix
D- Ampulla of fallopian tube
E- Peritoneal cavity
Ans: D

105- Primary gravida normal delivery which structure damage?
A- Ischial spine
B- Sacrotuberous Ligament
C- Perineal Body
D- Ureter
E- Levator ANI
Ans: E

106- Difference in maternal and fetal Circulation which fetal has less?
A- Less H ion
B- O2
C- CO2
D- Respiratory vascular resistance
E- Affinity for oxygen
Ans: B

CamScanner

107- One bar body present in nuclei/cell of:
A- Turner syndrome
B- Down syndrome
C- Normal female
D- Normal Male.
Ans: C

108- MMR definition:
A- No of maternal deaths/1000 population
B- No of maternal deaths /100000
C- No of maternal deaths /100
D- No. Of maternal deaths divided by 10
Ans: B

109- Leydig cells:
A- Make sperm testes barrier
B- Mainly reside in seminiferous tubules
C- Have high level of SER
D- Secrete estrogen
Ans: C

110- In spermatogenesis acrosomal cap is formed by:
A. Lysosomes
B. Mitochondria
C. Golgi complex
D. Endoplasmic reticulum
Ans: C

111- Most imp and acute effect on testosterone production is of:
A- LH
B- FSH
C- Prolactin
D- Oxytocin
Asn: A

112- Secondary oocyte is surrounded by corona radiata, which of the following layers contribute to the formation of corona radiata?
A- Granulosa cells
B- Theca internal cells
C- Theca external cells
D- Leydig cells
Ans: A

113- Progesterone works in contraceptive pills by:
A- Spermicidal action
B- Induces uterine contraction
C- Inhibits ovulation
D- Inhibits maturation of ovarian follicles
Ans: C

114- True regarding sperms of men above 70 years of age:
A- Are asthenospermic
B- Many lacks forward progressive motility
C- Count ">" (some figure) as they are ligospermic
D- Reduced quantity of semen because their seminal vesicles atrophy
E- Can fertilize ovum
Ans: A

115- Triple assessment for congenital fetal anomalies includes one of the following:
A- Estradione E2
B- Estrione E1
C- Estriol E3
D- All
Ans: C

Explanation:
- Estrogen in reproductive years – Estradiol (di- girl and boy)
- Estrogen in pregnancy – Estriol (tri - mom, dad , child)
- Estrogen in menopause – Estrione (1 - women becomes single again)
- Potency – estradiol>estrione> estriol

116- Mid-leuteal max hormone increase:
A- LH
B- FSH
C- Estrogen
D- Progesterone
E- Estrogen + progesterone
Ans: D

117- Regarding testosterone:
A- Regulated by FSH
B- Has receptors on membrane
C- Descend testis in late fetal life
D- Abundantly secreted by adrenal cortex
Ans: C

118- About human placenta:
A- 2 umbilical veins
B- 2 umblical artery and 1 vein
C- 1 umblicalartrey
D- 2 viens, 2 artries
Ans: B

119- Regarding sperm reaching epididymis:
A- Circular movement
B- Movement becomes directional
C- Acrosomal reaction takes place
D- Capacitance occurs here
Ans: B

120- Final stage of puberty:
A. Axillary hairs
A. Menstruation
B. Pubic hair growth
C. Growth spurt
D.
Ans: B

121- Leiomyoma with increased endometrial stroma and few glands what is the cause?
Atrophy
A. Hyperplasia
B. Neoplasia
C. Metaplasia
D.
Ans: A

122- In pregnancy what changes seen in respiratory system
A. CO_2 increase
B. TLC increase
C. Vital capacity increase
D. Residual vol. increase
E. Decrease $PaCO_2$
Ans: E

123- Implantation occurs after how many days of fertilization:
A. 6th day
B. 10th day
C. 3rd day
D. 15th day
E. None
Ans: A

124- A pregnant female has increased prolactin but doesn't eject milk due to the inhibitory effect of?
A. Estrogen/Progesterone
B. ACTH
C. Estrogen only
D. Progesterone only
Ans: A

125- Most dangerous complication in pregnant woman?
A. Tissue damage DIC
B. Fracture
C. Coagulopathy
D. Fat embolism
E. None
Ans: A

126- Germinal follicle present in
A- Cortex of lymph node
B- Medulla of lymph node
C- Cortex of thymus
D- Medulla of thymus
E- Red pulp of spleen
Ans: A

127- Which hormone causes softening of Cervix?
A- Estrogen
B- Progesterone
C- Prostaglandin
D- Testosterone
E- Oxytoxin
Ans: C

128- The whip-like ciliary movement on the surface of cells is seen mainly in
A- Fallopian tube
B- Olfactory membrane
C- Organ of corti
D- Spermatozoa
E- Utricle
Ans: A

129- Which of following remains dominant after puberty
A- Primary oocyte
B- Secondary oocyte
C- Primordial germ cell
D- Follicle
Ans: B

130- HCG main function is to
A- Enhanced breast
B- Ovulation
C- Reproduction
D- Corpus luteum Preservation
Ans: D

131- Human placenta has
A- Amnion on its fetal side
B- Chorioallantoic placenta
C- Get separated along the stratum spongiosum
D- Get separated when there is rupture of many uterine arteries
E- Hemochoridalmemberane
Ans: D (Prefer uterine muscles)

132- In Mid cycle cervical mucus has
A- Increase cellularity
B- Increase viscosity
C- Arborization
D- Increase RBC
Ans: B

133- Which hormone causes most potent protein synthesis in skeletal muscle?
A- DHT
B- Testosterone
C- Cortisol
D- Estrogen
E- Progesterone
Ans: B

CamScanner

134- Villi Are particular to
A- Fallopian tube
B- Intestine
C- Lungs
D- Heart
Ans: A

135- Normal function of placenta is
A- Prevent mixing of maternal and fetal blood
B- Prevent oxygenation
C- Prevent antibodies from mother to fetus
D- Prevent nutrition
Ans: A

136- A pregnant lady of 3rd trimester having unchanged
A- LH
B- Cortisol
C- PTH
D- Estrogen
E- Growth hormone
Ans: E

137- After ovulation, the oocyte is in whichphase of cell cycle?
A- Metaphase of Meiosis II
B- Prophase of first meiotic division
C- Prophase of 2nd meiotic division
D- Metaphase of first meiotic division
E- Anaphase
Ans: C

138- Most important factor in negativefeedback is
A- Release of Hormone
B- To bring Value to normal limit
C- Feed forward mechanism
D- Release Enzyme
Ans: B

139- Most important function ofprogesterone?
A- Secretory phase of endometrium
B- Decrease uterine contraction inpregnancy
C- Endometrium proliferation
D- Fat deposition
Ans: A

140- Which one of these crosses the placenta and affects baby?
A- IgM
B- Thyroxine
C- PTU
D- IgE
Ans: C

141- The volume of amniotic fluid at term is
A- 200 ml
B- 400 ml
C- 600 ml
D- 800 ml
Ans: D

142- During pregnancy endocervix protrudes due to:
A- Estrogen effect
B- Physiological effect
C- Pathological
D- Painful condition
E- Associated with vaginal discharge
Ans: B

143- Which physiologic change occurs during a normal pregnancy?
A- Hyperuricemia
B- Proteinuria
C- Hypertension
D- 40% increase GFR
Ans: D

144- Uterus having basal nuclei with saw tooth appearence of endometrium. In which phase uterus is:
A- Secretory phase
B- Proliferative phase
C- Follicular phase
D- Inhibitory phase
Ans: A

145- Female delivered a baby 2 day ago wants to breastfeed her child. What change would occur in her body?
A- Hypothalamaic Prolactin Increase
B- Decrease in oxytocin
C- Prolactin decrease
D- Hypothalamic Dopamine Increase
Ans: B(Only suitable)
Explanation:
- Prolactin released from pituitary so it must be increase prolactin from pituitary
Changes include are
- Increase Prolactin from pituitary due to low dopamine
- Decrease oxytocin

146- Beta HCG help in maintaining pregnancy by:
A- Inducing corpus luteum to secrete harmone
B- Inhibit corpus luteum
C- Inhibit LH
D- Stimulate Prostaglandins
Ans: A

147- Female of peri menopausal group, there Will be increase
LH
A- FSH
B- Progesterone
C- Estrogen
D- B >A
Ans:

148- During menstruation and parturition which layer shed:
A- Functionalis
B- Basalis
C- Functionalis and basalis
D- Basalis and endometrium
E- Endometrium + superficial myometrium
Ans: A

149- In third trimester of pregnancy estrogen released from:
A- Fetal Adrenal
B- Fetal liver
C- Placenta
D- Spleen
Ans: C

150- A woman is 3 weeks pregnant and given antibodies spontaneous abortion occur the role of HCG in Maintaining pregnancy
A- It decreases uterine contraction in pregnancy
B- Protects body against foreign tissue invasion
C- Responsible for corpus luteummaintainence
D- Decrease body temperature
Ans: C

151- Male breast different from female breast by
A- Glandular cells
B- Adipose tissue
C- Secretory cells
D- Aporcrine glands
Ans: A

152- Secondary oocyte Develops under the influence of:
A- Estrogen
B- Progesterone
C- FSH
D- LH
Ans: C

153- Pregnancy Stuck at which phase of Menses
A- Pro gestational
B- Ovulation
C- Pre menses
D- Follicular Phase
Ans: D

154- Pregnant lady, 20 week, preterm labour, later having dead fetus, fever, chills ,scan done showed no villous, with chorion and amnion, cause
A- Chemotrienes
B- Complement
C- Prostaglandins
D- Amyloid
Ans: B

155- Estrogen causes
A- Soft skin
B- Dark skin
C- Hairs on skin
D- Decrese vascularity
Ans: A

156- What increase in pregnancy?
A- Ca^{++}
B- Albumin
C- Cholesterol
D- Bicarbonate
Ans: C

157- Normal Neonatal Heart rate is
A- 200-250
B- 180-220
C- 110-150
D- 70-80
Ans: C

158- Testosterone produced by which offollowing
A- Sertoli cell
B- Seminefirous tubules
C- Lydig cell
D- Mullirian cell
Ans: C

159- Age estimation from 5th to 12th week isdone through
A- Crown rump length
B- Parietal diameter
C- Abdominal circumference
D- Crown heel length
Ans: A
Explanation:
- 1st trimester- CRL
- 2 Nd trimester- BPD

160- More Growth in human beings occurs -- in which age group
A- Intrauterine life
B- Old age
C- Aldoscents
D- Childhood
E- After recovering from illness
Ans: C

CamScanner

Explanation:
- Maximum growth – Adolescent
- Fastest growth – Intrauterine

161- Most potent affect of Decrease ACTH --- on:
A- Estrogen
B- Aldosteron
C- Adrenal Androgen
D- TSH
Ans: C

162- The fetal part of placenta is
A- Cytotrophobast
B- Syncytotrophoblast
C- Decidua Basalis
D- ChorionFrundosum
E- Extraembryonic Coelom
Ans: D

163- Lh surge 2 days before ovulation
A- 6-10fold raise
B- 4-6fold raise
C- 4-5 fold raise
D- 12-14 fold raise
Ans: A

164- Decrease in Size of uterus after 10days of delivery is 5-10g what it wouldbeafter 6-8 weeks
A- 100g
B- 500g
C- 60g
D- 200g
Ans: C

Explanation:
Uterus weight vary after delivery as follows
- After delivery uterus weight – 1000g
- After 1 week uterus weight – 500g
- After 2nd week uterus weight – 300-350g
- After 4th week uterus weight – 100g
- After 6-8 week (Involution complete)Uterus weight – 40-60g

165- Iron requirement in pregnantfemale ----
A- 500 mg
B- 1500 mg
C- 1000 mg
D- 2000mg
E- 1200 mg
Ans: C

166- Source of estrogen and progesterone in first trimester by:
A- Placenta
B- Ovary
C- Corpus luteum
D- Chorionic villi
E- Adenohypophysis
Ans: C

167- Level of education of reproductive knowledge is
A- Higher Secondary
B- Primary
C- Lower secondary
D- Doctorial
E- Postgraduation
Ans: C

168- Hormone Inhibiting FSH:
A- Ovary
B- Released By Testes
C- Corpus luteum
D- Placenta
Ans: B

169- Mid trimester erythropoiesis occurs in:
A- Liver
B- Yolk sac
C- Spleen
D- Bone marrow
Ans: A

170- On 4th postpartum day mother wants to feed baby what changes will occur
A- Decrease Cortisol
B- Increase dopamine
C- Increase prolactin by pituitary
D- Increase Oxytoxin by Hypothalamus
Ans: C

171- Anticoagulant decreasing in pregnancy:
A- Antithrombin 3
B- Factor 8
C- Factor 10
D- Factor 7
Ans: A

172- 50 year old postmenopausal women having hot flushes cause is:
A- Increased FSH, LH
B- Increased GnRH
C- Decreased FSH, LH
D- Normal levels of FSH, LH
E- Increase Progesterone
Ans: A

173- Pregnant women increase abdominal grip size and uterus changes likely due to
A- Structural Physiological change
B- Physiological + pathological change
C- Pathological change
D- Structural + pathological change
Ans: A

174- Total Sperm count in 1 day?
A- 120 Million
B- 10 Million
C- 20 Million
D- 50 Million
E- 150 Million
Ans: A

Explanation:
- Total spems produced by two testes perday -120 million
- Total sperms per ejaculate - 400 million /ejaculate or 120 million /ml
- Total number of mature sperms -100 million /ejaculate or 20 million /ml
- For person to be fertile sperm count should be at least 20 million /ml

175- Seminal vesicles secretes when increases in
A- Increase potassium
B- Intracellular calcium
C- Increase sodium
D- Decrease sodium
E- Decrease Potassium
Ans: B

176- After vasectomy seminal fluid will contain:
A- Seminal and prostatic fluid
B- Prostatic fluid
C- Sperm count decrease
D- Prostatic fluid and sperm only
Ans: A

177- Semen is alkaline and vaginal secretions are acidic. When Semen is inside the vagina the acidic Ph. of vagina changes to?
A- 3.8– 4.5
B- 5 – 6
C- 3 – 4
D- 8-9
Ans: B

Explanation:
- Vagina Ph is acidic=3.8-4.5
- Semen ph is alkaline=7.1-8
- During sex, the pH of your vagina rises in order to create a more alkaline environment to protect the sperm and encourage fertilization. This can also encourage the growth of certain bacteria.

178- Beta HCG most important function is:
A- Maintains corpus luteum
B- Formation of male sex hormone
C- Descend of testes
D- Maintain female androgenic hormone
E- Maintain Placenta
Ans: A

179- During lactation amenorrhea occur due to
A- Progesterone inhibition from ovary
B- Oestrogen inhibition from ovary
C- Inhibition of GnRH by prolactin
D- Inhibition from placenta
E- Inhibition of oxytocin
Ans: C

180- Oestrogen and progesterone produced in the last 7 months by:
A- Anterior pituitary
B- Corpus luteum
C- Hypothalamus
D- Placenta
E- Posterior pituitary
Ans: D

181- A 50-year-old female experiences the absence of menstrual periods. What is the most likely cause of this condition?
A- Pregnancy
B- Menopause
C- Polycystic Ovary Syndrome (PCOS)
D- Hypothyroidism
Ans: B

182- Which of the following is part of triple screening?
A- Estriol
B- Estrone
C- Estradiol
D- Progesterone
Ans: A

Explanation:
- Estriol in triple screening & after marriage
- Estrone in post-menopausal
- Estradiol in premenopausal just engaged

183- Spermatogenesis completed in how much period?
A- 48 days
B- 60 days
C- 87 days
D- 49 days
Ans: B

184- Which of the following is potent oestrogen?
A- Estriol
B- Estrone
C- Estradiol
D- Progesterone
Ans: C

Explanation:
- Most Potent Anabolic Hormone – Testosterone.
- Potency – DHT >TestosteronePotency – Estradiole>Estrone>Estriole

CamScanner

185- Regarding Cervical ectropion true is:
A- Normal in pregnancy
B- Associated with hydatid mole
C- Associated with partial mole
D- Seen in ectopic pregnancy
E- Premalignant
Ans: A

186- Sparse pubic hair in which stage
A- Stage 1
B- Stage 2
C- Stage 3
D- Stage 4
Ans: B

187- Sertoli cells releases which one?
A- Testosterone
B- Luteinizing hormone
C- Androgen
D- Androgen binding protein
Ans: D

Explanation:
- Androgen produce by Lydig cell
- Sertoli cell produce Androgen bindingproteinand Inhibin

188- Best test to confirm pregnancy
A- FSH
B- LH
C- ELISA
D- Oestrogen
Ans: C

189- Life span of corpus luteum increased by?
A- Endogenous estrogen
B- Endogenous HCG
C- Endogenous LH FSH
D- Endogenous progesterone
Ans: B

190- Uterus is most sensitive to which hormone during last trimester
A- Progesterone
B- Oxytocin
C- Estrogen
D- Cortisol
Ans: B

Explanation:
- Early – Progesterone
- Late – Oxytocin

191- Umbilical artery carries:
A- Deoxygenated blood to the placenta,
B- Deoxygenated blood from the placenta
C- Oxygenated blood to placenta.
D- Deoxygenated blood to fetus.
Ans: A

Explanation:
Umbilical artery carries deoxygenated blood from fetus towards placenta formourishment.
Umbilical Vein carry oxygenated andnutrient rich blood back to fetus

192- Pregnant woman has inc in girth of abdomen which is example of adaptation which is comprehensively defined as:
A- Reversible structural change in response to physiological stimulus
B- Reversible functional in response to physiological stimulus
C- Reversible structure and functional change in response to physiological and pathological stimulus
D- Pathological response
Ans: C

193- Married man had no children for few years and was diagnosed as sterile with azoospermia. What is investigation of choice?
A- Serum FSH and serum LH
B- Serum prolactin
C- Serum testosterone
D- Semen analysis
Ans: A

194- Pregnant woman with increase in abdominal girth due to:
A- Anaemia
B- Normal response to physiological stimuli
C- Folic acid deficiency anaemia
D- Increase placenta size
Ans: B

195- Twin pregnancy with two ovum. Which is correct?
A- Same placenta
B- Same amniotic sac
C- Separate amniotic sac
D- Same chorion
Ans: C

196- Viability of sperms?
A- 24-[illegible] hours
B- 24-[illegible] hours
C- [illegible]
D- [illegible]
Ans: [illegible]

197- [illegible] life span [illegible] at [illegible] body temperature
A- 12-[illegible] hours
B- 72 hours
C- 24-48 hours
D- 4 days
E- 36 hours
Ans: B

198- The part of sperm containing proteolytic enzymes to digest the zona pellucida is the:
A- Capacitor
B- Head
C- Corona
D- Acrosome
E- Cumulus
Ans: D

199- 45 age women having 3 children with regular menstrual cycle less fertile than women age 35. What can be the physiological reason behind this?
A- Inc Fsh & Lh
B- Increased Testosterone
C- Decreased Gnrh
D- Lactation
E- Increased Gonadotropins
Ans: C

200- A Female athlete had an injection given on 14th day of her menstrual cycle to delay mensturation; Which injection it could be?
A- Anti progestrogenic affect
B- Human chorionic gonadotropin
C- FSH
D- Testosterone
E- Progesterone
Ans: E

201- Pregnant lady with 41 weeks 05 days pregnancy anxious requested for induction of labor Post term pregnancy by WHO is called at?
A- 43 weeks Completed
B- 46 weeks completed
C- 37 weeks completed
D- 40 weeks completed
E- 38 weeks Completed
Ans: A(No option of 42 Completed Weeks)

202- At Ovulation,There is Rupture of graffian follicle, & if pregnancy doesnot happed, the leftover sloughing of corpus is?
A- Corpus hemmorhagicum
B- Corpus luteum
C- Corpus albicans
D- Corpus basale
Ans: A

203- During the first phase of menstrual cycle, There is Proliferation & Thickening of endometrium. This endometrial proliferation is under control of which hormone in this phase of the cycle?
A- Progesterone
B- Fsh & Lh
C- Estrogen
D- Gnrh
Ans: C

204- A young couple are trying to conceive and begin their family. After 1 year of "trying" they have come to a fertility clinic to seek some answer. You Initially guide them to try during ovulation days. Which of the following is true regarding ovulation?
A- It occurs due to FSH & Lh surge
B- Fern test positive
C- Low body temperature
D- Low estrogen
Ans: A

205- A Little girl having menses & She saw some pieces coming in her menstruation she is worriyng about it..What it could probably be?
A- Blood Clots
B- Sheds of endometrium
C- Spiral arteries
D- Sheds of myometrium
Ans: B

206- Hormone exhibiting relation between weight and puberty:
A- Leptin
B- Estradiol
C- Ghrelin
D- Progesterone
Ans: A>B

Explanation:
- Leptin and Estradiol both can be true but Leptin is better choice
- Leptin Makes you Lean
- Ghrelin Makes you Giant (obese)

207- Home based pregnancy test detects:
A- Estriol
B- Enzyme
C- Cortisol
D- HCG
Ans: D

CamScanner

208- Which cells will remain dormant in female upto age of 40?
A- Primary oocyte
B- Spermatids
C- First polar body
D- Ovum
E- Second polar body
Ans: A

209- Most Important function of progesterone is?
A- To contribute in mucous secretions of Fallopian tube
B- To contribute in Secretory phase of endometrium
C- To contribute in Breast duct development
D- To contribute in Breast Alveoli development
E- To contribute into development of Secondary Sexual characteristics
Ans: B

Explanation:
- Estrogen Function – Breast Duct Development + Endometrial Proliferation
- Progesterone Function – Maintain Endometrial Thickness (Proliferation) > Secretory phase > Alveoli and lobule development.

210- Ovarian granulosa cells are part of:
A- Germ cells
B- Ovarian follicles
C- Theca cells
D- Oocyte
E- Fallopian tube
Ans: B

211- USG frequency for prenatal scaning???
A- 15000-19000 Hz
B- Greater than 20,000 Hz
C- 5MHz
D- 10MHz
Ans: B

212- Husband wife want to conceive what will you counsel them about chance of pregnancy?
A- When estrogen level decrease
B- At menestrual phase
C- At time of LH surge
D- At secretory phase
E- At Ovulatory phase
Ans: C

213- A patient is undergoing workup for Primary Infertility. Which of the following will indicate ovulation has occurred?
A- Mucinous discharge
B- Raised body temperature
C- Corpus luteum secretion
D- Thick Cervical mucus with no Ferning
Ans: D

214- Ultrasound frequency used for prenatal diagnostic purpose in obstetrics:
A- 15 -19mhz
B- More than 20mHz
C- 15-29mHz
D- 1 to 10 mhz
Ans: A

215- Twin pregnancy with 2 ova at 16 Weeks of Gestation will most likely have:
A- Separate amniotic sacs
B- Single placenta
C- Single amnitoic sac
D- Single chorion
Ans: A

216- Patient presented to infertility clinic.Semen Analysis shows that Sperms' progressive motility is 25% and 25 % are spasmodically contracting.Cause is:
A- Sample is obtained from Epidydimis
B- Sample is obtained from Masturbation
C- Sample is obtained from sex with wife after she used sponge of cacl2
D- Mishandling of Specimen by technician
E- Sample is obtained from seminal vesicle
Ans: C

Explanation:
- Cacl2 is spermicidal that causes immobilization of sperms and spasmodic contractions of sperms

217- Spermatogenesis complete in how much period?
A- 48 days
B- 68 days
C- 87 days
D- 49 days
Ans: B

218- Testosterone is dependent on which of the following for its funtion?
A- LH
B- FSH
C- Prolactin
D- Oxytocin
Ans: A

219- Spermatogenesis complete in how much period?
A- 48 days
B- 68 days
C- 87 days
D- 49 days
Ans: B

220- Changes in Blood of 50 year old postmenopausal Women:
A- Increased FSH, LH
B- Increased GnRH
C- Decreased FSH, LH
D- Normal levels of FSH, LH
E- Increase Progesterone
Ans: A

221- Which one of the following inhibits FSH?
A- Testes
B- Seminal Vesicle
C- Epidydimis
D- Ejaculatory ducts
Ans: A

222- After Menopause Deficiency of Which hormone affects triglycerides level which leads to atherosclerosis of vessels?
A- Estrogen
B- Thyroxine
C- Progesterone
D- Growth Hormone
Ans: A

223- Ovum ejected from Primary oocyte. One of the component surrounding it is derived from Granulosa cell that gives rise to:
A- 2nd Polar body
B- Corona radiata
C- First polar body
D- 3rd polar body
Ans: B

224- Mother has galactorrhea in pregnancy, worried if it's normal, milk production depends on during pregnancy
A- Suckling
B- Prolactin
C- Concentration of estrogen and progesterone in pregnancy.
D- Oxytoxin
Ans: C

225- True regarding sperms of men above 70 years of age:
A- Sperms donot have progressive motility
B- Usually more then 500 millions sperms because they are non motile
C- Sperms can usually cause fertilization of ovum
D- Sperms are usually non motile because their seminal vesicle are not functional
E- Are asthenospermic
Ans: E

226- Couple trying to conceive for 6 months after marriage, Coital freuency is 2–3x in a week. On Investigation, All labs are normal, Chances of conceiving?
A- 90% Conceive Within 1 Year
B- 40% Conceive Within 1 Year
C- 85% Conceive Within 1 Year
D- 75% Conceive Within 1 Year
E- 80% Conceive Within 1 Year
Ans: E (DC Dutta textbook of Gynaecology)

Explanation:
- Eighty percent of the couples achieve conception if they so desire, within one year of having regular intercourse with adeuate freuency (4–5 times a week).
- Another 10 percent will achieve the objective by the end of second year.
- As such, 10 percent remain infertile by the end of second year

227- 28-weeks pregnant lady. On usg, What characteristic finding can be seen in Ovary?
A- Corpus luteum
B- Cumulus Oophorus
C- Corona Radiata
D- Secondary Follicle
Ans: A

228- Undifferentiated germ cells found in basal compartments of seminiferous tubules are called (Medicine Feb 2025)
A- Type A spermatogonia
B- Type B spermatogonia
C- Spermatids
D- Primary spermatogonia
Ans: A

229- Most semen produced in:(Medicine Feb 2025)
A- Prostate and seminal vesicles.
B- Prostate and testicles
C- Prostate
D- Seminal Vesicle
E- Epidydimis
Ans: A

CamScanner

230- Body Temperature is raised during ovulation due to the effect of which of the following hormone?(Medicine Feb 2025)
A- LH
B- Progesterone
C- Estrogen
D- Cortisol
Ans: B

231- Baby is on mother feed from last 8 months.Amenorrhea in lactation is due to:(Medicine Feb 2025)
A- Pressure effect on Gnrh leading to decreased Fsh & Lh
B- Inhibition of prolactin
C- Due to dopamine
D- Decrease secretion of estrogen and progesterone
Ans: A

232- During pregnancy, breast milk ejection prevented by:(Medicine Feb 2025)
A- Progesterone
B- Oxytocin
C- Prolactin
D- Oestrogen
Ans: D
Explanation:
• Estrogen + Progesterone > Estrogen > Progesterone

233- Alkaline phosphatase in semen acts to maintain acidic vaginal Ph in range? (Medicine Feb 2025)
A- 4-5
B- 5-6
C- 7-7.4
D- 3-4
Ans: A

234- Estrogen effect in adult female:(Medicine Feb 2025)
A- Thinning of cervical mucus
B- Enlargement of breast
C- Alveoli and lobule development
D- Inhibition of Uterine Contractions
Ans: B

235- Which of the following is function of testosterone(Surgery Feb 2025)
A- Thickening of the larynx
B- Improvement of vision
C- Increase in scalp hair growth
D- Responsible for high pitch voice
Ans: A

236- Which hormone is primarily detected by urine pregnancy test kits?(Surgery Feb 2025)
A- Luteinizing Hormone (LH)
B- Follicle-Stimulating Hormone (FSH)
C- Human Chorionic Gonadotropin (hCG)
D- Progesterone
Ans: C

237- Couple wants to conceive how to confirm fertile period: (Surgery Feb 2025)
A- LH
B- Progesterone
C- Estrogen
D- FSH
Ans: A

238- Which gene is located on the short arm of the Y chromosome and plays a crucial role in male sex determination?(Gynae & Obs Feb 2025)
A- Müllerian Inhibiting Factor (MIF)
B- Testosterone production gene
C- Testes-determining factor (TDF)
D- Progesterone
E- Estrogen
Ans: C

239- How to confirm ovulation has occurred?(Gynae & Obs Feb 2025)
A- Estrogen
B- Progesterone
C- Inhibin
D- FSH
E- Pre ovulatory LH levels
Ans: B

240- In monozygotic twins, a diamniotic dichorionic placenta results if the zygote spilts with in how many days after fertilization? (Gynae & Obs Feb 2025)
A- Within 3 days
B- 4-7 days
C- 8-12 days
D- After 12 days
Ans: A

MEDIPEDIA

- For Online Practice of Mcq Use Medipedia Application From Play Store
- You can search any Mcq in this App on Search bar
- Exam Oriented Pattern of MCQs in this App
- You Can Save Quiz and continue from same MCQ
- Practice Mock Tests on this App

GENERAL PATHOLOGY

CamScanner

CELL PATHOLOGY QUICK HINTS

Cell Injury

Reversible cell injury

- ✓ First Manifestation is **Cellular Swelling.**On microscopic Examination Smallclear vacuoles may be seen withincytoplasm that represent pinched offsegment of ER. This is called **hydropicchange or Vacuolar degeneration**

Ultrastructural changes

- ✓ Plasma membrane blebs & loss ofmicrovilli
- ✓ Mitochondrial swelling with smallamorphous densities
- ✓ Dilation of endoplasmic reticulum withintracytoplasmic myelin figure
- ✓ Nuclear alteration

Irreversible Cell injury

- ✓ Hall mark is Cell membrane damage
- ✓ Myelin figure derived from damage cellmembrane
- ✓ Dilation of mitochondria with Largeamorphous densities

Nuclear changes

- ✓ **Karyolysis**- Loss of DNA andbasophilia fade
- ✓ **Pyknosis** – Nuclear Shrinkage andincrease basophilia
- ✓ **Karyorhhexis** – Pyknotic nucleusundergo fragmentation

Note

- ✓ Reversible cell injury Prominent feature - Cell swelling >ER swelling
- ✓ Irreversible cell injury hall mark feature - Cell membrane damage >Lysosomal rupture
- ✓ Myelin figure present in both
- ✓ Not present in Irreversible injury - Mitochondrial Swelling
- ✓ Eosinophilia of cell due to - Loss of RNA

Necrosis

- ✓ Morphological changes caused by degradative action of enzyme on lethaly injured cell

Nucleus changes

- ✓ Karyolysis , Pkynosis and Karyorrhexis

Cytoplasm changes

- ✓ Eosinophilia due to loss of RNA

Types

Coagulative

- ✓ Cell outline preserved
- ✓ Occur in all hypoxic cell death(e.g MI) Except Brain

Liquefective

- ✓ Loss of cell outline
- ✓ Occur in Focal bacterial infection and Hypoxic cell death in CNS

Caseous

- ✓ Grossly cheasy and White
- ✓ Occur in Tuberculous infection, Histoplasma and nocardia

Fat Necrosis

- ✓ Occur due to Action of enzyme on fat or trauma
- ✓ Seen in Acute pancreatitis

Fibrinoid necrosis

- ✓ Invove arteries and arterioles and Type III HS
- ✓ E.g PAN

Gangrenous

- ✓ Initially Hypoxic coagulative(Dry gangreen)

Cellular Adaptations

Atrophy

- ✓ Decrease cell size
- ✓ Decrease Work load
- ✓ Decrease Endocrine activity
- ✓ Patient has cast applied now has Decreased muscle mass – Disuseatrophy + Decreased no of actin and myosin
- ✓ **Physiologically** - Atrophy of Thymus , gonads and Ductusarteriosus
- ✓ **Pathologically** - Loss of innervation and Endocrine activity

Hypertrophy

- ✓ Increase cell sizeE.g
- ✓ Growth of Uterus and Breast
- ✓ LVH ,RVH and Skeletal muscle hypertrophy

Hyperplasia

- ✓ Increase in Cell No
- ✓ **Physiologically** - Proliferation of Breast epithelium and Uterus smooth muscle
- ✓ **Pathologically** - Endometrium and Thyroid Hyperplasia
- ✓ **Compensatory**- Hyperplasia of remaining liver and Kidney
- ✓ Concurrent Hyperplasia and Hypertrophy occur in Uterus

Metaplasia

- ✓ Replacement of one adult cell type by another cell type(Epithelial or mesenchymal)
- ✓ Epithelial metaplasia is reversible& Mesenchymal metaplasia is irreversible
- ✓ Hyperplasia of Fibroblast to Chondroblast or Osteoblast is mesenchymal Hyperplasia
- ✓ Due to Chronic inflamnation , irritation and Vitamin A deficiency

Dysplasia

- ✓ Change in cell size shape and Polarity
- ✓ Abnormal mitoses
- ✓ Due to chorniclrritation , inflammation and infection
- ✓ E.g Actinic Keratosis

Calcification

Dystrophic

- ✓ Deposition of Ca in dead tissue with normal Ca metabolism
- ✓ Due to Necrosis or injury

Associated with

- ✓ TB (lung and pericardium) liquefactive necrosis , fat and caseous necrosis, Aortic stenosis(Damage heart valve) schistosomiasis, congenital CMV, toxoplasmosis, rubella, psammoma bodies, CREST syndrome, atherosclerotic plaques , Dead fetus and Hyadatid cyst

Metastatic

- ✓ Deposition of Ca in normal tissue due to abnormal Ca metabolism(Hypercalcemia)

Hypercalcemia due to

- ✓ Hyper parathyroidism , Hyperthyroidsim ,vitamin D intoxication , Sarcoidosis , Multiple myeloma and dialysis
- ✓ Predominantly in interstitial tissues of Lungkidney, and gastric mucosa

Pigments

Exogenous

- ✓ Carbon(Coal Dust)
- ✓ Iron
- ✓ Silicon

CamScanner

- ✓ Lipofusin
  1. Yellow brown Wear and tear pigment with aging due to Brown atrophy >Autophagy
  2. Autopsy of elderly person will reveal deposits in heart, colon, liver, kidney, eye, and other organs
- ✓ Melanin
- ✓ Hemosiderin

Apoptosis

- ✓ ATP-dependent programmed cell death.
- ✓ Involved activation of Caspases
- ✓ Characterized by deeply eosinophilic cytoplasm and basophilic nucleus, pyknosis, and karyorrhexis.
- ✓ Cell membrane typically remains intact without significant inflammation (unlike necrosis).
- ✓ Pro-Apoptotic – BAX and BAK
- ✓ Anti-Apoptotic – BCL2, BCL-XL andMCL1
- ✓ Fregmentation of DNA into nucleosime size particle called Apoptotic bodies or Councilman bodies

Hypoxia

- ✓ Neuron most sensitive to hypoxia
- ✓ Myocardia cell sensitive to hypoxia and infarction
- ✓ Epithelial cell of PCT senstive to Hypoxia
- ✓ Fibroblast resistant to Hypoxia

Types

Hypoxic Hypoxia (Decrease O_2 tension)
- High altitude
- V/Q mismatch

Anemic Hypoxia (Decrease O_2 Carrying)
- Anemia
- CO Poisning

Stagnant Hypoxia (Low Perfusion)
- Heart failure
- Shock

Histotoxic Hypoxia (Not Able to use O_2)
- Cyanide poison

Types of infarcts

- ✓ **Red infarcts** – Occurs in venous occlusion and tissues with multiple blood supplies e.g., liver, lung, intestine, testes and with reperfusion (e.g., after angioplasty).
- ✓ **White infarcts-** Occurs in solid organs with a single (end arterial) blood supply e.g., heart, kidney

CELL PATHOLOGY

1- Pancreatic tissue in gastric mucosa is related to which of following
A- Dysplasia
B- Choriostoma
C- Metaplasia
D- Hyperplasia
E- Anaplasia
Ans: B

2- Earliest sign of reversible cell injury:
A- Hydropic changes.
B- Myelin figures
C- Pyknosis
D- Cell membrane damage
E- Lysosome Rupture
Ans: A (Robins)

Explanation:
Reversible Cell injury
- First manifestation is cellular swelling. On microscopic examination small clear vacuoles may be seen within cytoplasm that represent pinched off segment of ER. This is called hydropic change or vacuolar degeneration.

Ultra structural changes:
- Plasma membrane blebs & loss of microvilli
- Mitochondrial Swelling with small amorphous densities
- Dilation of Endoplasmic reticulum with intracytoplasmic Myelin figure
- Nuclear Alteration

Irreversible Cell injury:
- Hall mark is Cell membrane damage
- Myelin figure derived from damage cell membrane
- Dilation of mitochondria with Large amorphous densities

Nuclear changes:
- Karyolysis – Loss of DNA and basophilia fade
- Pyknosis – Nuclear Shrinkage and increase Basophilia
- Karyorhhexis – Pyknotic nucleus undergo fragmentation

3- Biopsy of stomach done, there was none specialized gastric tissue and scattered goblet cells this is related to:
A- Metaplasia
B- Dysplasia
C- Ca stomach
D- Ulcer
E- Hyperplasia
Ans:

4- Type of change in metaplasia is
A- Polarity change
B- Irreversible change
C- Necrotic change
D- Functional and morphological change
E- Apoptotic
Ans: D

5- Increase in cell no is called as:
A- Atrophy
B- Hypertrophy
C- Hyperplasia
D- Metaplasia
E- Anaplasia
Ans: C

Explanation
- Increase in size – Hypertrophy
- Increase in cell no. – Hyperplasia

6- Mechanism of apoptosis in autoimmune disease is:
A- Molecular mimicry
B- Cross infection with virus
C- Gain of self-tolerance
D- Atropy
Ans: A

7- A young boy had injury to his thigh. After some months he presents with a mass at that spot The mass shows hemorrhage with bony trabeculae. This is most likely:
A- Metaplasia
B- Dysplasia
C- Metastatic calcification
D- Hyperplasia
E- Dystrophic calcification
Ans: A

8- After transplant liver recent size increase than previous in both donor and recipient by which mechanism?
A- Atrophy
B- Dysplasia
C- Hyperplasia
D- Hypertrophy
E- Anaplasia
Ans: C

9- Cells which cant regenerate after injury is which of following?
A- Permanent cells
B- Labile cells
C- Skeletal muscles
D- GIT
E- Liver

CamScanner

Explanation:
Labile Cells (Dividing)
- Surface Epithelia
- Columnar Epithelium of GIT tract, Uterus and fallopian tube
- Transitional epithelium of urinary tract
- Cells of Splenic, lymphoid and Hemopoietic tissu

Stable (Quiescent) Cells
- Parenchymal Cells of Liver, Kidney and Pancreas
- Mesenchymal Cells e.g Fibroblast and Smooth muscles
- Vascular Endothelial Cells

Permanent (Non Dividing) Cells
- Nerve, Skeletal muscle and Cardiac muscle
- Cannot Regenerate – Lens> Skeletal Muscle > Neuron > Cardiac
- Cannot Reproduce – RBC

10- Pathological process by activating caspases is which of following?
A- Necrosis
B- Apoptosis
C- Calcification
D- Metaplasia
E- Cytoskeltal degeneration
Ans: B

11- Type of change in metaplasia is:
A- Polarity change
B- Irreversible change
C- Necrotic change
D- Epithelial change
E- Apoptotic
Ans: D

12- A cell was on microscopic examination large mitochondrial densities are found indiating:
A- Reversible cell injury
B- Irreversible cell injury
C- Apoptosis
D- Necrosis
E- Inflammation
Ans: B(Robins)

13- Which of following is common cause of metastatic calcification in kidney?
A- Vit. A deficiency
B- Vit. D deficiency
C- Hyperparathyroidism
D- Hypothyroidism
E- Heart failure
Ans: C

Explanation:
Causes include
Hypercalcemia
- Primary hyperparathyroidism
- Hypervitaminosis D
- Sarcoidosis
- Hydroxyapatite deposition

Hyperphosphtaemia
- Phosphate derived excess Ca from normal tissue and deposit in basal ganglia cause metastatic Calcification
- CRF
- Hypoparathyroidism

Hyperuricemia

14- A microbiologist was examining a slide under microscope it show cell shrinkage, condensed nuclei in cells. Irregular cell membrane of cells what is happening to tissue?
A- Apoptosis
B- Necrosis
C- Reversible cell injury
D- Irreversible cell injury
E- Hypoxia
Ans: A

15- After a finger cut accidentally patient develop Abcess and fever type of necrosis?
A- Wet gangerene
B- Caugulatie
C- Liquefactive
D- Caseous
E- Fibrinoid
Ans: C

16- Apoptosis is the gaurdian mechanism for cells what happens in apoptosis?
A. Cell swelling
B. Cell shrinkage
C. Cell membrane damage
D. Organelle swelling
E. Nuclear membrane damage
Ans: B

17- Gastrocnemius size is reduced after cast applied for few weeks of fracture is most likely due to:
A. Decrease Blood supply
B. Decrease muscle caliber
C. Denervation atrophy
D. Decrease Actin & Myosin
Ans: D

18- Endogenous pigmentation causes:
A. Hemolysis
B. Hemosiderosis
C. Melatonin
D. Atrophy
Ans: B

19- Regeneration of liver is an example of:
A- Hypertrophy
B- Hyperplasia
C- Metaplasia
D- Fibrosis
Ans: B

20- Cells stain basophilia due to:
A- Ribosome
B- Lysosomes
C- SER
D- Peroxisomes
Ans: A

21- Sarcoma diagnosis by
A- Increase Vascularity
B- Pleomorphism
C- Metaplasia
D- Dysplasia
Ans: A

22- Platelets adherence facilitated by:
A- Smooth Endothelium
B- Rough Endothelium
C- Prostacyclin
D- NO
Ans: B

23- Most prominent feature of reversible cell injury:
A- Myline figure
B- Cellular swelling
C- Mitochondrial dysfunction
D- Atrophy
Ans: B

24- Aplasia:
A- Decrease in cell size
B- Failure of cell production
C- Decrease cell production
D- Absence of organ development
Ans: D (First aid)

25- The mucosal cells lining changes in the lower portion of esophagus is called:
A- Hyperplasia
B- Metaplasia
C- Anaplasia
D- Hypertrophy
Ans: B

26- Microscopic features of polyarteritis nodosa:
A- Caseous necrosis
B- Caugulative necrosis
C- Liquefactive necrosis
D- Fibrinoid necrosis
Ans: D

27- Pap smear, thick endothelium and malignancy cells shows:
A. Squamous cervical anaplasia
B. Metaplasia
C. Dysplasia
D. Squamous metaplasia
Ans: C

28- Parotid gland enlargement due to stone in parotid duct what will be cause of death of cells in gland?
A- Degeneration
B- Necrosis
C- Aplasia
D- Apoptosis
E- Gangrene
Ans: D

29- Transient adhesion of WBC to endothelium:
A. Selectin
B. Integrins
C. ICAM
D. VCAM
E. Vimentin
Ans: A

Explanation:
- Tansient adhesion – Selectin
- Firm adhesion – Integrin

30- Gastric epithelium is found in gall bladder may be due to:
A. Metaplasia
B. Anaplasia
C. Aplasia
D. Atrophy
Ans: A

31- Reversible Change in cell surface size and shape:
A. Dysplasia
B. Metaplasia
C. Anaphasia
D. Hyperplasia
Ans: A

32- Cell swelling in hypoxic injury is due to:
A- Entry of water from surroundings
B- Intracellular glycogen accumulation
C- Intracellular lipid acomulation
D- Intracellular lipofuscin accumulation
E- Intracellular protein accumulation
Ans: A

33- Dysplasia is recognized by:
A- Dyskeratosis
B- Loss of polarity and architecture
C- Pleomorphism
D- Mitotic figures
E- Invasion

CamScanner

34- Stab injury wound healing with abundant collagen & raised lesion projecting beyond original wound:
A- Keloid
B- Hypertrophic Scar
C- Granulation
D- None
Ans: A

Explanation:
- Keloid extends beyond boarders of original wound with claw-like projections typically on earlobes, face & upper extremities.
- Hypertrophic Scar is confined to boarders of original wound.

35- Free radicals are produced by which of the following poisoning:
A- CCL4
B- Ethanol
C- Opioids
D- Aspirin
Ans: A

Explanation:
- CCL4 produces free radicals and leads to hepatocytes damage.

36- Morphological & functional change is
A- Dysplasia
B- Atrophy
C- Metaplasia
D- Anaplasia
Ans: C

37- Dysplasia refers to:
A. Disordered Cellular growth
B. Failure of cell production
C. Decrease in cell production
D. Increase in cell production
Ans: A

38- Patient presented with vomiting blood, upper GI endoscopy shows columnar epithelium, 3cm above the GE junction, most likely morphological change is:
A- Dysplasia
B- Metaplasia
C- Anaplasia
D- Atrophy
Ans: B

39- Which of the following is the prominent step in irreversible cell injury?
A. Cell membrane damage
B. Massive Calcium influx
C. Cellular Swelling
D. Mitochondrial swelling

40- Cellular vault is maintained by:
A- Apoptosis
B- Necrosis
C- Lysosome
D- Enzymatic Destruction
E- Transport of mRNA
Ans: E>A

41- The mechanism of gene involvement for self – destruction is termed as:
A. Necrosis
B. Ischemia
C. Apoptosis
D. Cell – lysis
Ans: C

42- Pulmonary TB patient has cavitation with calcification. Type of change:
A- Dystrophic calcification
B- Metastatic calcification
C- Benign calcification
D- Malignant calcification
Ans: A

Explanation:
Dystrophic Calcification
- TB (lung and pericardium)
- granulomatous infections
- liquefactive necrosis
- fat necrosis
- infarcts
- thrombi
- schistosomiasis
- congenital CMV
- toxoplasmosis
- rubella
- psammoma bodies
- CREST syndrome
- atherosclerotic plaques

Metastatic Calcification
- Kidney
- Lung
- Gastric mucosa

43- A man having Hep C on histology eosinophilic granules in cytoplasm with compact chromatin:
A- Apoptosis
B- Necrosis
C- Fibrosis
D- Caseous necrosis
Ans: A

44- Liver damage occurred, binucleated cells were found which are due to?
A- DNA without histones
B- Histones without DNA
C- Karyokinesis without cytokinesis
D- RNA

45- Diagnostic feature of a dead cell is:
A- Pyknosis of nucleus
B- Karyorrhexis
C- Karyolysis
D- Cell shrinkage
E- Hydropic change
Ans: A

46- During hypertrophy?
A- Increase in DNA content.
B- Increase in no of cells
C- Increase Cytoplasm of cell
D- Decrease in no of cell
Ans: A

47- What starts apoptosis?
A- BCL2
B- P53
C- KRAS
D- BRCA
Ans: B

48- Nucleolus contains:
A- Large amount of DNA
B- Increase amount of RNA
C- Decrease amount of RNA
D- Increase amount of ribosome
Ans: B

49- Patient smokes 20 cigarettes per day what will be change in his lungs?
A- Metaplasia
B- Anaplasia
C- Dysplasia
D- Hyperplasia
E- Neoplasia
Ans: A

50- Which change makes possible for mother to lactate for whole year?
A. Lobular hypertrophy
B. Lobular hyperplasia
C. Ductal hypertrophy
D. Stromal hyperplasia
Ans. B

51- Respiratory burst is used for:
A- Inactivation of bacteria and viruses
B- Killing larvicidal effect
C- Has bacteriostatic property
D- Has bactericidal effect
Ans: D

52- Vaginal adenosis is a type of?
A- Dysplasia
B- Metaplasia
C- Atrophy
D- Hypertrophy
Ans. B

53- Woman has leiyomyoma and epithileum covering endometrium shows abundant stroma with a smaller number of endometrial glands.What is happening in endometrium?
A- Atrophy
B- Hypertrophy
C- Metaplasia
D- Hyperplasia
Ans: A

54- Which of the following shows metaplasia?
A- Vitamin B deficiency
B- Vitamin A deficiency
C- Vitamin C deficiency
D- Vitamin D deficiency
E- Vitamin E deficiency
Ans: B

55- A pathologist see on slide thatneutrophils are utilizing oxygen.Burst O2 reaction was seen in whichstep it is necessary?
A. Phagocytosis
B. Microbacterial activity of neutrophils
C. Vascular permeability
D. Inflammation
Ans: B

56- Ischemia ,Infarction and infection all cause Cell injury what is common thing that will happen due to cell injury by all of these
A. Lipid accumulation
B. ATP depletion
C. Free radical production
D. Protein Accumulation
Ans: C

57- RBCs are kept in a solution with Containing urea What will happen
A. Cell will shrink
B. Cell will swell and lyse
C. Cell will shrink and lyse
D. Cell will shrink then swell and then lyse
Ans: B

Explanation:
RBC in Only urea solution – Cell will swell and lyse
RBC in Urea with hypotonic solution – Cell will swell and lyse
RBC in Urea with hypertonic solution – Cell will shrink swell and lyse
RBC in hypertonic solution – Shrink Transiently

CamScanner

58- In hypernatremia what will happen?
A. Cell Lysis
B. Degranulation of lysomal enzymes
C. Cell shrinkage
D. Cell swelling
E. Decrease osmolarity of ICF
Ans: C

59- A 65 year old man having fatique pallor and weight loss. A golden yellow Pigment seen in liver which turn blue on staining this is?
A. Hemosiderin
B. Lipofuscin
C. Hemoglobin
D. Hemochromatosis
Ans: B

60- 28 year old male had intestinal obstruction at terminal part of ileum. Biopsy of that part shows granulomatous epitheloid cells. What type of necrosis will be seen?
A- Caseous
B- Coagulative
C- Fat necrosis
D- Liquefective
Ans: A

61- A 45 year old man with a long history of alcoholism presents with severe epigastric pain nausea vomiting fever and increase in serum amylase diagnosis of acute pancreatitis superimposed on chronic pancreatitis was made in this condition which of the following types of necrosis is most characteristic:
A- Coagulative necrosis
B- Fat necrosis
C- Fibrinoid
D- Caseous
E- Liquefactive necrosis
Ans: B

62- What type of necrosis is seen in omentum
A- Fat necrosis
B- Coagulative necrosis
C- Fibrinoid Necrosis
D- Liquefactive Necrosis
E- Medial necrosis
Ans: A

63- Ionizing radiation cause damage to cell by which of following?
A- Oxygen
B- Free radicals
C- Apoptosis
D- Fatty change
Ans: B

64- Coagulative necrosis seen in
A- Brain
B- Kidney
C- Heart
D- TB
Ans: C

65- A patient having Hypoxia. His PO2 measured is 65mmhg. Type of hypoxia is:
A- Anemic hypoxia
B- Hypoxia hypoxia
C- Cellular hypoxia
D- Histotoxic hypoxia
Ans: B

Explanation:
Hypoxic Hypoxia (Decrease O_2 tension)
- High altitude
- V/Q mismatch

Anemic Hypoxia (Decrease O_2 Carrying)
- Anemia
- CO Poisning

Stagnant Hypoxia (Low Perfusion)
- Heart failure
- Shock

Histotoxic Hypoxia (Not Able to use O_2)
- Cyanide poison

66- A 30-year-old man sustains a left femoral fracture in a skiing accident, and his leg is placed in a plaster cast. After the leg has been immobilized for several weeks, the diameter of the left calf has decreased. This change is most likely to result from which of the following alterations in the calf muscles?
A- Decrease Collagen
B- Increase Protein synthesis
C- Decrease contractile protein synthesis
D- Hyalinosis
Ans: C

67- Apoptosis is induced by activation of:
A- Caspases
B- Oncosuppresors
C- Bcl 2 activation
D- P53
E- Nucleases
Ans: A

68- Continous contraction without gap is
A- Partial tetanus
B- Complete tetanus
C- Paralysis
D- Flacidity

69- Ischemia, infarction and infection all cause cell injury what is common thing that will happen due to cell injury by all of these?
A- Lipid accumulation
B- ATP depletion
C- ROS production
D- Protein Accumulation
Ans: C

70- Hormone therapy against malignant condition involve which mechanism
A- Apoptosis
B- Degeneration
C- Necrosis
D- Infarction
E- Degeneration
Ans: A

71- A male with long standing history of HTN died. On Autopsy his heart was found to be 600g. Reason of his increase heart size is
A- Hyperplasia
B- Metaplasia
C- Atrophy
D- Hypertrophy
E- Anaplasia
Ans: D

Explanation:
- Cardiac Cells are non dividing cells so only hypertrophy will occur in these cells after hypertension work overload.

72- A patient who is chronic alcoholic presented to his physician GPE unremarkable. Albumin -- 4.1 AST 40 and ALT 40 what will be microscopic change
A- Fatty Change
B- Hypertrophy of SER
C- Hyperplasia of liver
D- Atrophy of Liver
Ans: B

73- Type of necrosis in Breast trauma is
A- Fat necrosis
B- Coagulative necrosis
C- Caseous necrosis
D- Liquifactive necrosis
E- Fibrinoid necrosis
Ans: A

74- Necrosis will have:
A- Metaplasia
B- Metastatic calcification
C- Dystrophic calcification
D- Atrophy
Ans: C

75- Fastest Regeneration occur in:
A- Kidney
B- Spleen
C- Liver
D- Intestine
E- Lungs
Ans: C

76- A patient Chest Pain with MI suddenly on autopsy what will be findings?
A- Fibrinoid necrosis
B- Coagulative necrosis
C- Liquefactive necrosis
D- Caseous necrosis
Ans: B

77- A 30-year-old man sustains a left femoral fracture in a skiing accident, and his leg is placed in a plaster cast. After the leg has been immobilized for several weeks, the diameter of the left calf has decreased. This change is most likely to result from which of the following alterations in the calf muscles?
A. Aplasia
B. Hypoplasia
C. Disuse Atrophy
D. Dystrophy
E. Hyalinosis
Ans: C

78- Increase nuclear to cytoplasmic ratio in dysplasia leads to
A- Abnormal RNA production
B- Abmormal DNA production
C- Abnormal protein synthesis
D- Abnomal mitochondria
Ans: B

79- Apoptosis is characterized by:
A- Nucleus fragments
B- Plasma membrane disruptions
C- No Host inflammation
D- Adjacent inflammation
Ans: C

80- Cells with pleomorphic nuclei and abnormal growth this is:
A- Squamous Metaplasia
B- Dysplasia
C- Squamous cervical Anaplasia
D- Adenoma
E- Carcinoma

CamScanner

81- Enzymes involved in cell remodelling of tissue:

A- Myeloperoxidase
B- Elastase
C- Lipase
D- Caspase

Ans: B

Explanation:

- Remodelling of tissue by – Metalloproteinase > Collagenase > Elastase

82- Uncontrolled mitosis and atypical nuclei associated with

A- Pleomorphism
B- Dysplasia
C- Neoplasia
D- Atrophy

Ans: C

83- Outline of cell is preserved in which of the following necrosis:

A- Fat
B- Fibrinoid
C- Coagulative
D- Liquefactive

Ans: C

84- Gastrocnemius size is reduced after cast applied for few weeks of fracture is most likely due to:

A- Decrease Blood supply
B- Decrease muscle caliber
C- Denervation atrophy
D- Decrease protein synthesis and increase degradation

Ans: D

85- Scientist see Decrease DNA and cell activity related to:

A- Cellular Hypertrophy
B- Cellular aging
C- Apoptosis
D- Necrosis

Ans: B

86- Most common feature in Ischemia injury cytotoxic cell injury and burn injury is

A- Lipid accumulation
B- ATP depletion
C- ROS production
D- Protein Accumulation
E- DNA damage

Ans: C

87- A female with intraductal Breast carcinoma ,All features suggestive of intraductal cancer with peripheral Desmoplasia . What's the desmoplasia ?

A- Metastasis involvement of surrounding tissues
B- Non neoplastic proliferation of fibrous connective tissue
C- Change of one epithelium to another
D- Increase in Cell Size

Ans: B

88- A Patient presented with anuria .Immediately after severe episodes of diarrhea and vomiting his Cr is 9.1 after 3 Session of dialysis patient failed to have urine output . Renal biopsy show cortical necrosis and severe acute tubular necrosis. What is cause in this patient?

A- Drug induced injury
B- Irreversible injury
C- Apoptosis
D- Cell death
E- Reversible injury

Ans: B

89- A man got fractured of a bone in an RTA and plaster is done . After few weeks there is atrophy of the tissue, what's the reason?

A- Decrease protein regeneration
B- Increased protein synthesis with decrease protein degradation
C- Increased protein degradation with decrease protein synthesis
D- Increase blood supply
E- Decrease blood supply

Ans: C

90- The process of apoptosis is lost during the carcinogenic activity. Which of the following factor has anti apoptotic activity:

A- BCL
B- BCL1
C- BAX
D- PKL
E- BAK

Ans: A (Robins)

Explanation:

- Pro-Apoptotic – BAX and BAK
- Anti-Apoptotic – BCL2, BCL-XL and

91- Young healthy patient with no comorbidies after RTA, leg stitching done he was kept on antiboitics and bone growth was normal but fluid continued to discharge from skin wound even after 3 weeks what is cause

A- Coagulopathy
B- Foreign body
C- Decrease blood supply
D- Platelets function defects

Ans: B

92- Cytoplasm was freeze fracture plasmalemma, containing intramembrane particle. What is it called?

A- E face
B- Replica
C- Cis face
D- Trans face
E- P face

Ans: E

Explanation:

- E Face is extracellular face and outer leaflet of cell membrane
- P face is protoplasmic face and inner leaflet of cell membrane contain more intramembrane particles (Proteins)

93- A young boy had fracture while playing football. Later he presents with swelling on the anterior thigh. Biopsy showed a bony trabeculae mass containing hemorrhage. This is most likely due to(Medicine Feb 2025)

A- Metaplasia
B- Dysplasia
C- Anaplasia
D- Metastatic Calcification

Ans: A

94- A microbiologist was examining a slide under a microscope.It shows cell shrinkage, condensed nuclei, Apical blebs, increase N/C ratio & irregular cell membrane. What is happening to tissues? (Medicine Feb 2025)

A- Dysplasia
B- Necrosis
C- Reversible cell injury
D- Irreversible cell injury
E- Apoptosis

Ans: E

95- Most reliable sign of irreversible cell injury(Medicine Feb 2025)

A- Karyolysis
B- Mitochondrial damage
C- Pyknosis
D- Autophagy of cell
E- Massive Ca influx

96- A patient presented Chest Pain with MI suddenly collapsed on autopsy what will be findings?(Medicine Feb 2025)

A- Fibrinoid necrosis
B- Coagulative necrosis
C- Liquefactive necrosis
D- Caseous necrosis

Ans: B

97- Muscle mass increased by doing exercise is called(Surgery Feb 2025):

A- Dysplasia
B- Metaplasia
C- Atrophy
D- Hypertrophy

Ans: D

98- Bone spicules found in muscle around a few months after injury to the said muscle. What type of response is this(Surgery Feb 2025)?

A- Metaplasia
B- Dystrophic calcification
C- Metastatic calcification
D- Dysplasia

Ans: A

99- Polychromasia in RBCs due to: (Surgery Feb 2025)

A- Cytoplasmic RNA
B- Cytoplasmic DNA
C- Nuclear RNA
D- Microtubules & Filaments
E- Mast cells

Ans: A

100- A patient presented with the Chronic fever , Night sweats Headache , Lethargy , Weight loss And Cervical Lymphadenopathy Epitheloid cells in sputum. CXR shows diffuse nodular opacities in apical lobe. Which type of Necrosis is seen in enlarged lymph nodes in this scenario(Gynae & Obs Feb 2025)?

A- Non caseous necrosis
B- Caseous necrosis
C- Coagulative necrosis
D- Liquefactive necrosis

Ans: B

Explanation:

- The scenario is related to Tb and on

CamScanner

101- A patient presented with a Carbuncle on Nape of his Neck. It was removed. On histology, Sheets of lymphocytes with erythema & necrotic exudate were seen. Which type of inflammation is evident? (Gynae & Obs Feb 2025)?

A- Acute
B- Chronic
C- Serous
D- Fibrinous
E- Granulomatous
Ans: B

102- Gastric mucosa present in middle 1/3rd of Esophagus: related to(Gynae & Obs Feb 2025)?

A- Hamartoma
B- Gastric metaplasia
C- Choriostoma
D- Choriocarcinoma
E- Metastatic Carcinoma
Ans: C

103- Seen in necrosis on cellular level? (Gynae & Obs Feb 2025)?

A- Fragmented RBCs smear
B- Spiral DNA
C- Proteolysis of caspases
D- Ladder pattern DNA
Ans: D

104- Most reliable sign of irreversible cell injury(Radiology Feb 2025)

A- Cell membrane damage
B- Mitochondrial damage
C- nuclear membrane damage
D- Autophagy of cell
E- Massive Ca influx
Ans: A>E

Explanation:

Reversible Cell injury

- First manifestation is cellular swelling. On microscopic examination small clear vacuoles may be seen within cytoplasm that represent pinched off segment of ER. This is called hydropic change or vacuolar degeneration.

Ultra structural changes:

- Plasma membrane blebs & loss of microvilli
- Mitochondrial Swelling with small amorphous densities
- Dilation of Endoplasmic reticulum with intracytoplasmic Myelin figure
- Nuclear Alteration

Irreversible Cell injury:

- Hall mark is Cell membrane damage
- Myelin figure derived from damage cell membrane
- Dilation of mitochondria with Large amorphous densities

Nuclear changes:

- **Karyolysis** – Loss of DNA and basophilia fade
- **Pyknosis** – Nuclear Shrinkage and increase Basophilia
- **Karyorhhexis** – Pyknotic nucleus undergo fragmentation

105- Cells characteristic to "Granuloma" are(Radiology Feb 2025):

A- Giant Cells+Plasma Cells
B- Macrophages+Neutrophils
C- Lymphocytes +Macrophages
D- Giant Cells+Macrophages
E- Giant Cells+Lymphocytes
Ans: C(Robins)

Explanation:

- Activated macrophages in granulomas have pink, granular cytoplasm with indistinct cell boundaries; these are called epithelioid cells because of their resemblance to epithelia. Typically, the aggregates of epithelioid macrophages are surrounded by a collar of lymphocytes. Frequently, but not invariably, multinucleate giant cells 40 to 50 µm in diameter are found in granulomas. Such cells derive from the fusion of multiple activated macrophages

106- A 30-year-old man sustains a left femoral fracture in a car accident, after that he was on prolong bed rest On examination his calf muscles are atrophied which of the following is cause of his condition(Radiology Feb 2025)

A- Aplasia
B- Metaplasia
C- Immobilization
D- Dystrophy
E- High protein intake
Ans: C

107- Hypoxic cell injury features? (Anesthesia Feb 2025)

A- ↓ Na+/K+ ATPase
B- ↓ Na+
C- ↓ Ca^{2+}
D- ↓ pH
E- ↓ ATP
Ans: E

INFLAMMATION & REPAIR QUICK HINTS

Acute Inflammation

✓ Initial step is transient Vasoconstriction followed by Vasodilation then Margination

Steps

Margination

✓ Due to Increase vascular permeability RBC acquire central position and Neutrophil peripheral or marginal position called margination

Rolling

✓ Leukocytes roll along the endothelium called Rolling

Adhesion

✓ Adhesion of Leukocyte to Endothelium
✓ WBC attach to Endothelium -ICAM
✓ WBC attach to bacteria – Opsonin

Transmigration(Diapesesis)

✓ Migration of neutrophils along the smooth epithelium of blood vessels

Migration(Chemotaxis)

✓ Movement of Leukocyte toward site of injury by chemical mediators

Phagocytosis , Degranulation and killing

✓ Neutrophil and macrophage recognize organisms if they are coated with Fc Fragment of igG and C3b component of complement and then attach and finally kill them

Mediators of inflammation

Cell derived

1)Preformed

✓ Histamine -By Mast cell , Basophil and platelets
✓ Serotonin(By platelets)

2)De novo synthesized

A)Arachidonic acid two pathway

i)Cyclooxygenase

✓ Prostacyclin(By endothelium) –Vasodilation + Inhibit platelets aggregation
✓ PG E2 D 2 and F2 - Vasodilation
✓ Thromboxane(By platelets) -Cause Platelets aggregation

ii)Lipoxegenase

✓ LTB4 C4 and D4 –Vasoconstriction +Bronchospasm + Increase Vascular permeability

iii)Platelets activating factors - Platelets aggregation +Increase vascular permeability +Chemotaxis

iv)Cytokine

✓ IL 1 - Fever and acute phase protein
✓ TNF - Fever
✓ IL8 -Powerfullchemoattractant of neutrophil with C5a

Plasma derived

1)Compliment derived products

✓ **Anaphylotoxins** -C3a -C5a
✓ **Chemotaxis** -C5a for neutrophil and monocyte
✓ **Phagocytosis** -C3b(Neutrophil and macrophages)
✓ **Membrane attack complex** -C5-9 (Cytolysis)
✓ Early Compliment Deficiency (C1-4) –Increase Risk of Recurrent Pyogenicsinus , Respiratory infection and SLE
✓ Terminal C

CamScanner

- ✓ C1 Esterase Inhibitor Deficiency –Result in Angioedema, Increase Bradykinin and Low C4 Level

2)Hagman factor activation

- ✓ Kinnin system and coagulation system

Summary

- ✓ 1st line in Tissue -- Macrophages
- ✓ 1st line in Blood -- Neutrophils
- ✓ 1st line on Surface --Skin
- ✓ Major scavengers --Macrophages
- ✓ Phagocytosis done by --Neutrophils and macrophages
- ✓ Opsonization -- C3b and Fc fragment of igG
- ✓ Most potent Chemo tactic Factor--LTB4 > C5a
- ✓ Pain--Bradykinin> Prostaglandins E2
- ✓ IL-1 and TNF – Fever mediator
- ✓ Prostaglandins F2, E2 and D2 – Vasodilation
- ✓ Late mediator of Inflammation – PG &Leukotriens
- ✓ Initial mediator of inflammation – Histamine
- ✓ Anaphylotoxin -C3a -C5a
- ✓ Membrane attack complex -C5-9
- ✓ Fibrinopeptide increase vascular permeability
- ✓ Neuropeptide cause neurogenic inflammation

Out come of Acute inflammation

- ✓ Resolution and healing (IL-10, TGF-β) Persistent acute inflammation (IL-8)
- ✓ Abscess (acute inflammation walled off byfibrosis)
- ✓ Chronic inflammation (antigen presentationby macrophages and other APCsActivation of CD4+ Th cells)
- ✓ Scarring

Chronic inflammation

1)Mononuclear cells -Monocytes –Macrophages ,Lymphocytes&Plasma cells
2)Eosinophils
3)Fibroblast

- ✓ Most **important** cell is Macrophage
- ✓ Most **Abundant** cell is Lymphocytes
- ✓ Plasma cell form antibodies

Lymphocytes type

A)T cell

- ✓ i)Helper T cell (Help other)
- ✓ ii)Suppressor T cell (Suppress other)
- ✓ iii)Cytotoxic T cell (Kill organism)

B)B cell

- ✓ B cell form Plasma cell that form immunoglobulins

C)NK cell

- ✓ NK cell is anti-tumor cell
- ✓ NK cell kill virus infected cell
- ✓ CD56 is marker of NK cell

2)Eosinophils

- ✓ Seen in immune reaction and Parasitic infection

3)Fibroblast

- ✓ Role in healing and Scar formation

Granulomatous inflammation

- ✓ Seen in - TB , Leprosy , Syphilis , Sarcoidosis , Schistosoma , Cryptococus , Silicosis and Berylliosis

Granuloma

- ✓ Composed of Macrophages and Epitheloid cells
- ✓ Surrounding collar of Lymphocytes and Few plasma cells and rim of fibroblast

Multinucleated giant cells

1. Langham type giant cell
2. Foreign body giant cell
3. Touton giant cell(Xanthomatosis)

Granuloma types

- ✓ Immune- T cell mediated
- ✓ Foreign body Granuloma
- ✓ Soft Granuloma - TB
- ✓ Hard Granuloma - Sarcoidosis
- ✓ Gumma - Syphilis

Types of inflammation

Serous

- ✓ Outpouring of protein poor fluid e.g Skin blister from burn

Fibrinous

- ✓ Increase vascular permeability and leak of fibrinogen
- ✓ Occur in linning of body cavities

Prulent(Suppurative)

- ✓ Pus contain Dead Neutrophils
- ✓ e.g acute appendicitis , Folliculitis and Cellulitis(Phlegmon) and Fruncle

Pseudomembranous

- ✓ e.gDiptheria(Pseudomembrane in oropharynx)&C difficile(Pseudomembrane colitis)

Histiocytic

- ✓ Involve Mononuclear phagocytic systeme.g occur in typhoid fever

Interstitial and Perivascular

- ✓ Perivascular accumulation and interstitial infiltraion of Macrophages , Lymphocyte and plasma cells
- ✓ e.g viral infection ,Typhus and Rocky mountain spotted fever and Syphilis

Acute phase reactants

Positive

- ✓ C reactive protein- Marker of MI
- ✓ Fibrinogen -Endothelial repair
- ✓ Serum amyloid A protein
- ✓ Hepcidin - Decrease Iron absorption and Decrease release of Iron
- ✓ Ferritin - Bind and Squester iron

Negative

- ✓ Albumin
- ✓ Transferin

Repair

Regeneration

- ✓ Replacement of injured tissue by parenchymal cell of same type leaving no residual trace of previous injury

Fibroplasia

- ✓ Replacement of injured tissue by connective tissue leaving scar

CamScanner

Cell types

Labile cells (dividing)

- ✓ Surface epithelia
- ✓ Columnar epithelium of GIT tract ,Uterus and fallopian tube
- ✓ Transitional epithelium of urinary tract
- ✓ Cells of splenic, lymphoid and Hemopoietic tissue

Stable (quiescent) cells

- ✓ Parenchymal cells of liver, kidney and pancreas.
- ✓ Mesenchymal cells e.g Fibroblast and smooth muscles
- ✓ Vascular endothelial cells

Permanent (non-dividing) cells

- ✓ Nerve, skeletal muscle and cardiac muscle
- ✓ Cannot regenerate – Lens> Skeletal Muscle > Neuron > Cardiac
- ✓ Cannot reproduce – RBC

Growth Factors

- ✓ Basic FGF elaborated by macrophages
- ✓ Acidic FGF elaborated by neural tissue
- ✓ PDGF produce by Platelets and Macrophages
- ✓ **Angiogenesis** done by Basic FGF , VEGF and PDGF
- ✓ **Remodeling** of tissue by –Metalloproteinase > Collagenase >Elastase
- ✓ Maximum wound Strength reach in 3 months

Repair Factors

- ✓ LOCAL factor for delayed wound healing -- Infection
- ✓ SYSTEMIC factor for delayed wound healing -- DM > Anemia> malnutrition
- ✓ Keloid – Beyond wound margin + Type1 +3 Collagen.
- ✓ Hypertrophied Scar – With in wound margin+ Type 3 Collagen.
- ✓ Lymphatics return tissue fluid
- ✓ Lymphatics resolve inflammation

Factors affecting ESR

Increase ESR

- ✓ Most anemias
- ✓ Infections
- ✓ Inflammation (eg, giant cell [temporal] arteritis,
- ✓ polymyalgia rheumatica)
- ✓ Cancer (eg, metastases, multiple myeloma)
- ✓ Renal disease (end-stage or nephrotic syndrome)
- ✓ Pregnancy

Decrease ESR

- ✓ Sickle cell anemia
- ✓ Polycythemia
- ✓ HF
- ✓ Microcytosis
- ✓ Hypofibrinogenemia

Primary and Secondary Intension Wound Healing

Primary

- ✓ No wound Contraction
- ✓ Less inflammation ,Scar and Granulation tissue
- ✓ Occur when little surgical Damage occur
- ✓ Vice Versa for Secondary healing

INFLAMMATION & REPAIR

1- How long a wound takes to attain maximal tensile strength?
A- 3 months
B- 1 year
C- 6 weeks
D- 10 days
Ans A

2. Histamine most imp mediator of source of histamine?
A- Basophills
B- Mast cell
C- Macrophages
D- Eosinophills
E- Monocyte
Ans: B

3- Regeneration occurs in following tissues except?
A- Epidermis
B- Liver
C- Adrenal glands
D- Lens
Ans D

4- Patient having Pleural effusion, on microscopy lymphocytes, macrophage fibroblasts and epitheloid cells found this is which type of inflammation ?
A- Serous
B- Chronic
C- Granulomatous
D- Acute
E- Purulent
Ans: C

5- Person has developed edema and increase proteins having:
A- Tranduate
B- Exudate
C- Infection
D- None
Ans: B

6- Phagocytosis in tissues by
A- Natural killer cells and lymphocytes
B- Neutrophils and macrophages
C- Plasma Cells
D- White cells
Ans: B

7- Regeneration is least affected by
A- Diabetes
B- UV light
C- Corticosteroids
D- Infection
Ans: B

8- Person met RTA and has Multiple long bone fracture which type of necrosis may be seen?
A- Caseous Necrosis
B- Fat Necrosis
C- Coagulative Necrosis
D- Fibrinoid Necrosis
Ans: B

9- Healing of wound is done by:
A- Microtubules
B- Microfilament
C- Cytokeratin
D- None
Ans: B

10- After partial pancreatectomy type of Necrosis is:
A- Liquefective
B- Coagulative
C- Fat
D- Caseous
Ans: C

Explanation:
- Brain – liquefactive necrosis
- Kidney, heart and adrenal glands – Coagulative necrosis
- Tb- caseous necrosis
- Any vasculitis- fibrinoid necrosis
- Dry gangrene – Coagulative necrosis
- Breast trauma or abdominal trauma – Traumatic fat necrosis

12- Patient with multiple jaw draining abscesses. What will be seen in microscopy?
A- Granulomatous
B- Granuloma with abscess
C- Abscess only
D- All of the above
Ans: B

13- Opsonization is done by:
A- C5a
B- C3b
C- C3a
D- C4a
Ans: B

Explanation:
- Phagocytosis done by – Neutrophils
- Opsonization – C3b & IgG
- Cytolysis – C5b-9
- Neutrophills chemotaxis – C5a , LTB4 , IL-8
- Anaphylaxia- C3a, C4a , C5a
- Vasodilation – PG2, PGE2 , PGF2a , Bradykinin , PAF , Nitric oxide
- Vasoconsriction – Txa2, LTD4 , LTE
- Leukocyte adhesion - LFA1

CamScanner

14- Initial response to acute inflammation is
A- Chemotaxis
B- Margination
C- Vasodilation
D- Formation of prostaglandins
Ans: C

15- Which of the immunoglobulin is important for complement fixation?
A- IgG
B- IgA
C- IgE
D- IgM
Ans: D>A

16- Type of necrosis in TB:
A- Cogulative
B- Liquefactive
C- Caseous
D- Fibrinoid
Ans: C

17- Increase ESR is due to:
A- Increase plasma proteins
B- Decrease albumin
C- Roulex formation
D- Increase fibrinogen
E- Decrease temperature
Ans: B

18- New blood vesseles are formed by:
A- Angiogenesis
B- Vasculogenesis
C- Recanalization
D- Collaterals
Ans: B

19- A patient died of ischemic stroke, type of necrosis in brain:
A- Caugulative
B- Liquefactive
C- Caseous
D- Fatty
Ans: B

20- Patient having raised serum amylase four times having acute pancreatitis, what type of mesenteric necrosis seen:
A- Caugulative
B- Caseous
C- Fatty necrosis
D- Liquefactive
Ans: C

21- The features associated with healing of open wound include all except
A- Formation of granulation tissue
B- Infection
C- Contraction
D- Giant cell
Ans: D

22- Repair of inflammatory process begins by
A- 24 hours
B- 5-7 days
C- 3 weeks
D- 1 week
E- 2 weeks
Ans A

23- Granulomatous inflammation is characterized by:
A- Macrophages and Epitheloid cells
B- Lymphocytes, and basophils
C- B cells
D- Antibody
Ans: A

24- Dystrophic calcification seen in
A- Kidney
B- Lung
C- Gastric mucosa
D- Tb
Ans: D

Explanation:
Dystrophic Calcification
- TB (lung and pericardium)
- granulomatous infections
- liquefactive necrosis
- fat necrosis
- infarcts
- thrombi
- schistosomiasis
- congenital CMV
- toxoplasmosis
- rubella
- psammoma bodies
- CREST syndrome
- atherosclerotic plaques

Metastatic Calcification
- Kidney
- Lung
- Gastric mucosa

25- Boy presented with fever for few days.. His cytokines like IL 1 and TNF are raised. These are raised in?
A- Acute inflammation
B- Chronic inflammaton
C- Causes WBC recruitment
D- Stimulates IgE production
Ans: A

26- Liqufective necrosis seen in:
A- Focal bacterial infection
B- Trauma
C- Myocardium
D- Kidney

27- Strong anaphylactic action through:
A- C5a
A- C6a
B- C3a
C- C4a
D-
Ans: A

28- Chemotaxis involves:
A- Neutrophil migration away from site
B- Neutrophil migration towards site of inflammtion
C- Neutrophil Killing
D- Lymphocyte killing
Ans: B

29- In which of the following maximum chemotaxis occur?
A- Migration
B- Acute inflammation
C- Diapedesis
D- Margination
Ans: B

30- Female patient with IUCD and history of PID. Histopathology shows increase plasma cells and macrophages with interspread lymphoid follicles. This change is called:
A- Acute inflammation
B- Chronic inflammation
C- Fibrinous necrosis
D- Caseous necrosis
Ans: B

31- Boy cut his finger and develop fever and abscess due to which
A- Coagulative necrosis
B- Fat necrosis
C- Fibrinoid necrosis
D- Liquefactive necrosis
Ans: D

32- On histology liver shows centrally distorted area surrounded by epitheloid cells, lymphocytes and giant cells this is related to
A- Coagulative necrosis
B- Caseous necrosis
C- Acute hepatitis
D- Fat necrosis
E- Acute
Ans: B

33- ESR more than 100 is seen in:
A- RA
B- OA
C- Multiple Myeloma
D- SLE
E- Sjogren

34- Which of the following is a pain mediator?
A- Bradykinin
B- Prostaglandin
C- Histamine
D- C3b
E- C3a
Ans: A

Explanation:
- Pain – Bradykinin > Prostaglandins E2
- IL-1 and TNF – Fever mediator
- Prostaglandins F2, E2 and D2 – Vasodilation

35- After finger cut what is the first response of body after bleeding?
A- Blood Vessel Constriction
B- Prostaglandin
C- Neutrophil
D- Chemotaxis
E- Rolling of WBC
Ans: A

36- Which one of following produced by the action of lipooxygenase on arachidonic acid and is a potent chemotactic factor?
A- LTB4
B- C5a
C- C6a
D- Interleukin
E- C3a
Ans: A

37- Patient present after RTA with redness and on arm and feel pain on movement diagnose is:
A- Chronic granulomatous
B- Chronic inflammation
C- Acute inflammation
D- Subacute
Ans: C

38- A women presented with fever and pain after surgery mediators of her symptoms is:
A- IL1+TNF
B- LTB4
C- C5a
D- Prostaglandin
E- Leukotriens
Ans: A

39- Enzymes involved in cell remodeling of tissue:
A- Myeloperoxidase
B- Collegenase
C- Lipase
D- Caspase
Ans: B

Explanation:
- Remodeling of tissue by –

CamScanner

40- 33 years obese women had hysterectomy, lower segment pfannenstiel incision was given, there was serosanguinous discharge after 3 days, what is most likely cause?

A- Wound infection
B- Wound dehiscence
C- Anemia
D- Inguinal hernia
E- Wound Scar
Ans: B

41- Wound healing is not promoted by

A- Zinc
B- Vitamin C
C- Oxygen
D- Cortisol
Ans: D

42- Most common skin defense system is:

A- Skin and mucous secretion
B- Margination
C- Chemotaxis
D- Macrophages
E- Monocyte
Ans: A

Explanation:

- In tissue – Macrophages
- In blood – Neutrophils
- On surface – Skin
- Over All first line – Skin

43- A patient of burn had hypotension and tachycardia most likely diagnosis is:

A- DIC
B- Infection
C- Normal phenomenon
D- Cardiac arrest
Ans: A

44- A Patient with everted margin of Wound. Wound healing occurs beyond margin this is called

A- Hypertrophic scar
B- Keloid
C- Rash
D- Deformed Scar
E- Atrophic Scar
Ans: B

Explanation:

- Keloid – Beyond wound margin +Type 1 +3 Collagen.
- Hypertrophied – With in wound margin +Type 3 Collagen.

45- A girl spilled hot water develops bulla few hours after burn, Later erythma and fever. Fluid in bullae was opaque, redness and warm area around it what's the type of Inflamnation?

A- Fibrinous
B- Serous
C- Mucinous
D- Prulent
E- Catharal
Ans: B (Robins)

46- Marker of ischemic heart disease:

A- IL-1
B- TNF-alpha
C- TNF-beta
D- CRP
E- IL-8
Ans: D

47- Correct sequence of events for neutrophil migration toward the site of acute is:

A. Margination, adhesion, rolling, transmigration
B. Margination, rolling, adhesion, transmigration
C. Rolling, adhesion, margination, transmigration
D. Transmigration, rolling, adhesion, Margination
Ans: B

48- Angiogenesis in wound healing is done by which of the following?

A- Metalloprotenase
B- VEGF
C- Collagenase
D- TGF
E- Elastase
Ans: B

Explanation:

- Angiogenesis by – VEGF >PDGF
- Remodeling of tissue by – Metalloproteinase > Collagenase > Elastase

49- Post operative infection delays wound healing because

A- Capillary loops fails to develop
B- Fibroblasts are decrease in number
C- Collagen is destroyed
D- Wound packed with lymphocytes
Ans: C

50- Undescended testes increase risk of which of following?

A- Infertility
B- Malignancy
C- Enlargement of Testis
D- Large Testis
E- Small Testis
Ans: B

51- First mechanism in the pathogenesis of thrombus formation

A- Immobility
B- Endothelial injuiry
C- Turbulent blood flow
D- Hyperviscosity
Ans: B

52- The mechanism by which phagocytosis is enhanced and leads to better killing is which of the following?

A- Opsonization
B- Phagocytosis
C- Chemotaxis
D- Microbial Killing
E- Margination
Ans: A

53- Cause of fat necrosis in breast:

A- Peritonitis
B- Breast Trauma
C- RTA
D- Fat Embolism
Ans: B

54- After chemotherapy size decrease by which mechanism:

A- Atrophy
B- Apoptosis
C- Agenesia
D- Necrosis
Ans: B

55- A patient had an abdominal surgery. After few months, the scar became enlarged and nodular, biopsy shows high collagen and fibroblasts:

A- Foreign body due to sutures
B- Keloid scar
C- Infection
D- Contracture
Ans: B

56- Diapedesis refers to:

A- Migration of WBCs from intravascular compartment to interstitial space
B- Margination of WBCs
C- Chemotaxis
D- Deaths of Cells
Ans: A

57- Least important in wound healing is

A- Protein deficiency
B- DM
C- Obesity
D- Persistent infection
E- Foreign body
Ans: A

58- A 30-year-old patient presented with 3rd degree burn. He is most likely to develop:

A- Keloid
B- Scar
C- Contracture
D- Wound dehiscence
Ans: C

Explanation:

- In 3rd degree burns: contracture.
- If Black skinned person mentioned then: Keloid.

59- Wound contraction is the function of

A- Myofibroblasts
B- Osteoclasts
C- Osteocytes
D- Fibroblasts
E- Lymphocytes
Ans: A

60- Diagnosis of transudate is made upon:

A- High sodium
B- High potassium
C- Hypercellular
D- Hypocellular
Ans: D

61- The delay in wound healing is most commonly caused by:

A- Infection
B- Malnutrition
C- Foreign body
D- Immobility
Ans: A

62- A patient is suffering from Pseudomonas aeruginosa infection with fever. What factor can worsen this kind of infection?

A- IL-I
B- PG-E
C- TNF
D- CD4
Ans: C

Explanation:

- Fever – IL1 , IL6
- TNF – fever in pseudomonas aeruginosa

63- Most important cells for secondary intention healing

A- Myofibroblasts
B- Osteoblasts
C- Osteocytes
D- Fibroblasts

CamScanner

64- Exogenous pyrogens stimulate production of cytokines. What is the role of cytokines in the eventual production of fever?
A. Recruit neutrophils to kill bacteria
B. Stimulates prostaglandins (PG) synthesis
C. Directly acts on the hypothalamus
D. Cause increased production of fibrinogen.
E. Stimulates production of C-reactive proteins
Ans: B

65- Patient with chronic wound has oozing from wound would be due to
A. Thrombocytopenis
B. Leukemia
C. Foreign body
D. Thrombophilia
Ans: C

66- 70 years old female develop poor wound healing she is taking meat and protein diet. but her diet is deficient in vegetables and fruits which is deficient in the body
A. No synthesis of collagen
B. Defective synthesis of collagen
C. Vitamin C deficiency
D. Decrease tensile strength of wound
Ans: C

67- During tissue repair collagen is produced by
A- Macrophages
B- Lymphocytes
C- Eosinophils
D- Mast cells
E- Fibroblasts
Ans: E

68- What is the most important factor for exudate formation?
A- Chemo taxis
B- Increased permeability of blood vessels
C- Increased oncotic pressure
D- Decrease hydrostatic pressure
Ans: B

69- Type of necrosis in dissecting aortic aneurysm:
A- Coagulative
B- Fibrinoid
C- Liquefactive
D- Medial
Ans: D

70- A diabetic patient with a draining sinus/pus. What will histology show?
A- Fibrosis
B- Granuloma with abscess
C- Serosis
D- Increase Vascularity
Ans: B

71- Cytokine showing at the start of inflammation for neutrophils?
A- IL3
B- IL4
C- IL6
D- IL8
E- IL10
Ans D

Explanation
- **IL_1,IL_6,TNF_alpha** --fever and sepsis
- **Fever**--IL1>IL6
- **Pseudomonas Fever** -- TNF
- **IL1** --Osteoclast activating factor
- **IL2** --Stimulates T cells
- **IL3** --Stimulates Bone marrow
- **IL4** --Stimulate growth of B cells
- **IL4** --Stimulates IgE production
- **IL5** --Stimulates IgA production
- **IL6** --Stimulates acute phase reactant formation
- **IL8** --Major chemotactic for neutrophil
- **IL10&TGF Beta** --Anti inflammatory cytokines
- **TNF Alpha** --Cachexia in malignancy
- **IFN_Gamma** --Induce granuloma formation
- **IL12** -- Facilitates granuloma formation
- **TNF_Alpha** -- Maintain granuloma

72- A bee sting presented on OPD with facial swelling and developing difficulty in breathing . Doctor give IM adrenaline in order to prevent
A- Local Urticaria
B- Hypotension
C- Systemic anaphylaxis
D- Systemic infection
Ans: C

73- An autopsy of dead cardiac tissue on 5th day will show which type of cells marginalization:
A. Neutrophils
B. Eosinophil
C. Macrophages
D. Basophils
Ans: C

74- After two days of an infection which cells will be present in the sputum?
A- Neutrophils
B- Eosinophil
C- Macrophages
D- Basophils
Ans: A

Explanation:
- Within initial 24-72 hours it will be migration of neutrophils then macrophages.

75- A surgeon removed a 10 year old breast implant , which had leaking what cells be seen in this type of
A. Giant cells, lymphocytes , plasma cells
B. Plasma cells
C. Lymphocytes
D. Giant cells
Ans: A

76- Most common local factor for delayed wound healing:
A- Foreign body
B- Trauma
C- Decrease blood supply
D- Infection
Ans: D

Explanation:
- Most common local factor for delayed wound healing is infection
- Most common systemic factor for delayed wound healing is Diabetes Mellitus

77- Phagocytosis in blood is done by:
A- Neutrophils
B- Lymphocytes
C- Basophils
D- Macrophages
Ans: A

78- A patient is diagnosed with Acute appendicitis fever is caused by
A- Cytokines
B- Prostaglandins
C- Lymphokines
D- IL8
Ans: A

79- Following is true about exudate:
A- Few inflammatory cells
B- Specific gravity of 1.012
C- Protein > 3.5 gram
D- Protein less than 2g/ dl
Ans: C

80- Lady working in a kitchen wound not healing wound is clean but gaping patient is febrile glucose is 130 mg/dl and Hb is 5 cause is:
A- Diabetes
B- Infection
C- Anemia
D- Foreign body
Ans: C

81- Which of the following systemic factor is responsible for poor wound healing?
A- Decrease Blood supply
B- Decreased Vitamin C
C- Diabetes
D- HTN
Ans: C

82- Macrophages are derived from?
A- Monocytes
B- Neutrophils
C- Eosinophils
D- Lymphocyte
Ans: A(Wheatear's Histology)

83- Which of the following Anti inflammatory as it prevents burn patient from contracture
A- Glucagon
B- IV antibiotic
C- Glucocorticoid
D- Erythropoietin
Ans: C

84- A 35 year old female presented with secondary infertility. Fallopian tubes were blocked. Endometrium showed a collection of epitheloid cells, histiocytes and giant cells:
A. Chlamydia infection,
B. Gonococcal infection
C. Herpes simplex infection
D. Trichomonas vaginalis infection
E. Tuberculous infection
Ans: E

85- In chronic granulomatous , defect in which of the following
A- FAD
B- ATP
C- NADPH
D- GAP
Ans: C

CamScanner

86- Free redicals are removed by:
A. Superoxide
B. Vitamin D
C. Transferrin
D. Lymphocytes
E. Vitamin K
Ans: C

87- In sarcoidosis Granuloma which of the following cells will increase
A- Plasma cells
B- B lymphocytes
C- T lymphocytes
D- Neutrophills
Ans: C

88- Platelets release:
A- TxA2 + ADP
B- PG
C- Kinin
D- Steroids
Ans: A

89- Organ that regenerates on its own:
A- Liver
B- Skeletal muscle
C- Cardiac muscle
D- Neuron
Ans: A

90- A child having recurrent bacterial infections and increased neutrophils in blood while absence of neutrophils at the infection sites. Neutrophils can't attach to endothelium to deficiency of:
A- LFA-1 (integrin)
B- Icam 1
C- Vcam
D- LTB4
Ans: A

91- Ghon complexes are characteristic of
A- Primary TB
B- Secondary TB
C- Syphillis
D- Sarcoidosis
E- Pneumothorax
Ans: A

92- Primary scavenger cells are:
A- Neutrophils
B- Macrophages
C- Plasma cells
D- Lymphocytes
E- Langerhans's cells
Ans: B

93- One of the most important chemical mediators of allergy is:
A- Histamine
B- Prostaglandin
C- Serotonin
D- Neutrophils
E- None
Ans: A (Golijan & Robbins)

94- In pyogenic abscess enzymes are released by
A- Neutrophills
B- Esinophills
C- Monocytes
D- Lymphocytes
E- Macrophages
Ans: A

95- Regarding Blood cell
A- Neutrophils don't take part in phagocytosis
B- Macrophages are major scavenger molecule in site
C- Eosinophils don't intervene unless immunological process
D- Neutrophils come late
E- Eosinophils have a half-life of 30 days
Ans: B

96- An embolus lodged in branch of renal artery. A dar later there is area of In which the renal parenchymal cells in the distribution of occuluded artery show Karylysis and Karyorrhexis. The outlines of the cells are visible , but the nuclei also have Basophillic staining and the cytoplasm is esinophillic but pale .Which of the following types of cellular necrosis is likely present
A- Fibrinoid necrosis
B- Coagulative necrosis
C- Liquifactive necrosis
D- Fat necrosis
A- Caseous necrosis
Ans: B

97- Gummatus necrosis occurs In
A. Chlymydia
B. Gonorrhea
C. Listeria
D. Syphillis
E. TB
Ans: D

98- Transformation of macrophages to epitheloid cells in chronic granulomatous is mainly brought about by which one of the following
A- IL-2
B- 1L-8
C- IL-12
D- Interferon gamma
E- IL-13
Ans: D

99- Transmigration of neutrophils along the strong endothelium:
A- Rolling
B- Diapedesis
C- Chemotaxis
D- Margination
Ans: B

100- Least likely factor affecting the healing of wound is
A- DM
B- Persistent infection
C- Retained product
D- Metabolic Disorder
Ans: D

101- Eosinophilia in Apoptotic cell is due to which of following?
A- Loss of Mitochondrial DNA
B- Loss of Mitochondria
C- Loss of Cytoplasmic RNA
D- Loss of Lysosomes
Ans: C

102- A microbiologist was examining aslide under microscope it show cell shrinkage, condensed nuclei in cells. Irregular cell membrane ofcells what is happening to tissue?
A- Apoptosis
B- Necrosis
C- Reversible cell injury
D- Irreversible cell injury
E- Hypoxia
Ans: A

103- Foam cell in atheroma form by
A- Neutrophil
B- Lymphocyte
C- B cell
D- T cell
E- Monocyte
Ans: E

104- Concomitant hyperplasia and hypertrophy can be seen in:
A- Breast development in puberty
B- Uterine changes in pregnancy
C- Endometrial Hyperplasia
D- Exercising Muscles
Ans: B
Explanation:
- Hyperplasia of uterine blood vessels andhypertrophy of uterine smooth muscles.

105- A cell was on microscopic examination large mitochondrial densities are found indicating:
A- Reversible cell injury
B- Irreversible cell injury
C- Apoptosis
D- Necrosis
E- 234ainab
Ans: B (Robins)

106- Cell producing Granulomatous and fibrous tissue is
A- Collagen
B- Elastin
C- Glial cells
D- Fibroblast
Ans: D

107- A patient suffers from appendicitis. Peripheral blood shows leukocytosis. He is having fever and Pain. Pain will be mediated by
A- IL 1 and TNF alpha
B- Serotonin
C- IL 6
D- Ekephalin
E- Prostaglandins
Ans: E (No Bradykinin option)

108- Person had traumatic incident of upper limb for 3 months he feels pain and tenderness a swelling developed at the region on x-ray swelling is bright after one year it resolved phenomenon is:
A- Hypertrophy
B- Hyperpladia
C- Metaplasia
D- Dystrophic Calcification
E- Metastatic Calcification
Ans: C (Myositis ossificans)

109- Plasma cells are produced from:
A- T lymphocytes
B- Eosinophil
C- B lymphocytes
D- Megakaryocytes
E- Bone marrow stem cells
Ans: C

110- Regarding lymphocytes true is:
A- Become monocytes when exposed to antigens
B- Are made in bone marrow before birth
C- Are cancer fighting cells
D- Made in bone marrow
Ans: C

CamScanner

111- Factor 8 is produced by:
A. Platelets
B. Endothelial cells
C. Parietal cells
D. Hepatocytes
E. Kupffer cells
Ans: B

112- Prostacyclin derived from:
A- Endothelial cells
B- Platelets
C- Neutrophil
D- Lymphocytes
Ans: A

113- Regarding Monocytes likely:
A- Can transfer into large multinucleated giant cells in chronic infection
B- Increase in allergy
C- Produce IgM
D- Formed from precursor cells in lymph nodes
E- Do not migrate across capillary wall Unlike granulocytes
Ans: A

114- A Child presented with fever chills, yellowish exudate, palpable lymphoid mass diagnosed as acute tonsillitis Mediators causing Fever is which of following?
A- IL1
B- C5a, LTB4
C- C3b
D- LTC4 D4 E4
E- IL 5
Ans: A

115- What connects WBC to endothelium?
A- L selectin
B- E selectin
C- ICAM
D- Integrin
E- CD 16
Ans: C

116- Clot retraction occurs due to which of following?
A- Basophils
B- Platelets
C- Eosinophils
D- Mast cells
E- Monocyte
Ans: B
Explanation:
- Platelets release thrombosthenin which causes retraction of platelets.

117- An Alcoholic patient Presented with hemorrhage near hair follicles, petechiae Bruises Skin and Mucosal lesion which are poorly healing with decrease collagen Defective cells are which of following?
A- Hepatocytes
B- Lymphocytes
C- Fibroblasts
D- Macrophages
E- Melanocytes
Ans: C

118- Premature rupture of aminotic cavity with still birth which thing did it?
A- Prostaglandin
B- Lymphokine
C- Compliment activation
D- Immuniglobulins
Ans: C

119- Main surface barrier to pathogen is:
A- Basophils
B- Macrophages
C- Mast Cell
D- Skin
E- Eosinophils
Ans: D

120- Mononuclear phagocytic Cells derived from which of the following?
A- Spleen
B- Liver
C- Bone marrow
D- Pancreas
Ans: C

121- Pleural biopsy having Amorphous coagulum is likely
A- Serous
B- Prulent
C- Fibrinous
D- Whity
Ans: C

122- Clear wound after surgical incision recognized by
A- Scar
B- Keloid
C- Hypertrophy
D- Contracture
Ans: A

123- A young girl with blisters on extremities type of fluid present between dermis and epidermis
A- Transudative
B- Serous
C- Exudative
D- Fibrinous
Ans: B

124- Patient complained of chest pain specific gravity less than 1.025 protein content less than 3g pericardiocentesis done fluid is called
Transudative
A- Exudative
B- Serous
C- Fibrous
D- Mixed
E-
Ans: A

125- In endothelial injury which of following factor is responsible for repair
A- Vitamin C
B- Platelets
C- Leukocytes
D- Steroids
E- Vitamin A
Ans: B

126- A 35 years black athlete presented with 3rd degree burn. He is most likely to develop
A- Keloid
B- Contracture
C- Rash
D- Atrophy
Ans: A
Explanation:
- Most Common Complication of 3rd Degree Burn over all – Contracture
- Most Common Complication of 3rd Degree Burn in Black – Keloid
- Most common Complication of Burn – Scar

127- Prostaglandin Features is
A- Protect Gastric Ulcer
B- Cause Gastric cancer
C- Involved in Gastric Ulcer
D- Prevent Dudenal perforation
Ans: A

128- Platelet aggregation is caused by
A- Thromboxane A2
B- Prostacyclin
C- Prostaglndin
D- Cox1
E- Cox2
Ans: A
Explanation:
- Platelets aggregation causes by - Thromboxane A2
- Platelets aggregation inhibited by - Prostacyclin

129- Main difference between primary and secondary intention wound healing is:
A- Granulation tissue
B- Wound contraction
C- Inflammatory cells
D- Keloid
Ans: B

130- Which cells are responsible for formation of pyogenic abscess
A- Macrophages
B- Lymphocytes
C- Monocytes
D- Eosinophils
E- Neutrophils
Ans: E

131- Which of the following is a pain mediator after knife injury?
A- Mast cell
B- Histamine
C- Prostaglandin
D- Prostacyclin
E- Macrophages
Ans: C (No Bradykinin option)

132- Neutrophils move out of the vessel via which adhesion molecules
A- ICAM 1
B- PECAM 1
C- NCAM
D- Selectin
Ans: B

133- Which of the following is secreted by fibroblasts?
A- Collagen
B- Hyaline
C- Amorphus Ground substance
D- Elastic
E- Lamella
Ans: C
Explanation:
- Fibroblast Secrete – Amorphous Ground Substance
- Fibrocartilage has – Rich Collagen

134- A woman develops carbuncle on the back of her neck which is removed by the surgeon. What type of necrosis and inflammation is present?
A- Fibrous
B- Serous
C- Acute
D- Fat
E- Fibrinoid
Ans: C (No option of Liquefactive)

CamScanner

135- Pleural fluid with inflammatory cells, eosinophils, mesh of threads of amorphous coagulum, type of inflammation is:
A- Fibrinous inflammation
B- Serous inflammation
C- Chronic
D- Acute
Ans: A

136- Prostacyclin is produced by:
A- Platelets
B- Endothelial cells
C- Parietal cells
D- Hepatocytes
E- Kupffer cells
Ans: B

137- A patient with wheezing nasal congestion runny nose and fever biopsy of nasal mucosa show degranulation of?
A- Mast cells
B- Basophils
C- Lymphocyte
D- Monocyte
E- Neutrophil
Ans: A

138- A patient has malaise and fatigue has decrease WBC , Platelets , Basophils , Neutrophils.All cell line decrease but Which one of following will not decrease:
A- HB
B- Eosinophils
C- T lymphocytes
D- Monocytes
Ans: C

139- Which one of the following laydown collagen in bone formation
A- Elastin
B- Hepatocytes
C- Fibroblast
D- Melanocytes
E- Macrophages
Ans: C

140- Edema fluid due to inflammation:
A- Exudate
B- Transudate
C- Serous
D- Fibrinous
Ans: A

141- Which type of inflammation is present in appendicitis with pus cells in it?
A- Purulent
B- Suppurative
C- Serous
D- Chronic
Ans: B

142- A Child presented with fever chills, yellowish exudate, palpable lymphoid mass diagnosed as acute tonsillitis Mediators causing systemic manifestation is which of following?
A- IL 1, TNF
B- C5a, LTB4
C- C3b
D- LTC4, D4, E4
E- IL 5
Ans: A

143- Acute phase protein is
A- Ceruloplasmin
B- Ferritin
C- Globulin
D- C Reactive protein
Ans: D

Explanation:
Acute phase reactants
Positive
- C reactive protein- Marker of MI
- Fibrinogen -Endothelial repair
- Serum amyloid A protein
- Hepcidin - Decrease Iron absorption and Decrease release of Iron
- Ferritin - Bind and Squester iron

Negative
- Albumin
- Transferin

144- Which factor is important for delayed wound healing?
A- Hypertension
B- Diabetes
C- Anemia
D- Tumor
E- Protein deficiency
Ans: B

145- Surgeon is suturing wound what will happen first:
A- Acute inflammation
B- Granulation tissue formation
C- Coagulation cascade activate
D- Debris formation
Ans: C

146- A female having worm infestation having spectacle shaped nucleus which cells will be raised inflammation
A- Eosinophil
B- Basophil
C- Lymphocyte
D- Monocytes
E- Neutrophils
Ans: A

147- Basophils and mast cells leads to inflammation
A- Vasoconstriction of arteries
B- Vasodilation of arteries
C- Decrease vascular permeability
D- Infection
Ans: B

148- Vasculogenesis in abdominal mass is done by which of these inflammation:
A- Metalloproteinase
B- VEGF
C- Collagenase
D- TGF
E- Elastase
Ans: B

149- In an experiment, a scientist treats a group of mice with an antiserum that substantially depletes the number of circulating neutrophils. Compared with untreated control animals, the mice with reduced numbers of neutrophils were found to be significantly more susceptible to death induced by bacterial inoculation. The increased mortality can be ascribed to a relative deficit in which of the following?
A- Acquired immunity
B- Oxidants
C- Platelets
D- Granulocyte/macrophage colony stimulating factor (GM-CSF)
E- Integrin
Ans: B

Explanation:
Neutrophils are a critical source of oxidants, innate immune mediators that are involved in bacterial killing

150- Collagen that give max tensile strength:
A- Type 2
B- Type 3
C- Type 1
D- Type 4
Ans: C

151- Girl has watery eyes, runny nose, which one is responsible:
A- Plasma cells
B- Histamine
C- Basophils
D- Monocytes
Ans: B

152- Role of endothelium in haemostasis?
A- Plasminogen activating inhibitor
B- Prostacyclin
C- Fibrinogen
D- Mechanical barrier
Ans: B

153- CRP, transferrin and Haptoglobin are examples of:
A- Chronic phase reactants
B- Negative phase reactants
C- Acute phase reactants
D- Biological markers
Ans: C

154- After inguinal hernia surgery what will occur in wound of clean suture:
A- Keloid
B- Scar formation
C- Hypertrophy
D- Skin rupture
Ans: B

155- A bacterial disease having yellow sputum which cells will be increased?
A- Lymphocytes
B- Plasma cells
C- Neutrophil
D- Mast cells
Ans: C

156- Old age diabetic patient having multiple abscesses. Supportive inflammatory cells reach inflammation area by:
A- Post capillary venules
B- Capillaries
C- Veins
D- Arteries
Ans: A

157- A patient has fever and abscess formation. Which of the following is a pain mediator in abscess region.
A- Mast cell
B- Histamine
C- Prostaglandin
D- Prostacyclin
E- Macrophages
Ans: C (No Bradykinin option)

CamScanner

- Pain – Bradykinin > Prostaglandins E2
- IL-1 and TNF – Fever mediator
- Prostaglandins F2, E2 and D2 – Vasodilation
- Late mediator of Inflammation – PG & Leukotriens
- Initial mediator of inflammation – Histamine

158- Most important factor leading to decreased wound healing is:
A- Hypothyroidism
B- Hypertension
C- Diabetes
D- Tissue hypoxia
E- Chemical injury
Ans: D

159- Type of fluid due to appendicitis is:
A- Exudate
B- Transudate
C- Serous
D- Fibrinous
Ans: A

160- After diapedesis cytokines involved in neutrophil migration is:
A- C5a
B- C5b
C- C3b + IgG
D- FC portion of C3B
Ans: A

161- Which one is involved in acute Inflammation?
A- T lymphocytes
B- Eosinophils
C- Plasma cells
D- Neutrophils
E- Macrophages
Ans: D

162- Person having knife injury to finger first mediator released will be
A- Prostaglandin
B- Leukotrien
C- Histamine
D- Basophil
E- NK cells
Ans: C

Explanation:
- Pain – Bradykinin > Prostaglandins E2
- IL-1 and TNF – Fever mediator
- Prostaglandins F2, E2 and D2 – Vasodilation
- Late mediator of – PG &Leukotriens
- Initial mediator of – Histamine

163- Healing of a Clean wound sutured by doctor characterized as
A- Regeneration
B- Contraction
C- Scar
Da- Organization
E- Hypertrophy
Ans: C

164- Transmigration of inflammatory cells by the help of
A- ICAM 1
B- PECAM 1
C- NCAM
D- Selectin
E- VCAM
Ans: B

165- WBCS travel between endothelial cells & exit via blood vessel through a process termed as:
A- Margination
B- Opsonization
C- Diapedesis
D- Rolling
Ans: C

166- Which of the following is true about plasma proteins?
A- Exert an oncotic pressure of 25mmhg
B- Globulins make a bulk of them
C- Made exclusively in liver
D- Buffer capacity upto 30%
Ans: A

167- Inflammatory Cells transport to the site of Inflammation from blood by?
A- Pre capillary venules
B- Post capillary venules to deep cortex
C- Cortex of lymph nodes
D- Arteries
Ans: B

168- In lymph nodes, where the Diffusion of lymphocytes from vessels to the lymph node really occur ?
A- Pre capillary arterioles
B- Post capillary Venules
C- At capillary level
D- Subcapsular afferent Lymphatics
Ans: B

169- What does bacteria secrete which help in proliferation of new capillaries in wound
A- Fibronectin
B- Phospholipase
C- PDGF
D- Mettalase
E- FGF
Ans: C>E

170- A patient has been taking glucocorticoids which cell line will decrease in this case
A- Neutrophils
B- Basophils
C- Monocytes
D- Macrophages
E- Lymphocytes
Ans: E

Explanation:
Steroid cause
- Lymphopenia
- Eoasinopenia
- Neutrophilia

171- Platelet aggregation is decreased by factor produced from endothelium is
A- Thromboxane 2
B- Prostaglandins
C- Prostacyclins
D- ADP
E- Calcium Ion
Ans: C

172- Which of the following Interleukin will cause Increase of Red Blood Cells from T lymphocytes ?
A- IL 2
B- IL 3
C- IL 6
D- IL 8
E- IL 4
Ans: B Better statement

173- A young female had RTA which resulted in femur fracture for which she had prosthesis placed. She developed SOB and petechiae the same day. Most probable cause:
A- Fat embolism
B- Pulmonary Embolism
C- Air embolism
D- Amniotic fluid embolism
E- Sepsis
Ans: A

Explanation:
- Air Embolism – History of Passing CVP then SOB
- Pregnant lady + Long bone fracture +Died on way to hospital within 24h or during labour – Amniotic fluid embolism
- Sudden death + Sudden SOB – Pulmonary Embolism
- Long bone fracture – Death after 3-5 days – Fat embolism

174- Which of the following is true about plasma proteins?
A- Exert an oncotic pressure of 25mmhg
B- Globulins make a bulk of them
C- Made exclusively in liver
D- Buffer capacity upto 30%
Ans: A

175- A boy has gotten a cut on his finger.Which of the following is the initial mediator for pain?
A- TNF
B- Prostacyclin
C- IL-6
D- Prostaglandin
E- IL-1
Ans: D(Bradykinin Was not given in the options)

Explanation:
- Pain – Bradykinin > Prostaglandins E2
- Fever mediator- IL-1 and TNF –
- Vasodilation- Prostaglandins F2, E2 and D2

176- A boy has gotten a cut on his finger. Which of the following is the initial mediator for pain?
A- TNF
B- Prostacyclin
C- IL-6
D- Prostaglandin
E- IL-1
Ans: D(Bradykinin Was not given in the options)

Explanation:
- Pain – Bradykinin > Prostaglandins E2
- Fever mediator- IL-1 and TNF –
- Vasodilation- Prostaglandins F2, E2 and D2

CamScanner

177- WBCS travel between endothelial cells & exit via blood vessel through a process termed as
A- Margination
B- Opsonization
C- Diapedesis
D- Rolling
Ans: C

178- Platelet aggregation is inhibited by?
A- Thromboxane 2
B- Prostaglandins
C- Prostacyclins
D- ADP
E- Calcium Ion
Ans: C

179- On Lung streptococcal pneumoniae infection clearance of infection by
A- Oxidase
B- H2O2
C- Prostaglandin
D- Leukotriens
Ans: B

180- A patient with recurrent tb infection having hilar lymphadenopathy with improper granuloma formation which one will Be raised
A- Compliment
B- 1L 17
C- Lymphokines
D- IL 12 +IF Gamma
E- Antibodies and plasma cells
Ans: D

181- Patient with multiple jaw draining abscesses. And develope granuloma What will be seen in microscopy?
A- Epithelioid cells
B- Granuloma with abscess
C- Abscess only
D- Giant cells
E- Macrophages
Ans: B better

182- Most common complication of burn:
A- Contracture
B- Keloid
C- Scar
D- Rash
E- Atrophy
Ans: C

Explanation:
- Most Common Complication of 3rd Degree Burn over all – Contracture
- Most Common Complication of 3rd Degree Burn in Black – Keloid
- Most common Complication of Burn – Scar

183- Most common Pain mediator in inflammation:
A- Bradykinin
B- Prostaglandin
C- IL2
D- Histamine
E- Serotonin
Ans: A

184- Main Mediator of inflammation in Sarcoidosis:
A- Histamine
B- Interferon gamma
C- Prostagladin E2
D- Bradykinin
Ans: B

185- After Ischemic reperfusion injury, Free radicals are released by which of these:
A- Neutrophils
B- Lymphocytes
C- Monocytes
D- Macrophages
E- Plasma cells
Ans: A

186- Healing of a Clean wound sutured by doctor characterized as
A- Regeneration
B- Contraction
C- Scar
D- Organization
E- Hypertrophy
Ans: C

187- Which of the following is a pain mediator?
A- Prostaglandin
B- Histamine
C- C3b
D- C3a
Ans: A

Explanation:
- Pain – Bradykinin > Prostaglandins E2
- IL-1 and TNF – Fever mediator
- Prostaglandins F2, E2 and D2 :Vasodilation

188- Surgeon suturing a wound, the first step in healing of this wound is
A- Activation of coagulation
B- Formation of granular tissue
C- Activation of inflammation
D- Infection
Ans:

189- Inflammatory Cells transport to the site of Inflammation from blood by?
A- Pre capillary venules
B- Post capillary venules to deep cortex
C- Cortex of lymph nodes
D- Arteries
Ans: B

190- which one of following occur in inflammation
A- Transudate
B- Exudate
C- Infection
D- None
Ans: B

191- A boy hit by something develops hand swelling and Fever cause of fever is:
A- Prostaglandin
B- IL8
C- IL1
D- Leukotriens
Ans: C

192- A patient with a normal protein diet but decreased intake of fruits and vegetables experiences slow repair after acute inflammation. Which of the following is the most likely reason for the delayed repair?
A- Decreased synthesis of granulation tissue
B- Decreased synthesis of type III collagen
C- Decreased tensile strength of the tissue
D- Decreased fibroblast proliferation
E- Decreased formation of new blood vessels
Ans: B

193- Which of the following is least likely to contribute to decreased repair after acute inflammation?
A- Increased age
B- Diabetes Mellitus (DM)
C- Protein deficiencies
D- Vitamin C deficiency
Ans: A

194- Healing of a Clean wound sutured by doctor characterized as
A- Regeneration
B- Contraction
C- Scar
D- Organization
E- Hypertrophy
Ans: C

195- First Step in incised wound healing(Medicine Feb 2025)
A- Formation of Granulation tissue
B- Acute Inflammation
C- Maturation of Scar
D- Keloid Formation
Ans: B

196- Aqueous humour drains via episcleral veins into canal of schelmm. Which type of Collagen will be Present in it?(Medicine Feb 2025)
A- Type 2 collagen
B- Type 1 Collagen
C- Type 4 Collagen
D- Type 3 Collagen
Ans: B

197- Fibers are not visible in Hyaline cartilage leading to its clear appearance. It is due to: (Surgery Feb 2025)
A- Glycosaminoglycans
B- Hyaluronic acid
C- Proteogylcans
D- Chondrocytes
Ans: A

198- Prolonged use of an intrauterine contraceptive device (IUCD) is most likely to lead to a chronic inflammatory reaction, with the following histological findings: plasma cells, lymphocytes, and macrophages. Which of the following is seen in this scenario?(Surgery Feb 2025)
A- Granulomatous inflammation
B- Fibrous inflammation
C- Caseous necrosis
D- Serous inflammation
Ans: A

199- A child with disorder in which leukocyte adhesion to endothelium is impaired. WBC attach to Endothelium by(Surgery Feb 2025)
A- Selectin
B- Integrins
C- ICAM
D- VCAM
Ans: C(Harsh Mohan)
Explanation:
- Intercellular adhesion molecule-1 (ICAM-1) and Vascular cell adhesion molecule-1 (VCAM-1) allow a tighter adhesion and stabilise the interaction between leucocytes and endothelial cells.

CamScanner

- Platelet-endothelial cell adhesion molecule-1 (PECAM-1) or CD31 may also be involved in leucocyte migration from the endothelial surface

200- A surgical incision is made in a sterile environment, and the wound is closed immediately. This type of wound healing is an example of: (Surgery Feb 2025)

A- Delayed primary closure
B- Primary intention
C- Secondary intention
D- Tertiary intention
Ans: B

201- Cells responsible for granuloma formation(Surgery Feb 2025)?

A- Lymphocytes
B- Epitheloid cells
C- Multinucleated giant cells
D- Neutrophils
Ans: C

202- During inflammation T cells bind with(Gynae Feb 2025)

A- MHC
B- HLA
C- BRCA
D- None of the above
Ans: A

203- Tensile strength in an uncomplicated abdominal wound with no systemic disease increases in 2 months due to: (Gynae Feb 2025)

A- Rapid increase of 50–70% with a change in the type of collagen
B- Slow increase of 50–70% with a change in the type of collagen
C- Increase of 50–70% due to the proliferation of collagen
D- 50-70% Fibroblast
Ans: B

204- After appendectomy wound healing by(Gynae Feb 2025)

A- Primary intention
B- Secondary intention
C- Tertiary Intention
D- Delayed healing
Ans: A

205- A person steps on a rusted nail. What is the initial process in wound healing?(Radiology Feb 2025)

A- Acute inflammatory cell infiltration
B- Proliferation of myofibroblasts
C- Collagen deposition
D- Granulation tissue formation
Ans: A

206- After women underwent laparotomy, what will u tell her that after how much time will her scar gain maximum strength? (Radiology Feb 2025)

A- 1 year
B- 6 months
C- 3 months
D- Never
Ans: C

207- Patient presented with history of Cough & Wheezing on examination. Th2 cells are involved in activation and survival of eosinophils. Which cytokines help in this?(Anesthesia Feb 2025)

A- IL-6
B- IL-5
C- TNF
D- IFN-γ
Ans: B

208- In a patient with liver fibrosis, which type of connective tissue is predominantly present? (Anesthesia Feb 2025)

A- Collagen type IV
B- Collagen type I
C- Elastic fibers
D- Collagen type III
Ans: B

209- Which type of connective tissue provides support to liver lobules and surrounds the hepatic sinusoids? (Anesthesia Feb 2025)

A- Elastic connective tissue
B- Reticular connective tissue
C- Loose connective tissue
D- Dense irregular connective tissue
Ans: B

HEMODYNAMICS QUICK HINTS

Thrombosis

Virchow triad

1. Endothelial injury
2. Blood Stasis
3. Hypercoagulability

✓ In women Post surgery DVT occur due to - Blood stasis +Hypercoagulability > Endothelial injury + Hypercoagulability

Types of thrombi

Arterial (White)

✓ Develop in arteries or heart
✓ On Transection Dark gray lines of Aggregated platelets interpersed between paler layer of Coagulated Fibrin these lamellae called **Lines of Zahn**
✓ Form Snake like structure away from heart

Venous (Red)

✓ Rich in RBC so are red
✓ On Transection Fibrin seen
✓ Form snake like structure towards Heart

Venous Thrombi vs Postmortem Clot

✓ Venous thrombi are firm and Postmortem clot rubbery
✓ Venous thrombi rich in RBC and Post mortem clot dependent port rich in RBC appear as Red Currant Jelly and Supernant Portion free of RBC appear as Chicken Fat
✓ Venous thrombi attach to vessel and Postmortem clot not

Line of Zahn seen in

✓ Coraline Thrombus
✓ Pre mortem Thrombus
✓ Arterial Thrombus

Chicken Fat Appearance seen in

✓ Post Mortem Thrombus

Embolism

✓ Occlusion of some part of cardiovascular system by some mass impaction(Embolus)

Types

Air Embolism

✓ History of Passing CVP then SOB
✓ In Ascending divers (caisson disease/decompression sickness)
✓ **Bend** - Pain in joint limb and abdomen due to gas bubble
✓ **Chock** - Sudden respiratory distress due to gas emboli

Amniotic Fluid Embolism

✓ Pregnant lady + Long bone fracture Died on way to hospital within 24h or during labour
✓ Lead to DIC
✓ Most Fatal type of Pulmonary Embolism that cause extensive Pulmonary necrosis Shock and Death

Fat Embolism

✓ Symptoms start to appear after 12 h
✓ Long bone fracture
✓ Death after 3-5 days
✓ Present with Hypoxemia and Cerebral Petechiae is due to Low platelets

Edema

✓ Peripheral edema in CLD due to – loss of albumin (Low oncotic pressure)
✓ Ascities in CLD due to – Portal HTN
✓ Renal origin edema due to – Loss of albumin (low oncotic pressure) + can be salt and waterretention.
✓ Nephrotic syndrome edema due to -Hypoalbuminemia
✓ Nephritic syndrome edema due to - Salt and water retention.

CamScanner

- ✓ Pedal edema in CHF and HTN due to – Increase hydrostatic pressure.
- ✓ In CHF edema woarsen by – Sodium and water retention.

Infraction

- ✓ Area of ischemic necrosis within tissue or organ by occlusion of either arterial or venous drainage

Haemorehagic (Red Infarct)

Due to venuous occlusion seen in

- ✓ Liver
- ✓ Lung
- ✓ Intestine
- ✓ Testis

Pale infarct (White)

Due to Arterial occlusion seen in

- ✓ Heart
- ✓ Kidney

Shock

- ✓ Inadequate organ perfusion and delivery of nutrients necessary for normal tissue and cellular function

Types

Hypovolemic Shock

- ✓ **Causes-** Hemorrhage , Dehydration and burn
- ✓ Increase TPR + Decrease Cardiac output + Decrease CVP +Increase Lactate +Cold Skin

Cardiogenic Shock

- ✓ **Causes** –MI , Heart failure and Arrhythmia
- ✓ Increase TPR + Decrease Cardiac output +Cold Skin

Distributive Shock

1. **Septic Shock** - Due to Sepsis + Decrease TPR +Increase Cardiac output +Increase Lactate +Warm Skin
2. **Anaphylactic Shock** - Decrease TPR +Increase Cardiac output +Warm Skin
3. **Neurogenic Shock** – Loss of vascular tone +Decrease TPR and Cardiac output
4. **Cardiac Shock** –Raised JVP

Random

- ✓ Factor V mutation(Laden) leads to -- **Thrombosis**
- ✓ Factor V deficiency leads -- **Bleeding**
- ✓ Factor 12 deficiency leads -- **Thrombosis**.
- ✓ Most common acquired thrombotic disorder is -- **Anti-phospholipid syndrome**
- ✓ Most common Inherited coagulopathy -- **VWBD**
- ✓ Most common inherited Thrombotic disorder is -- **Factor V Mutation (Laden)**

HEMODYNAMICS

1. An elderly obese man with severe atherosclerosis developed acute abdominal pain, on laparoscopy small intestine was dark purple in colour, superior mesenteric artery was atherosclerotic and thrombosed, mesenteric vein patent, this small intestine pathology will be called?

A- Dry gangrene
B- Red infarction
C- Volvulus formation
D- Wet gangrene
E- GIT bleeding

Ans: D(FA)

Explanation:

- For Red infarct Vein occlusion is must

2. Most characteristic site of hemorrhagic infarct:

A- Pancreas
B- Kidney
C- Spleen
D- Heart
E- Small intestine

Ans: E

3. White infarct occurs in which of the following site?

A. Heart
B. Lungs
C. Intestine
D. Testicular torsion
E. Atrial occlusion after angioplasty

Ans: A (Heart, Kidney, Spleen)

4. A lady has heart infarction what type of infarct seen in heart?

A- Pale
B- Red
C- Blue
D- Green

Ans: A (FA)

Explanation:

Haemorehagic (Red Infarct)

Due to venuous occlusion seen in

- Liver
- Lung
- Intestine
- Testis

Pale infarct (White)

Due to Arterial occlusion seen in

- Heart
- Kidney

5. Which of the following causes thrombus formation?

A- Decrease Blood flow
B- Decrease Viscosity
C- Endothelial injury Vasoconstriction
D- Increase blood flow

Ans: C(Robins)

Explanation:

- The Virchow's triad of thrombosis consist of stasis of blood flow, hypercoagulability & Endothelial Injury.

6. Lady after surgery present in ward with swollen legs bilaterally DVT suspected pathology is:

A- Endothelial injury
B- Endothelial injury plus blood stasis
C- Blood stasis
D- Hyper coagulopathy plus blood stasis
E- Coagulopathy

Ans: D >B

7. Upon autopsy, a patient was having a thrombus and line of zahn this is seen in:

A- Chicken fat supernatant
B- Pre mortem thrombus
C- Post mortem thrombus
D- Chicken lipid thrombus

Ans: B

Explanation:

Line of Zahn seen in

- Coraline Thrombus
- Pre mortem Thrombus
- Arterial Thrombus

Chicken Fat Appearance seen in

PostMortem Thrombus

8. Air embolism develops on how much air volume?

A- 50cc
B- 100cc
C- 10cc
D- 80cc
E- 20cc

Ans: B

9. A 38 years old man got pelvic fracture in RTA he loses 2L of blood in accident. After 5 days he died and his brain CT scan shows multiple areas of infarction what is cause of his death:

A- Air embolism
B- Fat embolism
C- Sepsis
D- Neurogenic shock
E- Violence

Ans: B

CamScanner

Explanation:
- Sudden death – Thromboembolism
- Death after 3-5days – Fat embolism
- Pregnant lady died during labour – Amniotic fluid embolism.

10. 1st step in formation of thrombus:
A- Stasis
B- Endothelial injury
C- Hyperviscosity
D- Hypoxia
Ans: B

11. Most imp factor in pathogenesis of thrombosis?
A- Endothelial injury
B- Prolong bed rest
C- OCP
D- Antithrombin 3 deficiency
Ans: A

12. Female patient of village has developed gum bleeding after delivery, PT14 sec, APTT 60sec, neutrophil 2400 BURR cells are seen in peripheral smear and FDP raised diagnosis is likely:
A- Amniotic fluid embolism
B- DIC
C- Hypotension
D- Shock
Ans: B

13. Which of the organ undergo hemorrhagic infarction?
A- Heart
B- Spleen
C- Liver
D- Kidney
Ans: C

14. A patient died of fat embolism, on autopsy fat embolism will be visualized by:
A- Frozen section of embolism
B- Silver stain embolism
C- Fat stain
D- Permanent stain
Ans: C

Explanation:
- Fat embolism can be identified at autopsy through microscopy by using fat stains and conducted on frozen tissues of fat emboli.

15. Which of the following will decrease chances of edema?
A- Venous constriction
B- Arteriolar constriction
C- Nephrotic syndrome
D- Inflammation
Ans: B

Explanation:
- Venous constriction will increase Capillary hydrostatic pressure thus likely increase chance of edema.

16. Most prone to ischemia:
A- Kidney
B- Liver
C- Neuron
D- Heart
E- Spleen
Ans: C

17. A pregnant lady from remote village died on the way to hospital, the probable cause is:
A- Amniotic Fluid Embolism
B- Fat Embolism
C- Pulmonary Embolism
D- Hemorrhage
Ans: A

18. Child with periorbital edema and generalized edema due to:
A- Hypoalbuminemia and increase salt water retention
B- Hyperalbuminemia
C- Increase Salt retention
D- Decrease Salt retention
Ans: A

19. Venous thrombosis results in:
A. Pulmonary Embolism
B. Thrombophlebitis
C. Peripheral gangrene
D. Neuropathy
Ans: A

20. Which of the following doesn't occur in edema?
A- Decrease Oncotic pressure
B- Increase Capillary Oncotic pressure
C- Increase Capillary Hydrostatic Pressure
D- Increase Permeability
Ans: B

Explanation:
- Edema occurs due to decrease capillary oncotic pressure, increase capillary hydrostatic pressure & increase capillary permeability so here increase capillary oncotic pressure doesn't occur in edema.

21. A patient with 3rd degree extensive burn, cause of edema is:
A- Acidosis
B- Alkalosis
C- Hypoalbuminemia
D- Hypokalemia
Ans: C

22. Cause of death in Extensive PE is:
A- Thromboembolism
B- Air
C- Fat
D- Gas
Ans: A

23. Child presented with edema is most likely due to:
A- Increase Albumin
B- Decrease Albumin
C- Increase Fibrinogen
D- Decrease Hydrostatic Pressure
Ans: B

Explanation:
- Edema could be caused by decrease oncotic pressure that's due to decrease albumin level or can occur due to increase hydrostatic pressure.

24. Patient diagnosed to have pale infarct. In which of the following conditions pale infarct occur:
A- Hypertensive stroke
B- Embolism
C- Atherosclerosis
D- Rupture of Berry Aneurysm
Ans: C

25. A patient presents with burns, which test should be done in him?
A- Keratin
B- Globulin
C- Albumin
D- Transferrin
E- Electrolytes
Ans: C

26. Regarding fat embolism due to
A- Fracture of long bones
B- 72 to 96 hours after trauma
C- Reversible with treatment
D- Long lasting
Ans: A

27. Which of the following embolism causes the most extensive necrosis and death?
A- Air embolism
B- Fat embolism
C- Thromboembolism
D- Amniotic fluid embolism
Ans: D

28. Which is the primary site of DVT?
A- Pulmonary artery
B- Pulmonary vein
C- Abdominal veins
D- Deep veins of calf
Ans: D

29. Regarding lymphatic function:
A- Have some valves
B- Superficial with vein
C- Deep with arteries
D- Drains the lymph from tissues
Ans: D

30. Most common complication of DVT:
A- Emboli
B- Thrombi
C- Clot
D- Death
Ans: A

31. Whole body Edema may be due to:
A- Hypernatremia
B- CCF
C- Excessive Renin secretion
D- Excessive Aldosterone secretion
Ans: B

32. Earliest step in formation of thrombus:
A- Formation of fibrin
B- Adherence of platelets
C- Trapping of erythrocytes
D- Activation of Hageman factor
Ans: B

33. Platelet formation by
A- ADP and thromboxane A2
B- Fibrinogen and thromboxane 2
C- Plasminogen
D- Plasmin and thromboxane 2
Ans: A

34. All of the following cause edema except?
A- Obstruction of lymphatic flow
B- Decrease oncotic pressure
C- Increase hydrostatic pressure in capillaries
D- Decrease venous pressure
E- Increase lymphatic pressure
Ans: D

35. Regarding Fat embolism true is
A- Is a common autopsy finding after fracture of long bones?
B- Is less common in females
C- Is not usually present as respiratory insufficiency
D- Produce clinical symptoms 5-10 days after injury
Ans: A

CamScanner

36. About Red infarct:
A- Organ have dual blood supply
B- Organ having single blood flow
C- Where venous blockage along with arterial
D- Only arterial blockage
Ans: A

37. Local edema Occur due to
A- Allergy
B- Infection
C- Immunosuppression
D- Trauma
Ans: A

38. Systemic arterial emboli are most likely due to?
A- Right atrial mural thrombus
B- Left ventricle mural thrombus
C- Systemic venous thrombus
D- Right ventricle mural thrombus
Ans. B

39. Steps in thrombosis?
A- endothelial damage, decrease blood flow and change in blood constituent
B- Endothelial damage, increase blood flow and increase constituents of blood flow.
C- Endothelial damage and increase blood flow
D- Increase viscosity
Ans. A

40. Patient with peripheral claudication present in?
A- SLE
B- Peripheral arterial disease
C- Venous obstruction
D- RA
Ans. B

41. A patient having Tachycardia abdominal distension and hypotension after laparotomy due to which of these
A- Hypovolumic Shock
B- Septic Shock
C- Cardiogenic Shock
D- Anaphylactic Shock
E- Neurogenic Shock
Ans: A

42. Woman after hysterectomy for benign ovarian cyst came with fever, pneumonia and BP 80/60mmHg. Gram negative rods were identified she goes into shock what is the mechanism of her shock?
A- Neurogenic
B- Septic shock
C- Anaphylactic
D- Hypotensive shock
Ans: B

43. Angiouretic edema associated with
A- Menstruations
B- Depression
C- NSAID poisning
D- IgE
E- Pregnancy
Ans: D

44. Which is not a feature of Shock
A- Increase Urine output
B- Muscle weakness
C- Tachycardia
D- Restlessness
E- Decrease Cardiac output
Ans: A

45. Generalized edema is called
A- Pitting edema
B- Myxedema
C- Dependent edema
D- Non pitting edema
E- Anasarca
Ans: E

46. Last mediator of endotoxic shock
A- 1L-6
B- TNF
C- IL-1
D- IL-3
Ans: A

47. In All type of shock following occur:
A- Hypovolemia
B- Hypervolumia
C- Decrease Cellular oxygenation
D- Decrease Cardiac output
Ans: C

48. Which is not a cause of Cardiogenic shock
A- Hemorrhage
B- MI
C- Cardiac tamponade
D- Arryhmia
Ans: A

49. Primary Sign of Shock is
A- Increase BP
B- Dyspnea
C- Altered Sensorium
D- Rapid Pulse
Ans: D

50. Which one result in hypovolemic shock
A- Severe hemorrhage
B- Head injury
C- Ventricular infarction
D- Allergy

51. In septic shock which of following raised
A- Venous O2 content
B- Lactate
C- A-V Oxygen difference
D- IgE
Ans: B

52. Which is not related to embolus
A- Gas
B- Amniotic fluid
C- Thrombus
D- Fat
E- Liquid
Ans: E

53. Most common acquired thrombotic disorder
A- Factor V deficiency
B- Anti phospholipid syndrome
C- Protein C deficiency
D- Protein S deficiency
Ans: B

54- First line of defense in bleeding is?
A- Blood vessels constriction
B- Coagulation system
C- Platelets
D- Wbcs
Ans: A

55- Cardiogenic shock occurs due to:
A- Hemorrhage
B- Burn
C- Septicemia
D- MI
Ans: D

56- Patient presented with hypovolemic shock gets treatment what is indicator for successful fluid resuscitation?
A- Increase blood pressure
B- Increase pulse pressure
C- Increase urine output
D- Decrease blood pressure
E- Increase pulse
Ans: C

57- In malnourished child cause of Generalized edema is
A- Hypoproteinemia
B- Increase hydrostatic pressure
C- Increase Oncotic pressure
D- Increase Calcium
Ans: A

58- Moderate hemorrhage can be diagnosed clinically as:
A- Postural dizziness
B- Supine hypotension
C- Postural hypotension in 35 years old
D- Postural hypotension in 65 years old.
Ans: A

59- Most characteristic site of hemorrhagic infarct:
A- Heart
B- Kidney
C- Liver
D- Heart
E- Lung
Ans: E(Robins)

Explanation:
Hemorrhagic (Red Infarct)
- Due to venous occlusion seen in
- Liver
- Lung
- Intestine
- Testis

Pale infarct (White)
- Due to Arterial occlusion seeing in
- Heart
- Kidney

60- Edema in burn patient is due to which -- of following
A- Loss of Calcium
B- Loss of Sodium
C- Loss of Albumin
D- Loss of Chloride
E- Loss of Heparin
Ans: C

61- True about fat embolism
A- Symptoms after 12 h
B- 80% fatal
C- Common cause of thrombophlebitis
D- Breast trauma
Ans: A

62- Pregnant female with labour pain for 20hour was admitted in emergency and was being prepared for C section suddenly dies due to
A- Air embolism
B- Fat embolism
C- Amniotic fluid embolism
D- Pulmonary thromboembolism
Ans: C

Explanation:
- Air Embolism – History of Passing CVP then SOB
- Pregnant lady + Long bone fracture + Died on way to hospital within 24h or during labour – Amniotic fluid embolism
- Sudden death + Sudden SOB – Pulmonary Embolism
- Long bone fracture – Death after 3-5 days – Fat embolism

CamScanner

63- Fireman visits ER with burn on right arm blisters with little dermal damage seen in
A- 1st degree
B- 2nd degree
C- 3rd degree
D- 4th degree
E- 5th degree
Ans: B

64- A non diabetic female underwent cholecystectomy presented on 4th post op day with Cough , Hemoptysis and Dyspnea cause is
A- Hypovolumic shock
B- Cardiac shock
C- Pulmonary embolism
D- Neurogenic shock
E- Air embolism
Ans: C

65- Old female fall in washroom lead to fracture and replaced by prosthesis. On following day she developed dyspnea and petechial on skin cause is which of following
A- Air embolism
B- Fat embolism
C- Thrombotic
D- Amniotic fluid embolism
E- Pulmonary Embolism
Ans: B

66- Cause of edema in CLD is
A- Collagen
B- Albumin
C- Elastin
D- Fibrillin
E- Dystrophin
Ans: B

67- Old age woman had CVA was bedridden suddenly she became dyspneic but no other symptoms. After 2 days she had left sided pleuritic pain. Had another CVA and died. On autopsy wedge shaped hemorrhagic area was seen on left lower lobe. What could be the cause in lungs?
A- Vasculitis
B- Thromboembolism
C- Atherosclerosis
D- PAN
Ans: B

68- A known CLD patient developed edema, the likely mechanism is:
A- Decrease oncotic pressure
B- Increase hydrostatic pressure
C- Increase oncotic pressure
D- Salt Retention
Ans: A

69- Mural thrombus originates in:
A- Lungs
B- Liver
C- Heart
D- Kidney
Ans: C

70- 70 year old man, with recurrent UTI, developed hypotension, tachycardia altered mental status type of shock is: hemodynamic
A- Neurogenic
B- Hypovolemic
C- Septic
D- Cardiogenic
E- Anaphylactic
Ans: C

71- After hemorrhage HB binds with which of these?
A- Ferritin
B- Haptoglobin
C- Transferrin
D- Albumin
E- Globulin
Ans: B

72- A student of final year mbbs witnessing surgery for the first time collapsed in OT due to:
A- Decrease in peripheral resistance
B- Increase vascular permeability
C- Decrease CO
D- Sympathetic shock
E- Vasovagal shock
Ans: E

73- Recent thrombus consists of:
A- Platelets
B- Fibrin
C- Fibrin degradation product
D- Capillaries
E- Collagen
Ans: B

74- Most important cause of infarction in solid organ:
A- Inflammation
B- Necrosis
C- Atheroma
D- Air embolism
Ans: C

75- Common Cause of DVT is
A- HTN
B- DM
C- Trauma
D- Prolong immobilization
Ans: D

76- When fibrinogen is converted into fibrin by thrombin fragment released in plasma is
A- Fibrinopeptide A
B- Thromboxane A2
C- Fibrinopeptide A2
D- Plasmin
E- Thrombin
Ans: A

77- Activated Platelets release:
A- ANP
B- PG
C- Kinin
D- Steroids
E- Thrombasthenia and serotonin
Ans: E

78- White blood cells enter the lymph node through
A- Capillary
B- Sub capsular afferent lymphatic
C- Sub capsular efferent lymphatic
D- Medullary sinus
Ans: B

79- Low molecular weight heparin activates:
A- Antithrombin 3
B- Factor 10
C- XII
D- Thrombin
Ans: A
Explanation:
- It Activates – Antithrombin 3
- It inhibit – Factor X

80- Which of the following is the initial mechanism that stops bleeding after a cut?
A- Platelet aggregation
B- Degranulation
C- Vasoconstriction
D- PGI2 release
E- Vasodilation
Ans: C

81- Female hot burn develop blister generalized swelling and bleeding from burn area. Generalized swelling is due to Decrease
A- Collagen
B- Albumin
C- Elastin
D- Fibrillin
E- Dystrophin
Ans: B

82- Woman after RTA rushed to ER, she has warm extremities what is the type of shock?
A- Neurogenic
B- Septic
C- Hypovolemic
D- Cardiogenic
E- Anaphylactic
Ans: A

83- Patient was diagnosed as case of pulmonary embolism. What are the most common source of pulmonary emboli?
A- Deep leg veins
B- Lumen of Left atrium
C- Lumen of right ventricle
D- Femoral vein
E- Superficial leg veins
Ans: D
Explanation:
- DVT – Popliteal vein
- Embolism – Femoral vein

84- What takes place in neurogenic shock?
A- Loss of vasomotor tone
B- Increase peripheral vascular resistance
C- Increase Heart Rate
D- Increase Cardiac Output
E- Decrease blood volume
Ans: A (FA + Guyton

85- A 22-year-old second-year medical student develops a " red" face after being asked a question during lecture. Which of the following statements best describes this vascular reaction?
A- Active hyperemia
B- Acute congestion
C- Nonpalpable purpura
D- Passive hyperemia
E- Petechial hemorrhage
Ans: A

86- Vasculitis that involves same vessel or different vessels with lesion of different ages is which among these:
A- Kawasaki disease
B- PAN
C- Giant cell arteritis
D- Temporal Cell arteritis
E- Polyangitis
Ans: B

87- Heart is showing pale white infarct, cause:
A- Venous occlusion
B- Arterial occlusion
C- Anemia
D- Blood Loss
Ans: B

CamScanner

Explanation:
Haemorhagic (Red Infarct)
Due to venuous occlusion seen in
- Liver
- Lung
- Intestine
- Testis

Pale infarct (White)
Due to Arterial occlusion seen in
- Heart
- Kidney

88- 45 year old diabetic lady since 10 years admitted in hospital due to pneumonia and developing shock like symptoms cause will be:
A- Increased vascular permeability
B- Increased vasoconstriction
C- Increased peripheral resistance
D- Increase hydrostatic pressure
E- Decrease permeability
Ans: A

89- Microscopic feature of Polyarteritis nodosa is:
A- Granuloma
B- Fibrinoid necrosis
C- Transmural inflammation
D- Liquefactive necrosis
Ans: B

90- A patient has Femur fracture with soft tissue injuries. Shock occur due to:
A- Peripheral vasoconstriction
B- Decrease cardiac output
C- Insufficient blood volume
D- Increase cardiac output
Ans: C

91- Peripheral vasodilation along with hypotension seen in:
A- Septic Shock
B- Hypovolemic Shock
C- Toxic Shock
D- Cardiogenic Shock
E- Vasovagal Shock
Ans: A

92- Feature common to all type of shock is:
A- Bradycardia
B- Raised Cardiac output
C- Raised Lactate
D- Tissue Hypoxia
E- Warm
Ans: D

93- Patient presented in shock-like condition after RTA, multiple soft tissue injuries, cause of shock in this condition is?
A- Sepsis
B- Inadequate blood volume
C- Peripheral vasodilation
D- Anaphylaxis
Ans: C

94- Lymphatic obstruction is caused by
A- Inflammation and fibrosis
B- Renal failure and hypoproteinemia
C- Hematuria and albuminuria
D- Cardiac failure and IHD
E- Arterial obstruction
Ans: A

95- Laminar flow is directly proportional to 4th power of:
A- Radius
B- Length
C- Density
D- Pressure
Ans: A

96- Cause of hypotension in cardiogenic shock
A- Decrease myocardial contractility
B- Decrease Cardiac output
C- Decrease preload
D- Decrease after load
Ans: A

97- Cause of hypotension in cardiogenic shock
A- Decrease myocardial contractility
B- Decrease Cardiac output
C- Decrease preload
D- Decrease after load
Ans: A

98- Activated platlets secrete:
A- Thromboxane A2+ ADP
B- Thromboxane A2+ Fibrinogen
C- Fibrinogen+ADP
D- Thromboxane
E- ADP
Ans: A

99- Patient came with history of trauma. On examination there was Pulsatile bleeding from right inguinal region. He has difficulty in breathing and can tell his name with difficulty. BP was low and pulse was high. What will you do first?
A- Look for other possible injuries
B- Pass IV and give fluids
C- Maintain airway
D- Start bleeding by torniquet & start blood transfusion
E- Shift to OT for Surgery
Ans: C

100- Most Important factor for The generation of Thrombus?
A- Decreased blood flow +Endothelial injury+Altered blood particles
B- Fast Blood Flow+Endothelial injury+ Altered Clotting factors
C- Endothelial damage & Turbulent Blood flow
D- Plamin, then fibrin, then thromboplast
E- Decreased Viscosity with accelerated Blood Flow
Ans: A(Virchow's triad)

101- A patient presents with shock and fever. Laboratory results reveal elevated urea, raised AST and ALT levels, and increased bilirubin. What is the most likely diagnosis:
A- Acute Viral Hepatitis
B- Acute Kidney Injury
C- Septicemia
D- HCC
Ans: C

102- Occlusive thrombi originate in:
A- Heart
B- Veins
C- Small Artery
D- Young
E- Children
Ans: C

103- A Thrombus is most likely to lodge in:
A- Arteries
B- Veins
C- Capillary
D- Arterioles
Ans: B

104- A person after RTA has lost 8% of blood in 30 minutes but arterial pressure remain same this bleeding is from which of the following
A- veins
B- Capillaries
C- Aorta
D- Arteries
Ans: A

105- Indication of CVP line in ICU after hemorrhagic shock.
A- Rapid transfusion of blood
B- Trauma
C- Neurosurgery Patient
D- Pre-Op cachexic Patient
E- Estimation of Pulmonary edema
Ans: A

106- Patient presented with difficulty in breathing. Extrinsic mass is compressing the trachea. Which type of flow is observed?
A- Laminar flow
B- Turbulent flow
C- Stenotic flow
D- Static Flow
Ans: B

107- A patient develop fever, Pain and hematuria after cystoscopy due to:
A- Fistula formation
B- Cyst formation
C- Sepsis
D- Anti biotic resistant
Ans: C

108- A patient presented to ER with history of Trauma to abdomen, Left Posterior back from bicycle. His vitals are Bp. 130/80mmHg Pulse. 110/min on examination Purple Bruise & Tenderness on Affected area. No blood in urine. Investigations reveal a Hct of 22%. Next appropriate response?
A- Arrange blood products
B- CT Scan Abdomen
C- Tell attendants that Patient is out of danger so Discharge with follow- up
D- Admit Patient & Repeat Serial HCTs
E- Ultrasound Abdomen
Ans: E

CamScanner

109- A patient who has undergone tonsillectomy you notice that patient is unable to speak well and patient was bleeding which of the following is immediate method to assess for active bleeding
A- Pulse
B- Drain bottle
C- Vomitus
E- BP
Ans: A

110- A patient after RTA presents with severe blood loss what is first step in management
A- Maintain airway
B- Apply tourniquet or direct pressure
C- Fluid Resuscitation
D- Change position
Ans: C

111- A 40 year old male undergoing surgery. During surgery he was transfused with blood during transfusion patient developed hypotension which shock patient has developed
A- Distributive shock
B- Cardiogenic shock
C- Neurogenic shock
D- Hypovolumic shock
Ans: A

112- Difference in anaphylactic shock and other shocks is
A- Increase cardiac output
B- Increase vascular resistance
C- High venous pressure
D- Low mixed venous saturation
Ans: A

Explanation:

	Hypovolumic shock	Cardiogenic shock	Obstructive shock	Distributive shock
Cardiac output	Low	low	low	high
Vascular resistance	High	High	high	Low
Venous pressure	Low	high	high	low
Mixed venous saturation	Low	low	low	high
Base deficit	high	high	high	high

Better

113- Most likely location for hemorrhagic infarct:
A- Septic embolus in kidney
B- Embolus in spleen
C- Thrombus in coronary vessels
D- Lungs
Ans: D

114- Which of the following is the example of hemorrhagic infract
A- Liver occlusion with hypotension
B- Spleen occlusion due to thrombus
C- Pulmonary thromboembolism
D- Retina with emboli
Ans: C

115- A Patient loses 1 L of blood in 5 min, He will most probably have which of the following changes after 5 minutes:
A- Splanchnic vasodilation,
B- Increased preload
C- Increased GFR
D- Increased Venous return
E- Decreased TPR
Ans: E

116- A child fell from a bike and sustained a partial avulsion fracture of the tibia leading to separation of bone fragments. The fracture is located on the lateral side of the lower tibia, medial to the fibula. What is the most likely type of fracture?(Medicine Feb 2025)
A- Salter-Harris Type I
B- Salter-Harris Type II
C- Salter-Harris Type III
D- Salter-Harris Type IV
Ans: B

Explanation:
- Salter-Harris fractures are pediatric fractures involving the growth plate (physis).
- Type II fractures extend through the growth plate and metaphysis, sparing the epiphysis.

117- Loss of 1 liter of blood rapidly in five minutes will cause: (Medicine Feb 2025)
A- Decrease in heart rate
B- Decrease bp
C- NO change
D- Increase GFR
E- Systemic vasodilation
Ans: C

118- A patient presents with a blood pressure of 90/40 mmHg and a pulse rate of 125 beats per minute. What is the estimated percentage of blood loss?(Medicine Feb 2025)
A- Up to 15%
B- 15-20%
C- 20-30%
D- 30-40%
Ans: C

119- Most fatal type of pulmonary embolism that causes extensive pulmonary necrosis, shock and then death: (Surgery Feb 2025)
A- Fat embolism
B- Thromboemolism
C- Air embolism
D- Amniotic embolism
Ans: D

120- Female with occasional episodes of syncope and similar unconscious associated with movement, cause?(Surgery Feb 2025)
A- Vasovagal syncope
B- Subclavian steal Syndrome
C- Aortic stenosis
D- HOCM
Ans: A

121- Significant increase in blood viscosity is seen in(Surgery Feb 2025)
A- Acclimitization to high altitude
B- Pregnancy
C- Dehydration
D- Diabetes
Ans: C

122- A Patient is diagnosed with septic shock His hypotension is not improving with IV fluids. Most probable cause?(Gynae & Obs Feb 2025)
A- Resistant to fluids
B- Distributive type of shock
C- Characterized by decreased CO
D- Increased vascular permeability
Ans: B

123- An Old age Patient presented with thigh trauma during operation continuous bleeding. Baseline coagulation profile deranged. PT , APTT raised fibrinogen and platelet count low. On inquiry, History of bruises since 06 months, no other abnormality.Cause?(Anesthesia Feb 2025)
A- Sepsis and DIC
B- Accidental heparin during surgery
C- Warfarin used before surgery
D- Occult carcinoma likely Prostate (Previous history)
Ans: A

124- A patient after an RTA comes to the ER. There is no history of blood loss. On examination, BP is 80/40 mmHg, pulse is 60 bpm, and the patient has warm peripheries. What type of shock is this? (Anesthesia Feb 2025)
A- Septic
B- Hypovolemic
C- Anaphylactic
D- Neurogenic
Ans. D

CamScanner

NEOPLASIA QUICK HINTS

Hemartoma
- ✓ Localized disorganized overgrowth of mature cells normally found in organe.g Hepatic and Pulmonary hemartoma

Choristoma
- ✓ Presence of mass of very well developed and normally organized tissue of one organ into anothere.g Pancreatic cells found in submucosa of Stomach , Dudenum and Small intestine

Dysplasia
- ✓ Loss of Cell size , Shape and Architecture
- ✓ Pleormorphism

Anaplasia
- ✓ Loss of structural and Functional differentiation of normal cells

Desmoplasia
- ✓ Non neoplastic proliferation of fibrousconnective tissue

Benign	Malignant
Well Differentiated	Poor Differentiated
Grow Slowly	Grow Rapidly
Encapsulated(Except Leiomyoma)	Non Capsulated
Do not metastasize	Metastasize

Metastasis
- ✓ Due to downregulation of E Cadherin

Routes

Seeding within body cavities
- ✓ Colon and Ovary CA - Peritoneal cavity
- ✓ Lung CA - Pleural cavity

Lymphatics
- ✓ Lung CA and Breast CA

Hematogenous
- ✓ RCC , HCC , Follicular CA of thyroid and Endometrial CA

Tumor suppressor genes

RB gene
- ✓ **Governer** of Cell cycle
- ✓ Retinoblastoma occur due to Two Hit hypothesis

Cancer in Homozygous loss of RB
- ✓ Retinoblastoma
- ✓ Osteosarcoma
- ✓ Breast Cancer
- ✓ Small cell Carcinoma of lung

P53 gene
- ✓ **Guardian** of Cell cycle

Cancer in homozygous loss of P53
- ✓ CA colon , Lung , Breast and ovaries

APC gene
- ✓ One allele mutation -Colonic Polyp
- ✓ Both allele mutation - CA colon

Carcinogenic Agents

A)Chemical Agents

Direct acting
- ✓ Nitrosoureas
- ✓ Cyclophosphamide
- ✓ Chloramabucil

Indirect acting
- ✓ Hydrocarbons
- ✓ Benz anthracene - Skin cancer
- ✓ Benzopyrene - Lung CA
- ✓ Aromatic amines and azoazo dye
- ✓ Naphthylamine - Bladder CA
- ✓ Natural plant -- Aflatoxin -Liver CA

B)Radiation
- ✓ Ultavoilte rays of Sun - Skin Cancer
- ✓ Xrays - Skin and Thyroid cancer
- ✓ Atomic bomd radiation- Leukemia , Thyroid breast and Colon CA
- ✓ Stronium 90 - Osteosarcima>Leukemia
- ✓ Radiation induced Brain malignancy - Meningioma
- ✓ Overall radiation induced CA - Leukemia

Viral oncogen

RNA virus
- ✓ HTLV -Human T cell leukemia

DNA viruses
- ✓ HPV 16 &18 - Squmous Carcinoma of cervix
- ✓ EBV -Burkit lymphoma
- ✓ Hep B virus - HCC

Tumor specific antigen
- ✓ Embryonic(Oncofetal)
- ✓ a feto protein
- ✓ CEA

Differentiated
- ✓ CD10(CALLA antigen) - Leukemia and lymphoma
- ✓ Ganglioside antigen and S100 - Melanoma

Summary

Microscopic feature of malignant tumor:

- ✓ Metastasis > Invasion of adjacent tissues >pleomorphism>increasead N/C ratio
- ✓ **Grading --** Nuclear differentiation / degree of differentiation / Mitosis
- ✓ **Staging** – Extent of spread / Lymph nodes involvement
- ✓ Difference between hyperplasia and benign tumor – Capsule
- ✓ Difference between benign and malignant tumor - Metastasis
- ✓ **Pre-malignant lesion** - Pleomorphism Diagnostic
- ✓ **Pre-malignant condition** - Increased N/C ratio Diagnostic
- ✓ Most Common Pre-malignant lesion - **Leukoplakia**
- ✓ Most Lethal Pre-malignant lesion - **Erythroplakia**
- ✓ Most Common Pre-malignant Condition - **Submucosal Fibrosis**
- ✓ Most Lethal Pre-malignant Condition - **Lichen Planus**
- ✓ Locally Malignant - **BCC>Ambleoblastoma**
- ✓ Most common skin CA - **BCC (nodular type)**
- ✓ Most common site of BCC is - **Upper lip**
- ✓ Most common after Basal CA - **Squamous CA**
- ✓ Most common site of SCC - **Lower lip**
- ✓ Common cause of SCC Overall Bowen Disease > ActinicKeratosis
- ✓ But on Cheeks Actinic Keratosis occur and it needs Excision
- ✓ Blue cell tumor in children + releasing catecholamine + gene Amplification - **Neuroblastoma**

CamScanner

- ✓ Most Aggressive CA- **Melanoma**
- ✓ Most Common Naveus In Children -**Junctional**
- ✓ Most Common Naveus In Adult is - **Intradermal**
- ✓ Highest Malignant Potential - **Dysplastic Naveus**
- ✓ Angiosarcoma in Plastic Factory Worker – **Vinyl chloride**
- ✓ Angiosarcoma in Farmer – **Arsenic**
- ✓ **Plastic** Factory Worker – **Liver Angiosarcoma**
- ✓ **Plastic** Factory worker + **Smoking – Lung CA >Angiosarcoma**
- ✓ **Hydrocarbon(Tyre Factory) +Aromatic Amines – Bladder CA**
- ✓ **Smoking + Hydrocarbon – Lung CA > Bladder**
- ✓ **Liver CA – Acohol>Aflatoxin>Smoking**
- ✓ **Transitional Bladder CA – Smoking >Amines >Hydrocarbon**
- ✓ **Squamous Cell Bladder CA – Schistostoma>Stones > Indwelling Catheter**
- ✓ Common method to detect **Tumor - Tumor marker**
- ✓ Common method to detect **Tumor cells - Peripheral smear**
- ✓ Old Age + Painless testicular tumor + Raised LDH – Lymphoma
- ✓ Old Age + Painless testicular tumor + Mature Stem cells – Teratoma
- ✓ Young + Painless testicular tumor + Raised LDH+ Radiosensitive – Seminoma
- ✓ Least Radio Sensitive Blood Cell – Platelets
- ✓ Most Radio Sensitive Organ – Skin
- ✓ Least Radio Sensitive Organ – Vagina
- ✓ Most Radio Sensitive Mucosa – Intestinal
- ✓ Radiation induced Brain malignancy –Meningioma
- ✓ Overall radiation induced CA – Leukemia
- ✓ Regarding sensitivity to radiotherapy - Lymph node tumor > Seminoma > Glioma > Craniopharyngioma
- ✓ Commonest childhood blood malignancy – Leukemia
- ✓ Commonest childhood renal malignancy – Wilms tumor
- ✓ After Transplant most Common malignancy – Skin
- ✓ After Transplant Common malignancy in 1 or 5 Year – Lymphoproliferative
- ✓ After Transplant Common malignancy after 10-15 Years – Skin
- ✓ Radiation cause malignancy after - 10 years
- ✓ Most common skin cancer - basal > squamous >> melanoma
- ✓ Most common cancer in males - Prostate > Lung > Colon/rectum
- ✓ Most common cancer in females – Breast > Lung > Colon/rectum
- ✓ TNF Alpha --Cachexia in malignancy
- ✓ Tumor without bony metastasis – Liver carcinoma
- ✓ Least common site of malignancy – Spleen
- ✓ Not a epithelial tumor – Liposarcoma
- ✓ Not predisposed the cancer – Bacterial products
- ✓ Dividing cancer cells derive energy from – Glycolysis
- ✓ Tumor suppressor gene – loss of function result in increase risk of cancer
- ✓ Oncogenes – gain of function result in increase risk of cancer
- ✓ Acute effect of radiotherapy – Desquamation
- ✓ Chronic effect of radiotherapy – Endarteritis obliterans
- ✓ Late effect of radiotherapy – Lymph proliferative disorder
- ✓ How to differentiate hematopoietic stem cells in myelocytic stage – CD34 positive
- ✓ P53 and RAS mutants in stool and serum – Pancreatic cancer
- ✓ P53 , APC and RAS mutants in stool and serum – Colon cancer
- ✓ P53 and RAS mutants in sputum and serum – Lung cancer
- ✓ P53 mutants in urine – Bladder cancer
- ✓ Ca 125 – Ovarian cancer
- ✓ Ca 15-3 – Breast cancer
- ✓ Ca 19-9 – colon , pancreatic cancer
- ✓ B-HCG – Trophoblastic tumors, Hydatiform mole , non- seminominomatus testicular tumors
- ✓ AFP - Hepatocellular carcinoma, endodermal sinus (yolk sac) tumor, mixed germ cell tumor, ataxia-telangiectasia, neural tube defect
- ✓ Neuron-specific enolase - Neuroendocrine tumors (eg, small cell lung cancer, carcinoid tumor, neuroblastoma).
- ✓ Calcitonin - Medullary thyroid carcinoma
- ✓ Alkaline phosphatase Metastases to bone or liver, Paget disease of bone, seminoma
- ✓ CEA Colorectal and pancreatic cancers - Minor associations: gastric, breast, and medullary thyroid carcinomas.
- ✓ **Virus cause malignancy by**
  - **Alteration** in protein synthesis
  - **Alteration** in proto – oncogene
  - **Have /By Using**– Oncogene
- ✓ **Radiation cause malignancy by**
  - They **Have** Proto oncogene
  - By **Producing**Free radicals

CamScanner

NEOPLASIA

1- Professor took biopsy of lungs CA, and some student asked about its growth and then the professor said its 1cm and it needs to divide many times to make 10*9 cells, then hey asked how many times a cell has to divide to reach this number 10*9 (1 billion):

A- 30 times
B- 50 times
C- 1000 times
D- 100000 times
Ans: A

Explanation:
- After 1 division 1 cell become 2
- After 2 division 2 cell becomes 4
- After 3 division 4 cell becomes 8 and so on
- In short make no of division power of 2 you will get desired value

2- Most common cause of squamous cell carcinoma is:

A- Bowens disease
B- Marjolin ulcer
C- Actinic keratosis
D- Leukoplakia
E- Erythroplakia
Ans: A (Davidson +Golijan)

Explanation:
- Overall Bowen Disease > Actinic Keratosis
- But on Cheeks Actinic Keratosis occur and it needs Excision (Davidson + Goljan)

3- The risk of Lichen planus changing in to malignancy is?

A- 1-10%
B- 10-15%
C- 11-14%
D- 0-5%
E- 5%
Ans: B

Explanation:
- Lichen planus incidence – 1-10%
- Lichen planus into malignancy – 10-15%

4- Common Premalignant lesion of oral cavity is which among Following

A- Lichen planus
B- Paget disease
C- Actinic keratosis
D- Leukoplakia
E- Submucosal fibrosis
Ans: D

Explanation:
- Most Common Pre-malignant lesion – Leukoplakia
- Most Lethal Pre-malignant lesion – Erythroplakia
- Most Common Pre-malignant Condition – Submucosal Fibrosis
- Most Lethal Pre-malignant Condition – Lichen Planus

5- A scientist was experimenting on mice, he gave croton oil several times to mice in a week, then asked about how promoters causes carcinogenesis:

A- DNA damage.
B- Inhibiting apoptosis
C- RNA damage
D- Clonal expansion
Ans: D (Robins)

6- Mechanism of cancer formation:

A- Initiator and promotors
B- Only initiator cause carcinoma
C- Initiator followed by promotor causing carcinoma
D- Multiple initiators
E- Promotor followed by Initiator causing Carcinoma
Ans: C (Robins)

7- Tumor Suppressor gene is:

A- BRCA
B- RET
C- P53
D- BCL
Ans: C

8- Bladder cancer in a chemical industry worker is due to:

A- Vinyl chloride
B- Aniline dye
C- Irritation
D- Arsenic
E- Vinyl chloride
Ans: B

9- P53 is a tumor suppressor gene, when it is absent or mutated it may indicate:

A- Cell survival
B- Apoptosis
C- Cell death
D- Cell necrosis
Ans: A

Explanation:
- P53 is tumor suppressor gene and normally because apoptosis when it is absent or mutated so it lost its function hence no apoptosis or cell death and cell survival will occur.

10- Malignancy of tumor is determined by which of following feature

A- Pleomorphism
B- Metastasis
C- Decrease N/C ratio
D- Dysplasia
E- Anaplasia
Ans: B

11- Grading of carcinoma shows:

A- Dysplasia
B- Permeability to basement membrane
C- Mitosis inside cell
D- Invasion
E- Degree of differention
Ans: E

Explanation:
- For malignancy – Metastasis > Invasion of adjacent tissues > pleomorphism > increased N/C ratio
- Grading – Nuclear differentiation /Degree of differentiation / Mitosis
- Staging – Extent of spread / Lymph nodes involvement
- Pre-malignant lesion – Pleomorphism Diagnostic
- Pre-malignant condition – Increased N/C ratio Diagnostic

12- Common premalignant condition

A- Lichen planus
B- Submucosal fibrosis
C- Leukoplakia
D- Erythroplakia
E- Ulcer
Ans: B

13- Bladder cancer in a chemical industry worker due to:

A- Vinyl chloride
B- Aryl amines
C- Irritation
D- Arsenic
E- Vinyl chloride
Ans: B

Explanation:
- Plastic Factory Worker – Liver Angiosarcoma
- Plastic Factory worker + Smoking – Lung CA > Angiosarcoma
- Hydrocarbon(Tyre Factory) +Aromatic Amines – Bladder CA
- Smoking + Hydrocarbon – Lung CA > Bladder
- Liver CA – Acohol>Aflatoxin >Smoking
- Transitional Bladder CA – Smoking >Amines >Hydrocarbon
- Squamous Cell Bladder CA – Schistostoma>Stones > Indwelling

14- Characteristic feature of metastasis:

A- Up regulation of cadherin
B- Up regulation of integrins
C- Down regulation of E cadherins
D- Down regulation of integrins
E- Down regulation of Spectrin
Ans: C

15- 25 year old girl presented with lower abdominal pain. She is suspected of having abdominal pelvic mass upto umbilicus. Chest metastasis is also found which tumor maker is likely raised?

A- CA 19-9
B- CA 15-3
C- CA 125
D- AFP
E- Beta HCG
Ans: C (Ovarian CA)

16- Which of the following is Diagnostic criteria for sarcoma?

A- Pleomorphism
B- Increased vascularity
C- Mitotic figures
D- Local invasion
E- Metastasis
Ans: B

17- Which one of the following inorganic compound is carcinogenic?

A- Arsenic
B- Asbestos
C- Alcohol
D- Cisplatin
Ans: B

18- A female has a Fibrous breast mass with irregular shape, non-mobile and 3cm in size with skin involvement. On gross examination, this condition is likely to be:

A- Metaplasia
B- Anaplasia
C- Dysplasia
D- Desmoplasia
E- Hyperplasia
Ans: D

19- Radiation usually causes cancer after:

A- 7 Years
B- More than 10 years
C- 5 years
D- 2 Years
E- 1 Year
Ans: B

CamScanner

20- A worker is being working near a nickel metal shop which carcinoma is being predisposed likely?
A- Nasal
B- Kidney
C- Bladder CA
D- Liver CA
E- Lung CA
Ans: E >A (FA)

Explanation:
- Nickle cause – Lung and Nose CA
- Lung CA – Smoking >Radon >Asbestos

21- Patient with bettle nut and pan chewing history, mouth lesion will be:
A- Leukoplakia
B- Erythroplakia
C- Sub mucosal fibrosis
D- Chronic ulcer
E- Basal cell carcinoma
Ans: C

22- Tumor suppressor gene involved in renal and gonadal agenesis:
A- WT1
B- P53
C- Bcl2
D- BRCA
E- KRAS
Ans: A

23- In malignant melanoma patient tissue excised for biopsy which shows heterogenous cell lines most predominant cells will be against tumor are:
A- Cytotoxic cell
B- B cell
C- NK cell
D- Macrophages
E- Plasma Cells
Ans: C

Explanation:
- NK cell is anti-tumor cell
- NK cell kill virus infected cell
- CD56 is marker of NK cell

24- A Girl presented to her physician with concern both her mother and sister died of metastatic breast cancer before 40 year age. She is worried about herself which of the following gene is mutated?
A- Multiparity
B- APC
C- RAS
D- BRCA-1 Mutation
E- Fibroadenoma
Ans: D

25- Most common skin cancer in HIV/AIDS patients is:
A- Kaposi sarcoma
B- Hodgkin Lymphoma
C- Basal cell carcinoma
D- Squamous cell carcinoma
E- Multiple Myeloma
Ans: A

26- Which of the following tumor follows knudson two hit hypothesis?
A- Retinoblastoma
B- Neuroblstoma
C- Burkit Lymphoma
D- Pheochromocytoma
E- Wilms Tumor
Ans: A (FA)

27- A Young man working in factory for the last 5 years presented with painless hematuria and weight loss, on histopathology it was confirmed that the patient is suffering from urothelial carcinoma the most probable agent involve in the pathogenesis is:
A- Vinyl chloride
B- Benzidine dye
C- Aniline dye
D- Arsenic
E- Nitrosamine
Ans: C

Explanation:
- Transitional bladder CA – Smoking >Amines > hydrocarbon
- Squamous Cell Bladder CA – Schistostoma>Stones > Indwelling
- Aromatic amines and azo dyes widely used in Aniline dye these include 2-Naphthylamine ,Benzidine and 2-Acetylaminofluorene so All aromatic amines used in Aniline dye so best ans is Aniline dye

28- A Child having tumor with Blue cells which is secreting catecholamines and is because of gene amplification which is the most probable diagnosis?
A- Neuroblastona
B- Ewing Sarcoma
C- Wilms Tumor
D- Retinoblastoma
E- Pheochromocytoma
Ans: A

29- A p... to see metastasis we should ...
A- Fever
B- Lymphadenopathy
C- Tenderness
D- Rash
Ans: B

30- Feature which differentiate dysplasia from malignancy
A. Metaplasia
B. Pleomorphism
C. Invasion to basement membrane
D. Mitotic activity
E. Chronocity
Ans: C

31- The process of apoptosis is loss during the carcinogenic activity the following factor has anti apoptotic activity is:
A. BCL2
B. BCL1
C. BAX
D. PKL
E. BAK
Ans: A (Robins)

Explanation:
- Pro-Apoptotic – BAX and BAK
- Anti-Apoptotic – BCL2, BCL-XL and MCL1

32- Complication of IUCD likely is
A- Squamous metaplasia
B- Purulent discharge
C- Fibroid
Ans: B

Explanation:
- Irregular vaginal bleeding >Prulent discharge.

33- Cytokeratin is an intermediate filament found in cells but is most commonly used for detection of:
A- Degree of metaplasia or dysplasia
B- To check rate of proliferation
C- For staging of disease
D- For growth
Ans: A

34- 10 Year old child present with lump on forehead Mass excised from forehead microscope shows anastomosis of vessels and single layer of endothelium it is most likely:
A. Lipoma
B. Hemangioma
C. Sarcoma
D. Fibroma
Ans: B

...medical shop which carcinoma is being predisposed likely?
A- Nasal
B- Kidney
C- Bladder CA
D- Liver CA
Ans: A

Explanation:
- Nickle cause – Lung and Nose CA
- Lung CA – Smoking >Radon >Asbestos

36- Which of the following is Premaligmant lesion of oral cavity?
A- Lichen planus
B- Apthous ulcers
C- Leukoplakia
D- Submucosal fibrosis
Ans: C

37- Which of the following feature of cervical pap smear shows carcinoma in situ?
A- Dyskariosis
B- Basement membrane invasion
C- Increase vascularity
D- Fibrosis
Ans: A

39- Risk factor for the development of malignant melanoma:
A- Nitrosamine
B- Xeroderma pigmentosa
C- Congenital Navus
D- Lichen Planus
Ans: B

40- Bladder CA associated with:
A- Irritation
B- UTI
C- Exstrophy
D- Pyonephritis
Ans: C

41- Which of the following is locally malignant tumor?
A- Melanoma
B- Squamous Cell Carcinoma
C- BCC
D- Adenoid cystic carcinoma
Ans: C

42- Anticancer agent:
A- Chocolate
B- Apple
C- Orange
D- All
Ans: D (Apple above All)

CamScanner

43- Grading of cell shows:
A- Number of mitosis
B- Cell number
C- Invasion
D- All of the above
Ans: A

Explanation:
- Grading shows: No of Mitosis and degree of differentiation.
- Staging shows: Extent of invasion

44- Tumour marker for breast CA:
A- CA 19
B- CA 125
C- CA 15-3
D- PSA
E- CEA
Ans: C

45- Which one is not epithelial Tumor?
A- Adenocarcinoma
B- Squamous Cell CA
C- Liposarcoma
D- Gastric CA
Ans: C

46- Which of the following is called as governor of cell cycle?
A- APC
B- RB
C- BCL2
D- P53
Ans: B (Robins)

Explanation:
- Governor – RB
- Guardian – P53

47- Difference between carcinoma in situ and malignant disease:
A- Invasion
B- Metastasis
C- Capsule
D- Lymph node involvement
Ans: A

48- Oesophageal carcinoma occur due to:
A- Hydrocarbon
B- Nitrosamine
C- Aflatoxin
D- Bettel nut
Ans: B

49- Leukoplakia is:
A- Premalignant Condition
B- Premalignant lesion
C- Malignancy
D- None
Ans: B

50- Staging of tumor shows:
A- Differentiation
B- Extent of tumor
C- Mitosis
D- Type of Cell
Ans: B

51- Which one is premalignant?
A- Achlasia
B- Barret's Esophagus
C- Mallory Weiss
D- Bourheves Syndrome
Ans: B

14- A Person working in a tyre factory for last 15 years is at increased risk of:
A- Bladder carcinoma
B- Hepatoma
C- Lung carcinoma
D- Leukemia
E- Small Cell Carcinoma
Ans: A

15- What is the type of mutation in Li fraumeni syndrome?
A- RB gene
B- MEN-1
C- Tp53
D- K-RAS
Ans: C

16- Which of the following is due to K-Ras mutation?
A- Gastric carcinoma
B- Breast carcinoma
C- Colorectal carcinoma
D- Hereditary non-polyposis of colon
Ans: C(Robins +FA)

17- Most common carcinoma of bladder:
A- Mesothelioma
B- Transitional cell carcinoma
C- Papillary carcinoma
D- Squamous cell carcinoma
Ans: B

18- Patient having alternative diarrhea and constipation habits and per rectal bleeding diagnosed as a case of colon cancer which is the tumor marker:
A- Alpha fetoprotein
B- CEA
C- CA-125
D- BRCA -2
Ans: B

19- A farmer presents with hyperkeratosis, parakeratosis, atypical cells and brown color lesion on face and cheek most likely is
A- Actinic keratosis
B- Solar keratosis
C- Squamous cell carcinoma
D- Basal cell carcinoma
Ans: A

20- A patient with complain of fatigue, weakness and weight loss. He gave history of Alcohol abuse in past now diagnosed as Liver carcinoma what tumor marker will be raised?
A- CEA
B- CA 125
C- AFP
D- CA 13
E- CA 19-9
Ans: C

21- Proto oncogene most commonly altered by:
A- Chemical
B- Virus
C- Radiation
D- Bacteria
E- Fungus
Ans: B

Explanation:
- Virus cause cancer by using – Oncogen
- Virus cause cancer by altering – Protein synthesis >Proto oncogene.
- Radiation cause cancer by using – Proto oncogene.

22- HCC most common cause:
A- Nitrosamine
B- CMV
C- Aflatoxin
D- Hydrocarban
Ans: C

23- Which one causes Lung CA?
A- Nitrosamine
B- H. pylori
C- Asbestos
D- Silica
Ans: C

Explanation:
- Smoking >Radon >Asbestos

24- Most important factor associated with malignancy:
A- Grading
B- Staging
C- Invasion
D- None of the above
Ans: B

25- Which of the following is most common benign tumor?
A- Pleomorphic Adenoma
B- Warthin Tumor
C- Mucoepidermoid Ca
D- SCC
Ans: B

26- Malignant Tumor feature is :
A- Pleomorphis
B- Metastasis
C- Desmoplasia
D- Increase N/C ratio
Ans: B

Explanation:
- Malignancy is characterized by:
- Metastasis > Invasion > Pleomorphism > Increase N/C Ratio.

27- 5 years after transplant surgery malignancy is:
A- Skin
B- Lymphoproliferative
C- Rectal
D- Lungs
Ans: B

Explanation:
- The commonest malignancy after transplant is: Skin
- After 10 years: Skin
- After 5 years: Lymphoproliferative

28- Which one of the following causes bladder carcinoma?
A- Cyclophosphamide
B- Aniline dye
C- Smoking
D- Alcohol
Ans: C

29- Angiosarcoma of liver in factory worker is caused by:
A- Vinyl Chloride
B- Arsenic
C- Aflatoxin
D- Aniline Dye
Ans: A

Explanation:
- If in history farmer is given then go for: Arsenic.
- If in history factory worker is given then go for: Vinyl chloride.

30- Obstructive lung disease is diagnosed in patient which of the following is the causative agent:
A- Nicotine
B- Arsenic
C- Nickle
D- Cadmium
Ans: A

CamScanner

31- Virus act on the cells by following mechanism:
A- Damage to cell membrane
B- Damage to nuclear membrane
C- Involving protein synthesis
D- Changing protein structure
Ans: C

85- Grading of carcinoma shows:
A- Type of Epithelium
B- Type of Muscle
C- Type of Cell
D- Type of Nuclei
Ans: C
Explanation:
- Grading shows type of Cells or differentiation.

32- Which of the following carcinoma is related to smoking?
A- SCC
B- BCC
C- Melanoma
D- None of the above
Ans: A

33- CEA is normally found in embryonic period, 60% pancreatic carcinoma and is also found in which of the following carcinoma:
A- Lungs
B- Colon
C- Liver
D- Kidneys
Ans: B

34- Which of the following tumor marker is positive in meigs syndrome?
A- CA-123
B- CA-125
C- AFP
D- LDH
Ans: B
Explanation:
- Meigs syndrome is defined as the triad of benign ovarian tumor with ascites and pleural effusion that resolves after resection of the tumor.

35- Which of the following is tumor marker of both pancreatic & colonic carcinoma?
A- CEA
B- AF
C- LDH
D- CA-125
Ans: A

36- Repetitive division/mitosis is seen in:
A- Grading
B- Staging
C- Permanent Cells
D- Cardiac Cells
Ans: A

37- Cell is arrested at G1 by:
A- TP53
B- Rb Gene
C- K-Ras
D- Bcl2
Ans: A

38- Which carcinoma is autosomal dominant?
A- Hepatocellular carcinoma
B- Colon carcinoma
C- Childhood retinoblastoma
D- DMD
Ans: C

39- Serum marker for hepatocellular carcinoma
A- AFP
B- CEA
C- CA-125
D- CA – 19-9
Ans: A
Explanation:
- Hepatocellular Ca: AFP
- Colorectal Ca: CEA
- Ovarian Ca: CA-125
- Pancreatic Ca: CA-19

40- Cryptorchidism increases the risk of:
A- Malignancy
B- Infection
C- UTI
D- Renal problem
Ans: A

41- Which of the following tumor marker is raised in neural tube defect?
A- AFP
B- LDH
C- CEA
D- CA-125
Ans: A
Explanation:
- AFP is raised in neural tube defect & helps in diagnosis
- Specific- Acetylcholinesterase
- Sensitive- AFP

42- Which of the following is premalignant lesion of Vulva?
A- Paget disease
B- Lichen scleorosis
C- Lichen planus
D- Krause Vulvae
Ans: A
Explanation:
- Paget Disease > Krause Vulvae > Lichen Sclerosis.

43- Metastasis most common to the brain is from:
A- Liver
B- Kidney
C- Lungs
D- Breast
Ans: C

44- Microscopic feature of malignancy us:
A- Pleomorphism
B- N/C Ratio
C- Invasion of surrounding tissues
D- Infarction
Ans: C

45- Virus causes cancer by undergoing alteration in:
A- Nuclear integration
B- Cell membrane proliferation
C- Protein synthesis
D- Lysis of Nucleic Acids
Ans: C

46- Schistosoma hematobium cause which cancer of bladder?
A- Transitional cell ca
B- Squamous cell ca
C- Adenocarcinoma
D- None
Ans: B

47- Which of the following is para-neoplastic syndrome?
A- Small cell carcinoma
B- HCC
C- RCC
D- Melanoma
Ans: A
Explanation:
- Cushing syndrome
- SIADH
- Polycythaemia
- Hypercalcemia

48- Paraneoplastic syndrome associated with renal cell carcinoma
A- Polycythaemia
B- Cushing syndrome
C- SIADH
D- Hypercalcaemia
Ans: A

49- A lady with cervical cancer of 3.5 cm. ipsilateral and lymph nodes are enlarged with suspected metaplasia. The staging classification will be:
A- T1N2M1
B- T2N1M1
C- T2N1M0
D- T1NOMO
Ans: B

50- Small cell carcinoma of lung causes
A- SIADH
B- Cushing disease
C- Hypercalcemia
D- Polycythaemia
Ans: A

51- In squamous cell carcinoma of lung there is increase
A- ACTH
B- ADH
C- Erythropoietin
D- PTHrP
Ans: D

52- Most radiosensitive tumor is:
A- Medulloblastoma
B- Brain stem glioma
C- Astrocytoma
D- Ependymoma
E- Craniopharyngioma
Ans: B
Explanation:
Lymph node > seminoma > glioma > craniopharyngioma

53- Highly radiosensitive tumor is:
A- Lymphoma
B- Glioma
C- Seminoma
D- Craniopharyngioma
Ans: A
Explanation:
Lymphoma > Seminoma > Glioma > Craniopharyngioma.

54- Only LDH increased with no other tumor marker. The condition is:
A- Lymphoma
B- Glioma
C- Seminoma
D- Craniopharyngioma
Ans: A

CamScanner

55- The chronic exposure to radiation causes:
A- Lichen Planus
B- Melanoma
C- Endarteritis obliterans
D- Anemia
Ans: C

56- A chronic smoker smoking 20 cigarettes per day for around 20 years would develop:
A- Squamous metaplasia
B- Burkitt lymphoma
C- Hyperplasia
D- Hypertrophy with hyperplasia
Ans: A

57- Malignancy occurs after how many years of exposure to radiations:
A- 5 years
B- 8 years
C- 10 years
D- 20 years
Ans: C

58- Diagnostic criteria for pre malignant condition is:
A- Increase N/C ratio
B- Pleomorphism
C- Hyperplasia
D- Dysplasia
Ans: A
Explanation:
- Malignancy: Metastasis > Invasion >Pleomrophism> Increase N/C ratio
- Pre malignant lesion : Pleomorphism
- Pre malignant condition: Increase N/C ratio

59- Histological diagnostic criteria for malignant tumour:
A- Pleomorphism
B- Local invasion
C- Mitotic figures
D- Increase N/C ratio
Ans: B

60- The histological feature less than 25 % differentiated cells is suggestive of
A- Poorly differentiated
B- SCC
C- Undifferentiated CA
D- Anaplasia
Ans: C

61- A study is performed to assess characteristic of malignant neoplasm biopsy specimen. The biopsies were perform patients who had palpable mass lesions on digital examination. Of the following microscopic finding is not an indicator of malignancy?
A- Pleomorphism
B- Atypia
C- Encapsulated
D- Increased N/C ratio.
E- Necrosis
Ans: C

62- Which of following is feature of Benign Tumor?
A- Invasion
B- Pleomorphism
C- Irregular margin
D- Encapsulated
Ans: D

63- The most common asbestos related tumor in human being is:
A- Bronchogenic carcinoma
B- Pleural mesothelioma
C- Bladder carcinoma
D- Breast carcinoma
Ans: A

64- Nasopharyngeal carcinoma is most commonly associated with:
A- HPV
B- Hep.B
C- Aflatoxin
D- EBV
Ans: D

65- Radiotherapy damage which phase
A- G1
B- G2
C- S
D- G0
E- M
Ans B

66- Barret esophagus can cause which of the following carcinoma:
A- Adenocarcinoma
B- Squamous cell Carcinoma
C- Melanoma
D- Small cell carcinoma
Ans: A

67- Benign tumor is
A- Leiomyoma
B- Lymphoma
C- Sarcoma
D- Leukemia
Ans: A

68- Risk Factor for endometrial carcinoma
A- Multiparity
B- Early menopause
C- Late menarchae
D- Hypotension
E- DM
Ans: E
Explanation:
Risk factors _ Obesity , DM , infertility , estrogen , Hypertension

69- Increase risk of cancer in HIV positive Female patient is
A- CA Bladder
B- CA bronchus
C- CA Cervix
D- CA lung
Ans: C

70- Patient with cancer T4N1M1 , such that these patients have low survival rate. What will be common to such patients?
A- Cachexia
B- HCC
C- Cervical Ca
D- Bladder cancer
Ans: A

71- Protoncogenes converted to oncogenes by:
A- Point mutation
B- Translation
C- DNA transcription
D- Chromosomal translocation
Ans: A

72- Mechanism of reduction in size of organ of a patient undergoing chemotherapy is
A- Atrophy
B- Apoptosis
C- Necrosis
D- Direct action of chemo drug
Ans: B

73- Hamartoma is
A- Ectopic tissue
B- Disorganized growth of mature cell indigenous to the site
C- A tumor which can metastasize
D- A tumor with all germ layers
Ans: B

74- Dysplasia is recognized by
A- Loss of polarity and architecture
B- Pleomorphism
C- Dyskariosis
D- Change of Epithelium
Ans A

75- Patient With below knee amputation. After that painful scar formed this is
A- Neuroma
B- Ganglioma
C- SCC
D- BCC
Ans: A

76- Most common location of Ectopic Salivary gland
A- Tongue
B- Palate
C- Cheek
D- Nose
Ans: B

77- Mammography reduces prevalence of CA breast by
A- 10%
B- 30%
C- 40%
D- 50%
Ans: C

78- Tumor that don't secrete any hormone:
A- Choriocarcinoma
B- Teratoma
C- Chondrosarcoma
D- None
Ans: C

79- Pap smear done for a women, HPV positive after 2yr increased nuclear size, prominent nucleoli. What is it?
A- Dysplasia
B- Anaplasia
C- Carcinoma
D- Metaplasia
Ans: A

80- Capsule of benign neoplasm is derived from
A- Parenchyma
B- Stroma
C- Necrotic tissue of tumor
D- None
Ans B

81- Premalingnat nevus is:
A- Compound nevus
B- Intradermal nevus.
C- Junctional nevus.
D- Dysplastic nevus
Ans: D
Explanation:
- Dysplastic >Cngenintal> Compound > Intradermal > Junctional

CamScanner

82- 70 years old male with burning micturition, urgency, dysuria and back pain and also history of left upper limb pain and fracture of bone on labs there is increase in alkaline phosphatase most appropriate investigation is
A- Serum phosphate
B- Serum calcium
C- Serum PTH level
D- Serum PSA
Ans: D

83- Permeation is defined as
A- Tumor invasion to blood vessels
B- Tumor invasion to adjacent tissue
C- Tumor invasion to lymphatics
D- Distant metastasis
Ans: C

84- A child has bald patch on scalp since birth. Which is leathery On microscopic exam there are papillomatous projections in epidermis. Dermis main abundance of sebaceous glands. What is the serious complication?
A- Basal cell carcinoma
B- Squamous cell carcinoma
C- Scaling alopecia
D- Melanoma
Ans: A(Sebaceus Naveus induced)

85- Which one of the following is mesenchymal in origin
A- Choristoma
B- Sarcoma
C- Hemartoma
D- Carcinoma
Ans: B

86- A patient with a bald patch on scalp which on examination is yellow velvet. It can lead to which dangerous condition:
A- Squamous cell carcinoma
B- Basal cell carcinoma
C- Keratoacanthoma
D- Transitional cell carcinoma
Ans: B

87- A patient is on radiotherapy after that DNA damage A gene which arrest in G1 phase progression defective unregulated growth occurs due to which?
A- K-ras
B- N-myc
C- P53
D- Bcl-2
Ans: C

88- Tumor marker of astrocytes
A- GFAP
B- CEA
C- CA-125
D- CA-19-9
E- FAP
Ans: A

89- Cancer in humans due to:
A- Apoptosis
B- One less chromosome
C- One extra chromosome
D- Over expression of proto oncogene
E- Non-lethal gene mutation
Ans: D

90- Which component of neoplasm determines its biological behaviour
A- Stroma
B- Parenchyma
C- Vascular component
D- Lymph vessels
Ans: B

91- AIDS defining cancer is
A- Esophageal carcinoma
B- Malignant melanoma
C- Kaposi sarcoma
D- Basal cell carcinoma
Ans: C

92- Following is not a characteristics of malignant tissue
A- Abnormal mitosis
B- Anaplasia
C- Metastasis
D- Fibrous reaction around tumor
E- Increased nuclear to cytoplasmic reaction
Ans D

93- Oat cell carcinoma tumor marker
A- ACTH
B- ADH
C- PTHrP
D- Erythropoietin
E- PSA
Ans: A

94- All are markers for osteoblastic activity except
A- Bone scan
B- Osteocalcin
C- Alkaline phosphatase
D- Hydroxyproline
Ans: D

95- Kaposi sarcoma is commonly seen in
A- Head and neck
B- Abdomen
C- Back
D- Upper limb
E- Lower limb
Ans: A

96- Neoplastic disease may be associated with all except
A- Dermatomycytosis
B- Necrobiosis lipodica
C- Acanthosis nigracians
D- Thrombophelibitismigrans
Ans: B

97- How to differentiate hematopoietic stem cells in myelocytic stage
A- Staining of granules
B- No lineage of specific markers
C- CD 33 negative
D- CD 34 positive
Ans: D
Explanation:
- When hematopoietic mention mark CD34 , otherwise staining of granules

98- Tumor containing all the three germ cell layers is
A- Yolk sac tumor
B- Seminoma
C- Teratoma
D- Granulosa cell tumor
Ans: C

99- Which is carcinogen
A- UV light for bones
B- Aflatoxin for breast
C- UV light for esophagus
D- Alcohol for liver
Ans: D

100- The following tumor may secrete hormone:
A- Carcinoid
B- Benign tumor of ovary
C- Seminoma
D- Choriocarcinoma
Ans: B

101- Testicular tumor what will increase if it's not seminoma?
A- Beta HCG
B- AFP
C- CA – 125
D- CA– 127
Ans: B >A

102- A tumor of vermis in child . histology was given . true rossets are present . what is diagnosis
A- Ependymoma
B- Medulloblastoma
C- Rhabdomyosarcoma
D- Basal cell carcinoma
Ans: B
Explanation:
- True Rosset or horner right rossets – Medulloblastoma
- Psudo rosettes - Ependymoma

103- Most likely primary site for metastatic lung cancer with histology of sheets of clear cells
A- Lung
B- Renal
C- Breast
D- Stomach
E- Cervix
Ans: B

104- Which one is benign tumor
A- Adenoma
B- Hepatoma
C- Leukemia
D- Lymphoma
E- Liposarcoma
Ans: A

105- Which one is not malignant tumor
A- Chronic Osteomyelitis
B- Ulcerative colitis
C- Erythroplakia
D- Sarcoidosis
E- Renal cell carcinoma
Ans: A

106- Which of following is most aggressive carcinoma?
A- BCC
B- SCC
C- Melanoma
D- Leukoplakia
E- Lichen planus
Ans: C

107- Which is produced by carcinoid tumor?
A- Serotonin
B- Histamine
C- Dopamine
D- Epinephrine
Ans: A

CamScanner

108- A patient diagnosed with Papillary Carcinoma of Thyroid with no family history Cause is
A- Iodine
B- Metastasis
C- Chemotherapy
D- Family history
E- Radiation in childhood
Ans: E

109- Medullary CA tumor marker is
A- CA 125
B- CA 19-9
C- Calcitonin
D- CA 15-5
E- ALP
Ans: C

Explanation:
Papillary CA
- Associated with radiation
- Psomomma bodies and orphan anie eye nucleus
- Slow growing
- Spread via lymphatic
- Best prognosis

Follicular CA
- Invade Capsule
- Vascular Spread
- 2nd Best Prognosis

Medullary CA
- Release calcitonin
- MEN 1 and men 2 associated
- Poor prognosis

Anaplastic CA
- Very poor prognosis
- Highly undifferentiated

110- Most Common CA in Men world wide:
A- Lung CA
B- Prostate CA
C- Liver CA
D- Colon CA
Ans: B

111- Biopsy of stomach done, there was none specialized gastric tissue and scatter goblet cells this is related to:
A- Metaplasia
B- Dysplasia
C- Ca stomach
D- Ulcer
E- Hyperplasia
Ans: A

112- N-Myc mutation is seen in
A- Neuroblastoma
B- Nephroblastoma
C- Wilms Tumor
D- Retinoblastoma
E- Glioblastoma
Ans: A

113- Clinically palpable lymph node but mattled and the likelyhood of metastasis in malignancy what will be the stage of this cancer?
A- T1N1M1
B- T1N1M0
C- T2N1M1
D- T1N0M0
Ans: C

114- Child presented with decrease vision and mass in eye likely diagnose is
A- Cataract
B- Glucoma
C- Retinoblastoma
D- Wilms tumor
Ans: C

115- A child diagnosed to have blue cell tumor with Gene amplification and high catecholamine. Which of the following gene associated with it
A- MS1
B- Myc gene
C- Retinoblastoma gene
D- P53
E- ACC
Ans: B

116- Woman had a polyp in the cervix Pap smear shows thick endothelium with pleomorphic cells and hyperchromatic nuclei showing koilocytes the change is:
E- Squmous Metaplasia
F- Dysplasia
G- Squmous cervical Anaplasia
H- Adenoma
I- Carcinoma
Ans: B

117- A Man smoke 20 packs per month work in factory he develops lung cancer which carcinogen in Cigarette cause lung cancer
A- Nitrosamines
B- Hydrocarbons
C- Vinyl chloride
D- Azo dye
E- Arsenic
Ans: B

118- A 30 years old male presented with history of fever, significant weight loss, painful micturition, hematuria and flank mass, his Hb is 18. what could be the possible pathology associated with his condition:
A- Rhabdomyosarcoma
B- Angiomyolipoma
C- Polycystic kidney disease
D- RCC
E- HCC

Explanation:
- As the patient presented with history of weight loss and symptoms related to renal system along with increase hemoglobin that's due to increase erythropoietin level secreted by kidneys and the most suitable among the mentioned options is RCC.

119- Diagnosis of colon CA made many years back CEA was raised that time pt came for regular checkup you advised CEA now what is role of CEA?
A- For Staging
B- For Follow up
C- To confirm Malignancy
D- Cell differentiation
Ans: B

120- Patient has Mass in front of neck. On examination it is firm and tender. The patient also has hoarseness. The test to be done for diagnosis?
A- Ultrasound neck
B- Biopsy
C- T4 levels
D- FNAC
E- Radioisotope Scan
Ans: A

121- Which of the following is locally malignant tumor?
A- Melanoma
B- Squamous Cell Carcinoma
C- Ambleoblastoma
D- Adenoid cystic carcinoma
E- Hemartoma
Ans: C

122- Female patient is diagnosed with invasive ductal carcinoma. Upon investigation CA was 6CM mass with skin involvement 4 axillary lymph nodes involvement tumor is graded as high grade CA due to ?
A- Skin involvement
B- Lymph nodes involvement
C- Nuclear malignancy
D- Invasion
E- Metastasis
Ans: E

123- Local Lymphatic obstruction is caused by combination of which two?
A- Infection and neoplasia
B- Renal failure and hypoproteinemia
C- Hematuria and albuminuria
D- Cardiac failure and IHD
E- Arterial obstruction
Ans: A

124- In Breast carcinoma orange peep secretions related to
A- Sebacous gland
B- Sweat gland
C- Fibrous scar cells
D- Invasive carcinoid cells
Ans: D

125- Cancer most prevalent in male of karachi is
A- Lung CA
B- Stomach CA
C- Liver CA
D- Oral Cancer
Ans: D

126- A Pap smear of lady done which shows dysplasia Increase N/C Ratio and Pleomorphism but basement membrane is intact what is associated with this?
A- Invasion of adjacent tissue
B- Invasion of basement membrane
C- Carcinoma in situ
D- Carcinoma
Ans: C

127- DNA is often damaged causing carcinogenesis. Which of following is DNA repair gene?
A- P53
B- Rb1
C- APC
D- KRAS
Ans: A

128- N-myc gene amplification associated with
A- Pheochromocytoma
B- Pituitary adenoma
C- Ewing sarcoma
D- Nephroblastoma
E- Neuroblastoma
Ans: E

129- Which of the following conditions is related to lymphatic obstruction?
A- Angiosarcoma
B- Rhabdomyosarcoma
C- Leiomyoma
D- Cystic hygroma
E- Mucocele
Ans: D

130- Extent of damage to tissue by ionizing radiations usually depends on:
A- Age of the patient
B- Type of radiation
C- Type of tissue exposed
D- Dose of radiation with short exposure
E- Duration of exposure

CamScanner

131- In grade 3 carcinoma how many cells remain undifferentiated?
A- 5%
B- 25%
C- 50%
D- 75%
E- All
Ans: D

132- Ovarian cancer Spreads by which route:
A- Direct spread
B- Peritoneal cavity
C- Pleural cavity
D- Inguinal nodes
E- Fallopian tubes
Ans: B

133- A patient with Sarcoma of thigh receives radiotherapy for after 6 months he develops scaring & fibrosis of the skin it is due to which of following?
A- Endarteritis Obliterans
B- Desquamation
C- Venous thrombosis
D- Infection
E- Inflammation
Ans: A

Explanation:
- Acute effect of radiotherapy – Desquamation
- Chronic effect of radiotherapy – Endarteritis obliterans
- Late effect of radiotherapy – Lymph proliferative disorder

134- Most common method to detect any type of cancer in blood is?
A- CBC
B- Tumor markers
C- Peripheral smear
D- Ferritin
Ans: B

Explanation:
- Common method to detect Tumor - Tumor marker
- Common method to detect any cancer - Tumor marker
- Common method to detect Tumor cells - Peripheral smear

135- A woman is suffering from HIV what cancer she is at risk of developing:
A- Endometrial CA
B- Ovarian Ca
C- Uterine and cervical Ca
D- Vulvular
Ans: C

136- For Extensive Metastasis Bone scan necessary for which cancer:
A- Melanoma
B- Squamous cell carcinoma
C- Basal cell carcinoma
D- Retinoblastoma
Ans: D

137- B cell markers used for their identification in a tumour:
A- CD 21
B- CD 23
C- CD 19 20
D- CD 15
Ans: C

138- Carcinogen cause mutation, these genetic mutations are?
A- Lethal
B- Non lethal
C- Acquired
D- Temporary
Ans: C

139- Colon adenocarcinoma where metasisis first?
A- Mesocolic lymph
B- Liver
C- Lung
D- Brain
E- Spleen
Ans: A

140- Patient breast carcinoma having history mother sister maternal aunt gene BRCA 1 causing carcinoma present on
A- Nucleus
B- Cytosol
C- Cytoskeletal
D- Plasma membrane
E- Cell surface
Ans: A

141- Which of following is tumor of upper eyelid
A- BCC
B- Actinic keratosis
C- Acanthamoeba
D- Leukoplakia
E- Lichen planus
Ans: A

142- CSF findings necessary to rule out which carcinoma
A- Retinoblastoma/Melanoma of Eye
B- Neuroblastoma
C- Nephroblastoma
D- Meningioma
E- SCC
Ans: A

143- Tumor of eye least likely to Metastasize
A- RB
B- Ewing sarcoma
C- BCC
D- SCC
E- Melanoma
Ans: C

144- All are germ cell tumor of testes except
A- Lymphoma
B- Teratoma
C- Leydig cell tumor
D- Choriocarcinoma
Ans: C

145- Tumour with good prognosis is:
A- Germ cell
B- Gastric
C- AML
D- Ovarian
Ans: B

146- Basal cell carcinomas are commonly Seen In which
A- Fitz -Hugh & Curtis syndrome
B- Gorlin goltz syndrome
C- Hermansky pudlak syndrome
D- Chediak Higashi syndrome
Ans: B

147- A patient has Lesion on nose examination reveal flesh color lesion with slightly elevated rolled edges and regular margins cause is
A- BCC
B- SCC
C- Smooth and shiny surface
D- Rough surface
Ans: A

148- Which tumor involves extension to --- nerve sheath
A- Myxoma
B- Adenoma
C- Hemangiopericytoma
D- Carcinoma expleomorphic adenoma
Ans: D

149- Most important test clinically for -- tumor is which of following
A- Grading
B- Pleomorphism
C- Staging
D- N/C ratio
E- Mitosis
Ans: C

150- Basal cell carcinoma most common -- type
A- Squamous
B- Anaplastic
C- Ulcer
D- Nodular
E- Inflammatory
Ans: D

151- A patient diagnosed case of Carcinoma and treated with radiation treatment of carcinoma by radiation decrease it's size by
A- Ionizing free radicals
B- Genetic mutation
C- Point mutation
D- Genetic draft
Ans: A

152- Virus causes cancer by alterations in
A- Proto oncogene
B- Oncogene
C- DNA
D RNA
Ans: A

Explanation:
- Virus cause cancer by using – Oncogen
- Virus cause cancer by altering – Protein synthesis >Proto oncogene.
- Radiation cause cancer by using – Proto oncogene

153- Loss of functional mutation in which gene cause cancer
A- APC
B- BCL3
C- TP53
D- BCL2
Ans: C

154- Feature of well differentiated Squamous cell carcinoma is
A- Cytokeratin
B- Myc gene
C- Rb 53
D- Keratin pearls
Ans: D

155- Most widely used technique to detect tumor cells is
A- CBC
B- Tumor markers
C- Peripheral smear
D- Ferritin
Ans: C

Explanation:
- Common method to detect Tumor – Tumor marker

CamScanner

- Common method to detect any cancer – Tumor marker
- Common method to detect Tumor cells – Peripheral smear

156- Most cancers have sporadic transmission but some have genetic element. Which syndrome is acquired as autosomal dominant with tumour mutation?

A- Familial adenomatous polyposis
B- Tay sach disease
C- Villous adenoma
D- Multiple sclerosis
E- Tubular adenoma
Ans: A

157- A professor was talking about tumor suppressor gene that involve in cancer of long bones due to mutation in single or both allele. He gives example of bringing their child being affected by a disease with rest of children being normal. The gene involved is:

A- KRAS
B- Myc
C- RB 1
D- WT 1
E- MSH
Ans: C

158- Gene alteration is CA pancreas is

A- APC
B- BRCA 2
C- KRAS
D- Bcl2
Ans: B

159- A group of mice was taken and injection of plastic hydrocarbon was given this will work as initiator in process the initiator work as:

A- Slow process will take time
B- Memory produce
C- It is last step in ccarcinogensis
D- Cause Clonal proliferation
Ans: B (Robins)

Explanation:

Initiators – All initiating chemical carcinogens are highly reactive electrophiles (have electron-deficient atoms) that can react with nucleophilic (electron-rich) sites in the cell. Their targets are DNA, RNA, and Protein. They cause permanent DNA damage and are rapid irreversible and has memory

Promoters – They don't have direct effect on DNA and cause Clonal proliferation of already initiated cells. They are reversible.

160- A man presented with generalized body swelling for two weeks. Physical examination shows thick waxy skin hepatomegaly and enlarge kidney. 24 h/urinary protein was 4g/day. Kidney biopsy shows apple colored birefringence fibril under congo red stain. What is diagnosis

A- Hepatitis
B- SLE
C- Malaria
D- TB
E- Multiple myeloma
Ans: E

161- Feature which differentiates full blown carcinoma from carcinoma in situ?

A- Metaplasia
B- Pleomorphism
C- Invasion to basement membrane
D- Mitotic activity
E- Chronicity
Ans: C

162- First step in beginning of cancer

A- Metaplasia
B- Pleomorphism
C- Invasion/degradtaion of ECM components of basement membrane
D- Mitotic activity
E- Chronicity
Ans: C

163- Patient has history of 60 packs cigarette smoking and develop mesothelioma risk factor for it is

A- Vinyl chloride
B- Asbestos
C- Nitrosamine
D- Hydrocarbon
E- Azo dye
Ans: B

164- If a cell is arrested in G1 phase and later developed uncontrollable mitotic activity what gene affected

A- BRAS
B- P53
C- KRAS
D- WT1
E- APC
Ans: B

165- A woman test positive for CA 125 it is tumor marker of which of these?

A- Breast CA
B- Lung CA
C- Liver CA
D- Ovarian CA
E- Pancreatic CA
Ans: D

166- Which one is important

A- Invasion
B- Pleomorphism
C- Increase n/c ratio
D- Dysplasia
E- Decrease n/c ratio
Ans: A

Explanation:

- Malignancy – Metastasis > Invasion of adjacent tissues > pleomorphism > increasead N/C ratio
- Grading – Nuclear differentiation / degree of differentiation / Mitosis
- Staging – Extent of spread / Lymph nodes involvement
- Pre-malignant lesion – Pleomorphism
- Diagnostic
- Pre-malignant condition – Increased N/C ratio Diagnostic

167- Lymph vessel involved in which on of following

A- Cavernous Hemangioma
B- Capillary Hemangioma
C- Angiodysplasia
D- Angiofibroma
Ans: A

168- Submucosal Fibrosis is

A- Metaplasia
B- Dysplasia
C- Pre-Malignant condition
D- Atrophy
E- Anaplastic chang
Ans: C

Explanation:

- Most Common Pre-malignant lesion – Leukoplakia
- Most Lethal Pre-malignant lesion – Erythroplakia
- Most Common Pre-malignant Condition - Submucosal Fibrosis
- Most Lethal Pre-malignant Condition – Lichen Planus

169. Peau'd orange appearance of breast occurs in malignancy of breast due to distortion of:

A- Lobules of Breast
B- Suspensory Ligaments of Breast
C- Tail of breast
D- Longitudinal Ligament of Breast
Ans: B

170. In Plastic Industry worker cause of Angiosarcoma is which of following

A- Arsenic
B- Vinyl chloride
C- Cadmium
D- Asbestosis
Ans: B

Explanation:

- Angiosarcoma in Plastic Factory Worker – Vinyl chloride
- Angiosarcoma in Farmer – Arsenic
- Plastic Factory Worker – Liver Angiosarcoma
- Plastic Factory worker + Smoking – Lung CA > Angiosarcoma

171- Common cause of mutation of proto – oncogene by exogenous substance is:

A- Virus
B- Ionizing radiation
C- Bacteria
D- Fungi
E- Metals
Ans: A

172- A 70 years non-smoker man presented with painless haematuria investigation reveals Urothelial CA bladder what is risk factor for CA bladder in him neoplasia

A- Aniline dye
B- Carbon
C- Vinyl chloride
D- Silica
E- Aflatoxin
Ans: A

173- Neoplasia has parenchyma and microenvironment, microenvironment has:

A- Stroma + inflammatory cells
B- Stroma + inflammatory cells + blood vessels
C- Stroma only
D- Endothelial cells
Ans: B

174- Carcinoma having genetic cause is:

A- Boil
B- Xeroderma pigmentosa
C- Congenital Nevus
D- Lichen Planus
Ans: B

175- Acoustic Neuroma is a tumour of:

A- Cochlear part of CN 8
B- Vestibular part of CN 8
C- Facial Nerve
D- Trigeminal nerve
Ans: B

176- In Steroid producing tumour which organelle will be involved?

A- Lysosome
B- Golgi body
C- Mitochondria
D- SER
Ans: D

CamScanner

177- Most useful technique used in screening of breast cancer is?
A- Self breast examination
B- Ultrasound of breast
C- Mammography
D- CT scan
Ans: C

178- Breast cancer in female metastasized to liver, peritoneum and pelvic organs route of metastasis:
A- Sub pleural lymphatic plexus
B- Sub peritoneal lymphatic plexus
C- Venous connections
D- Axillary lymph nodes
E- Arterial Thrombi
Ans: C

179- Proto oncogene is defined as
A- Abnormal gene cause cell proliferation
B- Abnormal gene cause cell Suppression
C- Normal gene cause cell proliferation
D- Normal gene cause cell Suppression
Ans: C

180- Carcinoma which first metastasized to bone:
A- Ovarian carcinoma
B- Lung carcinoma
C- Breast carcinoma
D- Prostatic Carcinoma
E- Thyroid carcinoma
Ans: D

181- The ectopic thyroid hormone is secreted by:
A- Small cell carcinoma of lung
B- Large cell carcinoma of lung
C- Carcinoid of lung
D- Adenocarcinoma of lung
E- Squamous cell carcinoma of larynx
Ans: E
Explanation:
- Small Cell CA – Smoking + Most aggressive + Ectopic ACTH (Cushing syndrome) + Lambert Eaton syndrome + SIADH.
- Squamous Cell CA – Smoking (Most commonly) + Hypercalcemia
- Ectopic thyroid produce by – Squamous Cell CA of Larynx

182- Which one is correct match?
A- CA Lung with Alcohol
B- CA liver with Asbestos
C- CA Skin with alcohol
D- CA liver with alcohol
Ans: D

183- Which is not oncogene and Cause gene amplification?
A- RET
B- HER 2
C- APC
D- Myc
Ans: C (FA)

184- Difference between malignant and normal cells such that malignant cells repair the shortening of chromosome so that they can continue dividing. Enzyme responsible?
A- Telomerase
B- Reverse transcriptase
C- Isomerase
D- Lipase
Ans: A

185- Carcinoma of cervix diagnosis by:
A- Capsule invasion
B- Invasion to basement membrane
C- Intact basement membrane
D- Increase E cadherin
Ans: B

186- Woman with breast cancer subsequently develop metastasis to vertebral column. The most direct route of spread of tumour to vertebral column is:
A- Internal thoracic veins
B- Axillary lymph nodes
C- Venous connections
D- Thoracic nodes
Ans: C

187- Only indication of use of radionuclide scan in a patient with developed and diagnosed thyroid carcinoma would be:
A- To see grades
B- For chemotherapy
C- To see cancer mets and spread
D- To see differentiation
Ans: C

188- Most common pancreatic carcinoma:
A- Adenoma
B- Cyst adenoma
C- Islet cell tumour
D- Cystic carcinoma
Ans: A

189- Posterior pituitary tumour causes which of these affect:
A- Anuria
B- Increase Aldosterone
C- Polyuria
D- Increase urine osmolality
Ans: C

190- After salpingo oophorectomy, for recurrence of tumour which marker is used:
A- CEA
B- CA 15- 3
C- CA 19- 9
D- AFP
E- CA 125
Ans: E

191- Benign tumour among the given is:
A- BCC
B- Ameloblastoma
C- Erythroplakia
D- Dysplastic nevus
E- Warthin tumour
Ans: E

192- A middle- aged man came back from Cairo & developed painless haematuria, what is the likely diagnosis?
A- Squamous cell carcinoma of the urinary bladder
B- Transitional cell carcinoma of the urinary bladder
C- Transitional cell carcinoma of the prostate
D- Squamous cell carcinoma of prostate
Ans: A (Cairo is the capital of Egypt and is endemic for schistosomiasis which causes SCC of the urinary bladder)

193- To know origin of neoplastic tissue which test used:
A- Flow Cytology
B- Immunohistochemistry
C- Gene assay
D- Gene drafting
Ans: B

194- Medullary CA proto-oncogene:
A- RAS
B- BCL2
C- RET
D- P53
Ans: C

195- Peau d orange appearance of breasts occurs in malignancy of breast due to:
A- Arterial obstruction
B- Venous + venous obstruction
C- Tumour invasion and Fibrosis
D- Fibrosis
Ans: B

196- Strontium 90 causes which of following
A- Adenoma
B- Dysplasia
C- Osteosarcoma
D- Fibroma
E- Fibrous dysplasia
Ans: C (Osteosarcoma > Leukemia)

197- Which one cause lung CA?
A- Asbestos
B- Radon
C- UV light
D- Silicon
Ans: B
Explanation:
- Smoking >Radon >Asbestos

198- Cervical carcinoma differs from benign lesion:
A- Invasion of basement membrane
B- Dysplasia
C- Pleomorphic
D- Mitosis
E- Decrease N/C Ratio
Ans: A

199- Most common cardiac tumor is:
A- Rhabdomyosarcoma
B- Leiomyoma
C- Myxoma
D- Angiosarcoma
Ans: C

200- Infection, Inflammation, Radiation cause injury by?
A- Reactive oxygen species
B- Oncogenes
C- Proto-Oncogenes
D- Deoxygenation
Ans: A

201- A male alcoholic and gutka eater develop non healing ulcer. He is prone to have
A- Adenocarcinoma
B- Squamous cell Carcinoma
C- Baretts esophagus
D- Erythroplakia
E- Sclerosing fibrosis
Ans: B

202- A patient with history of some type of cancer hemicolectomy done, having Dukes type B stage, you will follow up the case with the help of
A- Alpha feto protein
B- Human chorionic gonadotrophin
C- Carcinoembryonic antigen
D- BRCA
Ans: C

CamScanner

203- A young lady with breast cancer , having history of two sisters suffering from ovarian cancer. Which gene mutation is responsible
A- P53
B- BRCA 1
C- MSH 2
D- RAS
Ana: B

204- A female patient undergo radiotherapy of axilla due to Mets of breast Carcinoma. Now she is more prone to develop
A- Infection
B- Angiosarcoma
C- Metastatic CA
D- Abscess
Ans: B

205- In metastatic breast cancer sentinel lymph node biopsy helps in
A- Saving axilla during surgery
B- Confirm the ultimate prognosis of disease
C- To avoid metastasis
D- To know metastasis
Ans: A

206- In Malignancy of breast Nipple earliest lymph node to drain is
A- Internal mammary
B- Axillary
C- Apical
D- Intercostal
Ans: B

Explanation:
- Nipple drainge -- Ant. axillary (Pectoral)
- Upper lateral -- Ant. axillary mainly
- Lower lateral(Inferior) -- Ant. axillary + Sub diaphragmatic + Internal mammary.
- Medial Quadrant -- Mainly to Internal mammary (Internal thoracic)
- Lower Inner Medial Quadrant – Inferior Phrenic (Sub Diaphragmatic)
- Tail of Breast – Posterior (Scapular) Lymph Node

207- Which of the following is true regarding Increased N/C ratio?
A- Abnormal DNA production
B- Increased DNA production
C- Abnormal RNA production
D- Increased RNA production
E- Actinic keratosis
Ans: A

208- Premalignant condition predisposing to the development of Skin Cancer is:
A- Nitrosamine
B- Xeroderma pigmentosum
C- Congenital Navus
A- Lichen Planus
Ans: B

209- Hydrocarbon was given, this will work as initiator in process, the initiator work as:
A- Slow process will take time
B- DNA Damage
C- It is last step in carcinogensis
D- Cause Clonal proliferation
Ans: B

210- A group of mice was taken and injection of plastic hydrocarbon was given this will work as initiator in process the initiator work as:
A- Slow process will take time
B- Permanent DNA damage
C- It is last step in carcinogensis
D- Cause Clonal proliferation
Ans: B (Robins)

211- Common Tumor Suppressor gene is:
A- BRCA
B- RET
C- P53
D- BCL
E- WT1
Ans: C

212- Food which causes a decrease in risk of cancer
A- Chocolate bonbons
B- Smoked meat
C- Apples
D- Orange
Ans: A

213- Protooncogenes are:
A- Normal genes for DNA
B- Normal genes controlling cell growth
C- Abnormal DNA
D- Functional genes
E- Normal RNA
Ans: B
Better

214- Endometrial Ca spread least likely via which route?
A- Vascular
B- Peritoneal
C- Lymphatics
D- Direct myometrium invasion
Ans: A

215- After B/L salpingo oophorectomy and total abdominal hysterectomy, forrecurrence of tumour which marker is used:
CEA
A- CA 15- 3
B- CA 19- 9
C- AFP
D- CA 125
E-
Ans: E

216 Tumour with good prognosis and curable is:
Germ cell
A- Gastric
B- AML
C- Ovarian
D-
Ans: B

217- DNA repair gene prevent cancer. Defective repair causes Cancer due to:
A- Gain of mutation
B- Loss of mutations
C- Gene amplification
D- OverExpression of Genes
Ans: A

218- Cutaneous lesions of sarcoma can be easily diagnosed by?
A- Vascularity
B- Invasion to basement membrane
C- Lymph node
D- Pleomorphism
Ans: A

219- What is the best approach for ca cervix in situ?
A- Pap smear
B- Colposcopy
C- Biopsy
D- USG
Ans: C

220- Which of the following causes alteration in oncongene?
A- Virus
B- Bacteria
C- Fungus
D- Radiations
Ans: A

Explanation:
Virus cause malignancy by
- Alteration in protein synthesis
- Alteration in proto – oncogene
- Have /By Using– Oncogene

Radiation cause malignancy by
- They Have Proto oncogene
- By ProducingFree radicals

221- A 70 year old lady admitted with complain of irregular bleeding and pain on investigation it was diagnosed as case of endometrial cancer is associated with which of following inherited cancer?
A- BRCA 1
B- CA 125
C- HNPCC
D- Breast cancer
E- APC
Ans: C (FA)

222- Most common cancer in Pakistan:
A- Lung Cancer
B- Oral Cancer
C- Breast Cancer
D- Hepatocellular Carcinoma
E- Bladder Carcinoma
Ans: B

223- Programed cell death is related to
A- Degenaration
B- Necrosis
C- Aplsia
D- Apoptosis
E- Gangrene
Ans: D

224- UV radiation poses to risk of:
A- Cataract
B- Skin cancer
C- Teratogenesis
D- Bladder Ca
Ans: B

225- A person has mass on Forehead revealing Mature adipocytes on histology. Most probably it is:
A- Lipoma
B- Adenoma
C- Squamous Cell carcinoma
D- Melanoma
Ans: A

226- Most common cancer in men overall worldwide:
A- Prostate
B- Lungs
C- Kidney
D- Liver
E- Blood
Ans: A

227- Which of the following is the most common cancer in Pakistan affecting both males and females?
A- Lung
B- Breast
C- Ovary
D- Liver
Ans: A

CamScanner

228- In Dividing cell Chromosome defect cancer cause increase production of cell which enzyme is related to this?
A. Telomerase.
B. 5- transcriptase.
C. DNA polymerase.
D- Helicase
E- Topoisomerase
Ans: A

229- Which of the following is a cancer risk-reducing food:
A- Smoked meat
B- Orange
C- Chocolate
D- Rum
E- Cheese
Ans: B

230- Most common locally malignant carcinoma:
A- Ameloblastoma
B- Warthin tumour
C- Squamous cell CA
D- Basal cell CA
Ans: D>A

231- Crusted lesion on nose since 7 months but not healing:
A- BCC
B- SCC
C- HCC
D- RCC
Ans: A

232- A 60 years old patient came with enlarged spleen. Multiple lymph nodes in body was swollen. On peripheral smear there was cancer cells on lymph node biopsy what will be seen
A- Mixed mature and immature cells
B- Sheets of plasma cells
C- Sheets of lymph nodes
D- Granuloma
Ans: A

233- Programed cell death is related to
A- Degenaration
B- Necrosis
C- Aplsia
D- Apoptosis
E- Gangrene
Ans: D

234- Gene mutated in female leading to Ca ovary which other organ at risk of developing Carcinoma
A- Breast
B- Colon
C- Stomach
D- Kidney
Ans: A

235- Leading Cause of Death due to Cancers in Men Worldwide:
A- Prostate Cancer
B- Lung Cancer
C- Colorectal Cancer
D- Hepatocellular Cancer
E- Oral Cancer
Ans: B

236- Most common Cancer overall in both genders?
A- Lung Carcinoma
B- Oral Carcinoma
C- Breast Carcinoma
D- Hepatocellular Carcinoma
E- Colorectal Carcinoma
Ans: A

237- Patient HCV+, Presented To OPD with complains of Lethargy, Malaise & Weight loss. .Fibrosis & Centrilobular cells involving hepatic sinusoids seen on morphology. HCC Tumor marker is which of the following?
A- AFP
B- CEA
C- CA 19-9
D- CA 125
Ans: A

238- A group of mice was taken and injection of plastic hydrocarbon was given this will work as promotor in process. Promotors cause cancer by enhancing.
A- Cell initiation
B- Enhancing cell proliferation
C- Clonal proliferation
D- DNA Damage
Ans: B (Robins)

Explanation:
- **Initiators** – All initiating chemical carcinogens are highly reactive electrophiles (have electron- deficient atoms) that can react with nucleophilic (electron- rich) sites in the cell. Their targets are DNA, RNA, and Protein. They cause permanent DNA damage and are rapid irreversible and has memory
- **Promoters** – They don't have direct effect on DNA and cause Clonal proliferation of already initiated cells. They are reversible. Increased cell proliferation

239- A patient is scheduled for Cancer Radiotherapy. Which radiation intensity can cause severe GIT symptoms during radiotherapy of Cancer?
A- 10 cGy
B- 100 cGy
C- 1000 cGy
D- 10,000 cGy
Ans: C

240- A female patient with multiple sexual partners has been exposed to the HPV virus. Microscopy reveals atypical cells. If left untreated, she is at risk of developing which of the following conditions?
A- Adenocarcinoma
B- Squamous cell carcinoma
C- Basal Cell Carcinoma
D- Endometrial Carcinoma
Ans: B

241- Patient has Non- healing Ulcer in mouth for 4 months. He has Gutka history for 20 years. Doctor confirms a malignancy after tests. What is the most common malignancy in this case?
A- Adenocarcinoma
B- Squamous cell carcinoma
C- Chronic ulcer
D- Leukoplakia
Ans: B

242- Grade 3 Carcinoma
A- 50-60% dysplasia
B- 50% dysplasia
C- 90% dysplasia
D- 50-75% dysplasia
Ans: D

243- 2 Years Child presented with painless Swelling in testicular region. He underwent left orchiectomy. Specimen sent for Biopsy which showed Cuboidal Cells eosinophilic in nature, Non specific immature tuboidal glands with thin sheaths & glomeruloid structure. Diagnosis?
A- Yolk sac tumor
B- Teratoma
C- Seminoma
D- Dysgerminoma
E- Leydig Cell Tumour
Ans: A(Robins)

Explanation:
- Yolk sac tumors are the most common primary testicular neoplasm in children younger than 3 years of age.
- Histologic examination discloses low cuboidal to columnar epithelial cells forming microcysts,lacelike (reticular) patterns, sheets, glands, and papillae.
- A distinctive feature is the presence of structures **resembling primitive glomeruli**, the so- called Schiller-Duvall bodies.
Tumors often have eosinophilic hyaline globules

244- A young female patient presents with palpable lymph nodes on the left side of her neck, weight loss and left sided gastric mass which of the following is your diagnosis
A- Tuberculosis
B- Lymphoma
C- Gastric cancer
D- Mesentric cyst
E- Gastro-intestinal stromal tumor
Ans: C

245- A 45-year-old female patient presents with a confirmed diagnosis of invasive breast carcinoma. Clinical evaluation and imaging reveal involvement of four distinct lymph node sites, with significant progression of the disease. The malignancy has reached a state of maximal growth, which of the following stage of breast canc er according to Manchester system
A- Stage 2A
B- Stage 3B
C- Stage 4
D- Stage 1
E- stage 3C
Ans: C(Short text book of surgery)

Explanation:
- Staging of breast carcinoma according to Manchester system

Stage I
- Growth confined to breast

Stage II
- Growth confined to breast
- Affected mobile lymph nodes in ipsilateral axilla

Stage III
- Skin involvement or paeu d' orange larger than tumor but still limited to breast
- Tumor fixed to pectoral muscle but not to chest wall
- Ipsilataral axillary lymph nodes ,matted together or fixed to chest wall or ipsilateral supraclavicular nodes mobile or fixed or oedema of arm

CamScanner

Stage IV
- Wide skin involvement of breast
- Complete fixation of tumour to chest wall
- Distant metastasis

246- Which of the following is the stage of breast tumour if (TNM) of tumour is T3 N2 M0 is
A- Stage 3 A
B- Stage 2 A
C- Stage 2 B
D- Stage 1
Ans: A

247- A female patient presents in Surgical OPD presents with breast mass FNAC was performed which shows ductal cells with loss of polarity and adhesion, few RBCs and lymphocytes was present which of the following is ur diagnosis
A- Fibroadenoma
B- Ductal carcinoma
C- Fibrocystic disease
D- Galactocele
E- Papilloma
Ans: B

248- An antenatal female patient is diagnosed with severe cervical dysplasia. What should be the next step in management?
A- Cone sampling
B- Pap smear
C- Terminate pregnancy
D- Wedge biopsy
E- Pressure Biopsy
Ans: A

249- Virus cause cancer by
A- DNA
B- RNA
C- Alteration in Protein synthesis
D- Proto-oncogene
Ans: C

250- young adult received crush injury to his foot which became infected and necrosed for which BKA (below knee amputation. was carried out. Six months after the amputation, the patient developed a tender Haphazard bundles of nerves(nodule) with pain at the site of amputation. The nodule most likely is:
A- Ganglioma
B- Ganglio nueroma
C- Hamartoma
D- Neuroma
E- Naveus
Ans: D

251- The type of blood vessels commonly found in rabdomyosarcoma
A- Continous capillaries
B- Discontinous capillaries
C- Sheathed capillaries
D- Fenestrated capillaries
E- Lymphatics vessels
Ans: B

252- Dysplasia is seen in which of the following tumour
A- Epithelial tumour
B- Leiomyoma
C- Cytsadenoma
D- Lipoma
Ans: A

253- Retinoblastoma is the tumor that primarily effects which of the following
A- Eye
B- Brain
C- Bone
D- Liver
E- Lungs
Ans: A

254- A 35 year old male patient presents ion OPD with non healing ulcer in mouth diagnosed as a case of SCC which of the following is potential risk factor for oral cancer
A- Alcohol
B- Smoking
C- Age
D- Male gender
E- Unhealthy diet
Ans: B

255- Which of the following is responsible for causing cancer
A- Asbestos
B- Cotton dust
C- Sugar cane dust
D- Coal dust
E- Silica
Ans: A

256- Radiation exposure in Bone scan is equal to how many chest x-rays
A- 50
B- 100
C- 200
D- 300
E- 150
Ans: D
Explanation:
- Bone Scan radiation – 3-5 millisieverts
- One x-ray radiation – 0.01 millisieverts

So
- 300 x-ray = 0.01 x300 = 3 millisieverts

257- Most common occupational cancer:
A- Lung
B- Bladder
C- Skin
D- Prostate
Ans: A

258- Which of the following is fast spreading among the following?
A- Melanoma
B- Squamous Cell Carcinoma
C- Ambleoblastoma
D- Adenoid cystic carcinoma
E- Hemartoma
Ans: A

259- Which of the following is a key characteristic of apoptosis?(Medicine Feb 2025)
A- Ladder pattern DNA fragmentation
B- Increased intracellular calcium
C- Cell membrane damage
D- Cell shrinkage)
Ans: A

260- Paget's disease of the breast is most commonly associated with which underlying condition?(Medicine Feb 2025)
A- Lobular carcinoma in situ (LCIS)
B- Invasive ductal carcinoma
C- Ductal carcinoma in situ (DCIS)
D- Invasive lobular carcinoma
Ans: C

261- Which type of tumor has the highest tendency for malignant adenocarcinoma transformation?(Medicine Feb 2025)
A- Tubular adenoma
B- Hamartomatous
C- Villous adenoma
D- Serrated
Ans: C

262- A woman presents with a parotid gland swelling, and a diagnosis of pleomorphic adenoma is confirmed. Which classification best describes a pleomorphic adenoma origin? (Medicine Feb 2025)
A- Mixed tumor
B- Epithelial tumor
C- Malignant tumor
D- Connective tissue tumor
E- Benign tumor
Ans: A

263- A female patient is diagnosed with ovarian carcinoma, and an ascitic tap reveals the presence of malignant cells. What is the most likely route of spread? (Surgery Feb 2025)
A- Hematogenous
B- Seeding to the cavities
C- Lymphatic
D- Direct extension
E- Local Spread
Ans: B(Ten teachers gynae obs)
Explanation:
- Metastatic spread is by **direct spread** to peritoneum and other organs and by lymphatic spread to pelvic and para-aortic nodes.
- A high percentage of women with advanced disease have evidence of peritoneal disease on the diaphragmatic peritoneum

264- Which of the following is true about basal cell carcinoma(Surgery Feb 2025)
A- Tumour like growth
B- Local malignant tumour
C- Spread in whole body
D- Harmless tumour
E- Highly contagious
Ans: B

265- Choriocarcinoma spreads predominately via: (Gynae & Obs Feb 2025)
A- Lymphatics
B- Direct invasion
C- Blood
D- Peritoneal seeding
E- ranscoelomic
Ans: C

266- Genitourinary TB spreads via: (Gynae & Obs Feb 2025)
A- Direct extension
B- Lymphatics
C- Ascending infection
D- Hematogenous
Ans: D

267- A 30 year old female is diagnosed with a case of cervical dyskaryosis is best managed by which of the following?(Gynae & Obs Feb 2025)
A- Observation only
B- Colposcopy and biopsy
C- Hysterectomy
D- Excision of effected region
Ans: B

CamScanner

GENETICS QUICK HINTS

Codominance

- ✓ Both alleles contribute to the phenotype of the heterozygote.
- ✓ Examples:Blood groups A, B, AB; α1-antitrypsin deficiency; HLA groups.

Mosaicism

- ✓ Presence of genetically distinct cell lines in the same individual.

Imprinting

- ✓ One gene copy is silenced by methylation, and only the other copy is expressed
- ✓ Lead to parent-of-origin effects.

Prader-Willi syndrome

- ✓ Maternally derived genes are silenced
- ✓ Disease occurs when the paternal allele is deleted or mutated
- ✓ Hyperphagia, obesity, intellectual disability, hypogonadism and hypotonia , Behavioural problems in adolescence.
- ✓ Chromosome 15q 11-13 of paternal origin

Angelman Syndrome

- ✓ Paternally derived UBE3A is silenced
- ✓ Disease occurs when the maternal allele is deleted or mutated
- ✓ Seizures, Ataxia, severe Intellectual disability, inappropriate Laughter
- ✓ UBE3A on maternal copy of chromosome 15

Autosomal Dominant

- ✓ Incomplete Penetrance
- ✓ Heterozygous affected
- ✓ 1/2 of children affected.

Autosomal Recessive

- ✓ ¼ of children will be affected (homozygous),
- ✓ ½ of children will be carriers
- ✓ ¼ of children will be neither affected nor carriers.
- ✓ Increase risk in consanguineous families
- ✓ More Severe than Autosomal dominant

X Linked Recessive

- ✓ Sons of heterozygous mothers have a 50% chance of being affected
- ✓ No male-to-male transmission
- ✓ Skips generations
- ✓ Examples: Agammaglobulinemia, Bucker's dystrophy. Chronic granulomatous disease, Duchene muscular dystrophy, eye blindness (blue, green), Fabry's disease , Hemophilia A and B.

X linked Dominant

- ✓ Transmitted through both parents.
- ✓ Mothers transmit to 50% of daughters and sons
- ✓ Fathers transmit to all daughters but no sons.
- ✓ Examples: fragile X syndrome, Alport syndrome, hypophosphatemic rickets, Rett disease

Mitochondrial inheritance

- ✓ Transmitted only through the mother
- ✓ Mitochondrial myopathies—rare disorders.

- ✓ often present with myopathy, lactic acidosis, and CNS disease, eg, MELAS syndrome(Red **Ragged fibers)**
- ✓ Leber hereditary optic neuropathy (LHON— cell death in optic nerve neurons

Muscular dystrophies

Duchenne

- ✓ X-linked recessive disorder typically due to frameshift deletions or nonsense mutations (truncated or absent dystrophin protein)
- ✓ Pseudohypertrophy of calf muscles
- ✓ Waddling gait
- ✓ Onset before 5 years of age.
- ✓ Dilated cardiomyopathy is common cause of death
- ✓ **Gowers sign**—patient uses upper extremities to help stand up. Classically seen in Duchenne muscular dystrophy, but also seen in other muscular dystrophies (e.g polymyositis).

Becker

- ✓ X-linked recessive disorder typically due to non-frameshift deletions in dystrophin gene (partially functional instead of truncated).
- ✓ Onset in adolescence or early adulthood

Trinucleotide repeat expansion diseases

Huntington

- ✓ CAG Repeat and Autosommal dominant(AD)
- ✓ Myotonic dystrophy
- ✓ CTG Repeat and AD
- ✓ Cataract , Early balding and gonadal atrophy

Fragile X

- ✓ CGG Repeat and X Dominant
- ✓ Chin Protruding and Giant Gonads

Friedreich ataxia

- ✓ GAA Repeat and AR and Ataxic Gait

Trisomy

Down syndrome (trisomy 21)

- ✓ Findings: intellectual disability, flat facies, **prominent epicanthal folds**, **single palmar crease**, incurved 5th finger, gap between 1st 2 toes, duodenal atresia, Hirschsprung disease, Brushfield spots , Umbilical hernia

The 5 A's of Down syndrome:

1. Advanced maternal age
2. Atresia (duodenal)
3. Atrioventricular septal defect
4. Alzheimer disease (early onset)
5. AML/ALL

- ✓ 95% of cases due to meiotic nondisjunction, most commonly during meiosis I
- ✓ 4% of cases due to unbalanced Robertsonian translocation (Ch14 and 21)
- ✓ Only 1% of cases are due to postfertilization mitotic error.
- ✓ Increase Beta HCG and Inhibin
- ✓ Decrease AFP , Estriol and PAPP-A
- ✓ Increase nuchal translucency and hypoplastic nasal bone

Edwards syndrome (trisomy 18)

- Findings: **PRINCE Edward**—Prominent occiput, **R**ocker-bottom feet, **I**ntellectual disability, **N**ondisjunction, Clenched fists with overlapping fingers, low-set **E**ars, **micrognathia (small jaw)**, congenital heart disease, omphalocele, myelomeningocele. Death usually occurs by age 1.

CamScanner

Patau syndrome (trisomy 13)

- ✓ Findings: severe intellectual disability, rocker- bottom [illegible], microcephaly, cleft lip/palate, holoprosencephaly, polydactyly, cutis aplasia, congenital heart (pump) disease, polycystic kidney disease, omphalocele. Death usually occurs by age 1.

Cri-du-chat syndrome

- ✓ Congenital deletion on short arm of chromosome 5 (46,XX or XY, 5p−).
- ✓ Findings: microcephaly, moderate to severe intellectual disability, high-pitched crying, epicanthal folds, cardiac abnormalities(VSD)

Note

- ✓ Most common Inherited cause Intellectual disability – Fragile X Syndrome
- ✓ Most common Genetic cause Intellectual disability – Down Syndrome
- ✓ 2nd Common Genetic cause Intellectual disability – Fragile X Syndrome

Turner Syndrome

- ✓ 45XO or 44XO
- ✓ Short stature , Webbed neck and wide spaced nipple , Lymphedema in feet (Hand edema) and primary amonorrhea
- ✓ Streak ovaries prominent feature
- ✓ Permanent monosomy of C chromosome
- ✓ Hemizygous X chromosome
- ✓ Associated with Cystic hydroma
- ✓ Associated with Stunted growth ,horseshoe kidney, high-arched palate, shortened 4th metacarpals
- ✓ Bicuspid aortic valve, coarctation of the aorta (femoral < brachial pulse),
- ✓ No Bar body

Klinefelter syndrome

- ✓ Male, 47,XXY.
- ✓ Testicular atrophy, eunuchoid body shape, tall, long extremities, gynecomastia, female hair distribution
- ✓ Presence of inactivated X chromosome (Barr body).
- ✓ **Dysgenesis of seminiferous tubules** -Decrease inhibin B leas to increase FSH.
- ✓ **Abnormal Leydig cell function** -Decrease testosterone result in increase LH and estrogen

Other disorders

Kallman's syndrome

- Failure to complete puberty; a form of hypogonadotropic hypogonadism. Defective migration of neurons and subsequent failure of olfactory bulbs to develop so synthesis of dec GnRH in the hypothalamus
- Hyposmia/anosmia
- Dec GnRH, FSH, LH, testosterone
- Infertility (low sperm count) in males; amenorrhea in females

Fragile X disease

- X-linked dominant inheritance
- Trinucleotide repeat expansion [(CGG)n] occurs during oogenesis
- Premutation (50-200 repeats) tremor, ataxia, 1° ovarian insufficiency.
- Full mutation (>200 repeats) post pubertal machrochoridism (enlarged testes), long face with large jaw, large everted ears, autism, mitral valve prolapse, hypermobile joints.
- Self-mutilation is common

Autosomal dominant diseases

Achondroplasia, autosomal dominant polycystic kidney disease, familial adenomatous polyposis, familial hypercholesterolemia, hereditary hemorrhagic telangiectasia (Osler-Weber-Rendu syndrome), hereditary spherocytosis, Huntington disease, Li-Fraumeni syndrome, Marfan syndrome, multiple endocrine neoplasias, myotonic muscular dystrophy, neurofibromatosis type 1 (von Recklinghausen disease), neurofibromatosis type 2, tuberous sclerosis, von Hippel-Lindau disease.

Autosomal recessive diseases

Oculocutaneous albinism, autosomal recessive polycystic kidney disease (ARPKD), cystic fibrosis, Friedreich ataxia, glycogen storage diseases, hemochromatosis, Kartagener syndrome, mucopolysaccharidoses (except Hunter syndrome), phenylketonuria, sickle cell anemia, sphingolipidoses (except Fabry disease), thalassemias, Wilson disease

CamScanner

GENETICS

1. Which of the following disorder has repeated sequence of trinucleotides?
A. Downs syndrome
B. Turner syndrom
C. Fragile X syndrom
D. Digorge syndrome
Ans: C (First aid)

Explanation:
- Huntington –CAG and Autosommal dominant
- Myotonic dystrophy – CTG and AD
- Fragile X – CGG and X Dominant
- Friedreich ataxia – GAA and AR

2. Color blindness person can't differentiate between green and red?
A- Hemianopia
B- Quadrianopia
C- Deutranopia
D- Heteroanopia
Ans: C

Explanation:
- Can't differentiate Between Red and green - Protonopia
- Can't differentiate Between Green and red – Deutronopia

3. Mode of inheritance of defective genes involved in DNA repair:
A- X linked
B- Autosomal recessive
C- Autosomal dominant
D- X – link recessive
Ans: B

4. Marfan syndrome defective protein:
A- Fibrillin
B- Elastin
C- Collagen
D- Albumin
Ans: A

5. Turner syndrome karyotype is:
A- 45XX
B- 46X0
C- 45XO
D- 47XXY
Ans: C

Explanation:
- Turner syndrome: 45XO
- Klinefelter's syndrome: 47XXY

6. Regarding barr bodies which are incorrect?
A- Are inactive completely
B- Heterochromatin
C- X chromosome
D- Buccal smear
Ans: A

Explanation:
Regarding barr bodies
- Heterochromatin.
- Have X chromosome.
- Seen under light microscope.
- Absent in turner
- Scanty barr bodies in Klinefelter's
- 1barrbody inklinefelter's
- Ox - nobarrbody.
- Xx- 1barrbody.
- Xxx - 2barrbodies.

7. Klinefelter karyotype is:
A- 45XX
B- 47XXY
C- 46XX
D- 46XY
Ans: B

8. Most commmon congenital syndrome is:
A- Down syndrome
B- Fragile x syndrome
C- Turner syndrome
D- Klinefelter syndrome
Ans: A

Explanation:
- Most common congenital syndrome: Down
- Most common sex chromosomal abnormality :klinfilter's

9. Female Patient had aortic root dilation upto 4cm, ocular examination showed lens dislocation. mitral valve leaflet defect with a systolic click defect in which of the following?
A- Spectrin
B- Dystrophin
C- Laminin
D- Fibrillin
Ans: D (Marfan syndrome)

10. A patient presents with chorea, mental retardation, the disease has autosomal dominant inheritance is
A- Huntingtons disease
B- Sydenham chorea
C- Alzheimer's disease
D- Fragile X
Ans: A

11. Technique use to detected abnormality and microdeletion in chromosomes:
A- PCR
B- Microassay
C- Cytogenic abnormality
D- FISH
Ans: D

Explanation:
FISH used for – Localization of genes and its abnormality such as Microdeletion and Translocation
Microarray used for – Gene expression

12. Marfan syndrome gene defect located on which chromosome?
A- 22
B- 15
C- 17
D- 21
Ans: B

13. Mentally retarded 14-year-old boy has a microcephalic and low ear Epicanthal fold and protuberance of tongue Chromosome analysis is likely to demonstrate which of the following?
A- Trisomy 21
B- Trisomy 18
C- Trisomy 13
D- Fragile X syndrome
Ans: A

14. Patient with short stature and webbed neck lymphedema chromosomes sequence:
A- 44xo
B- 44xx
C- 47xxy
D- 46xx
Ans: A (45XO was not in options)

15. One bar body is present:
A- Down syndrome
B- Normal female
C- Turner syndrome
D- Patau syndrome
Ans: B

Explanation:
- One bar body – Normal Female >Klinfilter
- Scanty or absent bar body – Turner

16. A low birth weight baby is born having low line ears, small jaw, microcephaly, Cleft lip and prominent occiput type of trisomy:
A- Trisomy 21
B- Trisomy 11
C- Trisomy 18
D- Trisomy 13
Ans: C

17. Most common cause of sex chromosome abnormality:
A- Hermaphrodite
B- Klinefilter syndrome
C- Down syndrome
D- Multi X female
Ans: B

Explanation:
- Most common congenital syndrome: Down
- Most common sex chromosomal abnormality :klinfilter's

18. Most common pattern of genetic disease:
A- Multifactorial
B- Autosomal dominant
C- Autosomal Recessive
D- X link Recessive
Ans: A

19. Cystic hygroma seen in:
A- Down Syndrome
B- Klinfilter Syndrome
C- Turner Syndrome
D- Edward Syndrome
Ans: C

20. Which is autosomal dominant disorder?
A. Retinoblastoma
B. G6PD disease
C. Gastric ca
D. Alport syndrome
E. Thalessemia
Ans A

Explanation:
- **Retinoblastoma**- autosomal dominant
- **G6PD** - X linked recessive
- **Alport syndrome**- X linked dominant
- **Thalessemia**- Autosomal recessive

21. Patient presents with chorea, mental retardation, depression and memory lapse the mode of inheritance of this disease is:
A. X Link Recessive
B. X Link Dominant
C. Autosomal Recessive
D. Multifactorial
E. Autosomal Dominant
Ans: E (Huntington disease)

Explanation:
Clinical features of Huntigton's disease
- Involuntary jerking or writhing movements (chorea)
- Muscle problems, such as rigidity or muscle contracture (dystonia)
- Slow or abnormal eye movements
- Impaired gait, posture and balance
- Difficulty with speech or swallowing

CamScanner

22. Musculoskeletal growth occurs in which of the following genetic disease?
A- Klinfilter syndrome
B- Achondroplasia
C- Down syndrome
D- Turner syndrome
E- Edward syndrome
Ans: B

23. When both allele are fully expressed in heterozygote called?
A. Codominance
B. Transduction
C. Polymorphisms
D. Reduce penetrance
E. Variable expressivity
Ans: A

24. What is the inheritance pattern of hemophilia A?
A. X linked dominant
B. Autosomal Dominant
C. X linked recessive
D. Autosomal recessive
E. X linked dominant
Ans: C

Explanation:
X linked recessive disorders mnemonic ABCDEFGH
A- Agammaglobulinemia
B- Bucker's dystrophy
C- Chronic granulomatous disease
D- duchene muscular dystrophy
E- eye (eye blindness)
F- Fabry's disease
G- G6PD
H- Hemophilia A and B

25. Early Adolescents with a prominent forehead, everted looking ears and long longitudinal mandible and hypergonadism is clinically diagnostic of:
A- Down syndrome
B- Turner syndrome
C- Fragile X syndrome
D- Klinfilter syndrome
E- Patau syndrome
Ans: C

Explanation:
Fragile X syndrome features
- Postpubertalacroorchidism (enlarged testes),
- long face
- large jaw,
- Large everted ears,
- Autism,
- mitral valve prolapse
- permobile joints.
- Self-mutilation
- Hypotomia

26. In autosomal dominant genetic defect if phenotypically it is not expressed, pattern is:
A- Pleotropy
B- Reduced penetrance
C- Variable expressivity
D- Codominance
E- Sickle cell anemia
Ans: B

27. Most common autosomal dominant disease
A- Von Willebrand disease
B- Reinoblastoma
C- Huntigton's disease
D- Achondroplasia
E- Marfan's syndrome
Ans A

Explanation:
- Most common autosomal dominant - Von - willebrand disease
- Most common autosomal recessive - hemochromatosis

28. Most common cause of inherited intellectual disability:
A- Down syndrome
B- Fragile X syndrome
C- Edward Syndrome
D- Patau Syndrome
Ans: B (FA)

Explanation:
- Most common Inherited cause – Fragile X Syndrome
- Most common Genetic cause – Down Syndrome
- 2nd Common Genetic cause – Fragile X Syndrome

29. Genetic Analysis done with:
A. CVS
B. Amniotic Fluid Analysis
C. USG
D. Doppler
Ans: B

30. Down syndrome is trisomy:
A- 21
B- 18
C- 13
D- 14
Ans: A

Explanation:
- Down Syndrome: Trisomy 21
- Klienfilter Syndrome: Trisomy 18
- Patau Syndrome: Trisomy 13

31. Gynaecomastia is caused by:
A. Klienfilter syndrome
B. Down syndrome
C. Edward Syndrome
D. Patau Syndrome
Ans: A

Explanation:
Klinefelter's syndrome features
- Testicular atrophy (small, firm testes)
- Tall tature with eunuchoid proportions
- (delayed epiphyseal closure long bone length)
- Gynecomastia
- Female hair distribution may present with
- developmental delay.
- Presence of inactivated X chromosome
- (Barr body).
- Common cause of hypogonadism seen in
- infertility workup.
- Risk of breast cancer.

32. About Huntington's disease:
A. 50% children affected
B. Only female affected
C. Only Male affected
D. 1/3rd of children affected
Ans: A

33. Which of the following isn't true regarding G6PD deficiency?
A- X-Linked Disease
B- Rarely affect male
C- Protects against P.Falciparum
D- Genetic disorder
Ans: B

Explanation:
- G6PD is a genetic disorder that's X-Linked & commonly affects male & is protective against P. Falciparum.

34. A child died of some renal problem that showed multiple cysts on autopsy what is the mood of inheritance:
A- Autosomal Recessive
B- Autosomal Dominant
C- X Linked Recessive
D- X Linked Dominant
Ans: A

35. XXY is seen in
A- Down Syndrome
B- Klinefelter syndrome
C- Edward Syndrome
D- Patau Syndrome
Ans: B

36. Which of the following is part of triple screening?
A- Estriol
B- Estrone
C- Estradiol
D- Progesterone
Ans A

Explanation:
- Estriol in triple screening & after marriage
- Estrone in post-menopausal
- Estradiol in premenopausal just engaged

37. An adult male died with having multiple cysts on autopsy of kidneys, what is the mode of inheritance of the disease?
A- Autosomal dominant
B- Autosomal Recessive
C- X-Linked Dominant
D- X-Linked Recessive
Ans: A

Explanation:
Polycystic kidney disease is autosomal recessive in children & autosomal dominant in elders.

38. Which of the following is the karotype of true hermaphrodite?
A- XX
B- XY
C- XXY
D- XYY
Ans: A

Explanation:
XX > XX/XY > XXY

39. A person exhibiting an extra chromosome in his genes instead of normal two:
A- Trisomy
B- Triploids
C- Klinefelter Syndrome
D- Turner Syndrome
Ans: A

40. In autosomal dominant:
A- Both male and female are involved
B- Only male is involved
C- Only female is involved
D- Affects only male children
Ans: A

41. Concept of mother transmitting genetical disease via DNA of:
A- Nucleus
B- Mitochondria
C- Golgi body
D- Nucleolus
Ans: B

42. Snow storm appearance is related to which of the following?
A- Down Syndrome

CamScanner

B- Complete mole
C- Adrenogenital syndrome
D- Partial mole
Ans: B

43. Inherited form of endometrial carcinoma is associated with:
A- BRCA
B- Breast Cancer
C- HNPPC
D- CA-125
Ans: C
Explanation:
DNA mismatch repair causes colon, endometrial & ovarian cancer called cancer syndrome.

44. Offspring have 50% chances of developing disease and there's no carrier:
A- Autosomal dominant
B- Autosomal recessive
C- X linked recessive
D- X linked dominant
Ans: A

45. In down syndrome robersonian translocation transmits in how much percentage of next generation:
A- 15%
B- 50%
C- 33%
D- 80%
Ans: C

46. What is codominance?
A. A dominant gene will overpower all other genes to be the only one
B. One is recessive and other gene is dominant
C. Where two different traits are both expressed alongside each other
D. None
Ans: C

47. Duchene muscular destroy is due to deficiency of:
A. Amino acid
B. Dystrophin
C. Tyrosine
D. Spectrin
E. Myosin
Ans: B

48. A young lady presented in OPD with primary amenorrhea. On examination breast is present but uterus is absent and blind vagina. What is karyotype?
A- XYY
C- XY
D- XXY
Ans: C

49. A young boy presented with enlarged genitals, early pubic hair appearance, excessive body hair and rapid growth. What is Cause?
A- Acromegaly
B- Prolactinoma
C- Turner Syndrome
D- Adrenogenital syndrome
E- Klinefelter Syndrome
Ans: D

50. Barr body diagnostic for:
A- Down syndrome
B- Turner syndrome
C- Kline filter syndrome
D- Fragile X syndrome
Ans: B

51. A child born with genetically male but external appearance of genitals are like female what's is diagnosis?
A- Testicular feminization syndrome
B- Down syndrome
C- Klinefilter
D- Turner syndrome
Ans: A

52. In a pregnant lady, to diagnose open neural tube defect early which one of the following is used?
A- Chorionic villus sampling
B- Amniocentesis
C- Ultrasound
D- XRAY
E- CT Scan
Ans: C

53. Hypertelorism, oblique palpebral fissure seen in
A- Down
B- Turner
C- Klienfelter
D- Fragile X syndrome
Ans: A

54. A child present with occular anomalies, corneal defect, lens prolapsed. Diagnosis?
A- Potter syndrome
B- Trisomy 21
C- Trisomy 13
D- Trisomy 18
Ans: A

55. XX pseudohermaphrodite is
A- Adrenogenital syndrome
[illegible] syndrome
C- Turner syndrome
D-
Ans: A

56. Abnormalities are common in meiosis if a complete chromosome is transferred to haploid cell what this abnormality is called:
A- Trisomy
B- Meiotic non dysjunction
C- Monosomy
D- Mosiacism
Ans: A(if asked mechanism then b)

57. What is Allele?
A- Non identical gene at same locus
B- Same genes at same locus
C- Non alternative types of genes at same locus
D. same geme at different locus
E. non identical gene at different locus
Ans: A

58. Child with Down sndrome. One of the parents has chances of having?
A- Robertsonian translocation
B- Reciprocal translocation
C- Mosaicism
D- Non disjunction
Ans: A

59. Thalasemia suspected in fetus, how to diagnose
A- Chorionic villous sampling
B- Maternal blood for fetal rbcs or antigen
C- Materal urine for fetal Hb
D- Maternal Hb electrophoresis
Ans: A

60. Best diagnosis for turner:
A- Barr body
B- Karyotyping
C- Ultrasound
D- Chronic villus sampling
Ans: B

61. Bar body in xxx:
A- 1
B- 2
C- 3
D- 4
E- 5
Ans: B
Explanation:
- Bar body is one less than no of X chromosomes
- XX and female [illegible]

[illegible] years old girl has primary amenorrhea, she has normal breast development and secondary sexual characteristics, she has short blind ending vagina slight pubic hairs Ultrasound reveals about absent uterus. What would be diagnosis
A- Congenital adrenal hyperplasia
B- Chromosomal defect
C- Defect of paramesonephric duct
D- Failure of development of genital tuburcle
Ans: C

63. Regarding mitochondrial mutations:
A- Can cause fragile x syndrome
B- Only transmitted from mother
C- From paternal side
D- Prader wili syndrome
Ans: B

64. Regarding Autosomal dominant:
A- Incomplete penetrance
B- Both genes are mutated
C- Early presentation
D- None
Ans: A

65. Scanty Barr bodies will be present in:
A- Testicular feminization syndrome
B- Klinefelter syndrome
C- Turner syndrome
D- Down syndrome
Ans: C

66. A 12-year-old child has dwarfism due to short limbs & normal height of the trunk. Hx of Non consanguineous marriage between parents. There are no signs or symptoms suggestive of mental retardation. Pattern of development of dwarfism in this child would have been:
A- Autosomal dominant inheritance
B- Autosomal recessive inheritance
C- X linked dominant
D- X linked recessive
E- Not inherited
Ans: A (Achondrioplasia)

67. Regarding recombinant theory which of the following is true?
A- Plasmid
B- Pasminogen
C- Viruses
D- None
Ans: A

68. Female who is 45 XO will have
A- Gonadal dysgensis and germinal hypoplasia
B- Wide spaced nipple and low bridge nose
C- Short stature simbain crease
D- gynecomastia and small testis

CamScanner

69. In Autosomal dominant diseases:
A- Only females are affected
B- Complete penetrance
C- Heterozygous affected
D- Sign and symptoms appear in early life
E- X linked recessive
Ans: C

70. Huntington disease is in mother only. Father is normal. What chances are present in offsprings?
A- 50/50 chance in both
B- 50% sons only
C- 50% daughters only
D- 100%
Ans: A

71. Mental retardation associated with chromosomal trisomy is
A- 21
B- 18
C- 22
D- 44
Ans. A

72. Which is X-linked disease?
A- Duchene Muscular Dystrophy
B- cystic fibrosis
C- Achondroplasia
D- sickle cell anemia
Ans. A

Explanation:
- Duchene muscular dystrophy- X linked recessive
- Cystic fibrosis, sickle cell anemia - autosomal recessive
- Achondroplasia - autosomal dominant

73. Autosomal recessive differentiate from dominant?
A- Heterozygous
B- More in male
C- More in female
D- Disease present as 1 out of 4 children
Ans. D

74. Regarding X linked disorders:
A- Heterozygous females rarely affected
B- Homozygous females rarely affected
C- Males usually not affected
D- Marfan syndrome is X linked
Ans: A

75. In 40 year age female the chances of down syndrome are
A- 1 in 100
B- 1 in 700
C- 1 in 1000
D- 1 in 1500
Ans: A

Explanation:
- Risk of down syndrome with increasing maternal age
- Risk at 30 years - 1/1000
- Risk at 35 years - 1/350
- Risk at 40 years - 1/100
- Risk at 45 years - 1/30

76. Most common autosomal recessive disorder
A- Hemochromatosis
B- Cystic fibrosis
C- PKU
D- Cystinuria
E- Marfan's syndrome
Ans: A

Explanation:
- Most common autosomal dominant VWD disease
- Most common autosomal recessive hemochromatosis

77. Marfan syndrome is
A- Autosomal recessive
B- Autosomal dominant
C- X linked recessive
D- X linked dominant
Ans: B

Explanation:
Autosomal dominant diseases
Mnemonic: VERY POWERFUL DOMINANTHUMANS
V - Von Willebrand disease
V - Von hippellindau syndrome
E - ehlersdanlos syndrome
R - Retinoblastoma
P - peutzjehger syndrome
O - osteogenesis imperfecta
R - Romano ward syndrome
F - familial adenomatous polyposis
D - Dystrophia myotonica
M - marfan syndrome
N - Neurofiromatosis
A - Achondroplasia
N - Noonan syndrome
T - tuberose sclerosis
H - Heariditaryhemorhagictanglectesis
H - heriditary spherocytosis
H - heariditary non polypsois colorectal cancer
H - Huntington disease
H - hyperlipidemia type 2
H - hypokalemic periodic paralysis
M - malignant hyperthermia
A - Acute intermittent porphyria
A - adult polycystic disease

A- Autosomal dominant
B- X linked recessive
C- X linked dominant
D- D
Ans:

Explanation:
Mnemonic FAIR
F- Fragile X syndrome
A- Alport syndrome
I- Incontenta pigmenta
R- Resistant rickets

79. All are associated with down syndrome except
A- ASD
B- alzheimer
C- AML
D- Horse shoe kidney
E- Hypothyroidism
Ans: D(All are associated D here)

80. Patient present with Short stature, cleft palate finger extendable cardiac problem likely diagnose
A. Down syndrome
B. Kline filter
C. Patau
D. Di George
Ans: D

81. Female patient came in cardiac OPD with cardiac defect, psychiatric behavior and cleft palate likely due to:
A. A-Fragile X
B. B-Klinfilter
C. Down
D. Edward
E. Digeorge Syndrome
Ans: E

82. A 11 year old boy faced abdominal trauma and then presented to emergency. On labs there was 1+ blood and 3+ protein in Urine. What is the pattern of inheritance?
A. Autosomal recessive
B. Autosomal dominant
C. X linked dominant
D. X linked recessive
Ans: A

83. A patient with Cardia abnormality fascial anomlies thymic aplasia hypocalcemia and cleft palate all are features of
A. CATCH 22
B. IgA Deficiency
C. Edward Syndrome
D. Cri du chat syndrome
Ans: A

B. Phenyl ketouria
C. Cystic fibrosis
D. Hyperthyroidism
Ans: C

85. Alzheimer's diseases associated with which of following disease
A. Down syndrome
B. Turner syndrome
C. Klinfilter syndrome
D. Fragile X syndrome
E. Edward Syndrome
Ans: A(FA)

Explanation:
The 5 A's of Down syndrome:
- Advanced maternal age
- Atresia (duodenal)
- Atrioventricular septal defect
- Alzheimer disease (early onset)
- AML/ALL

86. Mother had alcohol during pregnancy; baby is at risk of developing?
A- Down syndrome
B- Prematurity
C- Spina bifida
D- Klienfelters syndrome
Ans: B

87. A patient with epicanthal folds retardation, protruded abdomen what is diagnose of chromosomal abnormality?
A. Trisomy down syndrome
B. Patau syndrome
C. Edward syndrome
D. Cri du cat syndrome
E. Omhpalocele
Ans: A

88. Inherited only from mother to child is
A. Impronted DNA
B. Mitochondrial DNA
C. X-linked
D. Maternal disomy
Ans: B

89. A female is of 36 week pregnant and having low AFP low estriol she is having
A. NTD
B. Down syndrome
C. Edward syndrome
D. Klifenter syndrome
E. Marfan syndrome

CamScanner

90. Hereditary spherocytosis defective protein is:
A. Fibrillin
B. Titin
C. Dystrophin
D. Spectrin
Ans: D

91. Regarding Aneuploidy true is
A. Extra chromosome
B. Increase or decrease number of chromosomes instead of 46
C. Increase number of chromosomes more than 46
D. Decrease number of chromosomes less than 46
E. E-Change in number of chromosomes and deletion
Ans: B

92. A 4-year-old boy was attended in clinic and was observed to have short neck, low hairline on the posterior aspect of neck and was known to be suffering from a heart condition. Xray neck showed fused cervical vertebrae and on examination limited movement of upper limb was noted. What is the most likely diagnosis?
A- Turner syndrome
B- Klinefelter syndrome
C- Down syndrome
D- VACTERL syndrome
E- Klippel feil syndrome
Ans: E

93. A female child with karyotype 46XX presents with ambiguous genitalia and large clitoris,what is the abnormality?
A- Testicular feminization syndrome
B- Fetal aromatase deficiency
C- Congenital adrenal hyperplasia
D- WNT-4 mutation
E- Down syndrome
Ans. C

94. A person working in Circus he is tall and has flexible joint. Suddenly he has chest pain and died. Examination reveal medial necrosis what is likely diagnosis?
A- Edward Syndrome
B- Fragile X Syndrome
C- Marfan Syndrome
D- Aortic aneurysm
Ans: C

95. A patient has repeated episodes of viral and bacterial infection , Also has Cleft palate and Cardiac defect what will be findings present:
A- No follicles in paracortex
B- Lymphocyte atrophy
C- Decrease lymphocyte carrying immunoglobulins
D- Atrophied tonsils
E- Absent germinal centre in lymph node
Ans: C(Digeorge syndrome)

96. Spina bifida associated with:
A- Turner syndrome
B- Down syndrome
C- Klinfilter syndrome
D- Turner syndrome
E- Edward syndrome
Ans: B

97. A baby presented with enlarge clitoris n sex chromatin positive diagnosis is:
A- Ovarian dysgensis
B- Tyrner syndrome
C- Klinfilter syndrome
D- Congenital adrenal hyperplasia
Ans: D

97. About Autosomal dominant true is
A- 1 in 4 affected
B- Variable expressivity
C- Early onset of disease
D- Affect Homozygous
E- Mostly Enzyme defects
Ans: B

98. Girl with coarse facial features, gap between incisors and spade like hands what happens to muscles involved in this disease?
A- Enlargement
B- Myositis
C- Regression
D- Fibrositis
Ans: A(Acromegalay)

99. Polydactyly, micropthalmia, rocker bottom feet seen in
A- Trisomy 47 xx/xy+13
B- Trisomy 47xx/xy+ 18
C- Trisomy 45XX
D- Trisomy 44X0+13
Ans: A

100- Hereditary spherocytosis is
A- Autosomal Recessive
B- X linked recessive
C- Autosomal Dominant
D- Multifactorial
Ans: C

101- A female with short stature hand swollen and neck and is now 20 years of age with amenorrhea and absent secondary sexual — characteristics likely karyotype of this — — diagnoses is
A- 47XXY
B- 46XY
C- 45XO
D- 47XY
E- 46XY
Ans: C (Turner Syndrome)

102- For prenatal congenital genetic ------- abnormalities best test is
A- Amniotic fluid sample
B- Urine sample
C- Chorionic villous sampling
D- Biopsy
E- Carodocentesis
Ans: C

103- Child with multiple fractures, blue sclera his uncle had same complains in past what is mode of inheritance of this
A- X linked
B- Autosomal recessive
C- Autosomal dominant
D- X linked dominant
E- Multifactoroal
Ans: C(Osteogenesis imperfecta)

104- A patient presents short limb, normal trunk and lumbar lordosis the mode of inheritance of this disease is
A- X Link Recessive
B- X Link Dominant
C- Autosomal Recessive
D- Multifactorial
E- Autosomal Dominant
Ans: E (Achondroplasia)

105- Primigravida 20 year old want to do test for thalassemia. They had cousin marriage both husband and wife are thalassemia carrier they have to do test because
A- Elderly Primigravida
B- Have one baby of thalassemia
C- Both have carrier gene defect
D- None
Ans: C

106- Which of Following is X linked recessive?
A- Duchene muscular dystrophy
B- Dystropy myotonic dystrophy
C- Marfan syndrome
D- Cystic fibrosis
E- Glycogen storage disease
Ans: A

107- Duchenne muscles dystrophy is an inherited disorder, its gene is located on
A- Chromosome 5
B- Chromosome 8
C- Chromosome 12
D- X chromosome
Ans: D (Near X P21)

108- A patient has Hemophilia. His two sister cannot have this disease because it is
A- X-linked dominant
B- X-linked recessive
C- Autosomal dominant
D- Autosomal recessive
Ans: B

109- Highest genetic Predisposition is of
A- SLE
B- Type 2 DM
C- Type 1 DM
D- RA
Ans: B

110- Autosomal dominant is
A- Marfan
B- Phenylketonuria
C- Gaucher
D- Hemophilia
Ans: A

111- Inherited decrease Potassium is associated with?
A- Bakers dystrophy
B- Myasthenia gravis
C- Duchenne muscular
D- Familial periodic paralysis
Ans: D

112- A child with mental retardation, umbilical hernia & protruded tongue likely diagnose is
A- Edward Syndrome
B- Down Syndrome
C- Klinefelter syndrome
D- Patau syndrome
E- Fragile X Syndrome
Ans: B

113- Which is Autosomal dominant?
A- Haemophilia
B- ITP
C- Tuberous sclerosis
D- Cystic fibrosis
Ans: C

114- Most common chromosomal abnormality is?
A- Down syndrome
B- Fragile X syndrome

CamScanner

Ans: A (FA)

Explanation:
- Most common inherited cause – Fragile X Syndrome
- Most common Genetic cause – Down syndrome
- 2nd Common Genetic cause – Fragile X Syndrome

115- A patient with Delayed puberty having small testis with Large legs and Gynecomastia and Karyotype is 47 XXY most suitable diagnose is:
A- True Hermaphrodite
B- Down Syndrome
C- Marfan Syndrome
D- Klinefelter Syndrome
E- Edward Syndrome
Ans: D

116- Regarding Prader willi syndrome true is;
A- Paternal
B- Hypogonadism
C- Hyperphagia
D- Chromsome 15 involved
Ans: D

117- Edward syndrome is;
A- Trisomy 21
B- Trisomy 13
C- Trisomy 18
D- Trisomy 22
Ans: C

118- A lady comes to you having thalassemia trait, planned for pregnancy comes to you for counseling her elder child has thalassemia major so what is the risk?
A- 25% diseased
B- 25% carrier
C- 25% unaffected
D- 50% diseased
Ans: A

Explanation:
- In case of thalassemia trait 25:50:25 ratio for diseased: Carrier: Unaffected.

119- How many different codons can stop lengthening?
A- 1
B- 2
C- 3
D- 5
E- 7
Ans: C

A- Under expression of gene
B- Over expression of gene
C- Gene deletion
D- Over flow chromosomes
Ans: B

121- Apert syndrome has high arch, Hypertelorism , Cleft palate and Craniosynostosis what else will be there
A- Delayed eruption of tooth
B- Syndactyly
C- Hypotonia
D- Enlarge testes
Ans: B

122- Genetic mutation inherited through:
A- Autosomal recessive
B- Autosomal Dominant
C- X linked Recessive
D- X linked Dominant
Ans: B

123- In which condition both female and male child are affected with skip generations:
A- Autosomal recessive
B- X linked recessive
C- X linked dominant
D- Autosomal dominant
Ans: A

124- A condition in which heterozygous child are also effected the parents will be male and female both are effected:
A- Only one parent affected
B- Both parents affected
C- Both Child affected
D- No parent affected
Ans: A

125- Female with oligo menorrhea karyotype 46XX/45X0 associated features is:
A- Wide nipple and depressed nasal bridge
B- Gonadal dysgenesis and germinal hypoplasia
C- Short stature, prominent simian crease
D- Webbed neck
Ans: B

126- Regarding Autosomal Recessive:
A- 1/2 children affected
B- 1/4 children affected
C- Skip generation present
D- All parents carrier

127- male, presents as:
A- Monozygous for X gene
B- Heterozygous for X gene
C- Bizygous for X gene
D- Multizygous for X gene
Ans: B

128- Single palmar line is:
A- Simian crease
B- Simian node
C- Axillary line
D- Nuchal line
Ans: A

129- Which of the following is a qualitative change in gene expression?
A- Gene amplification
B- Promoter expression
C- Point mutation
D- Enhancer insertion
Ans: C

130- At 16th week pregnancy lady wants to know about down syndrome what test should be done?
A- Triple test
B- Afp
B- B-hcg
D- CVS
Ans: A

131- In autosomal dominant what is true
A- One parent effected
B- Both parent effected
C- 1 of 4 children affected
D- Variable expression
E- 1 in 4 siblings affected
Ans: E

132- In Autosomal recessive true is
A- 1 of 4 siblings affected
B- 50% Children affected
C- 1 of 6 children affected
D- All children carrier
E- 1 of 4 siblins carrier
Ans: A

133- Hemophilia occurs only in males because it is X-Linked disorder & X chromosome in male is:
A- Monozygous
B- Hemizygous
C- Homozygous
D- Heterozygous
Ans: B

Karyotype will be
A- 47XY+13
B- 47XY+18
C- Trisomy 21
D- 45Xo
Ans: A(Patau syndrome)

135- Duchene muscular dystrophy defective gene makes the cell impermeable to which of the following?
A- Amino acid
B- Water
C- Electrolytes
D- Albumin
Ans: D

136- Husband & Wife Came to You regarding their concern that they both are thalassemia carriers & they are worried about their baby. Prenatal monitoring is necessary in this case because?
A- They Both are thalassemia carriers
B- Both have clinicomorphological picture
C- Their Child Will be thalasemic
D- No risk of Transmission
Ans: C

137- A female with short stature hand swollen and neck widely spaced nipple and is now 20 years of age with amenorrhea and absent secondary sexual characteristics likely karyotype of this diagnoses is
A- 47XXY
B- 46XY
C- 45XO
D- 47XY
E- 46XY
Ans: C (Turner Syndrome)

138- A Kid with thick secretion and having sweat chloride test positive . His parents are normal . The mode of inheritance will be
A- X linked recessive
B- Autosomal recessive
C- Autisomal dominant
D- Autosomal recessive

CamScanner

Explanation:
Autosomal recessive diseases Oh Please! Can Students Who Score High Grades Tell me Features
of the Kidney disorder

- O- Oculocutaneous albinism
- P- Phenylketonuria
- C- Cystic fibrosis
- S- Sickle cell disease
- W- Wilson disease
- S- Sphingolipidoses (except Fabry disease),
- H-Hemochromatosis,
- G - glycogen storage diseases,
- T - Thalassemia,mucopolysaccharidoses (except Hunter syndrome),
- F- Fiedreichatataxia
- K- Kartagener syndrome,
- A- Autosomal recessive polycystic kidney disease

139- A patient has history of memory loss which of following disease associated with this

A- Down syndrome
B- Turner syndrome
C- Klinfilter syndrome
D- Fragile X syndrome
E- Edward Syndrome
Ans: A(FA)

Explanation:
The 5 A's of Down syndrome:

- Advanced maternal age
- Atresia (duodenal)
- Atrioventricular septal defect
- Alzheimer disease (early onset)
- AML/ALL

140- A patient presented with Tall habitus, Gynecomastia & Small sized testes. What test should be done to know the underlying cause?

A- Karyotyping
B- Genetic Analysis
C- Fsh & Lh
E- FISH
Ans: A

141- A Patient with tall habitus presented with hypermobile & hyperextensible joints. Which one of the following is defective?

A- Fibrillin
B- Spectrin
C- Ankyrin
D- Fibroblasts
Ans: A

142- Which of Following is true regarding famililal muscular disorder?

A- Duchene muscular dystrophy - X linked recessive
B- Dystropy myotonic dystrophy- Autosomal dominant
C- Marfan syndromE- X linked recessive
D- Glycogen storage disease -X linked dominant
Ans: A

143- A male child presented with small eyes and retinal dysplasia. What is the most likely diagnosis?

A- Trisomy 18
B- Trisomy 13
C- Down syndrome
D- Potter syndrome
E- Trisomy 21
Ans: B

144- Mitochondrial diseases are transferred through

A- Paternal DNA
B- Impronted DNA
C- Maternal DNA
D- Maternal RNA
Ans: C

145- Patient is already diagnosed with chromosomal abnormality. Now his blood picture shows blast cells and CD10 antigen positive.

A- Turner syndrome
B- Cridu cat syndrome
C- Down syndrome
D- Trisomy 13
E- Klinefelter syndrome
Ans: C

146- A Kid with thick secretion and having sweat chloride test positive . His parents are normal. The mode of inheritance will be

A- X linked recessive
B- Autosomal recessive
C- Autisomal dominant
D- Autosomal recessive
Ans: D

147- Autosomal dominant characteristic if present in one generation & absent in another due to skip generations is due to:

A- Homozygous Pattern
B- Reduced penetrance
C- Variable expressivity
D- Because both Parents are affected
E- Because All children are affected

148- A patient has gynaecomastia and tall height with infertility. Karyotyping shows Double X & One Y. Likely Diagnosis:

A- Turner Syndrome
B- Klinfilter Syndrome
C- Down syndrome
D- Edward Syndrome
Ans: B

149- You are obliged to tell Prenatal diagnosis to Mother at which of the following Maternal age?

A- Above 25
B- Above 30
C- Above 35
D- Above 45
E- Any Age
Ans: E

150- Genetic Cause of Thrombosis:

A- Homocysteinemia
B- AntiPhospholipid Antibody Syndrome
C- VWD
D- Homocysteinuria
Ans: A

151- Parents are carriers of thalassemia.Prenatal diagnosis is necessary because:

A- Their Child will be thalassemic
B- Both partners are carriers
C- Both Partners are cousins
D- Half of Children will be affected
E- Mother is of Advanced Age
Ans: A

152- Patient with short stature and webbed neck lymphedema chromosomes sequence:

A- Xo
B- XX
C- XXY
D- XY
E- XYY
Ans: A

153- A patient with Klinefelter syndrome will have:

A- Superfluous X chromosome
B- An extra Y chromosome
C- An extra Sex chromosome
D- Trisomy
Ans: A

154- 40-60% of genetic defects are

A- Environmental
B- Genetic
C- Environment and gene mutation
D- Multifactorial
Ans: D

155- The individuals with autosomal dominant disease who don't express it phenotypically:

A- Incomplete Penetrance
B- Co-dominance
C- Genetic Heterogenicity
D- Complete Penetrance
Ans: A

156- A baby with small retinal dysplasia and optic nerve problems lense prolapsed. Diagnosis:

A- Trisomy 13
B- Trisomy 18
C- Trisomy 21
D- Potter syndrome
Ans: A

157- If there is 1 /10000 person is Autosomal reccesive in a population then probability of carriers?

A- 1/50
B- 1/500
C- 1/5000
D- 1/5
Ans: A

158- A 4 year boy presented with clinical features of failure to thrive , recurrent sinusitis, otitis media and RTI. He also gives h/o chronic Diarrhea.There is family h/o such complaints. Pattern of inheritance of this condition is ?

A- X linked
B- Autosomal recessive
C- Autosomal dominant
D- X – link recessive
Ans: B (Cystic fibrosis)

159- A Girl presented to her physician with concern that her mother and sister died of metastatic breast cancer before 40 years of age. She is worried about herself which of the following gene is mutated:

A- MH1
B- APC
C- RAS
D- BRCA-1+ BRCA-2 Mutation
E- P53
Ans: D

160- 40-60% of genetic defect are

A- Environmental
B- Genetic
C- Environment and gene mutation
D- Multifactorial
Ans: D

CamScanner

161- A female with breast Carcinoma His mother died of cervical carcinoma Which of the following is not an oncogene in Breast Carcinoma?
A- BRCA
B- APC
C- P53
D- HER2
E- RAS
Ans: B

162- Which of the Following poses Genetic predisposition to "SCHIZOPHRENIA"
A- Siblings
B- Monozygotic Twins
C- Dizygotic Twins
D- Children of Affected Mother & Father
Ans: B

163- Chromosomal abnormality was taught by a professor, his son got a Long bone deformity by a marker that is usually gene suppressor but can cause tumour of Long bones. What actually his son has?
A- Wt1
B- Rb-1
C- KRAS
D- Myc
E- NF1
Ans: B(Harsh Mohan Patho)

Explanation:
- The scenario suggests a **long bone deformity**, which is often associated with **hereditary retinoblastoma** caused by a mutation in the **Rb-1** gene. In hereditary retinoblastoma, there is an increased risk of developing secondary cancers, particularly **osteosarcoma**, a malignant tumor of the long bones.

RB1:
- **Function.** Inhibits G_1 to S phase of the cell cycle.
- **Inherited Mutation (Autosomal Dominant).** Retinoblastoma, osteosarcoma.
- **Somatic Mutation.** Retinoblastoma, osteogenic sarcoma, carcinomas of breast, lung, colon

164- A patient presents with chorea, mental Retardation, Hypotonia, Decreased Memory & Depressed mood. The disorder is single gene inherited disorder. It is most Likely:
A- Huntingtons disease
B- Sydenham chorea
C- Alzheimer's disease
D- Lesch-Nyhan syndrome
E- Duchenne's muscular dystrophy
Ans: A

165- A patient with Delayed puberty having small testis with Large legs and Gynecomastia and Karyotype is 47 XXY. Cause?
A- Non-disjunction
B- Disjunction
C- Microdeletion
D- Mosaicism
Ans: A

166- A 30-year-old G3P2 mother is phenotypically normal but has two children with a genetic syndrome. What is the most likely genetic abnormality in the mother?
A- Robertsonian translocation
B- Isochromosome translocation
C- Deletion of the q arm
D- Chromatid inversion
Ans: A

167- A patient has primary amenorrhea, short stature & webbed neck. Best modality to diagnose in this scenario will be:
A- Barr body
B- Karyotyping
C- FISH
D- Chronic villus sampling
Ans: B
Better

168- True regarding Marfan syndrome
A- 50% Kids will be carriers
B- 50% Kids will be diseased
C- 25% Will be carriers
D- 25% Will be diseased
Ans: B

Explanation:
- Marfan syndrome is an autosomal dominant genetic disorder, meaning that an affected individual has one copy of the mutated gene and one normal copy. Each child of an affected parent has a 50% chance of inheriting the disease because the mutation is dominant. There are no "carriers" in autosomal dominant disorders, as having the mutation typically leads to the disease phenotype.
- Autosomal dominant inheritance: One mutated copy of the gene causes the condition.
- Probability: Each child has:
1. 50% chance of being affected (diseased).
2. 50% chance of being unaffected (normal).
- There are no "carriers" as seen in autosomal recessive disorders

169- Klinefelter syndrome occurs due to
A- Superflous X chromosome
B- Superflous Y chromosme
C- less X
D- Associated with extra Y chromosome only
Ans: A

170- Chromosome dR... metaphase and ends up with haploid number. What is the process called when that one Chromosome ends up with additional Chromosome after failure of separation?
Trisomy
A- Non- Disjunction
B- Disjunction
C- Translocation
D-
Ans: A

171- A female neonate present with respiratory distress on examination she has micrognathia(small mandible), cleft palate , Glossoptosis which of the following is the most likely diagnosis of this patient
Mandible dysostosis
A- Goldenhar syndrome
B- Apert syndrome
C- Pierre robin syndrome
D-
Ans: D

172- Huntington's disease is characterized by involuntary flicking movements. What is the underlying cause?
A- Genetic in Nature
B- Related to GABA
C- Autoimmune in Nature
D- Related to Dopaminergic Neurons
Ans: A

173- A female patient presents with short stature and absence of menstruation, raising suspicion of turner syndrome. Laboratory findings reveal the presence of a barr body what is the most likely explanation
A- Faulty test
B- Turner mosaicism
C- Patient is male
D- Klinfter syndrome
Ans: B

174- Which of the following are features of turner syndrome
A- Secondary infertility
B- Short stature
C- Absent uteus
D- Blind ended vagina
E- Gynecomastia
Ans: B

of dorsum of hands and there is also fat at nape of neck with which of the following genetic disorder patient is suffering from
A- 47XXY
B- 45XO
C- XYY
D- XX/XY
Ans: B

176- Malignant hyperthermia is a life-threatening condition triggered by certain anesthetic agents. What is its pattern of inheritance?(Medicine Feb 2025)
A- Autosomal dominant
B- Autosomal recessive
C- X-linked dominant
D- X-linked recessive
Ans: A

177- Which of the following is a benign tumor?(Medicine Feb 2025)
A- Mesothelioma
B- Glioma
C- Lymphoma
D- Warthin tumor
Ans: D

178- A disease is inherited in an autosomal dominant pattern. Which of the following is a characteristic of this inheritance pattern?(Medicine Feb 2025)
A- The disease is expressed only in homozygous individuals
B- The disease is more common in females
C- The disease skips one generation
D- The disease is expressed in both heterozygous and homozygous individuals
Ans: D

179- Which type of gene is capable of moving from one genomic location to another while carrying essential sequences? (Medicine Feb 2025)
A- Gene mutation
B- Retrotransposons
C- Transposons
D- Gene duplication
Ans: C

180- Which type of DNA sequence does not encode proteins but can contribute to mutations? (Medicine Feb 2025)
A- Microsatellite
B- Tandem repeat
C- Trinucleotide repeat
D- Satellite DNA
E- Minisatellite
Ans: B

CamScanner

181- Kartagener syndrome is a rare genetic disorder characterized by which of the following defects?(Medicine Feb 2025)
A- Dynein arm defect in cilia, leading to chronic sinusitis, bronchiectasis, and situs inversus
B- Ciliary dysmotility due to radial spoke protein defect, leading to hydrocephalus and respiratory issues
C- Microtubule defect in flagella, leading to infertility and respiratory problems
D- Basement membrane defect in respiratory epithelium, leading to chronic cough and wheezing
Ans: A

182- A 10-year-old boy presents with hearing loss, renal failure, and syndactyly. Which of the following genetic disorders is most likely responsible for his symptoms?(Surgery Feb 2025)
A- Alport syndrome
B- Usher syndrome
C- Waardenburg syndrome
D- Branchio-oto-renal (BOR) syndrome
Ans: A

183- True Regarding "Codominance" (Surgery Feb 2025)
A- Both Alleles express equally & Independent of Each Other in heterozygotes
B- Both Alleles present on same chromosome
C- Both Alleles present on different chromosome
D- Only One Allele dominates
Ans: A

184- Males have 20% more colour blindness as compared to females because disease is: (Surgery Feb 2025)
A- Autosomal dominant
B- Autosomal recessive
C- X-linked recessive
D- X-linked recessive
E- Y-linked
Ans: C

185- What is Allele? (Surgery Feb 2025)
A- Copy of gene at same locus
B- Same genes at same locus
C- Non alternative types of genes at same locus
D- same geme at different locus
E- non identical gene at different locus
Ans: A

186- A child with hypermobile fingers and multiple fractures with new areas of Calcification.His uncle suffer from same condition diagnose is: (Surgery Feb 2025)
C- Osteogenesis imperfecta
D- Achondroplasia
E- Paget's disease
Ans: C

187- A 2 years old child presents with microcephaly, micrognathia, hypertelorism, palpebral folds, and hypotonia. What is the type of karyotype is present in this child?(Gynae & Obs Feb 2025)
A- 45XO
B- 47XXY
C- 46XY
D- 46XX 5p deletion
Ans: D

188- True Regarding "Retinoblastoma": (Gynae & Obs Feb 2025)
A- 5% childhood tumours
B- 80% hereditary
C- Giant cells on histology
D- Typically Affects Adults in 4th Decade
Ans: B

189- Rate of chromosomal abnormality in live births: (Gynae & Obs Feb 2025)
A- Less than 1%
B- 1-5%
C- 5-10%
D- 10-15%
Ans: A

190- A 10-year-old boy presents with hearing loss, renal failure, and syndactyly. Which of the following genetic disorders is most likely responsible for his symptoms?(Surgery Feb 2025)
A- Alport syndrome
B- Usher syndrome
C- Waardenburg syndrome
D- Branchio-oto-renal (BOR) syndrome
Ans: A

191- What is the type of mutation in Li fraumeni syndrome(Radiology & Anesthesia Feb 2025)
A- RB gene
B- MEN-1
C- Tp53 inhibiting Apoptotic Function
D- K-RAS
Ans: C

192- 2 years old child with history of recurrent fractures without trauma. Same history in other members of family. What is the inheritance of the disease?(Anesthesia Feb 2025)
A- AR
B- AD
C- X linked recessive
D- Mitochondria

Spleen
- ✓ Splenic Immunological function - White Pulp
- ✓ Splenic Immunological Filteration - Red Pulp
- ✓ In spleen worn out blood cells come at -Red Pulp and Sinusoid
- ✓ Antigen Presenting portion - Marginal Zone

Postsplenectomy findings:
- ✓ Howell-Jolly bodies (nuclear remnants)
- ✓ Target cells
- ✓ Thrombocytosis (loss of sequestration andremoval)
- ✓ Lymphocytosis (loss of sequestration)
- ✓ Increase Risk of infection by encapsulatedorganisms (pneumococci, Hib, meningococci).

Thymus
- ✓ Located in the anterosuperior mediastinum.
- ✓ Site of T-cell differentiation and maturation.
- ✓ Thymus epithelium is derived from third pharyngeal pouch (endoderm),
- ✓ Thymic lymphocytes are of mesodermal origin.
- ✓ Cortex is dense with immature T cells; medulla is pale with mature T cells and Hassall corpuscles containing
- ✓ epithelial reticular cells.
- ✓ Normal neonatal thymus "sail-shaped" onCXR
- ✓ T cell by Thymus
- ✓ B cell by Bone marrow
- ✓ **Thymoma**—neoplasm of thymus. Associated with myasthenia gravis, superior vena cava syndrome, pure red cell aplasia, Good syndrome.

Immunity

Innate immunity
- ✓ Neurtrophil , Macrophages , Monocyte , NK cell and Dendritic cells
- ✓ Occur rapidly , No memory cell and Non specific
- ✓ Toll like receptor recognize pathogen

Adaptive immunity
- ✓ T cells, B cells, circulating antibodies
- ✓ Occur over long time , produce memory cell and highly specific
- ✓ B and T cell recognize pathogen

Passive immunity
- ✓ Due to performed antibodies
- ✓ Rapid
- ✓ Examples are IgA in breast milk and Maternal IgG crossing placenta and Antitoxin
- ✓ After exposure to tetanus toxin, HBV, varicella, rabies virus, botulinum toxin, or diphtheria toxin, unvaccinated patients are given preformed antibodies (passive)

Active immunity
- ✓ Due to Exogenous antigen
- ✓ Slow
- ✓ Examples are Natural infection, vaccines, toxoid
- ✓ Combined passive and active immunizations can be given for hepatitis B or rabies exposure

CamScanner

Major histocompatibility complex I and II

MHC 1
- ✓ Bind CD8
- ✓ 1 long chain, 1 short chain
- ✓ Expressed by All nucleated cells, APCs, platelets (except RBCs)
- ✓ Present **endogenous antigens** (eg, viral orcytosolic proteins) to CD8+ cytotoxic T cells
- ✓ Associated with β2-microglobulin

MHC II
- ✓ Bind CD4
- ✓ 2 equal-length chains (2 α, 2 β)
- ✓ Expressed by APCs
- ✓ Present **exogenous antigens** (eg, bacterialproteins) to CD4+ helper T cells
- ✓ Associated with Invariant chain

HLA subtypes and diseases

B27
- ✓ Psoriatic arthritis, Ankylosing spondylitis,IBD-associated arthritis, Reactive arthritis
- ✓ PAIR. Also called seronegativearthropathies

B57
- ✓ Abacavir hypersensitivity

DQ2/DQ8
- ✓ Celiac disease

DR3
- ✓ DM type 1, SLE, Graves disease, Hashimotothyroiditis, Addison disease

DR4
- ✓ Rheumatoid arthritis, DM type 1, Addisondisease

HLA B5
- ✓ Bachet Syndrome

Antibody

Structure

Fab:
- ✓ Consist of Light and Heavy chain
- ✓ Fragment, antigen binding
- ✓ Determines idiotype: unique antigen-binding pocket

Fc (5 C's):
- ✓ Constant
- ✓ Carboxy terminal
- ✓ Complement binding
- ✓ Carbohydrate side chains
- ✓ Confers (determines) isotype (IgM, IgD, etc)

IgG
- ✓ Most Abundant in Serum
- ✓ Cross placenta
- ✓ Associated with warm autoimmune hemolytic anemia
- ✓ Present in chronic response
- ✓ Fix Compliment

IgM
- ✓ Largest Antibody
- ✓ Pentamer
- ✓ Associated with cold autoimmunehemolytic anemia
- ✓ Present in acute response
- ✓ **Fix Compliment -IgM>IgG(IgG3>IgG1>IgG2>IgG4)**

IgA
- ✓ Most Produced Antibody but low Serum concentration
- ✓ Does not Fix compliment
- ✓ Found in secretions and GI tract(Peyer patches)

IgD
- ✓ Found on surface of many B cells and in serum.

IgE
- ✓ Bind Mast cell and Basophil(Type 1 HS)
- ✓ Protective against Parasitic infection by Activating Eosinophils

Cytokines

- ✓ **IL_1,IL_6,TNF_alpha** --fever and sepsis
- ✓ **Fever**--IL1>IL6
- ✓ **Pseudomonas Fever** -- TNF
- ✓ **IL1** --Osteoclast activating factor
- ✓ **IL2** --Stimulates T cells
- ✓ **IL3** --Stimulates Bone marrow
- ✓ **IL4** --Stimulate growth of B cells
- ✓ **IL4** --Stimulates IgE production
- ✓ **IL5** --Stimulates IgA production
- ✓ **IL6** --Stimulates acute phase reactant formation
- ✓ **IL8** --Major chemotactic for neutrophil
- ✓ **IL10&TGF Beta** --Anti inflammatory cytokines
- ✓ **TNF Alpha** --Cachexia in malignancy
- ✓ **IFN_Gamma** --Induce granuloma formation
- ✓ **IL12** -- Facilitates granuloma formation
- ✓ **TNF_Alpha** -- Maintain granuloma

Transplant Rejection

- ✓ Liver most Resistant organ to transplant rejection
- ✓ Important Test For Transplant – HLA typing
- ✓ Best Blood Cell for HLA Sampling– WBC
- ✓ Best Site for HLA Sampling – Bucal Mucosa
- ✓ Best Tissue for HLA Sampling – Bone marrow
- ✓ TRALI occur in 6-24 hr

Hyper acute Rejection
- ✓ Within minutes
- ✓ Pre formed antibodies (Type 2 Hypersensitivity)
- ✓ Widespread thrombosis of graft vessels

Acute Rejection
- ✓ Weeks to months
- ✓ CD8 Cells (Type 4 Hypersensitivity)
- ✓ Vasculitis of graft vessels with denseinterstitial lymphocytic infiltrate

Chronic Rejection
- ✓ Months to years
- ✓ CD4 Cells (Type 2+4 Hypersensitivity)
- ✓ Proliferation of vascular smooth muscle, parenchymal atrophy, interstitial fibrosis by cytokines
- ✓ Dominated by arteriosclerosis
- ✓ Organ-specific examples:Chronic allograft nephropathy , Bronchiolitis obliteransAccelerated atherosclerosis (heart)&Vanishing bile duct syndrome

Graft vs Host Disease
- ✓ Type 4 Hypersensitivity
- ✓ Maculopapular rash, jaundice, diarrhea, hepatosplenomegaly

CamScanner

Immunodeficiencies

IgA deficiency
- ✓ Child
- ✓ Recurrent GIT and respiratory infection
- ✓ Atopy(Allergy)

IgG deficiency
- ✓ Recurrent infection
- ✓ Newborn

SCID
- ✓ Early age less than 3 months
- ✓ Both B and T cell defect
- ✓ No lymph node

CGD
- ✓ Catalase positive organism will be causing the disease i like Staph Aureus , pseudomonas

X link agammaglobulinemia(Bruten)
- ✓ 7-8 month
- ✓ Boy
- ✓ B cell defect
- ✓ Decrease all immunoglobulins

Common variable immunodeficiency
- ✓ After 2nd Decade
- ✓ Lymph node present

Hyper IgESyndrome(Jobbsydrome)
- ✓ Deficiency of Th17 cells due to
- ✓ STAT3 mutation
- ✓ Cold (noninflamed) staphylococcal Abscesses, retained Baby teeth, Coarsefacies, Dermatologic problems
- ✓ (eczema), bone Fractures from minor trauma
- ✓ **Findings :**Increase igE and Eosinophils

Thymic aplasia
- ✓ 22q11 microdeletion; failureto develop 3rd and 4thpharyngeal pouches
- ✓ Absent thymus and parathyroids
- ✓ **DiGeorge syndrome**—thymic,parathyroid, cardiac defects
- ✓ **Velocardiofacial syndrome**—palate, facial, cardiac defects

CATCH-22:
- ✓ Cardiac defects(conotruncal abnormalities[eg, tetralogy of Fallot, truncusarteriosus]), Abnormal facies,Thymic hypoplasia -T-celldeficiency Cleft palate, Hypocalcemia secondary to parathyroid aplasia result in tetany
- ✓ Findings : Decrease T cell , PTH and Ca
- ✓ Thymic shadow absent onCXR

Hypersensitivity

Type 1:
Examples Include:
- ✓ Anaphylaxis
- ✓ Bronchial Asthma
- ✓ Allergic Rhinitis(Hay Fever)
- ✓ Food Allergy
- ✓ Blood transfusion usually causes Type 2 Hypersensitivity but IgA Deficient Patient has Anti IgA when Blood Containing IgA Transfused in such Patient Anaphylaxis Reaction occur which is Type 1 Hypersensitivity.

Type 2:
Antibody Mediated Cellular Destruction:
1. Complement Activation or Phagocytosis
2. Antibody Dependent Cellular Cytotoxicity

Examples:
- ✓ Transfusion Reaction
- ✓ ErythroblastosisFetalis
- ✓ Autoimmune Hemolytic Anemia
- ✓ Immune Thrombocytopenia

Antibody Mediated Inflammation:
- ✓ Good Pasture Syndrome
- ✓ Rheumatic Fever
- ✓ Hyper Acute Graft Rejection

Antibody Mediated Cellular Dysfunction:

Hypo function
- ✓ Myasthenia Gravis

Hyper function
- ✓ Graves' Disease
- ✓ Pemphigus Vulgaris

Other
- ✓ Type 2 DM
- ✓ Pernicious Anemia

Type 3 (Immune Complex Mediated)
Examples:
- ✓ SLE
- ✓ Post Streptococus GN
- ✓ PAN
- ✓ Reactive Arthritis
- ✓ Serum Sickness
- ✓ Arthus Reaction

Type 4 (Cell Mediated)
Examples:
- ✓ Multiple Sclerosis
- ✓ Contact Dermatitis
- ✓ Psoriasis
- ✓ IBD
- ✓ Type 1 DM

Amyloidosis

- ✓ Amyloidosis visualized by -- **Congo stain**
- ✓ Most common organ affected in Primary Amyloidosis is -- **Kidney**
- ✓ Most Common cause of death in Primary amyloidosis is – **Cardiac Failure**
- ✓ Amyloidosis best confirmed by -- **Rectal biopsy**
- ✓ Dialysis & Carpal tunnel related amyloidosis -- **Beta 2 Microglobulin**
- ✓ AA(Secondary) amyloidosis associated with Chronic inflammation like -- **IBD and RA, Familial Mediterrnean Fever and Protracted infection**
- ✓ Senile amyloidosis – **Normal (Wild Type) Trasnsthyretin**
- ✓ Systemic(Primary) AL amyloidosis -- **Multiple myeloma**
- ✓ Azheimer's Disease -- **Beta amyloid protein**

CamScanner

- ✓ Diabetes Associated – **Islet Amyloid Polypeptide(Amylin)**
- ✓ Familial Amyloid Cardiomyopathy – **Mutated Transthyretin**
- ✓ Familial Amyloid Polyneuropathies – **Mutated Transthyretin**

TYPES OF GRAFTS

- ✓ **Autograft** (self to self) - skin graft from one part pf body to another part
- ✓ **Allograft** - graft between genitically different individual of same specie
- ✓ **Synegenic**graft (Isograft) - graft between identical twin
- ✓ **Xeograft** - graft btw 2 different species

Random

- ✓ Immunity Given by DPT is –Artificial Active
- ✓ Contraindicated in child with Seizure is –DPT
- ✓ Inactivated toxin Used as Toxoid in –Tetanus
- ✓ Active immunity given Tetanus toxoid is 100% effective
- ✓ MMR Vaccine – Live Attenuated
- ✓ Tetanus Vaccine –Inactivated Toxin
- ✓ Pertussive Vaccine – Whole cell(Killed organisms) 78-80% effective and Acellular Vaccine 71-85% effective
- ✓ Rubella vaccine given in reproductive age
- ✓ MMR contraindicated in Pregnancy , Anaphylaxis and Immunodeficiency
- ✓ BCG Vaccine give Active immunity
- ✓ Recurrent infection + thrombocytopenia + Eczema – Wiskott Aldrich syndrome
- ✓ Chédiak-Higashi syndrome - Defect in lysosomal trafficking + Microtubule dysfunction
- ✓ Ataxia-telangiectasia - Defects in ATM gene leads to failure to detect DNA damage
- ✓ C1 esterase inhibitor deficiency causes – Hereditary angioedema
- ✓ B cells present in follicles of white pulp
- ✓ T cells present in periarterial lymphatic sheath
- ✓ Fab portion for antigen binding
- ✓ Fc portion for complement binding
- ✓ C3b—opsonization
- ✓ C3a, C4a, C5a—anaphylaxis
- ✓ C5a—neutrophil chemotaxis
- ✓ C5b-9 (MAC)—cytolysis
- ✓ Major antigen presenting cells - Langerhans
- ✓ ABO antigen secreted in - Saliva
- ✓ Schwartzman reaction is – Endotoxin mediated
- ✓ Antibody production in response to foreign Antigen is - Immunogenecity
- ✓ Most common primary immunodeficiency – IgA deficiency
- ✓ Amyloid precursor protein located on – Ch21
- ✓ Master switch to nucleus for induction of inflammation – NFkb
- ✓ Complement components synthesized mostly in – Hepatocytes
- ✓ NK activity enhanced by IL12 , IFN-b, IFN-a
- ✓ Foreign body phagocytosed by -APC
- ✓ Live attenuated vaccine induced – Humoral response
- ✓ Jobs syndrome increases with immunogloblin – IgE
- ✓ Mixed Connective tissue antibody –Anti RNP
- ✓ All cells have MHC1 except -RBC
- ✓ MHC located on – Chromosome no.6
- ✓ Bar body associated with which cells - Neutrophills

IMMUNOLOGY

1- Tetanus toxin is
A- Endotoxin
B- Neurotoxin
C- Erythrogenin toxin
D- Toxoid
Ans: B

2- HLA DR4 associated with which of the following disease?
A- RA
B- Graves disease
C- SLE
D- Reactive arthritis
Ans: A

3- After 6 months of renal transplant, patient presents with sign of renal failure. His symptoms are resolved by giving immunosuppressive therapy. What is the likely cause?
A- Chronic cellular rejection
B- Acute cellular rejection
C- Acute humoral
D- Acute cell mediated
E- Graft vs host
Ans: B

Explanation:
Acute cellular rejection resolves with treatment.

4- Most common opportunistic infection after kidney transplant is
A- EBV
B- HSV
C- Polyoma
D- HIV
E- HPV
Ans: C

5- A patient has repeated episodes of viral and bacterial infection which among the following will also be present?
A- No palatine tonsils
B- A cleft palate
C- Mandibular hypoplasia
D- Decreased Cells in paracortex
Ans: D (Digeorge syndrome (Robins)

6- A patient undergoes kidney transplant. On first day he was unable to produce urine there is also tenderness at transplant site. Suitable pathogenesis is
A- Graft versus host rejection
B- Hyper acute graft rejection
C- Blockage of ureter
D- Renal artery stenosis
E- Thrombus at the site of transplant
Ans: E

Explanation:
Anuria occur due to thrombus and if asked what transfusion reaction occur then Hyper acute graft rejection

7- A patient present with arthritis having joint pain and morning stifness with CCP being raised and ANA negative. There is a precursor protein which stains red on Congo stain. What is the precursor protein?
A- Serum amyloid precursor protein
B- Serum amyloid associated protein
C- Lamba light chain
D- Transthyretin
E- Beta 2 microglobulin
Ans: B

8- Patient have one normal baby but she is RH+ve and baby is neg. In 2nd pregnancy preterm baby born in 33 weeks and on ventilator what type of antibodies baby have?
A- Immune pathway
B- Anti-receptor antigen
C- Delay cell mediated
D- Compliment mediated
Ans: D (Type 2 HS)

9- IgE level raised by which of the following?
A- Psitacosis
B- Liver Fluke
C- Chlymydia
D- Syphlis
Ans: B

10- NK cells function is:
A- Kill virus affected cells
B- Kill cancerous cells
C- Activate T cells
D- Kill natural body cells
E- Activate B cell
Ans: B

Explanation:
- NK cell is anti-tumor cell
- NK cell kill virus infected cell
- CD56 is marker of NK cell

11- Passive immunization is achieved by:
A- Vaccine
B- Natural disease
C- IV immunoglobulin
D- Injecting disease processes
E- Anti toxin
Ans: C

CamScanner

12- An appendicitis patient having fever which is mediated by?
A- Cytokine
B- Leukotrienes
C- Prostaglandins
D- Histamine
E- Mast cell
Ans: A

13- Women with long-standing asthma and depressive disorder. Most likely immunological change:
A- Decrease cytokines
B- Increase cytokines
C- Decrease acute phase reactants
D- Increased lymphocytic proliferative response to mitogens
Ans: D

14- Blood group agglutinin is?
A- Glycoprotein
B- Immunogenic
C- Hb molecule
D- Secreted by alveoli
Ans: A

15- MHC function is:
A- Immune suprresor m
B- Immune promoter
C- Immune recognition
D- Immune survival
Ans: C

16- Xenograft related to which of the following?
A- From identical twins
B- A graft used on it's normal anatomical location
C- A graph used at another site (not at its anatomical site)
D- From different species
Ans: D

17- Radioimmunoassay of hormone small displacement by antibody due to:
A- Excessive hormone in immunoassay
B- Inadequate sample of blood
C- Excessive antibody response
D- Antibody not specific in serum
E- Decrease Hormone in serum
Ans: C

18- Which of following causes compliment fixation?
A- IgA
B- IgG1
C- IgG3
D- IgG4
Ans: C (No IgM option)

Explanation:
About Compliment System
- Classic Pathway Activated by – IgM >IgG(IgG3>IgG1>IgG2>IgG4)
- Alternative Pathway by – Microbe Surface molecule

19- A child had recurrent infections and every time klebsella is found what is the diagnosis?
A- SCID
B- Bruton agammaglobulenemia
C- Common variable gamma globenemia
D- CGD
Ans: D(Robins)

20- HLA typing is done before organ transplant to prevent?
A- Rejection
B- Supression
C- Abo incompatibility
D- Allergic reaction
Ans: A

21- Type of hypersensitivity in lupus nephritis:
A- Type-1
B- Type-2
C- Type-3
D- Type-4
Ans: C

Explanation:
Type 3 hypersensitivity reactions
- SLE
- Rheumatoid arthritis
- Reactive arthritis
- Polyarteritis nodosa
- Poststreptococcal glomerulonephritis

22- Good pasture shows which type of hypersensitivity?
A- Type 1
B- Type 2
C- Type 3
D- Type 4
Ans: B

23- A child with eczema, recurrent respiratory tract infection, with low platelet count diagnose is
A- Wiskott Aldrich syndrome
B- IgA Deficiency
C- Hyper IgM syndrome
D- CGD

24- A small child had exchange transfusion as HB was decreased after that slowly his ear became red then trunk then whole body ,also he bad diarrhea jaundice and deranged LFTs he is having:
Hypersensitivity
A- Graft vs Host disease
B- Acute transfusion reaction
C- Delayed response
D- Septic shock
E-
Ans: B

Explanation:
- Hyper acute Rejection – Pre formed antibodies (Type 2 Hypersensitivity)
- Acute Rejection – CD8 Cells (Type 4 Hypersensitivity)
- Chronic Rejection – CD4 Cells (Type 2+4 Hypersensitivity)
- Graft vs Host Disease – Type 4 Hypersensitivity and Present with Diarrhea

25- Child given Hep B vaacine first dose 2nd and 3rd dose to be given at 1 and 6 month respectively. Memory cells will be formed after:
A- As soon as after first dose
B- 7 Days after first dose
C- After 3rd dose
D- After 2nd dose
Ans: B (Guyton)

Explanation:
Memory cells start forming after 7 days of first dose(Primary response) and then after 2nd dose rapid and abundant memory cells formed (Secondary response).

26- Light chain globulins in:
A- Systemic amyloidosis
B- Vascular Disease
C- Localized amyloidosis
D- Endocrine pathology
Ans: A

27- Hyperacute transplant rejection occurs due to:
A- Pre formed Antibodies
B- CD 8 cells
C- CD 4 cells
D- T cells
Ans: A

28- HLA B27 associated with:
A- Rieter syndrome
B- Bachet disease
C- DM
D- Hashimoto
Ans: A

Explanation:
HLA B27 associated:
- Rieter syndrome
- Ankylosing Spondylitis
- Psoariatic arthritis
- Acute anterior uveatis

29- Most common manifestation of autoimmune disease:
A- Arthritis
B- Hematological
C- Rash
D- Nausea
Ans: B(Robins)

30- Which of the following is most important for autoimmune disease?
A- ANA
B- Anti DNA
C- Anti RNA
D- TLC
Ans: A

31- TB has which Type of Hypersensitivity?
A- Type 1
B- Type 3
C- Type 4
D- Type 2
Ans: C

32- Poststreptococcal glomerulonephritis has which type of hypersensitivity?
A- Type 4
B- Type 2
C- Type 1
D- Type 3
Ans: D

33- A child presents with complain of passing black coloured urine. History revealed that he had sore throat with group A streptococcus 3 weeks back Type of hypersentivity in this patient:
A- Type 1
B- Type 2
C- Type 3
D- Type 4
Ans: C

34- Type of hypersensitivity in hydrops fetalis:
A- Type 1
B- Type 2
C- Type 3
D- Type 4
Ans: B

CamScanner

35- Least chance of rejection of:
A- Spleen
B- Liver
C- Pancrease
D- Kidney
Ans: B

36- An 11-month-old infant had upper and lower respiratory tract infections almost continuously since the time of birth, with organisms including Pneumocystis jiroveci and Pseudomonas aeruginosa identified. The baby also has oropharyngeal candidiasis. The baby succumbs to a cytomegalovirus pneumonitis At autopsy thymus is markedly hypoplastic, and lymph nodes throughout the body are small, with absent germinal centers on microscopic examination. Which of the following mechanisms is most likely to explain these findings?
A- Adenosine deaminase deficiency
B- Thymic hypoplasia
C- Human deficiency virus infection
D- Autoantibodies to both T and B lymphocytes
E- Failure of development of 3rd and 4th pharyngeal pouches
Ans: A

37- Patient having sore throat given amoxicillin injection died after amoxicillin injection which antibody will be raised?
A- IgM
B- IgE
C- IgG
D- IgA
Ans: B

38- Mother having rubella acute infection in baby diagnosed by:
A- IgG2
B- IgG1
C- IgM
D- IgG
E- IgE
Ans: C
Explanation:
- Mother Affected with Rubella and Baby got Symptoms Diagnosed by – Ig
- Mother Affected with Rubella and Baby Symptoms less to See globulin – IgG2 > IgG1
- Rubella in pregnancy complication overall – Deafness > Cataract
- Rubella in pregnancy complication Within 7 weeks – Cataract
- Rubella in pregnancy complication After 7 weeks – Deafness

39- Association of HLA B-5:
A- Reactive Arthritis
B- Ankylosing Spondylitis
C- Bechet disease
D- DM
Ans: C
Explanation:
HLA B5 examples
- Bachet disease
- Hashimoto thyroiditis
- Pernicious anemia

40- New born recurrent infection which globin deficiency is likely?
A- IgG
B- IgA
C- IgM
D- IgE
Ans: A
Explanation:
- IGA deficiency cannot be symptomatic till 4 years so in newborn IgG and if Child Mention Then IgA.

41- In AIDS, which cells are lost?
A- CD4
B- Cytotoxic T cells
C- Macrophages
D- Neutrophil
Ans: A

42- Patient Hands and feet progressively deform unable to open door and close button of cloth likely findings:
A- Increase RA Factor
B- Decrease ESR
C- Decrease RA Factor
D- Decrease ANA
Ans: A

43- Sjorgen syndrome has which of the following features?
A- Dryness of eye
B- Dryness of mouth
C- Dryness of mouth and eye
D- Genital sores
Ans: C

44- Globulin produced by:
A- Plasma cells
B- Basophils
C- Eosinophils
D- Mast cell

45- ANA is Characteristic of:
A- SLE
B- Sjogren
C- RA
D- OA
Ans: A

46- Anaphylactic reaction due to:
A- IgM
B- IgE
C- Performed antibodies
D- IgG
Ans: B

47- In multiple myeloma, globulin's are raised in the following order
A- IgM, IgA, IgG
B- IgG, IgA, IgM
C- IgG, IgM, IgA
D- IgA, IgG, IgM
Ans: B (Robins)
Explanation:
- IgG 60%
- IgA 20-25%
- IgM 15% or rarely seen

48- Mother's milk contains highest concentration of:
A- IgA
B- IgG
C- IgM
D- IgD
Ans: A
Explanation:
IgA found in secretions provide localized protection on mucous membranes

49- Which of the globulin is important for complement fixation?
A- IgG
B- IgA
C- IgE
D- IgM
Ans: D>A

50- The antigen processed by the exogenous epitope presentation pathways are presented with which one of the following;
A- T cell receptors
B- Fc receptor
C- MHC class 2
D- MHC class 1
E- IgG heavy chains
Ans: C
Explanation:
- **Exogenous** – MHC class 2
- **Endogenous** – MHC class 1

51- T-cell responsible for which disease:
A- DM – 1
B- DM – 2
C- Vasculitis
D- Pemphigus vulgaris
Ans: A (Type 4 HS Delayed T cell mediated)

52- Innate immunity achieved by:
A- Monocytes
B- Macrophages
C- Hepatocytes
D- NK cells
Ans: D

53- TRALI occur in:
A- 10H
B- 8H
C- 6H
D- 2H
Ans: C (FA)

54- Skin graft successful in:
A- Kidney Failure
B- Rasied Globulin
C- Agammaglobulinemia
D- Hypothermia
Ans: C

55- Patient undergoes renal transplant, he is likely to develop:
A- CMV
B- Candidiasis
C- EBV
D- Herpes
Ans: A

56- Antigen binding site:
A- L only
B- H only
C- Hypervariable portion both H and L
D- None
Ans: C

57- A ppd tuberculin test done to a patient. After 40 hours, 15mm erythema is noticed. Cells responsible for erythema are?
A- Helper T cell
B- Cytotoxic T cell
C- NK cells
D- Cd8 cells
E- Eosinophill
Ans: A (CD4 – Helper T cell and. Macrophages)

58- Antigen presenting cell which shows massive phagocytic effect:
A- Macrophage
B- T cell
C- B cell
D- Eaosinophil
Ans: A

59- Which can directly induce antibody response without Helper T cell involvement?
A- Tetnus toxoid
B- Bovine serum albumin
C- Hep. B vaccine
D- Rabbit globulin
E- Bacterial lipopolysaccride flagellin
Ans: E

Explanation:
Some antigen Require T cell for antibody production call T cell dependent and Some antigen do not need T cell called T cell independent. Bacterial LPS is B cell Mitogen (B cell activator) so directly induce Antibody production without T cell.

60- Tetanus prophylaxis is done with:
A- Tetanus Toxoid
B- Tetanus globulin
C- Washing hands
D- Chlorhexidine
Ans: A

61- Most important cells in immunity:
A- Helper T-Cells
B- Cytotoxic T-Cells
C- NK Cells
D- Antibodies
Ans: A

62- Which of the following is an Opsonin?
A- C3a
B- C3b
C- C4
D- IgM
Ans: B

Explanation:
C3b and igG are opsonins

63- HLA B-27 is associated with:
A- Ankylosing Spondylitis
B- Gout
C- Sepsis
D- IBS
Ans: A

64- Baby develops severe hemolytic anemia for which the baby required urgent blood transfusion, which antibody crossed the placenta and responsible for the hemolytic disease of this baby:
A- IgM
B- IgG
C- IgA
D- IgE
Ans: B

Explanation:
- IgG is the only antibody that crosses the placenta and take place in erythroblastosis fetalis reaction.

65- A female gave birth to a baby, after the birth she developed severe hemorrhage for which she was transfused with blood, after few minutes she developed signs and symptoms of transfusion reaction, what type of hypersensitivity response associated with transfusion related reaction:
A- Type-I hypersensitivity
B- Type-II hypersensitivity
C- Type-III hypersensitivity
D- Type-IV hypersensitivity
Ans: B

66- A patient presented after a bee sting with dyspnea most likely due to:
A- Type I HSR
B- Type II HSR
C- Type III HSR
D- Type IV HSR
Ans: A

67- Antigen appears on RBC at which of the following week?
A- 10th Week
B- 15th Week
C- 20th Week
D- 30th Week
Ans: C

68- Sjogren syndrome marker is:
A- Anti SSA
B- Anti DsDNA
C- Anti RNA
D- ANA
Ans: A

Explanation:
Sjorgen markers involved anti RO (Anti SSA) and anti LA (Anti SSB)

69- A person having blood group A+ve will develop transfusion reaction if transfused with:
A- O+ve
B- A+ve
C- B+Ve
D- A-Ve
Ans: C

Explanation:
A person having blood group A can only take blood from A or O which is universal donor & will develop transfusion reaction if transfused with blood

70- A patient presented with keratitis, xerostomia & joint pain is most likely suffering from:
A- Rheumatoid Arthritis
B- Sjogren Syndrome
C- SLE
D- Wegner Granulomatosis
Ans: B

Explanation:
Sjogren syndrome is characterized by Keratoconjunctivitis Sicca, Xerostomia & Rheumatoid Arthritis.

71- Which of the following is known as anti-tumour cells?
A- NK Cells
B- Antibodies
C- Plasma Cells
D- TNF
Ans: A

72- CD means:
A- Cluster of Differentiation
B- Classes of Differentiation
C- Conduct of division
D- None of the above
Ans: A

73- In Scabies, itching is due to:
A- Crawling of mites over the skin
B- Hypersensitivity to Mite protein
C- Type III HSR
D- None of the above
Ans: B

Explanation:
The itching in scabies is type 4 HSR to mite protein.

74- Splenic Immunological function:
A- Red Pulp
B- White Pulp
C- Marginal Zone
D- Arterioles
Ans: B

Explanation:
- Splenic Immunological function: White pulp.
- Splenic Immunological filtration: Red pulp.
- APC portion of spleen: Marginal zone.

75- Which of the following antibody cross the placenta?
A- IgM
B- IgE
C- IgG
D- IgD
Ans: C

76- In acute infection of toxoplasmosis which of the following antibody will be raised?
A- IgM
B- IgE
C- IgG
D- IgD
Ans: A

77- Autoimmune disease against single organ:
A- Rheumatoid Arthritis
B- Hashimoto's Thyroiditis
C- SLE
D- Sjogren Syndrome
Ans: B

78- 10 mins after transplant, Rejection is due to:
A- Cell Mediated
B- Preformed Antibodies
C- CD4
D- CD8
Ans: B

79- Important antigen that is involved in graft rejection:
A- MHC
B- HLA
C- Rh factor
D- AB Blood antigen
Ans: B

80- Patient appears to be having a butterfly rash on his face. What is the best initial test for this patient?
A- ANA
B- Anti – ds – DNA
C- Anti – Ro
D- Anti – SSA
Ans: A

Explanation:
For SLE
- Best initial test - ANA
- Confirmatory/Diagnostic test - Anti-ds-DNA

81- Which globulin is present in RH incompatibility?
A- IgG
B- IgM
C- IgD
D- IgE
E- IgA
Ans: A

82- The maturation of T cells occur in:
A- Bone Marrow
B- Trachea
C- Thymus
D- Payers patches
Ans: C

CamScanner

83- Which of the following autoimmune disease?
A- Mysthenia gravis
B- SLE
C- Sickle cell disease
D- Graves disease
Ans: C

84- Transplant from identical twin:
A- Allograft
B- Autograft
C- Isograft
D- Heterograft
Ans: C

Explanation:
- **Autograft** (self to self) - skin graft from one part pf body to another part
- **Allograft** - graft between geniticallly different individual of same specie
- **Synegenic**graft (Isograft) - graft between identical twin
- **Xeograft** - graft btw 2 different species

85- What is the most important form of protection against influenza?
A- Patient isolation
B- Vaccination and Immunization
C- Wearing mask
D- Sun exposure
Ans: B

86- Which of the following is the feature of SLE?
A- Anti-coagulants increase
B- Increase in red blood cells
C- Complement system level decreases
D- Complement system level increases
Ans: C

87- The antibodies involved in urticaria:
A- IgA
B- IgG
C- IgM
D- IgE
Ans: D

88- Which type of immunity is acquired by DPT?
A- Adaptive
B- Natural active
C- Natural passive
D- Artificial Active
Ans: D

89- A patient is administered a tuberculin test. Which of the following types of hypersensitivity reaction is being tested and which cells would be expected to mediate a positive test result?
E- Type 4 HSR, T-2 Helper cells
Ans: D

Explanation:
Tuberculin test is type 4 HSR & the cells involved are macrophages & type 1 helper T cells.

90- Atopic asthma, foreign substance reacts with:
A- Mast cells
B- Eosinophils
C- Alveolar Epithelial cells
D- Lymphoctyes
Ans: A

91- Raynaud's phenomenon is present in:
A- Arteriolar constriction
B- Venoconstriction
C- Peripheral vascular disease
D- CNS
Ans: C

92- Opsonization is done by:
A- FC portion of IgG & C3b
B- FC portion of IgM
C- FC portion of IgM & C5a
D- C5b & IgM
Ans: A

93- Which one is related to type 1 hypersensitivity?
A- Neutrophils'
B- Eosinophil's
C- Mast cells
D- Monocytes
E- Lymphocytes
Ans: C

94- Complement components are synthesized mostly in
A- Epithilealcellss
B- Langerhan's cells
C- Mast cells
D- Hepatocytes
Ans: D

95- The diagnosis of amyloidosis is best confirmed by:
A- Bence jone's proteinuria
B- Bone marrow
C- Clinical observation
D- Congo red stain
E- Rectal biopsy
Ans: E

96- A12 year old boy/girl repeated infections. Deficiency of:
A- IgG
B- IgA
C- IgE

97- Concentration of IgG about how many Percent in adult:
A- 75%
B- 15%
C- 30%
D- 10%
E- 1%
Ans: B

Explanation:
- IgG - 75%
- IgA - 15%
- IgM - 10%
- IgD - 1%
- IgE - 0.1 %

98- A young girl has history of SOB and wheezing , investigations reveal C1 deficiency and she lacks an esterase required by the body . Most likely diagnosis is
A- Angioedema
B- Myeloperoxidase deficiency
C- SLE
D- IgA deficiency
E- IgE deficiency
Ans: A

99- A lady having immune problems for 6 months. Now developed lymphoma with lymph node in neck. What happened?
A- AIDS
B- SCID
C- Syphilis
D- CMV
Ans: A

100- WBC and Endothelium adhesion by
A- ICAM 1
B- VCAM
C- ICAM 2
D- ICAM 3
Ans: A

101- Most important cells of specific immunity
A- Lymphocytes
B- Esinophills
C- Mast cells
D- Basophills
Ans: A

102- HLA DR3 is associated with
A- Type 1 DM
B- Rheumatoid arthritis
C- Ankylosing spondiolotis
D- Reiters syndrome
Ans: A

103- Negative Montoux test is seen in:
A- Patients taking immunosuppresants
B- Pregnant
C-
D- TB vaccination
Ans: A

104- Deficiency of post synaptic acetylcholine receptors is present in which of following disease
A- Myasthenia gravis
B- Digorge syndrome
C- Tb
D- Myositis
Ans: A

105- Factor that does not participate in development of natural immunity:
A- All four subtypes of globulins
B- Complement
C- Interferon
D- Plasminogen
E- Transfer of maternal immunity to child
Ans: D

106- Which of following is not active immunity?
A- Lymphocytes
B- Macrophages
C- Anti toxin
D- Leucocytes
Ans: C

107- Toll like receptors associated with
A- Innate immunity
B- Passive immunity
C- Active immunity
D- Adapttive immunity
Ans: A

108- Antibody released against previously exposed antigen:
A- IgG
B- IgA
C- IgE
D- IgM
E- IgD
Ans: A

109- During inflammation,T cells bind with
A- MHC
B- HLA
C- BRCA
D- None of the above
Ans: A

110- Pentavalent immunoglobulin is
A- IgG
B- IgA
C- IgE
D- IgM

CamScanner

111- M bands produced by:
A- B cells
B- Plasma cells
C- T cells
D- NK cells
Ans: B (macrophages)

112- For transplant, Best cell for HLA typing:
A- WBC
B- RBC
C- Kidney cells
D- Hepatic cells
Ans: A
Explanation:
- Important Test For Transplant – **HLA typing**
- Best **Blood Cell** for HLA Sampling– **WBC**
- Best **Site** for HLA Sampling – **Bucal Mucosa**
- Best **Tissue** for HLA Sampling – **Bone marrow**

113- A patient received PPD , after 24 hours she developed an indurated area along with macrophages . Most likely will be
A- B lymhocytes
B- T lymphocytes
C- Neutrophills
D- Esinophills
E- Basophills
Ans: B

114- Most important cells of chronic inflammation:
A- Lymphocytes
B- Macrophages
C- Monocytes
D- Mast cells
E- Epithelod cells
Ans: B
Explanation:
- Important – Macrophages
- Abundant- Lymphoacytes

115- Following is produced by plasma cells:
A- Albumin
B- Fibrinogen
C- Gamma globulin
D- Plasminogen:
Ans: C

116- Young pregnant lady with history of recurrent abortions and thrombosis. The most common autoimmune disease associated with abortion can be
A- Anti thrombin 3 deficiency
B- Hemophilia
C- SLE
D- Anti phospholipid syndrome
Ans: D

117- IgGs given after the HBV prick are examples of which type of immunity:
A- Active
B- Passive
C- Screeining
D- None
Ans: B

118- Immunologic test diagnostic for which?
A- Amoebic liver abscess
B- Hydatid disease
C- Sickle cell anemia
D- Thalassemia
Ans: B

119- Which doesnot cause eosinophilia?
A- IgM
B- IgE
C- Parasitic infestations
D- Asthma
Ans: A

120- Polysaccharide antigen conjugated to increase immunity with vaccine:
A- Meningococcal
B- Pertussis
C- Chlamydia
D- Vibrio
Ans: A

121- Prozone phenomenon:
A- Antigen excess
B- Antibody excess
C- Antigen depletion
D- Antibody depletion
Ans: B

122- An 8-month-old baby boy has history of repeated attacks of sinusitis, rhinitis, diarrhea and 2 episodes of pneumonia. On investigations his B lymphocytes are reduced with deficiency of all types of globulins. Diagnosis?
A- Isolated IgA deficiency
B- Common variable defeciency
C- X linked agammaglobulinemia
D- sjorgen syndrome
Ans C

123- Women with bee sting develops swelling and acute inflammation.Most likely mediator for it is:
A- Histamine
B- Bradykinin
C- Prostaglandin
D- Leukotreine
Ans: A

124- A boy with respiratory and GIT infections with normal lymphocytes but decreased or absent plasma cells:
A- Isolated IgA Def
B- Common variable immunodeficiency
C- DiGorge
D- brutons agammaglobulinemia
Ans: B

125- A girl with recurrent staph abscesses. Also had two bouts of aspergillosis. Cause is
A- NADPH deficiency
B- IgA def
C- IgE deficiency
D- IgD deficiency
Ans: A

126- Patient with diagnosis of aplastic anemia, was given anti thymocyte globulin then he develops rashes.Hypersensitivity type:
A- Type - 1
B- Type - 2
C- Type - 3
D- Type - 4
Ans: C

127- Patient visited hospital and have been diagnosed with amyloidosis.Which organ will be most affected by this condition?
A- Brain
B- Kidney
C- Lung
D- Skin
E- Heart
Ans: B

128- Newborn presented with tetany On term. serum Ca 6.3mg/dl on examination there is murmur present, cleft palate and got repeated infections from klebsiella, Pneumocystcarini, aspergillus fumigates cause is:
A- 22q deletion (di george syndrome)
B- Failure of plasma cell to mature in b and t cells
C- Adenosine deamidase deficiency
D- Cd4 cell defected or deficient
Ans: A

129- Myasthenia gravis due to:
A- IgG
B- IgM
C- IgA
D- Ig D
E- Ig E
Ans: A

130- Contact dermatitis is type of which hypersensitivity
A- Type 1
B- Type 2
C- Type 3
D- Type 4
E- Type 5
Ans: D

131- Schwartzman reaction is
A- Complement Mediated
B- Autoimmunity
C- Endotoxin Mediated
D- Antibody Mediated
Ans: C

132- Female with symptoms of chest infection. She goes on vacations and gets relieved her symptoms. shen she came back from vacations she develops again cough fever. CXR chows diffuse pulmonary nodules. The most likely reason is:
A- Mast cell degranulation
B- Interstial fibrosis
C- Langerhans cell histiocytosis
D- Granulomatous necrosis
Ans: A

133- Anti-voltage gated calcium channel antibodies are present in
A- Bucker myotrophy
B- Lambert eaton syndrome
C- Duchene muscular dystrophy
D- Hypothyroidism
E- Mysthenia gravis
Ans: B

134- A man was hiking and noticed a rash appeared on his arm which was not covered by clothing. The rash grew in size for 2 days and then subsided after 2 weeks. Which of the following reaction took place in this person:
A- Type 1 hypersensitivity
B- Type 2 hypersensivity
C- Type 3 hypersensivity
D- Type 4 hypersensitivity
Ans: D

135- 50 years lady received a renal transplant from a cadaver. One month later renal failure s/s were seem. Some biopsy findings pointing to HLA1 association, which cells are involved
A- CD4
B- CD8
C- Macrophages
D- Mast cells
Ans: B

CamScanner

136- Allograft is
A- From same species
B- From identical twin
C- From another species
D- self to self
Ans: A

137- Active immunity is by:
A- BCG
B- Sabine polio
C- Salk polio
D- Tetanus
Ans. A

138- When there is not adequate time left after exposure to infection, what should be given?
A- Active immunity
B- Protection
C- Passive immunity
D- IV antibiotics
Ans. C

139- B Cell function is to produce:
A- IgG and IgM production
B- IgM IgG and IgA production
C- IgM production only
D- IgA production only
Ans. B

140- Cell commonly involved in graft rejection
A- CD4
B- CD 10
C- CD 15
D- CD20
E- CD8
Ans: E
Explanation:
- Acute early - CD8
- Chronic - CD4

141- A neutropenic hypotensive patient admitted in oncology ward with History of dysuria & high grade fever. His blood culture yielded growth of P. aeruginosa. These findings suggest that the disease is a result of the excessive release of the following product
A- TNF
B- IL 6
C- IL 1
D- Granulocyte Stimulating factor
E- Proteases
Ans: A

142- A women after in contact with Tb undergoes an PPD test induration of about 3mm is on arm the phenomena is due to:
A- Type 4 hypersensitivity
B- Type 3 hypersentivity
C- Type 1 hypersensitvity
D- Type 2 hypersenstivity
Ans: A
Explanation:
- Skin PPD test that's used for diagnosis of Tb isbasically Type 4 HSR caused by Helper T cells& macrophages.

143- Endotoxin mediates its action by?
A- IL1
B- Activating compliment system
C- IL 12
D- C5a
Ans: A

144- Low affinity for MHC1 differentiate in thymus to form
A- Helper Th1
B- Helper Th2
C- CD4
D- CD8
Ans: D

145- During Anaphylactic shock Histamine released from:
A- Plasma cells
B- Mast cells
C- Basophils
D- Neutrophils
E- Macrophages
Ans: B

146- Antigen presenting cells which present antigen to T cell and start inflammatory process
A- Monocyte/macrophages
B- T cells
C- B cells
D- MHC 1
E- Basophils
Ans: A

147- Most specific First line defense mechanism is
A- Lymphocyte
B- Plasma Cells
C- Skin and its mucous membrane
D- Neutrophil
E- T cell
Ans: C

148- A woman of 30 years old needs renal transplantation. 5 donors came up for her. Which of the following is best match for organ transplantation
Her Identical twin
A- Sister
B- Husband
C- Son
D- Half brother
E-
Ans: A

149- Class of tumor cell which acts against host cell:
A- CD4
B- CD8
C- MHC1
D- MHC2
Ans: B

150- Cells containing dense granules and have IgE antibodies on their cell membrane?
A- Basophils
B- Neutrophil
C- Eosinophils
D- Lymphocytes
E- Histaminase
Ans: A

151- Myasthenia gravis shows which type of hypersensitivity?
A- Type 1
B- Type 3
C- Type 2
D- Type 4
Ans: C
Explanation:
- Myasthenia gravis – Type 2
- Multiple Sclerosis – Type 4

152- A patient of HIV having Decrease CD4 cell count follow up in this patient is done by
A- PCR
B- ELISA
C- Western blot
D- CD 8 cells
E- CD 4 helper cells
Ans: E

153- IgE is present on the surface of which cell?
A- Basophil
B- Eosinophil
C- Plasma cell
D- Lymphocytes
Ans: A

154- A boy hit by something develop hand swelling and Fever cause of fever is
A- Prostaglandin
B- IL8
C- IL1
D- Leukotriens
Ans: C

155- Regarding Microglial cells in brain:
A- Always active
B- Antigen presenting cells
C- Help lymphocytes in immunity
D- Make memory cells
Ans: B
Explanation:
- Microglia are central nervous system (CNS)resident immune cells for which the impact of MHC class I antigen presentation is still being defined We conclude that microglia are functional antigen presenting cells, and are required for a complete antigen specific CD8 iT cell response in the brain.

156- Infectious mononucleosis involve cells which appear as Atypical cells are of what type of Cells?
A- Activated B cells
B- Plasma cells
C- NK cells
D- Activated T cells
E- Macrophages
Ans: D
Explanation:
- IM shows Atypical Lymphocytes which include Activated T cells but Infected Cells are B cell.

157- Patient had Kidney transplantation develop cyanosis and organ failure within 10 minutes cause is:
A- Cytotoxic T cell rejection
B- Graft vs host disease
C- Non immune vascular disease
D- Antibody mediated rejection
E- Type 4 Hypersensitivity
Ans: D (FA)

158- Young girl presented with malar rash, polyarthritis swelling in hand sensitive to heat and cold , ANA positive what is next investigation?
A- CRP level
B- Serum complemnt C1 level
C- Anti RNP
D- Rheumatoid factor
Ans: B

CamScanner

159- Atopic asthma blood picture will show
A- Eosinophils
B- Lymphocytosis
C- Monocytosis
D- Basophillia
Ans: A

160- T lymphocytes activate MHC Class II by
A- IL 1
B- Alpha interferon
C- Gamma interferon
D- Beta interferon
Ans: C

161- Patient presented in OPD with complain of fever and examination tonsills found to be red swollen. Mechanism behind these immune symptoms ?
A- Bradykinin
B- IL1 and TNF
C- Leukotriens
D- C5a
Ans: B

162- Patient presented in ER with bee sting what will be raised ?
A- IgG
B- IgE
C- IgM
D- IgD
E- IgA
Ans: B

163- A 5-year-old boy comes to the clinic with recurrent cervical lymphadenopathy and infection.On each occasion klabsiella pneumoniais isolated. He is most likely suffering from which immunod eficient state?
A- Bruton's agamaglobinemia
B- Severe combined agamaglobinemia
C- Chronic granulomatous disease
D- Common variable agamaglobinemia
Ans: C

164- A blood group has which antibodies?
A- Anti A antibodies
B- Anti B Anti bodies of IgG variety
C- Anti B anti bodies of IgM variety
D- Both Anti A & Anti B antibodies
Ans: C

165- A patient having Rash, Joint pain with increase photosensitivity. Anti DsDNA is increased Two fold. What is likely type of hypersensitivity develop in this patient
A- Type 1
B- Type 2
C- Type 4
D- Type 3
E- Type 1+2
Ans: D

166- Type 1 hypersensitivity reaction occurs due to eosinophils and this mechanism will occur due to:
A- Organic Dust
B- Inhaled dust
C- Liver Fluke
D- Silica
E- Asbestos
Ans: B

167- Most important pre-requisite for transplantation is:
A- ABO compatibility
B- Donor matching
C- HLA compatibility
D- CBC
E- X-ray
Ans: C

168- Antibody production in response to foreign Antigen is:
A- Immunistimulant
B- Immunogenicity
C- Immunoinhibitory
D- Immune modifier
Ans: B

169- Treatment of erythroblastosis fetalis of B+.Exchange transfusion done with which of following:
A- B+ve
B- B-ve
C- AB+ve
D- Anti D
E- O-ve
Ans: B

170- Least likely reaction when B+ blood transfused to
A- Packed RBC O+
B- Whole blood O+
C- Whole blood AB+
D- Packed blood AB-
Ans: C

171- In linear antibody complex deposition on GBM on biopsy, which type of hypersensitivity it is?
A- Type 1
B- Type 2
C- Type 3
D- Type 4
E- Type 4+2
Ans: B
Explanation:
- Antibody deposition cause Type 2 HS
- Type 1 – IgE mediated
- Type 2 – Antibody mediated
- Type 3 – Immune complex deposition
- Type 4 – Cell mediated

172- Which is example of type 3 hypersensitivity?
A- Asthma
B- Transfusion Reaction
C- Farmers Lung
D- COPD
E- TB
Ans: C

173- Patient after renal transplantation develops moderate Acute cellular rejection acute moderate type what finding are present?
A- Neutrophils in myocardium
B- Lymphocyte in myocardium
C- Coronary stenosis
D- Coronary dilation
E- Ventricular aneurysm
Ans: B

174- HLA B27 is associated with:
A- Rey syndrome
B- Uveatis
C- R.A
D- SLE
E- Psoriatic arthritis
Ans: B
Explanation:
HLA B27 associated:
- Rieter syndrome
- Ankylosing Spondylitis
- Psoariatic arthritis
- Acute anterior uveatis

175- Mother Rh +Ve & father is Rh –ve what's the risk?
A- All babies will be affected
B- Needs serious counseling
C- Rh antigen will leak into mother circulation
D- Rh antibodies will be formed
Ans: C

176- Major antigen presenting cells:
A- Langerhan
B- Macrophage
C- Dendritic
D- Micoglial
Ans: C

177- Which one of these crosses the placenta and affects baby?
A- IgM
B- Thyroxin
C- PTU
D- IgE
Ans: C

178- Drug preventing binding of IgE to mast and basophil?
A- Sodium cromoglycate
B- Anti histamine
C- Epinephrine
D- Atropine
Ans: A

179- Body limit production of Antibodies due to
A- Not enough genome for production of Antibodies
B- Not more antigenic sites on bacteria
C- Low serum antibody
D- Dying bacteria
Ans: B

180- Diversion in antibody
A- long human genome is required for production of antibody
B- Less receptor for human bacteria
C- Gene v mutation is susceptible
D- J gene is required for cell
E- C gene for
Ans: C

181- IGG2 molecule is composed of which of the following
A- One alpha,one gamma2,2 kappa L chains
B- One gamma1 chain ,2 kappa chains
C- 2 gamma 1 chains and one kappa and one lambda chain
D- 2 gamma 1 chain,2 kappa L chains
E- 2 gamma chains and 2 kappa L chains
Ans: E

182- CD 4, TH1 produce which cytokine?
A- IL 2
B- IL 6
C- IL 4
D- IL 5
Ans: A (FA)

183- Biopsy of normal skin Immunofluorescence shows antibodies with IgG deposited at dermoepidermal junction due to what
A- CD4 positive T cells infiltrating skin
B- Compliment mediated
C- CD8 positive T cells infiltrating skin
D- Macrophages infiltration
Ans: B

184- Immune cells located in
A- Lamina propria
B- Lamina densa
C- Reticular layer
D- Lamina Serosa
Ans: C

CamScanner

185- Barr body associated with which cell type?
A- Lymphocyte
B- Macrophages
C- Plasma cells
D- Eosinophils
E- Neutrophils
Ans: E

186- Regarding Gamma globulin:
A- Facilitate roulex formation
B- Produce by liver
C- Produce Antibodies
D- Facilitate Ammonia formation
Ans: A

187- Labour with high fever hemoptysis effector molecule?
A- MAC
B- IgA
C- Tol receptor
D- IgG
Ans: C

188- E Fetalis antibody is:
A- IgG
B- IgD
C- IgA
D- IgE
Ans: A

189- 14 year girl with rash on legs and arms with itching whenever she eats fish after 1hr and resolves spontaneously after some time this is most likely:
A- Antibody mediated
B- Localized anaphylaxis
C- T cell mediated
D- Immune complex deposition
Ans: B

190- Biological activity of immuniglobin is due to:
A- FC portion
B- Fab portion
C- Disulphide bonds
D- Ionic bonds
Ans: A

191- After Cut in Skin Bacteria enter it causes
A- Apoptosis of surrounding cell
B- Activate IFG
C- Activate NK cell
D- Active Compliment
E- Activate Lymphocytes
Ans: D

192- A young patient know atopic having urticaria , rash presented with dyspnea on mild physical activity. He said these symptoms are due to pizza containing tommatos , Chicken and Mushroom. He sometimes remain normal after taking pizza of same brand what is cause of these symptoms
A- Allergy to tommatos
B- Allergy to Chicken
C- Alleegy to Mushroom
D- Exercise induced food anaphylaxis
Ans: D

193- 25 Years old Patient having depigmented Skin lesion on back , lips and cheeks. There is family history of Diabetes. What is suitable pathogenesis of this disease
A- Local reaction
B- Abnormal keratinocyte metabolism
C- Genetic disease
D- Autoimmune
Ans: D

194- Delayed cell immunity mediated by
A- IL 1
B- IL2
C- IL 8
D- IL 12
Ans: D

195- Most abundant immunoglobulin in serum
A- IgM
B- IgE
C- IgG
D- IgD
Ans: C

196- Secondary immunodeficiency is due to decrease in
A- Natural killer cells
B- CD 4 helper cells
C- CD 8 cytotoxic cells
D- B lymphocytes
Ans: B

197- After giving blood transfusion patients developed hypersensitivity reaction what type of reaction is this
A- Type 1 HS
B- Type 3 HS
C- Type 4 HS
D- Typ 2 HS
Ans: D

198- Delayed cell mediated hypersensitivity is following:
A- Post Strep GN
B- Contact Dermatitis
C- SLE
D- Rhinitis
E- Farmer lung
Ans: B

199- Antibody in Allergic rhinitis is
A- IgA
B- IgM
C- IgE
D- IgD
E- IgF
Ans: C

200- Gamma globulin synthesis occurs in
A- Spleen
B- Intestine
C- Liver
D- Lung
Ans: A

201- Sedimentation of erythrocyte increases by Decrease in:
A- Temperatur
B- Roulex
C- Albumin
D- Pressure
E- Size of particle
Ans: C

202- A Patient of TB is on Att for 2 months. Tb antibodies characteristic is
A- Circulating in plasma
B- Bound to nucleus
C- Cell bound
D- Albumin bound
Ans: C

203- A child presented with recurrent rhinitis urticaria and rash on lower limb. What is the cause
A- Type 3 HS
B- Type 2 HS
C- Compliment mediated
D- Antibody mediated
E- Type 1 HS
Ans: E

204- IgE receptor present on
A- Megakaryocyte
B- Basophil
C- Lymphocyte
D- Neutrophil
E- Monocyte
Ans: B
Explanation:
IgE receptors are mainly formed at the surface of Mast cells & Basophils.

205- Antigen presenting TH1 cells present the antigens with
A- MHC class 1
B- MHC class 2
C- CD8
D- CD4
Ans: C

206- Primary immune system organ, where T and B lymphocytes are formed and mature is which of following?
A- Bone marrow and thymus
B- Thymus and spleen
C- Spleen and bone marrow
D- Spleen and liver
Ans: A

207- Most sensitive test for screening of SLE?
A- Anti smith
B- Anti phospholipid
C- Anti DS
D- ANA
Ans: D

208- A ppd tuberculin test done to a patient. After 40 hours, 15mm erythema is noticed. Reactions occur via
A- IgE cell release from mast cell
B- Cytokines to cd4 cell
C- Antigen antibody mediated
D- Antigen to specidic antibody
Ans: B

209- When do antibodies form in a mother with Rh -ve and baby Rh +ve.
A- Antepartum
B- After 2 weeks of delivery of first baby
C- After 4 weeks
D- Last trimester of first pregnancy
Ans: A

210- Female with fever and sore throat and 60% B lymphocytes. B& T lymphocytes normal percentage in the blood?
A- B lymphocytes 50%
B- T lymphocytes 80 – 90% & B lymphocytes 10 – 20%.
C- B lymphocytes 90% and T lymphocytes 10%
D- T lymphocytes 20%
Ans: B

211- Contact Dermatitis has following Hypersensitivity
A- Type 1
B- Compliment mediated
C- Type 3
D- Delayed Hypersensitivity
Ans: D

212- IgE receptor present on
A- Plasma cells
B- Monocytes
C- Eosinophils
D- Macrophages
E- Mast cells
Ans: E

CamScanner

requires blood. Her blood ... reactive blood agglutinates with anti-sera B and anti-sera D. which blood is suitable for transfusion.

A- A+
B- B+
C- O+
D- AB+
Ans: B

214- Tb vaccination leads to:
A- Hypersensitivity type 3
B- Hypersensitivity type 4
C- Hypersensitivity type 2
D- Thick GB membrane
E- Honeycomb pattern
Ans: B

215- Plasma cells formed by which of following?
A- B cells
B- M cells
C- Plasma cells
D- Macrophages
E- NK cells
Ans: A

216- MHC-1 is associated with which of following?
A- CD4
B- CD8
C- CD2
D- NK cells
E- WBC
Ans: B
Explanation:
- MHC 1 – CD8
- MHC 2 – CD4

217- Type 3 HS occur in
A- TB
B- Asthma
C- SLE
D- Rheumatoid arthritis
Ans: C

218- In Tb helper T cells are involved in which type of reaction:
A- Type 1 HSR
B- Type 2 HSR
C- Type 4 HSR
D- Type 3 HSR
Ans: C

219- Immunoglobulin in Allergic reaction is:
A- IgM
B- IgE
C- IgG
D- IgD
Ans: B

A- Elastin
B- Hepatocytes
C- Fibroblast
D- Melanocytes
E- Macrophages
Ans: C

221- IgE in Allergic reaction can be prevented by
A- Antimalarial
B- Antibiotic
C- Antihistamine
D- Anticoagulant
Ans: C

222- Which lymphoid organ has paracrine action?
A- Thymus
B- Spleen
C- Lymph
D- Tonsils
E- Palatine tonsils
Ans: A

223- A patient was give pencillin for some infection he is allergic to pencillin what will be found in blood?
A- IgG
B- IgM
C- IgE
D- IgD
E- IgG3
Ans: C

224- Which of following cause compliment fixation?
A- IgA
B- IgG1
C- IgG2
D- IgGD
Ans: B (No IgM option)
Explanation:
About Compliment System
- Classic Pathway Activated by – IgM > IgG(IgG3>IgG1>IgG2>IgG4)
- Alternative Pathway by – Microbe Surface molecule
- Opsonization – C3b and IgG
- Anaphylaxis – C3a, C4a ,C5a(C5a >C3a>C4a)
- Neutrophil Chemotaxis – C5a
- Cytolysis – C5b – 9 (MAC)
- Early Compliment Deficiency (C1-4) Increase Risk of Recurrent Pyogenic sinus, Respiratory infection and SLE
- Terminal Compliment Increase Risk of Neisseria Bacteremia
- C1 Esterase Inhibitor Deficiency – Result in Angioedema, Increase Bradykinin and Low C4 Level

225- In renal transplant, what is the single most significant test to be done?
A- ABO Grouping and cross matching
B- HLA typing and matching
C- MHC
D- Graft vs host
E- CBC
Ans: B

226- Component of innate immunity active against viruses:
A- NK cells
B- T cells
C- B cells
D- Memory B cells
E- Monocyte
Ans: A

227- Acquired immunity by:
A- Compliment
B- Antibodies
C- Allergy
D- Parasites
Ans: B

228- T lymphocytes predominantly mature at which of the following?
A- Cortex
B- Germinal center
C- Paracortex
D- Medulla
Ans: C

229- Woman has Joint pain with photosensitivity and has Anti DsDNA positive with pleural and pericardial effusion. Urea is raised more than 66 times.What is the likely mechanism?
A- Antigen antibody complex in different tissue
B- Antibody in tissue
C- Cells in Tissue
D- IgE mediated damage
E- Immune complex deposition
Ans: E

230- Patient came with of skin rash and urticaria history of diphtheria vaccine few days back type of hypersensitivity will be:
A- Type 1
B- Type 2
C- Type 3
D- Type 4
E- Type 1+2
Ans: C

A- IgM
B- IgA
C- IgG
D- IgD
E- IgE
Ans: B

232- Latex Gloves cause allergy by:
A- Polysporin
B- Tectum
C- Acid
D- Zinc
Ans: A

233- Medical professional got eczematous dermatitis by wearing latex gloves Type of Hypersensitivity is:
A- Type 1
B- Type2
C- Type 3
D- Type 4
Ans: D

234- Grafts between genetically identical twins:
A- Are not rejected even without immunosuppression
B- Require immunosuppression drugs
C- Rejected with immunosuppression drugs
D- Rejected due to antibiotic
Ans: A

235- Person after two weeks after transplant having everything normal but develop petechiae and desquamations likely cause is
A- Hypersensitivity
B- Graft vs Host disease
C- Acute transfusion reaction
D- Delayed response
E- Septic shock
Ans: B
Explanation:
- Hyper acute Rejection – Pre formed antibodies (Type 2 Hypersensitivity)
- Acute Rejection – CD8 Cells (Type 4 Hypersensitivity)
- Chronic Rejection – CD4 Cells (Type 2+4 Hypersensitivity)
- Graft vs Host Disease – Type 4 Hypersensitivity and Present with diarrhoea, Jaundice and petechiae

236- Immunity against Covid 19 and tumour cells is of:
A- Neutrophils
B- NK cells
C- Macrophages
D- Basophil
E- Eosinophil
Ans: B

CamScanner

237- Which receptor, if absent, may result in tumor cells not being killed by host immune cells?
A- MHC1
B- MHC2
C- NK Cells
D- WBCs
Ans: A

238- Germinal centres are present in which of following:
A- Cortex of lymph node
B- Medulla of lymph node
C- Thymus
D- Liver
Ans: A

239- Reinfection with same antigen now which antibody will rise:
A- IgD
B- IGG
C- IGM
D- IGE
E- IGA
Ans: B

240- A patient was give penicillin for some infection it causes allergic reaction Having IgE and Eosinophils this is due to:
A- Monocytes
B- Mast cells
C- Plasma cells
D- Neutrophils
Ans: B

241- False positive anti sera d result from?
A- Lab error
B- Use of DAT
C- Rouleaux formation
D- None
Ans: C

242- Mechanism of SLE is?
A- Autoimmune
B- Graft Vs host disease
C- Cytokine mediated
D- Delayed hypersensitivity
Ans: A

243- TB test produces hypersensitivity reaction by which mechanism?
A- Autoimmune
B- Cytokine mediated
C- Allergen mediated
D- Contact dermatitis
Ans: B

244- Mechanism of tuberculin test is:
A- NK cells
B- CD 8 cells
C- Antigen presenting T lymph

245- Interleukin secreted by T cell causing RBC growth:
A- Growth factor
B- Interleukin 2
C- Interleukin 3
D- Interleukin 4
E- Interleukin 5
Ans: C

246- NK cells cause following:
A- Destroy normal cells
B- Compliment activation
C- Destroy virus infected cells
D- Antigen presenting
Ans: C

247- Type of hypersensitivity in SLE:
A- Type- 1
B- Type- 2
C- Type- 3
D- Type- 4
Ans: C

248- Best approach to prevent CMV infection in transplant patient:
A- Screening of Recipient
B- Screening of donor blood and CMV negative blood transfusion
C- Cmv positive blood transfusion
D- Screening of donor and CMV positive transfusion
Ans: B

249- Recurrent reaction/fever with blood transfusion, best to do:
A- Antipyretic
B- Packed cells transfusion
C- Leukocyte Filter
D- Antibody test
Ans: C

250- Cytotoxic T cells cause immune reaction by:
A- Interleukin
B- Lymphokines
C- NK cells
D- Plasma cells
Ans: A

251- Killed Whole Organism used as vaccine for?
A- Tetanus
B- Pertussive(Whooping Cough)
C- Mumps

252- Half life of IgA is
A- 9 days
B- 20 days
C- 6 days
D- 2 days
Ans: C

253- A child presented with chronic diarrhea & recurrent respiratory tract infections & there is history of reaction to blood transfusion. Whats the probable cause?
A- Graft vs host disease
B- IgA deficiency
C- IgG Deficiency
D- Brutons agammaglobulinemia
Ans: B

254- Which one of the following is memory immunoglobulin?
A- IgA
B- IgM
C- IgE
D- IgG
Ans: D

255- What is true regarding blood group antigens?
A- Agglutinin
B- Follow autosomal recessive pattern
C- Lipid in nature
D- Present on WBC surface
E- Glycoprotein
Ans: E

256- In erythroblastosis foetalis type of hypersensitivity is
A- Type 1
B- Type 2
C- Type 3
D- Type 4
Ans: B

257- Common Primary immunodeficiency
A- IgA deficiency
B- X linked agammaglob
C- SCID
D- Di George syndrome
Ans: A

258- Antibodies are produced by Mast cells . What's the percentage of IgA?
A- 30%
B- 70%
C- 90%
D- 100%
Ans:

259- A patient with history of chronic cough and fever , reticulonodular opacities on xray , epithelialioid cells seen on histology, what type of reaction is occurring in it
A- Type 3 HSR
B- Type 2 HSR
C- Type 4 HSR
D- Type 1 HSR
Ans: C

260- Cytoplasmic Anti neutrophilic Antibodies are seen in ?
A- Vasculitis
B- Sarcidosis
C- TB
D- Arthritis
E- Mesothelioma
Ans: A (Robins+Pathoma)

261- Function of C3a and C5a is
A- Increase vascular permeability and anaphylatoxin
B- Chemotaxis
C- Phagocytosis
D- Allergic reaction
Ans: A

262- Which one of the following is correct regarding the percentage of B & T lymphocytes?
A- B Lymphocytes 80-90%
B- T Lymphocytes 80-90%
C- T Lymphocytes 10-20%
D- B lymphocytes 50-60%
E- T lymphocytes 50-60%
Ans: B
Explanation:
- T lymphocytes 80-90%
- B lymphocytes 10-20%

263- Best investigation for HLA is
A- Axillary tissue
B- Bone marrow
C- Wbc
D- Buccal mucosa
Ans: B

264- Watchman presented with high grade fever , hemoptysis effector molecule is
A- MAC
B- IgG
C- Toll receptor
D- NK cell

CamScanner

265- A guard was performing night duty in cold weather presents with high grade fever, Cough, and basal crepitus which effector cell is primarily involved
A- Toll like receptors
B- NK cells
C- Cytotoxic T cells
D- Macrophages
E- Plasma cells
Ans: A
Better

266- Which one is primary lymphoid organ
A- Thymus
B- Spleen
C- Lymph
D- Tonsils
E- Palatine tonsils
Ans: A

267- Lymphiod tissue with eosinophillic cortex and basophillic medulla
A- Lymph node
B- Thymus
C- Spleen
D- Tonsills
Ans: B

268- Patient had cough and x-ray shows hilar lymphadenopathy, non caseating granuloma defective cells are
A- Neutrophils
B- Eosinophils
C- T lymphocytes
D- Plasma cells
Ans: C

269- A patient has asthma for 6 months cell involved will be
A- Neutrophils
B- Basophils
C- T lymphocytes
D- Plasma cells
Ans: B

270- Best for HLA sample is
A- WBC
B- Bone marrow
C- Cells of buccal mucosa
D- Basophils
Ans: B

271- Regarding the human MHC
A- Codes for blood group antigens
B- Codes for three classes of antigens
C- is composed of HLA genes
D- Resides at chromosomes no 12
E- Will be identical in dizygotic twins
Ans: C

272- A patient of chronic osteomyelitis is now diagnosed with amyloidosis. What is the most likely cause?
A- Systemic amyloidosis
B- Reactive amyloidosis
C- Shigella
D- Complylobacter
Ans: B

273- What is the function of NK cells?
A- Kill virus infected cells
B- Complement Stimulation
C- Destroy normal cells
D- Antigen presenting cells
E- Kill bacteria
Ans: A
better

274- Allograft is:
A- From one human to another
B- From human to animal
C- Between identical twins
D- From one part of the body to another
Ans: A
Explanation:
- **Autograft** (self to self) - skin graft from one part pf body to another part
- **Allograft** - graft between genitically different individual of same specie
- **Synegenic graft** (Isograft) - graft between identical twin
- **Xenograft**- graft btw 2 different species

275- A girl developed urticaria rash at arm trunk leg and face after eating sea food.what will be the cause of it
A- Localized type 1 Anaphylaxis
B- Generalized type 2 hypersensitive
C- Type 4 hypersensitive
D- Type 3 Hypersensitivity
Ans: A

276- A patient got scholar's A ppd tuberculin test done After 40 hours, 15mm erythema is noticed. Cells responsible for erythema are
A- Helper T cell
B- Cytotoxic T cell
C- NK cells
D- Cd8 cells
F- Eosinophill
Ans: A
better

277- Which of the following cell binds to Antigen in atopic asthma:
A- Mast Cells
B- Eosinophils
C- Basophils
D- Lymphocytes
Ans: A

Explanation:
- For Atopic Asthma prefer the cells in the following order:Mast Cells > Basophils > Eosinophils

278- In acute renal transplant rejection the histological findings suggesting the bad prognosis is
A- Interstitial lymphocytic infiltrate
B- Neutrophilic infiltration
C- Plasma cell infiltrate
D- Tubular necrosis
E- Vasulitis and thrombosis
Ans: E

279- Antigen presenting cell which show massive phagocytic effect:
A- Macrophage/Monocytes
B- T cell
C- B cell
D- Eaosinophil
Ans: A

280- Antigen presenting Cell to T cell:
A- Macrophages
B- Esosiophils
C- Dendritic Cell
D- M Cell
Ans: C

281- Rubella positive expecting mother but baby was born symptoms free. What antibodies would the baby have on ELISA:
A- IgM
B- IgG1
C- IgG4
D- IgM
E- IgA
Ans: B

282- A child presented with history of Skin Rashes & Recurrent chest infections. O/E, Hepatosplenomegaly found- Investiagtions reveal raised IgE levels, Slightly low igA levels while level of other immunoglobulins were normal. Nitroblue Tetrazolium test is slightly positive- Diagnosis?
A- Chediak hegashi syndrom
B- Chronic Granulomatous diease
C- Primary igA deficiency
D- Jobs syndrome
Ans: D(HyperIgE Syndrome)
Explanation:
Hyper-IgE syndrome (HIES)
- *It* is a rare, primary immunodeficiency distinguished by the clinical triad of atopic dermatitis, recurrent skin staphylococcal infections, and recurrent pulmonary infections. Furthermore, there are elevated IgE levels of early-onset in primary childhood.

CHEDIAK HIGASHI SYNDROME:
- Chediak-Higashi syndrome (CHS)is a rare, inherited, complex, immune disorder that usually occurs in childhood characterized by reduced pigment in the skin and eyes (oculocutaneous albinism) , immune deficiency with an increased susceptibility to infections, and a tendency to bruise and bleed easily.

283- Allograft is
A- From same species
B- From identical twin
C- From another species
D- self to self
Ans: A

Explanation:
- ***Autograft*** (self to self) - skin graft from one part pf body to another part
- ***Allograft*** - graft between genitically different individual of same specie
- ***Synegenic graft*** (Isograft) - graft between identical twin
- ***Xeograft*** - graft btw 2 different species

284- NK cells function is:
A- Kill cancerous cells
B- Kill COVID infected cells
C- Activate T cells
D- Kill natural body cells
E- Activate B cell
Ans: A>B
Explanation:
- NK cell is anti-tumor cell
- NK cell kill virus infected cell
- CD56 is marker of NK cell

285- Type of hypersensitivity in erythroblastosis foetalis is:
A- Complement mediated hemolysis
B- Immune complex mediated
C- Cell mediated
D- Serum sickness
E- Antibody receptor mediated
Ans: A

286- Type of immunity stimulated by adminsteration of Vaccination would be:
A- Adoptive
B- Artificial active
C- Artificial passive
D- Natural active
E- Natural passive
Ans: B

CamScanner

287- O +ve was transfused to O-ve.Antibodies raised primarily are:
A- IgG
B- IgG2
C- IgM
D- IgE
Ans: C

288- Live attenuated vaccine
A- BCG
B- Typhoid n paratyphoid
C- Pertussis
D- Polio
Ans: A >D

289- HLA complex is located on Chromosome no?
A- 6
B- 12
C- 10
D- 3
Ans: A

290- Undifferentiated T lymphocytes are protected from foreign bodies by which of the following?
A- Blood-thymus barrier
B- Capsule
C- Sinusoids
D- Lymph nodes
Ans: A

291- Which of the following is a non-specific (innate) defense mechanism?
A- Mucosa
B- NK (Natural Killer) cells
C- T lymphocytes
D- B lymphocytes
E- Antibodies
Ans: B

292- A child presented in the OPD with multiple permeating lesions involving all the bones of the body which of the following is the most probable diagnosis -
A- Neuroblastoma
B- Metastasis from osteosarcoma
C- Histiocytosis X
D- Metastasis from Wilm's tumor
Ans: C

293- EBV infect which of these cells
A- T lymphocytes
B- B lymphocytes
C- Plasma cells
D- Basophils
Ans: B

Explanation
- Infected cells- B cells
- Activated atypical cells- T cells

294- HLA associated diseases are due to deletion of short arm of which chromosome?
A- Chromosome 12
B- Chromosome 6 Band 6P21.3
C- Chromosome 3
D- Chromosome 10
E- Chromosome 5
Ans: B

295- Antigens donot reach to T cell due to:
A- Blood thymus barrier
B- Plasma Cells
C- Blood Brain barrier
D- Prevented by Hassle's corpuscles
Ans: A

296- False positive anti D result from which of following?
A- ESR
B- Infection
C- Inflammation
D- Rouleax formation
E- Recent Rh Immunoglobulin Administration
Ans: D

297- A lady, blood group Rh- negative, delivered a baby by house officer. The HO was worried about the baby's blood group as her husband's blood group was Rh- positive. What hypersensitivity reaction might she have?
A- Type I hypersensitivity
B- Type IV hypersensitivity
C- Type II hypersensitivity
D- Type III hypersensitivity
Ans: C

298- Tumour should supress which of the following to escape from body immunity
A- MCH 1
B- MCH 2
C- CD 8
D- CD 4
F- CD 3
Ans: A

299- woman is allergic to hazelnuts, Peach and apricot seeds. Which mediator is primarily involved in this allergic reaction?
A- PRU AR- 1 Lipid
B- PRP3
C- Allergen to P4
D- Allergen to L5
Ans: A

Explanation:
- "PRU AR-1" is a lipid transfer protein (LTP) found in hazelnuts and other related foods like peaches and apricot seeds. These LTPs are major allergens responsible for triggering IgE- mediated allergic reactions in sensitive individuals. This makes PRU AR- 1 the most likely mediator in this case.

300- Most common cause of negative montoux test:
A- Immunecompetent
B- Immunosuppression
C- Increase Steroids Intake
D- Age over 65
E- Recent Vaccination
Ans: B(Robins)

Explanation:
- Infection with M. tuberculosis typically leads to the development of delayed hypersensitivity, which can be detected by the tuberculin (Mantoux) test.
- A positive tuberculin skin test result signifies cell- mediated hypersensitivity to tubercular antigens. It does not differentiate between infection and disease.
- A well- recognized limitation of this test is that false- negative reactions (or skin test anergy) may be produced by certain viral infections, sarcoidosis, malnutrition, Hodgkin lymphoma, immunosuppression, and notably overwhelming active tuberculous disease.
- False positive reactions may result from infection by atypical mycobacteria

Better

301- Cytotoxic cells kills their targets by releasing
A- Digestive enzymes
B- Interleukin
C- Perforins
D- Histamines
Ans: C

302- Patient presented in ER with SOB & Rash. O/E, Bp is low. Which antibody is responsible for this presentation?
A- IgA
B- IgD
C- IgE
D- IgM
Ans: C

303- Which is risk after transplant?
A- Skin cancer
B- Acute leukemia
C- Cervical dysplasia
D- Renal cancer
Ans: A

Explanation:
- The commonest malignancy after transplant is: Skin
- After 10 years: Skin
- After 5 years: Lymphoproliferative

304- Sublingual immunosuppressant are differ from cutaneous immunosuppressant in
A- Mouth swelling and itching
B- Diarrhea
C- Vomiting
D- Anaphylaxis
Ans: A

305- A male infant presents in OPD with tetany having serum calcium level was 6.3,membranous ventricular septal defect ,at the age of one year he had respiratory infections of aspergillus and pneumocystic cranii which of the following is your diagnosis will be
A- 22q11 deletion
B- NADPH oxidase deficiency
C- Burton disease
D- SCID
E- GCD
Ans: A

Explanation:
- The above case is of DiGeorge syndrome or velocardiofacial syndrome (microdeletion of 22q11) patients with digeorge syndrome have thymic hypoplasia, resultant T cell immunodeficiency ,parathyroid hypoplasia giving rise to hypocalcemia ,a variety of cardiac abnormalities affecting the ouflow tract, mild facial abnormalities

306- Which of the following class if missing on the surface cause defect in cytotoxicity of micro organism by innate mechanism
A- MCH 1
B- MCH 2
C- CD 8
D- CD 4
E- CD 3
Ans: A

307- A boy came with history of Fever & Fatigue. O/E, cervical lymphadenopathy and splenomegaly found. Microscopic examination reveals Distinct Lymphoid tissue infiltrated by lymphocytes and plasma cells which are matured in thymus with Lymphoblast cells. Most probable Diagnosis?
A- Infectious mononucleosis
B- T- cell leukemia
C- Acute Leukemia
D- Lymphoblastic Cell Proliferation
Ans: A

CamScanner

308- Immature T-cells located in which part of the Thymus:
A- Cortex
B- Medulla
C- Subcapsular sinus
D- Paracortex
Ans: A

309- Eosinophilic granules present in:
A- Histiocytosis X
B- T- cell lymphoma
C- CML
D- CLL
Ans: A

Explanation:
Langerhans Cell Histiocytoses (Histiocytosis X)
Characteristics
- Histiocytes are CD1 positive.
- Cells contain Birbeck granules (tennis racket appearance
- Primarily occurs in children and young adults

Types of histiocytoses
- Letterer- Siwe disease
- Hand- Schüller- Christian disease
- Eosinophilic granuloma

310- Primigravia Rh-ive mother & Father is Rh+ive. Hemolytic disease of newborn can be caused by RH incompatibility. Which disease mediater can be found in Mother's blood after delivery?
A- IgG antibody
B- IgM antibody
C- IgA antibody
D- IgE Antibody
Ans: A

311- Structure surrounding vessels in spleen?
A- Splenic sinusoids with Endothelium
B- RBCS
C- Pericytes
D- Endothelial Cells
Ans: A

312- Maternal antibodies which cross placenta to cause erythroblastosis foetalis?
A- IgA
B- IgG
C- IgM
D- IgD
Ans: B

313- A child presented with history of Fever & Sore throat. ASO titres raised on investigations. Which Cells are involved after acute post- streptococcal infection leading to the development of Secondary Rheumatic Fever?
A- Th Cells
B- APC
C- Plasma Cells
D- Macrophages
E- Memory B Cells
Ans: E

314- A child was presented with fever and sore throat for 2 weeks in which ASO antibody titers are raised which of the following is responsible for the increased titers
A- Macrophages
B- Plasma Cells
C- Memory B cells
D- Neutrophils
E- lymphocytes
Ans: B

315- According to Gell and Coombs classification, IGE antibodies play role in which hypersensitivity reaction?
A- Type 1 HSR
B- Type 2 HSR
C- Type 3 HSR
D- Type 4 HSR
Ans: A

Explanation:
The Gell and Coombs classification categorizes hypersensitivity reactions into four types based on immune mechanisms:
1. **Type I (Immediate)**: IgE- mediated; involves mast cells and basophils (e.g., anaphylaxis, allergies).
2. **Type II (Cytotoxic):** IgG/IgM- mediated; targets cell surfaces or ECM (e.g., hemolytic anemia, Goodpasture's syndrome).
3. **Type III (Immune Complex):** Deposition of antigen-antibody complexes; leads to inflammation (e.g., lupus, serum sickness).
4. **Type IV (Delayed):** T-cell mediated; involves macrophages and cytokines (e.g., contact dermatitis, TB)

316- After blood transfusion what is the most convenient method to know there is no transfusion reaction
A- Indirect coomb test of donor blood
B- direct coomb test of recipient blood
C- Passage of clear Urine after transfusion
D- Blood clot in sample of post tranfusion
Ans: C

317- Main action of C3a and C5a is
A- Phagocytosis
B- Anaphylaxis
C- Chemotaxis of neutrophils
D- Leukocytic adhesion
E- Vasodilation
Ans: B

318- A patient presents with a history suggestive of post-streptococcal glomerulonephritis. Further investigation reveals the presence of IgG antibodies against glomeruli. What type of hypersensitivity reaction is this?
A- Type-1
B- Type-2
C- Type-3
D- Type-4
Ans: C

Explanation:
Type 3 hypersensitivity reactions
- SLE
- Rheumatoid arthritis
- Reactive arthritis
- Polyarteritis nodosa
- Poststreptococcal glomerulonephritis
-

319- Most bone marrow suppression is due to
A- Whole body irradiations
B- Chemotherapy
C- Extracorporeal Radiation
D- Anti Lymphocytes serum
E- Thymus removal
Ans: B

320- Live attenuated vaccine?
A- Tuberculosis BCG
B- Tetanus
C- Whooping cough
D- Polio
E- Typhoid parathypoid
Ans: A

321- Which of the following causes the most significant immunodeficiency
A- Surgery
B- Radiotherapy
C- Chemotherapy
D- Anti lymphocytic serum
Ans: D

322- Which organ is primarily affected in DiGeorge syndrome
A- Liver
B- Pancreas
C- Thymus
D- Spleen
E- Urinary bladder
Ans: C

323- Patient with pain in left hypochondrium, Splenomegaly was found, what can be found surrounding the capillaries in the enlarged organ?
A- Lymphocytes
B- RBCs
C- WBCs
D- Plasma cells
Ans: B

324- Cells in chronic atopic asthma:
A- Eosinophilic leucocytosis
B- Basophilic leucocytosis
C- Lymphocytosis
D- Monocytosis
Ans: A

325- Recognition of antigen is role of: (Medicine Feb 2025)
A- Major histocompatibility complex (MHC)
B- T cells
C- B cells
D- Fc Receptor
Ans: A

326- Innate immunity response activated by (Medicine Feb 2025)
A- Flagellin
B- Bacterial polysacchride
C- Bacterial DNA
D- Bacterial RNA
Ans: A

327- Type 3 hypersensitivity seen in: (Medicine Feb 2025)
A- Farmer's lung
B- Montox test
C- Tranplant rejection
D- Anaphylaxis
Ans: A

328- Histamine causes: (Medicine Feb 2025)
A- Vasoconstriction
B- Vasodilation
C- Bronchodilation
D- Increase Temperature
Ans: B(Katzung)

Explanation:
- Histamine causes vasodilation of arterioles caused by H1 receptor activation and is mediated mainly by release of nitric acid from the endothelium
- Histamine causes bronchoconstriction mediated by H1 receptor

329- Which mechanism allows certain viruses to evade natural killer (NK) cells?(Medicine Feb 2025)
A- Downregulation of MHC I on their surface
B- Upregulation of MHC I on their surface
C- Inhibition of interferon production
D- Activation of complement pathway
Ans: A

CamScanner

330- What is a possible adverse effect of sublingual immunosuppressant therapy? (Medicine Feb 2025)
A- Oral mucosal swelling
B- Gingival hyperplasia
C- Oral ulcers
D- Xerostomia (dry mouth)
Ans: A

331- A pregnant woman with Rh-negative blood type develops antibodies against the Rh-positive blood of her fetus, leading to the breakdown of fetal red blood cells. What is the most likely cause of this condition? (Medicine Feb 2025)
A- Anti-D IgM
B- Anti-D IgG
C- Anti-A IgG
D- Anti-B IgM
Ans: B

332- Which of the following primarily affected in DiGeorge syndrome: (Surgery Feb 2025)
A- Liver
B- Thyroid aplasia
C- Thymic hypoplasia
D- parathyroid hypoplasia
E- Urinary bladder
Ans: C

333- Which of the following immediately prevent the contracture formation in burn formation(Surgery Feb 2025)
A- Corticosteriods
B- Skin graft
C- Formation of granulation tissue
D- Antibiotics
Ans: B(Schwartz surgery)

334- Warm antibodies are most commonly associated with which of the following(Surgery Feb 2025)
A- Allogenic antibodies
B- Autoantibodies
C- both
D- Immune complex formation
Ans: B

335- A patient present with low levels of immunoglobulins and decreased levels of plasma cells what is your diagnosis(Surgery Feb 2025)
A- SCID
B- CVID
C- IgA deficiency
D- A gammaglobulinemia
Ans: B

336- Which of the following immunoglobulin is elevated in autoimmune pancreatitis(Surgery Feb 2025)
A- IgG
B- IgA
C- IgE
D- IgM
Ans: A

337- How IVIG work in treating ITP(Radiology Feb 2025)
A- Increase platelet production in bone marrow
B- Stimulate the spleen to produce more platelet
C- Blocks the Fc receptors o macrophages ,reducing platelets destruction
D- Directly destroy autoantibodies against platelets
E- Antiplatelate therapy
Ans: C

338- A child was brought to emergency room who collapsed within few minutes after receiving an injection of Ferrous sulphate given by his family physician .The most likely mediator in ilness is:(Radiology Feb 2025)
A- IgA
B- IgD
C- IgE
D- IgG
E- IgM
Ans: C

339- Specific immunity of body: (Radiology Feb 2025)
A- Skin and mucous membranes
B- Lymphocytes
C- PMNs
D- Macrophages
Ans: A

340- Haemolytic disease of new-born is associated with:(Gynae & Obs Feb 2025)
A- Direct combs test positive with raised IgG
B- Indirect combs test positive with raised IgG
C- Both IgG and IgM raised
D- Direct combs test positive with raised IgM
Ans: A

341- X-linked agammaglobulinemia has a defect in:(Gynae & Obs Feb 2025)
A- Pro-B to B cell maturation
B- Precursor T to CD4 cell maturation
C- Plasma cell maturation
D- T cell receptor signalling
Ans: A

342- Which of the following is most important property of IgM?(Gynae & Obs Feb 2025)
A- They are small molecules and appear late in the immune response.
B- They are large molecules and appear first in response to infection.
C- They are small molecules and appear first in response to infection.
D- They are large molecules and appear late in the immune response.
Ans: B

343- Which antigen is primarily responsible for RHincompatibility?(Gynae & Obs Feb 2025)
A- D antigen
B- C antigen
C- Lewis antigen
D- Kell antigen
Ans: A

344- 151. Rh negative woman is sensitized with Rh antigen in her first pregnancy at which of the following weeks of gestation of her 2nd pregnancy she should be advised for anti D to prevent hemolytic disease of newborn? (Gynae & Obs Feb 2025)
A- 28 and 34 weeks
B- 24 and 28 weeks
C- 34week and after delivery
D- After birth of baby
Ans: A

345- A hypertensive patient is undergoing laparoscopic cholecystectomy. During the procedure, a test dose of an antibiotic is administered, and pneumoperitoneum is created by inflating air into the abdomen. Shortly after, the patient develops a sudden drop in blood pressure and a rapid increase in pulse rate.What is the most likely cause?(Anesthesia Feb 2025)
A- Anaphylactic reaction
B- Air embolism
C- Intra-abdominal hypertension syndrome
D- Vasovagal response due to peritoneal stretching
Ans: A

346- Which vaccine is conjugated with protein? (Anesthesia Feb 2025)
A- Meningiococcal
B- Tetanus toxoid
C- Pertussis
D- Polio
Ans: A

347- A mother (Rh-negative) delivers her first baby without complications and does not receive Rhogam. After 18 months, she delivers her second baby, who develops hydrops fetalis. What type of hypersensitivity reaction is involved? (Anesthesia Feb 2025)
A- Type 1
B- Type 2
C- Type 3
D- Type 4
Ans: B

348- T cells are related to which of the following conditions? (Anesthesia Feb 2025)
A- ANCA-associated vasculitis
B- Vasculitis
C- Insulin-dependent diabetes mellitus (Type 1 DM)
D- Insulin-independent diabetes mellitus (Type 2 DM)
Ans. A

349- Beta globulins are synthesized in? (Anesthesia Feb 2025)
A- B cells
B- Plasma cells
C- T cells
D- Spleen
Ans: D

CamScanner

MEDIPEDIA

tice of Mcq Use Medipedia Application From Play Store
any Mcq in this App on Search bar
Pattern of MCQs in this App
)uiz and continue from same MCQ
'ests on this App

CVS PATHOLOGY QUICK HINTS

R-L Shunt Diseases(Early Cyanosis)

The 5 T's:
Truncus arteriosus (1 vessel)
Transposition (2 switched vessels)
Tricuspid atresia (3 = Tri)
Tetralogy of Fallot (4 = Tetra)
Total Anomalous pulmonary venous return-TAPVR(5 letters in the name)

TOF
Most common cause of early childhood cyanosis. Four main components are
Pulmonary infundibular stenosis (most important determinant for prognosis)
Right ventricular hypertrophy (RVH)— boot-shaped heart on CXR
Overriding aorta
VSD

L-R Shunt Diseases(Late Cyanosis)

VSD >ASD>PDA
VSD
ASD
PDA
Eissenmenger Syndrome

Arteriosclerosis

Arteriolosclerosis Common. Affects small arteries and arterioles. Two types:
Hyaline— Related to hypertension or diabetes mellitus
Hyperplastic—Onion skinning occur in severe hypertension
Mönckeberg sclerosis Also called medial calcific sclerosis. Uncommon. Affects medium-sized arteries. "Pipestem" appearance on x-ray. Does not obstruct blood flow; intima not involved

Atherosclerosis

Following vessel involved in descending order (LCP-DIC)
Lower abdominal aorta >Coronary artery >Popliteal artery >Descending thoracic aorta >Internal carotid artery >Circle of willis

Risk factors

Modifiable: Hypertension, tobacco smoking, dyslipidemia ,diabetes.
Non-modifiable: age, male sex, postmenopausal status, family history.

Components

Atherosclerotic Plaque Has 3 Principle Components
Cells
Smooth Muscle Cells, Macrophages and T cell
Extracellular Matrix
Collagen
Elastic Fibers
Lipids
Extracellular and Intracellular Lipids

Aortic dissection

A Longitudinal intimal tear forming a false lumen. Associated with hypertension, bicuspid aortic valve, inherited connective tissue disorders (eg Marfan syndrome)
Can present with tearing, sudden-onset chest pain radiating to the back markedly unequal BP in arms. CXR can show mediastinal widening. ECG show ST elevation
Stanford type A (proximal): involves Ascending aorta
Stanford type B (distal): involves only descending aorta (Below left subclavian artery)

CamScanner

Stable

Secondary to atherosclerosis (≥ 70% occlusion)
Exertional chest pain in (usually with ST depression on ECG)
Resolving with rest or nitroglycerin

Vasospastic (also called Prinzmetal or Variant)

Secondary to coronary artery spasm
Transient ST elevation on ECG. Tobacco Smoking is a risk factor
Treat with Ca2+ channel blockers, nitrates, and smoking cessation (if applicable).

Unstable

Thrombosis with incomplete coronary artery occlusion
ST depression and/or T-wave inversion on ECG but no cardiac biomarker elevation (unlike NSTEMI)
Increase frequency or intensity of chest pain or any chest pain at rest.

Myocardial infarction

Non–ST-segment elevation MI (NSTEMI)

Subendocardial infarcts
Subendocardium (inner 1/3) especially vulnerable to ischemia
ST depression on ECG

ST-segment elevation MI (STEMI)

Transmural infarcts
Full thickness of myocardial wall involved
ST elevation, pathologic Q waves on ECG

Investigations

Best Initial – ECG
Investigation of choice in First 6 h - ECG
1-2hr – Myoglobin
Within 4hr – CK MB
After 4hr – Trop
Sensitive – Trop T
Specific – Trop I

Leads and arteries

Inferior wall MI (RCA) – Leads 2, 3 and AVF
Anterior wall MI (LAD) – Leads V1-V6
Lateral wall MI (LCX) – Leads 1, AVL, V5 and V6

Complications

4h Post MI – Arrhythmia
4-24h Post MI – Arrhythmia
1-3 Days Post MI – Fibrinous Pericarditis
4-7 Days Post MI – Cardiac Temponade
Month Post MI -- Aneurysm

Heart Blocks

First Degree heart block is characterized by prolongation of PR interval
Second degree heart block has two types
Mobitz type 1: Characterized by prolongation of PR interval followed by a beat drop
Mobitz type 2: Characterized by Constant PR interval with beats drops
Third **degree heart block** or complete heart block characterized by no association of SA node with AV node.
Atrial rate >Ventricular rate

Dilated Cardiomyopathy

Systolic dysfunction
Displays eccentric hypertrophy (sarcomeres added in series)
Doxorubicin cause this

Findings include HF, S3, systolic regurgitant murmur, dilated heart on echocardiogram, balloon appearance of heart on CXR.

Hypertrophic Cardiomyopathy

Diastolic dysfunction
Marked ventricular concentric hypertrophy (sarcomeres added in parallel)
Causes syncope during exercise and may lead to sudden death
Findings include S4, systolic murmur. May see mitral Regurgitation due to impaired mitral valve closure.
HOCM Shows
Myocyte dissary
Binucleation (Hypertrophy myocardial cell show nuclear enlargment result in Binucleation)
3 type of fibrosis that is
-Interstitial fibrosis
-Replacement fibrosis
-Perivascular fibrosis

Restrictive Cardiomyopathy

Diastolic dysfunction
Can Have low voltage ECG
Associated with Postradiation fibrosis, Löffler endocarditis, Endocardial fibroelastosis Amyloidosis, Sarcoidosis Hemochromatosis

Endocarditis

Most common cause of Acute Endocarditis (No Heart Disease) – Staph Aureus
Most common cause of Sub Acute Endocarditis (with Heart Disease) – Strep. Virdian
Tricuspid valve endocarditis is associated with IV drug use
S bovis (gallolyticus) is present in colon cancer
S epidermidis on prosthetic valves.
Native valve endocarditis may be due to HACEK organisms (Haemophilus, Aggregatibacter [formerly Actinobacillus] Cardiobacterium, Eikenella, Kingella)
Libman mainly Involve Mitral and aortic but can involve any valve
Flat Small Vegetation - Libman Sac Endocarditis
Friable small Vegetatiom - NBTE
Large Irregular Vegetation - IE
SLE associated with – Libman
NBTE associated with – Terminal Neoplasm
Presentation include Fever ,Roth spots ,Osler nodes ,New Murmur ,Janeway lesions , Anemia ,Nail-bed hemorrhage and Emboli

Rheumatic fever

Caused by Group A beta hemolyitic organism
Affect Mitral >Aortic valve
Associated with Aschoff bodies and anitschkow cells
Immune mediated type II HS
JONES Criteria
Major
J-Joint involvement(Polyarthritis)
O-O looks like Heart(Myocarditis)
N-Nodules(Subcutaneous)
E-Erythema Marginatum
S-Sydenham Chorea
Minor
Fever
Arthralgia
Elevated ESR and CRP
Prolong PR Interval
Leukocytosis
Additional

CamScanner

Throat Culture +Raise...
2 Major Criteria or 1 Major and 2 Minor Criteria

Pericarditis

Commonly presents with sharp pain, aggravated by inspiration, and relieved by sitting up and leaning forw
Often complicated by pericardial effusion Presents with friction rub
ECG changes include
Widespread ST-segment elevation
PR depression more specific

Pericardium Patho

Hemoparicardium
Traumatic Rupture
Rupture aortic aneurysm(Type A)
Scurvy
Neoplasm and Leukemia
Chylopericardium
Obstruction of thoracic duct
Obstruction of SVC
Pericardial effusion
Heart failure
Viral Myopericarditis
Metastatic malignancy
Renal failure

Cardiac tumors

Most common metastatic tumor(Melanoma)

Myoxoma

Most common primary cardiac tumor in adult
Occur commonly in left atrium
Cause Ball valve obstruction in left atrium
Produce IL-6
May auscultate early diastolic "tumor plop" sound.
Histology shows Gelatinous material, myxoma cells immersed in glycosaminoglycans.

Rhabdomyosarcoma

Most common primary cardiac tumor in child
Associated tuberous sclerosis
Occur commonly in Ventricles
Histology show Hemartomatous growth

Random

Most Common Congenital/Acyanotic Disorder Child -- VSD
Most Common Acyanotic Disorder in Adults -- ASD
Most common Congenital Cyanotic Disorder – TOF
Most Congenital Cyanotic anomaly at birth -- TGA
Female living at Hill or if baby is premature -- PDA
Cyanotic Heart Disease in Which Shunt in Necessary for Survival – **TGA**

Kussmaul Sign

Paradoxical increase in JVP on inspiration(Normally Decrease JVP on inspiration)
May be seen with constrictive pericarditis, restrictive ... art failure, massive pulmonar

LHF signs
Include PND , Orthopnea and Pulmonary edema(HF cells)
RHF signs
Include Hepatomegalay , Jugular venous distension and Peripheral edema
Cardiac temponade
Beck triad (hypotension, distended neck veins, distant heart sounds)
Increase HR, pulsus paradoxus. ECG shows low-voltage QRS and electrical alternans
Pulsus paradoxus
Decrease in amplitude of systolic BP by > 10 mm Hg during inspiration.
Seen in constrictive pericarditis, obstructive pulmonary disease (eg, Croup, OSA, Asthma, COPD), cardiac Tamponade
Hypokalemia -- U wave + inverted T Waves
Hyperkalemia -- Tall T Waves
Normal ECG is unable to record - Electrical activity of SA node
ECG changes can be seen in the following conditions Except -- Sleep
Saw tooth appearance on ECG -- Atrial flutter
Irregular RR Interval > Absent P wave -- Atrial fibrillation
QRS complex shows -- Ventricle Depolarization
ST Segment shows -- Complete Ventricular Depolarization / Plateau phase
Isoelectric line -- PR segment
Isoelectric period -- ST segment
TP segment -- Relaxation of Ventricles
Hypoglycemia increase -- QT interval
Most specific finding of Pericarditis -- PR depression
Time taken by the impulse to travel from Endocardium to Epicardium – QRS Complex
Time taken by the impulse to travel from Epicardium to Endocardium – QT Interval
Absent p waves Pacemaker In -- AV node(Also R Ventricle-Moderator Band)
PR Segment on ECG coincides with -- A wave of JVP
Large A wave -- Tricuspid Stenosis
I
Tall QRS complex -- Hypertrophy of Ventricles
Low voltage QRS complex -- Obesity, Old MI, COPD & Constrictive pericarditis
P-Mitrale occurs in -- Mitral stenosis
Rustling Sound /Pericardial Rub -- Pericarditis
Pain unrelated to Respiration -- Myocarditis
Cardiac output unchanged in – **Sleep**

CamScanner

CVS PATHOLOGY

1- Which valves are most commonly involved in rheumatic heart disease?
A- Mitral and Aortic
B- Tricuspid & Bicuspid
C- Pulmonary valve
D- Bicuspid valve
Ans: A (First Aid)

2- Nonbacterial thrombotic endocarditis is most frequently associated with
A- Congenital heart disease
B- IHD
C- RHheumatc endocarditis
D- SLE
E- Terminal neoplastic disease
Ans: E

Explanation:
SLE associated with – Libman sac endocarditis
NBTE associated with – Terminal Neoplasm

3- Old male patient hass history of headache in temporal region thick cord like vessels in that area on biopsy giant cells are seen other findings will be
A- ESR more than 110
B- Steroids are not effective
C- Low Fibrinogen
D- Low ESR
Ans: A

4- Bergers disease is associated with which of these
A- Asbestosis
B- Silicosis
C- Anthracosis
D- Smoking
E- Berryless
Ans: D

5- Septic shock mainly caused by
A- Gram negative bacteria
B- Gram positive bacteria
C- Gonorrhea
D- MRSA
Ans: B (Robins+Golijan)

6- Myxoid degeneration associated with
A- Mitral valve prolapses
B- Libman sac endocarditis
C- Marantic
D- Infective endocarditis
E- Neoplasm
Ans: A(Robins+Kaplan)

7- Patient has pericardial friction rub with deranged RFTs What is the cause of pericarditis?
A- Serous
B- Fibrinous
C- Exudative
D- Transduative
E- Membranous
Ans: B

8- A women was watching a cricket match and develop malar rash. She has history of Arthritis what is likely complications
A- Pericarditis
B- Pulmonary fibrosis
C- Hepatitis
D- Gastriris
Ans: A

9- A 35 years old man die suddenly. Autopsy finding nill. Toxicology shows cocaine and its metabolite in blood. Cause of death:
A- Myofibrillar disarray
B- Contractile band
C- Myocarditis
D- Pericarditis
Ans: B

10- Most significant cause of atheroma:
A- Alcohol
B- Diastolic hypertension
C- Type 2 personality
D- Choleatatoma
Ans: B

11- A man with chest pain from last 14 hours which enzyme will be raised
A- CK-MB
B- CPK
C- LDH
D- CK MM
E- CK BB
Ans: A

Explanation:
Best Initial Investigation of choice – ECG
1-2 hr – Myoglobin
Within 4hr – CK MB
After 4hr – Trop
Sensitive – Trop T
Specific – Trop I

12- Left ventricular failure is caused by
A- Aortic valve disease
B- Mitral stenosis
C- Cor pulmonale
D- Pulmonary valve disease
E- Lung Fibrosis
Ans: A

13- In Auscultation 3rd intercostal space left to sternum of which heart area
A- Aortic A1
B- Aortic A2
C- Pulmonary valve sound
D- Mitral valve
E- Tricuspid valve
Ans: B

Explanation:
Aortic area A1 right second intercostal space
Aortic area A2 left to Sternum(Erb'sPoint)
- Pulmonary area left second intercostal space
- Tricuspid area Left sternal border of 5th intercostal space
- Mitral area left 5th intercostal space at midclavicular line

14- Most important clinical feature of water intoxication is
A- Slow pulse
B- Distended neck vein
C- Pulmonary edema
D- Pulmonary embolism
E- Rapid Pulse
Ans: A

15- Child with machinery like murmur likely due to
A- AS
B- MS
C- MVP
D- PDA
E- PS
Ans: D

Explanation:
AR – Early Diastolic murmur
AS – Ejection Systolic murmur
MS – Mid Diastolic murmur
MR,TR and VSD – Pansystolic murmur
PDA –Continous Machinery Murmur

16- PaO_2 is 100% seen in
A- Person who used to live in high altitude
B- Right to left shunt
C- Left to right shunt
D- Eissenmenger
E- PDA
Ans: C

17- Increased ASO titer seen in
A- Rheumatic fever
B- Endocarditis
C- Meningitis
D- Pericarditis
E- Pleural effusion
Ans: A(Davidson)

Explanation:
JONES Criteria
Major
J-Joint involvement(Polyarthritis)
O-O looks like Heart(Myocarditis)
N-Nodules(Subcutaneous)
E-Erythema Marginatum
S-Sydenham Chorea
Minor
Fever
Arthralgia
Elevated ESR and CRP
Prolong PR Interval
Leukocytosis
Additional
Recent Streptococcal infection +Elevated ASO
Diagnose
Throat Culture +Raised ASO
2 Major Criteria or 1 Major and 2 Minor Criteria

18- Last mediator of septic shock:
A- IL 6
B- TNF
C- IL 1
D- IL 10
E- IL 12
Ans: A

19- Mitral stenosis murmur best heard at
A- Aortic area
B- Apex
C- Mitral valve
D- Pulmonary area
E- Tricuspid area
Ans: B

20- Patient presents with vasculitis and p-anca positive, what should be the cause
A- Hepatitis B
B- Hepatitis A
C- Hepatitis C
D- Hepatitis D
E- Hepatitis G
Ans: A (FA)

21- Patient with MI, on day first trop-t was positive, on 3rd day of mi, patent collapsed with blood pressure down, pericardiocentesis was done which shows hemorrhages, instead of good resuscitative measures, patent expired. What cells will you find in his pericardial cavity?
A- Necrosis with neutrophils and macrophages
B- Lymphocytic infiltrates
C- Plasma cells
D- Scar
Ans: A (Robins)

CamScanner

22- Cause of cardiogenic shock
A- Hemorrhages
B- Septicemia
C- MI
D- Burn
Ans: C

23- There is small cystic mass in left parietal lobe with involvement of heart feature of
A- Myxoma
B- Glioma
C- Cardiac Hypertrophy
D- Cardiac Hyperplasia
Ans: A (Robins +Pathoma)

24- Loud S1 is due to
A- Mitral insufficiency
B- Aortic stenosis
C- RBBB
D- PR interval upper normal limit
E- PR interval lower normal limit
Ans: E
Explanation:
- PR interval coincides with late diastolic phase in which ventricles are still filling up. If somehow this PR interval is shortened definitely ventricles would not have enough blood in diastolic filing phase. And hence when ventricles would start contraction, mitral valves will close very fast with loud S1.

25- Patient who is shopkeeper suddenly collapsed with fine thread pulse of 120/min and low BP of 80/60mmhg with pale skin. Before collapse, patient experienced sudden central chest and epigastric pain. What is the reason of his collapse
A- Cardiogenic shock
B- Pulmonary embolism
C- Dissecting aortic aneurysm
D- HTN
Ans: B

26- C-ANCA is positive in which of following
A- Vasculitis
B- Sarcidosis
C- TB
D- Arthritis
E- Mesothelioma
Ans: A (Robins+Pathoma)

27- Patient taking Beta Blocker prolonged PR interval what's the cause?
A- Drug induced first degree heart block
B- Prolonged periods of heart unable to contract
C- Anxiety
D- Depression
Ans: A

28- In the case of complete heart block what happens?
A- Atrial rate is greater than ventricle
B- Ventricle rate doesn't correspond to atrial rate
C- Heart Beat Fast
D- Atrial Beat Slowly
Ans: B

29- What is characteristic in shock?
A- Tissue hypoperfusion
B- Tachycardia
C- Volume of blood decreases
D- PCV decrease
E- Increase blood volume
Ans: A

30- After tooth extraction cause of sub-acute endocarditis?
A- Streptococus
B- Viridins group of streptococci
C- Staph aurus
D- Influenza
E- Epidermitis
Ans: B(Robins + Pathoma)

31- Most common cause of sub-acute endocarditis
A- Viridans Streptococci
B- Staphloccus aureus
C- Epidermitis
D- Influenza
Ans: A(Robins + Pathoma)
Explanation:
- Most common cause of **Acute** Endocarditis **(No Heart Disease)** – **Staph Aureus**
- Most common cause of **Sub Acute** Endocarditis **(with Heart Disease)** or **after dental Procedure** – **Strep. Virdian**
- Libman mainly Involve Mitral and aortic but can involve any valve
- **Flat Small** Vegetation - **Libman Sac Endocarditis**
- **Friable small** Vegetatiom - **NBTE**
- **Large** Irregular Vegetation - **IE**
- **SLE** associated with – **Libman**
- **NBTE** associated with – **Terminal Neoplasm**

32- Man has non-lethal MI what happens to him in few minutes
A- Tamponade
B- Arrythmia
C- Shock
D- Myocarditis
E- Pericarditis
Ans: B (Robins)

33- Patient died after 6 days of MI on autopsy large amount of fluid seen in pericardium
A- Tamponade
B- Arrythmia
C- Shock
D- Myocarditis
E- Pericarditis
Ans: A (First Aid + Robins
Explanation:
4h Post MI – Arrhythmia
4-24h Post MI – Arrhythmia
1-3 Days Post MI – Fibrinous Pericarditis
4-7 Days Post MI – Cardiac Temponade
Month Post MI – Aneurysm

34- MI Typical Feature is:
A- Treated with defibrillation shock therapy
B- Rate is so rapid above 400beats/min
C- Heart beat between 200 and 350beats/min
D- Heart rate 50 beats/min
Ans: C(Kaplan + Robins)

35- A 35 year female having malar rash and positive anti ds dna now develops proteinuria & hematuria the most likely cause will be
A- Nephrotic syndrome
B- Amyloidosis
C- Cystitis
D- Glomerulonephritis
E- Lupus nephritis
Ans: E(Robins)

36- Patient with malaise and raised BP died because of haemorrhagic stroke in basal ganglia on autopsy bilateral small kidneys with petechial haemorrhages, hyperplastic arteriosclerosis and fibrinoid necrosis. What's the diagnosis?
A- Fibromuscular dysplasia
B- DM type II
C- Systemic sclerosis
D- Nsaid induced
E- Smoking
Ans: A(First Aid)

37- A patient undergoes tonsillectomy he became hypotensive after 2 hours why
A- Blood loss
B- Vasovagal shock
C- Hypovolemic shock
D- Due to trauma
E- Due to infection
Ans: C

38- A patient developed atrial fibrillation he was treated accordingly but same patient died due to occlusion of vessel in brain why?
A- Arrhythmia
B- Thrombus
C- [illegible]
D- Hypotension
Ans: C

39- A patient comes to u with chest pain what question will give u maximum information?
A- Tell me about pain
B- Any history of heart disease in your family
C- Previous history of pain
D- Have you ever visited doctor for heart Problem in last 6 months
Ans: A

40- In complete heart block pacemaker is placed:
A- Left atrium
B- Right ventricle
C- Right atrium
D- SA node
E- AV groove
Ans: B

41- Post MI death. On 4th day findings on biopsy of left myocardium:
A- Edema, loss of striation
B- Transmural collagen deposit
C- Lymphocytes
D- Necrosis, neutrophils,macrophages
E- Perivascular and interstitial amyloid deposit
Ans: D(Robins)

42- Feature of primary shock is:
A- Hypovolemia
B- Bradycardia
C- Tachycardia
D- Initial hypertension
E- Lower peripheral vascular resistance
Ans: C(Robins)

43- Physiological splitting of second heart sound Enhanced by
A- Early closure of Aortic valve
B- Delayed closure of Aortic valve
C- Early closure of mitral valve
D- Early closure of pulmonary valve
E- Delayed closure of mitral
Ans: A(FA)
Explanation:
Splitting of S2
Physiological Splitting
- Delayed Closure of Pulmonary Valve >Early Closure of Aortic Valve
- Inspiration Leads to drop in intrathoracic pressure increase venous return increase RV filling increase RV ejection time cause delayed closure of pulmonary valve

CamScanner

Wide Splitting
- Heard on Inspiration also
- Conditions leading to delayed RV emptying cause wide splitting by delayed closure of
- Pulmonary Valve e.g
- Pulmonary Stenosis
- Pulmonary HTN
- RBBB

Reverse Splitting
- Heard on Expiration
- Conditions that cause delayed Aortic Valve closure e.g
- Aortic Stenosis
- Systemic HTN
- LBBB

Fixed Splitting
- Heard in ASD
- No effect of respiration

44- Obese person working as a Clerk with sedentary life style, was routinely checking his blood pressure and blood pressure was raised. He was investigated but no cause was found, his raised blood pressure is due to?
A- Increased diastolic pressure
B- Increase SV
C- Increase CO
D- Increase vascular tone
Ans: D

45- Which of the following shows an initial Left to Right shunt before reversal?
A- Eisenmenger complex
B- Transposition of great vessels
C- Persistent truncus arteriosis
D- Ebstein anomaly
E- TOF
Ans: A (FA)

46- Difference between septic and hypovolemic shock
A- Temperature
B- Cardiac output
C- Heart rate
D- Blood flow
Ans: A

47- A 65 Year old mate patient Presented with chest pain for last 30 mins. And has ST segment elevation in leads V1 to V4. He is most likely to have:
A- Anterior infarction
B- Anterolateral infraction
C- Lateral infarction
D- Inferior infarction
E- Posterior Infarction
Ans: A(Kaplan + Davidson + Robins)

48- Heart failure is commonly (associated with/due to) which of the following conditions:
A- Fibrinous pericarditis
B- Hemopericardium
C- Pericardial effusion
D- Chylopericarditis
Ans: A

49- A 2 years old child has the history of premature birth. He is most likely to have the Following congenital anomaly
A- VSD
B- Patent ductus venosus
C- Patent ductus arteriosus
D- Patent foramen ovale
E- ASD
Ans: C(FA)

Explanation:
- Most Common Congenital/Acyanotic Disorder Child -- **VSD**
- Most Common Acyanotic Disorder in Adults -- **ASD**
- Most common Congenital Cyanotic Disorder – **TOF**
- Most Congenital Cyanotic anomaly at birth -- **TGA**
- Female living at Hill or if baby is premature -- **PDA**
- Cyanotic Heart Disease in Which Shunt is Necessary for Survival – **TGA**

50- A patient has irregularly irregular pulse on examination. ECG shows many abrupt P waves & the QRS complexes occur irregularly. What is the diagnosis?
A- Ventricular fibrillation
B- WPW syndrome
C- Atrial fibrillation
D- Atrial flutter
E- Ventricular tachycardia
Ans: C

51- A 50 years old man who has previous history of diabetic retinopathy & MI presented with chest pain coronary occlusion occurs commonly due to:
A- Vasospasm
B- Embolism
C- Stasis of blood
D- Hypercoagulable state
E- Thrombosis
Ans: E

Explanation:
Cause of Chest Pain is CAD

52- PDA Characteristic Feature is
A- Increase arterial PCO_2
B- Decrease arterial PO
C- Peripheral cyanosis
D- Increase systemic pressure
Ans: C(FA)

53- Total peripheral resistance is determined by:
A- Venous compliance
B- Diastolic BP
C- Systolic BP
D- Musclular Tone
Ans: B

Explanation:
- Preload determine by -- **EDV (Depends on Venous return)**
- After load determine by -- **MAP**
- TPR determine by -- **Diastolic BP**
-

54- Atherosclerotic plaque caused by:
A- Endothelial injury
B- Hyperlipidemia
C- Chronic inflammation
D- Infection
E- Embolism
Ans: A(Robins)

Explanation:
Virchow Triad
- Endothelial Injury
- Stasis
- Hypercoagulability

55- Most common anomaly of great vessels found is:
A- TOF
B- Post ductal coarctation of aorta
C- ASD
D- Aortic aneurysm
E- PDA
Ans: E

56- Patient has c/o joint pain n on X-Ray large silhouette of heart seen. In childhood she has recurrent attacks of pharyngitis of Streptococcal group which will be effected by this disease:
A- Mitral and aortic valves
B- Mitral and pulmonary valve
C- Aortic and pulmonary Semilunar valves
Ans: A

57- Patient having STEMI and there is elevation in Lead 2, 3 and AVF which wall MI is?
A- Lateral Wall MI
B- Anterior Wall MI
C- Posterior Wall MI
D- Inferior Wall MI
E- Anterolateral
Ans: D(Davidson +Kaplan)

Explanation:
Inferior wall MI (RCA) – Leads 2, 3 and AVF
Anterior wall MI (LAD) – Leads V1-V6
Lateral wall MI (LCX) – Leads 1, AVL, V5 and V6

58- In which condition atrial repolarization is shown on ECG in which of following
A- Third degree complete heart block
B- Inspiration
C- During exercise
D- Expiration
Ans: A

59- The pulmonary artery pressure will be higher than aortic pressure in which of following
A- Right to left shunt
B- Left to right shunt
C- Pulmonary embolism
D- Aortic dissection
Ans: B

60- Cause of decreased cardiac output is
A- Thiamine deficiency
B- Hypervolemia
C- IVC obstruction
D- Anemia
Ans: C

Explanation:
Thiamine, Hypervolemia and Anemia associated with High cardiac output

61- Hypovolemic shock, which will happens 1st
A- Arteriolar constriction
B- Renal absorption increases
C- Venous & venules constrict
D- Venous dilation
Ans: C

62- Which of the following is seen in ankylosing spondylitis?
A- Aortic insufficiency
B- Splinter hemorrhages
C- Mitral valve prolapse
D- Urethritis
Ans: A

63- Main difference between anaphylactic shock and hypovolumic shock:
A- Cardiac output
B- Sepsis
C- Blood lactate levels
D- JVP

64- True regarding carcinoid heart disease is
A- It occurs only in cancers
B- Woman are affected more
C- Thickening of tricuspid valve
D- Thickening of aortic valve
Ans: C

65- Patient present with chest pain On auscultation first heart sound is variable this occur due to which of following
A- Atrial flutter
B- Atrial fibrillation
C- Ventricular tachycardia
D- Ventricular flutter
Ans: B

Explanation:
Loud S1 causes
- Mitral stenosis
- Hyperdynamic state (Fever and exercise)

Soft S1 causes
- Mitral regurgitation
- Tachycardia

Variable intensity S1
- Atrial fibrillation
- Complete heart blocks

66- A patient has presented to you in ER with vasodilation and hypotension. Which type of shock is causing this
A- Septic shock
B- Hypovolemic
C- Cardiogenic
D- Vasovagal
Ans: A

67- Sodium retention is seen in which condition
A- Heart failure
B- Vasopressin
C- Addison's disease
D- Water Intoxication
Ans: A

68- Polyarteritis nodosa diagnosis by
A- Coagulative necrosis
B- Fibrinoid necrosis
C- Caseous necrosis
D- Liquifective necrosis
E- Fatty necrosis
Ans: B

69- In neurogenic shock, the difference from other shocks is
A- Increased cardiac output
B- Cold moist skin
C- Decreased total peripheral resistance
D- Increase urine output
Ans: C

70- A patient presented with signs of hypovolemic shock and received treatment for this very cause What indicator should be assessed for initial recovery in him?
A- Increase CO
B- Increase HR
C- Increase Urine output
D- Edema
Ans: C

71- Patient presented with central chest pain O/E rustling sound heard on inspiration structure involved is
A- Myocardium
B- Pericardium
C- Endocardium
D- Sub endocardium
Ans: B

72- Patient known case of severe mitral stenosis came with left atrial enlargement mid diastolic murmur. Loud S1 severe pulmonary HTN and was dyspneic. What is to be expected?
A- Left Ventricular Hypertrophy
B- Both Right and left ventricular hypertrophy
C- Decreased end diastolic volume
D- RVH
Ans: D

73- Child suddenly collapsed in school and died on autopsy Coronary artery aneurysm is found what is the Diagnosis is
A- Kawasaki disease
B- Takayasu disease
C- PAN
D- Viral infection
E- GB syndrome
Ans: A

74- Bicuspid aortic valve associated with
A- Coarctation of aorta
B- Rheumatoid arthritis
C- Achondroplasia
D- Osteoarthritis
Ans: A

75- After abdominal surgery patient presented with hypotension tachycardia tachcypnea abdominal pain and distension cold clammy peripheries. What is diagnosis?
A- Hypovolemic shock
B- Septic shock
C- Cardiogenic shock
D- Neurogenic shock
Ans: A

76- In neurogenic shock which of following occurs
A- Loss of vasomotor tone
B- Loss of vagal tone
C- Increase cardiac output
D- Increase CVP
Ans: A(Guyton)

77- A patient presented after 3 weeks of fever lethargic on examination there is hepatosplenomegally splinter hemorrhage murmur, which investigation appropriate?
A- Blood culture
B- Serology
C- Stool culture
D- ECG
Ans: A

78- A patient suddenly went into respiratory distress his EKG shows S1Q3T3 pattern what is next to being done?
A- Doppler studies
B- Echocardiography
C- HRCT chest
D- X ray chest
E- Gallium scan
Ans: E(Davidson +Kaplan)

79- Plasma proteins are normalized after hemorrhage in how many days
A- 1-3 days
B- 3-4 days
C- 7-10 days
D- 15 days
Ans: B

80- A middle age women with pain in temporal region and pulsation felt in temporal region cause?
A- Takayasu
B- Kawasaki
C- Giant cell arteritis
D- Migraine
E- Cocain abuse
Ans: C

81- Essential hypertension causes which of following
A- Increase cardiac work
B- Brain injury
C- Increase O_2 consumption
D- Vasodilation
Ans: A

82- Long standing hypertension edema occurs due to which of following
A- Increase hydrostatic pressure
B- Endothelial injury
C- Decrease colloidal pressure
D- Endothelial retraction
Ans: A

83- Patient's CHF is worsening what is the cause
A- Increase hydrostatic pressure
B- Decrease hydrostatic pressure
C- Increase oncotic pressure
D- Na & H20 retention
Ans: D(Robins)

Explanation:
- Peripheral Edema in CLD due to - Loss of albumin(Low Oncotic pressure)
- Ascities in CLD due to -Portal HTN
- Renal origin Edema due to -Loss of albumin(Low Oncotic pressure) + Can be salt and water Retension
- Nephrotic Syndrome edema due to - Hypoalbuminemia
- Nephritis Syndrome edema due to - Salt and water retension
- Pedal Edema in CHF and HTN due to - Increase Hydrostatic Pressure
- In CHF edema woarsen by -Sodium and water retension

84- After reperfusion injury free radicals released by which of these
A- Neutrophils
B- Lymphocytes
C- Monocytes
D- Macrophages
E- Plasma cells
Ans: A

85- Which one is Cause of pulmonary edema
A- Right heart failure
B- Left heart failure
C- Pulmonary embolism
D- Pneumonia
Ans: B

86- A patient with left ventricular hypertrophy with significantly increased end diastolic volume. Increased pulmonary wedge pressure with BP mentioned with increase systolic and decreased diastolic value 145/45 and increased aortic pressure. There was early diastolic murmur which was due to
A- Mitral stenosis

CamScanner

B- Aortic stenosis
C- Aortic regurgitation
D- Mitral regurgitation
E- Pulmonary regurgitation
Ans: C

Explanation:
AR – Early Diastolic murmur
AS – Ejection Systolic murmur
MS – Mid Diastolic murmur
MR,TR and VSD – Pansystolic murmur

87- Patient died of MI, on autopsy neutrophils with necrotic area seen after?
A- 12 hours
B- 24 hours
C- 48 hours
D- 78 hours
Ans: B

88- A pregnant woman from kohistan was presented in clinic her ultrasound scan showed a normal fetus. What can still be present in fetus?
A- PDA
B- VSD
C- ASD
D- Anencephaly
Ans: A

89- Heart failure results in which of following
A- Constrictive pericarditis
B- Chyloparicardium
C- Hemoparicardium
D- Pericardial effusion
Ans: D

Explanation:
Hemoparicardium
- Traumatic Rupture
- Rupture aortic aneurysm(Type A)
- Scurvy
- Neoplasm and Leukemia

Chylopericardium
- Obstruction of thoracic duct
- Obstruction of SVC

Pericardial effusion
- Heart failure
- Viral Myopericarditis
- Metastatic malignancy
- Renal failure

90- Which of the following causes transudate production by increased hydrostatic pressure
A- MI
B- CCF
C- Asthma
D- RVH
E- LVH
Ans: B

91- Hypertensive patient come to nutritionist for her diet plan. Which among the following should not give
A- Soup
B- Dates
C- Egg white part
D- Brown bread
Ans. A

92- Type of necrosis as a result of MI
A- Caseous necrosis
B- Liquefactive necrosis
C- Coagulative necrosis
D- Fibrinoid necrosis
Ans: C

93- Esophagus may be compressed by the enlargement of which structure
A- Left atrium
B- Right atrium
C- Left ventricle
D- Right ventricle
Ans: A

94- Notching of rib occurs in which of following
A- Pre ductal coarctation of aorta
B- Post ductal coarctation of aorta
C- Co-arctation of arc of aorta
D- PDA
E- VSD
Ans: B

95- Coarctation of aorta features is
A- Aortic obstruction
B- Common before subclavian division
C- Distal to origin of subclavian
D- Part of aorta wide
Ans: C

96- A patient presented in OPD has a blood pressure of 175/110 taking no antihypertensive. After a few days follow up he has a blood pressure of 170/105. He has no other complains, has risk of developing
A- Tricuspid regurgitation
B- Polyarteritis nodosa
C- Section pulmonary passive congestion
D- Giant cell arteritis
E- Hyperplastic arteriosclerosis
Ans: E

97- A person come with shortness of breath he has been diagnosis with pulmonary edema last week what could be reason
Decrease blood flow
A- Decrease lymphatic flow
B- Increase intravascular pressure
C- Increase oncotic pressure
D-
Ans: C

98- Which of the following is seen in cardiac muscles after irreversible muscle injury
Mitochondrial rupture
A- Nucleus rupture
B- Contraction band necrosis
C- None of the above
D-
Ans: C

99- Type A personality, vulnerable to CAD because of:
A- Alcohol overuse
B- High Cholestrol
C- Low Fats
D- Physiologic stress and increased competitive drive
Ans: D

100- Patient with atrial fibrillation died shows
A- Thrombosis
B- Embolism
C- Hyperplasia
D- Atrophy
E- Hyperplasia
Ans: B

101- A 35 years old male has hypertension for the first time and he dies his autopsy shows a ruptured aneurysm, there is deficiency of media at the site of rupture why he died
A- Berry aneurysm
B- Marfan aneurysm
C- Aortic dissecting
D- Mycotic aneurysm
Ans: C

Explanation:
- Absent Tunica + Type of Aneurysm – Berry Aneurysm
- Absent Tunica + Cause of Death – Aortic dissection
- Absent tunica +Syndrome – Marfan

102- Investigation of choice in infective endocarditis is
A- Blood culture
B- ASO titer
C- Urine culture
D- Bone marrow culture

Transudate	Exudate
Due to CCF, Cirrhosis and Nephrotic syndrome	Infection, Inflammation, Malignancy
Colorless	Prulent or Bloody
Specific gravity <1.015	Specific gravity >1.015
Protein <3g/dl	Protein >3g/dl
Less cell Count	More cell count
Pleura: Serum LDH <0.6	Pleura: Serum LDH >0.6
Pleura: Serum protein <0.5	Pleura: Serum protein >0.5

Ans: A

103- A known case of IHD came with chest pain diagnosed with diastolic murmur with low preload. Its due to
A- Aortic regurgitation
B- Mitral stenosis
C- Tricuspid regurgitation
D- VSD
Ans: B

104- A patient was brought to ER with chest pain for 6 hours, suspicion of M.I Which enzyme raised earliest?
A- CPK
B- LDH
C- ALT
D- AST
E- ALP
Ans: A

105- Most common cause of death in rheumatic fever is
A- Mitral stenosis
B- Endocarditis
C- Pericarditis
D- Myocarditis
Ans: D

106- The most common congenital heart defect is
A- VSD
B- PDA
C- Tetralogy of Fallout
D- Bicuspid aortic valve
E- Osteum secundum
Ans: A

107- A female presented with history of fever since last 10 days now with continuous chest pain that radiates to back and left parasternal rustling sound most likely suffers
A- Myocarditis
B- Pericarditis
C- Endocarditis
D- Pleurisy
Ans: B

CamScanner

108- Inferior wall MI due to blockage:
A- Right marginal
B- RCA
C- LCA
D- LCX
Ans: B (FA, ECG Textbook)

Explanation:
- Right marginal artery in 90% cases goes to apex of heart and don't cover inferior or diaphragmatic surface so it can't produce changes in inferior wall.

109- In lateral wall MI which artery is blocked
A- Right marginal
B- Diagonal artery
C- Right coronary artery
D- Left circumflex
Ans: D(Kaplan +First aid +Davidson)

Explanation:
- Inferior wall MI (RCA) – Leads 2, 3 and AVF
- Anterior wall MI (LAD) – Leads V1-V6
- Lateral wall MI (LCX) – Leads I, AVL, V5 and V6

110- Pansystolic murmur and cyanosis is noticed in a baby after 5 weeks of birth Diagnose is
A- VSD
B- ASD
C- PDA
D- TOF
Ans: A

111- Patient previously had MI now he again came with same condition which marker is useful for reinfarction of myocardium:
A- Trop I
B- Trop T
C- LDH
D- CKMB
Ans: D

112- The finding seen in cardiac tamponade is
A- Kussumal sign is negative
B- Pulsus paradoxus
C- Widened mediastinum
D- Steep Y descent absent
Ans: B

Explanation:
Pulsus Paradoxus
Causes
Cardiac
Cardiac Temponade
Constrictive pericarditis
Restrictive cardiomyopathy
Pericardial effusion
Respiratory
Pulmonary embolism
Severe asthma
Tension Pneumothorax
COPD
Other
Anaphylactic shock
SVC obstruction
Obesity

113- Loud S1 opening snap and mid diastolic rumbling murmur at apex are characteristic finding of which among these
A- Mitral regurgitation
B- Aortic regurgitation
C- Mitral stenosis
D- Tricuspid stenosis
Ans: C

Explanation:
Mitral Stenosis Features
Loud S1
Opening Snap
Mid diastolic murmur
Pre systolic accentuation
Taping Apex beat

114- Prolong QRS complex in Lead 2 indicates
A- Ventricular dystrophy
B- Ventricular arrhythmias
C- Atrial hypertrophy
D- Ventricular hypertrophy
Ans: D

115- Most common cause of infective endocarditis in IV drug abusers is
A- Strep viridians
B- Staph Aureus
C- Strep epidermis
D- Strep hemolyticus
Ans: B

116- Patient with anterior wall MI will most probable show
A- Lead V1-V4 and ST elevation
B- Lead 2, 3 and AVF and ST elevation
C- Lead 2-4 and ST elevation
D- None of the above
Ans: A

117- A young male presented with unequal BP reading in both the arms. On examination visible intercostal pulsation and Xray shows notching of ribs. What is the diagnosis
A- Preductal Aortic Coarctation
B- Postductal Aortic Coarctation
C- Aortic Arch Aneurysm
D- Descending Aorta Aneurysm
E- Aortic Stenosis

118- Systemic arterial emboli are most likely arise from which of following
A- Right atrial mural thrombosis
B- Left atrial mural thrombosis
C- Systemic venous thrombosis
D- Left ventricle mural thrombosis
Ans: D

119- Most common large vessel anomaly is
A- Aortic Dissection
B- VSD
C- PDA
D- ASD
Ans: C

120- Patient with chronic hypertension with decreased visual acuity changes in fundoscopy is most likely in which of the following
A- Retinal nerves
B- Vein
C- Arteries
D- Arterioles
E- Pigment epithelium
Ans: D

121- AV septum is ruptured which of following valve is affected most?
A- Bicuspid
B- Tricuspid
C- Aortic
D- Pulmonary
Ans: B

122- A cardiac patient presents to the emergency; on examination he had a collapsing radial pulse alongside diastolic murmur. What is the probable diagnosis
A- Aortic stenosis
B- Mitral stenosis
C- Mitral Regurgitation
D- Aortic Regurgitation
E- Mitral Valve Prolapsed
Ans: D

123- A patient presented with Chest pain from 6 hr ECG findings shows U waves, inverted T Waves Seen in
A- Hyperkalemia
B- Hypokalemia
C- Hypocalcemia
D- Hyperglycemia
Ans:

124- Acute left sided chest pain, Trop I, CKMB normal, posterior 5th 6th intercostal tenderness, what is the problem
A- MI
B- Angina
C- Costochondritis
D- Pleural effusion
Ans: C

125- 44yrs female has lost weight over 12 months, she has noticed episodes where her heart beats rapidly and strongly, her pulse is 90bpm and regular, enlarged goiter and her ECG shows sinus rhythm. What is her problem
A- Ventricular tachycardia
B- Paroxysmal atrial fibrillation
C- Pulmonary embolism
D- Anxiety disorder
Ans: B

126- Patient presented with chest pain, O_2& NG given next best step is
A- Coronary Angiography
B- Medications
C- Trade mill exercise test
D- Enzyme Level
Ans: D

127- Vasculitis features with purpura on the buttocks in a child seen in which of these
A- HSP
B- Arthritis
C- SLE
D- Sjogren Syndrome
Ans: A

128- Cushing triad consists of bradycardia, increase icp and one of the following
A- Hypotension
B- Hypertension
C- Malignancy
D- Regular Respiration
Ans: B

129- Septic shock differs from hypovolumic shock in
A- Cardiac output
B- Urinary output
C- Blood pressure
D- Pulse
Ans: A

130- The main difference between Anaphylactic shock & hypovolumic shock is
A- Decrease CO
B- Increase CO
C- Increase TPR
D- Vasoconstriction
Ans: B

CamScanner

Explanation:

- In Hypovolumic shock there's decrease blood volume leading to decrease venous return & decrease EDV, Decrease SV and hence Decrease Cardiac Output.
- In Anaphylactic Shock there is peripheral vasodilation leading to decrease Blood Pressure that in turn through baroreceptors increase HR & CO.

131- In dilated cardiomyopathy which functions is disturbed:

A- Systolic Dysfunction
B- Diastolic dysfunction
C- Both
D- Hypertrophy
Ans: A

Explanation:

- In dilated cardiomyopathy there's systolic dysfunction.
- In hypertrophic & constrictive cardiomyopathy there's diastolic dysfunction.

132- Middle diastolic murmur, pulmonary HTN and pulmonary edema, which of the following the patient will most likely develop

A- Right ventricular Hypertrophy + LVH
B- Right Ventricular hypertrophy
C- Right atrial hypertrophy
D- Left atrial hypertrophy
Ans: B

Explanation:
This is the case of Mitral stensosis & due to back pressure the patient is at risk of developing RVH (Right ventricular Hypertrophy).

133- Which of the following is most commonly associated with smoking

A- PAN
B- Thromboangitis Obliterns
C- Kawasaki Disease
D- Giant cell arteritis
E- Basal cell carcinoma
Ans: B

134- Pregnant lady on hilly area which of the following cardiac defect can be seen in the baby

A- ASD
B- VSD
C- PDA
D- TGA
Ans: C

Explanation:
As ductus arteriosus needs high tension oxygen post birth, to close and there's low partial pressure of Oxygen in hilly areas thus that will lead to Patent ductus arteriosus (PDA).

135- End arteries are present in

A- Spleen
B- Brain
C- Kidney
D- Retina
E- Heart
Ans: D

Explanation:
Functional end arteries – Heart
Anatomical / True end arteries – Retinal artery
END arteries are present in – Central retinal artery >> Spleen >> Heart

136- A patient with History of fracture after a while developed crepitus, foul smelling discharge with low BP what is cause

A- Hypovolemic Shock
B- Cardiogenic Shock
C- Anaphylactic Shock
D- Toxemic Shock
Ans: D

137- Old man died of MI five days back, on autopsy which of the following cells will be found?

A- Macrophages
B- Neutrophils
C- Eosinophils
D- Basophils
Ans: A

138- Which of the following is correct sequence in Infective endocarditis?

A- Damaged valve, thrombosis, Bacteremia, Perforation.
B- Damaged Valve, Bacteremia, thrombus & perforation
C- Bacteremia, Perforation & thrombus
D- Perforation & Bacteremia
Ans: A

Explanation:
Remember DTBP for the sequence (Damaged Valve, Thrombosis, Bacteremia & Perforation).

139- Anterior wall MI, Left ventricle damaged which of the following artery is involved

A- RCA
B- LAD
C- PAD
D- Right marginal artery

140- Which artery leads to posterior wall MI?

A- RCA
B- LCA
C- Cirumflex
D- Marginal artery
Ans: A

141- A patient alcoholic presented with Nutmeg liver with raised JVP and hepatic congestion, likely cause is

A- Chronic Alcoholism
B- RHF
C- Passive Congestion
D- Periportal congestion
Ans: A

Explanation:
Cause is Chronic Alcoholism. While condition is RHF due to distended neck veins.

142- Diabetic, smoker, increased cholesterol with increased LDL is at a risk of

A- Atheroma
B- Atherosclerosis
C- Kidney Failure
D- Liver Failure
Ans: B

143- Hypertrophic cardiomyopathy typical feature is

A- Myocyte Necrosis
B- Myoctye disarray
C- Systolic Dysfunction
D- Decrease TPR
Ans: B

Explanation:
HOCM has following features

- Myocyte disarray
- Nuclear Enlargement and Binucleation
- 3 type of fibrosis
- Interstitial or plexiform fibrosis
- Replacement or Scar fibrosis
- Perivascular fibrosis

144- In essential hypertension which of the following is increased

A- Increase Oxygen demand
B- Increase size
C- Increase Work load
D- Increase cardiac output
Ans: C

145- In a cardiac patient which of the following is the cause of edema?

A- Increase Plasma Oncotic pressure
B- Decrease Hydrostatic pressure
C- Increase Hydrostatic pressure
D- Decrease vascular permeability
Ans: C

146- Which of the following murmur is heard in rheumatic fever?

A- Pansystolic
B- Early diastolic
C- Early systolic
D- Systolic clicks
Ans: A

147- A 20 years old boy with rheumatic valvular heart disease has been running a low grade fever for the last two weeks. In addition to a pansysotlic murmur, he is found to have splenomegaly and clubbing, the treatment should be

A- Inj. Cefotaxime + Metronidazole
B- Inj. Ceftriaxone
C- Inj. Penicillin
D- Inj. Penicillin + Gentamycin
E- Inj. Ciprofloxacin
Ans: D

148- 50 years old hypertensive patient presented with severe pain radiating towards back suddenly collapsed. On Autopsy what could be seen

A- Ischemic Necrosis
B- Medial Necrosis
C- Atherosclerosis
D- Arterioscleorsis
Ans: B

Explanation:
Aortic dissection commonly results from hypertension; chronic hypertension causes hyaline arteriosclerosis of vasa vasorum that supply media and leads to necrosis of media and weakness in vessel wall leading to tear & dissection.

149- A patient after RTA presented with low Blood pressure due to which of following

A- Hypovolemic shock
B- Septic shock
C- Cardiogenic shock
D- Cardiac Tamponade
Ans: A

150- Inflammation marker that is related to Ischemic heart disease

A- PGE1
B- CRP
C- C3b
D- Integrins
Ans: B

151- A chronic pressure overload in the left ventricle due to aortic stenosis results in which of following

A- Altered left ventricle distensibility
B- Decreased contractility
C- Left ventricular dilatation
D- Left ventricular hypertrophy
E- No change

CamScanner

152- The low voltage QRS complexes commonly represent which one of the following
A- Acute MI
B- LVH
C- RVH
D- Old MI
Ans: D

153- What takes place in neurogenic shock
A- Decrease peripheral vascular resistance
B- Increase peripheral vascular resistance
C- Increase Heart Rate
D- Increase Cardiac Output
Ans: A

154- A point that distinguishes partial transection of the spinal complete transection
A- Spinal shock
B- Bladder atonia
C- Increase reflexes
D- Diminish reflexes
Ans: A

155- The shock associated with pelvic fracture is owing to
A- Blood loss
B- Fat embolism
C- Anaphylaxis
D- Cardiogenic shock
Ans: A

156- The infarct of the posterior septum would cause injury to which cardiac structure
A- AV node
B- SA node
C- Bundle of His
D- Purkinje fibers
Ans: A

157- Puerperal sepsis not responding to IV fluids is usually responsive to which of these
A- IV antibiotics
B- IV steroids
C- IV vasoactive agents
D- IV antiviral agents
Ans: A

158- Endotoxic shock is initiated by which among these
A- Endothelial injury
B- Peripheral vasodilation
C- Increase vascular permeability
D- Cytokine action
Ans: D

159- High output cardiac failure is found in
A- Anemia
B- Beri beri
C- Hypothyroidism
D- Low blood pressure
E- Vitamin D deficiency
Ans: B

160- New born baby was alright for 6hrs after that she developed blue discoloration of lips and hands. Diagnosis is
A- Tetralogy of fallot
B- VSD
C- Transposition of great vessel with no shunt
D- PDA
Ans: C

Explanation:
Not compatible with life unless a shunt is present to allow mixing of blood. Most infants die within the 1st few months of life.

161- Omphalocele is associated with which of following cardiac anomaly
A- Transportation of vessel
B- Coartation of Aorta
C- VSD
D- ASD
E- TOF
Ans: C

162- In anaphylactic shock what changes occur in patient?
A- Hyperpyrexia
B- Arteriolar and venous vasodilation
C- Vasoconstriction
D- Low CO
Ans: B

163- Common congenital heart disease is:
A- ASD
B- VSD
C- TOF
D- PDA
E- Eissenmenger
Ans: B

164- A Young man with heart failure and B/L pleural effusion, in Pleural tap which cells are present in heart failure?
A- Lymphocytes
B- Heart failure cells
C- Macrophages
D- Basophills

165- What will raise in acute myocardial infarction?
A- Myoglobin
B- CkMM
C- CPK
D- LDH
E- CKBB
Ans: A

Explanation:
Best Initial Investigation of choice for
6h – ECG
1-2hr – Myoglobin
Within 4hr – CK MB
After 4hr – Trop
Sensitive – Trop T
Specific – Trop I

166- A patient having Tachycardia abdominal distension and hypotension after laparotomy due to which of these
A- Hypovolumic Shock
B- Septic Shock
C- Cardiogenic Shock
D- Anaphylactic Shock
E- Neurogenic Shock
Ans: A

167- A patient presented with chest pain, left ventricular hypertrophy, On auscultation early diastolic murmur, pulmonary edema is due to:
A- AR
B- MR
C- AS
D- MS
E- TR
Ans: A

Explanation:
AR – Early Diastolic murmur
AS – Ejection Systolic murmur
MS – Mid Diastolic murmur
MR,TR and VSD – Pansystolic murmur

168- 45 year old diabetic lady since 10years admitted in hospital due to pneumonia and developing shock like symptoms cause will be:
A- Increased vascular permeability
B- Increased vasoconstriction
C- Increased peripheral resistance
D- Increase hydrostatic pressure
E- Decrease permeability
Ans: A

169- A patient with Cardiac abnormality fascial anomlies thymic aplasia hypocalcemia and cleft palate all are features of
A- CATCH 22
B- IgA Deficiency
C- Edward Syndrome
D- Cri du chat syndrome
Ans: A

170- A Person taken to siachen 12000 feet from sea level develops dyspnea post 12 hours most likely due to:
A- Secondary polycythemia
B- Pulmonary edema
C- Airway obstruction
D- Inflammation
E- Infection
Ans: B

Explanation:
Within 24hr Symtoms – Pulmonary edema.
After 5-6 months Symptoms on returning – Secondary polycythemia

171- Most common cause of thoracic aortic dissection in hypertensive patients?
A- Atherosclosis
B- Increase vascular Resistantce
C- Atherosclosis
D- Medial degeneration
Ans: D

172- A patient on ECG there is absent P wave but normal QRS complex where is the pacemaker located?
A- SA node
B- AV node
C- Parkine fibers
D- Bundle of His
Ans: B

173- Vasculitis that involves same vessel or different vessels with lesion of different ages is which among these
A- Kawsaki disease
B- PAN
C- Giant cell arteritis
D- Temporal Cell arteritis
E- Polyangitis
Ans: B

174- Right ventricular pressure at which pulmonary valve open is?
A- 0.5mmHg
B- 30mmHg
C- 8mmHg
D- 100mmHg
E- 40mmHg
Ans: C

Explanation:
R ventricle Pressure during Systole – 25
R ventricle Pressure during Diastole – 0 – 8
R ventricle Pressure at which Pulmonary Valve Open – 8mmhg
L ventricle Pressure at which Aortic Valve Open – 80mmhg

CamScanner

175- After a road traffic accident massive blood loss patient undergoes shock BP 85/40 what will activate now:

A- RAAS
B- CNS Ischemic response
C- Release of Renin
D- Baroreceptor reflex mechanism
Ans: B

Explanation:
MAP is calculated as

- PP =Systolic -Diastolic =85-40=45
- 1/3rd of PP =15
- MAP=Diastolic BP + 1/3rd PP
- 40 +15=55
- Baroreceptor respond maximally to – Increasing BP (Ganong).
- Most rapid response to decrease BP – Baroreceptor.
- Most potent response to decrease BP – CNS Ischemic.
- CNS ischemic activate at – 60 or below 60mmHg (Guyton).
- Maintain During Shock – Baroreceptor
- Maintan As a whole – RAAS
- Short Term BP control – Baroreceptor
- Long Term BP control – RAAS

176- 1 year old child presents to you with failure to thrive, progressive cyanosis, tachypnea and left ventricular hypertrophy, which of the following defects are you suspecting?

A- TOF
B- Ebstein's anomaly
C- TAPVR
D- ASD
Ans: A

177- Infective Endocarditis occur commonly in:

A- Immunocompitent
B- Diabetics
C- IV drug Abuser
D- Neutrophilia
Ans: C

178- The extra systolic beat would produce:

A- Increase pulse pressure because contractility is increased.
B- Increase pulse pressure because HR is increased
C- Decrease pulse pressure because ventricular filling is increased
D- Decrease pulse pressure because SV is decreased
E- Decrease pulse pressure because the PR interval is increased
Ans: D

Explanation:

- Extra systole will cause – Decrease pulse pressure.
- Normal beat after extra systole cause – Increase pulse pressure.

179- A patient after RTA with multiple ribs fracture which of the following must be the first treatment?

A- Fluid Replacement
B- Blood Replacement
C- Platelets
D- FFPs
E- Whole Blood
Ans: A

180- A patient who was admitted to a hospital and Got operated. On 8th post-operative day he suddenly developed dyspnea most likely pathology will be:

A- Pulmonary edema
B- Pulmonary embolism
C- Amniotic Fluid embolism
D- Septic shock
E- Air Embolism
Ans: B

Explanation:

- Air Embolism – History of Passing CVP then SOB
- Pregnant lady + Long bone fracture + Died on way to hospital within 24h or during labour – Amniotic fluid embolism
- Sudden death + Sudden SOB – Pulmonary Embolism
- Long bone fracture – Death after 3-5 days – Fat embolism

181- Thromboembolism is most commonly arising from which area

A- Leg
B- Liver
C- Brain
D- Kidney
E- Spleen
Ans: A

Explanation:

- Thromboembolism arises from Deep Veins of Leg and then Embolus go to brain So Embolism occur in Brain then
- Thromboembolism -Femoral Vein
- DVT – Popliteal Vein

182- A Person Stands from Supine position what will maintain MAP?

A- Proprioceptors
B- Mechanoceptors
C- Baroreceptors
D- Chemoreceptor
E- Electroreceptor
Ans: C

183- A 50 year old nonsmoker with recurrent chest pain and angina like symptoms also systolic murmur this is related to heart valve. Most likely heart valve disease that cause angina like pain is:

A- PS
B- MS
C- AS
D- MR
E- TR
Ans: C

184- 10 yrs old child with history of aortic aneurysm and sudden chest pain due to:

A- Coarctation of aorta
B- Esophgeal spasm
C- Kawasaki disease
D- Marfan syndrome
E- Aortic Aneurysm
Ans: C (FA)

185- A known diabetic patient with good glycemic control presented with sign and symptoms of UTI by gram negative rod and shock like state, which of the following is responsible for the shock like state of this patient:

A- Increase Vascular Permeability
B- Decreaae Permeability
C- Endotoxic Shock
D- Exotoxic Shock
Ans: A

186- A boy met a road traffic accident, had pelvic fractures. He died before reaching to the hospital. What is the cause?

A- Excessive blood loss
B- Fat embolism
C- Hypotension
D- Amniotic fluid embolism
E- Hypertension
Ans: A

187- Newborn baby having difficulty in breathing, and poor skin colour, this is due to:

A- Muscular VSD
B- Septum secondum defect
C- Transposition of great arteries
D- TOF
E- ASD
Ans: C

188- A Patient died in ER with long standing pulmonary congestion due to mitral stenosis on autopsy the alveoli will be lined by which of the following?

A- Serosa cells
B- Heart failure macrophages
C- Type 1 pneumocytes
D- Type 2 pneumocytes
E- Lymphocytes
Ans: B

189- A person lost 1 litre of blood in 5 minutes what will occur?

A- Decrease Diastolic BP
B- Decrease TPR
C- Increase venous return
D- Decrease HR
Ans: B

190- A patient on beta blocker presented with prolong PR interval which of the following could be the possible cause is which of following?

A- Drug induced 1st degree heart block
B- 2nd Degree heart block
C- Complete heart block
D- Sinus tachycardia
E- Complete block
Ans: A

191- After 5 days post MI the most prominent cells are:

A- Neutrophils
B- Macrophages
C- Monocytes
D- Lymphocytes
E- Plasma Cells
Ans: B

192- New channel formation in a thrombus of a granulation tissue is done so that thrombus can be removed due to which of the following process?

A- Recanalization
B- Collateral circulation
C- Organization
D- Neoplasia
E- Endothelization
Ans: A

193- A patient in cardiac diastole having back flow of blood which is heard as murmur this is which of following murmur?

A- Ejection Systolic murmur
B- Mid Diastolic murmur
C- Early Diastolic murmur
D- Pansystolic murmur
E- Machinery murmur
Ans: C (Aortic Regurg)

Explanation:

- **AR** – Early Diastolic murmur
- **AS** – Ejection Systolic murmur
- **MS** – Mid Diastolic murmur
- **MR, TR and VSD** – Pansystolic murmur

CamScanner

194- Atrial fibrillation Related ECG findings are which of following?
A- Absent P-Waves
B- Irregular R-R Interval
C- Regular R-R Interval
D- Prominent QRS
E- Narrow P-R interval
Ans: B >A

195- Atrial septal defect is due:
A- Osteum secundum
B- Ostium premium
C- Failure of Osteum primum
D- Failure of Septum primum
Ans: A

196- The semilunar valve opening is seen at the beginning of:
A- Reduced ejection
B- Isovolumetric contraction
C- Isovolumetric relaxation
D- Rapid ejection
Ans: D

197- A Patient having 2 p wave followed by QRS complex due to which of following?
A- Fast SA Node Conduction
B- Decreased AV nodal conduction
C- Decrease conduction in purkinji
D- Slow ventricular pacemaker conduction
Ans: B

198- A patient has RTA 1.5L blood was lost which will occur first?
A- Decrease RBC count
B- Decrease MCV
C- Decrease Hematocrit
D- Decrease BP
E- Decrease Hb
Ans: D

Explanation:
Hemorrhage class

Parameters	Class I	Class II	Class III	Class IV
Blood loss (ml)	0-750	750-1500	1500-2000	>2000
Blood loss (%)	0-15	15-30	30-40	>40
Pulse	<100	>100	>120	>140
B.P	Unchange	Unchange	Decrease	Decrease
Orthostasis	Absent	Minimal	Marked	Marked
Capillary Refill	Normal	Delayed	Delayed	Delayed
UO (ml/h)	>30	20-30	5-15	<5
CNS Sign	Slight Anxiety	Mild Anxiety	Anxious/Drowsy	Confuse/Unconsious
R.R	14-20	20-30	30-40	>40

199- Pregnant lady with complain of mitral stenosis develops dyspnea and orthopnea that worsen due to which of the following reason?
A- Pulmonary HTN
B- Left ventricular failure
C- Systolic HTN
D- Atrial fibrillation
E- IVC compression
Ans: A (Davidson)

200- Aortic insufficiency is associated with which of following?
A- Burkit lymphoma
B- Ankylosing spondylitis
C- Rheumatoid arthritis
D- Celiac disease
E- SLE
Ans: B

201- A known case of rheumatic mitral stenosis develops fever lassitude bodyache after tooth extraction dr suspect sub-acute bacterial endocarditis most likely organism in blood culture is:
A- E. coli
B- S Aureus
C- S Viridian
D- H infleunza
E- Streptococus
Ans: C

202- Angina like symptoms occurs in which of following condition?
A- Mitral stenosis
B- Tricuspid stenosis
C- Aortic stenosis
D- Aortic regurgitation
E- Tricusoid regurgitation
Ans: C

203- The BP recording of 2 males, a Hypertensive with reading of 228/160 and a Normotensive with 120/80 were noted respectively. If 10 mmHg is added to the mean BP of both, how will the response of Hypertensive patient vary from that of normal?
A- No change in sympathetic activity of both
B- Increase sympathetic activity in hypertensive
C- Decrease sympathetic activity
D- Increase parasympathetic activity
E- Decrease parasympathetic
Ans: D

204- Atherosclerois plaque which of following 3 found?
A- Smooth muscle, C.T neutrophil
B- Smooth muscle lymphocyte
C- Lymphocytes
D- Smooth muscle, Extracellular matrix, intracellular matrix and lipids
Ans: D (Robins)

Explanation:
- Atherosclerotic Plaque Has 3 Principle Components

Cells
- Smooth Muscle Cells, Macrophages and T cell

Extracellular Matrix
- Collagen
- Elastic Fibers

Lipids
- Extracellular and Intracellular Lipids

205- Moderate hemorrhage can be diagnosed clinically as:
A- Postural dizziness
B- Supine hypotension
C- Postural hypotension in 35 years old
D- Postural hypotension in 65 years old.
Ans: A

205- Patient met an accident and was brought to emergency department. BP 80/40, Tachycardia, Low urinary output after catheterization. Renin was increased due to?
A- Decrease in arterial blood flow
B- Decrease in arterial blood pressure
C- Increase arterial blood flow
D- Increase arterial blood pressure
Ans: A

206- A patient presented with Jaw claudication chronic headache and visual disturbances on examination temporal artery firm and then biopsied which disease is associated with this?
A- Giant Cell arteritis
B- Takayasu arteritis
C- Kawasaki disease
D- PAN
E- Rheumatoid arthritis
Ans: A

207- Large friable irregular vegetation seen in:
A- Libman Sac endocarditis
B- Infective Endocardtitis
C- Terminal Neoplasm
D- Rheumatoid arthritis
Ans: B

Explanation:
- Flat Small to medium Vegetation – Libman Sac Endocarditis
- Friable small Vegetatiom – NBTE
- Friable Large Irregular Vegetation – IE

208- The most significant clinical finding in patient of aortic regurgitation is:
A- Heaving apex beat
B- Femoral bruit
C- Bounding pulse
D- Bradycardia
E- Nail atrophy
Ans: C

209- Neuroendocrine response after surgery is due to?
A- Hemorrhage
B- Toxic stimuli
C- Starvation
D- Nociceptor afferent
E- Intubation
Ans: A

210- Vibrations of ventricles during rapid filling of ventricles show which heart sound?
A- 1st heart sound
B- 2nd heart sound
C- 3rd heart sound
D- 4th heart sound
E- Spliting of sound
Ans: C

Explanation:
- **First heart sound** – Isovolumetric contraction (Closure of mitral and tricuspid valve).
- **Second heart sound** – Isovolumetric relaxation (Closure of aortic and pulmonary valve)
- **Third heart sound** – Rapid ventricular filling (Normal in children, pregnancy and athletes)
- **Fourth heart sound** – Atrial Systole

211- Degranulation of basophilis and mast cells causes what kind of shock?
A- Septic shock
B- Hypovolemic shock
C- Cardiogenic shock
D- Anaphylactic shock
E- Toxic shock
Ans: D

CamScanner

212- A patient Whose ECG is normal, cardiac enzymes normal, x-ray lung field clear but on CT scan 0.5cm calcification found what is related condition and origin of this?
A- Atrial myxoma from left atrium
B- Atrial myxoma from right atrium
C- Pulmojary embolism
D- MI
Ans: A

213- A patient Presented with Chest pan radiating to left arm and diagnosed as MI, which type of shock will be found in this?
A- Hypovolumic shock
B- Septic shock
C- Anaphylactic shock
D- Cardiogenic Shock
Ans: D

214- In early stage of shock aerobic to anaerobic metabolism occur due to:
A- Reduced perfusion
B- Imbalance of O2 supply and demand
C- Depletion of enzymes
D- Low PCV
E- Low Blood volume
Ans: B

215- Streptolysin O is seen in which of these?
A- Rheumatic fever
B- Endocarditis
C- Myocarditis
D- Pericarditis
Ans: A

216- After myocardial injury what biochemical changes will be seen in hypoxia:
A- Aerobic Glycolysis
B- Oxidative Phosphorylation
C- Anaerobic Glycolysis
D- Gluconeogenesis
Ans: C

217- Re-Entry Circuit occur Due to which of the following?
A- Paroxysmal Nodal Tachycardia
B- Atrial Flutter
C- Atrial Fibrillation
D- Systolic Hypertension
E- 2nd Degree block
Ans: A

218- Most common site of atherosclerosis:
A- IVC
B- SVC
C- Aorta
D- Femoral artery
E- Radial artery
Ans: C

Explanation:
Following Vessel involved in descending order (LCP-DIC)
Lower Abdominal aorta
Coronary artery
Popliteal artery
Descending thoracic aorta
Internal Carotid artery
Circle of Willis

219- A Patient after RTA having 8% blood loss in 30 min with no change in arterial pressure which of the following has maximum lost of blood?
A- Aorta
B- Arteries
C- Arteriole
D- Capillary
E- Veins
Ans: E

220- A woman having bacterial infection came with fever, pneumonia and BP 80/60mmHg and increase Heart rate and Cardiac output she goes into shock what is the mechanism of her shock?
A- Neurogenic
B- Septic shock
C- Anaphylactic
D- Hypotensive shock
Ans: B

221- During normal systole, backward flow of blood of heart is seen as:
A- Dicrotic notch
B- Pulsus alterans
C- Pulsus paradoxus
D- Raised JVP
Ans: A

222- In child cause of rheumatic fever is:
A- Group A Streptococcus
B- Group B Streptococcus
C- Staph aureus
D- Streptococcus virdian
E- Streptococcus pneumoniae
Ans: A

223- Patient dies suddenly on autopsy mitral valve is myxodematous with chordae tendiniae broken cause of death is related to which of following?
A- Rheumatic fever
B- Infective endocarditis
D- Mitral valve prolapse
D- VSD
E- Atrial fibrillation
Ans: C

224- A patient Post MI on angiography LCX artery blocked after 3 days which of following will be most abundant in involved area:
A- Histamine
B- VEGF
C- Prostaglandins
D- Leukotriens
E- TGF
Ans: B

225- The most common source of systemic emboli?
A- Right Ventricle
B- Pulmonary vein
C- Right atrium
D- Left ventricular mural thrombosis
E- Popliteal vein
Ans: D

226- A 25 years old male with complain of sob, X-ray shows a large shadow in chest, on echo it was related to right ventricle of heart, containing hemorrhagic and necrotic area:
A- Rhabdomyosarcoma
B- Leiomyoma
C- Myxoma
D- Angiosarcoma
Ans: D

227- A Man dies at 7th day of MI he died due to which of following?
A- Arryhmia
B- Pericardial temponade
C- Viral infection
D- Kawasaki
E- Aneurysm
Ans: B

Explanation:
- 4h Post MI – Arrhythmia
- 4-24h Post MI – Arrhythmia
- 1-3 Days Post MI – Fibrinous Pericarditis
- 4-7 Days Post MI – Cardiac Temponade
- Month Post MI – Aneurysm

228- A boy who is diagnosed with the rheumatic fever and suddenly present with the tricuspid regurgitation murmur will be heard as:
A- Early Diastolic
B- Pansystolic murmur over apex
C- Ejection systolic murmur
D- Midsystolic click
E- Mid Diastolic
Ans: B

Explanation:
AR – Early Diastolic murmur
AS – Ejection Systolic murmur
MS – Mid Diastolic murmur
MR,TR and VSD – Pansystolic murmur

229- Patient in shock reversed phenomena operating will be
A- Metabolic acidosis
B- Metabolic acidosis with respiratory alkalosis
C- Respiratory acidosis
D- Respiratory alkalosis
E- Metabolic alkalosis
Ans: B

Explanation:
- In shock usually Metabolic acidosis occur which is compensated by Respiratory alkalosis
- But in Decompensated progressive shock in which compensatory mechanism fail then it will lead to Metabolic acidosis with respiratory acidosis
- In shock reverse phenomenon – Metabolic acidosis with Respiratory Alkalosis
- In Decompensated shock where reverse phenomenon fail – Metabolic acidosis with Respiratory acidosis

230- Inferior wall MI due to blockage in which of following artery?
A- Right Marginal
B- LADA
C- LCA
D- LCX
E- PDA
Ans: A (No option of RCA if present prefer RCA)

231- A young female presented with fever for last 10 days and continuous chest pain unrelated to respiration the likely cause related to
A- Mycardium
B- Pericardium
C- Pleurisy
D- Chostrochonditis
E- Sub endocardium
Ans: A

Explanation:
- Rustling sound /pericardial Rub – Pericarditis
- Pain unrelated to respiration – Myocarditis

CamScanner

232- If RCA gets blocked after giving Right marginal artery, which portion of heart will be affected?
A- Right atrium
B- SA node
C- Apex of heart
D- Purkinje fiber
E- AV node
Ans: E

233- Which lead to coronary artery disease?
A- Omega 3 fatty acid
B- Omega 6 fatty acid
C- Trans fatty acids
D- Mono unsaturated fatty acid
E- Di unsaturated fatty acid
Ans: C

234- What are the features of hypertrophic cardiomyopathy?
A- Myocytes disarray
B- Binucleation
C- Perivascular fibrosis
D- All
Ans: D

235- In IV drug user's most common involved organism will causes what infections?
A- Osteomyelitis
B- Skin infection
C- Soft tissue infection
D- Infective endocarditis
Ans: D

236- Approach to pericardiocentesis:
A- 2nd ics
B- 5th intercoastal space mid axillary line
C- 5th Left intercoastal space close to sternal angle
D- Between 5th and 6th intercoastal space
Ans: C

237- Acute MI ECG changes:
A- R wave inversion
B- ST segment Elevation
C- Q wave
D- U wave
Ans: B

238- 39 yr old man ad 2 attack of MI and now complaining of bilateral edema, 4 and 5 intercostal nodule ascites liver tenderness on examination shifting dullness positive:
A- CHF
B- Chronic cirrhosis
C- Low protein
D- High protein
Ans: A

239- 3rd heart sound due to:
A- Rushing of blood rapidly in ventricle
B- Contraction of atria over stenotic valve
C- Opening of Semilunar Valve
D- Closure of Mitral Valve
Ans: A

240- Sustained increase of cardiac output occurs in:
A- MR
B- Anemia
C- Aortic regurgitation
D- Atrial fibrillation
Ans: B

241- 65 year old man had sudden onset of severe chest pain for 5hours. He was rushed to the emergency department, his vitals were pulse 93b/m, temp 98•F RR 23/'m, BP 130/85mmHg. ECG was performed which showed ST segment elevation in V1-V6. Which of the following markers would be raised in this patient?
A- Trop I
B- LDH
C- CK-MB
D- Myoglobin
Ans: A

Explanation:
Best Initial IOC for first 6H– ECG
1-2hr – Myoglobin
Within 4hr – CK MB
After 4hr – Trop
Sensitive – Trop T
Specific – Trop I

242- Old age woman with hx of IHD presented with irregular heart beat and abnormal QRS complex. What is the drug of choice for her?
A- Amiodarone
B- Lidocaine
C- Digoxin
D- Beta blockers
Ans: B

243- Patient having diabetic retinopathy & IHD develop chest pain due to:
A- Thrombosis
B- Coronary artery disease
C- Embolism
D- DVT
Ans: B

Explanation: Coronary artery disease which is due to Thrombosis so B >A

244- Cardiac output decrease in:
A- Hypertension
B- Anaphylactic Shock
C- Heart failure
D- Exercise
Ans: C

245- Hyponatremia with increased ECF cause is:
A- Excessive water intake
B- ADH excess
C- CCF
D- CLD
Ans: C (Kaplan)

Explanation:
- Hypervolumic Hyponatremia – CCF, Nephrotic syndrome and Cirhosis.
- Euvolumic Hyponatremia – Excess water intake (Polydipsia), Hypothyroidism
- Hypovolumic Hyponatremia – Vomiting, Diarrhea and Sweating.

246- 18 year old girl died suddenly and unexpectedly only headache history 2 Days back on autopsy lymphocytes in myocardium heart valve normal:
A- Pericarditis
B- Coxsackie
C- Myocarditis
D- Adeovirus
Ans: B

247- Ashcoff bodies generation initial stage:
A- Fibrosis
B- Epithelioid
C- Fibrinoid degeneration
D- Plasma cells
Ans: C

Explanation:
- **Early Exudative phase** – Collection of fibrinoid material on swollen collagen called fibrinoid degeneration
- **Classic Phase** – Central focus of fibrinoid change is surrounded by leukocytes, fibroblasts and histocytic cell called Anitschkow Myocyte.
- **Late Phase** – Progressive fibrosis

248- A patient presented with chest pain and on auscultation doctor find early diastolic murmur:
A- AR
B- MS
C- MR
D- TR
Ans: A

249- A young girl in supine position with bp 80/50 and pulse 100 when she stand her pulse rate increase to reason for this increase in pulse?
A- Decrease contractility of heart
B- Decrease venous return to heart
C- Decrease Sympathetic
D- Increase TPR
Ans: B

Explanation:
When a person stand from supine there will be decrease venous return and in compensation baroreceptor will decrease firing rate and sympathetic outflow increase which cause increase HR and increase cardiac output

250- In ECG complete ventricular depolarization shows
A- QRScomplex
B- ST segment
C- PT interval
D- TP segment
Ans: B

Explanation:
Complete ventricular depolarization – ST segment
Ventricular depolarization – QRS

251- Murmur heard in patient of mitral regurgitation is:
A. Systolic murmur
B. Diastolic murmur
C. Pansystolic murmur
D. Continuous machinery murmur
Ans: C

Explanation:
AR – Early Diastolic murmur
AS – Ejection Systolic murmur
MS – Mid Diastolic murmur
MR,TR and VSD – Pansystolic murmur

252- Characteristic of murmur heard in PDA:
A- Pansystolic murmur
B- Diastolic murmur
C- Systolic murmer
D- Machinery murmur
Ans: D

253- A young patient was brought to the ER in a state of shock with pulse rate of 150/min, bp 70/50,GCS 13/15 after road traffic accident X-ray shows fracture of pelvic bone, the culprit responsible for low BP is:
A- Loss of vasomotor tone
B- Excessive blood loss
C- Fat embolism
D- Stasis of blood in venous pool
Ans: B

CamScanner

254- ECG of a patient who is on potassium sparing diuretics will show:
A- U waves
B- Tall T waves
C- Osborn waves
D- Q waves
Ans: B

255- Myocyte disarray is seen in:
A- DCM
B- HOCM
C- Restrictive cardiomyopathy
D- Mitral stenosis
Ans: B

256- Most specific finding of pericarditis:
A- ST elevation
B- ST depression
C- PR depression
D- T wave inversion
Ans: C(Davidson)

257- St depression in V2 and V3 and R wave:
A- Anterior wall MI
B- Lateral wall MI
C- Posterior wall MI
D- Inferior wall MI
Ans: C

258- A patient presented with raised JVP, right ventricular hypertrophy and neck vein distended most likely
A- Right heart failure
B- Contractive pericarditis
C- Pulmonary artery atherosclerosis
D- Cardiac temponade
Ans: A

259- MRI brain, cystic swelling, what is origin of left atrial myxoma?
A- SA node
B- Foramen ovale
C- Fossa ovalis
D- Left ventricle
Ans: C

260- C-wave on jvp is corresponding to:
A- Atrial contraction
B- Atrial fibrillation
C- Right ventricular contraction
D- Constrictive pericarditis
E- Rapid ventricular ejection
Ans: C

Explanation:
- **A wave** – Atrial Contraction
- **C wave** – Right ventricle contraction (Closed tricuspid valve bulging into atrium)
- **X descent** – Closed Tricuspid Valve downward displacement during rapid ventricular ejection phase
- **Absent X descent** – RHF and T.R
- **V wave** – Increase Right atrial pressure due to fillin against closed tricuspid valve
- **Y descent** – RA emptying into RV
- **Slow Y descent** – T.S
- **Rapid Y descent** –Constrictive pericarditis
- **Absent Y descent** – Cardiac temponade
- **Prominent A wave** – T.S, P.S And pulmonary HTN
- **Giant A wave** – AV Dissociation, Complete Heart block
- **Prominent V wave** – T.R

261- Most common sequele of rheumatic heart disease:
A- Tricuspid regurgitation
B- Aortic stenosis
C- Mitral stenosis
D- Aortic regurgitation
Ans: C (Most commonly involve heart valve are mitral > aortic > tricuspid)

262- A patient had chest pain died few hours after MI what is the cause of death?
A- Interventricular Septal rupture
B- Papillary muscle rupture
C- Cardiac arrhythmia
D- Ventricular pseudoaneurysm
Ans: C

263- Area for mitral valve auscultation:
A- Right second intercostal space
B- Left second intercostal space
C- Left arsenal border
D- Midclavicular line of fifth intercoastal space
Ans: D

264- MI of posterolateral surface of heart. Vessel involved?
A- Posterior ventricular artery
B- Posterior interventricular artery
C- Left circumflex
D- LADA
Ans: C

265- Libman sac endocarditis associated with SLE affect which valve commonly:
A- Mitral and Aortic valve
B- Mitral and Triscupid valve
C- Pulmonary Valve
D- Aortic Valve
Ans: A (First aid)

266- ECG of patient shows progressive prolongation of PR interval in successive beats followed by dropped heart Beat patient is suffering from?
A- Mobitz 1 AV block
B- Mobitz 2 AV block
C- Atrial flutter
D- Complete AV block
E- 1st degree AV block
Ans: A

267- 45 years female was on prolonged bed rest and now she is having shortness of breath and peripheral edema with Nutmug liver Her chest X-ray shows many areas of infarction:
A- Massive pulmonary embolism
B- Recurrent pulmonary embolism
C- Left Heart Failure
D- Pulmonary Edema
E- Stroke
Ans: B

Explanation:
It is recurrent pulmonary embolism because in x ray areas of infarct shows previous history of mild pulmonary infarction and patient is also having peripheral edema a major risk factor for dvt which leads to embolism and also look for signs of right heart failure (cor pulmonale) secondary to chronic pulmonary disease recurrent thromboembolism.

268- ECG shows prolonged PR interval without any other finding:
A- Atrial fibrillation
B- Atrial Flutter
C- First degree heart block
D- Complete heart block
Ans: C

269- Which of the following is the site of septic shock?
A- Gastrointestinal system
B- Cardiovascular system
C- Genitourinary system
D- Pulmonary system
Ans: C

270- Patent ductus arteriosus associated with:
A- Maternal age
B- Prematurity
C- Drugs
D- CO_2
Ans: B

271- Female patient with b/l pleural effusion and dyspnea and having pedal edema:
A- Recurrent thromboembolism
B- DVT
C- CHF
D- CLD
Ans: C

272- In response to hemorrhage what will decrease?
A- HR
B- Oxygen
C- Venous Capacitance
D- Urine Flow
Ans: C

Explanation:
- In response to haemorrhage – Venous Capacitance Decrease
- After Compensation of haemorrhage – Decrease – HR
- After successful Resuscitation of Haemorrhage – Increase urine output.

273- Common presentation of pulmonary emboli is:
A- Clinically silent
B- Pulmonary HTN
C- Pulmonary Infarct
D- Edema
Ans: HA

274- First sign of irreversible injury in cardiac muscles:
A- Massive Na influx
B- Contraction band in cytoplasm
C- Increase Neutrophil
D- Decrease Calcium
Ans: B

275- Interventriculer septum is damaged which of the following valve most commonly affected?
A- Aortic
B- Pulmonary
C- Tricuspid
D- Mitral
Ans: C

276- 10 year child having cyanotic spells on exertion most common anomaly:
A- VSD
B- TOF
C- ASD
D- TGA
Ans: B

277- In TOF what is found?
A- Ventricular septal defect
B - Right Atrial hypertrophy
C- Left ventricle hypertrophy
D- Aorta associated with right ventricle
Ans: A

Explanation:
- TOF consist of
- Ventricular septal defect
- Right ventricular hypertrophy
- Pulmonary stenosis
- Overriding aorta

278- 40 year old patient with edema, productive cough and orthopnea Diagnose is:
A- Hypoproteinemia
B- CCF
C- MI
D- Nephrotic syndrome
Ans: B

279- Anaphylactic reaction characteristic feature:
A- Bronchodilation
B- Hypertension
C- Bronchospasm
D- Bradycardia
Ans: C

280- Atrial Contraction is shown by which JVP wave?
A- C wave
B- A wave
C- X Descent
D- V wave
Ans: B

281- A patient has presented with cyanosis increased A-a gradient likely diagnose is:
A- VSD
B- PDA
C- ASD
D- TOF
Ans: D(BRS
Explanation:
Increase A-a Gradient Seen in:
- 1-Fibrosis
- 2-V/Q Defect
- 3-R-L Shunt
- TOF has Right to Left Shunt
- A-a Gradient Normal Value – 0 -10mmhg
- A/a Ratio Normal – 0.8(>0.75)

282- Neurotransmitter given in cardiogenic shock:
A- Dopamine
B- NE
C- Epinephrine
D- Atropine
Ans: A
Explanation:
- Cardiogenic Shock – Dopamine
- Cardiac Arrest – Epinephrine
- Bradycardia – Atropine

283- For CVP, right atrium level taken at:
A- 4th ICS mid axillary line
B- 4th ICS anterior axillary line
C- 5th ICS mid axillary
D- Manubriosternal angle

284- Patient from hill station having labour pain HCG done. Fetus normal. Still which anomaly can be at greater risk?
A- PDA
B- VSD
C- ASD
D- TOF
Ans: A

285- Ventricle septum wall thicker than Ventricle wall seen in
A- Dilated cardiomyopathy
B- Restrictive cardiomyopathy
C- Hypertrophic cardiomyopathy
D- Cardiac temponade
Ans: C

286- Common Cyanotic heart disease is:
A- ASD
B- VSD
C- TOF
D- PDA
E- Eissenmenger
Ans: C

287- Patient presented with SOB and pink fluid with no RBC and WBC in alveoli occurs in what is reason?
A- CCF
B- Obstruction due to tumor
C- Viral infection
D- Lymph block
Ans: A

288- A patient presented to you with mitral valve regurgitation he has most probably which murmur
A- Diastolic murmer
B- Crescendo murmur
C- Ejection systolic mermur
D- Pansystolic murmur
E- Mid diastolic murmur
Ans: D
Explanation:
- AR – Early Diastolic murmur
- AS – Ejection Systolic murmur
- MS – Mid Diastolic murmur
- MR,TR and VSD – Pansystolic murmur

289- A tall young man is performing in circus he has sudden cruciating pain in the chest and lens dislocation what other finding will be there
A- Rheumatic fever
B- Infective endocarditis
D- Mitral valve prolapse
D- VSD
E- Atrial fibrillation

290- In Mitral [illegible]
absent
A- A Wave
B- C Wave
C- V Wave
D- P wave
Ans: A

291- A patient presented with irregular pulse and irregular R-R interval diagnose is
A- VT
B- VF
C- AF
D- Atrial flutter
E- Mitral stenosis
Ans: C

292- An old man collapsed and her ECG shows atrial rate of 75 and ventricular rate of 35 bpm what is the cause
A- Adam stokes
B- AV nodal tachycardia
C- WPW syndrome
D- Atrial prematurity
Ans: A

293- Emboli in venous circulation will lodge in:
A- Aorta
B- Pulmonary artery branches
C- Kidney
D- Heart
E- SVC
Ans: B
Explanation:
- Emboli First go to – IVC >Right atrium
- Emboli first loadge in – Pulmonary artery (Lung)

294- Gaint cell arteritis is associated with which one of the following disease??
A- Polymyalgia rheumatica
B- Takayasu arteritis
C- Kawasaki synd
D- Microscopic polyangitis
Ans: A

295- Patient came in emergency with failing heart DOC in heart fail is
A- Dopamine
B- NE
C- Epinephrine
D- Atropine
Ans: A

long standing pulse and left axis deviation is caused by
A- Aortic regurgitation
B- Arotic stenosis
C- Tricuspid regurgitation
D- Mitral stenosis
Ans: C

297- Aortic regurgitation most significant finding is
A- Bounding pulse
B- Pansystolic murmur
C- Slow pulse
D- Early diastolic murmur
E- Ejection systolic murmur
Ans: D

298- A 3 years baby inhaled something after that he had SOB o/e breath sound on the right were normal while on left side they were absent CXR confirmed foreign body lodged in left lower bronchus diagnose is:
A- Trachea deviated
B- Situs inversus
C- Left bronchus collapse
D- Alveoli collapse
Ans: B

299- Body metabolic response to trauma Skeletal muscle responds by:
A- Decreased proteolysis
B- Increase glucose loss
C- Increase proteolysis
D- No metabolic change
E- Decrease Protein loss
Ans: C

300- Systolic phase of cardiac cycle correspond to the following component of ECG:
A- QRS complex
B- QR interval
C- ST segment
D- PR Segment
E- QT/RT
Ans: E
Explanation:
- **P wave** – Atrial Depolirization
- **PR Interval** – Shows Atrial Depolirization to Ventricular Depolirization. It Represent time needed for impulses to reach from SA Node to Ventricle(From SA node through Atria , AV node , Bundle of His , Bundle branches and Purkinji to ventricle)
- **QRS Complex** – Ventricular depolirization

CamScanner

- **ST Segment** – Complete Ventricular Depolirization
- **QT Interval** – Represent Entire Systolic phase
- **T Wave** – Ventricular Repolirization
- **U Wave** – Papillary Repolirization

301- A female had aortic root dilation upto 4cm, ocuular examination showed lens dislocation. mitral valve leaflet defect with a systolic click defect in which of the following?

A- Acquired deficiency of fibrillin
B- Inherited deficiency of fibrillin
C- Inherited deficiency of laminin
D- Acquired deficiency of Spectrin
Ans: B

302- Pregnant lady with labor pain and obstructed labour was taken to the hospital but Died before reaching to hospital most likely cause is:

A- Pulmonary Embolism
B- Amniotic fluid embolism
C- Fat embolism
D- MI
E- Sepsis
Ans: B

Explanation:

- Air Embolism – History of Passing CVP then SOB
- Pregnant lady + Long bone fracture + Died on way to hospital within 24h or during labour – Amniotic fluid embolism
- Sudden death + Sudden SOB – Pulmonary Embolism
- Long bone fracture – Death after 3-5 days – Fat embolism

303- Second degree heart block would most likely result in

A- Atrial rate more than ventricular rate
B- Ventricular tachycardia
C- Atrial contraction less than ventricle
D- Bizarre ventricular complexes on ECG
E- Both independent
Ans: A

304- Angiography of patient done LCX was blocked which part of heart is affected ?

A- Anterior part of left ventricle
B- Posterior part of left ventricle
C- AV node
D- IV septum
E- SA node
Ans: B

305- Patient came with SOB rustling sound present labs shows creatinine : 9.8 urea: 150 fluid aspired and cause of this is ?

A- Fibrinous pericarditis
B- Serous pericarditis
C- Cardic Temponade
D- Constrictive pericarditis
Ans: A

306- Patient died of hypertension upon autopsy vessel lacked tunica media type of aneurysm is

A- Dissecting aneurysm
B- Marfan aneurysm
C- Berry aneurysm
D- Aortic aneurysm
E- Rupture aneurysm
Ans: C

307- A patient presented in emergency with chest pain, sweating from 4hr which cardiac marker will be raised?

A- Trop T
B- CK MB
C- Myoglobin
D- LDH
Ans: B

308- A Man dies after 4 hours of MI he died due to which of following?

A- Arrythmia
B- Pericardial tamponade
C- Viral infection
D- Kawasaki
E- Aneurysm
Ans: A

Explanation:

- 4h Post MI – Arrhythmia
- 4-24h Post MI – Arrhythmia
- 1-3 Days Post MI – Fibrinous Pericarditis
- 4-7 Days Post MI – Cardiac Temponade
- Month Post MI – Aneurysm

309- A young male had an RTA which resulted in a femur fracture. He died 5 days later autopsy showed cerebral petechiae. Diagnosis is

A- Sepsis
B- Fat embolism
C- Pulmonary embolism
D- Myocardial dysfunction
Ans: B

310- Patient had an MI on ECG ST elevations in lead II, 111 and AVF are seen, vessel involved?

A- RCA
B- RCx
C- Marginal
D- LCA
E LCx
Ans: A

311- Heart

A- Aortic
B- Tricuspid
C- Pulmonary
D- Mitral
Ans: D

312- Patient present with pansystolic murmur at left sternal border (lower) VSD in

A- Membranous part of the septum
B- Infundibulum part of the septum
C- Trebaculae
D- Papillary muscle
Ans: A

313- Person present with Central chestpain for 3hr which cardiac enzyme will be raised?

A- CK MB
B- CK-BB
C- CPK
D- ALT
E- AST
Ans: A

314. A patient died of fat embolism, on autopsy fat embolism will be visualized by:

A- Frozen section of embolism
B- Frozen section with Silver stain
C- Frozen section with Fat stain
D- Permanent section of silver stain
Ans: C

Explanation:

- Fat embolism can be identified at autopsy through microscopy by using fat stains and conducted on
- frozen tissues of fat emboli.

315. Patient came in ER with chest pain ECG normal cardiac enzymes normal doctor advised thoracic cage X-RAY which one of these structures is cartilaginous+Amphiarthrosis joint?

A- Manubrioosternal
B- Costochondral
C- Xiphisternal
D- Sternocostal
Ans: B

316. A patient with acute myocardial infarction this is shown on ECG shown by which of following:

A- RVH
B- LVH
C- ST displacement
D- U wave
E- Right atrium hypertrophy
Ans: C

extremity edema is evaluated because of the sudden onset of shortness of breath and pleuritic chest pain. A diagnosis of pulmonary embolism is made. Which of the following signs, if present on physical examination, would be the most specific indicator of pulmonary arterial hypertension in this patient?

A- Increased jugular venous pressure
B- P2 louder than A2
C- Peripheral edema
D- Presence of an S3
E- Pulmonary crackles
Ans: B

318. A patient presented with Headache having ESR 120 cause is. Polymyalgia rheumatica is associated with which one of the following disease?

A- Giant cell arteritis
B- Akayasu arteritis
C- Kawasaki syndrome
D- Microscopic polyangitis
Ans: A

319. Feature of hypertrophic obstructive cardiomyopathy is:

A- Systolic Failure with Increase SV
B- Diastolic Failure with Increase SV
C- Diastolic Failure with Decrease SV
D- Systolic Failure with Decrease SV
Ans: C

320. A patient having pansystolic murmur at aortic area with Plateau pulse likely cause is

A- Tricuspid incompetence
B- ASD
C- Aortic stenosis
D- PDA
E- VSD
Ans: E

321. A Pregnant Lady having Shortness of Breath and Irregularly irregular pulse. On Auscultation there is mid diastolic murmur Most likely findings would be:

A- Constant R-R interval
B- P-Mitrale on ECG
C- Pulsus Paradoxus
D- LVH
E- High Gradient Accross Mitral Valve
Ans: B

CamScanner

322. 62 years old patient of congestive heart failure presented with dyspnea and orthopnea, the mechanism of pulmonary edema in case of CHF is which of following?
A- Increased plasma colloid osmoticpressure
B- Decreased plasma colloid osmoticpressure
C- Decreased hydrostatic pressure
D- Increased hydrostatic pressure
E- Increased permeability of pulmonaryvasculature
Ans: D

323- On Autopsy a Person having Cardiac disease subendocardial Infarct.A Circumferential Lesion is noted on left ventricle was noted the mechanism is
A- Cardiac temponade
B- Hypovolumic Shock
C- Thrombotic occlusion of LCX
D- Pulmonary Embolism
E- Thrombotic occlusion of RCA
Ans: C

324- A patient ECG shows prolonged PR. Echocardiography shows no ventricular hypertrophy Left axis deviation seen this is which block
A- Unifascicular
B- Bifascicular
C- Trifascicular
D- Third degree block
E- Complete block
Ans: C
Explanation:
- Unifascicular-Left Axis deviation
- Bifascicular- Prolong PR Interval
- Trifascicular-Left axis deviation +Prolong PR Interval

325- A patient presents with chest pain radiating to the back, not related to respiration. On examination, muffled heart sounds are heard along the left sternal border. What is the most likely diagnosis?
A- Pericarditis
B- Myocarditis
C- Cardiac tamponade
D- MI
Ans: C

326- Giant cell arteritis diagnose by:
A- CBC
B- ESR
C- Temporal artery Biopsy
D- CT head
Ans: C

327- 65 male, previous healthy life, with pulmonary congestion and failing heart for 1 year. on examination bp 125/85, afebrile, glucose 86, total cholesterol 185, cpk not raised, x-ray showed pulmonary edema and left prominent heart border diagnose is:
A- Amyloidosis
B- Alcoholic cardiomyopathy
C- Aortic dissection
D- Calcified bicuspid aortic valve
E- Tricuspid valve carditis
Ans: D

328- Most likely indication of mitral valve replacement:
A- Mitral valve prolapses
B- Post rheumatic
C- Floppy mitral valve
D- Rupture of papillary muscle
Ans: C

329- A pregnant lady having shortness of breath and irregularly irregular pulse. On auscultation there is mid diastolic murmur. Most likely it is:
A- Aortic stenosis
B- Aortic regurgitation
C- Mitral regurgitation
D- Mitral stenosis with insufficiency
Ans: D

330- In fetus which system causes deaths:
A- Neurological diseases
B- CVS diseases
C- Dermatological diseases
D- Respiratory diseases
Ans: B

331- Decrease ventricular muscle fiber length in which one of the following
A- Increase venous return
B- Contracetion of skeletal muscles
C- Decrease intra thoracic pressure
D- Increase intra pericardial pressure
Ans: D

332- Hypertension on kidney as compared to normotensive is
A- Increase Na affect more than other
B- ANP affect in arteries decrease
C- ANP affect in arteries increase
D- Increase Phosphate affect
Ans: A

333- Long standing hypertension leads to
A- Aneurysm
B- Hard exudate
C- Soft exudate
D- Hemorrhage
Ans: B

334- Child is lethargic weak mentally in school having TOF, due to
A- ASD
B- Aortic over riding and VSD
C- LVH
D- Right atrium enlargement
Ans: B

335- In Mitral stenosis, ECG shows
A- Biphasic p wave in lead 2
B- P.mitrale in lead 2
C- P mitale in lead 4
D- P mitrale in lead 1
Ans: B >A

336- The cause of edema in mitral stenosis
A- Increase Interstitial hydrostatic pressure
B- Increase Capillary hydrostatic pressure
C- Increase oncotic pressure
D- Vagovagal reflexes
E- Lymphatic obstruction
Ans: B
Explanation:
- Peripheral edema in CLD due to – loss of albumin (Low oncotic pressure)
- Ascities in CLD due to – Portal HTN
- Renal origin edema due to – Loss of albumin (low oncotic pressure) + can be salt and water retention.
- Nephrotic syndrome edema due to - Hypoalbuminemia
- Nephritic syndrome edema due to – Salt and water retention.
- Pedal edema in CHF and HTN due to – Increase hydrostatic pressure.
- In CHF edema woarsen by – Sodium and water retention

337- Enzyme released in Heart failure is
A- ANP
B- BNP
C- Aldosterone
D- Potassium
Ans: B

338- Atheroma formation is due to
A- VLDL
B- HDL
C- LDL
D- Chylomicron
E- Phospholipids
Ans: C

339- Most common site of atrial myxoma is
A- Right Atrium
B- Right ventricle
C- SVC
D- Left atrium
E- Anterior wall
Ans: D

340- 45-year man presented with sudden onset of retrosternal chest pain with sweating and breathlessness. O/E BP was 90/60, and pulse was 110/min, low volume. Most likely diagnosis is
A- Dissecting aneurysm
B- MI
C- Pneumonia
D- Pulmonary embolism
E- Tension pneumothorax
Ans: B

341- Patient had Road traffic car accident and had injury to spine and developed quadriplegia. His respiration and BP normal. After three months he came with blood pressure that flactuates and raises high 180/110, and told that BP gets lowered when lower abdomen and bladder area is massaged and after passing urine, what is cause of increase BP
A- Increase sensitivity to catecholamines because of upregulation of alpha receptors.
B- Exaggerated autoimmune reflexes because of regeneration process of spinal cord.
C- Filling of atonic bladder which is painful
D- Activation of pons
E- Increase Parasympathetic activity
Ans: A

342- Patient present with subcutaneous bleeding petechiae and ecchymosis with coagulation profile and CBC normal diagnose is
A- Haemophila
B- Vasculitis
C- VWD
D- Platelets aggregation defect
E- Platelets adhesion defect
Ans: B

343- A known patient of MI with pericardial friction rub having raised creatinine and urea most likely complication is
A- Exudative pericarditis
B- Transduative pericarditis
C- Serous pericarditis
D- Uremic pericarditis
Ans: D

CamScanner

345- Hypercalcemia leads to
A- Systolic arrest
B- Diastolic arrest
C- Both arrests
D- No significant effect on heart
Ans: A

Explanation:
- Hypercalcemia and hypokalemia – Systolic heart arrest
- Hypocalcemia and hyperkalemia – Diastolic heart failure

346- Interventricular septum thickness septum to free wall thickness 3:1 what is cause
A- Dilated cardiomyopathy
B- Hypertrophic cardiomyopathy
C- Restrictive cardiomyopathy
D- Dilation of ventricles
Ans: B

347- After RTA patient develop hypotension and Septic shock due to release cytokine
A- IL 1
B- TNF
C- Interferon
D- IL 8
Ans: B

348- A patient came in emergency 2cm water JVP 2L cardiac output, lactate 30 in blood BP 70/30, what type of shock is this
A- Anaphylactic shock
B- Cardiac tamponade
C- Hypovolemic shock
D- Septic shock
E- Cardiac shock
Ans: C(Ganong)

Explanation:
- Low CVP Low CO mainly seen in hypovolumic. also hypovolumic shock can produce increase lactate by anaerobic metabolism
- if only low Bp and height lactate mention low CO not mention then prefer septic
- In cardiac shock – Raised JVP

349- A baby has some cardiac abnormality, she has machinery murmur on auscultation what is the Abnormality
A- PDA
B- TOF
C- VSD
D- ASD
E- TGA
Ans: A

350- Patient with history of severe chest pain crushing in nature radiating to left arm of 2hr duration. ECG is inconclusive which cardiac enzyme will be raised
A- Myoglobin
B- CK-MB
C- CPK
D- Trop T
Ans: A

Explanation:
- Best Initial – ECG
- Investigation of choice in First 6 h - ECG
- 1-2hr – Myoglobin
- Within 4hr – CK MB
- After 4hr – Trop
- Sensitive – Trop T
- Specific – Trop I

351- Which abnormality is associated with bicuspid aortic valve
A- ASD
B- VSD
C- PDA
D- Coaractation of Aorta
E- TOF
Ans: D

352- Renal cause of uncontrolled hypertension
A- Polycystic kidney disease
B- Atherosclerosis of proximal 2cm of renal artery
C- Atherosclerosis of distal 2cm of renal artery
D- Pelviureteric stone
Ans: B

353- Silver and copper wiring occur in retina in
A- DM
B- HTN
C- Smoking
D- Hyperlipidemia
Ans: B

354- A patient has frequently irregular pulse on examination. ECG shows no p wave and many abrupt R waves and QRS complex occurs irregularly what is the diagnosis
A- Ventricular fibrillation
B- WPW syndrome
C- Atrial fibrillation
D- Atrial flutter
Ans: C

355- A patient died had mitral stenosis and suddenly died after prolonged pulmonary congestion what will the alveoli be rich in?
Epitheloid cells
A- Heart failure cells
B- Histiocytes
C- Macrophages
D-
Ans: B

356- A 37-year-old woman develops a malar rash when she spends several hours outside at a Kensington Oval cricket match. Ordinarily, she avoids being in the sun, but a friend provided free tickets to a West Indies test match. When she sees her physician, a urinalysis is performed that shows hematuria and proteinuria. A skin biopsy shows immunofluorescence positivity along the dermal-epidermal junction with antibody to C1q. Which of the following additional complications is she most likely to suffer as a consequence of her underlying disease?
A- Pulmonary hemorrhage
B- Joint ankylosis
C- Nodular glomerulosclerosis
D- Pulmonary fibrosis
E- Pericarditis
Ans: E

357- Pregnant lady presented with rheumatic fever. Which of the following is characteristic feature of rheumatic fever in this lady?
A- Mitral stenosis
B- Mitral regurgitation
C- Aortic stenosis
D- Aortic regurgitation
E- Tricuspid regurgitation
Ans: A

358- Patient with complain of regurgitation chest pain mid night partially relieved by elevation of bed head side Frothy like liquid is coming from mouth what should doctor advised?
A- Atropine
B- Partial vagotomy
C- Complete vagotomy
D- Decrease fatty diet
Ans: D

359- On ECG of a girl, you see saw tooth waves, with p waves in a ratio of 3:1. Her pulse is regularly irregular. Which of the following has occurred?
A- Atrial flutter
B- Atrial fibrillation
C- Ventricular tachycardia
D- Ventricular fibrillation
E- Ventricular flutter
Ans: A

360- An ECG of patient with electrolytes disturbances shows U wave, inverted T wave, prolonged PR interval on ECG due to:
A- Hypomagnesemia
B- Hyperkalemia
C- Hyponatremia
D- Hypernatremia
E- Hypokalemia
Ans: E

361- A patient has Chest pain having cardiac problem from one year now having opening snap, mid diastolic murmur which are characteristic due to:
A- MR
B- AR
C- Tricuspid stenosis
D- Mitral stenosis
Ans: D

362- ECG of patient shows no association between P- R wave and had history of fainting due to
A- 1st degree Heart block
B- 2nd degree Heart block
C- 3rd degree Heart block
D- Mobitz block
Ans: C

363- An 18 year-old student visits her physician for a routine physical examination. She has no complaints. Physical examination is unremarkable except for a mid- systolic click followed by a late systolic murmur heard at the lower left sternal border and apex. The murmur duration increases in standing and shortens with squatting. Electrocardiogram (ECG) shows no abnormalities. Which of the following is the most likely diagnosis of this condition?
A- Mitral stenosis
B- Aortic stenosis
C- Mitral valve prolapses
D- Tricuspid regurgitation
E- Dilated cardiomyopathy
Ans: C

CamScanner

364- Pansystolic murmur occurs in
A- Aortic regurgitation
B- Aortic stenosis
C- Mitral regurgitation
D- Mitral stenosis
Ans: C

365- Patient with MI died even after aggressive management likely cause is
A- Hypovolumic shock
B- Neurogenic shock
C- Septic shock
D- Hypoxic Hypoxia
E- Cardiogenic Shock
Ans: E

366- In Aortic aneurysm layers from inward to outward is
A- Adventitia , intima and media
B- Intima , media and adventitia
C- Media , adventitia and intima
D- Media , intima and adventitia
Ans: B

367- Which one is directly related to coronary artery disease?
A- Plasma cholesterol
B- LDL-C
C- HDL-C
D- Trans fatty acid
Ans: B

368- MI occurs due to thrombosis which factor is important and independent of other factors?
A- Immobolization
B- Vascular injury
C- Stasis
D- Hypercoagubility
Ans: A

369- A patient having Pansystolic murmur left ventricle Hypertrophy and Atrial fibrillation he is suffering from
A- AS
B- PS
C- MS
D- MR
E- TR
Ans: D

370- Patient Rheumatic heart disease in childhood new murmur sound dyspnea chest pain most likely diagnose now:
A- Aschoff bodies
B- Mitral stenosis
C- Papillary muscle damage
D- AR
E- AS
Ans: B

Explanation:
- Asch off bodies is diagnostic for rheumatic fever and not a diagnose itself so diagnose is MS because mitral valve is commonly affected.

371- Diagnostic test to rule out MI?
A- CK-MB
B- Trop I
C- CK-MM
D- ECHO
E- LDH
Ans: B

372- Increased mean arterial pressure and right atrial pressure with decreased resistance to Venous return is seen in which of these:
A- Hypertension
B- Low vascular resistance
C- Hyperglycemia
D- Exercise
Ans: D

373- An adult male comes to you with hypertension & radiofemoral pulse delay; the likely diagnosis is?
A- Coarctation of aorta
B- Pre-ductal coarctation of Aorta
C- Post-ductal coarctation of aorta
D- PDA
E- Atherosclerosis
Ans: C

374- Cause of left axis deviation on ECG
A- Left ventricular damage
B- AV node damage
C- Purkinji fibre damage
D- Right ventricular damage
Ans: D

375- A patient has increased preload and Diastolic murmur due to:
A- Aortic regurgitation
B- Aortic stenosis
C- Mitral stenosis
D- Tricuspid stenosis
Ans: A

376- A patient has increased Heart rate with normal BP especially during stress and anxiety this is:
A- SVT
B- Ventricular tachycardia
C- Sinus Tachycardia
D- Premature ventricular contraction
Ans: C

377- Systolic murmur in aortic area,a rash,plateau pulse and left axis deviation: .
A- Aortic stenosis
B- Mitral stenosis
C- Mitral regurgitation
D- Aortic regurgitation
E- Tricuspid stenosis
Ans: A

378- Father died of heart disease. Son also has heart disease now presented with SOB and died. On autopsy what findings will be there?
A- RVH
B- Left ventricular hypertrophy
C- Left atrium atrophy
D- Band formation
Ans: B

379- Most commomly disease heart valve is:
A- Aortic
B- Tricuspid
C- Mitral
D- Pulmonary
Ans: C

380- A child has TOF and got cyanosed and unconscious while playing what is likely cause.
A- VSD
B- ASD
C- Overriding aorta
D- TGA
Ans: C

381- In Atherosclerosis which part of vessel affected most:
A- Endothelium
B- Lamina interna
C- Lamina externa
D- Collagen fibers
E- Elastic fibers
Ans: E

382- A patient has chronic chest pain Irregular pulse and diagnosed as atrial fibrillation . He is unable to walk and fall suddenly and can't reach his phone. Emboli from Atrial fibrillation lodge in which artery.
A- MCA block
B- PCA block
C- ACA block
D- Anterior communicating
Ans: C

383- In Right Hear failure dilations of Right Ventricle and Right Atria also associated with?
A- Dilations of coronary artery
B- Dilations Coronary Sinus
C- Dilation of intercostal artery
D- Compression of septomarginal
E- Trabuclae dilation
Ans: B

384- Female patient after multiple blood transfusion ECG shows tall T waves what is your diagnosis?
A- Hypokalemia
B- Hyperkalemia
C- Hypercalcemia
D- Hypocalcemia
E- Hypomagnesemia
Ans: B

385- A boy with recurrent pharyngitis due to streptococal pyogenes is at risk of which of following.
A- Sepsis
B- DIC
C- Rheumatic heart disease
D- Coagulopathy
Ans: C

386- A patient presents with an atrial rate of 85 beats per minute (bpm) and a ventricular rate of 35 bpm. What is the likely cardiac condition?
A- Complete heart block
B- Mobitz type 1 (Wenckebach)
C- Mobitz type 2
D- Atrial flutter
Ans: A

Explanation:
- Complete heart block is characterized by a complete absence of ventricular contractions, leading to a slow ventricular rate.

387- Patient presented with decrease peripheral pulsation with abdominal pain and creatinine kinase normal and pulsating abdominal mass with fasting glucose of 130 – 150 from last 20 years is most likely suffering from:
A- Thoracic aortic Aneurysm
B- Abdominal Aortic Aneurysm
C- Rupture of IVC
D- Diabetes mellitus type 2
E- Superior vena Cava Aneurysm
Ans: B

CamScanner

388- The site of murmur for aortic regurgitation:
A- Neck
B- Apex of heart
C- Left 5th ICS
D- Right 2nd ICS
E- Left 2nd ICS
Ans: D

389- Single factor independent of others causing thrombus formation in old age patient developed coronary artery thrombi is due to:
A- Hypocoagubility
B- Endothelial retraction
C- Turbulence of blood flow
D- Endothelial injury
Ans: C

390- In Second degree heart block:
A- Ventricular rate more than atrial rate
B- Ventricular rate less than atrial rate
C- Ventricular rate independent of atrial rate
D- Atrial rate equal ventricular rate
Ans: B

391- Patient came with complain of sinking of heart, muscle weakness and ECG shows T waves. What is the cause?
A- Hyponatremia
B- Hyperchloremia
C- Hypochloremia
D- Hyperkalemia
E- Hypokalemia
Ans: E

392- Infarct in ventricle postero septal area but heart beat is high and regular cause is:
A- Infarct has only involved AV node
B- Infarct has only involved SA node
C- Infarct has involved some portion of myocardium
D- Infarct involved whole myocardium
Ans: C

393- Most specific biomarker for ischemic injury of cardiac tissue:
A- CK MB
B- Troponin I
C- LDH
D- Myoglobin
E- Troponin T
Ans: B
Explanation:
- Sensitive -Trop T
- Specific - Trop I

394- Common cause of non obstetrical death in our country?
A- Asthma
B- Heart disease
C- TB
D- Domestic violence
Ans: B

395- A lady brought her 6 year old child with complaints of sore throat malaise, joint pain and painful nodules on extensor surface, what test you will do to confirm diagnosis?
A- Blood culture
B- ASO titre
C- Throat culture
D- Gram stain
Ans: C

396- Atrio ventricular dissociation occur in:
A- Third degree complete heart block
B- Inspiration
C- During exercise
D- Atropine overdose
Ans: A

397- Normal ecg with prolong PR interval?
A- Mobitz type 1
B- Mobitz type 2
C- Complete heart block
D- Mobitz type 2 A
Ans: A

398- Cannon A wave is associated with:
A- Tricuspid regurgitation
B- Pulmonary stenosis
C- Mitral regurgitation
D- Pulmonary embolism
E- Complete heart block
Ans: E

399- In which condition there is no relation between P and QRS complex:
A- Tricuspid regurgitation
B- Pulmonary stenosis
C- Mitral regurgitation
D- Pulmonary embolism
E- Complete heart block
Ans: E

400- A patient has A fib and MI on autopsy what is likely:
A- HTN
B- DM
C- Trauma
D- Prolonged immobilization

401- Aortic stenosis will cause left ventricle:
A- Decrease distensibility
B- Increase contractility
C- Decrease contractility
D- Increase distensibility
Ans: C

402- A 6 years old Japanese boy with a sick appearance has a 7- days lasting fever, bilateral conjunctivitis, cracked lips, bilateral cervical lymphadenopathy and maculo-papular skin rash. What is the most likely diagnosis?
A- Measles
B- Infectious erythema
C- Kawasaki disease
D- Ritter disease
E- Mumps
Ans: C

403- Thoracic duct block causes:
A- Chylopericardium
B- Hemopericardium
C- Inc CVP
D- Dependent edema
Ans: A

404- Granulomatous polyangitis is associated with:
A- C ANCA
B- P ANCA
C- Anti SSA
D- Anti Jo
Ans: A

405- Most common structure damged by ischemia is:
A- Liver
B- Neuron
C- Lung
D- Myocardium
Ans: B

406- In type 2 heart block:
A- Ventricular rate slower than atria
B- SV is decreased
C- More chances of ventricular of ventricular arrhythmia
D- HR is increased
Ans: A

407- A patient with epistaxis, hematuria, saddle nose & granulomatous inflammation diagnose is:
A- Churg strauss syndrome
B- Granulomatosis with polyangitis
C- SLE
D- HIV
Ans: B(FA+Pathoma)

408- In old age cardiomyopathy related to:
A- Ca+ influx
B- Na influx
C- K efflux
D- K influx
Ans: A

409- Person present with Central chest pain for 4hr which cardiac enzyme will be raised?
A- Trop I
B- CK-BB
C- CPK
D- ALT
E- AST
Ans: A

410- A smoker who is having two packs per day with associated heart disease is at risk of which arterial complications:
A- Vasculitis
B- Atherosclerosis
C- Arteriosclerosis
D- Fibrinoid necrosis
Ans: B

411- Pericardiocentesis location for straw colored fluid is which of following?
A- Caudal sternum region at medial end of 4th and 5th costal cartilage
B- Left parasternal 3rd intercostal space
C- Midclavicular line
D- Midaxial line
E- Right parasternal 2nd Intercostal space
Ans: A

412- What metabolic derangement is present in progressive non compensated shock in which reverse phenomenon failed (Med Feb 2024)
A- Metabolic acidosis
B- Metabolic alkalosis
C- Partially compensated metabolic alkalosis
D- Metabolic acidosis and respiratory Acidois
E- Respiratory acidosis
Ans: D
Explanation:
- In shock usually Metabolic acidosis occur which is compensated by Respiratory alkalosis
- But in Decompensated progressive shock in which compensatory mechanism fail then it will lead to Metabolic acidosis with respiratory acidosis
- In shock reverse phenomenon – Metabolic acidosis with Respiratory Alkalosis
- In Decompensated shock where reverse phenomenon fail – Metabolic acidosis with Respiratory acidosis

CamScanner

413- A Man dies at 9th day of MI he died due to which of following?
A- Arryhmia
B- Pericardial tamponade
C- Viral infection
D- Kawasaki
E- Aneurysm
Ans: B

414- In mitral stenosis where should doctor place stethoscope for Auscultation?
A- Right second intercostal space
B- Right sternal border
C- Left sternal border
D- Left 5th intercostal
E- Left 4th intercostal space
Ans: D

415- Man is having RHD and MS and on lung heart failure cells are seen, what is the mechanism of formation:
A- MI tissue hypoxia
B- Chronic passive congestion
C- Hypertrophy
D- Constricted myopathy
Ans: B

416- AV nodal delay results in:
A- Prolonged pr interval
B- Short PR interval
C- Long QRS
D- Short QT interval
Ans: A

417- 30 year female presented with acute chest pain and hemoptysis one week after delivery there is no fever ECG shows S1Q3T3 pattern most appropiate investigation would be:
A- CPK
B- CT angiogram
C- LDH
D- SGOT
E- X-Ray chest
Ans: B

418- A 26 year old female presented with uncontrolled hypertension. There is radiofemoral delay. Most likely cause of hypertension in this patient will be
A- Renal artery stenosis
B- Pheochromocytoma
C- Coartaction of aorta
D- Conn syndrome

419- During left ventricular failure following occur
A- Increase in pulmonary capillary pressure
B- Orthopnea while standing
C- Decrease pulmonary pressure
D- Pulmonary edema can never occur
Ans: A

420- On ECG p wave and QRS complex with ratio of 3:1 is
A- Mobitz 1
B- Mobitz 2
C- Complete block
D- First degree block
Ans: B

Explanation:
In complete heart block there will be complete P-R dissociation

421- Increased Calcium in Extracellular matrix will result in?
A- Systolic Cardiac arrest
B- Diastolic Cardiac arrest
C- AV conduction abnormality
D- SA node abnormality
Ans: A

Explanation:
- Increase extracellular Ca+ mean more in blood hypercalcemia so:
- Hypercalcemia and hypokalemia – Systolic heart arrest
- Hypocalcemia and hyperkalemia – Diastolic heart failure

422- A Female patient with SOB. Pleurocentesis done. Fluid having specific gravity of 1.006 cause is
A- Recurrent thromboembolism
B- DVT
C- CHF
D- MI
Ans: C

423- A patient with left atrial hypertrophy, Increased pulmonary artery pressure, loud S1, mid diastolic murmur , what's the diagnosis:
A- Aortic stenosis
B- Mitral stenosis
C- Tricuspid stenosis
D- Aortic Regurgitation

424- Patient with history of Rheumatic Valvular disease (Mitral Stenosis) Presented With Dysphagia. On Examination Reddish Cheeks & Raised Jugular venous pressure. Which of the following enlargement can be the cause of dysphagia in this patient?
A- Left atrium
B- Right atrium
C- Left ventricle
D- Right ventricle
E- Inferior Vena Cava
Ans: A

425- A 55 years old lady with mild HTN, wants lifestyle modification ,advice shall be
A- Salt restriction
B- Walk 1 mile daily 4 days/week
C- Bike riding 30mine 4days/week
D- High salt diet
Ans: B>A

Explanation:
- If life style modification asked then B>A
- But if salt restrictions upto 6g/day mentioned then prefer that
- If dietry modification asked then always prefer Salt restrictions in all circumstances

426- An old aged patient with generalized edema having increased Translucency of Lungs in Upper fields , flattened diaphragms, no evidence of infiltration , No H/O of fever , prominent both pulmonary arteries , Prominent right border of Heart on radiograph , what is most likely mechanism involved in Pulmonary arteries ?
A- Granulomatous vasculitis
B- Organizing Atherosclerosis
C- Aneurysm
D- Medial dissection
Ans: B

427- In Left circumflex blocked. Which heart part affected?
A- Left atrium anterior
B- left ventricle posterior
C- Right atrium
D- Right ventricle
Ans: B

428- Most significant cause of atheroma:
A- Immobilization
B- Diastolic hypertension
C- Type 2 personality
D- Endothelial Injury
E- Diabetes
Ans: B
better

429- Increase ECF potassium what will be effect on heart
A- Myocardial weakness
B- Spastic paralysis
C- Diastolic cardiac arrest
D- Systolic cardiac arrest
E- Tremors
Ans: C

Explanation:
- Increase ECF potassium mean More in blood hyperkalemia
- Hypercalcemia and hypokalemia – Systolic heart arrest
- Hypocalcemia and hyperkalemia – Diastolic heart failure

430- Increase afferent traffic impulses from carotid body due to
A- Methemglobinemia
B- CO poisoning
C- Cyanide poisoning
D- Anemic hypoxia
E- Stagnant hypoxia
Ans: A

431- Hypertrophic Cardiomyopathy occurs primarily due to:
A- Decreased stroke volume due to decreased diastolic filling
B- Increased stoke volume due to decreased diastolic filling
C- Increased stroke volume due to increased diastolic filling
D- Decreased stroke volume due to increased diastolic filling
Ans: A

432- A patient presents with persistent epigastric pain and chest pain vomiting from last 4 hours. ECG shows ST elevation BP 130/80 Cardiac enzymes normal what is the diagnosis:
A- MI
B- Acute pericarditis
C- Myocarditis
D- Dissectionof Aorta
Ans: D

433- Patient presented with palpitations and having absent p waves with irregular pulse and irregular R-R interval and also having diastolic rumbling murmur likely cause is
A- Mitral stenosis with insufficiency
B- Aortic stenosis
C- Pulmonic stenosis
D- Aortic regurgitation
Ans: A

CamScanner

434- Patient presented with palpitations and having absent p waves with irregular pulse and irregular R-R interval and also having diastolic rumbling murmur likely cause is

A- Mitral stenosis with insufficiency
B- Aortic stenosis
C- Pulmonic stenosis
D- Aortic regurgitation
Ans: A

435- A patient Whose ECG is normal, cardiac enzymes normal, x-ray lung field clear but on CT scan 0.5cm calcification found and ball movement of heart valves noted. What is primary heart tumor related to this

A- Atrial myxoma
B- Rhabdomyosarcoma
C- Pulmojary embolism
D- MI
Ans: A

436- Person present with Central chest pain for 4 hrs, which cardiac enzyme will be raised?

A- ALP
B- CK-BB
C- LDH
D- ALT
Ans: C

437- A patient with non-lethal Myocardial infarction. After few minutes Which of the following is most likely to occur:

A- Complete recovery without complications
B- Arrhythmia
C- Cardiac tamponade
D- Pericarditis
Ans: B

Explanation:
Complications
- 4h Post MI – Arrhythmia
- 4-24h Post MI – Arrhythmia
- 1-3 Days Post MI – Fibrinous Pericarditis
- 4-7 Days Post MI – Cardiac Temponade
- Months Post MI -- Aneurysm

438- Patient has tearing chest pain, unequal b.p in arm and mediastinal widening due to??

A- Aortic disection
B- Coarctation of aorta
C- Aortic regurgitation
D- Atherosclerotic Aneurysm
Ans: A

439- A patient presented with c/o Shortness of Breath.O/E, Irregularly irregular pulse. On Auscultation there is mid diastolic murmur Most likely findings would be:

A- Constant R-R interval
B- P-Mitrale on ECG
C- Pulsus Paradoxus
D- Right ventriculat hypertrophy
E- Increaed pressure gradient between left atrium and left ventricle
Ans: B
Better

440- Hypertensive retinopathy affect which of Following

A- Veins
B- Arteriole
C- Venules
D- Arteries
E- Capillaries
Ans: B

441- Patient having chronic cardiac problem having recent Mi got to dentist for tooth extraction. He suddenly collapsed &become paralyzied due to thrombos occluding which artery?

A- Anterior choroidal artery
B- MCA
C- Posterior Choroidal artery
D- Posterior communicating artery
Ans: B

442- A 45-year-old patient presents with a systolic murmur that is audible up to the neck without the use of a stethoscope. Which of the following conditions is most likely associated with this finding?

A- Aortic regurgitation
B- Mitral stenosis
C- Aortic stenosis
D- Mitral regurgitation
E- Tricuspid regurgitation
Ans: C

Explanation:
- A systolic murmur that radiates to the neck is most characteristic of aortic stenosis. The murmur often originates from the left second intercostal space and can be transmitted to the carotid arteries, making it audible in the neck.

443- Which of the following structures is primarily affected by retinal hypertension?

A- Central retinal artery
B- Retinal veins
C- Retinal arterioles
D- Choroidal vessels
E- Optic nerve fibers
A---

444- A patient having some medication for cardiac issue now presented with prolongation of PR interval what is the cause

Drug induced first degree heart block
A- Mobitz type 1
B- second degree heart block
C- Arrythmias
D-
Ans: A

445- A patient presented with Jaw claudication headache on examination temporal artery firm and then biopsied which disease is associated with this:

Giant Cell arteritis
A- Takayasu arteritis
B- Kawasaki disease
C- PAN
D- Bachet disease
E-
Ans: A

446- Left Ventricle enlarged in Hypertension due to:

A- Hyperplasia
B- Increased Stroke volume
C- Atrophy
D- Hypertrophy
E- Increased Workload
Ans: E

Explanation:
- Hypertrophy is itself for enlarge or increase size
- Workload increases Size of Heart or hypertrophy
- Hypertrophy is already in stem

447- Valve involved in interventricular septal defect:

A- Aortic
B- Mitral
C- Tricuspid
D- Pulmonary
Ans: C

448- A patient presents with retrosternal pain radiating to the epigastrium lasting for 3-4 hours, accompanied by ST-segment elevation on ECG but no change in cardiac enzyme levels. What is the most likely diagnosis?

A- Aortic dissection
B- Acute myocardial infarction (MI)
C- Acute Pericarditis
D- Acute Myocarditis
Ans: A

449- ECG of patient shows no association between P-R wave and and had history of fainting due to

A- 1st degree Heart block
B- 2nd degree Heart block
C- 3rd degree Heart block
D- Mobitz block
Ans: C

450- In anaphylactic shock, which of the following is incorrect?

A- Increased vascular permeability
B- Increased venous return
C- Endotoxin
D- Arteriolar dilatation
Ans: B

451- Inferior wall MI, Left ventricle damaged which of the following artery is involved

A- LCA
B- LAD
C- PAD
D- Right marginal artery
Ans: B

452- 55 year old male present to the clinic with complain of increasing fatigue ,SOB, and palpitation over the past six months he reports occasional chest discomfort and difficulty breathing when lying down on examination Water hammer pulse and wide pulse pressure was present on auscultation high pitched blowing diastolic murmur was heared this is characteristic finding of which of the following condition

A- Aortic stenosis
B- Aortic regurgitation
C- Mitral stenosis
D- Mitral regurgitation
E- Mitral valve prolapse
Ans: B(Davidson)

Explanation:
Abnormal heart sounds
1. **Aortic stenosis**
   - Systolic ejection murmur
   - Crescendo-Decrescendo murmur
   - Slow raising pulse or slow pulse
2. **Aortic regurgitation**
   - Early blowing diastolic murmur
   - Wide pulse pressure
   - Bounding pulse(water hammer pulse)
   - Head bobbing
   - Quinke pulse
3. **Mitral valve prolapse**
   - Mid systolic click followed by regurgitation murmur
4. **Mitral regurgitation**
   - Holosystolic or pan systolic murmur
5. **Mitral stenosis**
   - Opening snap followed by diastolic rumble

CamScanner

453- A murmur is heard on Left 3rd intercostal space at parasternal border. Which of the following murmur is most likely?

A- Aortic Area 1
B- Mitral
C- Aortic Area 2
D- Tricuspid
Ans: C

454- Hypertensive, Hyperlipidemic smoker Patient with sternal Chest pain from last 30mins brought to ER .Vitals reveal Normal Pulse & Bp. Investigation reveal a normal ECG. What investigation will you do next to reach the diagnosis?

A- Echocardiography
B- Coronary Angiography
C- Exercise Tolerance Test
D- Give Aspirin
Ans: B

455- Security guard had history of fall and remain unconscious for 30 sec. His neurological examination is unremarkable. He is having irregular pulse what is cause is

A- Syncope
B- Mi
C- Heat Stroke
D- Transient Ischemic Attack
E- Seizure
Ans. A

456- Variable 1st heart sound in:

A- Atrial Fibrillation
B- Ventricular Fibrillation
C- Atrial Flutter
D- Supraventricular Tachycardia
Ans: A

457- A 54-year-old male is seen in the clinic with complaints of palpitations and light-headedness. Physical examination shows a heart rate of 100 bpm and blood pressure of 75/40 mmHg. What is the most likely adjustment that has occurred in the cardiac cycle?

A- Systolic time has decreased proportionately more than diastolic time
B- Diastolic time has decreased proportionately more than systolic time
C- Both systolic and diastolic times are equally reduced
D- Cardiac output has increased proportionately
Ans: B

458- A patient presented with Central chest pain. ECG shows ST elevation of 1mm in Lead 1 & AVL & ST depressions along with T- Wave inversions lead avR & lead 3. Diagnosis?

A- Anterior wall MI
B- Posterior Wall MI
C- Lateral Wall MI
D- NSTEMI
E- Acute Pericarditis
Ans: C

459- 65-year-old patient presents with episodes of dizziness. ECG findings reveal a regular RR interval, visible P waves, and a 2:1 AV conduction pattern. What is the most likely diagnosis?

A- Mobitz Type 1
B- Mobitz Type 2
C- Third- degree (Complete) Heart Block
D- First-degree Heart Block
Ans: B(Kumar and clerk medicine)

Explanation:

First- degree AV block

- This is simple prolongation of the PR interval to >0.22 s.
- Every atrial depolarization is followed by conduction to the ventricles but with delay

Second- degree AV block

- This occurs when some P waves conduct and others do not.
- There are several forms:

1- **Mobitz I block** (Wenckebach block phenomenon) Is progressive PR interval prolongation until a P wave fails to conduct. The PR interval before the blocked P wave is much longer than the PR interval after the blocked P wave.

2- **Mobitz II block** occurs when a dropped QRS complex is not preceded by progressive PR interval prolongation. Usually the QRS complex is wide (>0.12 s).

3- **2 : 1 or 3 : 1 (advanced) block** occurs when every second or third P wave conducts to the ventricles. This form of second- degree block is neither Mobitz I nor II

460- A patient presents to the ER with chest pain for the last 30 minutes and a systolic murmur. The initial ECG is normal. What is the next best step in management?

A- Repeat ECG
B- Echocardiogram
C- Troponin I levels
D- Exercise Tolerance test
E- Chest X- Ray
Ans: C

461- Which of the following is grossly visible in atheroma even in child

Vasoconstriction
A- Increased submucosal infiltration
B- Fatty streaks in aorta
C- Platelet aggregation
D-
Ans: C

462- Patient with irregular R-R interval & absent P waves. Along with primary treatment, What should be given to this patient?

A- Aspirin
B- Warfarin
C- Aspirin+Clopidogrel
D- Clopidogrel
Ans: B (Atrial Fibrillation)

463- A 67 years old patient came to hospital after an RTA, major injuries are suspected. She is a known case of CCF, on examination bilateral wheeze was present basally. What will be the fluid of choice in this patient for resuscitation.

A- 3 percent of ringer lactate
B- 0.9% normotensive normal saline
C- 3% hypertonic normal saline
D- 5% Dextrose Saline
Ans: B

464- Patient was present in cardiology department with chest pain so ECG was ordered On ECG there was ST elevation in lead 1 ,2 and AVL

A- Inferior wall MI
B- Anterioseptal wall MI
C- Lateral wall MI
D- Anterior wall MI
E- Posterior wall MI
Ans: C

Explanation:

- Inferior wall MI (RCA. – Leads 2, 3 and AVF
- Anterior wall MI (LAD . – Leads V1-V6
- Lateral wall MI (LCX . – Leads 1, AVL, V5 and V6
- In above question there is ST elevation in 1, 2 and AVL means two leads of lateral side are involve .If there is any change in 2 leads then it is diagnose as MI if there is change only in one lead then it not consider as MI

465- A male patient was present in cardiology OPD on examination he has ejection systolic murmur heard in right 2nd intercoastal space and plateau pulse and left axis deviation which of the following condition patient is suffering from

A- MR
B- MS
C- AR
D- AS
E- VSD
Ans: D

Better

466- Which condition is characterized by a congenital heart defect that initially causes a left-to-right shunt, which eventually reverses to a right-to-left shunt due to the development of pulmonary hypertension, leading to cyanosis?

A- Eisenmenger Syndrome
B- Tetralogy of Fallot
C- Atrial Septal Defect (ASD)
D- Patent Ductus Arteriosus (PDA)
E- VSD
Ans: A

467- Characteristic of Atrial Fibrillation:

A- Saw tooth waves
B- Increased P wave with Qrs complexes
C- Pulsus deficit
D- Irregular QRS complexes
E- Increased P Wave
Ans: C

468- ECG shows 1 qrs complex pattern after 2 constant P waves along with regular Heart Rate.PR interval is 0.14msec. Diagnosis is:

A- Mobitz type 1
B- Mobitz type 2
C- Complete heart block
D- Torsades De Pointes
E- Atrial Fibrillation
Ans: B(FA)

Explanation:

- **First- Degree AV Block:** Prolonged PR interval (>200 msec), benign and asymptomatic.
- **Second- Degree AV Block**

1. Mobitz Type I (Wenckebach): Progressive lengthening of PR interval until a beat is dropped (P wave not followed by QRS complex).
2. Mobitz Type II: Dropped beats without preceding PR interval changes, indicating structural abnormality.

CamScanner

- **Third- Degree (Complete) AV Block:** Complete dissociation between atrial (P waves) and ventricular (QRS complexes) rhythms, with atrial rate > ventricular rate)

469- Severe Bilateral Optic Disc Edema due to:

A- Acute Severe Hypertension
B- Diabetes Mellitus
C- Thyroid Disorders
D- Metabolic Syndrome
Ans: A

470- Patient had MI 6 months back now presented with chest pain and SOB.ECG shows bigeminy QRS complexes and inverted T waves cause is

A- Torsades de pointes
B- Prolong QT Syndrome
C- Premature ventricular contraction
D- Complete heart block
Ans: C

471- A 45-year-old male patient presents to the emergency department with shortness of breath and sinking heart and a history of recent fatigue and muscle weakness, On auscultation, bilateral fine crackles are heard in the lung bases.An ECG is obtained, which shows T wave depression in several leads which of the following is the cause of his condition

A- Hypokalemia
B- Hyperkalemia
C- Hypercalcemia
D- Hypocalcemia
E- Hyponatremia
Ans: A

Explanation:
ECG findings in Hyperkalemia
- Tall,peaked T waves
- Wide QRS complex
- PR –prolongation
- Loss of P-waves

ECG findings in Hypokalemia
- Flattened T- waves
- U- waves
- ST- depression

472- Middle aged Patient present in Cardiology OPD with MODERATE hypertension, he is taking thiazide diuretic for 10 months which of the following you will now prescribe

A- Double the dose of thiazide for better effect
B- Decreasing cardiac output due to dec volume
C- No need of potassium replacement
D- Decrease extracellular fluid
E- No need of salt restriction
Ans: D

473- Patient has a bicuspid Aortic Valve. What other condition might be associated with a bicuspid valve

A- Aortic Coarctation
B- Aortic Dissection
C- TOF
D- ASD
E- VSD
Ans: A

474- Essential hypertension, Cause of Edema in Legs:

A- Increased plasma colloid osmotic pressure
B- Decreased plasma colloid osmotic pressure
C- Decreased hydrostatic pressure
D- Increased hydrostatic pressure
E- Increased permeability of pulmonary vasculature
Ans: D

475- Patient diagnosed case of RHD. where should doctor placed stethoscope for auscultation?

A- Right second intercostal space
B- Right sternal border
C- Left sternal border
D- Left 5th intercostal
E- Left 4th intercostal space
Ans: D

476- Large A wave in JVP due to

A- Mitral stenosis
B- Mitral regurgitation
C- Aortic stenosis
D- Tricuspid stenosis
E- Aortic regurgitation
Ans: D

Explanation:
C Wave
C wave – Right ventricle contraction (Closed tricuspid valve bulging into atrium)
A Wave
A wave – Shows Atrial Contraction
Prominent A wave –Seen in T.S, P.S And Pulmonary HTN
Giant A wave – Seen in AV Dissociation, Complete Heart block
X Descent
X descent – Closed Tricuspid Valve downward displacement during rapid ventricular ejection phase
Absent X descent – Due to RHF and T.R
V Wave
V wave – Increase Right atrial pressure due to filling against closed tricuspid valve
Prominent V wave – Seen in T.R
Y Descent
Y descent – RA emptying into RV
Slow Y descent – Due to T.S
Rapid Y descent –Due to Constrictive pericarditis
Absent Y descent – Due to Cardiac tamponade

477- In Rheumatic heart disease murmur heard at

A- 5th ICS
B- 4TH ICS
C- 2ND ICS
D- 3rd ICS
E- 6th ICS
Ans: A

Explanation:
- Most common valve involve in rheumatic heart disease is mitral valve
- Acute present with MR and chronically with MS
- (Murmur of MS and MR located at apex which is at 5th ICS)

478- An older patient presents with MI that is Moderately severe in nature however ,complication develop suddenly after the attack in a few minutes, including

A- Ventricular fibrillation
B- Congestive cardiac failure
C- No cmplication
D- Cardiac temponade
E- Pericarditis
Ans: A

Explanation:
- 4 hr Post MI – Arrhythmia
- 4-24 hr Post MI – Arrhythmia
- 1-3 Days Post MI – Fibrinous Pericarditis
- 4-7 Days Post MI – Cardiac Temponade
- Month Post MI – Aneurysm

479- A patient presents with acute retrosternal pain and he was administered aspirin and clopidogeral following treatment ,the pain was subsided ,the likely reason for pain relief is

A- Increase venous capacitance
B- Decreased arteriolar resistance
C- Increased blood supply to the heart
D- Decrease heart rate
Ans: C

480- IN VSD most common defect occurs in which of the following

A- Membranous Portion
B- Non membranous portion
C- Trabecular portion
D- Outflow portion
E- Inflow portion
Ans: A

Explanation:
- VSDs is the most common congenital cardiac defect,it occurs as a result of incomplete septation of the ventricles ,embryologically ,the interventricular septum has a membranous and muscular portion and the latter is further divided into inflow,trabecular and outflow portions most congenital defects are perimembranous occurring at the junction of membranous and muscular portion of the septum

481- Female with mid diastolic rumbling murmur, diagnosis?

A- Mitral stenosis
B- Mitral regurgitation
C- Aortic stenosis
D- Aortic regurgitation
Ans: A

482- Man with pericarditis.What will decide its progresss/ fate/severity?

A- Blood in it
B- Cell count
C- Depends on nature of Underlying disease
D- Type of Cells
Ans: C

483- A woman brings her son with temp 38.5, also noticed some weird movements(chorea), and nodules. what will be your best investigation?

A- Blood culture for s.pyogenes
B- Anti-streptolysin O
C- Blood culture for s. Pneumoniae
D- Urine Culture
Ans: B

484- patient with Persistent PR interval & P:QRS 2:1,No PR prolongation, P wave normal. Most likely diagnosis?

A- Atrial flutter
B- Afib
C- Mobitz type 1
D- Mobitz type 2
Ans: D

485- A patient presents with an increased atrial rate compared to the ventricular rate and an irregular pulse. What is the most likely cause?

A- Atrial fibrillation (Afib)
B- Atrial flutter
C- Paroxysmal atrial tachycardia
D- Paroxysmal ventricular tachycardia
Ans: B

486- Anterior wall MI

A- ST elevation in V3-V4
B- ST elevation in V1-V4
C- ST elevation in II, III, aVF
D- ST elevation in I,aVL
E- ST elevation in V1-V6
Ans: E

CamScanner

Explanation:

Area of infarction	Leads	Artery involved
Inferior wall MI	II,III,aVF	RCA
Anteroapical wall MI	V3 and V4	Distal LAD
Anteroseptal MI	V1-V2	LAD
Anterolateral wall MI	V5-V6,I and aVL	LAD OR LCX
Lateral wall MI	1, aVL	LCX
Posterior wall MI	V7,V9 and Tall R waves and ST depression in V1-V3,	Posterior descending artery

487- A 45 year old patient presents in Cardiology department with history of fainting from past 6 months his ECG shows P and QRS dissociation

A- Atrial fibrillation
B- Atrial flutter
C- 1st degree block
D- 2nd degree block
E- 3rd degree block
Ans: E

488- A 55 year old male present to ER department with SOB, hypotention, and swelling of neck veins on examination the hear sound are muffled which of the following is ur diagnosis

A- Cardiac temponade
B- Constrictive Pericarditis
C- Myocarditis
D- CHF
E- Cardiomyopathy
Ans: A

Explanation:

- Above case is of cardiac temponade it occurs due to compression of heart by fluid(blood, effusions) in the pericardial space leads to decrease CO
- Equilibration of diastolic pressures in all 4 chambers
- Findings: **Beck triad**(hypotension, distended neck veins, distant heart sounds) increase HR, pulsus paradoxus
- ECG shows low violtage QRS complex and electrical alternas(due to swinging movement of heart in large effusions)

489- An older patient presents with MI that is Moderately severe in nature however, complication develop suddenly after the attack in a few hours and die, including

A- Ventricular fibrillation
B- Congestive cardiac failure
C- No complication
D- Cardiac tamponade
E- Pericarditis
Ans: A

Explanation:

- 4 hr Post MI – Arrhythmia
- 4-24 hr Post MI – Arrhythmia
- 1-3 Days Post MI – Fibrinous Pericarditis
- 4-7 Days Post MI – Cardiac Temponade
- Month Post MI – Aneurysm

490- At which of the following level of potassium ECG will show the Tall T waves and wide QRS complexes

A- 4
B- 3.5
C- 4.5
D- 6
E- 5
Ans: D

491- A 11 year old boy, died Autopsy finding revealed aortic dilation which of the following is most likely cause

A- Takayasu arteritis
B- Kawasaki disease
C- Marfan syndrome
D- Congenital heart defect
Ans: B

492- Which of the following represents the backward flow of the blood into the aorta during the cardiac cycle

A- Dicrotic notch
B- Pulsus alterans
C- Pulsus paradoxus
D- Raised JVP
Ans: A

Explanation:

- Dicrotic notch is caused by the closure of the aortic valve. As the left ventricle relaxes,the pressure in the aorta will eventually exceed the pressure in the left ventricle when this happens, the aortic valve will close and retrograde blood flow will towards the the aortic valve

493- Hyperkalemia leads to which of the following:

A- PR prolongation
B- Muscle spasm
C- Cardiac arrhythmias
D- Powerful contraction
E- Spasficity
Ans: C

494- A 72 year old women presents to the ER department with a two weak history of headache, and the headache was throbbing and persistent she also reports transient loss of vision and jaw pain while chewing which of the following is ur diagnosis

Giant cell arteritis
A- Takayasu arteritis
B- TB meningitis
C- Trigeminal neuralgia
D- Brain abcesses
E-
Ans: A

495- Patient presented with chest pain. ECG was done which showed irregular heart beat, prominent U waves. What is the likely cause?

A- Hypokalemia
B- Hyperkalemia
C- Hyponatremia
D- Hypermagnesemia
E- Hypocalcemia
Ans: A

ECG findings in Hyperkalemia

- Tall,peaked T waves
- Wide QRS complex
- PR –prolongation
- Loss of P-waves

ECG findings in Hypokalemia

- Flattened T- waves
- U- waves
- ST- depression

Better

496- An ECG of patient showing R-R interval of 0.55 sec Which of the following is most likely this ECG shows the heart rate of

A- Normal person heart rate
B- Athlete's heart rate
C- Bradycardia
D- Tachycardia
Ans: D

Explanation:

Calculation of HR from R-R interval
HR=60/R-R interval
HR=60/0.55
HR=109beats
Tachycardia =>100 beats/min
Bradycardia =<60 beats/min
HR of normal person is about 60-100 beats/min
Athlete's HR is <60beats/min

497- A 62 year old male present with chest pain and SOB having recent history of MI he has has stent placement ,on examination patient is anxious and hypotensive with bp of 80/50mmhg which of the following is most likely cause

A- Anaphylactic shock
B- Cardiogenic shock
C- Hypovolumic shock
D- Septic shock
E- Neurogenic shock
Ans: B

498- A 60 year old male presents with chronic heart failure presents with symptoms of volume overload ,including severe peripheral edema and SOB on lab findings there was low potassium which of the following drug should be prescribed to cover both

A- Loop diuretics
B- Spiranolactone
C- Thiazide
D- Mannitol
Ans: B

499- Patient with history of severe chest pain radiating to left arm of 3hr duration. ECG is inconclusive which cardiac marker will be diagnostic of his condition in this case?

A- Myoglobin
B- CK-MB
C- CPK
D- Trop T
E- LDH
Ans: B

500- A 58 year man with a history of hypertension and smoking presents with chest pain that occurs during exercise and relieves with rest after 5 minutes ,the pain is described as a dull, squeezing sensation in the chest ,sometimes radiating to left arm what is your diagnosis

A- Unstable angina
B- Stable angina
C- Pericarditis
D- Myocarditis
E- MI
Ans: B

CamScanner

501- A 62 year old women with DM and sedentary life style experiences chest tightness and discomfort after hearing stressful news,the pain radiates to her jaw and left arm but disappears after resting for few minutes what is your diagnosis

A- Stable angina
B- MI
C- Unstable angina
D- Panic attack
E- Pericarditis

Ans: A

502- A 40 year old male patient present in cardiology OPD with chest pain ,on ECG there was elevation in V3 and V4 which of the following vessel is effected

A- LCX
B- LAD
C- RCA
D- Marginal artery
E- Posterior descending artery

Ans: B

Explanation:

Area of infarction	Leads	Artery involved
Inferior wall MI	II,III,aVF	RCA
Anterior wall MI	V3 and V4	LAD
Anteroseptal MI	V1-V4	LAD
Anterolateral wall MI	V4-V6,I and aVL	LAD OR LCX
Posterior wall MI	Tall R waves and ST depression in V1-V4,tall upright T waves	Posterior descending artery

---

503- Patient had MI 6 months back now presented with chest pain and SOB.ECG shows bigeminy QRS complexes and inverted T waves cause is

A- Torsades de pointes
B- Prolong QT Syndrome
C- Premature ventricular contraction
D- Complete heart block

Ans: C

504- A patient present with multiple tumors,including angiomyolipoma and atrial myxoma which of the following condition is most likely associated with these findings

A- Tuberous sclerosis
B- Von hippel-lindau syndrome
C- Neurofibromatosis
D- Cowden syndrome
E- Sturge weber syndrome

Ans: A

505- An elderly patient develops generalized body edema. She has a history of being treated for tuberculous pericarditis 10 years ago. What is the most likely cause of her edema?

A- Constrictive Pericarditis
B- Congestive Heart Failure (CHF)
C- Miliary Tuberculosis (TB)
D- Nephrotic Syndrome

Ans: A

506- A patient came with newly developed murmur he gives history of having rheumatic fever in childhood. It is most likely associated with

A- Mitral stenosis
B- Aschoff bodies
C- Papillary muscle damage
D- Aortic Regurgitation

Ans: A

507- Order of cardiac enzyme elevation?(Medicine Feb 2025)

A- Myoglobin > CKMB > TROP I > LDH
B- Myoglobin > LDH > CKMB> TROP-I
C- Myoglobin > LDH = CKMB
D- LDH>TROP-I>CK-MB>MYOGLOBIN

Ans: A

508- A lady with S1Q3T3 Pattern on ECG.Best investigation of Choice will be: (Medicine Feb 2025)

A- Ventilation perfusion test
B- Pulmonary angiography (CTPA)
C- Spiral CT
D- ECG
E- D-Dimers

Ans: B

509- An MRI of the chest and abdomen is performed on an elderly patient to evaluate for age-related changes. Calcifications are seen. Which of the following is a benign change associated with aging?(Medicine Feb 2025)

A- Aortic calcification
B- Calcification of the coronary arteries
C- Calcification of the mitral valve
D- All of the above

Ans: D

510- A patient with a history of post-valvular stenosis is diagnosed with heart valve dysfunction. Which layer of the heart valve is most likely affected? (Medicine Feb 2025)

A- Ventricularis layer
B- Fibrosa layer (collagen)
C- Atrialis layer
D- Spongiosa layer (elastic)

Ans: B

511- A patient presents with signs of digoxin toxicity. Which of the following ECG findings is most commonly associated with this condition?(Surgery Feb 2025)

A- Monophasic T waves
B- ST segment depression
C- Biphasic T waves
D- Inverted T waves

Ans: C

512- Which ECG finding is most commonly associated with digoxin therapy?(Surgery Feb 2025)

A- Prolonged PR interval
B- Wide QRS complex
C- Inverted T waves
D- Scooped or sagging ST segment

Ans: D

513- In organophosphorus poisoning death occurs due to which of the following:(Gynae & Obs Feb 2025)

A- Cardiac arrhythmia
B- Respiratory failure
C- Kidney failure
D- Hypovolemic shock

Ans: B

514- Most common cause of non-Obstetrical maternal mortality in Pakistan(Gynae & Obs Feb 2025)

A- HIV
B- IHD
C- Asthma
D- Tuberculosis
E- Domestic Violence

Ans: B

515- Diabetic pregnant mother has amputed her toe, first and second finger because they first turn red and then became black which of the following is likely cause of her amputation?(Gynae & Obs Feb 2025)

A- DM
B- Atherosclerosis
C- Moenckeberg medial calcific sclerosis
D- Buerger Disease

Ans: B

516- A patient with a history of myocardial infarction (MI) one month ago undergoes evaluation. Which of the following best describes the predominant histological finding at this stage of healing?(Radiology Feb 2025)

A- Fibrous scar formation
B- Myocardial aneurysm
C- Granulation tissue with inflammatory cells
D- Coagulative necrosis

Ans: A

517- What is the most important determinant of prognosis in Tetralogy of Fallot? (Radiology Feb 2025)

A- Overriding aorta
B- Right ventricular hypertrophy
C- Ventricular septal defect (VSD)
D- Pulmonary infundibular stenosis

Ans: D

518- Aortic stenosis leads to ventricular hypertrophy. The biosynthesis of which molecule is affected? (Radiology Feb 2025)

A- Elastin
B- Collagen
C- Myosin
D- Fibrillin

Ans: B

519- TOF diagnosis made, what will be seen?(Anesthesia Feb 2025)

A- interatrial septal defect
B- pulmonary infundibulum stenosis
C- left ventricular hypertrophy
D- Right ventricular hypertrophy

Ans: B

520- 18 year old girl died suddenly and unexpectedly only headache history 2 Days back on autopsy lymphocytes in myocardium heart valve normal: (Anesthesia Feb 2025)

A- Pericarditis
B- Coxsackie
C- Myocarditis
D- Adeovirus

Ans: B

521- In mitral stenosis, when does the opening snap occur? (Anesthesia Feb 2025)

A- Beginning of diastole
B- End of isovolumetric relaxation
C- When atria contract during atrial systole
D- Mid-diastole
E- After S_2

Ans: E

522- A patient has a pansystolic murmur, LVH, and atrial fibrillation. What is the most likely cause? (Anesthesia Feb 2025)

A- Mitral stenosis (MS)
B- Mitral regurgitation (MR)
C- Tricuspid stenosis (TS)
D- Aortic regurgitation (AR)

Ans: B

CamScanner

GIT PATHOLOGY QUICK HINTS

Esophageal Cancer

Upper 2/3rd (Squamous cell carcinoma)
- ✓ Alcohol
- ✓ Hot Liquids
- ✓ Stricture
- ✓ Smoking Achlasia

Lower 1/3rd (Adenocarcinoma)
- ✓ Chronic GERD
- ✓ Barret Esophagous
- ✓ Obesity
- ✓ Smoking
- ✓ Achlasia

Gastritis

Acute

Erosions can be caused by:
- ✓ NSAIDs—Decreade PGE2 Decrease gastric mucosa protection
- ✓ Burns (Curling ulcer)
- ✓ Brain injury (Cushing ulcer)

Chronic
- ✓ H Pylori -MALT lymphoma affect antrum then body
- ✓ Autoimmune -Pernious anemia affect body/Fundus

Gastric Cancer
- ✓ Most commonly gastric adenocarcinoma
- ✓ Associated with blood type A.

Intestinal
- ✓ Associated with H pylori, dietary nitrosamines (smoked foods), tobacco smoking, achlorhydria, chronic gastritis.
- ✓ Commonly on lesser curvature looks likeulcer with raised margins.

Diffuse
- ✓ Most cases due to E-cadherin mutation
- ✓ Signet ring cells (mucin-filled cells with peripheral nuclei)
- ✓ Stomach wall grossly thickened and leathery (linitis plastica).

Peptic Ulcer disease

- ✓ Gastric ulcer increase with diet
- ✓ Dudenal ulcer decrease with diet
- ✓ H pylori cause Dudenal ulcer > Gastric ulcer
- ✓ Most common location of duodenal ulcer 1st part of duodenum.
- ✓ Perforation of posterior wall of duodenum bleeds by gastroduodenal artery.
- ✓ Most common location of gastric ulcer near incisura angularis on lessure curvature.
- ✓ Perforation of lesser curvature bleeds by left gastric artery.
- ✓ Perforation of posterior wall of stomach bleeds by splenic artery

Celiac disease

- ✓ Gluten-sensitive enteropathy
- ✓ Decrease mucosal absorption primarily affects distal duodenum and/or proximal jejunum
- ✓ Moderately increase risk of malignancy (eg, T-cell lymphoma)

Antibodies
- ✓ IgA anti-tissue transglutaminase (IgA tTG),
- ✓ Anti-endomysial
- ✓ Anti-deamidated gliadin peptide antibodies

Findings
- ✓ Villous atrophy
- ✓ Crypt hyperplasia
- ✓ Intraepithelial lymphocytosis.

Whipple disease

- ✓ Infection with Tropheryma whipplei (intracellular gram ⊕) PAS ⊕ foamy macrophages in intestinal lamina propria Mesenteric nodes.
- ✓ Cardiac symptoms
- ✓ Arthralgias
- ✓ Neurologic symptoms

Crohn disease

- ✓ Transmural inflammation
- ✓ Skip lesion
- ✓ Cobble stone appearance
- ✓ String sign
- ✓ Fistula formation

Ulcerative colitis

- ✓ Mucosal and submucosal inflammation Continous colonic lesion
- ✓ Crypt abscess
- ✓ Ulceration
- ✓ Lead pipe appearance

Intussusception

- ✓ In Intussusception sausage shape mass present
- ✓ In Intussusception USG/CT may show Target sign
- ✓ Associated with IgA vasculitis (HSP) and adenovirus

Polyp

- ✓ Villous adenoma most associated with Malignancy
- ✓ Tubular adenoma least likely associated with Malignancy
- ✓ Tubulovillous has intermeduate malignant potential

Malignant
- ✓ Adenomatous polyp
- ✓ Serrated

Non Malignant
- ✓ Hyperplastic polyp
- ✓ Hemartonatous polyp

FAP
- ✓ Autosomal dominant mutation of APC tumor suppressor gene
- ✓ Thousands of polyps arise starting after puberty; pancolonic; always involves rectum

Peutz-Jeghers syndrome
- ✓ Autosomal dominant syndrome featuring numerous hamartomas throughout GI tract, along with hyperpigmented macules on mouth, lips, hands, genitalia

Juvenile polyposis syndrome
- ✓ Autosomal dominant syndrome in children (typically < 5 years old) featuring numerous hamartomatous polyps in the colon, stomach, small bowel

Gardner syndrome
- ✓ FAP + osseous and soft tissue tumors

Turcot syndrome
- ✓ FAP or Lynch syndrome + malignant CNS tumor

Colorectal Cancer

- ✓ Rectosigmoid > ascending > descending.
- ✓ **Right side** (cecal, ascending) associated with occult bleeding
- ✓ **Left side** (rectosigmoid) associated with hematochezia and obstruction (narrower lumen).
- ✓ **Ascending**—exophytic mass, iron deficiency anemia, weight loss.
- ✓ **Descending**—infiltrating mass, partial obstruction, colicky pain, hematochezia.
- ✓ Can present with S bovis (gallolyticus) bacteremia/endocarditis or as an episode of diverticulitis.

CamScanner

- ✓ "Apple core" lesion seen on barium enema x-ray B .
- ✓ CEA tumor marker

Adenoma Carcinoma hypothesis seen

- ✓ Loss of APC gene -Colon at risk
- ✓ KRAS mutation -**Adenoma**
- ✓ Loss of tumor suppressor gene(s) (TP53, DCC)- **Carcinoma**

Hepatitis

- ✓ Orofecal Route - Hep A >Hep E
- ✓ Most lethal Hepatitis - Hep D
- ✓ Most common in pregnancy - Hep A
- ✓ Most lethal/Remote Area in pregnancy - Hep E
- ✓ Most lethal/Common virus after blood transfusion – CMV >Hep B > Hep C
- ✓ Most common sexual spread – Hep B
- ✓ HCC - Hep B > Hep C
- ✓ Cirrhosis – Alcohol >Hep C > Hep B
- ✓ Needle Stick injury Risk – Hep B (30%) > C (3%) > HIV (0.3%)
- ✓ Hep A & E - Naked Viruses
- ✓ Acute infection – HbsAg +ve, HbeAg +ve, Anti Hbc (Igm+ve), Anti Hbs -ve
- ✓ Chronic infection - HbsAg +ve, HbeAg +ve, Anti Hbc (IgG+ve), Anti Hbs -ve
- ✓ Immune from Previous infection - HbsAg -ve, HbeAg -ve, Anti Hbc, Anti Hbs +ve
- ✓ Immune from vaccination - HbsAg -ve, HbeAg -ve, Anti Hbc -ve , Anti Hbs +ve
- ✓ Window period - HbsAg -ve, HbeAg -ve, Anti Hbc (IgM +ve), Anti Hbs -ve

Liver pathology marker

- ✓ **Viral:** ALT>AST
- ✓ **Drug :** ALT
- ✓ **Alcohlic:** AST>ALT
- ✓ **Non Alcohlic:** ALT >AST
- ✓ **Non Alcohlic(Cirhosis or Fibrosis):** AST>ALT
- ✓ **Cholestatis Plus bone disease:** ALP Raised
- ✓ **Hepatobilliary:** Both ALP and GGT Raised
- ✓ **Liver disease plus pregnancy**: Check GGT always
- ✓ Albumin used for chronic liver disease
- ✓ PT >Factor V estimation used to see Developing Liver failure

Conjugated Hyper bilirubinemia

- ✓ Billiary disease(Stones)
- ✓ Dubin jonson
- ✓ Rotor syndrome

Un conjugated Hyper bilirubinemia

- ✓ Hemolysis
- ✓ Newborn
- ✓ Cirgler najar
- ✓ Gilbert

Mixed Hyperbillirubinemia

- ✓ Hepatitis
- ✓ Cirhosis

Wilson disease

- ✓ Present with Liver disease , Neurological disease and Kayser-Fleischer rings (deposits in Descemet membrane of cornea)
- ✓ Autosommal recessive Muts in ATP7B on chromosome 13
- ✓ Decreaase Cu excretion into bile
- ✓ Increase Cu in liver
- ✓ Cu spills in blood and deposists in brain and eye
- ✓ Low ceruloplasmin in serum
- ✓ **Diagnostic** – 24h urinary copper > Serum Ceruloplasmin
- ✓ **Best or Gold standard** – Liver Biopsy

Hemochromatosis

Iron over load secondary to transfusion

- ✓ Autosomal recessive. On HFE gene, located on chromosome 6
- ✓ Classic triad of cirrhosis, diabetes mellitus, skin pigmentation ("bronze diabetes").
- ✓ Also causes restrictive cardiomyopathy (classic) or dilated cardiomyopathy (reversible), hypogonadism, arthropathy (calcium pyrophosphate deposition; especially metacarpophalangeal joints).

Primary sclerosing cholangitis

- ✓ Onion skin bile duct fibrosis
- ✓ Associated with ulcerative colitis.
- ✓ P-ANCA ⊕ and Increase IgM.
- ✓ Increase risk of cholangiocarcinoma and gallbladder cancer

Primary billiary cirhosis

- ✓ Autoimmune reaction
- ✓ Classically in middle-aged women
- ✓ Anti-mitochondrial antibody ⊕, Increase IgM.
- ✓ Associated with other autoimmune conditions (eg, Hashimoto thyroiditis, rheumatoid arthritis, celiac disease).

Stones

- ✓ Pigment stones (black = radiopaque, Ca2+ bilirubinate,
- ✓ Hemolysis -brown = radiolucent, infection).
- ✓ Cholesterol stones (radiolucent with 10–20% opaque due to calcifications)—80% of sto

Pancreatitis

Acute

- ✓ Fatty necrosis seen
- ✓ Specific is Serum lipase > Serum amylase
- ✓ Complications: pseudocyst ,abscess, necrosis, hemorrhage, infection, organ failure

Chronic

- ✓ Chronic inflammation, atrophy, calcification of the pancreas
- ✓ Major causes include alcohol abuse and genetic predisposition
- ✓ Complications include pancreatic insufficiency and pseudocysts.

Pancreatic CA

- ✓ CA 19-9 tumor marker
- ✓ **Migratory thrombophlebitis**—redness and tenderness on palpation of extremities (Trousseau syndrome)
- ✓ Obstructive jaundice with palpable, nontender gallbladder (Courvoisier sign) Vs No palpable gallbladder in stones
- ✓ Most common in head of pancreas

Random

- ✓ Intermitten pain of Small intestine felt at umbilicus
- ✓ In Appendicitis pain us via - Sympathetic T10
- ✓ **Diverticulum** - Blind pouch A protruding from the alimentary tract that communicates with the lumen of the gut
- ✓ **Diverticulosis** - Many false diverticula of the colon commonly sigmoid
- ✓ **Diverticulitis** - Inflammation of diverticula with wall thickening classically causing LLQ pain, fever, leukocytosis
- ✓ Patient have abdominal pain on sigmoidoscopy there is obstruction in upper part of sigmoid colon with ulcer patient have appendectomy scar that was done few year back cause of this is – **Diverticulosis**
- ✓ **Most common site of volvulus is – sigmoid**
- ✓ **2 nd most common site of volvulus - Ceccum**
- ✓ **Midgut volvulus** more common in infants and children (minors)

CamScanner

- ✓ **Sigmoid volvulus** (coffee bean sign on x-ray more common in seniors (elderly)
- ✓ **Plummer vinson syndrome** has Triad of Dysphagia, Iron deficiency anemia, Esophageal webs and increase risk of esophageal Squamous cell carcinoma
- ✓ **Boerhaave syndrome**—transmural, usually distal esophageal rupture due to violent retching.
- ✓ **Mallory-Weiss syndrome** has Partial thickness, longitudinal lacerations of gastroesophageal junction
- ✓ HCC tumor is AFP and mainly caused by Hep B
- ✓ Angiosarcoma in Plastic Factory Worker –Vinyl chloride
- ✓ Angiosarcoma in Farmer – Arsenic
- ✓ **Hirshprung disease** is absense of ganglionic cell due to failure of neural crest cell migration. Associated with RET mutation and Down syndrome. It show Squirt sign(Explosive expulsion of feces)
- ✓ Most common site of **appendix – Retrocecal**
- ✓ 2nd most common ste of appendix is **Retrieval**
- ✓ 3rd most common site of appendix **- Pelvic**
- ✓ In western populationmost common cause of macrocytosis – **Alcohol**
- ✓ Baby diaper gets yellow due to – Billiary atresia
- ✓ Gastric lymphoma ssociated with – H.pylori gastritis
- ✓ H.pylori stained by – Sterner liver
- ✓ Bacteria which is carcinogenic is – H.pylori
- ✓ Terminal ileum resection will cause increase loss of water in
- ✓ Hydroxyindoacetic acid in urine – Carcnoid syndrome
- ✓ Pancreatic cells involved in DM – B- cells
- ✓ Severe steatorrhea result from **- Total pancreatectomy**
- ✓ In liver cell injury, enzyme decreased is – 5 neuclotidase
- ✓ Hairy leukoplakia associated with – HIV
- ✓ Zollinger Ellison syndrome associated with – Peptic ulcer disease
- ✓ Commonest cause of esophegeal perforation is instrumentation
- ✓ Connective tissue disorder associated with GERD – Scleroderma
- ✓ Most common area that have lymph nodes in abdomen – Illeum
- ✓ Test of choice for eradication of H.pylori – Urea breath test
- ✓ Double – bubble sign in – Deuodenal atresia
- ✓ Intestine commonly strangulated in – Omental burs
- ✓ Most common GIT malignancy in children – Lymphomas
- ✓ Typhoid Reside in Payer patches(1-4weeks) and in Gall Bladder (>4 weeks)
- ✓ Neonates commonly have hyperbilirubinemia due to – Hemolysis
- ✓ Pathological jaundice – first 24 hours of life
- ✓ Physiological jaundice – 2nd day onwards
- ✓ Breast milk jaundice- between 1 and 12 weeks in normal breast milk fed infants
- ✓ Breast feeding jaundice – first 3to 15 days of life
- ✓ Test used to differentiate the type of jaundice is
- ✓ Pregnant lady with bile duct obstruction , the best diagnostic test will be – GGT
- ✓ Alcoholic dysphagia is due to – **Strictures formation**
- ✓ Antibodies in primary sclerosing cholangitis - Anti-neutrophil cytoplasmic Antibodies
- ✓ Juvenile polyp is – Hemartomatous
- ✓ Chagas disease and congenital megacolon affects **- Muscularis Externa**

GIT PATHOLOGY

1- A patient having Total anti Hbc reactive, IgM –ve, Hbs ag-ve? What is diagnosing?

A- Past exposure
B- Vaccinated
C- Acute phase Hep. B
D- Transient resolving state

Ans: A (First Aid)

Explanation

- **Acute infection** – HbsAg +ve, HbeAg +ve, Anti Hbc (Igm+ve), Anti Hbs -ve
- **Chronic infection** - HbsAg +ve, HbeAg +ve, Anti Hbc (IgG+ve), Anti Hbs -ve
- **Immune from Previous infection** - HbsAg -ve, HbeAg -ve, Anti Hbc, Anti Hbs +ve
- **Immune from vaccination** - HbsAg -ve, HbeAg -ve, Anti Hbc -ve , Anti Hbs +ve
- **Window period** - HbsAg -ve, HbeAg -ve, Anti Hbc (IgM +ve), Anti Hbs -ve

2- A patient presented with Hepatitis viral markers negative, ALT slightly raised, on examination there were KF ring seen . What is the suitable diagnostic test?

A- Serum ceruloplasmin
B- Urinary copper
C- HbsAg
D- Anti mitochondrial ab

Ans: B

Explanation:

- Diagnostic – 24h urinary copper > Serum Ceruloplasmin
- Best or Gold standard – Liver Biopsy

3- What is Cause of fatty liver in our country

A- Hep B & Hep C
B- Alcoholism
C- Fatty diet
D- Starvation

Ans: D

4- Gastric lymphomas related to which of the following

A- H.pylori
B- Clostridium perfringes
C- Corneybacterium urealytiycum
D- EBV

Ans: A(Robins)

5- Which Cells of pancreas involved in DM-1

A- Alpha cells
B- Beta cells
C- Delta cells
D- Mucous cells

Ans: B

6- A female with history of itching jaundice xanthoma and heptatosplenomegalay required investigation for diagnosis is:

A- Anti mitochondrial antibodies
B- Anti cardiolipin
C- Antismoothmusle antibodies
D - Anti nuclear antibodies

Ans: A

7- Severe steatorrhea will result from which of the following

A- Gall bladder resection
B- Total pancreatectomy
C- Jejunum resection
D- Colon resection
E- Gastric resection

Ans: B

8- Most common cause of HCC in developing world

A- Hep B plus Hep C
B- Hep B
C- Hep C
D- Hep D

Ans: A

9- The life style pattern of healthy persons from 20 to 30 years of age are studied. A subset of these persons has a lifestyle characterized by consumption of a lot of pizza and very little physical activity. Which of the following tissue changes is most likely to develop in these subsets of persons as a consequence of this lifestyle

A- Fatty Metamorphosis of liver
B- Pancreatic fat Necrosis
C- Fatty degeneration of myocardium
D- Hypertrophy of Steatocytes

Ans: D

10- Patient presented with obstructive jaundice; now having bleeding cause is

A- Vit K deficiency
B- Decrease cloting factor production due to liver problem
C- Vit C deficiency
D- Decrease prothrombin

Ans: A

11- Patient with vague abdominal pain with nausea, pain was not related to any meal, no cardiac issues, glucose normal, endoscopy was done which showed normal stomach with no mass or ulcers, it was found non-ulcer gastritis, what is the cause?

A- H.pylori
B- Pernicious anemia
C- Zollinger ellison syndrome
D- Auto immune anemia

Ans: B

weeks in normal breast milk fed infants
Breast feeding jaundice – first 3to 15 days of life

- HypokalemiC- hypochloremic metabolic alkalosis is seen

<60mmhg | Fluid requirments>4L PCO2:not available

D- Surgery

Ans: C

CamScanner

12- In liver cell injury, enzyme decreased is
A- ALP
B- 5-nucleotidase
C- AST
D- GGT
E- ALT
Ans: B

13- Chronic hepatitis is characterized for how much duration
A- 6month
B- 3month
C- 2month
D- 1month
Ans: A

14- Chronic alcoholic with normal LFT on microscopy liver will show:
A- Hepatic atrophy
B- Normal
C- Fatty changes
D- Hyperplasia
Ans: C

15- Smoking and alcoholic presented with non-healing ulcer in oral cavity what it could be?
A- Squamous cell carcinoma
B- Basal cell carcinoma
C- Melanoma
D- Adenocarcinoma
Ans: A

16- Chronic liver disease which of the histological finding suggest chronicity?
A- Fibrosis
B- Councilman bodies(apoptosis)
C- Neutrophils
D- Macrophages
Ans: A

17- Bare area of liver related to:
A- Hepato gastric ligament
B- CBD
C- Hepato dudenal ligament
D- Coronary ligament
Ans: D

18- True about Hairy leukoplakia is
A- Fungal growth
B- Smoking
C- Associated with HIV
D- Leukemia
Ans: C

19- A 50 years patient who used to drinks from 20 years. His labs are Bilirubin 5 times raised than normal, ALT 2 times and ALP 3 times. His histopathology of liver will show
A- Piecemeal necrosis
B- Bridging necrosis
C- Councilman bodies
D- Periportal Lymphocytosis
Ans: A

20- Which vessel is involved in portal hypertension?
A- Portal vein
B- SMA
C- IMA
D- IVC
Ans: A

21- Which of the following disease presents with raised ALT most commonly?
A- Acute viral hepatitis
B- Hepatic malignancy
C- Sclerosing cholangitis
D- Hepatic adenoma
Ans: A

22- Pregnant lady with yellow sclera and dark colored urine Obstructive jaundice What is the appropriate investigation in this patient?
A- Serum glutamyltransferase
B- Alkaline phosphatase
C- Gamma glutamyl transferase
D- Liver biopsy
E- Ultrasound
Ans: C

Explanation:
- ✓ **Viral:** ALT>AST
- ✓ **Drug :** ALT
- ✓ **Alcohlic:** AST>ALT
- ✓ **Non Alcohlic:** ALT >AST
- ✓ **Non Alcohlic(Cirhosis or Fibrosis):** AST>ALT
- ✓ **Cholestatis Plus bone disease:** ALP Raised
- ✓ **Hepatobilliary:** Both ALP and GGT Raised
- ✓ **Liver disease plus pregnancy:** Check GGT always

Conjugated Hyper bilirubinemia
- ✓ Billiary disease(Stones)
- ✓ Dubin jonson
- ✓ Rotor syndrome

Un conjugated Hyper bilirubinemia
- ✓ Hemolysis
- ✓ Newborn
- ✓ Cirgler najar
- ✓ Gilbert

Mixed Hyperbillirubinemia
- ✓ Hepatitis
- ✓ Cirhosis

23- A 9-year-old boy presents to you with the history of yellow sclera & dark colored urine. Most appropriate investigation would be?
A- SGPT
B- SGOT
C- Bilirubin
D- SGPT & bilirubin
Ans: D

24- A 6 weeks old infant presents with jaundice on exam diaper is yellow stained diagnose is:
A- Gilbert syndrome
B- Biliary atresia
C- Crigller najar
D- Physiological
E- Pathological
Ans: B

25- An alcoholic present with Dysphagia, endoscopy shows circular patch at mid esophagus biopsy shows polygonal cells with pleomorphic changes cause is
A- H- Pylori
B- Fiber diet
C- Alcohol
D- Smoking
Ans: C

26- A person has previous history of jaundice 10 years ago. Now AST ALT both 100 plus. Bilirubin direct. 8 histology shows ballooning degeneration. what is patient likely to have further?
A- Deficiency a-antitrypsin
B- HbsAg
C- Antimitochondrail antibodies
D- Raised ceruloplasmin
Ans: B

27- 5 year old Child was diagnosed with polyp and he was having rectal bleeding. Polyp was removed from rectum by polypectomy what type of polyp it could be
A- Hypertrophic
B- Hyperplastic
C- Inflammatory
D- Hemorrhagic polyp
E- Adenomatous
Ans: D

28- A women with splenomegaly, conjugated bilirubin 1% with urinary bilirubinogen, hepatic abnormality is due to
A- Hemochromatosis
B- Hemolysis
C- Benign cholestasis
D- Biliary obstruction
Ans: B

29- Presence of delta antigen indicates
A- Infectivity
B- Recovery
C- Chronicity
D- Acute Phase
E- Fatality/Severity of disease
Ans: C

30- In CLD most affected thing is
A- Albumin
B- PT
C- Hemostatis
D- APTT
Ans: A

31- Quack gave medicine which causes hepatic necrosis which of following will increase?
A- ALT
B- ASt
C- LDH
D- Alkaline phosphatase
Ans: A

Explanation
- **ALT** – most likely acute viral , acute drug induced , severe necrosis of liver , Acute liver damage to Quack doctor medicine
- **AST** - Most likely Alcoholic , Drug induced chronic hepatitis , Chronic liver damage to Quack doctor medicine

32- After an abdominal surgery blood was transfused to a patient, after which he developed jaundice, vomiting and lethargy. Hepatitis was diagnosed. Which is most commonly transmitted via blood transfusions:
A- Hep A
B- Hep C
C- Hep D
D- HIV
E- Hep B
Ans: E(Kaplan)

Explanation:
- Orofecal Route - **Hep A >Hep E**
- Most lethal Hepatitis - **Hep D**
- Most **common** in pregnancy - **Hep A**
- Most **lethal/Remote Area** in pregnancy - **Hep E**
- Most Common virus after blood transfusion – **Hep B > Hep C**
- Most lethal after transfusion and transplant -- **CMV**
- Most common sexual spread – **Hep B**
- HCC - **Hep B > Hep C**
- Cirrhosis –**Alcohol > Hep C > Hep B**
- Needle Stick injury Risk – **Hep B (30%) > C(3%) > HIV(0.3%)**
- Hep A & E - **Naked Viruses**

CamScanner

33- A woman has presented with dysphagia which is worsening since 3 months. Now it is difficult for her to swallow pudding. On examination of the neck surgeon notices enlarged lymph nodes on the side of her neck. What is the cause?
A- CA Esophagus
B- CA trachea
C- TB
D- CA lung
Ans: A

34- Most common spread by orofecal route is which of following:
A- Hep. B
B- Hep. C
C- Hep. D
D- Hep. E
E- Hep. G
Ans: D

35- What should be checked to diagnose Hep B disease
A- Hbsantigen+antihbc igm
B- Hbsag+hbe antigen
C- Antihbc
D- Anti hbc igG
Ans: A

36- Few days after bacteremia of typhoid, where will the bacteria reside?
A- Gallbladder
B- Payer patches
C- Dudenum
D- illium
Ans: B
Explanation:
- Typhoid Reside in Payer patches(1-4weeks)
- Gall Bladder (>4 weeks)

37- Neonates commonly have hyperbilirubinemia due to:
A- Hemolysis
B- Dubin Johnson
C- Crigla najar
D- Rotor syndrome
Ans: A

38- Which is most commonly STD transffered among these
A- Typhoid
B- Hep B
C- TB
D- Hep A
E- Hep C
Ans: B

39- Patient with HBsAg +ve, Hbs ab-ve AFP 107 hepatic Nodule on U/S what is the diagnosis?
A- Hemangioma
B- Hepatocellular Carcinoma
C- Hepatic Adenoma
D- CLD
Ans: B

40- Patient Diagnosed with CA Gall bladder alongwith Cholilithiasis cause of his Cancer is:
A- Chronic Irritation
B- Stones
C- Obstructive jaundice
D- Infection
Ans: A

41- In Alcoholic liver microscopic finding is
A- Mallory Bodies.
B- Nutmeg liver
C- Fibrosis
D- Atrophy of hepatocytes
Ans: A

42- A women was being examined a single 2cm long mass which was covered by normal intestinal mucosa at base Diagnose is
A- Adenomatous polyp
B- Hyperplastic polyp
C- Hemorrhagic polyp
D- Adenoma
Ans: B

43- Patient presented with severe itching and jaundice.His total bilirubin is at 10 direct bilirubin 12 and ALP raised what is the cause
A- Intra hepatic cholestasis
B- Hemolytic jaundice
C- Extra hepatic cholestasis
D- CBD Obstruction
Ans: C

44- Newborn presented with jaundice after 2days of birth was breast fed indirect bilirubin 10:
A- Physiological jaundice
B- Pathological jaundice
C- Breast milk jaundice
D- Gilbert atresia
Ans: A
Explantaion
- **Pathological jaundice** – first 24 hours of life
- **Physiological jaundice** – 2nd day onwards
- **Breast milk jaundice**- between 1 and 12 weeks in normal breast milk fed infants
- **Breast feeding jaundice** – first 3to 15 days of life

45- Test used to differentiate the type of jaundice is
A- ALP
B- GGT
C- Total bilirubin
D- Direct bilirubin
E- Indirect bilirubin
Ans: B

46- Proximal part of small intestine removed what will be decreased?
A- Bile acid secretion
B- Emptying of solid food
C- Emptying of liquid food
D- Increase in pancreatic secretion
Ans: A

47- Hepatoma causes compression of Which of these
A- Portal vein
B- Hepatic vein
C- CBD
D- Hepatic duct
Ans: A
Explanation:
- Hepatoma will compress early Portal vein.
- **In IVC blockage** there will be dependent edema and dilated abdominal veins.
- **In Portal vein compression** there will be Ascities.

48- Child with constipation and on exam no neurons were present in colon diagnose is
A- Cystic fibrosis
B- Ectopic anus
C- Hirschsprung's disease
D- Obstruction
Ans: C

49- Pathology in dissecting aortic aneurysm is
A- Cougulative necrosis
B- Ischemic necrosis
C- Medial necrosis
D- Atherosclerosis
Ans: C

50- A person with 2 month history of foul smelling stools, bloating and pain investigation of choice is
A- Stool culture
B- Stool complete examination
C- Stool for colistridum.difficile
D- Chloride sweat test
Ans: B

51- Which of them increased most in hepatocyte damage?
A- SGPT
B- SGOT
C- GGT
D- ALP
Ans: A

52- Vagotomy above esophagus causes which of these
A- Loss of acid
B- Loss of movement at fundus and pylorus
C- Loss of antrum motility
D- Loss of bowel movement
Ans: A

53- 50 years old man diagnosed liver cirrhosis as presented to outpatient department with pain for 3 months, liver is enlarged and tender, there is suspicion of hepatocellular carcinoma, best investigation is to confirm diagnosis
A- AFP
B- CT scan liver
C- P53
D- CEA
E- Liver biopsy
Ans: B(CMDT)

54- Alcoholic dysphagia is due to which of the following?
A- Decrease peristalsis
B- Polyp formation in esophagus
C- Strictures
D- Increase peristalsis
Ans: C

55- Fibrinous necrosis associated with which among these
A- Hepatitis A
B- Hepatitis B
C- Hepatitis C
D- Hepatitis D
E- Hepatitis E
Ans: B(FA)

56- A boy ate chickpeas from road side developed Hepatitis , which type
A- Hep A
B- Hep B
C- Hep C
D- Hep D
E- Hep E
Ans: A

57- In CLD cause of hematemesis is involvement of
A- Left gastric vein
B- Right gastric vein
C- Splenic vein
D- Right gastrodudenal vein
Ans: A

CamScanner

58- Antibodies of importance in Primary sclerosing cholangitis?
A- Anti-mitochondrial antibodies
B- Anti-smooth muscle antibodies
C- Anti-ds-DNA
D- Anti-neutrophil cytoplasmic Antibodies
E- Anti Flagellar antibodies
Ans: D

59- A middle aged women presented in OPD with complaint of pain in the epigastric region posterior thoracic wall and right shoulder after a fatty meal the pain is originating from:
A- Appendix
B- Gall bladder
C- Kidney and ureter
D- Diaphragm
E- Spleen
Ans: B

60- Barret esophagus is
A- Anaplasia
B- Dysplasia
C- Metaplasia
D- Desmoplasia
Ans: C

61- Alcoholic patient presented with jaundice & AFP of 988 cause is
A- Alcoholic Hepatitis
B- RHF
C- Iron overdose
D- Cholestasis
Ans: A

62- Gastrectomy performed 1.2 years back now presented with deficiency of
A- Vitamin B12
B- Vitamin B6
C- Vitamin B3
D- Vitamin B5
Ans: A

Explanation:
- Partial Gastrectomy – Iron Deficiency anemia.
- Complete Gastrectomy – Megaloblastic anemia so inj. Vitamin B12 should be given
- Before 6 months – Iron Deficiency anemia.
- After 6 months – Megaloblastic anemia
- Over all – Iron Deficiency anemia > Megaloblastic anemia.
- Gastrectomy can produce Pernious anemia like symptoms but not actual Pernious anemia as it is Autoimmune.

63- Intrinsic factor is required for activation of which vitamin?
A- Vitamin B6
B- Vitamin B3
C- Vitamin B12
D- Folate
Ans: C

64- Which of the following Hepatitis has most lethal effect during pregnancy
A- Hep. A
B- Hep. B
C- Hep. C
D- Hep. D
E- Hep. E
Ans: E

65- A patient has gastric ulcer the pain will be felt in which of following region?
A- Epigastric region
B- Radiated to back
C- Shouldr tip
D- Iliac region
E- Lumbar region
Ans: A

Explanation
- **Pancreas** – back
- **Diaphragm** – shoulder
- **Gall bladder** – shoulder
- **Angina** – Arm, Jaw
- **Appendicitis** – Umbilical region
- **Stomach** – Epigastric region

66- A 50 years old male, diagnosed case of chronic pancreatitis, presented with steatorrhea, this abnormality is caused by the deficiency of which lipid digestive enzyme
A- Amylase
B- Lipase
C- Lactase
D- Enterokinase
Ans: B

67- Inflammation of portal triads that spills into adjacent lobules, bands of inflammation extending between portal areas and terminal hepatic (Central) Veins with foci of liver necrosis, diagnosis is:
A- Chronic Passive congestion
B- Chronic Active hepatitis
C- Fulminant hepatitis
D- Cirrhosis
E- Fibrosis
Ans: B

68- Patient presented with decrease peripheral pulsation with abdominal pain and creatinine kinase normal and pulsating abdominal mass with fasting glucose of 130 – 150 from last 20 years is most likely suffering from
A- Thoracic aortic Aneurysm
B- Abdominal Aortic Aneurysm
C- Rupture of IVC
D- Common Iliac artery Aneurysm
Ans: B

69- A 30 years old male suddenly died after a sudden rise in blood pressure, at autopsy the ruptured vessel completely lack the tunica media at the point of aneurysm most likely aneurysm is
A- Berry Aneurysm
B- Dissecting Aneurysm
C- Marfan Aneurysm
D- Mycotic Aneurysm
Ans: A

70- A 40 years old alcoholic patient presented with consolidation in right lung apex, he died & autopsy shows enlarged liver and hepatocytes filled with lipids, cause of death is
A- Alpha 1 Antitrypsin Deficiency
B- Chronic Alcoholism
C- Smoking
D- Liver disease
Ans: B

Explanation:
- As the scenario mentions history of drinking Alcohol so we pick Chronic Alcoholism as our option or else Alpha 1 anti tryspin deficiency may involve liver and lungs too but here chronic alcoholism is preferred

71- Medical lab technician presented with history of fatigue for 4 months, LFTs deranged with ballooning & inflammation of hepatocytes on biopsy, which test to perform?
A- HbsAg
B- HAV
C- HIV
D- EBV
Ans: A

72- A man presented with fever, rigors & renal parenchymal damage is most likely suffering from
A- UTI
B- Chronic Pyelonephritis
C- Acute Pyelonephritis
D- Appendicitis
Ans: C(Davidson)

73- A known smoker, presents with abdominal pain, bloody vomit and a 3cm lesion with no mass at the gastric antrum most suitable cause is
A- Peptic Ulcer Disease (PUD)
B- Gastric Carcinoma
C- Esophgeal Carcinoma
D- Mallory weis syndrome
Ans: A

74- Fat malabsorption could lead to which of the following?
A- Bleeding
B- Steatorrhea
C- Vitamin A deficiency
D- Carbohydrate Imbalance
Ans: B

75- Which of the following is Autosomal dominant condition?
A- Familial adenomatous polyposis
B- Hemophilia
C- DMD
D- None of the above
Ans: A(FA)

Explanation:
- FAP is autosomal dominant
- Hemophilia is X-Linked recessive
- DMD is X-Linked recessive

76- Site of red infarct is
A- Spleen
B- Liver
C- Kidney
D- Brain
Ans: B(Robins + FA)

Explanation:
Haemorehagic (Red Infarct)
- Due to venous occlusion seen in
- Liver
- Lung
- Intestine
- Testis

Pale infarct (White)
- Due to Arterial occulsion seein in
- Heart
- Kidney

77- A female patient with achalasia would have following
A- Absence of myenteric plexus in lower esophagus
B- Loss of lower esophageal sphincter tone
C- Increase Stomach peristalsis
D- Increase Intestinal motility
Ans: A

Explanation:
- Achalasia Cardia is one of the common cause of motor dysphagia that's caused by loss of inhibitory ganglion in the myenteric plexus in lower esophagus.

CamScanner

78- In Perforation of Posterior wall of stomach which artery is involved?
A- Gastroduodenal artery
B- Splenic artery
C- Gastroepoploic artery
A- Left gastric artery
Ans: B

Explanation:
- Perforation of posterior wall of duodenum Bleed by Gastro duodenal artery
- Perforation of lesser curvature Bleed by Left gastric artery
- Perforation of posterior wall of stomach Bleed by Splenic artery

79- Patient who is smoker and alcoholic.His lab report revealed increase bilirubin and increase alpha feto protein.Cause of raised alpha feto protein
A- Alcohol
B- Smoking
C- Hep. A
D- Drug use
Ans: A

80- What is the predisposing condition to Adenocarcinoma of the esophagus?
A- Lichen Planus
B- Leukoplakia
C- Erythroplakia
D- Barrett Esophagus
E- Ulcer
Ans: D

Explanation:
Upper 2/3rd (Squmous cell carcinoma)
- Alcohol
- Hot Liquids
- Stricture
- Smoking Achlasia

Lower 1/3rd (Adenocarcinoma)
- Chronic GERD
- Barret Esophagous
- Obesity
- Smoking
- Achlasia
-

81- A 12 years old boy presented with diarrhea not responding to routine anti diarrheal treatment. Jejunal biopsy showed partial villous atrophy with mansy PAS positive macrophages. Most likely diagnosis is
A- Carcinoid syndrome
B- Topical sprue
C- Giardiasis
D- Immunoproliferative disease
E- Whipple disease

Explanation:
- Improved with gluten free diet: Celiac disease
- Not responding to Gluten free diet: Giardiasis
- PAS positive: Whipples

82- A young patient presents with jaundice. The investigations revealed high serum ALP and decreased Hb and increased retic count. Most likely cause of jaundice is
A- Hepatitis
B- Drug induced cholestasis
C- Cholingiocarcinoma
D- Hematological malignancy
E- Pigment stones
Ans: E

83- Gall bladder has a stone in the upper part of the bile duct, what will increase?
A- Increase in fatty stool
B- Increase excretion of bile salts
C- Increase LDL
D- Increase formation of chylomicrons
E- Increase bile salts in circulation.
Ans: A

84- An alcoholic man presents with exhibition of prominent neck veins and limb swelling. He also had centrilobar congestion and early fibrosis of liver. The cause is
A- Alpha 1 antitrypsin deficiency
B- Right Heart Failure
C- Left Heart Failure
D- Chronic Alcoholism
Ans: D

85- A patient was administered drug by a quack, he presents with jaundice. Which of the following enzymes will be raised?
A- ALP
B- AST
C- ALP & AST
D- ALT
Ans: D

86- Medial necrosis on autopsy seen in
A- Berry aneurysm
B- Dissecting aneurysm
C- Polyarthritis nodosa
D- Fibrinoid necrosis
Ans: B

87- Treatment of choice in upper GI bleeding
A- Octerotide
B- Vitamin – K
C- FFP
D- Heparin
Ans: A

Explanation:
- DOC is terlipressin >Octreotide
- In IHD Octreotide preferred.
-

88- Most lethal organism after transfusion is
A- Hep. B
B- Hep. C
C- Herpes
D- CMV
Ans: D

Explanation:
- CMV >Hep B >Hep C
-

89- The vitamins which are produced by intestinal flora and absorbed into the blood
A- Vitamin D
B- Vitamin C
C- Vitamin K
D- Vitamin B12
E- Vitamin B6
Ans: C

90- The deficiency seen in plummer vinson syndrome is of which of these
A- Calcium
B- Magnesium
C- Sodium
D- Potassium
E- Iron
Ans: E

91- Most common cause of hepatic cirrhosis
A- Hepatitis B
B- Hepatitis A
C- Hepatitis E
D- Hepatitis C
Ans: D

Explanation:
- Most common sexual spread – **Hep B**
- HCC - **Hep B > Hep C**
- Cirrhosis –**Alcohol >Hep C > Hep B**

92- Morphological changes in chronic hepatitis
A- Apoptosis
B- Complement cascade
C- Peripheral necrosis and fibrosis
D- No major changes
Ans: C

93- Hepatitis B spreads through which among these
A- Coughing
B- Sneezing
C- Sexual contact
D- Breast feeding
Ans: C

94- The glands atrophy in the stomach of an alcoholic and smoker patient would result in
A- Anemia
B- Gastric cancer
C- Hypomobility of stomach
D- Diminished blood supply
Ans: A(Atrophic gastritis)

95- Gastric ulcers common location is
A- Fundus
B- Anterior wall of stomach
C- Antrum
D- Lesser curvature
Ans: D

96- Most common hepatitis that is found in Asia and has least amount of complications
A- Hep. C
B- Hep. E
C- Hep. D
D- Hep.A
Ans: D

97- Peptic ulcer pain is transmitted via
A- Greater Splanchnic Nerve
B- Lesser Splanchnic Nerve
C- Least Splanchnic Nerve
D- Costal Nerve
Ans: A

98- 26 year old girl 28 week of gestation developed vomiting, bilirubin 20mg/dl AST272 and ALT 220 two weeks back when she went to meet her parents in a remote village. What is her diagnosis?
A- Hep. A
B- Hep. B
C- Hep. C
D- Hep. D
E- Hep. E
Ans: E

99- Which cause of intestinal obstruction gives worst prognosis?
A- Adhesion
B- Diverticulitis
C- Mesenteric ischemia
D- Hernia
E- Intrinsic cause
Ans: C

CamScanner

100- Which one is correct match?
A- CA Lung with Alcohol
B- CA liver with Asbestos
C- CA Skin with alcohol
D- CA liver with alcohol
Ans: D

101- A 57 year old male with a history of alcoholism presented to the emergency room with abdominal pain, jaundice and hyperbilirubinemia.His labs show AST (SGOT) 88 U/L,ALT (SGPT) 121 U/L, Bilirubin Total 6.5 mg/dL.What is the cause of leakage of these liver enzymes in blood?
A- Hepatocyte membrane damaged
B- Increased level of enzymes in biliary tree
C- Increased level of enzymes is normal in Hep. C
D- Increased as result of fibrosis
E- Increase due to ischemia
Ans: A

102- A patient with alcoholic hepatitis with Mallory bodies. Interwoven structure is
A- Intermediate filaments
B- Beta Amyloid
C- Alpha syncline
D- Alpha Amyloid
Ans: A

103- Biochemical change in Wilson disease?
A- ↓Ceruloplasmin
B- ↓Copper in liver brain cornea kidneys
C- ↓Urinary Copper
D- ↑Ceruloplasmin
Ans: A

104- A chronic alcoholic suffering from liver cirrhosis developed portal hypertension with caput medusa. In this condition, the veins around the umbilicus are connected to the left branch of portal vein through
A- Hepatic portal vein
B- Lumbar veins
C- Musculophrenic veins
D- Paraumblical veins
E- Thoraco-epigastric veins
Ans: D

105- In liver cell injury, enzyme decreased is
A- ALP
B- 5-nucleotidase
C- AST
D- Pseudocholinestrase
E- ALT
Ans: D

106- A baby dies after birth with edema jaundice and anemia on post partum you find which of da following changes:
A- Bile pigments in basal ganglia
B- Heart problem
C- CNS problem
D- Liver problem
E- GIT problem
Ans: A

107- In the first week of typhoid fever, which is the most probable diagnostic test?
A- Widal test
B- Blood culture
C- Typhidot
D- Stool culture
E- Urine culture
Ans: B

Explanation:
BASU
- Blood Culture – 1st week
- Agglutination Test (Widal Test) – 2nd week
- Stool culture – 3rd week
- Urine culture – 4th week

108- Young male anti HCV positive. Asymptomatic and LFTs are normal. What is the next best investigation?
A- Repeat anti HCV
B- Repeat LFT
C- Biopsy
D- PCR RNA
Ans: D

109- Alcoholic patient presented with abdominal pain, serum amylase 1600, ALT 75, ALP 200 diagnosis:
A- HCC
B- Obstructive jaundice
C- Acute pancreatitis
D- Hepatitis
Ans: C

110- A patient's 100cm of ileum was resected which vitamin is needed for supplementation
A- Vitamin C
B- Vitamin K
C- Vitamin B12
D- Vitamin B6
Ans: C

111- Cancer of Head of pancreas will compress which structure
A- SMA
B- CBD
C- Portal vein
D- Hepatic artery

About Colon Adenocarcinoma?
112-
A- RAS mutation
B- Cell from biopsy will show telomerase 1 Antibody
C- P53 not involved
D- Not linked with fatty diet
Ans: A

113- A man consumed food from street vendor develops right hypochondriac pain. After 10 days in hospital he suddenly developed dyspnea with hemoptysis with streaks of blood. X-ray was done showing homogenous opacity with multiple air fluids level confirming lung abscess. What could have possibly caused the lung abscess
A- Hematogenous spread from liver
B- Aspiration of vomitus containing trophozoite
C- Aspiration of vomitus containing cyst
D- Direct extension of infection via liver
Ans: D

114- A patient diagnosed and treated for hepatitis what findings will show possibility of high transmission of infection
A- Hbe Ag+ and HBe Ab-
B- Hbs Ag+ and HBs Ab-
C- HBc Ag+ and HBs Ag-
D- HBc Ag+ and HBc Ab-
E- Hbe Ag+ and HBs Ab+
Ans: A

115- Most common hepatic malignancy:
A- Metastasis to liver
B- Hepatocellular carcinoma
C- Chronic hepatitis
D- Cirhosis
Ans: A

116- Treated case of Hep A will show on histology
A- Fibrosis
B- Lymphocytes
C- Normal histology
D- Cirhosis
Ans: C

117- Malignancy that spreads through blood relation more
A- HCC
B- CA Colon
C- Medullary CA thyroid
D- Hep A
Ans: A

118- Alcoholic patient present with bleeding from hair follicles and ulcer not healed, which cell is defective?
A- Hepatocytes
B- Fibroblasts
C- Collagen
D- Elastin
Ans: B

119- HCC Tumor marker is which of following
A- AFP
B- CEA
C- CA 19-9
D- CA 125
Ans: A

120- Edema in CLD cause is
A- Increased hydrostatic pressure
B- Portal hypertension
C- Decrease plasma colloid osmotic pressure
D- Increase plasma oncotic pressure
Ans: C

Explanation:
- Peripheral edema in CLD due to – loss of albumin (Low oncotic pressure)
- Ascities in CLD due to – Portal HTN
- Renal origin edema due to – Loss of albumin (low oncotic pressure) + can be salt and water retention.
- Nephrotic syndrome edema due to - Hypoalbuminemia
- Nephritis syndrome edema due to - Salt and water retention.
- Pedal edema in CHF and HTN due to – Increase hydrostatic pressure.
- In CHF edema woarsen by – Sodium and water retention.

121- Mass near porta hepatis, structure damaged will be
A- Common hepatic artery
B- Cystic duct
C- Portal vein
D- Hepatic vein
Ans: C

122- Which of the following dietary substance is a carcinogen and play a role in carcinoma esophagus?
A- Nitrosamines
B- Naphthalamine
C- Hydrocarbons
D- Asbestos

CamScanner

123- Commonest cause of fatty liver disease in our country
A- Viral hepatitis
B- Obesity
C- Protein deficiency
D- Alcohol
Ans: C

124- A few days old new born presented with abdominal distention and vomiting was diagnosed as a case Hirschsprung disease in which there is complete absence of parasympathetic ganglia. These ganglia receive preganglionic innervation from which segment of cord?
A- S1, 2, 3
B- S2, 3, 4
C- L2-4
D- L55-S1
Ans: B

125- Meckel's diverticulum is found in
A- Duodenum
B- Sigmoid colon
C- Ileum
D- Jejunum
Ans: C

126- Most resistant organ to transplant rejection is
A- Heart and lungs
B- Pancreas
C- Kidney
D- Intestine
E- Liver
Ans: E

127- A chronic smoker came with history of weight loss and jaundice. His LFTS are deranged. He also has history of consuming large amount of alcohol initial Investigations gave suspicion of hepatic carcinoma. What will be most probable cause?
A- Aflatoxin
B- Smoking
C- Alcohol
D- Nitrosamine
Ans: C

128- A patient suffering from crohn s disease had 100 cm ileal resection what will result
A- Decrease fat absorption
B- Increase water content of faeces
C- Increased bile Acid concentration in enterohepatic circulation
D- Increase absorption of iron
Ans: B

129- What is a feature of crohn's disease?
A- Surgical resection always curative
B- Does not involve mucosa
C- Does not involve small intestine
D- Hyperoxaluria
E- Ca absorption increases
Ans: D

130- Best Monitoring test for Hepatitis B?
A- GGT
B- SGPT
C- PT
D- Serum bilirubin
E- Alkaline phosphatase
Ans: B

Explanation:
- Monitoring test For Hep B – ALT
- To see developing Liver Filer or Prognostic factor – PT >Factor V

131- Following splenectomy which organism least likely to cause severe septicemia?
A- Meningococcus
B- Neisseria
C- E.Coli
D- Pneumococcus
E- Haemophilus
Ans: C

Explanation
- The order of infection after splenectomy is → S.Pneumoniae >> H.Influenza >> N. Meningitidis >> Beta hemolytic Streptococcus >> Staphylococcus Aureus >> Escherichia Coli >> Pseudomonas sp

132- Investigation done for hepatic encephalopathy is:
A- Serum ammonia level
B- Serum creatinine
C- Potassium
D- Sodium
Ans: A

133- 60 years farm worker presented with ascites, contain malignant cells, liver biopsy showed Angiosarcoma cause is
A- Aflatoxin
B- Arsenic
C- Hydrocarbons
D- Nitrosamine
Ans: B

Explanation:
- Angiosarcoma in Plastic Factory Worker – **Vinyl chloride**
- Angiosarcoma in Farmer – **Arsenic**

134- Aflatoxin causes which of these:
A- HCC
B- Hepatic adenoma
C- Hemangioma
D- Hepatoma
Ans: A

135- The parasite associated with cholangiocarcinoma is
A- Clonorchis sinensis
B- Leishmania donovani
C- Schistosoma Japonicum
D- Schistosoma Mansoni
E- Toxoplasmosis Gondii
Ans: A

136- Which of the following occurs in severe diarrhea?
A- Metabolic alkalosis
B- Metabolic acidosis
C- Respiratory acidosis
D- Respiratory alkalosis
Ans: B

137- Strong correlation with colorectal cancer is seen in:
A- Peutz-Jeghers polyp
B- Familial polyposis coli
C- Juvenile polyposis
D- Hyperplastic polyp
Ans: B

138- Right upper quadrant abdominal pain that radiates to tip of right shoulder this is clinical finding of:
A- Acute pancreatitis
B- Acute cholecystitis
C- Cholelithiasis
D- Appendicitis
Ans: B

139- The most common complication of pancreatitis is
A- Pancreatic abscess
B- Pancreatic pseudocyst
C- Pancreatic Hemorrhage
D- Malabsorption
Ans: B

140- Juvenile polyposis syndrome is:
A- Neoplastic
B- Hyperplastic
C- Adenomatous polyp
D- Haemartomatous
Ans: D

141- Patient undergo Barium swallow Feathery appearance in left abdomen feature of which of these
A- Jejunum
B- Ileum
C- Stomach
D- Gall bladder
Ans: A

142- The cause of primary hepatic carcinoma
A- Alpha Antitrypsin 1 deficiency
B- Aflatoxin 1 in Diet
C- Naphthalene
D- Hydrocarbons
Ans: B

143- Patient showing no improvement with H2 blocker is likely due to
A- Gastric Ulcer
B- Zollinger Ellison syndrome
C- Pernicious Anemia
D- ITP
Ans: B

144- A Deficiency of enzyme produced by brush border will cause
A- Lactose intolerance
B- Steatorrhea
C- Inability of miscelle formation
D- Decrease absorption of triglycerides
Ans: A

145- An African woman had hepatic adenoma. Exposure of which of the following is involved?
A- Aflatoxin
B- Betel nuts
C- Steroids
D- Arsenic
E- Vinyl chloride
Ans: C

146- A pregnant patient presented with jaundice, deranged AST, ALT, most common Hepatitis is
A- Hep. A
B- Hep. B
C- Hep. C
D- Hep. E
E- Hep. D
Ans: A

147- Squamocolumnar epithelium present 3 cm above of cardiac end of esophagous diagnose is:
A- Normal Variant
B- Esophagous Carcinoma
C- Barrett Esophagous
D- Adenocarcinoma
E- Stricture formation
Ans: C

CamScanner

Explanation:
- Upto1-2cm – Normal Variant
- Above 3cm – Barrette Esophagous

148- Most common cause of liver cirrhosis:
A- Hep. C
B- Hep. B
C- Alcohol
D- Hep. A
E- Aflatoxin
Ans: C

Explanation:
- Most common sexual spread – Hep. B
- HCC – Hep. B > Hep. C
- Cirrhosis - Alcohol >Hep. C > Hep. B
- Needle Stick injury Risk – Hep. B (30%) > C (3%) > HIV (0.3%)

149- In alcohlic patient steatohepatitis develop due to which of these
A- Acetate
B- Acetoacetate
C- H_2O_2
D- Acetaldehyde
Ans: D

150- A pregnant lady presented with obstructive Jaundice features which of the following investigation will confirm the diagnosis?
A- GGT
B- Bilirubin
C- ALP
D- AST
E- ALT
Ans: A

151- A patient having HCV +ve LFT's normal and PCR positive what is next best approach is?
A- Start interferon
B- Start ribavirin
C- Start interferon + ribavirin
D- Biopsy
E- Do nothing
Ans: C

152- Most Prominent effect of Vagotomy on GIT is:
A- Loss of migratory motor complex
B- Decreased proximal stomach contraction
C- Decreased distal stomach peristalsis
D- Loss of secondary persistlatic waves in esophagus
Ans: C

153- A 25 year old man presented with the complaint of post prandial bloating & abdominal cramping. He has history of passing foul smelling stool. Which investigation will give us multiple information regarding the problem?
A- Stool C & S
B- Stool DR
C- Serum lipid profile
D- Ultrasound abdomen
E- MRI
Ans: B

Explanation:
When sign of infection present choose Stool C/S and to rule out mass or malignancy we do Stool DR

154- A 23 year old man wants to increase his muscle mass for playing physical contact sports. He attempts to accomplish by injections of a substance obtained from a 'friend'. Over the next year he develops acne , icterus and increased fatigue. An infertility workup reveals hypospermia. Laboratory studies shows HB 19.2 g/dl, HCT 58.1.4% , Platelet count 330,300/ microliter and WBC count 7410/ microliter. Which of the following neoplasms is he at the greatest risk for developing in future?
A- Hepatocellular carcinoma (HCC)
B- Papillary carcinoma
C- Renal cell carcinoma (RCC)
D- Rhabdomyosarcoma
E- Seminoma
Ans: A (Androgen Induced)

155- A patient having alternative diarrhea and constipation habits and per rectal bleeding diagnosed as a case of colon cancer which is the tumor marker?
A- Alpha fetoprotein
B- CEA
C- CA-125
D- BRCA -2
E- CA 19-9
Ans: B

156- 40yrs old male with jaundice liver function tests shows direct bilirubin 10, AlP 1000, ALT 75, GGT 227 what is the most likely diagnosis?
A- Intrahepatic cholestasis
B- Hepatic cholestasis
C- Bile duct obstruction
D- Drug induced jaundice
E- Extra hepatic cholestasis
Ans: E

157- A Chronic smoker and alcoholic having ulcer on lower lip margin which is indurated and pale type of CA develop is?
A- SCC
B- Basal cell CA
C- Adeno CA
D- Lymphoma
Ans: A

Explanation:
- Upper lip – BCC
- Lower lip SCC
-

158- Known smoker presents with dysphagia to solid foods. This dysphagia is due to which of following mechanism?
A- Decrease Saliva
B- Decreased peristalsis
C- Achalasia
D- Barrette esophagus
Ans: B

159- A patient of jaundice with Total bilirubin 10, direct 9, what is the cause?
A- Criggler Najar
B- Gilbert Syndrome
C- Cholidocholilithias
D- Physiological jaundice
E- Cirhosis
Ans: C

160- Rh negative mother delivered a baby at 34 weeks with anemia pallor. Baby died 6 hours after transfusion. Autopsy findings?
A- Basal ganglia staining
B- Cardiac malformations
C- Hydrops fetalis
D- Renal cyst
Ans: A

161- A patient having retrosternal chest pain nausea and GERD with velvety esophagous and columnar epithelium it will increase chance of which of these?
A- Esophagitis
B- Barret esophagous
C- Mallory weise tear
D- Gastritis
Ans: B

162- The most common cause of ascites in patient of chronic HCV:
A- Increase colloid osmotic pressure
B- Increase hydrostatic pressure.
C- Decrease colloid osmotic pressure
D- Decrease hydrostatic pressure
Ans: C

163- Young female develops endometrial CA. Mother died of same disease. Brother diagnosed case of colon CA. What gene is mutated in family?
A- WT-1
B- APC
C- MSH-2
D- P53
E- BRCA-1
Ans: C

164- A 15 year old boy C/O loss of appetite, vomiting & high coloured urine, O/E yellow discoloration of sclera, investigation of choice is?
A- Alkaline phosphatase estimation
B- Bilirubin & ALT estimation
C- Liver biopsy
D- Serum & Urinary bilirubin
E- GGT
Ans: B

165- 40y old lady presents with hepatosplenomegaly, pruritis, xanthlesma and jaundice for last 3 months most appropriate
A- ALT
B- ALP
C- U/S
D- AMA
E- GGT
Ans: D

166- Adenoma carcinoma mechanism of tumerogenesis sequence typically showed by:
A- Cervical ca
B- Hepatic Angio carcinoma
C- Lung carcinoma
D- Endometrial CA
E- Colon CA
Ans: E (Robins +FA)

167- Liver carcinoma caused by which of following?
A- Aromatic amines
B- Hydrocarbon
C- Aflatoxin B1
D- Benzidine
E- Nitrosamine
Ans: C

168- A patient having facial paralysis, angular cheilitis and fissure tongue the most likely associated syndrome is which of following?
A- Merkersson-rosenthal syndrome
B- Frey's syndrome
C- Reiter's syndrome
D- Eagle syndrome
E- Reeder's syndrome
Ans: A

CamScanner

169- Man with gunshot injury 3 finger beneath xiphisternum and two episodes of hematoemesis siteof lesion is:
A- Lesser Curvature
B- Cardio esophageal junction
C- Lower Third of esophagous
D- Greater Curvature
E- Pyloric
Ans: C

170- A 22/32 year old patient was prescribed analgesic for 2 months for a chronic infection. Now he is presented with complain of diarrhea 7-8 stools per day and vomiting. What will be seen on colonoscopy?
A- Dense mucosa
B- Fragile submucosa
C- Multiple abscess
D- Hemartamous polyps
Ans: B

171- A researcher working on different chemical carcinogens. These carcinogens cause carcinogenesis by:
A- Permanent change in DNA
B- Change in mitochondia
C- Change in lysosome
D- Change in RNA
E- Damage peroxisome
Ans: A

172- Most common malignancy of large bowel:
A- Carcinoid
B- Lymphoma
C- Adenoma
D- Adenocarcinoma
E- Mesenteritis
Ans: D

173- A patient presented with pain in right hypochondrium, Nasuea and and jaundice Pain is going to shoulder region and upper back which condition is associated?
A- Appendicitis
B- Hepatitis
C- UTI
D- Cholecystitis
E- Urethritis
Ans: D

174- Esophageal stage of swallowing effected by:
A- Gastritis
B- Scleroderma
C- GERD
D- Hepatitis
Ans: B

175- A middle aged women was diagnose with the moderately differentiated adenocarcinoma of stomach and she had a history of biopsy few year ago shows premalignant condition most likely is:
A- Atrophic gastric
B- Nonspecific gastritis
C- Hamartomatous polyp
D- Hyperplastic polyp
E- Juvinile polyp
Ans: A

176- A patient contacted with hepatitis b virus on viral serology which of the following hepatitis would it require to have because it's weak in its own:
A- Hep. A
B- Hep. B
C- Hep. C
D- Hep. E
E- Hep. G
Ans: B

177- In Chronic alcoholic, FNA biopsy of liver will most likely show:
A- Disorganized liver architecture
B- Constricted central vein
C- Normal portal triads
D- Mitotically active hepatocytes
E- Distortion of porta hepatis
Ans: A

178- A 68y man who is a known case of liver cirrhosis has developed ascites. What is the mechanism for the development of ascites?
A- Portal HTN
B- Hypo-albuminuria
C- Congestive heart failure
D- Liver failure
E- Salt retention
Ans: A

179- A student want to get vaccinated with hepatitis b vaccine but he is not sure about his previous vaccination against hep.B which test is done to know the previous vaccination status?
A- Anti HbS antibodies
B- Anti Hb e antibodies
C- Hbs Ag
D- Hbe Ag
Ans: A

180- The pressure on lower esophageal sphincter is increased due to:
A- Smoking
B- Alcohol
C- Increase Serum gastrin
D- After fatty meal
E- Anticholinergic
Ans: C

Explanation:

Increase LES pressure	Decrease LES pressure
M receptor agonist	Botulinum Toxin and CCB, anticholinergic
Alpha receptor agonist	Gastric distension
D2 receptor antagonist (Metachlopromide)	Dopamine
Gastrin, Motilin	Secretin ,CCK and Progesteron
Protein Meal	Fat meal, chocolates and smoking

181- Nutmeg liver cause is:
A- Peri portal congesion
B- Centri lobular congestion
C- Peripheral congestion
D- Chronic Passive congesion
Ans: D

182- Person taking high performance drug has increase HB, Acne and Striae. Which carcinoma is likely to develop?
A- RCC
B- HCC
C- Pancreatic CA
D- Gastric CA
Ans: B (Androgen induced)

183- HCV is which type of virus?
A- DNA
B- RNA
C- RNA + DNA
D- None
Ans: B

184- Patient present with complain of abdominal bloating and diarrhea. Reports show bilirubin 16, ALP 365, alpha-fetoprotein normal and raised CEA. Diagnosis:
A- Ulcerative colitis
B- Crohn disease
C- Stomach CA
D- CA Colon
Ans: D

185. Most common cause of bleeding in duodenal ulcer in Posterior wall is which artery?
A- Superior pancreatic duodenal artery
B- Inferior pancreatic duodenal artery
C- Gastro duodenal artery
D- Right gastroepiploic artery
E- Left gastroepiploic artery
Ans: C

186- A alcoholic patient present to doctor with acute abdominal pain doctor diagnosed it as a case of acute pancreatitis which of the following laboratory test use for best for confirmation?
A- Serum amylase + CBC
B- Serum lipase + CBC
C- Serum amylase + Serum lipase
D- CBC
Ans: C

187- What is the characteristics sign of crohns disease?
A- Transmural inflammation
B- Continuous lesion
C- Cause cancer in young
D- Lead pipe appearance on imaging
Ans: A

Explanation

Disease	Crohn's disease	Ulcerative colitis
Location	Terminal ilium with colon	rectum
spread	Continuous	Discontinuous
Morphology	Transmural inflammation	Mucosal and submucosal inflammation
Gross features	Cobblestone mucosa, creeping fat, bowel wall thickening	Friable mucosa with superficial and/or deep ulcerations, "lead pipe" appearance on imaging.
Microscopy	Noncaseating granulomas and lymphoid aggregates	Crypt abscesses and ulcers, bleeding, no granulomas.
Complications	Fistulas, phlegmon/abscess, strictures (causing obstruction), perianal disease	Fulminant colitis, toxic megacolon, perforation.
Extraintestinal complications	Kidney stones	Rash (erythema nodosum), eye inflammation (episcleritis, uveitis), oral ulcerations (aphthous stomatitis), arthritis (peripheral, spondylitis).
Treatment	Corticosteroids, azathioprine, antibiotics (e.g., ciprofloxacin, metronidazole), biologics (e.g., infliximab, adalimumab)	5-aminosalicylic acid preparations (e.g., mesalamine), 6-mercaptopurine, infliximab, colectomy.

CamScanner

188- Patient with dysphagia severe chest pain difficult belching and air fluid level ECG looks normal Cardiac enzyme normal this is likely due to:
A- GERD
B- Achlasia
C- Erosive intake
D- Esophagitis
Ans: B

189- The main difference between crohns disease and UC is:
A. Peri anal lesion
B. Primary sclerosing cholangitis
C. Toxic megacolon
D. Crypt abscesses
Ans: A

190- 40 years old man known alcoholic for 10 years shows deranged LFTs, liver biopsy of such patient shows:
A- Loss of architecture
B- Hyperplasia
C- Dilated hepatic veins
D- Congestion of hepatic ducts
Ans: A

191- H-pylori causes:
A- Colorectal carcinoma
B- Gastric cancer
C- Breast cancer
D- Ovarian cancer
Ans: B

192- A patient of portal hypertension has dilated engorged prominent veins para umbilical is called:
A- Spider angioma
B- Spider nevi
C- Caput medusae
D- Pyloric stenosis
Ans: C

193- Most common cause of epigastric pain:
A- Hernia
B- Gastric ulcers
C- Gastric carcinoma
D- Perforation
Ans: B

194- Ileal resection causes the deficiency of:
A- Vitamin B6
B- Vitamin B12
C- Vitamin K
D- Vitamin D
Ans: B

195- Patient presented with Hx of fever and jaundice which type of gall stones are present?
A- Crystalline
B- Cholesterol
C- Pigmented
D- None
Ans: C

196- 55years old male with past history of epigastric pain for which he was taking antacids was diagnosed as gastric lymphoma what is the most likely cause?
A- Drug induced gastritis
B- Ulcers
C- Intestinal metaplasia
D- Atopic gastritis
E- H. Pylori
Ans: E

197- Hepatitis associated with p-ANCA :
A- Hepatitis A
B- Hepatitis B
C- Hepatitis C
D- Hepatitis D
E- Hepatitis E
Ans: B

Explanation
- P-ANCA Granulomatosis associated with - Hep B
- Polyarteritis Nodosa is associated with - Hep B
- C-ANCA is associated wtith – Wegner granulomatosis

198- After Partial Gastrectomy of a patient most likely develops?
A- Iron deficiency anemia
B- Fat malabsorption
C- Pernicious anemia
D- Blood loss anemia
Ans: A

199- Major hemostatic defect in CLD:
A- Raised BT
B- Raised PT
C- Raised APTT
D- Raised FDP
Ans: B

200- A patient presented with anemia his total gastrectomy was done in past. Now having tingling sensation. What is treatment option
A- Inj Folic acid
B- Folic acid
C- Inj B12
D- Iron
Ans: C

201- The best diagnostic test for Wilson disease:
24 hrs urinary copper excretion
A: Serum ceruloplasmin
B: Serum copper level
C: Liver biopsy
D: D
Ans:
Explanation:
- Diagnostic – 24h urinary copper > Serum Ceruloplasmin
- Best or Gold standard – Liver Biopsy
-

202- Diagnosed appendicular tumor which has mucinous secretion called Pseudomyxoma peritonei will spread how?
Lymph node
A. Venous
B. Arterial spread
C. Venous and lymph
D. Seeding to other sites
E.
Ans: E

203- A person having chronic anemia and on ultrasound having Stones in gall bladder which one is likely to be raised?
A- AST
B- ALT
C- ALP
D- SGPT
Ans: C

204- A patient history bloody diarrhea and weight loss with pallor. He was diagnosed as case of Colon Carcinoma and was treated for that. Now which marker is used for follow up of that patient?
A- AFP
B- CA 125
C- CA 19-9
D- CEA
E- CA 15-3
Ans: D

205- CLD caused by which virus?
A- Hep. C
B- Hep. D
C- Hep. A
D- Hep. E
Ans: A

Explanation
- **HCC** - Hep B > Hep C
- **Cirhosis** – Alcohol >Hep C > Hep B
- **CLD** – Hep C

206- Boy has dysphagia, regurgitation of food and complains of dull Sternal pain. Bariam swallow shows esophageal enlargement:
A- Achlasia
B- Gastritis
C- Gastric ulcer
D- Duedenal ulcer
Ans: A

207- Epigastric pain going to back organ involved is:
A- Liver
B- Pancreas
C- Stomach
D- Kidney
Ans: B

Explanation
- **Pancreas** – back
- **Diaphragm** – shoulder
- **Gall bladder** – shoulder
- **Angina** – Arm, Jaw
- **Appendicitis** – Umbilical region
- **Stomach** – Epigastric region

208- True about IBS:
A- Psychosomatic disturbance
B- Continues Constipation
C- Continues Diarrhea
D- None of the above
Ans: A

209- Zollinger ellison syndrome associated with:
A- Decrease Gastric acid
B- Increase Gastric acid
C- Increase Parietal cells
D- Increase mucous cells
Ans: B

210- A patient with acute appendicitis pain and fever for last 24h on pathological examination seen:
A- Neutrophil in muscular wall
B- Lymphoid hyperplasia with giant cell in muscular wall
C- Macrophages in muscular wall
D- Eosinophils
E- Monocytes
Ans: A

211- A diabetic patient with abdominal pain, severe vomiting and visible peristalsis and audible sound on examination, the condition is:
A- GERD
B- Achalasia
C- Crohn Disease
D- Pyloric stenosis
E- Gastritis
Ans: D

CamScanner

212- A 30 year old man has symptoms of reflux esophagitis esophageal biopsy revealed columnar lining with intestinal metaplasia this patient has increase risk of developing
A- Adenocarcinoma Stomach
B- Adenocarcinoma Esophagus
C- Adenocarcinoma of Lung
D- Adenocarcinoma of Trachea
Ans: B

213- An young man has liver enlargement and splenomegaly his ALT is 256IU and AST is 300IU his serum ceruloplasmin was low , what findings will you see in this patients
A- Lense opacities
B- Kayser fleischer ring
C- Spiderr angioma
D- Ptosis
Ans: B

214- Patient with complain of regurgitation chest pain mid night partially relieved by elevation of bed head side Frothy like liquid is coming from mouth what should doctor advised?
A- Upper esophagaeal sphinter removal
B- Partial vagotomy
C- Complete vagotomy
D- Decrease fatty diet
E- Lower esophageal sphinter removal
Ans: D

215- Which part of intestine thick loop with less mesentery fat and long Vasa recta with her arcades surgeon asked by uplifting of gut during surgery?
A- Duodenum
B- Jejunum
C- Ileum
D- Colon
E- Rectum
Ans: B

Explanation:

Jejunum	Ilium
Deeper red	Paler pink
Thick and heavy	Thin and light
Greater vascularity	Lesser vascularity
Few Long Vasa recta	Many small Vasa recta
Less fat in mesentery	More fat in mesentery
Few Lymph nodules	Many Lymphoid nodules (Payer patches)
Plicae Circulares (Valvulae Conniventes) Large & Tall	Plicae Circulares (Valvulae Conniventes) Low & Sparse

216- Wilson disease characterized by
A- Excess iron
B- Excess Potassium
C- Excess Copper
D- Low Copper
Ans: C

217- Which one cause severe steatorrhea?
A- Gall Bladder Resection
B- Pancreatic Resection
C- Jejunum Resection
D- Zollinger Ellison Syndrome
E- Colon Resection
Ans: B

218- Mallory bodies seen in
A- Hepatitis
B- RCC
C- Hemangioma
D- Alcoholic hepatitis
Ans: D

219- A woman after RTA was brought to the emergency where she was intubated and was transfused blood. After a few days her Hb got down from 12 to 8. On endoscopy gastritis and gastric ulcers were found What's the reason behind gastritis.
A- Bicarb and Chloride shift.
B- Pepsin
C- Increased blood flow to mucosa.
D- Histamine
Ans: A

220- In Patient of anorexia nervousa What is seen?
A- Decrease cortisol
B- Increase androgen
C- Hyperkalemia
D- Impaired glucose tolerance test
Ans: D

Explanation:
In anorexia nervosa
- Incrase Cortisol
- Decrease Androgen
- Hypokalemia

221- A 45 year old man with a long history of alcoholism presents with severe epigastric pain radiating to back nausea vomiting fever and increase in serum amylase diagnose is:
A- Pancreatic CA
B- Gall Bladder CA
C- Biliary Stone
D- Acute Pancreatitis
Ans: D

222- A boy is excreting meconium from rectum and has severe constipation. The rectal examination showed no ganglion cells. The condition is called:
Intussusceptions
A- Hirschsprung's disease
B- Anorectal stenosis
C- Imperforate anus
D- Rectal atresia
E-
Ans: B

223- PT is use for following
Beri beri
A- Jaundice
B- VWD
C- Haemophilia
D- ITP
E-
Ans: B (Liver Disease)

224- Hep. B infectivity rate indicated by:
HBeAg Positive, HBeAb Negative
A- HBsAg Positive, HBsAb Positive
B- HBcAg Positive, HBsAg Negative
C- HBcAg Positive, HBcAb Negative
D-
Ans: A

225- One year old child presented with diarrhea after 1 year History of some milk intake is given by mother Doctor asked her to stop giving milk to baby Cause is
A- Sprue disease
B- Lactose intolerance
C- Hirshsprung disease
D- Celiac disease
E- Whipple disease
Ans: B

226- A female had colostomy and she is on parenteral nutrition, what problem can arise due to parenteral nutrition?
A- Hyperkalemia
B- Hypocalcaemia
C- Hypercalcemia
D- Fatty liver
E- Hyperglycemia
Ans: E

227- Bacteria which is carcinogenic is
A- Salmonella
B- Bacillus
C- H Pylori
D- Nisseria
Ans: C

228- Achalasia due to defect in:
A- Sympatheic nervous system
B- Parasympathetic nervous system
C- Myenteric plexuses
D- Mesisser plexuses
E- Mucosa
Ans: C

229- Pregnant lady has increase amniotic fluid with normal size baby , cause is ?
A- Bilateral renal agenesis
B- Posterior urethral valves
C- Duodenal atresia
D- Club foot
E- Pulmonary hypoplasia
Ans: C

Explanation
- **Polyhydromnios** – Deudenal atresia, anencephaly; both result in inability to swallow amniotic fluid), diabetes in pregnant patient, fetal anemia, multiple gestations.
- **Oligohydromnios** - Associated with placental insufficiency, bilateral renal agenesis, posterior urethral valves (in males); these result in inability to excrete urine.

230- In case of obstructive jaundice bleeding tendency due to
A- Liver unable to synthesize prothrombin
B- Decreased absorption of vit k in gut
C- Decreased absorption of vit c in gut
D- Decreased bile salts
Ans: A

231- A patient is on peritoneal dialysis. His plasma K is 6.5 what will you advice him to avoid
A- Cereales
B- Yougart
C- Apple
D- Tomatos
E- Carrots
Ans: E>D

232- Old lady with dysphagia she ignored but after 3 month came back with weight loss and dysphagia to puddings milks now on exam there is a mass in deep middle neck on palpitation malignancy of which organ involved?
A- Esophagus
B- Larynx
C- Trachea
D- Tonsil
Ans: B

233- Patient known case of smoking develop adenocarcinoma of lower third of esophagous what is premalignant history of lower third of esophagous
A- Goblet hyperplasia
B- Columnar hyperplasia
C- Squmous metaplasia
D- Goblet anaplasia
Ans: B

CamScanner

234- An old women presented with jaundice and biliary colic, diagnosis of cholelithiasis was made Synthesis of which of the following enzyme is likely to be increased?
A- AST
B- ALP
C- ALT
D- Nucleases
Ans: B

235- Diagnosed case of Appendicitis, Patient complaining of pain in medial rotation and flexion of hip, Most probably position of appendix is:
A- Pelvic
B- Retrocecal
C- Preileal
D- Postilleal
Ans: A

236- After ileal resection steatorrhea occur due
A- Decrease Absorption of Triglycerides
B- Lactose Intolerance
C- Decrease absorption of Micelles
D- Lactase Intolerance
Ans: C

237- Common feature of anorexia nervosa, type 1 DM , hyperthyroi & Celiac Disease is
A- Weight loss
B- Diarrhea
C- Malabsorption of nutrients
D- Hypertension
Ans: A

238- Which of the following is associated with Decrease turnover of bile acids?
A- Ileal resection
B- Ileal and colon resection
C- Increase cholymestyramine
D- Jejunal resection
Ans: A

239- Patient with esophageal bleed. Bp low and pulse above 150. What will be the initial management?
A- Platelets
B- Blood transfusion
C- Crystalloid
D- Colloid
Ans: C

A 20 year old boy presented with yellowing of sclera with no nausea and vomiting, Alt was normal with increased bilirubin which was unconjugated. He just had eye discoloration which sometimes disappears too. He probably has?
A- Gilbert syndrome
B- Rotor syndrome
C- Cirhosis
D- Dubin johnson
Ans: A

240- A young lady has gallstone which has caused blockage of bile duct. this will lead to
A- Increase fat contents of stool
B- Increase enterhepatic circulation of bile – salts
C- Increase absorption of fat soluble vitamins
D- Increase absorption of fat in small intestine
Ans: A

241- A 38 week pregnant woman visited her family and a remote area after which she develop jaundice suddenly. Which type of hepatitis is most likely prevalent in the pregnant women?
A- Hep. A
B- Hep. B
C- Hep. C
D- Hep. D
E- Hep. E
Ans: E

Explanation:
- Orofecal route – Hep. A >Hep. E
- Most lethal hepatitis – Hep. D
- Most common in pregnancy – Hep. A
- Most lethal/remote Area in pregnancy – Hep. E

242- Patient whose small gut is resected due to crohns disease present with hyperoxaluria. The cause of this condition is
A- Decrease blood calcium to form calcium oxalate
B- Increase calcium absorption from gut
C- Increase oxalate absorption from gut
D- Increase blood calcium to form calcium oxalate
Ans: C

243- A patient presented with fever vomiting abdominal pain. On Examination there is guarding of abdomen likely diagnose is
A- Listeria
B- Leptospirosis
C- Enteric fever with perforation
D- Malaria
Ans: C

244- Carcinoid syndrome is diagnosed by
A- VMA in urine
B- Metnephrine in urine
C- 5 HIAA(hrdoxy indole acetic acid)
D- Proteins in urine
E- Fats in urine
Ans: C

245- A person is having history of smoking On Endoscopy there is valvety lesion in lower third of esophagus. It is risk factor for
A- Adenocarcinoma
B- Squamous cell Carcinoma
C- Baretts esophagus
D- Chronic esophagitis
E- Gastritis
Ans: A

Explanation:
Upper 2/3rd (Squamous cell carcinoma)
- Alcohol
- Hot Liquids
- Stricture
- Smoking
- Achlasia

Lower 1/3rd (Adenocarcinoma)
- Chronic GERD
- Barret Esophagous
- Obesity
- Smoking
- Achlasia

246- A patient present with esophageal varices having bleeding which vessel is involved?
A- Left gastric Vein
B- Right gastric artery
C- Splenic artery
D- Hepatic artery
E- Celiac artery
Ans: A

248- Patient has anti HBc IgG positive, anti HBs negative, anti HBe negative, Hbc and Hbeag negative this is:
A- Acute resolving
B- Chronic resolving
C- Past exposure
D- Vaccinated against Hep B
E- Incubation period
Ans: C

248- A 44 year old woman is diagnosed with Zollinger Ellison Syndrome which of the following is Consistent with the diagnosis?
A- Decreased serum gastrin levels.
B- Increased serum insulin levels.
C- Increased absorption of dietary lipids.
D- Decreased partial cell mass.
E- Peptic ulcer disease
Ans: E

249- Chagas disease and congenital megacolon affects which layer of GIT:
A- Serosa
B- Mucosa
C- Submucosa
D- Muscularis externa
E- Muscularis mucosa
Ans: D

250- A 28 years old male was prescribed nicotinic acid for his hypercholesterolemia e noticed yellow discoloration of sclera after few days lab investigatiobs shows hb 11g/dl serum bilirubin total 3mg/dl direct bilirubin 0.8mg/dl alt 35iu/l the most likely cause of his jaundice is
A- Drug induced hepatitis
B- Dubin jonson syndrome
C- Gilbert syndrome
D- Hemolysis
E- Viral hepatitis
Ans: A

251- An young man has liver enlargement and splenomegaly his ALT is 256IU and AST is 300IU his immunological test normal and has ring in eye, what is most useful investigation?
A- Ceruloplasmin
B- Liver biopsy with stain
C- USG
D- X-ray Eye
Ans: A

252- Test necessary for Anti HCV positive patient before starting treatment:
A- USG abdomen
B- RFT
C- LFT
D- PCR HCV RNA
Ans: D

253- A person is having history of smoking and drinking from many years on endoscopy there is a mass in middle third of esophagus. What could it likely be?
A- Adenocarcinoma
B- Squamous cell Carcinoma
C- Baretts esophagus
D- Chronic esophagitis
E- Gastritis
Ans: B

CamScanner

254- A child developed diarrohea, biopsy shows villous atrophy but gluten free diet does not improve his symptoms diagnose is:
A- Whipple disease
B- Celiac disease
C- Shigellosis
D- Giardiasis
E- Tropical sprue
Ans: D

255- Adenocarcinoma of colon first metastasize to:
A- Liver
B- Mesocolic lymph
C- Lung
D- Bone
E- Breast
Ans: B

256- In portal HTN following vein is likely to be dilated:
A- Esophageal
B- Right gastric
C- Azygous vein
D- Inferior epigastric
E- Inferior phrenic
Ans: A

257- Female with right upper quadrant pain, mild jaundiced and yellow sclera, cause of icterus Diagnosis of Primary Biliary Cirrhosis made is confirmed by?
A- AMA
B- Elisa
C- X-ray
D- Ct-scan
E- ANA
Ans: A

258- Arshad had Eaten cholay from a street vendor, now develops nausea, vomiting and jaundice, what is Likely cause?
A- Hepatitis A
B- Hepatitis B
C- Hepatitis C
D- Hepatitis D
E- Hepatitis G
Ans: A

259- An eight month, old infants present with alternating episodes of obstruction and passage of diarrheal stools. Radiological finding show dilated bowel segments. Colonic biopsy finding reveal absence of ganglion cell in the distended bowel segment. It is a case of:
A- Ischemic bowel disease
B- Hirschsprung disease
C- Meckel diverticulum
D- Omphalocele
E- Intestinal malrotation
Ans: B

260- A young boy came in Er with profuse bleeding from minor trauma he has this complain for last 6 month there is no family history he has also chronic diarrhea bleeding time 6mins clotting time 30min most likely cause is:
A- Christmas disease
B- Classical disease
C- Liver failure
D- Kidney failure
E- Vitamin k deficiency
Ans: E

261- An alcoholic hypothyroid patient Presented with epigastric pain, nausea vomiting and numbness. O/E Patient is anaemic Biopsy of stomach shows atrophic gastritis what shall be the treatment plan?
A- Inj Vitamin B12
B- Oral folic acid
C- Iron intake
D- Alcoholic abstinence
E- Increase thyroxine dose
Ans: D

262- Truncal vagotomy causes:
A- Decrease gastric motility
B- Decrease acid seccretion
C- Decrease pepsin secrection
D- None of above
Ans: B

263- Most common organism for pyogenic liver abscess:
A- E. coli
B- Pseudomonas
C- Streptococus
D- Staph aureus
Ans: A

264- A male has been diagnosed with colon cancer through CEA doctor does CEA for what?
A- For Site of malignancy
B- Size of malignancy
C- To see metastasis
D- For Follow up of malignancy
E- To see treatment effects
Ans: D

265- Iron deficiency anemia, glossitis, and cheilosis are the features of:
A- Mallory -Weiss syndrome
B- Hirschsprung disease
C- Plummer Vinson syndrome
D- Menetrier Disease
E- Zollinger -Ellison Syndrome
Ans: C

266- In jaundice clotting time is prolonged due to:
A- Increase thrombin
B- Decrease prothrombin
C- Increase prothrombin
D- Decrease Factor 8
Ans: B

267- Which one is premalignant?
A- Hamartomatous polyp
B- Hyperplastic polyp
C- Chronic nonspecific gastritis
D- Atrophic gastritis
Ans: D

268- The Most Common cause of esophageal varices is?
A- Hepatic schistomiaisis
B- Portal hypertension
C- Hepatitis
D- Hepatic failure
Ans: B

269- Patient presented with sign and symptoms of appendicitis emergency appendectomy was performed which fluid will be present after appendectomy?
A- Exudative
B- Transcellular
C- Serous
D- Infected
E- Fibrinous
Ans: A

270- Benign tumor common in git is of which of following:
A- Smooth muscle
B- Adipose
C- Epithelium
D- Skeletal muscle
Ans: B

271- Young boy eo. O food from restaurant and after few days develop jaundice and loss of appetite cause is:
A- Hepatitis C
B- Hepatitis A
C- Hepatitis B
D- Hepatitis G
E- Liver failure
Ans: B

272- A patients undergoes renal transplant, he is on immunosuppressive therapy and develops angular chelitis and GIT problems causative agent is:
A- EBV
B- Dudenal ulcer
C- Gastric ulcer
D- Candida Esophagitis
E- Aspergillus
Ans: D

273- In prehepatic jaundice there is:
A- Increase conjugated Bilirubin
B- Increase indirect bilirubin
C- Absent hapcidin
D- Over production of hepcidin
Ans: B

274- Vaccination schedule for Hepatitis:
A- 0, 1, 6 month
B- 12 month
C- 6,12 month
D- 0, 1, 8 month
Ans: A

275- A 19 years old female with increased TAGs, which one of the following serious condition can occur?
A- Pancreatitis
B- Appendicitis
C- Cystitis
D- Cholecystitis
Ans: A

276- A 55-year-old male alcoholic presents with symptoms of liver disease and is found to have mildly elevated liver enzymes. A liver biopsy examined with a routine hematoxylin and eosin (H&E) stain reveals abnormal clear spaces in the cytoplasm of most of the hepatocytes. Which of the following is most likely cause of this:
A- Hemosiderin
B- Lipochrome
C- Lipofuscin
D- Steatosis
Ans: D (Robins)

Explanation:
Fat accumulation in hepatocytes (steatosis) appears as round well circumscribed clear spaces with in cytoplasm. Though it's difficult to see on H &E stain but can be seen. More accurately oil red o stain used for this purpose

277- A pregnant lady which develops some skin changes just like her uncle who is HCV + and cirrhosis which are those changes:
A- Spider telangectasia and palmer erythema
B- Spider telengectasia and hyperpigmentation
C- Striae and Cholastama
D- Spider neviae
Ans: A

278- AST is raised in?
A- MI
B- Muscular dystrophy
C- Bone disease
D- Prostatic carcinoma
E- Pancreatitis
Ans: E

CamScanner

279- A patient has sudden onset of pain in abdomen hypochondrium region on u/s fluid filled in pancreas which enzyme will be specific?
A- Lipase
B- Liguase
C- Sucrase
D- Salivase
Ans: A

280- A patient of 56 years is chronic carrier of Hep B from 10 years, he has now developed fever and jaundice, delta antigen is +ve. What does this indicate?
A- Immune from disease
B- Superinfection with severity of disease
C- Chronicity
D- Resolution
Ans: B

281- HB surface and core antigen +ve. Core antibody IGM is +ve what is that?
A- Acute infection
B- Chronic infection
C- Immunization
D- Recovery
Ans: A

282- Hep B +ve patient has raised AFP, He might be having?
A- Hepatitis
B- HCC
C- Lymphoma
D- Thymoma
Ans: B

283- Students went on trip during trip students were advised not to eat unhygienic food but one student ate cholay from one of the shop and started abdominal pain at night which nerve is involved:
A- Splanchnic sympathetic
B- Splanchnic parasympathetic
C- Sympathetic somatic
D- Somatic both
Ans: A

284- Microscopic feature of chronic disease of liver in hepatitis C case
A- Lymphocytes infiltration
B- Fatty Accumulation
C- Portal & periportal fibrosis
D- Dense lymphocytic infiltrates
Ans: C

285- In pregnancy increasead level of Billirubin 40mg,all other was normal
A- Primary biliary cirhosis
B- Cholestatic liver
C- Primary cholangitis
D- None
Ans: B

286- Gastrectomy performed 1.2 years back now presented with tingling sensation. On investigation, MCV 112. What is the probable diagnosis?
A- Anemia of chronic disease
B- Iron deficiency anemia
C- Pernicious anemia
D- Folic acid deficiency anemia
Ans: C (Prefer B 12 Deficiency anemia if present in option)

287- 62 years old patient of cirrhosis presented with edema & swelling in legs, the mechanism of edema in case of cirrhosis is which of following?
A- Increased plasma colloid osmotic pressure
B- Decreased plasma colloid osmotic pressure
C- Decreased hydrostatic pressure
D- Increased hydrostatic pressure
Ans: B

288- A patient with pyloric stenosis has chronic vomiting the most likely biochemical abnormality in this would be
A- High serum bicarbonate
B- Hypokalemia
C- Hyponatremia
D- Hypovolemia
E- Decreased PH
Ans: B

289- Patient developed anemia after gastrectomy what should be given to him
A- Transcobalamin I
B- Vitamin B6
C- Folic acid
D- Intrinsic factor
Ans: D

290- Chronic Liver Disease will have:
A- Prolong Prothrombin Time
B- Decrease albumin
C- Increase albumin
D- Short Prothrombin time
Ans: B

291- Which of the following is the commonest site for ectopic salivary gland?
A- Palate
B- Buccal mucosa
C- Lips
D- Tongue
E- Pharynx
Ans: A

292- A patient presented with Swelling at the floor of Mouth. On bimanual palpation of mouth, Sialolith in duct of salivary gland. Which salivary gland is most probably involved?
A- Sublingual gland
B- Submandibular gland
C- Parotid gland
D- Minor salivary glands at the base of tongue
Ans: B

293- Which of the following virus is most commonly associated with chronic liver failure?
A- Hepatitis A
B- Hepatitis B
C- Hepatitis E
D- Hepatitis C
Ans: D

294- An alcoholic presented with Dysphagia to solids as well as liquids. What it could be?
A- Squamous cell carcinoma
B- Basal cell carcinoma
C- Melanoma
D- Adenocarcinoma
Ans: A

295- In a patient with liver Disease which factor used to monitor see he is developing acute liver failure?
A- Serum albumin
B- Serum AFP
C- Serum bilirubin
D- Factor V estimation
E- PT
Ans: E > D (Davidson + Harrison)
Explanation:
- For Monitoring Hep B –SGPT
- For Liver Failure -PT

296- Carcinomas are usualy very lethal & incurable. Which one of the following is curable Carcinoma?
A- Gastric adenocarcinoma
B- Colon Carcinoma
C- Melanoma
D- Lung carcinoma
E- Hepatocellular carcinoma
Ans: A

297- 55years old male with past history of epigastric pain for which he was taking antacids was diagnosed as gastric lymphoma what is the most likely cause?
A- Drug induced gastritis
B- Ulcers
C- Intestinal metaplasia
D- Atopic gastritis
E- H. Pylori
Ans: E

298- A patient presented with crohn disease. for her treatment of remission corticosteroids are given what is best for maintenance of remission of her disease:
A- Methotrexate
B- Mesalamine
C- Azathioprine
D- Bedosinide
E- Ciprofloxacin
Ans: C
Explanation:
- Crohn's disease
- Induce remission
- Steroid first line
- Aminosalisylates second line
- Maintenance of remission
- Azathioprine or Mercaptopurine
- Alternative is Methotrexate
- Ulcerative colitis
- Induce remission
- Aminosalisylates First line
- Steroid Second line
- Maintenance of remission
- Azathioprine or Mercaptopurine
- Alternative is Methotrexate

299- An old patient with a history of constipation and abdominal pain. While investigating, a mass is found in the colon which was diagnosed as adenocarcinoma. Which of the following is the risk factor for colonic adenocarcinoma?
A- Smoking
B- Alcohol
C- Sedentary lifestyle
D- Entamoeba
E- Fatty diet
Ans: E

300- A patient having Total anti Hbc reactive, IgM –ve, Hbs ag-ve & Anti HBS Positive. What is the probable diagnosis?
A- Past exposure
B- Immunity from disease
C- Active Liver disease
D- Chronic Liver disease
E- Latent infection
Ans: A (First Aid)

CamScanner

301- A girl presented with persistent cough with thick mucus, wheezing and Repeated lung infections. She is also having petechia all over body and have bleeding tendency. She is diagnosed with cystic fibrosis. Which Vit is deficient in this case?

A- Vitamin A
B- Vitamin k
C- Vitamin D
D- Vitamin C
Ans: B

302- Liver regenerates after partial hepatectomy in how many days:

A- 5-7 Days
B- 6-15 Days
C- 14-21 Days
D- 4-6 Weeks
Ans: A

303- Boy ate street food after which he developed Nausea, Vomiting, Scleral icterus & Jaundice. Which of the following is responsible for this presentation?

A- Hepatitis B
B- Hepatitis A
C- Hepatitis E
D- Hepatitis D
Ans: B

304- A patient with history of chronic foul smelling diarrhea with no history of abdominal pain, no occult bleeding. On stool DR, fatty stools. Biopsy shows villous atrophy, lymphocytes and crypt hyperplasia.What will you advise to the patient?

A- Corticosteroids
B- Antibiotics
C- Gluten free diet
D- Surgery
Ans: C

305- A person presents with abdominal pain for 2 months. On investigations there is a mass in duodenum that is found to be arising from submucosa Which of the following is secreted by this part of duodenum from where mass is arising.

A- Lactase
B- Peptidase
C- Acidic Mucus
D- Urogastrone
E- Gastrin
Ans: D

Explanation:
Brunner gland located in submucosa of duodenum secrete alkaline mucus and urogastrone.

306- An old man with liver mass, HbsAg positive & raised AFP 1000, He might be having?

A- Hepatitis
B- Hepatocellular carcinoma
C- Lymphoma
D- Thymoma
Ans: B

better

307- In alcohlic Patient Steatohepatitis develops due to:

A- Acetate
B- Cholesterol
C- Fatty acids
D- Phospholipid
Ans: C

308- Which of the following vitamin is deficient in chronic pancreatitis?

A- B12
B- B7
C- Vitamin D
D- Vitamin C
E- Thiamine
Ans: C

309- Child having meckel diverticulum is having bleeding per rectum due to:

A- Volvulus
B- Chronic inflammation
C- Ectopic gastric tissue
D- Jejunum
E- Cecum
Ans: C

Explanation:
Rule of 2
- Seen commonly in under 2 year
- 2% Population
- 2Feet proximal to illiocecal valve
- 2 inches long
- 2 types of mucosa (**Ectopic gastric mucosa** which usually bleed and **Pancreatic mucosa**(May cause bleed). These two mucosa are important histological feature of Meckel diverticulum

310- In an adult ileostomy and jejunectomy has been done. He has diarrhea and 15-20 bowel sounds per minute. The most likely cause of this decreased transit time is:

A- Secretory diarrhea
B- Osmotic diarrhea
C- Secretory+Osmotic diarrhea
D- High concentration of Bile Salts in the colon
Ans: C

Explanation:
- **Colostomy** Results in **Secretory** Diarrhea
- **Jejunostomy** Result in **Osmotic** Diarrhea
- **illeostomy** Result in **Osmotic** Diarrhea
- **Jejunostomy+illeostomy** Result in **Secretory+Osmotic** Diarrhea

311- A patient with acute diarrhea has serum Cl = 112, sodium 131, Potassium 2.5, anion gap 10, what is the most likely type of metabolic acidosis?

A- Hypochloremic metabolic acidosis with a normal anion gap
B- Hypochloremic metabolic acidosis with an increased anion gap
C- Hyperchloremic metabolic acidosis with a normal anion gap
D- Hyperchloremic metabolic acidosis with an increased anion gap
Ans: C

312- A patient with abdominal pain has been taking 10 tablets of paracetamol (500 mg each), along with aspirin and other NSAIDs. Considering the potential effects of these medications, which investigation should be ordered first?

A- Liver Function Tests
B- Urea, Creatinine, & Electrolytes
C- CT Scan of the Abdomen
D- Ultrasound of the Abdomen
Ans: A

313- Patient came with a brain lesion and there is formation of ring seen in peripheral cornea on investigation what will be seen

A- Increase Serum Ceruloplasmin in blood
B- Increase serum ceruloplasmin in urine
C- Decrease copper in blood
D- Decrease Serum Ceruloplasmin in blood
Ans: D

314- In a patient with cirrhosis who presents with acquired bleeding abnormalities, which of the following laboratory findings is most consistent with the condition?

A- Prolonged bleeding time
B- Prolonged prothrombin time
C- Prolonged activated partial thromboplastin time
D- Decreased albumin
E- Normal clotting time
Ans: B

315- 30 years old female patient presented with Nausea, vomiting and gastric upset for 5 days. Biopsy of stomach shows lymphocytes neutrophils, macrophages, plasma cells but no ulceration. What is the most probable diagnosis?

A- H pylori
B- Staph aureus septicemia
C- Tb
D- Gastric Ca
E- Gastritis
Ans: A

316- Liver cirrhosis patient with coagulopathy, transfusion before surgery by which fluid?

A. Lymphocyte removed full blood
B. FFP
C. Cryoprecipitate
D. Albumin
Ans: B

317- A patient presents with pain in the right hypochondrium that worsens over time after eating. The pain is aggravated by palpation in the right hypochondrium, and the patient tends to hold their breath during palpation. What is the most likely diagnosis?

A- Acute pancreatitis
B- Acute cholecystitis
C- Cholelithiasis
D- Appendicitis
Ans: B

318- Location of Chylomicrons in liver:

A- Cholangiole
B- Space of disse
C- Sinusoids
D- Herring canal
Ans: B

319- Which of the following plays a mitogenic role in regeneration in early stages after partial hepatectomy:

A- EDGF
B- Hepatocyte growth factor
C- PDGF
D- methionine related drugs
E- TGF-alpha
Ans: B

320- 19 years old child presented with scleral icterus & pale stools. Investigations reveal Decreased Haptoglobin, Total Bilirubin 3.5 Indirect Bilirubin 2.8. Diagnosis?

A- Rotor Syndrome
B- Hereditary Spherocytosis
C- Gilbert Syndrome
D- Dubin Johnson Syndrome
E- Crigler Najjar Syndrome
Ans: B

CamScanner

321- Councilman bodies occur in process of:
A- Hypertrophy
B- Apoptosis
C- Atrophy
D- Yellow fever
Ans: B

Explanation:
- Occur in process of Apoptosis
- Seen in disease – Yellow Fever

322- TRUE regarding Gastric emptying:
A- Increases with Increased secretin
B- Increases with Increased CCK
C- Increases with Exaggerated muscle activity
D- Increases with Vagotomy
E- Decreases by decreased vagal stimulation
Ans: E

323- Ileal resection of patient done. what will happen post surgery
A- Constipation
B- Steatorrhea
C- Weight loss
D- Diarrhea
Ans: B

324- A patient presents with symptoms of flushing, diarrhea & wheezing along with raised JVP.What is the most likely diagnosis?
A- Carcinoid tumor
B- Mesenteric Ischemia
C- Inflammatory bowel disease
D- Peptic ulcer disease
E- Crohn's disease
Ans: A

325- A breast fed child with raised unconjugated bilirubin levels on 2nd day, reason when mother is B positive.
A- Physiological jaundice
B- Rh incompatibility
C- Breast milk jaundice
D- Gilbert Atresia
E- Neonatal hemorrhagic disease
Ans: A

Explanation:
- Pathological jaundice – first 24 hours of life
- Physiological jaundice – 2nd day onwards
- Breast milk jaundice- between 1 and 12 weeks in normal breast milk fed infants
- Breast feeding jaundice – first 3to 15 days of life

326- A patient receiving multiple transfusions with raised ferritin levels, receiving chelating therapy but not compliant, what could likely be the cause of his mortality?
A- Liver disease and cirrhosis
B- dysthymia
C- Hemosiderosis
D- Adrenals
Ans: A

327- pylori infection has a definite etiologic role in pathogenesis of:
A- Chronic gastritis
B- Gastric MALT lymphoma
C- Gastric adenocarcinoma
D- Duodenal adenocarcinoma
E- Peptic ulcer disease
Ans: B

328- A 45 year old patient presents with diarrhea,and vomiting on DRE rectum was smooth and warm on sigmoidoscpy no mass was present, but rectal mucosa was inflammed which of the following is appropriate treatment
A- 5 aminosalicyclic acid
B- Topical Steriods
C- IV Antibiotics
D- Only follow up
E- Enema with salazine
Ans: A

329- diabetic patient with abdominal pain, severe vomiting and visible peristalsis and audible sound on examination, diagnosed as a case of pyloric stenosis which of following change u will seen on lab findings
A- Metabolic acidosis
B- Hyperchloremia
C- Hypochloremia
D- Hyperkalemia
Ans: C

Explanation:
Pyloric stenosis
- Most ommonly effects the boys aged 2-8weeks
- Projectile vomiting after feeds
- Test feed or ultrasound to confirm the diagnosis
- Gastric peristalsis can be seen and an olive felt
- HypokalemiC- hypochloremic metabolic alkalosis is seen

330- Which of the following is precursor lesion of adenocarcinoma of the stomach
A- Atrophic gastritis
B- Hypertrophy
C- Hemartomatous polyp
D- Hyperplastic polyp
Ans: A

331- An alcoholic patient with stricture in esophagus diagnose by
A- Endoscopy
B- Ultrasound
C- X-ray
D- CT chest and abdomen
E- MRI
Ans: A

332- 14 year old patient present in OPD with yellow discolouration of skin and sclera which of the following investigation u will order
A- Bilirubin
B- Bilirubin +ALT
C- Serology
D- Biopsy
Ans: B

333- Which of the following labs you will find in severe pancreatitis
A- Amylase 800, Albumin 3.2 ,WBCs 18k
B- Amylase 500, wbcs 18k ,PCO2 65%
C- AST>250, wbcs 18k,albumin 3.1, Amylase 800
D- Amylase 800,LDH 370, albumin 3.1
Ans: C

Explanatiom: (RANSON'S CRITERIA)

Non gallstone pancreatitis	Gall stone pancreatitis
On admission	**On admission**
Age >55years	Age>75 years
Blood glucose >200mg/dl	Blood glucose >220mg/dl
White cell count >16k	White cell count >18k
LDH>350	LDH>400
AST >250	AST>250
After 48 hours	**After 48 hours**
Hematocrit fall by >10%	Hematocrit fall by >10%
Serum calcium<8mg/dl	Serum calcium<8mg/dl
Base deficit>4meq/L	Base deficit>5meq/L
BUN:increase by >5mg/dl	BUN:increase by >2mg/dl
Fluid requirments>687L	Fluid requirments>4L
PCO2<60mmhg	PCO2:not available

334- An elderly patient presents in OPD with thick white layer in the mouth what is likely diagnosis
A- Oral thrush
B- Leukoplakia
C- Lichen planus
D- Oral carcinoma
E- Oral hairy leukoplakia
Ans: A

335- A 50 year old female presents in OPD with complain of episodic flushing,diarrhea and abdominal cramping she also reports experiencing wheezing and SOB cardiac auscultation reveals a holosystolic murmur best heared at lower left sternal border which increases with inspiration her blood pressure is normal and pulse is slightly elevated which of the following is ur diagnosis
A- Colorectal cancer
B- Carcinoid syndrome
C- Crohn's disease
D- Ischemic colitis
E- Pheochromocytoma
Ans: B

336- A patient presents with multiple bowel and vascular injuries vascular injuries have been repaired but the patient is now found to have metabolic acidosis and hypothermia what is your best step in management
A- Resect the bowel ,form a stoma and transfer the patient to icu
B- Form a stoma ,leave the abdomen open and transfer to icu
C- Resect the bowel and close the abdomen
D- Stop surgery and resuscitate
Ans B

337- A patient with history of chronic foul smelling diarrhea with no history of abdominal pain, no occult bleeding. On stool DR, fatty stools. Biopsy shows villous atrophy, lymphocytes and crypt hyperplasia.What will you advise to the patient?
A- Corticosteroids
B- Antibiotics
C- Gluten free diet
D- Surgery
Ans: C

CamScanner

338- **72 year old male present with sudden onset left lower abdominal pain ,fever and bright red rectal bleeding on examination he has tenderness in left iliac fossa and he is febrile. A CT scan of the abdomen reveals thickened sigmoid colon what is likely diagnosis of the patient**

A- Colorectal cancer
B- Acute sigmoid diverticulitis
C- Ischmic colitis
D- Irritable bowel syndrome
E- crohn's disease
Ans: B

339- **A 35 year old patient presents with complain of a sore ,inflamed tongue(glossitis. ,persistent abdominal distention,and noticeable pigmentation on skin over past few months the patient also reports occasional diarrhea, fatigue, and weight loss which of the following condition is most likely describes the patient condition**

A- Ulcerative colitis
B- Whipple disease
C- Crohn's disease
D- Celiac disease
Ans: D

340- **A 45 year old male present with heart burn and epigastric pain occurring 2 hour post prandial especially at night what is most likely diagnosis**

A- Gastric ulcer
B- Duodenal ulcer
C- Esophagitis
D- Esophageal spasm
Ans: B

341- **A patient has been in a coma for a prolonged period and was receiving total parenteral nutrition (TPN). The patient now has gastric atrophy. What is the most likely reason for this condition?**

A- Increased secretin
B- Increased gastrin
C- Low gastrin
D- Low cholecystokinin (CCK)
E- Low cholecystokinin (CCK)
Ans: C

Explanation:

- **Total parenteral nutrition (TPN)** bypasses the gastrointestinal (GI) tract, which means the stomach is not stimulated by food intake.
- Gastrin secretion is **primarily stimulated by food in the stomach** and gastric distension.
- In a patient receiving TPN and who has been in a prolonged coma, there is a lack of oral intake, resulting in **decreased gastrin secretion**.
- Gastrin is essential for stimulating **gastric mucosal growth** and acid secretion. Prolonged **low gastrin levels** can lead to **gastric atrophy** because of the lack of trophic stimulation of the gastric mucosa.

342- **What is the most common organism isolated in ascitic fluid obtained via paracentesis (ascitic tap)?**

A- E. coli
B- Proteus
C- Klebsiella
D- Bacteroids
Ans: A

343- **Most important factor causing liver carcinoma?**

A- Alcohol
B- Smoking
C- Hep. A
D- Drug use
Ans: A

344- **In a patient with a gastric ulcer due to reflux, which area is most likely affected?**

A- Esophagus
B- Pylorus
C- Fundus of the stomach
D- Cardia of the stomach
Ans: D

345- **A female trying to lose weight by consuming bran bread complains of diarrhea, gas, abdominal cramps, and fatigue during her morning walk. What is the most likely diagnosis? (Medicine Feb 2025)**

A- Lactose intolerance
B- Wheat intolerance
C- Anemia due to malabsorption of iron
D- Anemia due to malabsorption of B12
Ans: B

Explanation:

- The symptoms suggest **wheat intolerance** (likely celiac disease), where gluten triggers an immune response leading to malabsorption. This can result in gastrointestinal symptoms like diarrhea, gas, and cramps, as well as fatigue from nutrient deficiencies like iron and B12.

346- **A 40-year [illegible] ulcerative colitis is now presenting [illegible] exacerbation of gastrointestinal symptoms. Which of the following can be used to assess the severity of the exacerbation? (Medicine Feb 2025)**

A- Erythema nodosum
B- Anemia
C- Dose of Salazopyrin
D- Ankylosing spondylitis
E- Dysplasia on colonoscopy
Ans: D

347- **Patient is having cholestatic jaundice. Cause of increase CT is: (Medicine Feb 2025)**

A- Increase fats in the stool
B- Decrease PT
C- Increase Water content of Stool
D- Due to Bile stones
E- Decreased Vitamin C
Ans: A

348- **Non neoplastic cause of Ascites due to viseral organs: (Medicine Feb 2025)**

A- Cirrhosis
B- Alcohol
C- Budd Chiari Syndrome
D- Portal Vein Thrombosis
E- Fulminant Liver
Ans: A

349- **A 40-year-old female presents with right upper quadrant (RUQ) pain, right-sided pleural effusion, and high-grade fever. What is the most likely diagnosis? (Medicine Feb 2025)**

A- Acute cholecystitis
B- Liver abscess
C- Hydatid cyst
D- Pulmonary embolism
Ans: B

350- **Which of the following is the most convenient non-invasive test for the diagnosis of *Helicobacter pylori* infection?(Medicine Feb 2025)**

A- ELISA
B- Ammonia breath test
C- Urea breath test
D- Culture and sensitivity
E- Biopsy
Ans: C

351- **Which of the following is the primary source of fluid accumulation in ascites? (Medicine Feb 2025)**

A- Peritoneal lymphatics
B- Systemic vasculature
C- Hepatic vasculature
D- Portal vasculature
Ans: D

chelating therapy but not compliant. what could likely be the cause of his mortality? (Medicine Feb 2025)

A- Liver disease and cirrhosis
B- dysthymia
C- Hemosiderosis
D- Adrenals
Ans: A

353- **A new born was present with esophageal atresia which of the following is most characteristic symptom: (Surgery Feb 2025)**

A- Regurgitation of first feed
B- Drooling of saliva
C- Coughing on feeding
D- cyanosis during feeding
Ans: A

354- **40 years old obese lady presented with Jaundice. Investigations reveal high levels of Conjugated bilirubin along with High Urinary Bilirubin & normal urobilinogen. Most likely diagnosis? (Surgery Feb 2025)**

A- Obstruction of CBD
B- Liver Parenchymal Injury
C- Hepatitis b and c
D- Dubin johnson
E- UGT Deficiency
Ans: A

355- **A 50-year-old patient with a history of tubulovillous adenoma of the colon presents with iron-deficiency anemia and weight loss. What is the most likely diagnosis?(Surgery Feb 2025)**

A- Diverticulitis
B- Colonic adenocarcinoma
C- Inflammatory bowel disease
D- Colonic lymphoma
Ans: B

356- **A patient presented with Jaundice along with Pain RHC. Investigations reveal ALP level of 1100. Most likely Diagnosis? (Surgery Feb 2025)**

A- Viral Hepatitis
B- Obstruction of Common Bile Duct
C- Dubin Johnson Syndrome
D- Liver Parenchymal Injury
Ans: B

CamScanner

357- A 20 year old boy presented with yellowing of sclera with no nausea and vomiting, Alt was normal with increased bilirubin which was unconjugated. He just had eye discoloration which sometimes disappears too. He probably has? (Surgery Feb 2025)

A- Gilbert syndrome
B- Rotor syndrome
C- Cirhosis
D- Dubin johnson
Ans: A

358- An 45 year- old woman presents to the clinic with complaints of progressive dysphagia for both solids and liquids over the past few months. She reports difficulty in belching and occasional regurgitation of undigested food. On further questioning, she denies weight loss or chest pain. A chest X- ray reveals air- fluid levels in the mediastinum, and an esophagogram shows a "bird-beak" appearance of the lower esophageal sphincter. What is the most likely diagnosis? (Surgery Feb 2025)

A- Achalasia
B- Esophageal spasm
C- CREST syndrome
D- Gastritis
Ans: A(CMDT 2025)

Explanation:
ACHALASIA:

- Chest X- ray shows a dilated oesophagus, sometimes with a fluid level seen behind the heart. The fundal gas shadow is absent.
- Barium swallow shows lack of peristalsis and often synchronous contractions in the body of the oesophagus, sometimes with dilatation. The lower end shows a 'bird's beak' due to failure of the sphincter to relax

359- A patient presents with acidosis and hypokalemia. The fluid is most likely being drained from which part of the gastrointestinal tract?(Gynae Feb 2025)

A- Duodenum
B- Jejunum
C- Ileum
D- Colon

360- 40 year female presented with C/O diarrhea, Facial flushing, right sided heart murmur due to involvement of Tricuspid valve. Most probable diagnosis? (Gynae Feb 2025)

A- Colorectal CA
B- Kruckenberg tumor
C- Post menopausal syndrome
D- Carcinoid syndrome
Ans: D

361- A patient present with history of smoking and alcohol present with mid esophageal mass what is your diagnosis(Radiology Feb 2025)

A- Squamous cell carcinoma
B- Adenocarcinoma
C- Basal cell carcinoma
D- Barret esophagus
E- Esophagitis
Ans: A

362- Which of the following will occur if pancreatic secretion not reaching the intestine(Radiology Feb 2025)

A- Lactose intolerance
B- No chylomicron formation
C- Glycogen malabsorption
D- Steatorrhea
E- NO Triglyceride absorption
Ans: D

363- A new born was present with esophageal atresia which of the following is most characteristic symptom(Radiology Feb 2025)

A- Regurgitation of first feed
B- Drooling of saliva
C- Coughing spell on eating
D- cyanosi during feeding
Ans: A

364- Young Woman wants to loose weight & taking Ipecac for the said purpose. After that, she develops 15 episodes of vomiting, hypotension & SOB. Recent 2 Episodes show bright red blood. What is the most Probable diagnosis(Anesthesia Feb 1025)

A- Perforated peptic ulcer
B- Gastric ulcer
C- Mallory Weis tear
D- Boerhaave Syndrome
E- Gastritis

EXPLANATION:

- Mallory-Weiss Syndrome is characterized by partial-thickness, longitudinal lacerations at the gastroesophageal junction, confined to the mucosa and submucosa. It is caused by severe vomiting or retching and often presents with hematemesis, with or without abdominal or back pain.
- Boerhaave Syndrome involves a transmural rupture of the esophagus, typically in its distal portion, caused by violent retching or vomiting. It presents with severe chest pain, subcutaneous emphysema, and may lead to life-threatening mediastinitis if not treated promptly

365- A man experienced repeated episodes of vomiting followed by chest pain, tachycardia, and fluid accumulation in the supraclavicular region. What is the most likely cause? (Anesthesia Feb 2025)

A- Mallory Weis tear
B- Boerhaave Syndrome
C- Gastric Perforation
D- Duodenal Perforation
Ans: B

366- 26 year old girl 28 week of gestation developed vomiting, bilirubin 20mg/dl AST272 and ALT 220 two weeks back when she went to meet her parents in a remote village. What is her diagnosis? (Anesthesia Feb 2025)

A- Hep. A
B- Hep. B
C- Hep. C
D- Hep. D
E- Hep. E
Ans: E

367- An elderly patient presents with Fever, Malaise & lower abdominal pain. O/E, there is tenderness in the left iliac fossa, and a history of loose stools with blood. What is the most appropriate investigation to perform?(Radiology Feb 2025)

A- X ray
B- Colonoscopy
C- Sigmoidoscopy
D- CT Abdomen
E- Barium enema
Ans: C

368- A cirrhosis patient was having air level in the branching pattern inside the liver extending upto the peripheral capsule. Which part is involved? (Radiology Feb 2025)

A- Extra hepatic biliary tree
B- Intrahepatic billiary tree
C- Portal vein tributaries
D- Hepatic Veins
Ans: B

369- Severity of Pancreatitis is best assessed by: (Radiology Feb 2025)

A- Amylase 650, WBC 18,000, PaO_2 65 mmHg
B- Amylase, LDH, and Albumin levels
C- Amylase 800, WBC elevated, and LDH 6.5
D- Serum lipase alone is the best predictor of severity
Ans: A

370- A 40-year-old patient presents with a long history of postprandial right upper quadrant (RUQ) pain. He now has fever, raised TLC, gallbladder wall thickening, multiple gallstones, and pericholecystic fluid on ultrasound.What is the most likely diagnosis?(Anesthesia Feb 2025)

A- Perforated gallbladder
B- Gallbladder mucocele
C- Biliary colic
D- Acute cholecystitis
Ans. D

371- Hirschsprung's disease primarily affects which part of the large intestine? (Anesthesia Feb 2025)

A- Ascending colon
B- Sigmoid colon
C- Cecum
D- Rectum
Ans: D

372- A young patient has five episodes of vomiting and no other symptoms. Investigation shows an air fistula between the pancreas and the GIT. Where is the fistula most likely located? (Anesthesia Feb 2025)

A- Colon
B- Descending colon
C- Stomach
D- Duodenum
E- Jejunum

CamScanner

373- **A patient with dysphagia undergoes an endoscopy, which reveals patches of discoloration but no ulcers. Barrett's esophagus increases the risk of which condition? (Anesthesia Feb 2025)**

A- Adenocarcinoma
B- Signet ring adenocarcinoma
C- Squamous cell carcinoma
D- Lymphoma

Ans: A

374- **Which type of polyp has potential to become malignant? (Anesthesia Feb 2025)**

A- Serratus
B- Hemartomatous
C- Adenomatous
D- Hyperplastic
E- Tubular

Ans: C

375- **A patient presents with dysphagia. Endoscopy reveals a mass with an intact mucosa. Histology shows spindle cells and CD117 positivity. What is the most likely diagnosis? (Anesthesia Feb 2025)**

A- GIST (Gastrointestinal Stromal Tumor)
B- Leiomyoma
C- Leiomyosarcoma
D- Adenocarcinoma
E- Squamous cell carcinoma

Ans: A

376- **A patient presents with abdominal pain but no hematemesis. Endoscopy shows involvement of mucosal and submucosal layers. What is the most likely diagnosis? (Anesthesia Feb 2025)**

A- Atrophic gastritis
B- Peptic ulcer disease
C- Gastroesophageal reflux disease (GERD)
D- Eosinophilic gastritis

Ans: B

377- **A patient presents with high-grade fever, right hypochondrial pain, elevated alkaline phosphatase (ALP), and eosinophilia. What is the most likely diagnosis? (Anesthesia Feb 2025)**

A- Amebic liver abscess
B- Acute pancreatitis
C- Acute cholecystitis
D- Viral hepatitis

Ans: A

RENAL PATHOLOGY QUICK HINTS

Nephritic Syndrome

- ✓ Hematuria, RBC casts in urine
- ✓ Proteinuria <3.5g/day

Acute poststreptococcal glomerulonephritis

- ✓ Most frequently seen in children.2–4 weeks after group A streptococcal infection of pharynx or skin(Cellulitis)
- ✓ Presents with peripheral and periorbital edema, tea or cola-colored urine
- ✓ Show Type 3 HS and Decrease C3 compliment
- ✓ **LM**—glomeruli enlarged and hypercellular
- ✓ **IF**—("starry sky") granular appearance ("lumpy-bumpy") due to IgG, IgM, and C3deposition along GBM and mesangium
- ✓ **EM**—Subepithelial humps

Rapidly progressive (crescentic)glomerulonephritis

- ✓ **LM**- crescent moon shape . Crescents consist of fibrin and plasma proteins (eg, C3b) with glomerular parietal cells, monocytes, macrophages

Types

Linear IF - due to antibodies to GBM and alveolar basement membrane:

- ✓ ***Goodpasture syndrome***- Hematuria/hemoptysis and type II HS

Negative IF/Pauci-immune (no Ig/C3 deposition):

- ✓ Eosinophilic Granulomatosis with polyangiitis (formerly Churg-Strauss syndrome)—PR3-ANCA/C-ANCA
- ✓ Granulomatosis with polyangiitis or Microscopic polyangiitis—MPO-ANCA/p-ANCA

Granular IF—PSGN or DPGN

Diffuse proliferative glomerulonephritis

- ✓ Often due to SLE
- ✓ **LM**—"wire looping" of capillaries
- ✓ **IF**—granular
- ✓ **EM**—Subendothelial >Subepithelial

IgA nephropathy (Berger disease)

- ✓ Episodic hematuria that usually occurs concurrently with respiratory or GI tract infections
- ✓ **LM**—Mesangial proliferation
- ✓ **IF**—IgA-based IC deposits in mesangium; EM—Mesangial IC deposition

Alport syndrome

- ✓ Mutation in type IV collagen
- ✓ Most commonly X-linked dominant. Retinopathy, glomerulonephritis, sensorineural deafness;
- ✓ **EM**—"Basket-weave" appearance due to irregular thickening of GBM

Membrano- proliferative glomerulonephritis

Type I

- ✓ May associated with hepatitis B or C
- ✓ Subendothelial IC deposits with granular IF

Type II

- ✓ Associated with C3 nephritic factor
- ✓ Intramembranous deposits, also called dense deposit disease
- ✓ Both types: GBM splitting "tram-track"

Nephrotic Syndrome

- ✓ Massive proteinuria (> 3.5 g/ day)
- ✓ Hypoalbuminemia and edema
- ✓ Frothy urine with fatty casts
- ✓ Hypercoagulable state due to antithrombin III loss in urine
- ✓ Increase risk of infection

CamScanner

Minimal change disease
- ✓ Most common cause of nephrotic syndrome in children.Often Causes of primary Idiopathic Infection, Immunization, Immune stimulus(4 I's of MCD).
- ✓ Rarely, may be secondary to lymphoma
- ✓ Excellent response to corticosteroids.
- ✓ LM—Normal glomeruli (lipid may be seen in PCT cells)
- ✓ IF—⊖
- ✓ EM—effacement of podocyte foot processes

Focal segmental glomerulosclerosis
- ✓ Associated with HIV infection, sickle cell disease, heroin use, obesity, interferon
- ✓ Massive Proteinuria
- ✓ LM—segmental sclerosis and hyalinosis
- ✓ IF—often⊖
- ✓ EM—effacement of foot processes

Membranous nephropathy(membranous glomerulonephritis)
- ✓ Associated with NSAIDs, penicillamine,
- ✓ HBV, HCV, syphilis ,SLE, and solid tumors.
- ✓ LM—Diffuse capillary and GBM thickening
- ✓ IF—granular due to immune complex (IC) deposition
- ✓ EM—"Spike and dome" appearance of subepithelial deposits

Casts in urine

- ✓ **RBC casts -** Glomerulonephritis, hypertensive emergency
- ✓ **WBC casts -.** Tubulointerstitial inflammation, acute pyelonephritis, transplant rejection
- ✓ **Granular casts -** Acute tubular necrosis (ATN).
- ✓ **Fatty casts -** Nephrotic syndrome
- ✓ **Waxy casts -** End-stage renal disease/chronic kidney disease

Renal Stones

Calcium
- ✓ Most common **(80%)**
- ✓ Calcium Oxalate(Caused by Hypocitraturia and Crohn disease) >Calcium Phosphate(Precipitated by Increase PH)

Ammonium magnesium phosphate (struvite)
- ✓ Account for **15%** of stones. Caused by infection with urease ⊕ bugs (eg, Proteusmirabilis, Staphylococcus saprophyticus, Klebsiella)
- ✓ Precipitated by Increase PH

Uric Acid
- ✓ Causes Hyperuricemia(Gout)and Leukemia(Cell turnover)
- ✓ 5%
- ✓ Precipitates with Decrease PH

Cystine
- ✓ Hereditary (autosomal recessive) condition in which Cystine-reabsorbing PCT transporter loses function, causing cystinuria
- ✓ COLA- Cystine, Ornithine, Lysine, Arginine (COLA)

Note
- ✓ All Stones are Radiopague excep uric acid which are Radiolucent

Cystitis

- ✓ Inflammation of urinary bladder. Presents as suprapubic pain, dysuria, urinary frequency, urgency. Systemic signs (eg, high fever, chills) are usually absent.

Causes:
- ✓ E coli (most common)
- ✓ Staphylococcus saprophyticus—seen in sexually active young women (E coli is still more common in this group)
- ✓ Klebsiella
- ✓ Proteus mirabilis—urine has ammonia scent

- ✓ Labs: ⊕ leukocyte esterase. ⊕ nitrites
- ✓ Pyuria with ⊖ urine cultures could suggest urethritis by Neisseria gonorrhoeae or Chlamydia
- ✓

Pyelonephritis

Acute
- ✓ Neutrophils infiltrate renal interstitium Affects cortex with relative sparing of glomeruli/vessels.
- ✓ Presents with fevers, flank pain (costovertebral angle tenderness), nausea/vomiting, chills.
- ✓ E coli(UTI) is most common cause
- ✓ CT would show striated parenchymal enhancement
- ✓

Chronic
- ✓ The result of recurrent or inadequately treated episodes of acute pyelonephritis.
- ✓ Vesicoureteral reflux and renal stone common cause
- ✓ Corticomedullary scarring, blunted calyces. Tubules can contain eosinophilic casts resembling thyroid tissue (thyroidization of kidney).

Acute interstitial nephritis

Causes
- ✓ 5P and S
- ✓ Pee (diuretics)
- ✓ Pain-free (NSAIDs)
- ✓ Penicillins and cephalosporins
- ✓ Proton pump inhibitors
- ✓ RifamPin
- ✓ Sulfa drugs , sjogren ,Sarcoidosis and SLE
- ✓ Mycoplasma

Renal papillary necrosis
- ✓ Sloughing of necrotic renal papillae result in gross hematuria

Associated with:
- ✓ Sickle cell disease or trait
- ✓ Acute pyelonephritis
- ✓ Analgesics (eg, NSAIDs)
- ✓ Diabetes mellitus

Transudate and exudate

Transudate	Exudate
Due to CCF, Cirrhosis and Nephrotic syndrome	Infection, Inflammation, Malignancy
Colorless	Prulent or Bloody
Specific gravity <1.015	Specific gravity >1.015
Protein <3g/dl	Protein >3g/dl
Less cell Count	More cell count
Pleura: Serum LDH <0.6	Pleura: Serum LDH >0.6
Pleura: Serum protein <0.5	Pleura: Serum protein >0.5

AKI

Pre Renal:
- ✓ Urine osmolarity - >500
- ✓ BUN/Cr Ratio - >20
- ✓ Urinary Na - <20
- ✓ Free Excretion of Na - <1

Intrinsic renal failure:
- ✓ Urine osmolarity - <350
- ✓ BUN/Cr Ratio - <15
- ✓ Urinary Na - >40
- ✓ Free Excretion of Na - >2

Post renal azotemia:
- ✓ Urine osmolarity - <350

CamScanner

- ✓ BUN/Cr Ratio - vary
- ✓ Urinary Na - vary
- ✓ Free Excretion of Na - vary

CKD

- ✓ This is Stage wise reduction in GFR thus lead to retension of waste products
- ✓ It result in Decrease Vitamin D , Low Calcium and High Phosphate(Kidney unable to excrete Phosphate)

Consequences (MAD HUNGER):

- ✓ Metabolic Acidosis(Compensatory Hyperventilation result in low CO2)
- ✓ Dyslipidemia (especially increase triglycerides)
- ✓ High potassium
- ✓ Uremia-Can present with nausea, anorexia, encephalopathy (seen with asterixis), pericarditis, platelet dysfunction
- ✓ Na+/H2 O retention (HF, pulmonary edema, hypertension) so advised should be water intake less than 0.5L/day
- ✓ Growth retardation and developmental delay
- ✓ Erythropoietin deficiency (anemia)
- ✓ Renal osteodystrophy

Autosomal dominant polycystic kidney disease

- ✓ Occur in Adult
- ✓ Numerous cysts in cortex and medulla Presents with combinations of flank pain, hematuria, hypertension, urinary infection.
- ✓ Mutation in PKD1 (85% of cases, chromosome 16) or PKD2 (15% of cases, chromosome 4).
- ✓ Complications include chronic kidney disease and hypertension (caused by renin production).
- ✓ Associated with berry aneurysms, mitral valve prolapse, benign hepatic cysts, diverticulosis.

Autosomal recessive polycystic kidney disease

- ✓ Cystic dilation of collecting ducts
- ✓ Often presents in infancy. Associated with congenital hepatic fibrosis.
- ✓ Significant oliguric renal failure in utero can lead to Potter sequence

Renal Cell Carcinoma

- ✓ Polygonal clear cells filled with accumulated lipids and carbohydrate.
- ✓ Originates from PCT and invades renal vein
- ✓ May develop varicocele if left sided
- ✓ Class triad: flank pain, palpable mass, hematuria.
- ✓ Increase incidence with tobacco smoking and obesity.
- ✓ Associated with paraneoplastic syndromes, eg, PTHrP, Ectopic EPO, ACTH, Renin ("PEAR"-aneoplastic).
- ✓ Clear cell **(most common subtype)** associated with gene deletion on chromosome 3 (sporadic, or inherited as von Hippel-Lindau syndrome).

Nephroblastoma

- ✓ Also called Wilms tumor. Most common renal malignancy of early childhood (ages 2–4).
- ✓ Contains embryonic glomerular structures. Most often present with large, palpable, unilateral flank mass and/or hematuria and possible HTN.
- ✓ Can be associated with loss-of-function mutations of tumor suppressor genes WT1 or WT2 on chromosome 11.

Bladder Cancer

Urothelial carcinoma(Transitional Cell)of the bladder

- ✓ Common tumor of urinary tract system (can occur in renal calyces, renal pelvis, ureters, and bladder
- ✓ Factors - Phenacetin, tobacco Smoking, Aromatic amines (found in dyes), Cyclophosphamide
- ✓ Smoking >Amines >Hydrocarbon

Squamous cell carcinoma of thebladder

- ✓ Chronic irritation of urinary bladder lead to squamous metaplasia result dysplasia and squamous cell carcinoma.

- ✓ Risk factors include Schistosoma haematobium infection (Middle East), chronic cystitis smoking, chronic nephrolithiasis (stones).
- ✓ Schistostoma >Stones > IndwellingCatheter

Random

- ✓ Usual route of spread of renal cell carcinoma is through renal veins
- ✓ In nephrogenic diabetes-ECF osmolarity increase
- ✓ Most common shift of K+ to ECF – Strenous exercise
- ✓ Acute glomerulonephritis protienuria – Basement memberane defect
- ✓ Common Site of Lodging of ureteric stones overall/Adults – Vesico ureteric Junction
- ✓ Common Site of Lodging of ureteric stones in Child – Pelvico ureteric Junction
- ✓ Ureter Narrows at -- Vesico ureteric Junction > Where it enters Bladder
- ✓ In dialyzing fluid ,Glucose and HCO3 are more than plasma
- ✓ In dialyzing fluid , Na , K, Cl are less than plasma
- ✓ In dialyzing fluid , Mg and Ca equal to plasma
- ✓ Most common nephritic in Adult – IgA nephropathy
- ✓ Most common nephritic in infant – PSGN
- ✓ Most common nephrotic in Adult – Memberanous glomerunonephritis
- ✓ Most common nephrotic in infant – Minimal change disease
- ✓ Retic count decrease in- Chronic renal disease
- ✓ When ureteric bud doesnot grow towards metanephric cap – Absent ureter
- ✓ Nephrotic patient has increase risk of infection due to – Hypogammaglobunemia
- ✓ Most common cause of intrarenal azotemia – ATN
- ✓ In dialysis estimated GFR decreases to – 5%
- ✓ Dialysis is done when GFR is less than 10
- ✓ Commonest complication of dialysis – Hypotension
- ✓ Decision between dialysis and transplant is by – Creatinine clearance
- ✓ Recovery of renal function after renal transplantusually takes – 1 month
- ✓ Nephrotic syndrome associated with Hodgkin lymphoma – Minimal change disease
- ✓ Tumor is of embryonic origin in infancy – Nephroblastoma
- ✓ Smell of Burnt urine is present in - Maple syrup urine disease
- ✓ In uremic nephropathy type of anemia is – Normocytic normochromic anemia

CamScanner

RENAL PATHOLOGY

1. The association of IgA nephropathy is with which kind of deposits?

A. Sub epithelial deposits
B. Sub endothelial deposits
C. Linear sub endothelial deposits
D. Dome and spike sub epithelial deposits
E. Mesangial deposits

Ans: E(FA +Pathoma)

Explanation

Sub epithelial deposits	PSGN + MPGN (Tram track)
Sub endothelial deposits	SLE
Linear Sub endothelial deposits	Goodpasture Syndrome
Dome and Spike Sub endothelial	MGN
Kimmestiel Wilson lesions	DM Nephropathy
Mesangial deposits	IgA nephropathy
Sub endothileal humps	Memberane proliferative
Dense deposit disease	MPGN II

2. Most common nephritic syndrome in adult

A- PSGN
B- IgA nephropathy
C- Minimal change disease
D- Memberanous glomerulonephritis

Ans: B

Explanation

- Most common nephritic in Adult – IgA nephropathy
- Most common nephritic in infant – PSGN

3. Most common neprhrotic syndrome in infants

A- PSGN
B- IgA nephropathy
C- Minimal change disease
D- Memberanous glomerulonephritis

Ans: C

Explanation

- Most common nephrotic in Adult – Memberanous glomerunonephritis
- Most common nephrotic in infant – Minimal change disease

4. Which one is nephrotic syndrome?

A- Amyloidosis
B- IgA nephropathy
C- Diffuse proliferative glomerulonephritis
D- Membranous proliferative glomerulonephritis

Ans: A

Explanation

Nephrotic syndrome

- Minimal change disease
- Focal segmental glomerulosclerosis
- Membranous nephropathy
- Amyloidosis
- Diabetic glomerulonephropathy

Nephritic syndrome

- Acute poststreptococcal glomerulonephritis
- rapidly progressive (crescentic) glomerulonephritis
- Diffuse proliferative glomerulonephritis
- IgA nephropathy (Berger disease)
- Alport syndrome
- Membranoproliferative glomerulonephritis

5. RBC casts seen in:

A- Glomerulonephritis
B- Acute tubular necrosis
C- ESRD
D- ATN
E- Acute Pyelonephritis

Ans: A

Explanation:

- **Rbc cast** - Glomerulonephritis, hypertensive emergency
- **WBC casts** - Tubulointerstitial inflammation, acute pyelonephritis, transplant rejection.
- **Granular casts** - Acute tubular necrosis (ATN).
- **Fatty casts** - ("oval fat bodies") Nephrotic syndrome.
- **Waxy casts**- End-stage renal disease/chronic kidney disease
- **Hyaline casts** - Nonspecific, can be a normal finding with dehydration, exercise, or diuretic therapy. Form via solidification of Tamm-Horsfall mucoprotein (uromodulin), secreted by renal tubular cells to prevent UTIs

6. An 11 year old boy faced abdominal trauma and then presented to emergency. On labs there was 1+ blood and 3+ protein in Urine. What is the pattern of inheritance?

A- Autosomal recessive
B- Autosomal dominant
C- X linked dominant
D- X linked recessive

7. 46 years male presented withnephrotic synd Immunofluorescence microscope of renal biopsy showed Sclerosis with deposition of IgM and C3. What is most likely diagnosis?

A- Focal segmental glomerulosclerosis
B- Membranous nephropathy
C- Minimal change nephropathy
D- IgA nephropathy
E- PSGN

Ans: A(FA+Pathoma)

8. Adult polycystic kidney disease mode of transmission is

A- X linked Dominant
B- X linked Recessive
C- Autosomal dominant
D- Autosomal recessive
E- Multifactorial

Ans: C(FA+Pathoma)

Explanation:

- Adult – Autosomal Dominant
- Child – Autosomal Recessive

9. A middle age known ESRD list for hemodialysis multiple transfusion done Normocytic normochromic anemia Which is more appropriate therapy

A- S/C erythropoietin
B- S/C CGF
C- Iron supplements
D- Inj Vitamin B 12 IM
E- Inj Folate IV

Ans: A(FA+Pathoma)

10. A 70 years old with recurrent UTImost likely due to:

A- Outflow obstruction
B- Carcinoma
C- Pyelonephritis
D- Renal Failure
E- Cystitis

Ans: A(FA+Pathoma)

11. A Boy with H/O of pharyngitis having Raised ASO high amount proteinuria mechanism of disease :

A- Antigen antibody complex in different tissue
B- Antibody in tissue
C- Cells in Tissue
D- IgE mediated damage

Ans: A (PSGN)

12. Renal tubular necrosis would result in which of the Following:

A- Hyperkalemia
B- Hypernatremia
C- Hypokalemia
D- Increase urine volume
E- Increase concentrated urine

Ans: A>E(CMDT

Explanation:

- Hyperkalemia and Hyperphosphatemia common and pronounced finding in Renal tubular necrosis
- Urinary Sodium also high indicate Concentrated Urine

13. A child with generalized edema on urine examination proteinuria 2+there is GBM thickening what type of deposit will be seen?

A- IgM on GB Membrane
B- Sub Endothelial
C- Epithelial
D- Sub Epithelial

Ans: D(Membranous GN)

14. Patient presented with loin pain and mass in pelvis with hematuria Suspected carcinoma is?

A- RCC
B- Squamous cell carcinoma of bladder
C- Transitional cell carcinoma of bladder
D- Liver CA
E- Pancreatic CA

Ans: A

15. A lady on antihypertensive suddenly collapsed with serum potassium 6.7 and other signs is due to:

A- Acute Renal failure.
B- Chronic renal failure
C- Diuretic use
D- ACE inhibitor
E- CLD

Ans: A

16. Patient presented with complains of cough and hemoptysis kidney biopsy shows granular deposition of antigen antibody complexes with C1Q positive and GBM splitting noted.This is related to:

A- ANA positive
B- Post streptococcal antibodies
C- Anti glomerular antibodies
D- Membranoproliferative GN

Ans: D

17. Child is having proteinuria flank pain which protein deficient in this case?

A- Tryptophan
B- Albumin
C- Elastin
D- Collagen
E- Serotonin

CamScanner

18. In uremic nephropathy,What type of anemia occurs?
A- Hypochromic Normocytic anemia
B- Normochromic Normocytic anemia
C- Micro chromic Normocytic anemia
D- Megaloblastic anemia
E- Hemolytic anemia
Ans: B

19. A man presented with fever, rigors &and Pus in urine which is treated for 2 weeks is most likely suffering from:
A- UTI
B- Chronic Pyelonephritis
C- Acute Pyelonephritis
D- Appendicitis
E- Adenitis
Ans: C

20. A 7 years old school going boy develops sore throat. He received antibiotic for it, which resolved it, following 2 weeks later, he developed generalized body edema, hypertension and hematuria type of hypersensitivity in this is:
A- Type 1
B- Type 3
C- Type 4
D- Type 2
E- Type 4+2
Ans: B (PSGN)

21. Type 2 Diabetes patient has weakness and increase frequency of urine since 2 weeks. What is possible mechanism of polyuria?
A- Decrease water absorption from renal tubules
B- Decrease sensitivity of ADH on Aquaporin
C- Decreased glucose reabsorption from PCT
D- Increased Sodium absorption in gut
E- Decreased sodium delivery to gut
Ans: C

22. Patient presented with complain of fatigue, cough with hemoptysis and hematuria for 2days. Renal biopsy showed extra capillary glomerulonephritis with linear deposits of IgG along the GBM. What is the likely cause?
A- PSGN
B- Focal segmental glomerulonephritis
C- Good pasture syndrome
D- Alport syndrome
E- IgA nephropathy
Ans: C

23. Patient is passing dilute urine(asthenuria), there is tubuloglomerular concentrating problem, what other factor you will see in this condition?
A- Fixed specific gravity of urine
B- Low urinary sodium
C- High Urinary sodium
D- High Blood urea
Ans: B

Explanation:
- Clearly problem is in concentration ofurine so salt that is sodium will be lowin urine.
- In Isothenuria ans will be A

24. A patient has severe hypovolumia which kidney changes will be prominent?
A- Renal tubular acidosis
B- Acute tubular necrosis
C- Acedemia
D- Hypertension
Ans: B

25. Which of the following tumor is of embryonic origin in infancy?
A- Nephroblastoma
B- Neuroblastoma
C- Wilms tumor
D- Warthin tumor
E- Ewing sarcoma
Ans: A

26. Crescents are mainly formed by:
A- Epithelial cells
B- Mesengail cell
C- Parietal cell with increase Neutrophils
D- Macrophages
E- Lymphocytes
Ans: C (Only Suitable option No separate option of Parietal cells)

27. A male patient presented withhistory of fever, significant weightloss, painful micturition, hematuria and having raised creatinine and hematocrit. He is having cancer of which ofthe following organ?
A- Kidney
B- Thyroid
C- Stomach
D- Breast
Ans: A

28. Patient with history of multiple myeloma presented with polyuria, Polydipsia & He now has hypercalcemiaand confusion.Urine osmolality is 310mosm/l, what is the reason of polyuria?
Renal tubules do not respond to ADH
A- Decrease ADH formation
B- Psychogenic polydipsia
C- Increase Aldosterone
D-
Ans: A

29. A young boy after strenous exercisefelt pain in lumbar region. History ofstone what is Suitable investigation to reach diagnose?
A- Ultrasound KUB + CT KUB
B- X-ray KUB
C- Ultrasound KUB + X-ray KUB
D- Ultrasound KUB + Urethrogram + X-ray KUB
E- Ulteasound Abdomen
Ans: A

30. Sympathetic nerve block to urinary bladder will cause which of the following?
A- Unable to empty bladder
B- Decrease tone of external bladder sphincter
C- Increase tone of internal bladder sphincter
D- Pain and filling sensation loss
E- Detrusor contraction
Ans: D(Guyton)

31. Obstruction of ureteric stone most common:
A- Near the kidney
B- Superior to ischial spine
C- At the level of pelvic brim bounded by external iliac vessel
D- Above kidney
Ans: C

Explanation:
- Common Site of Lodging of ureteric stones overall/Adults – Vesico ureteric Junction
- Common Site of Lodging of ureteric stones in Child – Pelvico ureteric Junction
- Ureter Narrows at -- Vesico ureteric Junction > Where it enters Bladder Here C Suitable

32. A 40 year old man come in Er with complain of body weakness and oliguria he give history of taking some drug for weight gain from general quack urine detailed report urine specific gravity is 1.010 urea creatinine is raised ALT (slightly raised) urine calcium is raised the likely diagnosis is:
A- Nephrocalcinosis
B- RTA
C- Acute glumerulounephritus
D- Icteric form of hepatitis
Ans: A

33. Edema in nephrotic syndrome is due to:
A- Salt and water retention
B- Hypoalbuminemia
C- Increase hydrostatic pressure
D- Increase oncotic pressure
E- Portal HTN
Ans: B

Explanation:
- Peripheral edema in CLD due to – Loss of albumin (Low oncotic pressure)
- Ascities in CLD due to – Portal HTN
- Renal origin Edema due to – Loss of albumin (Low oncotic pressure) + Can be salt and water retention.
- Nephrotic syndrome edema due to – Hypoalbuminemia
- Nephritis Syndrome edema due to – Salt and water retension
- Pedal edema in CHF and HTN due to – Increase hydrostatic pressure
- In CHF edema woarsen by – Sodium and water retention

34. Patient went through cystoscopy due to hematuria. Later developed fever and hypotension cause of hypotension:
A- Hematuria
B- Sepsis
C- DIC
D- Bladder CA
Ans: B

35. Hypokalemic metabolic alkalosis leading to volume expansion is seen in:
A- Conn syndrome
B- ACTH secreting tumor
C- Primary adrenal insufficiency
D- None
Ans: A

36. BUN/Cr ratio greater than 20 cause will be:
A- Post renal Azotemia
B- Pre renal azotemia
C- ATN
D- CKD
Ans: B(Kaplan +FA)

CamScanner

Explanation:
Pre Renal:
- Urine osmolarity - >500
- BUN/Cr Ratio - >20
- Urinary Na - <20
- Free Excretion of Na - <1

Intrinsic renal failure:
- Urine osmolarity - <350
- BUN/Cr Ratio - <15
- Urinary Na - >40
- Free Excretion of Na - >2

Post renal azotemia:
- Urine osmolarity - <350
- BUN/Cr Ratio - vary
- Urinary Na - vary
- Free Excretion of Na – vary

37. Low calcium high phosphate no increase in CAMP on giving PTH likely due to:
A- ARF
B- CRF
C- Vit. D deficiency
D- Vit. D Excess
Ans: B

38. IgA Nephropathy deposits are:
A- Subendothelial
B- Subepithelial
C- Mesangial
D- Linear
Ans: C

39. Patient met an accident and was brought to emergency department. BP 80/40, Tachycardia, Low urinary output after catheterization. Renin was increased due to?
A- Decrease in arterial blood flow
B- Decrease in arterial blood pressure
C- Increase arterial blood flow
D- Increase arterial blood pressure
Ans: A

40. In nephrotic syndrome edema is due to:
A- Increase hydrostatic pressure
B- Decrease oncotic pressure
C- Salt retention
D- Water retention
Ans: B

41. Decision between dialysis and transplant is by:
A- Urea level
B- Ammonia level
C- Creatinine clearance
D- Potassium level
Ans: C

42. On electron microscopy, PSGN shows:
A- Subendothelial deposits
B- Sub epithelial deposits
C- Tramtrack appearance
D- Spike and dome appearance
Ans: B

43. On immunofluorescence, IgA nephropathy shows:
A- Increased mesangial deposition
B- Effacement of podocytes
C- Sclerosis of glomerular capillaries
D- Increased deposition in GBM
Ans: A

44. 5years old girl is brought to the physician because of facial swellings, puffy eyes and swollen legs, she had history of mild cellulitis after a mosquito bites 3 weeks ago, and her urine sample shows a reddish brown hue and contains both RBCs and proteins. Which of the following will most likely see on renal biopsy?
A- Fusion of podocytes foot process
B- Hyperplastic arteriolitis
C- IgA in the mesangium
D- Linear IgG deposits
E- Sub epithelial electron dense hump
Ans: E

Explanation:
- PSGN followed by cellulitis which shows sub epithelial hump
- Also note that Minimal change disease has effacement of foot process not fusion so A is wrong.

45. Selective proteinuria occurs in :
A. Nephritic syndrome
B. Acute MPGN
C. Membranous GN
D. Minimal Change Disease
Ans: D(FA+Pathoma)

46. In cresenteric glomerulonephritis antibody complex deposition on GBM which type of hypersensitivity?
A- Type 1
B- Type 2
C- Type 3
D- Type 4
Ans: B

Explanation:
- TYPE 1 – IgE mediated
- TYPE 2 – Antibody mediated
- TYPE 3 – Immune complex deposition
- TYPE 4 – Cell mediated

47. Carcinoma that is associated with increase hemoglobin:
A- Colonic carcinoma
B- Gastric carcinoma
C- Renal cell carcinoma
D- Squamous cell carcinoma
Ans: C

48. Man with History of being not well for long time Hb was 17 and on ultrasound there is 3 or 6cm spherical mass found on lower pole of kidney diagnose is:
A- Renal Adenoma
B- Renal Carcinoma
C- Gastric Carcinoma
D- Liver Adenoma
Ans: B

49. CKD with low calcium cause is:
A- Decrease Phosphate
B- Decrease 1, 25 Dihydroxycholichalciferol
C- Decrease Excretion
D- Decrease PTH
Ans: B

50. A patient has fever of 40 c with flank pain increase frequency chills and rigors. Diagnosis is done by:
A- Blood culture
B- Urine culture
C- Blood and urine culture
D- X-ray Kub
Ans: C

Explanation:
- If no fever mention then only urine culture.

51. Fanconi syndrome a rare genetic disorder. The child will present with:
A: Increase arginine level in blood
B: Glycosuria
C: Hyperkalaemia
D: Hyperphosphataemia
Ans: B (FA)

Explanation:
- Increase Glucose and Amino acid excretion
- Metabolic Acidosis (Proximal RTA)
- Hypophosphatemia
- Osteopenia

52. 59 years old patients known case of CRF presents with anemia due to:
A: Iron deficiency
B: Erythropoietin deficiency
C: Hematoma
D: Defective erythropoiesis
Ans: B

53. Patient presented with periorbital edema and proteinuria and RBCs cast on urinalysis, the problem is in:
A: GBM
B: PCT
C: DCT
D: Loop of Henley
Ans: A

54. Benign tumor among the given is
A: Warthin tumor
B: Ameloblastoma
C: Erythroplakia
D: Dyaplastic nevus
Ans: A

55. A child x-rays showing unilateral hydronephrosis. What is the cause behind this?
A- Ureterovesical obstruction
B- Posterior vesicle stricture
C- Pelvic ureteric junction obstruction
D- Pelvic Brim
Ans: C

56. Which one raised significantly in end stage renal disease?
A- Calcium
B- Creatinine
C- Magnesium
D- Choloride
Ans: B

57. A day following hysterectomy, a patient complains of severe pain in the right upper lumbar region of the back. Which of the following structures was most likely damaged during the surgery?
A- Inferior mesenteric artery
B- Internal iliac artery
C- Psoas major muscle
D- Pudendal nerve
E- Ureter
Ans: E

58. Which of the following is Paraneoplastic Syndrome of Kidney?
A- Polycythemia
B- Carcinoid Syndrome
C- PrRP
D- ADH
Ans: A

Explanation:
- Renal system mainly secreteserythropoietin that leads to Polycythemia & is considered as paraneoplastic syndrome

CamScanner

59. A sample of blood was drawn from the vein of a patient of renal failure, which of the followings is estimated from this sample:
A- Creatinine
B- PAH
C- Nitrogen
D- Inulin
Ans: A

60. A 60 years old male presented with history of fever, significant weight loss, painful micturition, hematuria and flank mass, his Hb is 18 what could be the possible pathology associated with his condition:
A- Renal cell carcinoma
B- Rhabdomyosarcoma
C- Angiomyolipoma
D- Polycystic kidney disease
Ans: A
Explanation:
- As the patient presented with history of weight loss and symptoms related to renal system along with increase hemoglobin that's due to increase erythropoietin level secreted by kidneys and the most suitable among the mentioned options is RCC.

61. ASO-Titer is used as marker for:
A- PSGN
B- Diabetic nephropathy
C- Minimal change disease
D- Proliferative disease
Ans: A
Explanation:
ASO-Titer is used in PSGN (Post streptococcal Glomerulonephritis).

62. Patient having hypokalemia, hypertension, with normal cortisol &VMA & raised aldosterone is most likely suffering from:
A- Cushing disease
B- Cushing Syndrome
C- Conn's Syndrome
D- Pheochromoctyoma
Ans: C
Explanation:
- As VMA is normal so Pheochromocytoma is excluded and then with normal cortisol cushing disease & syndrome is excluded. This is case of Conn's syndrome due to increase aldosterone level that has led to decrease potassium level, hypertension.

63. A known case of CRF, likely gland to enlarge:
A- Thyroid
B- Parathyroid
C- Adrenal gland
D- Pituitary
Ans: B(FA+Pathoma)

64. A patient with hematuria and RBC cast in urine. Structure involved:
A- JG Cells
B- Glomerulus
C- Bowmen's capsule
D- Epithelial cells
Ans: B

65. Good pasture syndrome related to
A- Sub endothelial deposition
B- Sub epithelial deposition
C- Linear deposition
D- IgG deposit
Ans: C

66. A renal disease with continuous elevated levels of renin:
A- Child polycystic kidney disease
B- Adult polycystic kidney disease
C- Focal segmental glomerulonephritis
D- Goodpasture syndrome
Ans: B(FA+Pathoma)

67. The renal problem associated with SLE:
A- IgA Nephropathy
B- FSGN
C- PSGN
D- Lupus Nephritis
Ans: D

68. True regarding kindey:
A- Cuboidal epithelium in parietal layer of bowman's capsule
B- Podocytes in visceral layer of bowman's capsule
C- Slit like space between macula and JG apparatus
D- DCT is longer than PCT
E- Glomerulus has one artery
Ans: B

69. An old age diabetic lady with CRF is on dialysis. Her X-ray Lower limb, femur head shows loss of trabecular bone. Which hormone is responsible for such X-ray findings:
A- PTH
B- Cortisol
C- Calcitonin
D- Throxine
Ans: A

70. 20 years old patient presented with increase urea, creatinine & increase K level:
A- AKI
B- RTA
C- DKA
D- HONK
Ans: A

71. An old lady presented in medical emergency in unconscious state. Her Bp 180/90 Temp 39 Pulse 90.Labs are Glucose 350mg/dl Na 130, K 3.5, Urea is 10. Diagnosis?
Chronic Renal Failure
A- RTA
B- Diabetic Keto acidosis
C- Honk
D-
Ans: A
Explanation:
- Since patient is Hypertensive,Urea is increased,Unconscious due to Urosepsis, All are indicating about chronic renal failure.Since potassium level is also normal range in CKD potassium level is less likely to fluctuate.

72. In post streptococcal glomerulonephritis finding is:
A- Linear depositions
B- Mesangial proliferation
C- Sub epithelial deposits
D- Alveolar damage
E- Sub Endothelial Deposits
Ans: C(FA+Pathoma)

73. 24, 25 dihydroxycholecalciferol increase in:
A- Chronic Renal failure
B- Hyper parathyroidisam
C- Hyperthyroidism
D- Prolactinoma
E- Paget's Disease
Ans: A (FA+Pathoma)

74. Hypercalcemia and renal failure. Cause?
A- PTH adenoma
B- Sarcodosis
C- Hypervitaminosis D
D- Metastatic
Ans: A

75. A patient with epistaxis, hematuria, saddle nose & granulomatous inflammation diagnose is
A- Churg strauss syndrome
B- Wegner granulomatosis
C- SLE
D- HIV
Ans: B(FA+Pathoma)

76. Young patient developed ARF after PPH which part of kidney is most likely damaged?
A- PCT
B- Loop of Henle
C- Collecting tubules
D- DCT
Ans: A

77. Patient with renal artery stenosis may present with very high blood pressure due to increased renin secretion. Which of the following structure in kidney is responsible for sensing inadequate perfusion and secreting renin?
A- Afferent Arterioles
B- Collecting duct
C- Juxtaglomerular cells
D- Efferent Arterioles
E- Arcuate artery
Ans: C

78. Edema due to renal cause can be due to:
A- Albuminuria
B- Glomerulonephropathies
C- Na retention
D- Na retention and albuminuria
Ans: D

79. Retic count decrease in:
A- Chronic renal disease
B- Hereditary spherocytosis
C- Bleeding from gut
D- Polycystic kidney disease
Ans: A

80. Child with generalized edema and proteinuria 6g per day. Which part of the kidney involved?
A- Interstitium
B- Basement membrane
C- Collecting tubules
D- Proximal convoluted tubules
E- Distal tubules
Ans: B

81. Proteins normally don't leak out in tubular fluid due to:
A- Endothelium is fenestrated
B- Basement membrane is thick
C- Basement membrane is negatively charged
D- Basement membrane is positive charged
Ans: C

82. Rectal biopsy was done. How to diagnose ameba infection:
A- Electron microscopy
B- Antibodies
C- PAS
D- DERA
Ans: C

83. Type 2 Renal tubular acidosis is due to:
A- Failure to excrete Hydrogen
B- Defect in HCO3 reabsorption
C- Dec NH4 Secretion
D- H secretion
Ans: B

CamScanner

84. There is increased risk of carcinoma of bladdar exposure to:
A. Ultraviolet radiation
B. Aryl Amines
C. Hydrocarbons
D. Arsenic
Ans: B

85. Focal segmental Glomerulosclerosis:
A. Subepithelial Humps
B. Subendothelial Humps.
C. Massive proteinuria
D. Wbc casts in urine
Ans: C

86. Long standing HT.Now shortness of breath, edema is due to:
A. Increase oncotic pressure
B. Decrease hydrostatic pressure
C. Increased hydrostatic pressure
Ans. C

87. An i/v urograph of 8 year old boy shows normal kidney on right side but absence of shadow on left side instead the shadow appear above the bladder on left side which of the following is the condition:
A- Left pelvic kidney
B- Unilateral renal agenesis
C- Constricted ectoipic kidney
D- Non rotation kidney
E- Horse shoe kidney
Ans. A

88. IgA nephropathy is associated with?
A- Berger disease
B- Minimal change disease
C- Post streptococcus
D- Wegner's granulomatosis
Ans: A(FA+Pathoma)

89. Calcium stones formation may be prevented by cohate through which process?
A- Complex formation
B- Precipitation
C- Diffusion
D- Osmosis
Ans. A

90. A lady with CRF patient, sample taken which was placed in refrigerator over night, next day, normal sodium, raised K(6.3) Raised PO4 and LDH(600) what is the cause?
A- Endstage renal failure
B- Hemolysis of Blood sample
C- Hemolysis of Tissue
D- Renal CA
E- Drug Intoxication
Ans: B

91. A 35 year female having malar rash and positive anti ds dna now develops proteinuria & hematuria the most likely cause will be
A- Nephrotic syndrome
B- Amyloidosis
C- Cystitis
D- Glomerulonephritis
E- Lupus nephritis
Ans: E

92. An old patient presented withfatigue weakness and dyspnea withlabs showing decreased calciumlevel, increased phosphate level,raised creatinine and increased PTHis a case of:
A- Acute renal failure
B- Renal tubular acidosis
C- ESRD
D- RCC
E- HCC
Ans: C

Explanation:
- Secondary hyperparathyroidism due to CRF will show low CA and high phosphate
- Secondary hyperparathyroidism due to any other cause will show low Ca and low phosphate

93. A man is a plumber he is having difficulty in breathing from last 1 year he is also short of breath and dyspenic his blood ABGS show PH7.4 HCO3 19 and PCO2 31 he has most likely
A- Metabolic acidosis
B- Metabolic alkalis
C- Compensated metabolic alkalis
D- Compensated metabolic acidosis
E- Mixed metabolic acidosis and alkalosis
Ans: D

94. A patient presented with severe diarrhea and vomiting . he ABGS are PH 7.23 HCO 16 and PCO2 36 he is having
A- Metabolic acidosis
B- Metabolic alkalis
C- Compensated metabolic alkalis
D- Compensated metabolic acidosis
E- Respiratory alkalosis
Ans: A

95. A patient came to you with hematuria what is the level of injury
A- Tubule
B- CD
C- Glomeruli
D- DCT
E- PCT

96. A patient has following ABGs PH of7.2, HCO3 levels of 19 and PCO2 of39 what is likely diagnose is?
A- Metabolic alkalosis
B- Respiratory acidosis
C- Metabolic alkalosis
D- Metabolic acidosis
E- Normal
Ans: D

97. A 70 kg man has cholesterol level of200, creatinine 0.8, BUN 20,Proteinuria of 30mg/dl , glycosuria++, fasting blood glucose 88, andhypertension cause of thishypertension is:
A- Diabetic nephropathy
B- Secondary hypertension
C- Glomerulonephritis
D- Pheochromocytoma
Ans: C

98. Patient presented with history of head trauma his urine osmolarity was decreased &Plasma osmolarity increased also developed symptoms of polydipsia and polyuria and Positive CH2O clearance Likely cause would be
A- Central Diabetes insipidus
B- Nephrogenic Diabetes insipidus
C- Diabetes Mellitus
D- SIADH
E- Psychogenic Polydyspia
Ans: A

99. ADH causes which effect:
A- Increase plasma osmolality
B- Decrease urine osmolality
C- Decrease plasma volume
D- Increase urine osmolarity
Ans: D

100. 3 weeks old child with h/o projectile vomiting since birth findings will be
A- Hypochloremic metabolic alkalosis
B- Metabolic acidosis
C- Hyperchloremic metabolic acidosis
D- Respiratory acidosis
Ans: A

101. A patient of burn given Succinylcholine after which ECG shows Tall T wave due to
A- Hyponatremia
B- Hypokalemia
C- Hyperkalemia
D- Hypochloremia
Ans: C

102. Metabolic acidosis is due to
A- Increase Bicarbonate in blood
B- Decrease Bicarbonate in blood
C- Increase CO2 in blood
D- Increase CO2 in alveoli
E- Decrease CO2 in blood
Ans: B

103. ABG's of a patient advised report shows PH:7.3 HCO3 :15 PCO2:38 diagnosis?
A- Metabolic acidosis
B- Metabolic alkalosis
C- Respiratory alkalosis
D- Respiratory acidosis
E- Mixed acid base
Ans: A

104. Known CCF Patient developed pedal edema and pleural effusion pleural tap done what will be findings of fluid suggestive of transudate ?
A- Cloudy appearance
B- Low cell count
C- High protein
D- Fibrin
E- Hemorrhagic
Ans: B

105. Female at gestational age 34 havingsymphysio-fundal height of 28 weeks.Cause may
A- Anencephaly
B- Esophageal atresia
C- Renal agenesis
D- Tracheo esophageal fistula
Ans: C

Explanation:
- If Gestational age is more than Fundalheight then – Renal Agenesis andOligohydramnios.
- If Gestational age is less than fungalheight then – Esophageal atresia,Hydrocephalus and polyhydramnios.

106. Patient present with Low serum calcium and ionic calcium, high serum phosphate, increased PTH, most likely suffering from
A- CRF
B- Osteomalacia
C- Hyperparathyroidism
D- Bone metastases
Ans: A

107. Horse shoe kidney associated with?
A- Renal failures
B- Pelvi ureteric junction abnormality
C- Polycystic KD
D- Vesico ureteric Reflux
Ans: B

CamScanner

108. An I/V urograph of 8 year old child shows fusion of lower poles of kidney which one of the following is most likely condition?

A- Hoarse shoe kidney
B- Constricted ectopic kidney
C- Pelvis kidney
D- Non rotating kidney
E- Unilateral Renal agenesis

Ans: A

109. Intra membranous electron dense deposits are most characteristic of:

A- Acute pyelonephritis
B- DM
C- Hepatitis B antigenemia
D- Positive NVA test
E- Post streptococcal nephritis

Ans: E

110. In CKD which of the followingoccurs?

A- Anemia is of IDA type
B- Plasma CO2 tend to be low
C- Amount of ionized calcium in the bloodrises due to calcium retention
D- Specific gravity of urine is high
E- Water intake should be restricted upto0.5 L /day

Ans: B

Explanation:

- In CKD plasma CO2 tend to be lowand we advise water restriction upto0.5L/D
- So if asked what occur then B
- If asked what should be advised then E

111. Usual route of spread of renal cell carcinoma is through:

A- Direct infiltration
B- Lymphatics
C- Renal artery
D- Ureter
E- Renal veins

Ans: E

112. Patient with high bp, 180/110 ANA+ , complimemt level normal, what will be other finding?

A- Acute glomerulonephritis
B- Hyperplastic atherosclerosis
C- Daibetic nephropathy
D- Nodular glomerulonephritis

Ans: D

113. A patient has presented with generalized body edema and peripheral edema his urine show hematuria and protein cause of edema is:

A- Decrease hydrostatic pressure
B- Increase hydrostatic pressure
C- Lymphatic obstruction
D- Increase oncotic pressure
E- Salt Retention

Ans: E

114. In nephrogenic diabetes, what will occur?

A- Urine osmolarity increase
B- ECF osmolarity increase
C- ECF volume increase
D- ECF osmolarity decrease

Ans: B

Explanation:

- In Nephrogenic DI ADH can't work on renal tubules no Water reabsorption occur all water filtered to Urine and Salt increase in ECF so osmolarity increase in ECF and in urine water becomes more and salt become less so urine osmolarity decrease.

115. An 8 year old patient presents to theclinic with periorbital edema. Hislabs showed protein greater than3.5g/dl. What is the probable cause?

A- Potassium retention
B- Sodium retention
C- Naturesis
D- Albuminuria and sodium retention
E- Calcium retention

Ans: D

116- Which of following is commoncause of metastatic calcification inkidney?

A- Vit. A deficiency
B- Vit. D deficiency
C- Hyperparathyroidism
D- Hypothyroidism
E- Heart failure

Ans: C

Explanation:

Causes include

Hypercalcemia

- Primary hyperparathyroidism
- Hypervitaminosis D
- Sarcoidosis
- Hydroxyapatite deposition

Hyperphosphtaemia

- Phosphate derived excess Ca from normal tissue and deposit in basal ganglia cause metastatic Calcification
- CRF
- Hypoparathyroidism

Hyperuricemia

117- A patient after RTA having blood loss develop acute tubular necrosis which part of nephron will be affected

A- CD
B- Loop of henele
C- PCT
D- DCT

Ans: C

118- ABGS of a patient shows PH = 7.5, PCO2 = 20, HCO3 = 20, PO2 = 80, the likely diagnosis is:

A- Metabolic acidosis
B- Metabolic alkalosis
C- Uncompensated Respiratory alkalosis
D- Compensated metabolic alkalosis

Ans: C

119- A patient suffering from generalized Edema and frothy urine renal biopsy was done and there were pink foam cells in tubules. This is due to the:

A- Absorption of Fats
B- Absorption of lipid
C- Absorption of glucose
D- Absorption of Proteins

Ans: D

120- Increase incidence of cancer kidney due to:

A- Increase UTI cases
B- Analgesic nephropathy
C- Central DI
D- Hyperglycaemia

Ans: B

121- 22 Year old boy with abdominal pain purpura and having raised Urea nitrogen cause is:

A- IgA nephropathy
B- HUS
C- PSGN
D- Nephritic syndrome

Ans: B

122- Most significantly increased creatininein

A- Severe dehydration
B- Kidney Stones
C- ESRD
D- HCC

Ans: C

123- Patient known case of HBV having cirrhosis, most common cause of secondary hyperaldosteronism is?

A- ACTH
B- CRF
C- Renin
D- Prolactin

Ans: C

124- A Patient came in ER with BP 160/100having headache, fatigue andpalpitation lab reveals Na 150 and K 3 What is likely cause of this condition?

A- MI
B- Hyperaldosteronism
C- Hypoaldosteronism
D- Addison Disease

Ans: B

125- A patient has palpable pruritic rash raised creatine with burning feet and handalso having urine plasma protein diagnose is:

A- ITP
B- IgA nephropathy
C- HSP
D- TTP

Ans: C

126- A patient has generalized body edema and peripheral edema. His urine shows hematuria and protein . Cause is

A- Salt retention
B- Increase hydrostatic pressure
C- Increase oncotic pressure
D- Decrease hydrostatic pressure

Ans: A

127- A patient is suffering from chronicrenal failure GFR decrease to less than 50% and on dialysis. Increase in which parameter of blood is alarming to doctor

A- Calcium
B- Creatinine
C- Urea
D- Sodium
E- Potassium

Ans: E

128- Patient is on peritoneal dialysis having K 6.1 what should be avoided

A- Leaf
B- Eggs
C- Yogurt
D- Tomatoes

Ans: D

129- If patient has right flank mass, hematuria proteinuria then what will you suspect?

A- Increase erytopoeitin
B- Hypocalcemia
C- Increase Uric acid
D- Decrease RBC mass

Ans: A

CamScanner

130- A patient After RTA having blood loss and develop hypovolumic shock histological findings in this patient kidney will be:
A- Acute tubular necrosis
B- Increase concentrated urine
C- Increase diluted urine
D- Increase renin
Ans: A

131- Diabetic nephropathy diagnosed by which of following?
A- Increase urinary Albumin
B- Increase Serum Albumin
C- Microalbuminuria
D- Increase Urinary Nitrogen
E- Increase Urinary Creatinine
Ans: C

132- Minimal Change disease feature is
A- Non proteinuric
B- Proteinuria 35mg/dl
C- Resistant to steroid
D- Pus cells
E- RBC greater than 10/hpf
Ans: B

133- Renal cause of uncontrolled hypertension:
A- Polycystic kidney disease
B- Atherosclerosis of proximal 2cm of renalartery
C- Atherosclerosis of distal 2cm of renalartery
D- Pelviureteric stone
Ans: B

134- Sub endothelial electron dense deposits are most characteristics of?
A- MSGN
B- Positive nva test
C- Post streptococcal nephritis
D- Minimial change disease
Ans: C

135- A female with Ph 7.5, Hypolkalemia, normal sodium and normal cortisol but raised renin levels?
A- Renal artery stenois
B- Siadh
C- Conns syndrom
D- Cushing sundrome
Ans: A

136- Elder brother is concerned about his younger brother because he is having renal tumor which tumor marker should be looked for?
A- P53
B- WT1
C- Bcl2
D- BRCA 1
E- KRAS
Ans: B

137- ADPKD with gene defect located on:
A- Chromosome 6
B- Chromosome 16
C- Chromosome 8
D- Chromosome 10
Ans: B

Explanation:
- PKD2 Chromosome 4q21 --15%
- PKD1 Chromosome 16p13.3 --85%

138- A Patient after RTA had severe blood loss and no urine output. Even after 3 days patient failed to have urine output Cr 9.5 biopsy show cortical necrosis and severe acute tubular necrosis. What is cause in this patient?
A- Drug induced injury
B- Irreversible injury
C- Apoptosis
D- Calcification
Ans: B

139- Dangerous substance elevated in ARF is
A- Calcium
B- Creatinine
C- Urea
D- Sodium
E- Potassium
Ans: E

140- A child has minimal change lesion and has frothy urine. Microscopy shows pink drops this is due to:
A- Proteinuria
B- Decrease membrane permeability
C- Nephron damage
D- Vasa recta leak
Ans: A

141- Patient with CRF, having low calcium and high phosphate explain the biochemical change
A- Decrease CA absorption in gut
B- Decrease 1, 25 dihydrocalceferol
C- Increase level of parathormone
D- Increase calcium loss in urine
E- Increase osteoclastic activity
Ans: B

142- Cause of kidney stones in vitamin A deficiency?
A- Atrophy of renal mucosa
B- Hypertrophy of renal mucosa
C- Hyperplasia of renal mucosa
D- Dysplasia of renal mucosa
E- Metaplasia of renal mucosa

143- A few family members have polycystic kidney disease now to confirm autosomal dominant polycystic kidney disease in some other member before appearing of cysts which investigation should be done:
A- Karyotyping
B- FISH
C- DNA sequence
D- Frequency matching
Ans: C

144- Chronic renal failure will cause:
A- Dehydration
B- Anemia
C- Increase urine output
D- Decrease Phosphate
E- Hypercalecmia
Ans: B

145- Membranous glomerulonephritis associated with:
A- RA
B- SLE
C- Selective proteinuria
D- Hepatitis A
Ans: B

146- Child having periorbital puffiness will have:
A- Proteinuria >3.5 g per day
B- Proteinuria >2.5 g per day
C- Increase pus cells
D- Proteinuria < 1.5 g per day
Ans: A

147- 33 years old female is found to have hematuria and proteinuria in urinalysis. She is not complaining of dysuria abdominal pain or any other urinary symptoms you notice on exam that her face looks cachexic. Her buccal fat pads are absent and her eyes appear shrunken which of the following is the likely diagnosis?
A- Type 2 membranoproliferative glomerulonephritis
B- Lupus nephritis
C- Acute glomerulonephritis
D- Type 1 membranoproliferative glomerulonephritis
Ans: B

148- In Renal failure which cells will be effected:
A- Interstitial cell of kidney
B- Mesangial cell
C- JG cell
D- Peritubular cells
Ans: D

149- In CRF which of the followlng occurs:
A- Water intake should be restricted to 2L/day
B- Anemia when occurs is of iron deficiency type
C- Specific gravity of urine Is high
D- Amount of ionized calcium in the blood rises due to calcium retention
E- Plasma pC02 tends to be low
Ans: E

150- Renal origin edema occur due to:
A- Increase hydrostatic pressure
B- Decrease oncotic pressure
C- Salt retention
D- Water retention
Ans: B

151- Child with generalized body edema cause is?
A- Hypoproteinemia
B- Increase hydrostatic pressure
C- Decrease Sodium
D- Increase Sodium
E- Decrease Magnesium
Ans: A

152- Patient Presented with fever, decrease platelets and bloody diarrhea peripheral film shows schistocytes what is likely cause?
A- HUS
B- TTP
C- HSP
D- ITP
Ans: A

153- A young boy with proteinuria of 3.5g/dl and whole body swelling. Cause of edema is
A- Increased Na absorption
B- Hypoalbuminemia
C- Hyperalbuminemia
D- Increase K absorption
Ans: B

154- Patient presented with increase bp upto 180/110, Renin is increased on investigation.Which one of the following is defective?
A- Peritubular capillaries
B- JG cells
C- Vasa recta
D- Macula densa
Ans: B

CamScanner

155- In crescenteric glomerulonephritis antibody omplex deposition on GBM which type of hypersensitivity?

A- Type 1
B- Type 2
C- Type 3
D- Type 4
Ans: B

Explanation:

- Over all glomerulonephritis has type 3 HS
- But antibody deposited mentioned then type 2 HS

(Add explanation to the already added bcq only)

156- Minimal Change disease feature is

A- Non proteinuric
B- Proteinuria 3.5 g
C- Resistant to steroid
D- Pus cells
E- RBC greater than 10/hpf
Ans: B

157- A Diabetic patient undergoing an IPV test shows filling defects in renal pelvis and ureter. What is the likely diagnosis?

A- Pyelonephritis
B- Hydronephrosis
C- Nephrolithiasis
D- Renal cyst
E- Emphysematous pyelonephritis
Ans: E

158- A hypertensive can be managed pharmacologically and surgically, on labs what's the evidence that makes it possible for him to be treated pharmacologically instead of surgery?

A- Increase Catchecholamines
B- Hyperrenemia
C- Hyperaldosteronism
D- Hypercalcemia
E- Inflammatory response to Kidney
Ans: B

159- A patient presented with vomiting and signs of dehydration having urea 70 and Cr 0.8 cause will be:

A- Post renal Azotemia
B- Pre renal azotemia
C- ATN
D- CKD
E- Glomerulonephritis
Ans: B

160- *Type 2 Renal tubular acidosis* has

A- Increase *HCO3 absorption*
B- Decrease *H ions absorption*
C- Decrease *HCO3 absorption*
D- *H ions secretion defect*
Ans: C

Better

161- Child with generalized edema,1st line of investigation?

A- Urinary protein
B- Albumin/globulin ratio
C- Serum albumin
D- Serum creatinine
Ans: A

162- A patient presents with hematuria, facial flushing, mass in right iliac fossa. Laborotory findings will show:

A- Hypocalcemia
B- Hypertension
C- High Renin
D- Polycythemia
Ans: D(RCC induced)

163- Immune deposit present in

A- Cortex
B- Mesangium
C- Afferent arteriol
D- Renal Medulla
Ans: B

164- A research study was conducted to evaluate kidney function in patients with various renal disorders. During the study, it was observed that many patients had urine that appeared cloudy. The researchersanalyzed the patients' renal functions, focusing on how effectively their kidneys were performing various tasks. Given this scenario, which specific kidney function is most likely compromised if the primary observation is cloudy urine?

A- Filtration
B- Reabsorption
C- Concentration
D- Secretion
Ans: B

165- Patient of CRF presented to ER with raised BP of 210/150mmHg.After initial management, Investigations were advised which revealed a serum Creatinine level of 8mg/dL (Normal. 0.7-1.3mg/dL).Function of which of the following structure is impaired?

A- JG Cells
B- Mesangial Cells
C- Glomerulus
D- Peritubular Capillaries
E- PCT
Ans: A

166- A patient presents with history of Edema. His vitals reveal Increased Blood Pressure. Investigations reveal: Hypokalemia, decreased renin levels, Increased Sodium levels but Renin, Angiotensin 2 & Aldosterone levels are within normal limits. A diagnosis of Liddle syndrome is made. Where is the defect located?

A- Mutation in Epithelial sodium channel (ENaC) in the collecting duct
B- Sodium-potassium ATPase pump
C- Aldosterone receptor
D- Renin-angiotensin system
E- Na-H Cotransport
Ans: A

167- Known patient of CKD taking dialysis twice a week how will you make a decision between transplants and to continue dialysis:

A- Inulin Clearance
B- Nitrogen Accumulation
C- Creatinine clearance
D- Urea Clearance
E- Glucose Estimation
Ans: C

168- A patient presents with diluted urine. After administering desmopressin, the patient's condition gets better, leading to an improvement in urine osmolality. What was deficient in the patient's serum?

A- ADH
B- Ang2
C- Aldosterone
D- Renin
Ans: A

169- Cause of Respiratory Acidosis among the following:

A- Barbiturate overdose
B- Salicylate toxicity
C- Diuretics
D- V/Q Mismatch
Ans: A(FA)

Explanation:

Cause: Hypoventilation

- Airway obstruction
- Acute lung disease
- Chronic lung disease
- Opioids, sedatives
- Weakening of respiratory muscles

170- Patient having following ABGS after returning 10 days from Height pH: 7.2 ,pCo2: 60mmHg and HCO3- :32mEq/L . Diagnosis is

A- Respiratory acidosis with partially compensated metabolic alkalosis
B- Respiratory acidosis with metabolic acidosis
C- Metabolic Alkalosis
D- Metabolic Acidosis
Ans: A

171- Normotensive patient with hypomagnesemia, hypocalcemia, Hypocalciuria, Hypokalemia & increased renin angiotensin. Most suitable Diagnosis?

A- Liddle Syndrome
B- Barter Syndrome
C- Gitelman Syndrome
D- Renal Tubular Acidosis
E- Conn Syndrome
Ans: C(Clinical Nephrology Textbook)

Explanation:

Bartter Syndrome:

- Reabsorption defect: Thick ascending loop of Henle (affects $Na^+/K^+/2Cl^-$ cotransporter).
- Key findings: Metabolic alkalosis, hypokalemia, hypercalciuria.

Gitelman Syndrome:

- Reabsorption defect: NaCl in the distal convoluted tubule (DCT).
- Key findings: Metabolic alkalosis, hypomagnesemia, hypokalemia, hypocalciuria.

Liddle Syndrome:

- Mutation type: Gain-of-function mutation leads to decreased degradation of sodium channels.
- Effect: Increased sodium reabsorption in the collecting tubules.
- Key findings: Metabolic alkalosis, hypokalemia, hypertension, decreased serum aldosterone

172- Metabolic acidosis with normal anion gap is caused by

A- Acute salicylate poisoning
B- Carbonic anhydrase inhibitor
C- DKA
D- Drowning
E- Renal failure
Ans: B

CamScanner

Metabolic acidosis with increase anion gap	Metabolic acidosis with normal anion gap
Lactic acidosis	Renal tubular acidosis
Ketoacidosis	Diarrhea
Renal failure	Addisons disease
Salicylate poisoning	Pancreatic fistula
Ethylene glycol poisoning	Carbonic anhydrase inhabitors
Methanol poisoning	Ammonium chloride ingestion

173- 50 year old woman with normal anion gap acidosis, cause: (Medicine Feb 2025)

A- Diabetic Ketoacidosis
B- Chronic Renal Failure
C- Psychoneurosis
D- Excessive Use of HCO3- Inhibitors
E- Diarrhea
Ans: E

174- An 8-year-old patient presents to the clinic with periorbital edema. His labs showed protein greater than 3.5g/dl. What is the probable cause?(Medicine Feb 2025)

A- Loss of Albumin in urine
B- Decreased Production of Albumin
C- Increased Hydrostatic pressure
D- Salt Retention
Ans: A

175- 60-year-old patient on anticancer therapy presents with blood in urine (hematuria). Which drug is most likely responsible?(Medicine Feb 2025)

A- Cisplatin
B- Bleomycin
C- Vincristine
D- Cyclophosphamide
Ans: D

176- What is the most likely cause of persistent hypokalemia? (Medicine Feb 2025)

A- Low potassium (K^+) diet
B- Persistent vomiting
C- Hyperaldosteronism
D- Acute kidney injury
Ans B

177- Pink-colored inclusions in kidney tubules indicate increased reabsorption of:(Medicine Feb 2025)

A Protein
B- Glucose
C- Sodium
D- Lipids
Ans: A

178- A female suffering from episode of hysteria has ph 7.6 HCO3 35,what is the diagnosis?(Medicine Feb 2025)

A- Metabolic alkalosis
B- Respiratory alkalosis
C- Metabolic acidosis
D- Compensatory respiratory alkalosis
Ans: A

179- Metabolic alkalosis and hypokalemia due to excess of:(Medicine Feb 2025)

A- Aldosterone
B- Cortisol
C- Renin
D- Angiotension
Ans: A

180- A 28 year old male presents in ER department with hemoptysis and hematuria in this linear deposits if antibodies are directed against which structures: (Medicine Feb 2025)

A- Glomerular basement basement
B- Mesengium
C- Endothelial cells
D- Podocytes
E- Bowman's capsule
Ans: A

181- A man presents with complain of flank pain and hematuria.X-ray detects no kidney stones urin analysis shows acidic urine and crystals which kidney stone is this: (Medicine Feb 2025)

A- Calcium oxalate stone
B- Calcium phosphate stone
C- Ammonium magnesium phosphate
D- Cysteine stone
E- Uric acid stone
Ans: E

182- A patient has following ABGs PH of 7.2, HCO3 levels of 19 and PCO2 of 39 what is likely diagnose is?(Surgery Feb 2025)

A- Metabolic alkalosis
B- Respiratory acidosis
C- Metabolic alkalosis
D- Metabolic acidosis
F- Normal
Ans: D

183- A patient present with ABGs of PH 7.28, PCO2 50mmhg and HCO3 is 28 which of the following is acid base balance of the patient: (Surgery Feb 2025)

A- Respiratory acidosis
B- Respiratory acidosis with partial compensation
C- Metabolic acidosis
D- Metabolic alkalosis
Ans: B

184- A patient present with ABGs of PH 7.35, PCO2 60mmhg and HCO3 is 35 which of the following is acid base balance of the patient(Surgery Feb 2025)

A- Respiratory acidosis with complete compensation
B- Respiratory acidosis with partial compensation
C- Metabolic acidosis with partial compensation
D- Metabolic acidosis with full compensation
E- Mix acidosis
Ans: A

185- A patient presents in a semi-conscious state and develops blindness the next day after treatment. Methanol level testing is unavailable. Which of the following tests can best assess the severity of the condition and potential kidney damage?(Gynae & Obs Feb 2025)

A- Arterial Blood Gas (ABG)
B- Complete Blood Count (CBC)
C- Creatinine Clearance
D- Osmolality Gap
E- Electrolyte Panel
Ans D

186- "A 2-year-old child presents with metabolic acidosis (pH 7.2, HCO_3^- 14) and hypokalemia (K^+ 2.6). Sodium is normal. What is the most likely diagnosis?(Radiology Feb 2025)

A- Renal Tubular Acidosis (RTA)
B- Lactic Acidosis
C- Diabetic Ketoacidosis (DKA)
D- Dehydration
Ans: A

187- Which of the following is the most consistent investigation for post-streptococcal glomerulonephritis (PSGN)? (Radiology Feb 2025)

A- ASO titer
B- Blood culture
C- Complement levels (C3, C4)
D- Urine Culture
Ans: C

CamScanner

RESPIRATORY PATHOLOGY QUICK HINTS

Pulmonary embolism

- ✓ Obstruction of the pulmonary artery or its branches by foreign material (usuallythrombus) that originated elsewhere.
- ✓ Present with sudden-onset dyspnea and Cause sudden death pleuritic chest pain, tachypnea, tachycardia, hypoxemia, respiratory alkalosis
- ✓ **CT pulmonary angiography** is imaging test of choice for PE (look for filling defects)
- ✓ **ECG** may show sinus tachycardia or, less commonly, **S1Q3T3** abnormality.
- ✓ V/Q mismatch that Show Increase or Infinity
- ✓ Emboli first go to IVC
- ✓ Emboli firs loadge in Pulmonary artery(Lung)

Types

Air Embolism

- ✓ History of Passing CVP then SOB
- ✓ In Ascending divers (caisson disease/decompression sickness)

Amniotic Fluid Embolism

- ✓ Pregnant lady + Long bone fracture Died on way to hospital within 24h or during labour
- ✓ Lead to DIC
- ✓ Most Fatal type of Pulmonary Embolism that cause extensive Pulmonary necrosis Shock and Death

Fat Embolism

- ✓ Symptoms start to appear after 12 h
- ✓ Long bone fracture
- ✓ Death after 3-5 days
- ✓ Present with Hypoxemia and Cerebral Petechiae is due to Low platelets

Mediastinal masses

Anterior - 4 T's: thyroid (substernal goiter), thymic neoplasm, teratoma, "terrible" lymphoma.
Middle - esophageal carcinoma, metastases, hiatal hernia, bronchogenic cysts.
Posterior - neurogenic tumor (eg, neurofibroma), multiple myeloma

Obstructive Diseases

Chronic bronchitis

- ✓ Wheezing, crackles, cyanosis and Dyspnea
- ✓ Diagnostic criteria: Productive cough for ≥ 3 months in a year for > 2 consecutive years.
- ✓ Hypertrophy and hyperplasia of mucus-secreting glands in bronchi
- ✓ Reid **index** (thickness of mucosal glandlayer to thickness of wall between epithelium and cartilage) > 50%

Emphysema

- ✓ Barrel-shaped chest
- ✓ Increase AP diameter
- ✓ Increase Elastase activity Decrease elastic fibers decrease Recoil result in increase lung compliance

A-Centriacinar

- ✓ Affects respiratory bronchioles while sparing distal alveoli
- ✓ Associated with tobacco smoking Frequently in upper lobes

B-Panacinar

- ✓ Affects respiratory bronchioles and alveoli,
- ✓ Associated with α1 antitrypsin deficiency. Frequently in lower lobes.

Asthma

- ✓ Intermittent episodes of coughing, wheezing, tachypnea, dyspnea, hypoxemia
- ✓ Hyperresponsive bronchi Reversible bronchoconstriction lead to Smooth muscle hypertrophy and hyperplasia
- ✓ Curschmann spirals
- ✓ Charcot-Leyden crystals
- ✓ Type I hypersensitivity reaction occur

Bronchiectasis

- ✓ Daily purulent sputum, recurrent infections hemoptysis, digital clubbing.
- ✓ Pseudomonas common pathogen
- ✓ Permanently dilated airways.
- ✓ Associated with Kartagener syndrome and cystic fibrosis
- ✓

Sarcoidosis

- ✓ Characterized by immune-mediated, widespread noncaseating granulomas Elevated serum ACE levels, and elevated CD4/CD8 ratio in bronchoalveolar lavage fluid
- ✓ CXR shows bilateral Hilar lymph adenopathy and coarse reticular opacities
- ✓ Associated with Bell palsy , Uveatis ,Lupus pernio , Schaumann And asteroid bodies Rheumatoid arthritis-like arthropathy
- ✓ **Histologically diagnosed by Non Caseating Granuloma >Granuloma and Asteroid bodies**
- ✓ **Characteristics feature is Erythma Nodosum >Hypercalcemia**

Pneumoconioses

Asbestosis

- ✓ **Affect Lower lobe**
- ✓ Associated with Shipbuilding, roofing, plumbing
- ✓ Supradiaphragmatic and pleural plaques are pathognomonic of asbestosis.
- ✓ Risk of bronchogenic carcinoma > risk of mesothelioma
- ✓ Increase risk of caplan syndrome
- ✓ Iron staining done for ferruginous (Asbestose) Bodies

Silicosis

- ✓ Affects upper lobes
- ✓ Associated with sandblasting, foundries, mines
- ✓ Leads to TB
- ✓ Increase Risk of cancer, cor pulmonale and Caplan syndrome
- ✓ Eggshell calcification of hilar lymph nodes on CXR

Coal Worker pneumoconiosis

- ✓ Affects upper lobe
- ✓ Prolonged coal dust exposure macrophages laden with carbon lead to fibrosis
- ✓ Also known as black lung disease increase risk of Caplan syndrome
- ✓ Anthracosis - Asymptomatic milder type of pneumocobisosis condition found in many urban dwellers exposed to sooty air

Mesotheloma

- ✓ Histology may show psammoma bodies. Tonofilaments. With Calretinin and cytokeratin 5/6 ⊕

ARDS

Diagnosis of exclusion with the following criteria (ARDS):

- ✓ Abnormal chest X-ray (bilateral lung opacities) B
- ✓ Respiratory failure within 1 week of alveolar insult
- ✓ Decreased Pao2 /Fio2(ratio < 300, hypoxemia due to ◆ intrapulmonary shunting and diffusion abnormalities)
- ✓ Symptoms of respiratory failure are not due to HF/fluid overload

Pneumothorax

Primary spontaneous pneumothorax

- ✓ Due to rupture of apical subpleural bleb or cysts.Occurs most frequently in tall, thin, young male
- ✓ Associated with tobacco smoking.
- ✓ No lung disease

Secondary spontaneous pneumothorax

- ✓ Due to diseased lung (eg, bullae in emphysema, Marfan syndrome, infections), mechanical ventilation with use of high pressures(barotrauma)

Traumatic pneumothorax

- ✓ Caused by any type of trauma

Tension pneumothorax

- ✓ Can be from any of the above. Air enters pleural space but cannot exit.
- ✓ Trachea **deviates away from affected lung**

CamScanner

Pneumonia

Lobar Pneumonia
- ✓ Involve single lobe or whole lung

Organism
- ✓ S pneumoniae (most common), Legionella and Klebsiella

Stages

Congesion
- ✓ 1-2 days
- ✓ Partial consolidation of parenchyma
- ✓ Exudate with mostly bacteria

Red Hepatization
- ✓ 3-4 days
- ✓ Red-brown consolidation
- ✓ Exudate with fibrin, bacteria, RBCs, WBCs
- ✓ Reversible

Gray Hepatization
- ✓ 5-7 days
- ✓ Uniformly gray
- ✓ Exudate full of WBCs, lysed RBCs, and fibrin

Resolution
- ✓ 8+ days
- ✓ Enzymatic digestion of exudate by macrophages

Bronchopneumonia
- ✓ Involve greater than 1 lobe

Organism
- ✓ S pneumoniae, S aureus, H influenza and Klebsiella

Interstitial (atypical) pneumonia

Organism
- ✓ Mycoplasma, Chlamydophila pneumoniae, Chlamydophila psittaci, Legionella
- ✓ Viruses (RSV, CMV, influenza, adenovirus)
- ✓ Has indolent course ("walking" pneumonia).

Cryptogenic organizing pneumonia (bronchiolitis obliterans organizing pneumonia (BOOP).
- ✓ Non infectious has Inflammated bronchioles
- ✓ Respond to Steroid but not to antibiotics

Percussion

Dull percussion note - inPleural effusion ,Atelactasis and Consolidation(Lobar Pneumonia and Pulmonary edema)

Hyper resonant percussion note - inSimple pneumothorax and Tension pneumothorax

Lung Cancer

Presentation: cough, hemoptysis, bronchialobstruction, wheezing, pneumonic "coin" lesion on CXR or noncalcified nodule on CT.

Sites of metastases from lung cancer: liveradrenals, bone and brain

Small Cell Cancer

Small Cell CA
- ✓ Central
- ✓ Smoking + Most aggressive
- ✓ Ectopic ACTH (Cushing syndrome) + Lambert Eaton syndrome + SIADH Amplification of myc oncogenes common + Encephlitis
- ✓ Kulchitsky cells -small dark blue cells
- ✓ Enolase And Synaptiphysin positive
- ✓ Responsive to chemo and radiotherapy

Non Small Cancer

Squamous Cell CA

- ✓ Central
- ✓ Smoking + Hypercalcemia(PTHrp) + Cavitation
- ✓ Keratin pearls and intercellular bridges(desmosomes).

Adenocarcinoma
- ✓ Peripheral
- ✓ Most Common histological Lung CA
- ✓ Most common in Non Smoker and Females
- ✓ Associated with hypertrophic osteoarthropathy (clubbing).
- ✓ Glandular pattern, often stains mucin ⊕
- ✓ Bronchioloalveolar **subtype** -grows along alveolar septa cause thickening of alveolar wall

Large Cell CA
- ✓ Peripheral
- ✓ Highly Anaplastic
- ✓ Strong association with smoking
- ✓ Produce HCG -Gynecomastia
- ✓ Less response to chemotherapy
- ✓ Pleomorphic giant cells

Bronchial carcinoid tumor
- ✓ Central or peripheral
- ✓ Excellent prognosis
- ✓ Symptoms due to mass effect or carcinoid syndrome (flushing, diarrhea, wheezing).
- ✓ Nests of neuroendocrine cells and chromogranin A ⊕.

Conclusion
- ✓ Both Small Cell and Squamous Cell
- ✓ CA Strongly associated with Smoking but Most Aggressive is Small Cell CA.
- ✓ Smoking + Aggressive = Small Cell CA
- ✓ Smoking + Common = Squamous Cell CA
- ✓ Ectopic thyroid produce by – Squamous Cell CA of Larynx.

Lung Hemartoma has well define and has nodules

2 types
- ✓ Chondromatous – Has cartilage
- ✓ Lieomyomatous – No cartilage
- ✓ Both show Coin lesion on Xray
- ✓ So what will not be present in lung hemartoma -Cartilage in lesion area

◇◇◇◇◇◇◇◇◇◇

CamScanner

RESPIRATORY PATHOLOGY

1- Dead Space increases in:
A- Lung collapse
B- Pulmonary edema
C- Hypertension
D- Hypotension
E- Atelectasis
Ans: D

Explanation:
Increased Dead Space:
- Emphysema
- Pneumonia
- ARDS
- Smoking
- ETT intubation
- Bronchitis
- Asthma
- Cardiac Failure
- Pulmonary Embolism
- Neck Extension
- Standing
- Hypotension
- Bronchodilation

Decreased Dead Space:
- Atelectasis
- Tracheostomy
- Sleep
- Maxillectomy
- Hyperventilation
- Neck Flexion
- Supine Position
- Bronchoconstriction

2- A patient Nonsmoker, fever for 6 weeks and cough with small amount of blood on xray "Coin lesion "is seen in upper lobeRelated to
A- Small cell carcinoma
B- Granuloma.
C- Silicosis
D- Adenocarcinoma
Ans: B(Golijan)

3- Farmer's lung is due to which of the following agent
A- Grain dust
B- Sugar cain
C- Cotton fiber dust
D- Coal dust
E- Asbestos
Ans: A

Explanation:
- Grain Dust – Farmer Lung
- Aspergillosis – Farmer lung with Granuloma rhino sinusitis medial eroision and calcification of lung
- Inorganic dust – Diffuse lung fibrosis on X-ray without fever or Cough

4- A patient presented with Fever productive cough and altered sensorium. X-Ray shows lobar pneumonia. How to confirm diagnose
A- Sputum culture
B- Montox test
C- Monospot test
D- Tensilon test
Ans: A

5- Patient has facial congestion, lung CA diagnosed to be small cell (oat cell) CA, it will show increased:
A- ACTH
B- PTHrP
C- TSH
D- Cortisol
Ans: A(Robins +FA)

6- Obstructive lung disease with decreased oxygenation and retention of CO_2, hyperinflation of lung on x-ray likely diagnose among these is:
A- Emphysema
B- Asthma
C- Cystic fibrosis
D- Aspergillosis
E- Bronchiectasis
Ans: A

7- Which of following is true regarding Diffusion capacity of O_2
A- Less than N_2
B- More than CO_2
C- Decreases in exercise
D- Decreases in lung fibrosis
Ans: D

8- Patient with lung fibrosis has dyspnea due to which of following reason
A- Dec diffusing capacity of O2.
B- Increased airway resistance
C- Increase diffusion of CO2
D- Atelectasis
Ans: A

9- A person who is smoker and working in construction factory , bilateral diaphragmatic lung lesions on CXR due to which of these
A- Asbestosis
B- Silicosis
C- Tb
D- Byssinosis
E- Carbon
Ans: A

10- Regarding alveoli true is
A- Surfactant avoid collapse of alveoli
B- Produce by type II pneumocytes
C- Decrease compliance
D- Increase Surface tension
Ans: A

11- A man with no cough and fever CXR show diffuse lung fibrosis likely cause is
A- Smoking
B- Organic dust
C- Inorganic dust
D- Radon
Ans: C

Explanation:
- Grain Dust – Farmer Lung
- Aspergillosis – Farmer lung with Granuloma rhino sinusitis medial eroision and calcification of lung
- Inorganic dust – Diffuse lung fibrosis on X-ray without fever or Cough

12- Patient working in mine has tuberculin test positive presented with Cough, fever, weight loss and hilar Lymphadenopathy which of following could be the reason behind these findings
A- Silicosis
B- Asbestosis
C- Anthracosis
D- Pneumoconiosis
Ans: A(Silicosis induced TB)

13- Dead space decreased in which of following condition
A- Emphysema
B- Pleural effusion
C- Atelectasis
D- Standing
E- Pneumothorax
Ans: C

14- Dead space decrease in which of following condition
A- Standing
B- Tracheostomy
C- Deep inspiration
D- Shallow breathing
Ans: B

15- Carbon laden macrophages develop in which of following disease
A- Silicosis
B- Pneumoconiosis
C- Anthracosis
D- Asbestosis
Ans: C (Golijan)

16- Common source of pulmonary embolism is
A- Popliteal vein
B- Femoral vein
C- Saphenous vein
D- Tibial vein
Ans: B

Explanation:
- DVT – Popliteal vein
- Embolism – Femoral Vein

17- Ashcoff bodies generation initial stage is which of following
A- Fibrosis
B- Epithelioid
C- Fibrinoid degeneration
D- Granuloma
Ans: C

Explanation:
- **Early Exudative phase** – Collection of fibrinoid material on swollen collagen called fibrinoid degeneration
- **Classic Phase** – Central focus of fibrinoid change is surrounded by leukocytes, fibroblasts and histiocytic cell called Anitschkow Myocyte.
- **Late Phase** – Progressive fibrosis

18- Adult ARDS was treated with porcilin (surfactant), What was its MOA
A- Decrease alveolar surface tension
B- Increase complaince
C- Increase intrapleural pressure
D- Increase surface tension
Ans: A

19- Obstructive disease of lung increases which capacity
A- FRC
B- FEV1
C- VC
D- TLC
Ans: A(BRS)

Explanation:

Feature	Obstructive disease (Asthma&COPD)	Restrictive Disease (Fibrosis)
FEV1	Decrease++	Decrease+
FVC	Decrease+	Decrease++
FEV1/FVC	Decrease	Normal or Increase
FRC	Increase	Decrease

CamScanner

20- Which is more related to malignancy
A- Asbestos
B- Berrylium
C- Aromatic amines
D- Silica
Ans: A

21- A Female patient with B/L pleural effusion and dyspnea with basal crepitation and having pedal edema most suitable diagnose is
A- Recurrent thromboembolism
B- DVT
C- CHF
D- MI
Ans: C

22- In obstructive lung disease what will increase
A- TV
B- RV
C- FEV1
D- Increase elastic recoil
Ans: B

23- Pulmonary embolism leading to shock and death caused by which of these
A- Thromboembolism
B- Infarction
C- Fat emboli
D- Air emboli
Ans: A

24- 55 years old female, non-insulin dependent diabetes. Had cholecystectomy done on 3rd post op day she developed sudden dyspnea, chest pain and hemoptysis likely Cause is
A- Hiatus hernia
B- MI
C- Pneumonia
D- Pulmonary embolism
E- Spontaneous pneumothorax
Ans: D

25- Characteristic feature of sarcoidosis is
A- Diabetesinsipidus
B- Erlythema-nodosum
C- Hepaticgranuloma
D- Hypercalcemia
E- Pleuraleffusiom
Ans: B(Davidson)

26- 5 year old girl with SOB no cough for three months present with temp 38.7 F R/R 25.sputum clear negative culture with ordinary media ANA negative on CXR hilar Lymphadenopathy and right lower lobe infiltrates Diagnose is
A- Bronchogenic carcinoid CA
B- Pneumonia
C- TB
D- SLE
Ans: B

27- A patient had non-productive cough for 2 months. Now presented with blood streaked sputum. Left Lung has 5 cm hilar mass. Sputum shows hyper chromatic, pleomorphic cells with scanty cytoplasm. Cause of this condition is
A- Silicosis
B- Asbestosis
C- Smoking
D- Passive smoking
E- Radon exposure
Ans: E

28- Paraneoplastic syndrome is caused by which of the following
A- Small cell carcinoma of lung
B- Renal cell carcinoma
C- Carcinoid
D- HCC
Ans: A

29- Vital capacity less than 80% present in:
A- Restrictive lungs disease
B- Normal person
C- Asthma
D- Bronchitis
Ans: A

30- A neonate born prematurely has a deficiency of surfactant. She is at a risk of Developing which of following condition
A- Lung hypoplasia
B- Respiratory distress syndrome
C- Asthma
D- COPD
Ans: B

31- Woman with respiratory symptoms that improve on her vacation, bronchopulmonary biopsy shows increase in lymphocytes, some eosinophils and neutrophils, also allergic alveolitis and some hilar nodes. what will be the history findings
A- She crackscocain
B- She has pigeons/parrots in basement
C- Tobacco smoke
D- House has lead composition
Ans: B

32- COPD is diagnosed when Fev1
A- Less than 90
B- More than 80
C- Less than 0.8
D- More than 0.8
Ans: C

33- Regarding pulmonary embolus true is
A- Alveolar po2 increase
B- Arterial PCO_2 increase
C- Perform ventilation mismatch
D- V/Q become low
Ans: A

34- A 55 year old lady with swelling of both legs and B/L pleural effusion presents to you. Lab values= AST 263, ALT 223, LDH 760, CK 150. No fever or other symptoms diagnosis is
A- Reno vascular hypertension
B- Recurrent thromboembolism
C- Rheumatoid arthritis
D- Hepatic failure
Ans: B

35- Asthma affects which of the following
A- Medium size bronchiole
B- Medium size bronchus
C- Respiratory bronchiole
D- Tertiary bronchioles
Ans: A

36- Surfactant deficiency causes which of the following
A- Reduced change of negative intrapleural pressure
B- Patchy atelectasis
C- Decreased surface tension
D- Increase Compliance
Ans: B

37- Increased calcium in squamous cell carcinoma is due to which of following factors
A- PTHrp
B- Increased PTH
C- Increased ACTH
D- Increase Vitamin D
Ans: A(FA+Pathoma)

38- A Patient who is indulged in Demolition of Old buildings develops dyspnea recently. CXR showed diffuse interstitial Fibrosis of Lungs bilaterally. On histology, iron staining of the cells was positive. Most likely diagnosis is
A- Silicosis
B- Asbestosis
C- Anthracosis
D- Bysinosis
Ans: B

39- Patient with Cough, fever for last 3 months and cervical lymphadenopathy and he also has non healing ulcer on tongue Histology shows granuloma with Caseous Necrosis. Hilar lymph sign on chest Xray are normal what is suitable diagnose
A- TB
B- Histoplasmosis
C- Bronchogenic CA
D- Sarcoidosis
Ans: B
Explanation:
- Non healing ulcer on tongue mostly seen in Histoplasmosis
- Hilar Xray Sign normal in Histoplasmosis
- Non healing ulcer on tongue also seen in TB but Xray is abnormal

40- Patient is Smoker on biopsy of alveoli there will be which of these findings
A- Decrease no of Goblets cell
B- Squamous metaplasia
C- Columnar epithelium
D- Increase number of goblet cells
Ans: B

41- Which of the following increases in Asthma
A- IgE
B- IgG
C- IgD
D- IgM
E- Basophils
Ans: A

42- A patient with cervical lymphadenopathy CXR shows bilateral hilar lymphadenopathy biopsy shows caseating granuloma pattern Likely diagnose is
A- TB
B- Histoplasmosis
C- Sarcoidosis
D- Hodgkin lymphoma
Ans: A

43- Non caseating granuloma with asteroid bodies Related to which of these
A- TB
B- Histoplasmosis
C- Aspergilosus
D- Sarcoidosis
Ans: D

44- Cause of Interstitial lung disease is which one of following
A- Inorganic dust
B- Histoplasmosis
C- Silicosis
D- Asbestosis
Ans: A

CamScanner

45- Regarding Primary TB following is true
A- Dry cough
B- Caseous necrosis
C- Ghon complex
D- Sputum production
Ans: C

Explanation:
- Primary Tb – Ghon Complex + Lower Lobe
- Secondary Tb -- Cavitation + Upper Lobe

46- Patient presented with Dry cough, and his chest x-ray shows hilar lymph nodes what is required for diagnosis?
A- Granuloma with asteroids
B- Granuloma with caseation
C- Gumma
D- Ghon focus
Ans: A

47- The type of cells involved in sarcoidosis are:
A- T lymphocytes
B- Eosinophils
C- Plasma cells
D- Neutrophils
E- Macrophages
Ans: A (FA)

48- Which of the following are called Dust cells?
A- Alveolar macrophages
B- Neutrophils
C- Lymphocytes
D- Eosinophil
Ans: A

49- A female resident received a case of chronic smoker with hoarseness of voice and lymphatic nodules. It is due to which of following
A- CA of esophagus
B- Lymphoma
C- Nasopharyngeal CA
D- CA of larynx
Ans: D(Dhingra)

50- ACTH release and carcinoid syndrome is caused by which carcinoma
A- Small cell
B- Larger cell
C- Bronchogenic
D- Squamous cell
Ans: A(FA+ Pathoma +Robins)

51- Patient has lung cancer came to oncologist with the complain of increase urinary phosphate concentration. After complete evaluation, you find this patient has increase parathyroid related hormone level. Which carcinoma is responsible for this
A- Small cell
B- Larger cell
C- Bronchogenic
D- Squamous cell
Ans: D(FA + Pathoma +Robins)

Explanation:
Squamous Cell CA Associated with
1- Smoking
2- Hypercalcemia (PTHrP)
3- Keratin Pearls and Intracellular Bridges

52- Patient had difficulty in breathing for some days, O/E breath sounds are decreased on both sides and dullness on percussion, CXR shows bilateral fluid & leg edema what could be the possible cause
A- Hypoalbuminemia
B- Hypoglobulinemia
C- Hypernatremia
D- Deranged LFTs
Ans: A

53- Schaumann bodies are found in which of following
A- Sarcoidosis
B- Parkinson's Disease
C- Rabies
D- Asbestosis
Ans: A

Explanation:
- Schaumann Bodies: Sarcoidosis
- Negri Bodies: Rabies
- Lewy Bodies: Parkinson's Disease
- Ferruginous Bodies: Asbestosis

54- An Old patient with fever and weight loss, patches in lungs, hemoptysis, epitheloid cells next step Is which among these
A- AFB
B- CXR
C- HIV Serology
D- CD4 Count
Ans: A

Explanation:
The scenario is related to TB and next best step is AFB to confirm the diagnosis.

55- Aspiration in sitting (upright) position the content will go into which of these sites
A- Left posterior zone
B- Left Lower zone
C- Right Posterior Zone lower lobe
D- Apical/Superior Segment of Right lower lobe
Ans: C

Explanation:
- Foreign Body in **Supine** – Apical (Superior) Segment of Right Lower Lobe
- Foreign Body in Sitting/Standing **(Upright)** -- Posterior basal Segment of Right Lower Lobe
- Foreign Body in **Right Lateral** – Posterior Segment of Right Upper Lobe
- Foreign Body in **Left Lateral** – Inferior Lingular of Left Upper Lobe

56- Bronchogenic carcinoma metastasize most commonly to which of the following endocrine gland
A- Pituitary Gland
B- Adrenal Gland
C- Thyroid Gland
D- Parathyroid Gland
Ans: B

Explanation:
Adrenal gland is the commonest endocrine gland site for metastasis of the bronchogenic carcinoma that's 22% followed by Pituitary gland.

57- A farmer contacted a disease from sheep & the skin lesion is ulcerated black most likely is
A- Plaque
B- Anthrax
C- Pneumoconiosis
D- Leishmania
Ans: B

Explanation:
Anthrax is a bacterial disease of animals most commonly seen in cattle, sheep and goats.

58- Which of the following is part of respiratory conducting portion?
A- Trachea
B- Alveoli
C- Alveolar Duct
D- Alveolar Sac
Ans: A

Explanation:
Trachea is part of conducting portion of respiratory system while Alveolar Duct, Alveoli & Alveolar Sac are part of Respiratory portion.

59- Difference between sarcoidosis & Tb is
A- Symmetrical B/L hilar lymphadenopathy
B- Fever
C- Constitutional symptoms
D- Night Sweats
Ans: A

60- A patient presented with low grade fever, night sweats & productive cough most likely due to:
A- TB
B- AIDS
C- Sarcoidosis
D- Histoplasmosis
Ans: A

61- A man went from sea level to 12000height in 2 days. After 12 hours reaching the destination, he developed dyspnoea. Whats the cause:
A- Pulmonary edema
B- Secondary polycythaemia
C- Primary polycythaemia
D- Heart Failure
Ans: A

Explanation:
High Altitude Pulmonary Edema (HAPE) is a no cardiogenic pulmonary edema which typically occurs in lowlanders who ascend rapidly to higher altitudes. Early symptoms includes non-productive cough, dyspnea on exertion & reduced exercise performance & later on dyspnea occurs eve at rest.

62- Commonest type of bronchogenic carcinoma is
A- Sqamous cell carcinoma
B- Adenocarcinoma
C- Small cell carcinoma
D- Large cell carcinoma
Ans: B (Robins +Pathoma +FA)

Explanation:
Adenocarcinoma of the lung is the most common form of lung cancer accounting for 30% of all cases overall and about 40% of all non-small cell lung cancer occurrences.

63- A 55 years old female known case of some hematological pathology, admitted to the hospital with the history of sudden onset of severe dyspnea, on echocardiography it was found that the lady has severe pulmonary hypertension what could be the best possible cause associated with the condition
A- Repeated pulmonary emboli
B- Massive pulmonary embolism
C- DVT
D- MI
Ans: A

CamScanner

64- **A child known case of cystic fibrosis presented with acute respiratory infection, on investigation the organism diagnosed as pseudomonas aruginosa, what are the other findings associated with this patient**
A- Bronchial asthma
B- Bronchiectasis
C- Emphysema
D- Pleural effusion
Ans: B

65- **Regarding Pulmonary TB true is:**
A- Occur in Posterior upper lobe in lung
B- Occur in Posterior lower lobe in lung
C- Foul Smelling Sputum
D- Foul Smelling Saliva
Ans: A (Davidson)

Explanation:
- Pulmonary Tb -Upper Posterior lobe(Oxygen tension in upper lobe Favours survival of Aerobic organism)
- Primary Tb -Ghone Complex + Lower Lobe
- Secondary Tb -Cavitation + Upper Lobe

66- **Which of following tumor secrete parathyroid hormones?**
A- Small cell carcinoma of lung
B- Hepatocellular carcinoma
C- Squamous cell carcinoma of lung
D- Papillary carcinoma
E- Renal Carcinoma
Ans: C (FA +Pathoma)

Explanation:
- **Small Cell CA** – Smoking + Mostaggressive + Ectopic ACTH (Cushingsyndrome) + Lambert Eaton syndrome +SIADH.
- **Squamous Cell CA** -Smoking +Hypercalcemia(PTHrp)
- **Ectopic thyroid produce by** – SquamousCell CA of Larynx

67- **Bronchogenic carcinoma is due to exposure to which of these agent**
A- Asbestosis
B- Nickel
C- Cadmium
D- Carbon
Ans: A

Explanation:
- Bronchogenic carcinoma & mesothelioma is caused by exposure to asbestosis
- Bronchogenic carcinoma > Mesothelioma on exposure to Asbestosis

68- **Histological findings of chronic bronchitis include**
A- Reid Index > 50 %
B- Reid Index < 50%
C- Atrophy of Mucosal Glands
D- Enlargement of Air spaces
Ans: A(FA+Robins+Pathoma)

Explanation:
Histological findings of chronic bronchitis is characterized by hyperplasia of mucus secreting glands in bronchi that's Reid index (thickness of mucosal gland layer to thickness of wall between epithelium and cartilage) > 50%.

69- **A patient presented with weight loss, productive cough & night sweats what will be seen on histology?**
A- Non caseous necrosis
B- Caseous necrosis
C- Granuloma with Asteroid
D- Non Asteroid
Ans: B

Explanation:
The scenario is related to Tb and on histology there will be caseous necrosis.

70- **Diagnostic test for Leprosy is**
A- AFB
B- Montoux Test
C- Nasal Scrapping
D- None
Ans: C

71- **In Plastic Industry worker cause of Angiosarcoma is which of following**
A- Arsenic
B- Vinyl chloride
C- Cadmium
D- Asbestosis
Ans: B

Explanation:
- Angiosarcoma in Plastic Factory Worker – **Vinyl chloride**
- Angiosarcoma in Farmer – **Arsenic**
- **Plastic** Factory Worker – **Liver Angiosarcoma**
- **Plastic** Factory worker + **Smoking – Lung CA > Angiosarcoma**

72- **Emphysema due to smoking is which of these**
A- Panaciniar
B- Centriacinar
C- Both
D- Distal acinar

Explanation:
Centriacinar begins in the respiratory bronchioles and spreads peripherally mainly in the upper half of the lungs and is usually associated with long standing cigarette smoking.
Panacinar associated with Alpha-1 antitrypsin deficiency.

73- **A patient presented with history of low grade fever, weight loss, productive cough & Granulomatous nasal lesion is most likely suffering form which of following disease**
A- M-TB
B- M-Leprae
C- Staph Aureus
D- Hemophilus
Ans: B

74- **A Pregnancy of 28 weeks with no complications suddenly needed resuscitation and given mechanical intubation due to respiratory insufficiency and zero respiratory effort having increase opacities on X-ray after premature birth. What will be found in baby lungs?**
A- Decreased lamellar bodies in type 2
B- Pneumocytes
C- Alveolar hemorrhage
D- Diffuse Alveolar edema
Ans: A

75- **A 60 years old ate street food developed lung abscess due to which mechanism**
A- Indirect spread from liver
B- Direct Spread from liver
C- Release of exotoxin
D- Release of endotoxin
Ans: B

76- **Which of the following is the cell of atopic asthma**
A- Mast Cells
B- Eosinophils
C- Basophils
D- Lymphocytes
Ans: A

Explanation:
For Atopic Asthma prefer the cells in the following order:Mast Cells > Basophils > Eosinophils

77- **Following sudden relief in ARDS, patient develops one of these is**
A- Apnea
B- Hypertension
C- Postural Hypotension
D- GIT disturbances
Ans: A

78- **Kartagener's Syndrome involves which of these**
A- Collagen
B- Fibrillin
C- Dynein Arms
D- Centrioles
Ans: C(Robins)

79- **DLCO decreases in which condition**
A- Pulmonary Fibrosis
B- Polycythemia
C- Pulmonary hemorrhage
D- Asthma
Ans: A

80- **Asthmatic Patient having respiratory rate of 30/min and dyspneic findings include**
A- Increase Lung compliance
B- Decrease Lung compliance
C- No change
D- None of the above
Ans: A

81- **Regarding the lung compliance, the following is true:**
A- Increased by stiff lung
B- Increase by increase elastic recoil
C- Increase by decrease intrapleural pr
D- Increase in old age
E- Increase in bronchial obstruction
Ans: D

Explanation:
Increase in Old age
- Lung compliance
- RV
- V/Q mismatch
- A-a gradient

Decrease in Old age
- Chest wall compliance
- FVC and FEV1
- Respiratory muscle strength
- Ventilatory response to hypoxia / hypercapnia

82- **A young male living in a populatedtown, he died in an RTA on theautopsy the lymph nodes of lungs arefound black in color, which of thefollowings associated with thecondition of this patient:**
A- Melatonin
B- Anthracosis
C- Bronchogenic carcinoma
D- Bronchial asthma
E- TB

CamScanner

83- Which factor sees an increase in restrictive lung diseases?
A- FEV1/FVC
B- Compliance
C- FRC
D- TV
E- ERV
Ans: A(FA+Pathoma)

84- Sarcoidosis is diagnosed microscopically by?
A- Granuloma with asteroid
B- Caseating granuloma
C- Non caseating granuloma
D- Macrophages
Ans: C (Robins)

85- A patient with one year history of SOB presents with cough. O/E wheeze, hyper-resonant chest and decrease vocal fremitus. PFTs show decrease FEV/FVC and also decreased lung elastase. What is the cause of increased activity of neutrophil elastase?
A- Nicotine
B- NO
C- Carbom
D- Alpha 1 antitrypsin
E- Silicosis
Ans: A

86- A patient has signs of Byssinosis. He works in which industry?
A- Coal
B- Textile
C- Road
D- Plumber
Ans: B

87- Acute respiratory distress syndrome isrelated to which of following?
A- Late birth
B- Prematurity
C- Genetical disease
D- Obstetrics complications
E- Chemical
Ans: B

88- Female was diagnosed Alpha 1 antitrypsin deficiency. Which part of respiratory tract would be most affected?
A- Alveolar duct
B- Terminal bronchioles
C- Alveoli
D- Medium sized bronchi
Ans: A

89- A 7 year old child with cough and mucus, increase eosinophills x-ray shows hyperinflation Likely diagnose is
A- Cystic fibrosis
B- Bronchial asthma
C- Hypersensitivity pneumonitis
D- Gastric aspiration
E- Aspergillosis
Ans: B

90- What pulmonary disease, most commonly associated with smoking, results in enlarged, overinflated lungs owing to the destruction of the alveolar walls with diminished elastic recoil seen in which of following
A- Asthma
B- Lung carcinoma
C- Emphysema
D- Pneumoconiosis
Ans: C

91- Diabetic mother presented with respiratory distress fetus should be given
A- Betamethasone
B- Promethasone
C- Momethasone
D- Dexamethasone
Ans: A

92- An alcoholic female presented with history of 4 kg weight loose in last few months,Temp 38.5 Pleuritic chest pain,Cough with Hemoptysis.On chest x ray b/l Perihilar finding was present.Her alveolar wash shows a few epitheloid cells.CBC shows: Neutrophils-78, Lymhocytes-8, Eosinophils-3. What is Probable Diagnosis?
A- Sarcoidosis
B- Hamartoma
C- TB
D- Pneumonia
Ans: C

Explanation:
Peri hilar lymphadenopathy and Epitheliod cells are Hallmark of TB.

93- A patient is diagnosed case of COPD (Chronic bronchitis) diagnostic feature histologically is
A- Hypertrophy and hyperplasia of mucus secreting glands
B- Atrophy of mucus secreting gland
C- Hypertrophy of serous glands
D- Atrophy of serous glands
Ans: A

94- Stony dull percussion note shows
A- Fluid in pleural cavity
B- Pneumonia
C- Simple pneumothorax
D- Spontaneous rupture of bulla
Ans: A

Explanation:
- Pleural effusion – Dull
- Atelectasis - Dull
- Simple pneumothorax- Hyperresonant
- Tension pneumothorax – Hyperresonant
- Consolidation (lobar pneumonia, pulmonary edema)- Dull

95- Asthmatic patient with RR 30/min dyspenic will have
A- Decrease airway entry
B- Increase $PaCO_2$
C- Decrease $PaCO_2$
D- Increase lung compliance
E- Decrease airway trapping
Ans: C

96- Type 1 respiratory failure occurs in all except
A- ARDS
B- Pneumonia
C- Drug over dose
D- Blunt chest trauma
Ans: C

97- Pneumonia causes which type of respiratory failure
A- Type1
B- Type2
C- Mixed
D- None
Ans: A

Explanation:

Type 1 Respiratory Failure(Hypoxemia and normal CO2	Type 2 Respiratory Failure(Hypoxemia and Hypercapnia)
Pulmonary embolism	COPD & Asthma
ARDS	Chronic bronchitis
Pneumonia	GB Syndrome
R-L Shunt	Ankylosing spondylitis
Pulmonary edema	Motor neuron dissease Drug overdose

98- A man had a cardiac transplant 1 month ago presents with fever and cough for the last five days. He gives history of using antibiotics for 6 months now with no improvement in symptoms. On CT chest he has left lower lobe basal consolidation and CT brain shows multiple abscesses in brain. Gram staining revealed normal flora. The most likely causative agent is
A- Aspergillus
B- Pneumocystis carini
C- Mycoplasma
D- Nocardia
E- Mycobacterium avium
Ans: D(FA)

99- 35-year-old bird keeper, presented withflu like illness, chest X Ray showsinfiltrates which organism is responsible
A- Chlamydia Psittacosis
B- Chlamydia Trachomatis
C- H. Influenza
D- Corynebacterium
Ans: A(FA)

100- In Histoplasmosis most commonly involved organ system is:
A- Renal
B- CVS
C- Respiratory
D- Reticulo endothelial system
E- CNS
Ans: D(FA+Robins)

101- A person working in cotton industry, is on risk of developing:
A- Farmers lungs
B- Byssinosis
C- Baggasosis
D- Silicosis
Ans: B

102- 10 year old boy presents with recurrentupper respiratory tract infections.History revealed that he also hadcomplained of chronic diarrhea andBronchiectasis Most appropriate testfor diagnose?
A- CBC
B- Duodenal biopsy
C- Sputum culture
D- Sweat chloride test
E- Jujenal biopsy
Ans: D

CamScanner

Explanation:
Cystic fibrosis has recurrent respiratory infection, otitis media, Diarrhea and Bronchiectasis so Sweat chloride test is done to diagnose Cystic fibrosis.

103- Asbestosis is related to which of thefollowing:
A- Kidney Cancer
B- Malignant Mesothelioma
C- Endothelial cancer
D- Bladder Cancer
E- Liver CA
Ans: B

Explanation:
- Smoking >Radon >Asbestose -Lung CA
- Asbestose cause -Lung CA >Mesothelioma

104- Absent Surfactant leads to Which of following
A- Decrease oxygen tension
B- Increase compliance
C- Decrease compliance
D- Decrease elastic recoil
Ans: C

Explanation:
- Surfactant normally decreases surface tension and Increase lung compliance

105- Farmer presented with chest pain and rightsided calcification cause is:
A- Abscess
B- Aspergillosis
C- Sarcoidisis
D- TB
Ans: B

106- On microscopy of lymph node, biopsy specimen, granuloma with caseous necrosis found for diagnosis of TB What should be looked for?
A- Coagulative Necrosis
B- Langhans Gaint Cells
C- Demonstration of AFB
D- Macrophage
E- Neutrophil
Ans: C

107- A 57-year-old Man working and smokers from long time having non-productive cough which worsened for past 2 months. Bilateral wheeze and having 5 cm mass in hilar region cause is:
A- Asbestosis
B- Smoking
C- Passive smoking
D- Silicosis
E- Radon exposure
Ans: B

Explanation:
- Smoking >Radon >Asbestose

108- The deficiency of surfactant in child will cause which of following:
A- Respiratory distress syndrome (RDS)
B- Emphysema
C- Pneumonia
D- Pulmonary Congestion
E- Pulmonary Embolism
Ans: A

109- A patient in RTA had head injury after which he has increase respiration and decrease respiration. This type of respiration is known as:
A- Cheyne stroke
B- Laboured
C- Hysterical
D- Kussmaul
E- Apnea
Ans: A

Explanation:
Chyne Stroke Breathing:
- Pattern of breathing characterized by rapid deeper and faster breathing followed by decrease breathing then stop (Apnea)

Causes:
- Trauma to Brain or Respiratory Centre
- Brain Tumor
- Heart Failure
- Kidney Failure

Kussmaul Breathing:
- Pattern of Breathing characterized by Deep too rapid Breathing to eliminate acid from Body

Causes:
- DKA
- Kidney Failure

110- A 45 year old previously normal lady start having dyspnea, dry cough, fever 3 months back Recovered for one month when she went on vacation. Again developed symptoms when she got back to her canaries. X-ray multiple nodular lesions in all lung zones. The mechanism of her symptoms was due to:
A- Antigen antibody mediated reaction
B- Progressive interstitial lung disease
C- Mast cell degranulation
D- Compliment mediated
Ans: A (Hypersensivity pneumonitis)

111- Definitive diagnosis of pneumonia is by which of following
A- Throat culture
B- Urine culture
C- Sputum culture
D- Gram staining
E- X-ray
Ans: C

112- End expiratory volume will be increased in?
COPD
A- Interstitial lung disease
B- Restrictive lung disease
C- Silicosis
D-
Ans: A

113- What is likely Cause of mesothelioma?
Cane fibres
A- Asbestosis
B- Silicosis
C- Ammonia
D- Sugar fibers
E-
Ans: B(FA+Pathoma)

114- Type 1 hypersensitivity reaction occurs due to eosinophils and this mechanism will occur due to:
A- Organic Dust
B- Inhaled dust
C- Liver Fluke
D- Silica
E- Asbestos
Ans: B

115- Which of following volume decrease in Asthma?
A- FRC
B- FEV1
C- FVC
D- Vital Capacity
Ans: B

116- A patient presented with chronic fever night sweats and cervical lymphadenopathy, epitheloid cells in sputum, CXR shows diffuse nodular opacities diagnose is:
A- Sarcoidosis
B- TB
C- Lymphoma
D- Infectious mononucleosis
Ans: B

117- Due to emphysema change occur in lung is:
A- Increase elastic tendency to lungs
B- Decrease elastic recoil tendency of lungs
C- Decrease stifness of lung
D- Increase Elastase in lung
Ans: B

118- Man working in ship craft develop which carcinoma?
A- Bronchiogenic carcinoma
B- Liver carcinoma
C- Malignant mesothelioma
D- Kidney carcinoma
E- Bladder carcinoma
Ans: A

119- A child previously having TB comes to you with the complain of fever and cough along with noisy breathing and difficulty in swallowing, now diagnosed as retropharyngeal Abscess, which structure it will invade first?
A- Pre cervical fascia
B- Prevertebral fascia
C- Carotid sheath
D- Buccopharyngeal fascia
Ans: B

120- A Tailor had TB infectiontransmitted to two of his familymembers mode of spread of this is:
A- Aerosolated air droplets
B- Blood
C- Blood transfusion
D- Sexual contact
E- Needle sticks injury
Ans: A

121- Person working in digging deep earth crust is prone to have:
A- Silicosis
B- Coal workers pneumoconiasis
C- Anthracosis
D- Asbestosis
E- Bysinosis
Ans: A

122- Child present with chronic Cough he took ATT for cough but cough not resolved. On examination clubbing anemia and Low BMI present. X-ray reveals Tram track sign likely diagnose is:
A- Chronic Bronchitis
B- Bronchiectasis
C- Pneumonia
D- Lung CA
Ans: B

Explanation:
- On X-ray Tram tract sign seen in Bronchiectasis and pulmonary edema.

123- Women with long-standing asthma and depressive disorder. Most likely immunological change:
A- Decrease cytokines
B- Increase cytokines
C- Decrease acute phase reactants
D- Increased lymphocytic proliferative response
Ans: D

CamScanner

124- Patient of cervical lymphadenopathy CXR shows bilateral hilar lymphadenopathy. Biopsy shows typical granulomatous necrosis of submandibular and sublingual glands diagnosis is:
A- TB
B- Syphilis
C- Leprosy
D- Sarcoidosis
Ans: D

125- A patient presented with fever, weight loss and tongue ulcer, cxr shows b/l hilar lymphadenopathy microscopy shows caseouS necrosis most suitable diagnose:
A- TB
B- Histoplasmosis
C- Wegener granulomatosis
D- Sarcoidosis
E- IgA Nephropathy
Ans: A

126- A Kid having cystic fibrosis developing recurrent chest infection and otitis media most likely associate findings:
A- Increase sweat chloride
B- Increase sodium
C- Decrease sweat chloride
D- Increase Blood Magnesium
Ans: A

127- Regarding the bronchial asthma the most probable finding will be?
A- FEVI reduces
B- FEVI increases
C- FRC increases
D- FEV1/FVC < 65%
Ans: D

128- A yound girl with difficulty in breathing, her vitals were fine except respiratory rate was increased. Nothing on auscultation.Sputum Result were negtive. On X-Ray There was hilar lymphadenopathy on right side and a nodular lesion in the middle lobe of the same side lung. What's the cause?
A- Mycobacterium tuberculosis infection
B- Hypersensitive pneumonitis.
C- Leprosy
D- Infective endocarditis
Ans: B

129- Which will not be present in a lung hamartoma?
A- Coin lesion on x ray chest
B- Cartilage in lesion area
C- Well define
D- Nodules
Ans: B
Explanation:
- It is well define and has nodules

130- Indication for endo bronchial intubation:
A- Large Tongue
B- Large Head
C- Short Neck
D- Long Neck
E- Short Head
Ans: C

131- Pulmonary vasoconstriction occurs due to:
A- Hypoxia
B- CO_2
C- Edema
D- Decrease pulmonary pressure
Ans: A

132- A young man of 30 years having Kyphoscoliosis in which respiratory muscle weakness observed decrease respiration result due to which of these?
A- Decrease vital capacity
B- Increase FRC
C- Hypercapnia
D- Oxyhaemoglobin
Ans: A

133- In weather changes and asthmatic have cough which receptors involved?
A- Peripheral chemoreceptors
B- Stretch receptors
C- Nociceptors
D- Central chemoreceptors
E- Irritant receptors
Ans: E

134- A mother has child of 10 year diagnosed with meneigititis and now she ask that another 2 child 4 and 6 year old are at risk of the meningitis. Tell her the route of spread of infection:
A- Airborn
B- Oral
C- Respiratory droplet
D- Blood

135- Antibodies against calcium channel form in:
A- Myasthenia
B- Lambert Eaton syndrome
C- Cushing Disease
D- Addison disease
Ans: B

136- A female presented with isolated lung mass in periphery of right lung?
A- Bronchogenic carcinoma
B- Small cell carcinoma
C- Adenocarcinoma
D- Clear cell carcinoma
Ans: C

137- Type 2 pneumocytes deficiency in infant's causes:
A- Meconium aspirations
B- Respiratory distress syndrome
C- Neural tube defects
D- Congenital diaphragmatic hernia
Ans: B

138- The stimulus for pulmonary vasoconstiction is:
A- Increase PaO_2
B- Decrease PaO_2
C- Increase O_2
D- Decrease O_2
Ans: B
Explanation:
- Pulmonary Vasoconstriction due to – Low Alveolar O2 >Low Systemic O2 (Guyton)
- Pulmonary Vasoconstriction Accentuated by – Increase CO_2 (Guyton)

139- 9 yrs old girl presented to you with the complain of sob, on auscultation chest was clear, no murmor ,gallop ,c-xay shows hilar lymphadenopathy and 1cm nodule in right middle lobe ,no infilterations no mass, sputum and blood tests are also negative, dx?
A- Infectious endocsrditis
B- Arterial myxoma
C- Mycobacterium tuberculosis
D- Carcinoid tumor
Ans: D

140- Which is characteristic of sarcoidosis in female?
A- Hepatic granuloma
B- Erythema nodosum
C- Erythema Granulosum
D- Hypercalcemia
Ans: B(Davidson)

141- Alpha 1 anti-trypsin deficiency is:
A- Autosomal recessive
B- Autosomal Dominant
C- X linked Recessive
D- X linkes Dominant
Ans: A

142- 15 year Gardner with history of chestpain, no other symptoms, X-Ray was done which showed Round mass which is calcified?
A- Aspergillus
B- Tuberculosis
C- Sarcoidosis
D- Hydatid
Ans: A

143- Thymoma is associated with myasthenia gravis. What other disease is associated with it?
A- Pure Red Cell Aplasia
B- Aplastic Anemia
C- Eaton Lambort Syndrome
D- Megaloblastic Anemia
Ans: A

144- Female with cervical lymphadenopathy histology showed granulomatous diagnosis of TB is strongly suggested due to:
A- Montoux test
B- IgE test
C- Tensilon test
D- None
Ans: A

145- A patient having cervical lymphadenopathy is suspected as having TB, which of the followingwill most likely give diagnosis of TB?
A- Giant cell
B- Montoux test
C- X-ray chest
D- Caseous necrosis
Ans: D

146- L-S ratio of amniotic fluid represents the function of:
A- Fetal Heart
B- Fetal lungs
C- Fetal Kidney
D- Fetal Liver
Ans: B

147- Lung pressure volume test in emphysema will show:
A- Decrease lung volumes
B- Increase lung volume
C- Decrease Trans pulmonary pressure
D- Increases Trans pulmonary pressure
Ans: B

CamScanner

148- A patient who was admitted to ahospital and Got operated. On 8th post-operative day he suddenly developed dyspnea most likely pathology will be:
A- Pulmonary edema
B- Pulmonary embolism
C- Amniotic Fluid embolism
D- Septic shock
E- Air Embolism
Ans: B

Explanation:
- Air Embolism – History of Passing CVP then SOB
- Pregnant lady + Long bone fracture +Died on way to hospital within 24h orduring labour – Amniotic fluid embolism
- Sudden death + Sudden SOB – PulmonaryEmbolism
- Long bone fracture – Death after 3-5 days– Fat embolism

149- The ectopic thyroid hormone issecreted by:
A- Small cell carcinoma of lung
B- Large cell carcinoma of lung
C- Carcinoid of lung
D- Adenocarcinoma of lung
E- Squamous cell carcinoma of larynx
Ans: E

Explanation:
- **Small Cell CA** – Smoking + Most aggressive + Ectopic ACTH (Cushing syndrome) + Lambert Eaton syndrome + SIADH.
- **Squamous Cell CA** – Smoking (Most commonly)+ Hypercalcemia
- **Ectopic thyroid** produce by – Squamous Cell CA of Larynx

150- A Kid with sweat chloride test positivedeveloping recurrent chest infectionand otitis media likely due to associated: (med feb)
A- Asthma
B- Bronchiectasis
C- Emphysema
D- Decrease Surfactant
E- Pleural effusion
Ans: B

151- Increase lymphocyte can be seen in
A- Bacterial infection
B- Fungal infection
C- TB
D- Pus formation
Ans: C

152- If the sympathetic nerve supply of urinary bladder is cut following happens
A- Difficulty in passing urine
B- Decreased bladder tone and relax spincter
C- Increased frequency
D- Retrograde ejaculation
Ans: D

Explanation:
- Sympathetic normally prevent outflow of semen into bladder when cut then retrograde ejaculation will happen

153- A patient presented to you with pleural effusion he is dyspenic and weak and has pedal edema , his pleural effusion aspirates was taking and labeled as transudative fluid On what findings this fluid is called transudative
A- Increase cell count
B- Increase protein
C- Decrease cell count
D- Increase LDH
Ans: C

154- Which of the followingparaneoplastic syndrome isassociated with Oat cell carcinomaof lungs?
A- ACTH
B- Insulin
C- Glucagon
D- Androgen
E- Erythropoeitin
Ans: A

155- 13 year young patient admitted in emergency with complain of dysnea and diarrhoea Clubbing present on examination What is ur diagnosis?
A- Asthma
B- Cystic fibrosis
C- Hereditary newborn syndrome
D- Lung hemartoma
Ans: B

156- A man after RTA with excessiveblood loss hypotensive kept inventilatory support PEEP given with100% FIO2 5 days later patientdied on examination of lungs therewas hyaline streaks with increasednumber of macrophage and fewneutrophils likely cause:
A- Diffuse alveolar damage
B- Patchy atelactasis
C- Fibrosis
D- Tension Pneumothorax
E- Bronchopneumonia

157- A patient has LRTI for many days. On histology os respiratory tree which of the following will be damaged.
Microvilli
A- Cilia
B- Plasmalemma Protein
C- Desmosome
D- Hemidesmosome
E- B
Ans: B

158- Young man with heart failure, b/l pleural effusion, in plural tap low protein content what type of fluid is
Serous
A- Fibrinous
B- Exudative
C- Transudative
D- Opague
E- D
Ans: D

159- A patient presented with worsening pneumonia associated with the production of large quantities of red-brown sputum. Chest X-ray shows a cavity in the right upper lobe with a fluid level. What is the most likely infection:
A- Streptococcus Pneumonia
B- Legionella Pneumonia
C- Heamophilis Pneumonia
D- Klebsiella
E- Chlamydia Pneumonia
Ans: D

160- A patient after RTA having SOB and Respiratory distress and then died on autopsy pulmonary infarct was found history of femur fracture 4 days back what is your diagnosis?
A- Air embolism
B- Thromboebolism
C- Marrow embolism
D- Amniotic Fluid embolism
Ans: C(Fat or Marrow embolism)

161- Primary TB focus consists of
A- Healed lymph node
B- Healed pulmonary focus
C- Calcified lymph node
D- Calcified pulmonary focus
E- Parenchymal focus and lymphatics
Ans: D

162- An Old man with non-productive cough, Xray shows lower lobe round lesion, afebrile, antibiotics given, but no improvement, same xray findings, bronchioalveolar lavage done, atypical cells with scattered macrophages Diagnose is
A- TB
B- Sarcoidosis
C- Bronchoalveolar CA
D- Pneumonia
Ans: C

163- A 26 year male presented to you in surgical ER after penetrating injury to right lateral chest on examination when he inspire the mediastinum moves to left side and during expiration the shift towards left side is enhanced what will be the most likely diagnose
A- Open pneumothorax
B- Haemothorax.
C- Tension pneumothorax.
D- Pleurisy
Ans: C

164- A patient known case of copd When he walks to 100 m he has to stop to take breath MRC grading of his condition is
A- Grade 1
B- Grade 2
C- Grade 3
D- Grade 0
Ans: C

Explanation:
- **Grade 0** - Dyspnea on Strenous exercise
- **Grade 1** - Dyspnea while going uphill or hurrying on the level
- **Grade 2** - Walk slower than people of same age or Has to stop to take breath during normal pace walking
- **Grade 3** - Stop to take breath after 100m distance
- **Grade 4** - Dyspnea while dressing or undressing or leaving home

165- Patient has choking history present with fever onxray inferior right lung lobe opacity seen with pulled hilumof lung slightly down how to confirm diagnosis:
A- CT scan
B- Bronchoscopy
C- Sputum Culture
D- Gastric lavage
E- Thoracotomy
Ans: B

CamScanner

166- A man is a construction worker , demolishes the building, has developed cough , dyspnea pleural plaque cause is:
A- Silica
B- Asbestosis
C- Byssinosis
D- Anthracosis
E- Siderosis
Ans: B

167- A middle age Male patient presented to opd with cough and dyspnea, he has increase level of sputum production upon doing investigation lab found curshman spirals and charcot leyden crystal in mucus. He is labeled as:
A- Bronchiectasis
B- Pneumonia
C- Aspiration pneumonia
D- Asthma
A- Embolism
Ans: D

168- Asbestos and tobacco smoking can cause
A- Bladder carcinoma
B- Bronchogenic carcinoma
C- Lymphoma
D- Malignant mesothelioma
E- Liver carcinoma
Ans: B (FA)

169- Pressure at 10cm of water by PEEP for 24 hrs would cause:
A- Spontaneous Pneumothorax
B- Pulmonary embolism
C- Raised O_2 saturation
D- Raised PCO_2
E- Alveolar damage
Ans: A

170- In Tb induration is about:
A- 5mm
B- 10mm
C- 15mm
D- 20mm
Ans: C

171- A female with 2 days history of SOB. There is bluish discoloration of lips and hands. What investigation should be done
A- ECG
B- Echo
C- ABGs
D- HB
Ans: C

172- Restrictive lung disease, onspirometery finding will be
A- FVC Increase
B- FEV1 Decrease
C- FEV1/FEV Decrease
D- TLC Increase
Ans: B

173- Child while supine with Peanutaspiration will lodge in
A- Apical segment of Right lower lobe
B- Right upper lobe
C- Right posterior lobe
D- Left Posterior lobe
Ans: A (FA+Grey'anatomy)

Explanation:
- Foreign body in **supine** – Apical(Superior) segment of right lower lobe.
- Foreign body in **sitting/standing(Upright)** – Posterior basal segment ofright lower lobe.
- Foreign body in **right lateral** – Posteriorsegment of right upper lobe.
- Foreign body in **left lateral** – Inferiorlingular of left upper lobe

174- Which of the followingparaneoplastic syndrome isassociated with small cell carcinomaof lung?
A- Cushing syndrome
B- Hyperparathyroidism
C- Addison_s disease
D- Pheochromocytoma
E- Zollinger ellison_s syndrome
Ans: A

Explanation:
- **Small Cell CA** – Smoking + Mostaggressive + Ectopic ACTH (Cushingsyndrome) + Lambert Eaton syndrome+ SIADH.
- **Squamous Cell CA** -Smoking +Hypercalcemia(PTHrp)
- Ectopic thyroid produce by –Squamous Cell CA of Larynx

175- Engineer working in Construction presented with pleural plaques.FVC decreased and FEV1/FVC normal diagnosis is
A- Silicosis
B- Anthracosis
C- Asbestosia
D- Fibrosis
E- Asthma
Ans: C

176- A patient after trauma all muscles of abdomen and chest paralysed stop breathing which level injury occur?
A- C4
B- Below C5
C- T4
D- T12
Ans: B

177- Tb is involved in
A- Schouman bodies
B- Churshman spiral
C- Hypersensitivity
D- Aschoff bodies
Ans: C

178- If patient has decrease FEV1 decrease FRC decrease FVC and has chronic cough with dyspnea which is related to
A- Chronic bronchitis
B- Pulmonary interstitial fibrosis
C- Asthma
D- Pneumonia
Ans: A

179- The most common presentation of carcinoid syndrome is
A- Dyspnea
B- Diarrhea
C- Tachycardia
D- Cutaneous flushing
E- Facial telangiectasia
Ans: D

180- A patient has lung CA calcification and nodule. What will be the characteristic of it?
A- Lamellar
B- Eccenteric
C- Nodular
D- Cresenteric
Ans: B

181- A smoker patient present with interstitial lung disease and pleural plaques cause?
A- Smoking
B- Asbestos
C- Silicosis
D- Anthracosis
Ans: B

182- A young man presented with chest pain and dyspnea physician advised xray chest, which part is costocartilaginous in x-ray chest?
A- Manubrosternal joint
B- Costochondral joint
C- Sternoclavicular joint
D- Xphisternum
Ans: B

183- In patient with emphysema, which of the following is appropriate:
A- Decreases TLC
B- Increased TV
C- Increased lung volume
D- Decreases RV
Ans: C

184- Which condition is related to Eosinophilia
A- TB
B- COPD
C- Asthma
D- Silicosis
Ans: C

185- Byssinosis is related to;
A- Cotton industry
B- Sugar cane
C- Smoking
D- Carbon particles
Ans: A

186- Giant cell type in TB:
A- Langerhan
B- Histiocyte
C- Dendritic
D- Langhan
Ans: D

187- Which of the followings is elevated in nasal polyps?
A- Macrophages
B- Neutrophils
C- Monocytes
D- Eosinophil
Ans: D

188- Patient had cough and x-ray shows hilar lymphadenopathy, non caseating granuloma and hypercalcemia present diagnose is:
A- Sarcoidosis
B- TB
C- Syphlis
D- Leprosy
Ans: A (Robins)

189- A Patient after Gastric content in supine position aspiration will lodge in which of following lobe
A- Right lower lobe
B- Right upper lobe
C- Right posterior lobe
D- Left Posterior lobe
E- Left Upper lobe
Ans: A (FA + Grey'anatomy)

Explanation:
- Foreign body in supine – Apical(Superior) segment of right lower lobe.
- Foreign body in sitting/standing(Upright) – Posterior basal segment ofright lower lobe.
- Foreign body in right lateral –Posterior segment of right upper lobe.
- Foreign body in left lateral – Inferiorlingular of left upper lobe

CamScanner

190- A patient of asthma came in ER his FEV1/FVC ratio is less than 65%. All initial treatment given what will be resultant increase in Ratio after treatment
A- 5%
B- 12%
C- 15%
D- 20%
E- 10%
Ans: B (Davidson)

191- All spirometry values go down in which disease
A- Asthma
B- Fibrosis
C- ILD
D- Restrictive lung disease
Ans: B

192- ACTH producing tumor is:
A- Oat cell Carcinoma
B- Alveolar cell carcinoma.
C- Squamous cell carcinoma
D- Adenocarcinoma
E- Large cell carcinoma
Ans: A

193- A patient has low grade fever, cough and bilateral hilar lymphadenopathy. Which findings will be present on Microscopy?
A- Granuloma with asteroid bodies
B- Non caseating granuloma
C- Granuloma with abscess formation
D- Caseating granuloma
E- Macrophages
Ans: B (Robins)

194- A Man given hyperbaric oxygen for 24 hours now liable to:
A- Pulmonary edema
B- Tension pneumothorax
C- Spontaneous pneumothorax
D- Pulmonary embolism
Ans: C

195- Giant Cell in TB are composed of:
A- Neutrophils
B- Activated Macrophages
C- Monocytes
D- Lymphocytes
E- Plasma Cells
Ans: B

196- In restrictive lung disease what will increase
A- FVC
B- Vital capacity
C- Airway resistance
D- Lung volume
Ans: C

197- A patient with recurrent wheezing nasal congestion runny nose and fever every April due to degranulation of?
A- Mast cells
B- Basophils
C- Neutrophils
D- Monocyte
Ans: A

198- Painter having headache and coughing only releive on Sunday this is likely
A- COPD
B- Bronchitis
C- Occupational asthma
D- Pneumonitis
Ans: C

199- Patient is having history of smoking and has barrel shaped chest what is the cause
A- Asthma
B- COPD
C- Emphysema
D- Bronchitis
Ans: C

200- Most common cause of pyogenic lung abscess:
A- Staph Aureus
B- E.Coli
C- Streptococcus Pneumoniae
D- Klebsiella
E- H influenza
Ans: A

201- Pulmonary disease patient with cough and 0.5 cm perihilar nodule and on microscopy eosinophil both inside and peripheral Most likely cause is
A- Non invasive Aspergillosis
B- Wegener granulomatosis
C- Candidiasis
D- Blastomycosis
E- Pneumonia
Ans: A

202- A patient with Bronchial obstruction having PCO2 53 PaO2 57 PH 7.3 HCO3 26:
A- Type 1 Respiratory failure
B- Type 2 Respiratory failure with metabolic acidosis
C- Type 2 resporatory failure with uncompensated respiratory acidosis
D- Type 1 Respiratory failure with metabolic acidosis
Ans: C

203- Patient having dyspnea but no sputum production. Lung volume increased and there are emphysematous lesion likely cause is
A- COPD
B- Alpha 1 antitrypsin deficiency
C- CO deficiency
D- Penumonitis
Ans: B

204- FEV1 and FVC preserved in:
A- Asthma
B- COPD
C- Interstitial lung disease
D- Fibrosis
Ans: C

205- In case of ARDS the ventilation is hampered as result of interstitial edema due to:
A- Increased capillary permeability
B- Increased Hydrostatic pressure
C- Decrease capillary permeability
D- Decrease oncotic pressure
Ans: A

206- In Pnemothorax:
A- Chest Outward
B- Chest Inward
C- Lung inward and Chest wall outward
D- Chest wall inward and lung outward
Ans: C

207- During Acute asthmatic attack which test will you perform?
A- Tidal volume
B- FEV1
C- Arterial PO2
D- FRC
Ans: B

208- Premature baby born has lung not fully developed leads to:
A- ARDS
B- Abdominal muscle paralysis
C- IBS
D- RA
Ans: A

209- Patient had Cough and has epithelioid granuloma without necrosis diagnose is:
A- Sarcoidosis
B- TB
C- Syphlis
D- Leprosy
Ans: A

210- Squamous cell lung CA common site:
A- Periphery
B- Carina
C- Hilum
D- Bronchi
Ans: B

211- A patient has depressed nasal bridge and non caseating granuloma likely cause is:
A- TB
B- Silicosis
C- Sarcoidosis
D- Leprosy
E- Asbestosis
Ans: D

212- A patient abdominal surgery done now he developed pulmonary infarction due to?
A- Pulmonary embolism in large artery
B- Pulmonary embolism in Medium artery
C- Pulmonary embolism in small artery
D- Pulmomary embolism of all arteries
Ans: B

213- Hyaline disease most important etiology is?
A- Late birth
B- Prematurity
C- Genetical disease
D- Obstetrics complications
E- Chemical
Ans: B

214- Patient is having history of smoking and has decreased gaseous exchange what is the cause?
A- Asthma
B- COPD
C- Emphysema
D- Bronchitis
Ans: C

215- In COPD diagnosis will be made by:
A- V/Q = 0.1
B- V/Q = 1.0
C- Physiologic dead space
D- Shunt
E- V/Q infinite
Ans: A

CamScanner

216- Regarding the bronchial asthma themost probable finding will be?
A- RR 12
B- Tidal volume 500
C- FRC increases
D- FEV1/FVC <75%
E- Arterial PO2 40mmhg
Ans: D

217- Which one of the following will be seen in restrictive lung disease?
A- Decreased lung compliance with decreased FEV/FVC
B- Decreased lung compliance with increased FEV/FVC
C- Increased lung volume
D- Bronchial obstruction
E- Increased FRC
Ans: B

218- 10 year old boy presents with recurrent upper respiratory tract infections. History revealed that he also had complained of chronic diarrhea and Bronchiectasis. What findings will be There?
A- K more than normal healthy person
B- Cl more than normal healthy person
C- Na more than normal healthy person
D- Cl less than normal healthy person
Ans: B

219- Common feature between sarcoidosis & Tb is
A- Restrictive lung disease
B- Consolidation
C- Granulomatous hepatitis
D- Caseous necrosis
Ans: C

220- Baby born at 24 weeks with respiratory distress syndrome. Which of the following is correct regarding this condition
A- Lecithin Sphingomyelin ratio 2:1
B- Alveolar collapse
C- Decreased Surface tension
D- Increases Lung compliance
Ans: B

221- A patient having presented with disoriented state. His Hb is 5.6g/dl & Po2 is 96%. Type of hypoxia is:
A- Anemic hypoxia
B- Hypoxia hypoxia
C- Cellular hypoxia
D- Histotoxic hypoxia
Ans: A

222 Emphysema Decreases lung compliance bycausing:
A- Destruction of alveolar septa
B- Inflammation
C- Fibrosis.
D- Scarring
Ans: A

223- Pakistani student got scholarship for abroad for which he is required MTB test . How are Tb macrophages different from normal macrophages
A- Pain mediation
B- Phagocytosis
C- Secretory
D- dhesive
E- Cytokine
Ans: B

224- Alternobaric vertigo in divers is due
A- Unequal pressure in middle ear during ascent
B- Unequal pressure in middle ear descent
C- Perforation of tympanic membrane
D- Equal pressure in outer ear during ascent
E- Barotrauma
Ans: A

225- Upper lobe consolidation is related to
A- Asbestosis
B- Amidarone
C- Tb
D- Asthma
Ans: C

226- Total layers prieced by a Stab wound before touching lung parenchyma are?
A- 5
B- 6
C- 7
D- 8
E- 9
Ans: D

227- Increased Ventilation perfusion ratio is seen in which of the following conditions?
A- Pneumothorax
B- Pleural effusion
C- Airway obstruction
D- Shunt
E- Pulmonary embolism
Ans: E

228- Paraneoplastic syndrome is caused by which of the following
A- Small cell carcinoma of lung
B- Renal cell carcinoma
C- Carcinoid
D- HCC
E- Melanoma
Ans: A

229- In asthma which one increases
A- FRC
B- FEV1
C- VC
D- TLC
Ans: A(BRS)

230- A patient has chronic cough, to mark him as patient of chronic bronchitis what finding should be present
A- Squamous metaplasia
B- Hyperplasia of mucous gland(cells)
C- Narrowing of Bronchioles
D- Dysplasia
E- Shrinkage of Alveoli
Ans: B
(Better statement but repeated)

231- A man inhaling silica dust for 6 years due to his job. Developed cough.1cm mass in x-ray was present .What cells may be seen in his lungs:
A- Foreign body giant cell
B- Eosinophils
C- Lymphocytes
D- Silicosis
Ans: A

232- Regarding right side open pneumothorax with penetrating injury true is
A- Mediastinum shifts towards right
B- Atmospheric and pleural pressures becomes equal
C- V/q ratio increases
D- Hyperinflation of left lung
Ans: B

233- A patient with Decrease FEV1, FVC and ratio in which of following?
A- Asthma
B- Chronic bronchitis
C- Bronchiectasis
D- Sarcoidosis
Ans: A

234- Bysinnosis occurs because of:
A- Sugarcane dust
B- Grain dust
C- Cotton dust
D- Tobacco
Ans: C better

235- A patient has cervical lymph nodes. Biopsy shows non caseating granuloma and is AFB positive.Which of the following is most probably the diagnosis?
A- TB
B- Cat scratch disease
C- Leprosy
D- Sarcoidosis
Ans: C

236- A Farmer with exposure to mouldy hay dust rushes in ER with breathlessness. X rays findings show bilateral infiltrates in upper lungs.Most likely cause:
A- Aspergillus Fumigatus
B- Histoplasmosis
C- Coccidiomycosis
D- Mucormycosis
Ans: A

237- An alcoholic female presented with Cough, dyspnea from 2 weeks, Weight loss & hemoptysis. Transbronchial biopsy done, what will be the findings?
A- Cells with increased N/C ratio and scanty cytoplasm
B- Pleomorphic Cells with dark staining and angular nuclei
C- Liver Metastasis
D- Atrophy of Hepatocytes
Ans: A

238- Patient with SOB, having FEV1 2.1 and FVC2 2.9, Actual Vomax 19.1(normal), vemax 34 after exercise stress test. Where is the pathology. Spo2 is normal at room air but decrease to 89%. Cause?
A- Pulmonary vascular disease
B- Restrictive diseases
C- Obstructive lung disease
D- ARDS
E- Normal test
Ans: C

239- Parapneumonic effusion of lobar pneumonia has:
A- LDH greater than 100
B- Protein greater than 3.5
C- Specific gravity greater than 1.003
D- Eosinophils
Ans: B

240- What pulmonary disease, most commonly associated with smoking, results in enlarged, overinflated lungs owing to the destruction of the alveolar walls with diminished elastic recoil ?
A- Asthma
B- Lung carcinoma
C- Emphysema
D- Pneumoconiosis
Ans: C

CamScanner

241- Patient had respiratory symptoms and has lymphatics , blood vessels and epithelioid granuloma without necrosis diagnose is:
A- Sarcoidosis
B- TB
C- Syphlis
D- Leprosy
Ans: A

242- A patient with pulmonary fibrosis what will be seen in patient lung
A- Decrese lung diffusing capacity
B- Increase resistance
C- Increase tidal volume
D- Decrease FEV1
Ans: A

243- Old lady admitted for two weeks for femure fracture. She had pain and tender on palpation then suddenly develop dyspnea. What will be further complication leading to this
A- Hematoma of thigh
B- Pulmonary thromboembolism
C- Sarcoma
D- Neoplasia
Ans: B

244- A patient has no history of fever & cough but Fibrosis seen on XRAY. Cause?
A- Inorganic dust
B- Histoplasmosis
C- Silicosis
D- Asbestosis
E- Bysinossis
Ans: A
Explanation:
- Grain Dust – Farmer Lung
- Aspergillosis – Farmer lung with Granuloma, rhino sinusitis, medial eroision and calcification of lung
- Inorganic dust – Diffuse lung fibrosis on X-ray without fever or Cough
better

245- Capnometer is used to measure end tidal CO2, other possible use of this device?
A- Indicator of Air embolism
B- Indicator of Fat Embolism
C- Measure oxyhb conc
D- Measure sat of CO2
E- Ultraviolet analyzer
Ans: A

246- Kartagener's Syndrome involves which of these:
A- P53
B- Spectrin
C- Dynein Arms
D- Centrioles
E- KRAS
Ans: C(Robins)
better

247- A patient with COPD and a history of smoking presents with pulmonary hypertension. Which of the following is the primary cause of pulmonary hypertension in this context?
A- Hypoxia
B- Vascular dilation
C- Hypercapnia
D- Left-sided heart failure
E- Increased pulmonary venous pressure
Ans: A

248- Which of the following is a characteristic feature of a tuberculosis ulcer?
A- Raised margins
B- Undermined edges
C- Rolled margins
D- Shiny surface
E- Punched-out appearance
Ans: B

249- A boy had a car accident after which he is bed ridden. He develops DVT He came to ER with chest pain and dyspneA- What will be the findings?
A- Increase PO2
B- Ventilation perfusion mismatch
C- Increase pcO2
D- Decrease pO2
Ans: B

250- A boy was continuously inhaling and exhaling into a paper bag for several minutes despite being advised not to. After 5 minutes, his colleagues noticed that his face was red and he was hyperventilating. What is the most likely cause of this condition?
A- Decrease O2 in the blood
B- Increase CO2 in the blood
C- Increase in bicarbonates
D- Decrease in Ph
Ans: B

251- In a patient with asbestosis diagnosed as a restrictive lung disease, what is the expected change in pulmonary function tests (PFTs)?
A- FEV1/FVC ratio decreases
B- FEV1/FVC ratio increases
C- FVC decreases with no change in FEV1
D- FEV1 increases with no change in FVC
E- Both FEV1 and FVC increase equally
Ans: B

252- Patient has complaint of Polyuria but blood glucose level and ADH are normal cause is
A- Nephrogenic DI
B- Central diabetes insipidus
C- SIADH
D- ADH deficiency
Ans: A

253- A Man smoke 20 packs per month work in factory he develops lung cancer which carcinogen in Cigarette cause lung cancer:
A- Nitrosamines
B- Polyaromatic hydrocarbons
C- Vinyl chloride
D- Azo dye
E- Arsenic
Ans: B
Explanation:
- Angiosarcoma in plastic factory worker – Vinyl chloride
- Angiosarcoma in farmer – Arsenic
- Plastic factory worker – Liver Angiosarcoma
- Plastic factory worker + Smoking – Lung CA > Angiosarcoma
- Hydrocarbon (tyre factory) + Aromatic Amines – Bladder CA
- Smoking + Hydrocarbon – Lung CA > Bladder
- Liver CA –Acohol >Aflatoxin > Smoking
- Transitional bladder CA – Smoking > Amines > Hydrocarbon
- Squamous cell bladder CA – Schistostoma > Stones > Indwelling catheter

254- A diabetic patient after cholecystectomy developed dyspnea, most likely pathology will be:
A- Pulmonary edema
B- Pulmonary embolism
C- Amniotic Fluid embolism
D- Septic shock
E- Air Embolism
Ans: B
Explanation:
- Air Embolism – History of Passing CVP then SOB
- Pregnant lady + Long bone fracture + Died on way to hospital within 24h or during labour – Amniotic fluid embolism
- Sudden death + Sudden SOB – Pulmonary Embolism
- Long bone fracture – Death after 3-5 days – Fat embolism

255- Three days after cholecystectomy, a patient experiences pain, dyspnea, and hemoptysis. What is the most likely diagnosis?
A- Pneumothorax
B- Pulmonary embolism
C- Acute bronchitis
D- Pleural effusion
E- Postoperative atelectasis
Ans: B

256- Squmous cell carcinoma occur in which part of lung
A- Lower part of left bronchus
B- Upper part of right /left bronchus
C- Upper part of right bronchus
D- Central part of right/left bronchus
Ans: D

257- Patient had respiratory symptoms and has lymphatics , blood vessels and epithelioid granuloma without necrosis diagnose is:
A- Sarcoidosis
B- TB
C- Syphlis
D- Leprosy
Ans: A
Better

258- A Patient presented with chronic smoking.Small cell carcinoma of lung confirmed on Biopsy) What will be secreted from oat cells?
A- ACTH
B- Insulin
C- Glucagon
D- Androgen
E- Erythropoeitin
Ans: A

CamScanner

259- A patient presented with the Chronic fever , Night sweats Headache , Lethargy , Weight loss And Cervical Lymphadenopathy Epitheloid cells in sputum. CXR shows diffuse nodular opacities in apical lobe. Which type of Necrosis is seen in enlarged lymph nodes in this scenario?

A- Sarcoidosis
B- TB
C- Lymphoma
D- Infectious mononucleosis
Ans: B

260- A patient presents with reduced lung volumes and reduced FEV1. What type of defect is most likely?

A- Alveolar
B- Interstitial
C- Extrathoracic
D- Intrathoracic
Ans: B

Explanation:
Reduced lung volumes and FEV1 are characteristic findings of **restrictive lung disease**, which is commonly associated with interstitial lung diseases. These conditions affect the lung parenchyma, leading to fibrosis, stiffness, and reduced compliance, resulting in reduced lung volumes

261- Patient with prolong hx of dust exposure, decreased CO diffusion. FEV1/FVC is preserved along with decreased Total Lung capacity. Area involved?

A- Alveolar
B- Interstitium
C- Lobule
D- Alveoli
Ans: B

262- Restrictive lung disease is different from obstructive lung disease by:

A- FEV1 is normal in obstructive diseases
B- FEV1/FVC increased
C- FEV1/FVC decreased
D- FVC is reduced less than FEV1
Ans: B

263- People with coal- workers' pneumoconiosis are predisposed to developing which disease?

A- Tuberculosis
B- Carcinoma of the lung
C- Progressive massive fibrosis
D- Silicosis
E- Heart failure
Ans: C

264- A 15 years old child came in ER with complain of dyspnea & cough along with Wheezing& Whistling sounds. He is completing sentences in one breath. His vitals are: Heart rate >110, Respiratory Rate is 30.O/E.. On auscultation, Chest is Silent. What is the most probable diagnosis?

A- Pneumothorax
B- Emphysema
C- Bronchial asthma
D- Acute exacerbation of COPD
Ans: C

265- A patient came in ER with Respiratory difficulty along with wheezing. Spirometry shows Reduced FEV1. What is the most probable diagnosis?

A- Bronchitis
B- Emphysema
C- Asthma
D- Fibrosis
Ans: C

266- A Military patient came with complain of cough not improving. He was refer to pulmonologist who ordered a spirometry that revealed decreased FEV1 , decreased FVC & decreased FRC. Most probable diagnosis:

A- Asthma
B- Pulmonary fibrosis
C- Emphysema
D- Pneumonia
E- Bronchitis
Ans: B(BRS Physio)

267- A child known case of cystic fibrosis presented with acute respiratory infection, on investigation the organism diagnosed as pseudomonas aeuroginosa what are the other findings associated with this patient

A- Bronchial asthma
B- Bronchiectasis
C- Emphysema
D- Pulmonary Fibrosis
E- Adenocarcinoma
Ans: B

268- Which factor sees a decrease in restrictive lung diseases?

A- FEV1/FVC
B- Compliance
C- FRC
D- FVC
E- FEV1
Ans: C(FA+Pathoma)

Explanation:
Obstructive vs Restrictive

Feature	Obstructive Disease (Asthma & COPD)	Restrictive Disease (Fibrosis)
FEV1	Decrease++	Decrease+
FVC	Decrease+	Decrease++
FEV1/FVC	Decrease	Normal or Increase
FRC	Increase	Decrease

269- A patient presents to the OPD with respiratory distress. Sputum analysis reveals eosinophilia. What is the most likely diagnosis?

A- Aspergillosis
B- Cystic fibrosis
C- Bronchial asthma
D- Hay fever
E- Parasitic Infection
Ans: C

270- A soldier presents with persistent cough. On physical examination and pulmonary function testing FEV1 & FVC Decreased. What is the most likely diagnosis?

A- Pulmonary Fibrosis
B- Chronic Bronchitis
C- ILD
D- Asthma
Ans: B

270- A morbidly obese patient is undergoing a general anesthesia (GA) assessment. What are the key considerations?

A- Decreased FRC
B- Increased compliance
C- Increased TLC
D- Increased inspiratory peak volume
E- Decreased inspiratory peak volume
Ans: A

Explanation:
- **Morbid obesity** significantly affects respiratory mechanics due to increased chest wall and abdominal fat, leading to reduced lung compliance and limited diaphragmatic movement.
- **Functional Residual Capacity (FRC)**, which is the volume of air remaining in the lungs after a normal exhalation, is decreased due to increased intra-abdominal pressure and restricted lung expansion

271- A Chronic smoker presents with cyanosis due to which of the following

A- Increase conc: of Oxygenated hb
B- Increase conc: of deoxygenated hb
C- Decrease conc: of deoxygenated hb
D- Polycythemia
Ans: B

272- A 79 year old patient presented with dyspnea there was no cough and sputum a lesion was noted in the lungs with increase spindles invading the smooth muscles most likely due to inhalation of

A- Silica
B- Cotton dust
C- Asbestosis
D- Coal dust
Ans: C

273- A patient 's spirometry values are. Reduced Functional Residual Capacity (FRC), Forced Expiratory Volume in 1 second (FEV1), and Forced Vital Capacity (FVC). What is the most likely diagnosis?

A- Asthma
B- Pneumonia
C- Pulmonary Fibrosis
D- Chronic Obstructive Pulmonary Disease (COPD)
Ans: C

Explanation:
Obstructive vs Restrictive

Feature	Obstructive disease (asthma & copd)	Restrictive disease (fibrosis)
Fev1	Decrease++	Decrease+
Fvc	Decrease+	Decrease++
Fev1/ Fvc	Decrease	Normal or increase
Frc	Increase	Decrease

274- A COPD patient achieves 50% hemoglobin saturation at an oxygen tension (PaO_2) of 37 mmHg. This observation is best explained by which physiological principle?

A- Fick's Law
B- Bohr Effect
C- Haldane Effect
D- La Place Law
Ans: B

Explanation:
- HaLdane effect: Shift to Left
- BohR effect: Shift to right

CamScanner

275- A patient is diagnosed with a pulmonary artery embolism following a CT pulmonaryangiography. What is the initialinterventionto restore the ventilation-perfusion mismatchin this patient?

A- Thrombolytic therapy
B- Oxygen therapy
C- Embolectomy
D- Mechanical Ventilation
Ans: B

Explanation:

- The initial intervention for a patient diagnosed with a pulmonary embolism (PE) is to provide **oxygen therapy** to improve oxygenation and alleviate hypoxemia caused by the ventilation-perfusion (V/Q) mismatch. Oxygen helps restore arterial oxygen levels and reduces the effects of hypoxia on vital organs while other definitive treatments are initiated

276- The serology test for "Aspergillus":

A- Galactosidase
B- Galactomannan
C- Galactofuran
D- Phospholipid A
Ans: B

Explanation:

Laboratory diagnosis of "Aspergillus"

- Biopsy specimens show septate, branching hyphae invading tissue Cultures show colonies with characteristic radiating chains of conidia.
- In persons with invasive aspergillosis, there may be high titers of **galactomannan** antigen in serum.
- Patients with ABPA have high levels of IgE specific for Aspergillus antigens and prominent eosinophilia. IgG precipitins are also present.

Better

277- Pulmonary embolism of left lung can cause death due to:

A- V/ ratio infinity
B- Alveolar 02eual to atmospheric 02
C- V/ ratio decrease
D- Alvelor 02 eual venous 02
E- FEV1 Decreased
Ans: A

278- Infant of diabetic mother developed patchy atelactasia has an increased risk of:

A- Neonatal jaundice
B- Macrocytic anemia
C- Hyperglycemia
D- ARDS
E- Hypercalcemia
Ans: D

279- The patient presents in OPD diagnosed as a case TB he was put on ATT which of the following ATT causes liver damage

A- Isoniazid
B- Pyrazinamide
C- Ethambutol
D- Rifampicin
E- Streptomycin
Ans: B>A(Katzung)

Explanation:

- The **isoniazid** induced hepatotoxicity is only clinically present in only 1% which can be fatal if drug not abrupty discontinued.the risk of hepatitis depend upon age,alcohol use ,during preganacy and postpartum period.10-20% have asymptomatic isoniazid induced hepatitis and in these donot require cessation of isoniazid
- Major adverse effects of **pyrazinamide** include hepatotoxicity (in 1-5% of patients), nausea, vomiting, drug fever, and hyperurice- mia. The latter occurs uniformly and is not a reason to halt therapy. Hyperuricemia may provoke acute gouty arthritis

280- 40 year old male patient present in cardiology OPD respiratory distress on Chest xray RA was enlarged and there was pulmonary edema diagnosed as a case of CHF what other finding you will find in this patient

A- Pulmonary artery dilation
B- Coronary veins dialation
C- Anterior vein dialation
D- Pulmonary vein dialation
Ans: A(Davidson)

Explanation:

- High pulmonary venous pressure in left-sided heart failure first shows on the chest X-ray as an abnormal distension of the upper lobe pulmonary veins (with the patient in the erect position). The vascularity of the lung fields becomes more prominent, and the right and left pulmonary arteries dilate. Subsequently, interstitial oedema causes thickened interlobular septa and dilated lymphatics. These are evident as horizontal lines in the costophrenic angles(septal or 'Kerley B' lines). More advanced changes due to alveolar oedema cause a hazy opacification spreading from the hilar regions, and pleural effusions

281- Middle aged woman with mediastinal Granuloma without necrosis cause is

A- Sarcoidosis,
B- Toxoplasmosis
C- Cat scratch disease
D- Tuberculosis
Ans: A

282- Smoker With FEV1/FVC 51% & Irreversible pattern. Cause?

A- COPD
B- Bronchial Asthma
C- Lung Fibrosis
D- Silicosis
Ans: A

283- Man has exertional dyspnea, Dry Cough & Basal crackles likely due to

A- Edematous Bronchioles
B- Restrictive Bronchioles
C- Hyperinflammatory bronchioles
D- Narrow bronchi
Ans: B

284- A patient presented with history of recurrent respiratory infections. A water soluble dye used to assess neutrophil oxidative burst in Neutrophols particularly in chronic granulomatous disease CGD?

A- Nitroblue Tetrazolium Test
B- Tetrazolium Blue
C- Tetrazolium Red
D- Immunohistochemistry
Ans: A

285- Pulmonary Fibrosis will result in

A- Decrease VC
B- Increase VC
C- NO effect on VC
D- Decrease RV
E- Increase RV
Ans: A

286- A solider went on altitude most likely feature in him

A- Anemic hypoxia
B- Histotoxic hypoxia
C- Stagnant hypoxia
D- V/Q mismatch
E- Cynosis
Ans: D

287- Patient presented with history of head trauma. O/E: RR 11. what will be seen in ABGS of this patient?

A- Dec O2
B- Increased CO2
C- Decreased PH
D- Increased HCO3
E- Decreased Co2 & Increased O2
Ans: B

288- A patient dies suddenly in an accident, and an autopsy reveals black pigmentation in the hilar lymph nodes, with no other abnormalities or comorbidities. What is the most likely diagnosis?(Medicine Feb 2025)

A- Anthracosis
B- Silicosis
C- Asbestosis
D- Coal worker's pneumoconiosis
Ans: A

289- A pregnant woman at 30 weeks experiences uterine contractions and is concerned about her baby's ability to breathe after birth. Which factor is most crucial for neonatal respiration? (Medicine Feb 2025)

A- Thickness of the alveolar wall
B- Number of type 1 pneumocytes
C- Quantity of surfactant
D- Size of the lungs
E- Number of type 2 pneumocytes
Ans: C

290- A 20-year-old patient presents with cough and dyspnea. Which finding is most supportive of a diagnosis of asthma?(Medicine Feb 2025)

A- Increased eosinophil count in peripheral blood
B- Arterial blood gas showing metabolic acidosis
C- FEV1 reversible with bronchodilators
D- FEV1/FVC ratio <0.7 with no reversibility
E- Chest X-ray showing bilateral infiltrates
Ans: C

CamScanner

291- A 55-year-old male with a 30-pack-year smoking history presents with progressive shortness of breath and a chronic cough producing scant sputum. Spirometry is performed, and post-bronchodilator testing with salbutamol shows no significant improvement in FEV1/FVC. What is the most likely diagnosis?(Medicine Feb 2025)

A- COPD
B- Asthma
C- Pulmonary Fibrosis
D- Bronchiectasis
Ans: A

292- A man with established diagnosis of small cell carcinoma, with liver mets on CT, presented with Puffy face and bruises. What is the cause of these symptoms?(Medicine Feb 2025)

A- Paraneoplastic syndrome
B- Mets in liver
C- Carcinoid syndrome
D- Polycythemia
Ans: A

293- Secondary to hyperventilation: (Medicine Feb 2025)

A- Respiratory alkalosis
B- Tachypnea
C- Hypercapnea
D- Tachycardia
Ans: A

294- A patient has an oxygen consumption rate of 700 ml/min. The oxygen content in the pulmonary artery is 140 ml/L, and the brachial artery oxygen content is 40. Calculate the cardiac output. (Medicine Feb 2025)

A- 4.2 L/min
B- 30 L/min
C- 7 L/min
D- 10L/min
Ans: C

Explanation:
Total oxygen consumption /Arterial 02 content -pulmonary O2 content
=700/140-40
=7L/min

295- Hypoxia due to anemia, what happens to oxygenation:(Medicine Feb 2025)

A- Increased oxygenation does not have any effect
B- Decrease oxygenation
C- Increase oxygenation
D- oxygenation remains normal
Ans: A

296- A COPD patient with respiratory acidosis is expected to have renal compensation for potassium what is expected effect(Surgery Feb 2025)

A- Rise in potassium with acid excretion
B- Decrease in potassium with acid excretion from renal tubules
C- No change in potassium levels
D- Rise in potassium without acid excretion
E- Increase in PH
Ans: B

297- According to GINA guidelines what percentage of FEV1 for bronchial asthma should increase by bronchodilator(Surgery Feb 2025)

A- FEV1>15% reversibility
B- FEV1>20% reversibility
C- FEV1> 12% reversibility
D- FEV1>25%reversibility
Ans: C

298- A premature new born is diagnosed with NRDS which of the following statement is correct regarding this condition(Surgery Feb 2025)

A- Causes alveolar collapse
B- Resulting from overproduction of surfactant
C- Primarily effects the term infants
D- Self limiting condition
Ans: A

299- A patient present with a Fev/Fvc < 55 and irreversible air flow limitation which of the following is likely cause(Surgery Feb 2025)

A- Pneumonia
B- COPD
C- Lung fibrosis
D- Cystic fibrosis
Ans: B

300- If patient has decrease FEV1 decrease FRC decrease FVC and has chronic cough with dyspnea which is related to(Surgery Feb 2025)

A- Chronic bronchitis
B- Pulmonary interstitial fibrosis
C- Asthma
D- Pneumonia
Ans: B

301- A patient with multiple rib fractures presents with tachypnea, tachycardia, and low SpO2 despite a normal blood pressure. What is the most likely reason for their hypoxemia?(Surgery Feb 2025)

A- Low ventilation/perfusion (V/Q) ratio
B- High ventilation/perfusion (V/Q) ratio
C- Physiological shunt with overperfusion
D- Alveolar hypoperfusion
Ans: A

302- A patient presented with low grade fever, night sweats & productive cough. His presentation is not responding to First line drugs of TB Most likely due to(Gynae Feb 2025)

A- MDR Tb
B- AIDS
C- Sarcoidosis
D- Histoplasmosis
Ans: A

303- Patient was having bronchiolar inflammation and increased productive cough. What is the progenitor cell of the structure damaged in this condition? (Gynae Feb 2025)

A- Basal cell
B- Granular cell
C- Clara cell
D- Goblet Cell
Ans: C

304- Cystic fibrosis CT findings:(Gynae & Obs Feb 2025)

A- Cystic opacities
B- Vesicular opacities
C- Bronchial dilation with thickened walls
D- Nodular opacities
Ans: C

305- A Military patient came with complain of cough not improving. He was refer to pulmonologist who ordered a spirometry that revealed decreased FEV1 , decreased FVC & decreased FRC. Most probable diagnosis: (Radiology Feb 2025)

A- Asthma
B- Pulmonary fibrosis
C- Emphysema
D- Pneumonia
E- Bronchitis
Ans: B (BRS Physio)

306- A 65-year-old male smoker presents with a mass in the right lower lung. Histopathology reveals giant pleomorphic cells. What is the most likely diagnosis?(Anesthesia Feb 2025)

A- Small cell lung carcinoma (SCLC)
B- Squamous cell carcinoma
C- Large cell carcinoma
D- Adenocarcinoma
Ans: C

307- Baby born and on 1 minute was resuscitated and ETI was passed. What would be the APGAR of the baby at birth?(Anesthesia Feb 2025)

A- 0-2
B- 3-4
C- 5-7
D- 8-10
Ans: A

CamScanner

HEMATOLOGY QUICK HINTS

Iron deficiency Anemia

- ✓ MCV <80FL
- ✓ Decrease Serum Iron , Ferritin
- ✓ Increase TIBC , RDW , Free Erythrocyte protoporphyrin
- ✓ May manifest as glossitis, cheilosis, Plummer-Vinson syndrome
- ✓ **Diagnostic** is Serum Ferritin

Alpha Thalassemia

- ✓ α-globin gene deletions on chromosome 16 decrease α-globin synthesis.
- ✓ Cis deletion (deletions occur on same chromosome)
- ✓ Trans deletion (deletions occur on separate chromosomes)

α-thalassemia minima

- ✓ No anemia (silent carrier)
- ✓ One Gene deleted (α α/α –)

α-thalassemia minor

- ✓ Mild microcytic, hypochromic anemia
- ✓ Two Gene deleted (α –/α –; trans) or (α α/– –; cis)

Hemoglobin H disease (HbH)

- ✓ Excess β-globin forms β4
- ✓ Moderate to severe microcytic hypochromic anemia
- ✓ Three Gene deleted (– –/– α)

Hemoglobin Barts disease

- ✓ No α-globin, excess γ-globin forms γ4
- ✓ Hydrops fetalis; incompatible with life
- ✓ All four gene (– –/– –)

Beta Thalassemia

- ✓ Point mutations in splice sites and promoter sequences on chromosome 11
- ✓ Decrease β-globin synthesis
- ✓ Basophilic stippling

Minor

- ✓ HbA2 >3.5%
- ✓ β chain is underproduced

Major

- ✓ β chain is absent
- ✓ Target cells and increased anisopoikilocytosis
- ✓ Crew cut on skull x-ray
- ✓ Chipmunk facies
- ✓ Extramedullary hematopoiesis result un hepatosplenomegaly increase risk of parvovirus B19–induced aplastic crisis
- ✓ Increased HbF (α2 γ2), HbA2 (α2 δ2)

Sideroblastic anemia

- ✓ Increase Serum Iron and Ferritin and decrease or normal TIBC
- ✓ Ringed sideroblasts
- ✓ Basophilic stippling

Megaloblastic Anemia

- ✓ MCV > 100FL
- ✓ Megaloblastic anemia shows hypersegmented neutrophil.
- ✓ Most common cause is – folic acid deficiency.
- ✓ Anemia + Neurological sign – B12 deficiency.

Folate deficiency

- ✓ Increase Homocystein level
- ✓ Normal Methylmalonic acid
- ✓ No neurological symtoms
- ✓ Occur due to Methotrexate and phenytoin
- ✓ **Diagnostic RBC folate level**

B12 deficiency

- ✓ Increase Homocystein level
- ✓ Increase Methylmalonic acid
- ✓ Neurological signs(DCML related)
- ✓ Occur due to Diphyllobothrium and in vegatarian diet
- ✓ Fisher man has low B 12 due to Diphyllo bothrium
- ✓ **Diagnostic is Serum B12 Level**
- ✓ Schilling test also used

Anemia of chronic disease

- ✓ IL6 increase Hepcidin that decrease release of iron From macrophages and decrease Iron absorption in gut
- ✓ Usually normocytic but can be microcytic
- ✓ Decrease Iron and TIBC and Increase Ferritin

Aplastic anemia

- ✓ **Fatty marrow diagnostic**
- ✓ Pancytopenia seen
- ✓ Occur due to Radiation , drugs and Viral agents
- ✓ Increase EPO

Hemolytic Anemia

- ✓ Hereditory spherocytosis
- ✓ Autosommal dominant
- ✓ Defect in RBC membrane skeleton and plasma membrane (Spectrin , Ankyrin Band 3 and Protein 4.2)
- ✓ Osmotic fragility test used

GCPD

- ✓ X linked recessive
- ✓ Decrease NADPH decrease Glutathion susceptible to Oxidative stress (Sulpha drugs and Fava beans)
- ✓ Heinz bodies and bite cells seen

Sickle cell Anemia

- ✓ Point mutation in β-globin gene single amino acid substitution (glutamic acid valine)
- ✓ In HBC Glutamic acid–to-lyCine (lysine) mutation in β-globin
- ✓ Increase HBS and HBF and Low HBA
- ✓ Crescent-shaped RBCs
- ✓ Crew cut on skull x-ray

Aplastic Crisis

- ✓ Erythropoeisis arrest due to B19 parvo infection

Hemolytic crisis

- ✓ Deep jaundice
- ✓ Low Hb

Sequestration Crisis

- ✓ Abdominal Pain
- ✓ No Jaundice
- ✓ Autosplenectomy (Howell-Jolly bodies)
- ✓ Increase risk of infection by encapsulated organisms (eg, S pneumoniae)
- ✓ Painful vaso-occlusive crises: dactylitis priapism and acute chest syndrome

Autoimmune hemolytic Anemia

Warm type

- ✓ IgG associated RBC agglutination
- ✓ Associated with SLE , CLL and alpha methyl dopa

CamScanner

Cold type
- ✓ IgM associated RBC agglutination
- ✓ Seen in Mycoplasma ,Mononucleosis and CLL

Microangiopathic hemolytic anemia
- ✓ RBCs are damaged when passing through obstructed or narrowed vessels.
- ✓ Schistocytes (eg, "helmet cells") are seen on peripheral blood smear
- ✓ Seen in DIC, TTP/HUS, SLE, HELLP syndrome, hypertensive emergency

Macroangiopathic hemolytic anemia
- ✓ Prosthetic heart valves and aortic stenosis may also cause hemolytic anemia
- ✓ Schistocytes are seen

Blood disorder

Coagulation Disorder

Hemophilia
- ✓ Hemophilia A: deficiency of factor VIII; X-linked recessive.
- ✓ Hemophilia B: deficiency of factor IX; X-linked recessive.
- ✓ Hemophilia C: deficiency of factor XI; autosomal recessive.
- ✓ Presented with Hemarthroses (bleeding into joints, eg, knee) easy bruising, bleeding after trauma or surgery (eg, dental procedures).
- ✓ Intrinsic pathway coagulation defect (Increased APTT)

Platelets Disorder

- ✓ All platelet disorders have Increase bleeding time (BT), mucous membrane bleeding, and microhemorrhages (eg, petechiae, epistaxis)

Bernard-Soulier syndrome
- ✓ Defect in adhesion Decrease GpIb Decrease platelet-to-vWF adhesion
- ✓ Abnormal ristocetin test
- ✓ Large platelets
- ✓ Normal to Mild decrease in Platelets

Immune thrombocytopenia
- ✓ Destruction of platelets in spleen. Anti-GpIIb/IIIa antibodies
- ✓ Associated with SLE , Viral illnes and CLL
- ✓ Increase megakaryocytes on bone marrow biopsy
- ✓ Marked Low platelet count.
- ✓ ITP also has Large platelets

Glanzmann thrombasthenia
- ✓ Defect in aggregation. Decrease GpIIb/IIIa(Decrease integrin αIIbβ3)
- ✓ Decrease platelet-to-platelet aggregation and defective platelet plug formation
- ✓ Blood smear shows no platelet clumping.

Mixed platelet and coagulation disorders

Von Willebrand disease
- ✓ Intrinsic pathway coagulation defect: Decrease vWF
- ✓ Defect in platelet plug formation: Decrease vWF defect in platelet to-vWF adhesion
- ✓ Raised APTT and BT

DIC
- ✓ Widespread clotting factor activation deficiency in clotting factors result in bleeding
- ✓ Causes - Snake bites, Sepsis (gram ⊖), Trauma, Obstetric complications, acute Pancreatitis, Malignancy, Nephrotic syndrome, Transfusion
- ✓ Raised APTT , BT , PT ,FDP(D dimers) and decrease Fibrinogen , Factor V and VIII

Thrombotic microangiopathies

Thrombotic thrombocytopenic purpura
- ✓ Typically females
- ✓ Inhibition or deficiency of ADAMTS13
- ✓ Triad of thrombocytopenia (Low platelets), microangiopathic hemolytic anemia (Low Hb, schistocytes, Raise LDH), acute kidney injury (Increase Cr) + Fever and Neurological symptoms

Hemolytic-uremic syndrome
- ✓ Typically children
- ✓ Commonly caused by Shiga-like toxin from EHEC (serotype O157:H7) infection
- ✓ Triad + Bloody Diarrhea

Lymphoma

Hodgkin
- ✓ Localized, single group of nodes with **contiguous spread**
- ✓ Reed Sternberg cell is variety of Hodgking lymphoma having Bilobe cell and CD 15 and CD 30 positive.
- ✓ Associated with EBV.
- ✓ Bimodal distribution (Young adult hood and age >55Y)
- ✓ **Lymphocyte Rich** – Best prognosis
- ✓ **Lymphocyte Depleted** – Poor prognosis
- ✓ **Lymphocyte Predominance** – Popcorn cell
- ✓ **Nodular sclerosis** – Most common and has Lacunar cell
- ✓ **Mixed cellularity** – Abundant Eosinophils.

Non Hodgkin
- ✓ Multiple lymph nodes involved; extranodal involvement common; **noncontiguous spread.**
- ✓ May be associated with autoimmune diseases and viral infections (eg, HIV, EBV, HTLV).
- ✓ B cell origin

B cell Origin

Burkit Lymphoma
- ✓ t(8:14) **"Starry sky" appearance**, sheets of lymphocytes with interspersed "tingible body" macrophages
- ✓ **Jaw lesion** in endemic form in Africa; **pelvis or abdomen** in sporadic form
- ✓ Linked with EBV

Mantle Cell Lymphoma
- ✓ t (11:14)
- ✓ Very aggressive

Follicular Lymphoma
- ✓ t(14:18)
- ✓ Painless "waxing and waning" lymphadenopathy

Diffuse large B cell lymphoma
- ✓ Most common type of Non hodgkin
- ✓ Mutation in BCL2 and BCL6

Primary Central Nervous System Lymphoma
- ✓ Occur in HIV and is AIDS defining illness
- ✓ Look for Antibody againt HIV
- ✓ Also linked With EBV

Marginal Zone lymphoma
- ✓ t(11:18)
- ✓ Associated with chronic inflammation (eg,
- ✓ Sjögren syndrome, chronic gastritis [MALT lymphoma]

T cell origin

Adult T cell Lymphoma
- ✓
- ✓ Caused by HTLV
- ✓ Cutaneous lesions
- ✓ Associated with IV drug abuse

Mycosis fungoides/ Sézary syndrome
- ✓
- ✓ Mycosis fungoides: skin patches and plaques (cutaneous T-cell lymphoma)
- May progress to Sézary syndrome (T-cell leukemia).

CamScanner

Plasma cell dyscrasias

Multiple myeloma

- ✓ Overproduction of IgG 60% > IgA 20-25% > IgM 15% or rarely seen

Clinical features: CRAB

- ✓ HyperCalcemia
- ✓ Renal involvement
- ✓ Anemia
- ✓ Bone lytic lesions ("punched out" on X-ray A) - Back pain
- ✓ Rouleaux formation
- ✓ Bone marrow analysis shows > 10% monoclonal plasma cells with clock-face chromatin C and intracytoplasmic inclusions containing IgG.

Waldenstrom macroglobulinemia

- ✓ Overproduction of IgM
- ✓ Peripheral neuropathy
- ✓ No CRAB findings
- ✓ Hyperviscosity syndrome: Headache , Blurry vision ,Raynaud phenomenon ,Retinal hemorrhages
- ✓ Bone marrow analysis shows >10% small lymphocytes with IgM-containing vacuoles (lymphoplasmacytic lymphoma).

Leukemias

ALL

- ✓ Most frequently occurs in **children**
- ✓ T cell ALL can present as **mediastinal mass** (presenting as SVC-like syndrome)
- ✓ Increase **Lymphoblasts**
- ✓ **TdT**+ (marker of pre-T and pre-B cells), **CD10**+ (marker of pre-B cells).
- ✓ **t(12;21)** better prognosis.

CLL

- ✓ **Age > 60 years**. Most common adult leukemia
- ✓ **Mature Lymphocytes**
- ✓ Smudge cells Seen

Hariy cell Leukemia

- ✓ Adult males. Mature B-cell tumor. Cells have filamentous, hair-like projections (fuzzy appearing on LM)
- ✓ Stains TRAP (tartrate-resistant acid phosphatase) ⊕
- ✓ Dry Tap due to fibrosis

AML

- ✓ Median onset 65 years.
- ✓ **Auer rods and myeloperoxidase ⊕**
- ✓ Increase Circulating **Myeloblast**
- ✓ APL (formerly M3 AML), **t(15;17),** responds to all-trans retinoic acid (vitamin A) and arsenic and DIC is a common presentation.

CML

- ✓ Peak incidence: 45—85 years; median age: 64 years.
- ✓ Philadelphia chromosome **(t[9;22], BCR-ABL)**
- ✓ Massive Splenomegaly
- ✓ **Basophilia**
- ✓ Very low leukocyte alkaline phosphatase (LAP) vs High LAP in leukemoid reaction

Polycythemia vera

- ✓ Primary polycythemia. Disorder of increase RBCs, usually due to acquired JAK2 mutation.
- ✓ May present as intense itching after shower (aquagenic pruritus)
- ✓ Decrease EPO in primary polycythemia
- ✓ Increase EPO in Secondary polycythemia (Absoulte Polycythemia)

Myelofibrosis

- ✓ Bine marrow fibrosis
- ✓ **Prominent** feature is massive Splenomegalay
- ✓ **Characteristic** is Tear Drop Cell

Random

- ✓ Hemoglobin synthesis starts in -- **Proerythroblast or Early Normoblast**
- ✓ Hemoglobin First appears in -- **Intermediate Normoblast**
- ✓ RBC Nuclei disappear in -- **Late Normoblast >Reticulocytes**
- ✓ Max Production -- **Late Normoblast**
- ✓ Maximum concentration -- **Reticulocytes**
- ✓ Iron Transport form --- **Transferrin**
- ✓ Iron Excess storage form -- **Hemosiderin**
- ✓ Iron Normal Storgae Form -- **Ferritin**
- ✓ Iron Fe2+ in reduced form binds to -- **Hemoglobin**
- ✓ Heme binds with -- **Hemopexin**
- ✓ Hemoglobin binds with -- **Haptoglobin**
- ✓ Iron is absorberd from -- **Duodenum**
- ✓ Diagnostic for IDA -- **Serum Ferritin**
- ✓ Diagnostic For B12 Deficiency -- **B12 Assay**
- ✓ Diagnostic For Folate Deficiency -- **RBC Folate Level**
- ✓ Diagnostic For Pernicious Anemia -- **Anti Intrinsic Factor Antibodies**
- ✓ Diagnostic feature of Aplastic anemia -- **Fatty marrow > Pancytopenia**
- ✓ Acute Intravascular Hemolysis -- **Decrease Hepatoglobin > Reticulocytosis**
- ✓ Chronic Intravascular Hemolysis -- **Hemosidrinuria >Hemoglobinuria**
- ✓ Chloride Shift occur by – Band 3
- ✓ Venous Blood have more – HCO3 & PCV(PCV >HCO3)
- ✓ RBC Venous Blood Have more – Chloride Ions
- ✓ Cryoprecipitate has – Factor 8+13
- ✓ FFP has – Factor 9
- ✓ Partial Gastrectomy – Iron Deficiency anemia.
- ✓ Complete Gastrectomy – Megaloblastic anemia so inj Vitamin B12 should be given
- ✓ Before 6 months –Iron Deficiency anemia.
- ✓ After 6 months – Megaloblastic anemia
- ✓ Over all – Iron Deficiency anemia > Megaloblastic anemia.
- ✓ Gastrectomy can produce Pernious anemia like symptoms but not actual Pernious anemia as it is Autoimmune.
- ✓ Factor V mutation(Laden) leads to -- **Thrombosis**
- ✓ Factor V deficiency leads -- **Bleeding**
- ✓ Factor 12 deficiency leads -- **Thrombosis**.
- ✓ Most common acquired thrombotic disorder is -- **Anti-phospholipid syndrome**
- ✓ Most common Inherited coagulopathy -- **VWBD**
- ✓ Most common inherited Thrombotic disorder is -- **Factor V Mutation (Laden)**
- ✓ Natural anticoagulant and anti-thrombotic -- **Heparin**
- ✓ Natural thrombolytic -- **Plasminogen**
- ✓ Extrinsic and intrinsic pathway converge on -- **Stuart factor (Factor 10)**
- ✓ Factor 8 is produced by -- **Endothelium**
- ✓ Clotting factor not completely synthesized in liver is -- **Factor 8**
- ✓ Activation of extrinsic path way by – **Thromboplastin (Tissue Factor)**
- ✓ Activation of Intrinsic Pathway by – **Facto 12**

CamScanner

- ✓ Vitamin k dependent factor with **Shortest** half-life is -- **Factor 7**
- ✓ Vitamin k dependent factor having **Longest** half-life is -- **Factor 2**
- ✓ First factor to be lost from Stored blood is – 2,3DPG
- ✓ APTT raised only -- **Hemophilia(Intrinsic Pathway)**
- ✓ APTT and BT raised – **VWBD (Intrinsic Pathway)**
- ✓ APTT and PT raised -- **Vit-K deficiency or liver disease**
- ✓ All 3 raised -- **DIC**
- ✓ Only BT raised – **ITP (Low Platlets) or Platelets Function Defect (Platlets count normal)**
- ✓ Heparin Inhibit -- **factor Xa**
- ✓ Heparin Act by -- **Anti-thrombin 3**
- ✓ Antidote of heparin is -- **Protamine sulphate**
- ✓ Heparin monitoring is done by – **APTT (Intrinsic Pathway)**
- ✓ Heparin is given -- **IV**
- ✓ Warfarin acts on and inhibits -- **Vitamin K Epoxide reductase**
- ✓ Warfarin antidote is – **FFP (Immediate)**
- ✓ Warfarin action is reversed by -- **Vitamin k (long acting)**
- ✓ Warfarin monitoring is -- **INR > PT(Extrinsic Pathway)**
- ✓ Warfarin in given -- **Orally**

HEMATOLOGY

1. A lady noticed some skin changes with nodules ranging from 0.5 to 2mm in size, there was a lesion in brain upon doing CT scan, and also some lesion in the abdomen was noticed with some imaging technique. What's the mutation involved in the disease?

A- NF 1
B- APC
C- N-myc
D- NF 2
E- RB
Ans: A (First Aid)

Explanation:
- NF1 – Neurofibromatosis type 1 has Pheochromocytoma, Nodules and focal neurological lesion.
- NF2 – Neurofibromatosis type 2 has B/L Vestibular Schwannoma and cataract.

2. A 24years boy develops jaundice, pallor, and breathlessness having splenomegaly jaundice develop again and again likely cause is:

A- Sidroblastic anemia
B- Thalassemia
C- Hemolytic anemia
D- Autoimmune anemia
Ans: C

3. Lady had a difficult labour at home in village. She was brought to hospital with history of PV bleed & oozing from gums for the last 10 hours. Her CBC shows 6 g/dl, platelets 30,000, TLC 24000 with neutrophilia, Theperipheral blood film shows burr cells. Her PT & APTT were prolonged. Most likely cause is:

A- ITP
B- FTP
C- Septicemua
D- Hemophilia
E- DIC
Ans: E

Explanation:
In DIC
- PC - Dec
- BT - inc
- PT - Inc
- PTT - Inc
- Labs - shistiocytes , inc fibrin degradation products (D dimers) , dec fibrinogen , devmcy factor 5 and 8

4. Patient on oral anticoagulants monitoring done by which parameter

A- BT
B- APTT
C- PT
D- CT
E- FDP
Ans: C

Explanation:
- Heparin – APTT
- Warfarin (Oral) – INR >PT

5. A 50year man presented with Hb 8.2, enlarge spleen. WBC raised. Peripheral smear showing immature myeloid lineage. What is the genetic defect?

A- 9:22
B- 14:18
C- 11:14
D- 8:14
Ans: A

6. Regarding hematopoises true is

A- Long bones causes cell formation after 20years
B- Sternum stops hematopeisis after 21 years
C- 75%myleoid stem cells
D- 75% erythroids stem cells
Ans: B

7. 26 year old boy present with pallor and weakness also having fever of 101F bruises and petechia present definitive diagnosis will made on:

A- Serology
B- CBC
C- Bone marrow aspiration
D- Molecular biology
E- Factor 2
Ans: C

8. A 65year patient presents with jaundice. On workup HB 4.5, increase bilirubin, increase retic count 9%, smear shows polychromasia and clumps, what test to confirm diagnosis?

A- Coombs test
B- Hb electrophorosis
C- Osmotic fragility test
D- G6PD
E- Bone marrow biopsy
Ans: A

CamScanner

9. Known patient of arthritis using drugs for 8 to 9 months presents with HB llg/dl, MCV 101fl, MCH = 30, bone marrow biopsy shows hyper cellular:

A- Aplastic anemia
B- Megaloblastic anemia
C- Leukemia
D- Lymphoma
E- Sideroblastic anemia

Ans: B

Explanation:

- **Microcytic** - MCV < 80fL
- **Normocytic** - 80 to 100 fL
- **Macrocytic** - >100 fL

10. A 30 years man with sore throat & cervical lymphadenopathy; CBC picture shows presence of atypical lymphocytes the most important test in this setting is:

A- Monospot test
B- Mantoux test
C- Lymph node biopsy
D- Blood culture
E- X-ray

Ans: A

Explanation:
Sore throat with cervical lymphadenopathy and atypical lymphocytes indicating Infectious mononucleosis which is diagnose by Monospot test and Causative virus is EBV.

11. After Mismatched blood transfusion what will occur

A- Donnor blood agglutination and hemolysis
B- No reaction
C- Graft vs host reaction
D- Hyperacute Graft rejection

Ans: A

12. Normal physiological parameters of blood components or cells are:

A- 45%Blood cells and 55%plasma
B- 75%platelets
C- 75% cells r of myeloid origin
D- 75% cells r of lymphoid origin
E- 90% Platelets

Ans: A

13. A female patient with Hb 9.6 g/dl and doctor prescribed iron, after 2 months she presents with Hb 10.2 g/dl. What should be further considered for diagnosis?

A- Ferritin
B- Bone Marrow Biopsy
C- Hb electrophoresis
D- TIBC
E- Retic count

Ans: C

14. A male presented to OPD with 104 fevers for last 4 days and gives history of using Anti-malarial She has been passing cola color urine for the last 1 day with deranged LFTs and increased unconjugated bilirubin. Bite cells seen on histopathology.What is the cause?

A- Glucose 6 Phosphate dehydrogenase deficiency
B- Black Water fever
C- Drug induced jaundice
D- Paroxysmal nocturnal hemoglobinuria
E- Glucose 6 Phosphate Deficiency

Ans: A

Explanation:
G6PD deficiency due to sulfa drugs, anti malarials , fava beans

15. Bone marrow biopsy is done at which of the following site?

A- Ventral iliac crest
B- Pubis
C- Ischiooubis
D- Ischial Tuberosities

Ans: A

16. Which of the following is last to appear normal in blood after hemorrhage?

A- Hematocrit
B- Hemoglobin
C- RBCs
D- Reticulocytes

Ans: C

17. A 28 year old soldier after returning from Siachen glacier, having spent 6 months there, presents to CMH Rawalpindi, with complains of headache and peripheral cyanosis of his fingers. Most probably the cause is?

A- Secondary Polycythemia
B- Polycythemia Vera
C- Sickle Cell anemia
D- Physiologic Polycythemia
E- Anemia

Ans: A

Explanation:

- Within 24hr Symtoms – Pulmonary edema
- After 5-6 months Symptoms on returning - Secondary polycythemia

18. Aplastic anemia characteristic diagnostic feature is

A- Pancytopenia
B- Bicytopenia
C- Fatty marrow
D- Red cell dysplasia
E- Anaplasia

Ans: C

Explanation:
Fatty marrow > Pancytopenia

19. A school boy while crossing road hit by a car and lost 1.5 liters blood what type of anemia will be there?

Microcytic microchromic anemia
Normochromic normocytic anemia
A- Macrocytic Anemia
B- Iron deficiency
C-
D-

Ans: B

20. Mother Rh +Ve & father is Rh –ve what's the risk?

All babies will be affected
A- Needs serious counseling
B- Rh antigen will leak into mother circulation
C- Rh antibodies will be formed
D-

Ans: C

21. The blood group antigens are not present on RBCs until:

A- 5 weeks
B- 10 weeks
C- 15 weeks
D- 20 weeks
E- 25 weeks

Ans: D

22. An 18 year old girl presented with epistaxis and ecchymosis on bone marrow aspirate, there is hyperplasia of megakaryocytes, the most likely diagnosis is:

A- ITP
B- DIC
C- TTP
D- Myelodysplastic syndrome
E- VWD

Ans: A

23. A female Patient present with fatigue, easy bruisibility after small cuts and recurrent infection alongside fever from 2 weeks. After investigations the report shows blast cells and Promyelocyte in smear. Suspected Diagnose is indicated by which translocation

A- 9:22
B- 8:14
C- 11:14
D- 15:17
E- 14:18

Ans: D (Robins)-AML

Explanation:

- AML – 8:21 and 15:17
- CML – 9:22
- Burkit Lymphoma – 8:14
- Mantle Cell Lymphoma – 11:14
- Follicular Lymphoma – 14:18
- Ewing Sarcoma – 11:22
- Prostatic Carcinoma – 7:21 and 17:21

24. Most common presentation of G6PD is:

A- Neonatal juandice
B- Acute drug induced hemolysis
C- Chronic Hemolysis
D- Favism
E- Anaphylaxis

Ans: B

25. 55-Year-old patient with generalized lymphadenopathy. Platelets and TLC count was raised. Peripheral smear showed mature lymphocytes. What is the diagnosis?

A- CML
B- Hairy cell leukemia
C- Burkitt lymphoma
D- Hodgkin lymphoma
E- CLL

Ans: E

Explanation:
Age > 60 years. Most common adult leukemia. CD20+, CD23+, CD5+ B-cell neoplasm. Often asymptomatic, progresses slowly; smudge cells B in peripheral blood smear; autoimmune hemolytic anemia. CLL = Crushed Little Lymphocytes (smudge cells).

26. Which test is diagnostic for pernicious anemia?

A- Anti Parietal cell Antibodies
B- Anti Intrinsic factor Antibodies
C- Anti Smith Antibodies
D- Anti iliac Antibodies
E- Anti Glutan Antibodies

Ans: B

27. A thalassemic child took appointment from dentist for tooth extraction but two days before that he developed deep jaundice dark urine HB 4.9, MCV56 hepatosplenomegaly

A- Hemolytic crisis
B- Sequestration crisis
C- Thrombotic crisis
D- Aplastic crisis
E- Embolic crisis

Ans: A

28. Which of the following is the Most common inherited bleeding disorder?

A- VWD
B- Hemophilia
C- Antiphospholipid
D- Factor V laden
E- Factor X1

Ans: A

Explanation:

- Factor V mutation (Laden) leads to – Thrombosis
- Factor V deficiency leads to – Bleeding
- Factor 12 deficiency leads to – Thrombosis

CamScanner

- Most common acquired thrombotic disorder is – Anti-phospholipid syndrome
- Most common Inherited coagulopathy – VWBD
- Most common inherited Thrombotic disorder is – Factor V Mutation (Laden)

29. Treatment of erythroblastosis fetalis of B+ Exchange transfusion done with which of following

A- B+ve
B- B-ve
C- AB+ve
D- Anti D
E- O-ve
Ans: B

30. Lady with hypochromic microcytic anemia HBA 96% HBA2 4% what is your diagnosis:

A- Iron deficiency
B- Alpha thalassemia
C- Beta thalassemia
D- Thalassemia trait
E- Sickle Cell Anemia
Ans: D(FA)

31. The maturation of T cells occur in

A- Bone Marrow
B- Trachea
C- Thymus
D- Payers patches
E- Spleen
Ans: C

32. A pregnant lady in 30 weeks taking only iron supplements she will be deficient in:

A- Folic acid
B- Vitamin B12
C- Vitamin B6
D- Magnesium
E- Phosphorous
Ans: A (Prefer Calcium if present)

33. Young girl oral bleeding, gingival swelling, petechiae, lower lip paraesthesia, CBC and bone marrow biopsy advised. Which is most likely diagnosis?

A- Leukemia
B- Herpetiform ulcer
C- Bahcet disease
D- Lymphoma
Ans: A

34. ALL markers is which of the following?

A- CD 8
B- CD 18
C- CD 10
D- CD 30
E- CD 22
Ans: C

35. Patient having a bleeding due to which partial gastrectomy has been done which type of anaemia occurs?

A- Microcytic hypochromic anaemia
B- Macrocytic hypochromic anaemia
C- Microcytic macrocytic
D- Normocytic normochromic
Ans: A

Explanation:

- Partial gastrectomy – Iron deficiency anemia.
- Complete gastrectomy – megaloblastic anemia.
- Before 6 months – Iron deficiency anemia.
- After 6 months – Megaloblastic anemia
- Over all – Iron deficiency anemia > Megaloblastic anemia.
- Gastrectomy can produce pernious anemia like symptoms but not actual pernious anemia as it is autoimmune.

36. How are ABGs samples collected?

A- Whole arterial blood in heparinized syringe
B- Whole venous blood in heparinized syringe
C- Whole arterial blood in Non -heparinized syringe
D- Whole venous blood in non-heparinized syringe
Ans: A

37. Female patient presents with fever and excess menstrual blood loss her labs show HB much less than her age and sex range but ferritin is normal. What is conclusion?

A- Patient has iron overload
B- Patient is not suffering from iron deficiency anemia
C- Concomitant sideroblastic anemia
D- Serum ferritin normal due to compensation
Ans: C

38. Hb binds with which of following?

A- Albumin
B- Heme
C- Globulin
D- Haptoglobin
E- Macroglobulin
Ans: D

Explanation:

- Hb binds with -**Haptoglobin**
- Heme binds with - **Hemopexin**

39. Venous blood is higher to arterial blood in

A- Oxygen
B- Hemoglobin
C- Hematocrit
D- Platelets
E- Leukocyte
Ans: C

Explanation:

- Venous Blood have more – HCO3 & PCV (PCV >HCO3)
- RBC venous blood have more – chloride ions
- Arterial blood has more O2

40. Clotting factors associated with prothrombin time are:

2, 7, 9, 10
A- 1, 2, 5, 7, 10
B- 2, 5, 7, 9, 10
C- 2, 5, 7, 10
D- 1, 3, 7, 12
E-
Ans: B(Pathoma)

Explanation:

- PT – Measure extrinsic (Factor VII) and common (Factors II, V, X and Fibrinogen)
- APTT – Measure intrinsic (Factors XII, XI, IX, VIII) and common (Factors II, V, X and fibrinogen)

41. Female presented with pallor fatigue and severe loss of vibration investigation of choice will be:

A- B12 Level
B- Serum Ferrting
C- TIBC
D- Stomach Biopsy
E- X-ray Spine
Ans: A

42. Hemagglutinin characteristic feature is:

A- Complex glycoprotein
B- Immunogenic
C- Found on outer membrane
D- Destroy RBC
Ans: A

43. 12 Years old child with bruises and occasional epistaxis since birth, bleeding time is increased while platelets are 180,000 HB 11.5 What is the underlying defect?

A- Idiopathic thrombocytopenia
B- Platelet functional defect
C- Haemophilia
D- Leukaemia
E- Anti platlet therapy
Ans: B

44. Patient presented with jaundice bilirubin 6 direct bilirubin 0.9 reticulocyte 10 ALT 17 ALP 75 Hb 7 combs test +ve what is likely cause?

A- Pernicious anemia
B- Hemolytic anemia
C- Anemia of chronic disease
D- Microcytic anemia
E- Sideroblastic anemia
Ans: B

45. A Patient having Bleeding tendency and diagnosed as VWD. which among the following test is used for diagnosis of VWB disease?

A- Increase PT
B- Increase BT
C- Decrease APTT
D- Increase FDP
E- Decrease PT
Ans: B

Explanation:

- Haemophilia: Raised APTT
- ITP: Raised BT
- VWD: Raised BT And APTT
- DIC: Raised PT, APTT, BT &FDP

46. Anti sera agglutinates with A and D and plasma has anti B antibodies which blood group it is?

A- A-ve
B- A+ve
C- O-ve
D- O+ve
E- B+
Ans: B

Explanation:

As anti-sera agglutinates A and D that means the group has A & D (Rh) Antigen and as well plasma has Anti B antibodies that's why it's A +ve that has Antigen A & Rh with antibody B.

47. 14year old boy came from Balochistan with painful legs, ulcers on the leg and mild jaundice. What is the probable diagnosis?

A- Thalassemia
B- Sickle cell anemia
C- Heredity spherocytosia
D- G6PD
E- Hemolytic anemia
Ans: B

Explanation:

Crisis in sickle cell anemia

Thrombotic crisis

- infection , deoxygenation , dehydration e.g, hand foot syndrome in children , avascular necrosis of hip ,painful leg ulcers

CamScanner

Sequestration crisis

- Sickling with organs such as spleen or lings causes pooling of blood with worsening of anemia eg acute chest syndrome (dyspnea, chest pain)

Hemolytic crisis

- Fall in Hemoglobin due to an increase rate of hemolysis

Aplastic crisis

- Caused by infection with Parvo virus lead to sudden fall in HB

48. A patient of VWD present with bleeding what is the most appropriate treatment of VWD if no factor 8 is available?

A- FFP
B- Cryoprecipitate
C- Factor 9
D- Vitamin k
E- Vitamin C
Ans: B

Explanation:

- Cryoprecipitate has – Factor 8+13
- FFP has – Factor 9

49. A Girl with swollen tender knee history of excessive bleeding after tooth extraction. What is the suitable test for diagnosing the cause of bleed?

A- BT
B- APTT
C- PT
D- Factor 8 assays
Ans: A

Explanation:

- Hemophilia do occur in girl but very rare.
- How ever VWB type 3 has same presentation in girl as in hemophilia so we check BT first to rule out these causes.

50. Patient with Hb 5g/dl, enlarged spleen and recurrent blood transfusion , what's the diagnosis?

A- Iron deficiency anemia
B- Myelofibrosis
C- Sickle cell disease
D- Thalessemia minor
E- Thalassemia major
Ans: E

51. Anticoagulant released in blood by mast cells:

A- Heparin
B- Histamine
C- Bradykinin
D- Platelets actiating factor
E- Prostaglandin
Ans: A

52. Total hematocrit in infant is:

A- 36
B- 54
C- 60
D- 45
Ans: B (Nelson)

53. Blood clot consists of:

A- Fibrin
B- Fibrinogen
C- Plasminogen
D- Plasmin
Ans: A

54. A boy with uneventful tooth extraction presented with the very next day with bleeding likely reason is:

A- Vitamin k deficiency
B- Hemophilia
C- VWD
D- Anti coagulant effect
E- ITP
Ans: D

55. Most common inherited thrombotic disorder is due to?

A- Factor 8
B- Factor 7
C- Factor V laiden
D- Anti phospholid syndrome
E- Factor 8 inhibitor
Ans: C

56. Insoluble form of iron stored is:

A- Transferrin
B- Hemosiderin
C- Ferritin
D- Hemoglobin
Ans: B

Explanation:

- Iron Transport form – Transferrin
- Iron excess insoluble storage form - Hemosiderin
- Iron normal storage form – Ferritin

57. MCV remains normal in which?

A- Chronic blood loss
B- Terminal ileum resection
C- Gastrectomy
D- Pregnant lady not taking multivitamin
E- Acute blood loss for 2 days
Ans: E

58. A 6 year boy with swollen tender knee history of excessive bleeding after tooth extraction. What is the best test for diagnose cause of bleed?

A- BT
B- APTT
C- PT
D- Factor 8 minor assays
E- Factor X
Ans: D

59. A 24 years old lady who is 6 months pregnant complains of generalized weakness and lethargy her Hb is 9.8 g/dl with MCV 58 fl and MCH 15 pg her serum ferritin level is 150 mg /dl diagnose is?

A- Anemia of chronic disease
B- Iron deficiency anemia
C- Thalassemia trait
D- Megaloblastic anemia
E- Sideroblastic anemia
Ans: C

Explanation:

- Thalassemia trait – MCV low + Ferritin normal
- Iron deficiency – MCV low + Ferritin low

60. A young boy having mass in neck biopsy of lymph node shows effaces architecture atypical mononucleosis cell with bilobed nucleus and eosinophilia and CD 15 and CD 30 positive diagnose is:

A- Non Hodgkin lymphoma
B- Hodgkin lymphoma
C- T cell leukemia
D- Infectious mononucleosis
E- Burkit lymphoma
Ans: B

Explanation:

Reed Sternberg cell is variety of Hodgking lymphoma having Bilobe cell and CD 15 and CD 30 positive.

61. An Old man who was being treated by a GP for infection with certain drugs comes to you with complaints of Generalized weakness, pallor, easy bruising. Hb 5g/dl and decrease RBC,WBC PLT. Retic count 0.1%. Bone tap hypocellular bone marrow with few cells diagnose is:

A- Aplastic anemia
B- Acute leukemia
C- Myelodysplastic
D- Megaloblastic anemia
Ans: A

62. What is the inheritance pattern of hemophilia A?

A- X linked dominant
B- Autosomal Dominant
C- X linked recessive
D- Autosomal recessive
E- X linked dominant
Ans: C

Explanation:

- Thalessemia , sickle cell anemia - autosomal recessive
- Heariditary spherocytosis - autosomal dominant
- G6pD deficiency - X linked recessive
- Pyruvate kinase deficiency- autosomal recessive

63. O-ve blood transfused with AB+ve what is the secondary blood transfusion reaction:

A- Anaphylaxsis
B- Hemoglobinuria
C- Bilirubinemia
D- Febrile reaction
Ans: B

64. A 9 month old baby fell from bed and got frontal ecchymosis his Hb is 5 platelets are 180000, 2 sisters are normal but brother died of profuse bleeding after circumcision which is the most appropriate test to rule out the cause:

A- Bleeding time
B- Platelet Count
C- Coagulation profile
D- LFT
E- CBC
Ans: C (Look for APTT for Hemophilia)

65. A 51 year old man complains of lethargy tiredness and pruritus. The pruritus is worse after he takes a hot shower. He also says that he feels a burning sensation in his fingers and toes. Splenomegaly was found during an abdominal examination. His medical history is significant for gout. RBC ,WBC and platlets raised and erythropoietin decrease what is the single most likely diagnosis?

A- Polycythaemia rubra vera (PRV)
B- Myelofibrosis
C- Rheumatoid arthritis
D- Scleroderma
E- Systemic lupus erythematosus
Ans: A

66. A patient is having Bleeding Problem lab Shows PT 14sec, APTT 60 sec (prolonged) Bleeding time 6mins and defect in which of following Pathway?

A- Extrinsic pathway
B- Intrinsic pathway
C- Platelet function
D- Clot Retraction
E- Blood Propagation
Ans: B (FA +Guyton)

Explanation:

- APTT raised only – Hemophilia (Intrinsic Pathway)

CamScanner

- APTT and BT raised – VWBD (Intrinsic Pathway)
- All 3 raised -- DIC
- Only BT raised – ITP (Low Platelets) or Platelets Function Defect (Platelets count normal)
- Heparin monitoring is done by – APTT (Intrinsic Pathway)
- Warfarin monitoring is -- INR > PT (Extrinsic Pathway)

67. International normalized ratio INR is use for:

A- Monitoring of heparin therapy
B- Monitoring of LMWH therapy
C- Monitoring of Oral anticoagulant therapy
D- Monitoring of IV warfarin therapy
Ans: C

Explanation:
- Heparin monitoring is done by—APTT (Intrinsic Pathway)
- Heparin is given – IV
- Warfarin monitoring is – INR > PT (Extrinsic pathway)
- Warfarin in given – Orally

68. A patient presented with epistaxis, excessive bleeding and increase bleeding time this is due to which of following?

A- Decrease Collagen
B- Decrease Ca
C- Increase Collagen
D- Decrease Platelets
E- Decrease Iron
Ans: D

69. 21 Year old boy diagnosed with leukemia he has to undergo bone marrow biopsy patient bone marrow is taken from which of following?

A- Sternum
B- Femur
C- Sacrum
D- Tibia
E- Clavicle
Ans: A (No option of illiac crest)

Explanation:
First – Posterior illiac crest
- Easily accessible

Second – Anterior superior illiac crest
- Specially in obese

Third – Spinous process of lumbar vertebrae
Fourth –Tibia
- Used in Less than 1 year age
- Medial aspect of upper end of tibia

Fifth – Sternum
- Manubrium or first part of body of sternum

70. Chronic intravascular hemolysis is characterized by:

A- Hemoglobenemia
B- Hemoglobinuria
C- Low haptoglobin
D- Hemosiderinuria
E- Unconjugated bilirubin
Ans: D > B

Explanation:
- Acute intravascular hemolysis – Decrease hepatoglobin > reticulocytosis
- Chronic intravascular hemolysis – Hemosidrinuria > Hemoglobinuria

71. An elderly lady taking rheumatoid arthritis drugs presents with weakness and malaise. Her retic count 0.1 %, HB 9, WBC $2x10^9$ and platelets $20x10^9$ bone marrow is hypercellular Likely cause is:

A- Aplastic anemia
B- Myelofibrosis
C- Leukemia
D- Hemolytic anemia
E- Megaloblastic Anemia
Ans: E>B

Explanation:
- Aplastic anemia – Hypocellular bone marrow
- CML-Cell line increase + Hypercellular bone marrow
- Myelofibrosis – Hypercellular bone marrow
- Megaloblastic anemia – Arthritis medication (methotrexate) cause low folate so megaloblastic anemia occur which also show hypercellular bone marrow.

72. Female pale lethargic do not take any antenatal care during delivery she bleeded heavily which nutrient deficiency?

A- Vitamin K
B- Iron
C- Calcium
D- B12
E- B6
Ans: B

73. Diagnosis of iron deficiency anemia is made by which of the following?

A- Serum iron and tibc
B- Serum ferritin
C- Hb electrophoresis
D- CBC
Ans: B (Davidson)

74. A 10 year old boy pale and lethargic her mother elaborate history of eating mud (pica) what is the underlying cause of eating these thing?

A- Calcium Deficiency
B- Iron Deficiency
C- B6 Deficiency
D- B12 Deficiency
E- Folate Deficiency
Ans: B

75. In hemostasis the word Gain is for:

A- Negative feedback
B- Positive feedback
C- Exagerration of the clotting mechanism
D- Child birth
Ans: C

76. A boy came in OPD with complain of bleeding after tooth extraction her mother give history that her paternal side male uncle have same issue of bleeding due to which factor abnormality:

A- Factor 12
B- Factor 7
C- Factor 5
D- Factor 2
E- Factor 8
Ans: E

77. A girl has repeated admission for joint pain and abdomen pain her mother is pathan has beta thalassemia trait her father is balochi. Hb 10 MCV 70 MCHC decreased diagnosis is

A- Thalassemia major
B- Sickle thalassemia syndrome
C- Thalassemia intermedia
D- G6pd deficiency
E- Thalassemia trait
Ans: B

78. N2O prolong exposure, human have increased risk of:

A- Leukemia
B- Megaloblastic anemia
C- Aplastic anemia
D- Iron deficiency anemia
Ans: B

79. Patient presented with lethargy generalized weakness, easy bruisibility, fever, Hb 5.6gm/dl, Platelets 30,000, TLC 3400 and Retic count 0.1 is most likely suffering from:

A- Megaloblastic anemia
B- Dengue
C- Aplastic anemia
D- Hemolytic anemia
E- IDA
Ans: C

80. In Leukemia eye involvement in which percentages?

A- 80
B- 40
C- 30
D- 60
Ans: A

81. Prothrombin time is useful in which of these?

A- Jaundice
B- Hemophilia
C- Cholestasis
D- ITP
E- Antibiotic overuse
Ans: A

82. Which blood group is transfused successfully without reaction and can be used?

A- O Negative to A Negative
B- AB Positive to A Positive
C- AB Positive to B Positive
D- B Positive to O Negative
Ans: A

83. How to differentiate cells in myelocytic stage:

A- Staining of granules
B- CD34 positive
C- CD33 negative
D- No specific marker
Ans: A

Explanation:
- Myelocytic stage cell – Staining of granules
- Hematopoietic stem cell – CD34

84. Patient present with fatigue, Pallor and generalized body weakness and diagnosed as iron deficiency anemia, blood picture will show?

A- Low MCV, low MCH, high MCHC
B- High MCV, high MCH, high MCHC
C- Low MCV, high MCH, high MCHC
D- Low MCV, low MCH, low MCHC
E- High MCV, high MCH, low MCHC
Ans: D

Explanation:
- All three parameters low – Microcytic hypochromic anemia (Iron deficiency anemia)
- All three parameters high – Macrocytic/ megaloblastic anemia
- All three parameters normal – Normocytic normochromic anemia.

85. In thalassemia what's true?

A- Decrease iron
B- Increase iron
C- Decrease folic acid
D- HbF decrease
Ans: B

CamScanner

86. Iron deficiency anemia, glossitis, cheilosis are the features of:
A- Mallory -Weiss syndrome
B- Hirschsprung disease
C- Plummer Vinson syndrome
D- Menetrier Disease
E- Zollinger -Ellison Syndrome
Ans: C

87. A patient presented with low grade fever night sweat and enlarge cervical lymph node lacunar cells with few reeds sternberg cells seen which type it is:
A- Lymphocytes Predominant
B- Lymphocytes Depleted
C- Nodular Sclerosing
D- Mixed Cellularity
Ans: C (Pathoma + FA)

Explanation:
- Reed Sternberg cell seen in hodgkin lymphoma and lacunar cells seen in Nodular sclerosis which is substype of Hodgkin lymphoma
- Lymphocyte Rich – Best prognosis
- Lymphocyte Depleted – Poor prognosis
- Lymphocyte Predominance – Popcorn cell
- Nodular sclerosis – Lacunar cell
- Mixed cellularity – Abundant Eosinophils.

88. Which one of the following is responsible for blood clot retraction?
A- Fibrin
B- Platelets
C- Monocyte
D- Histamine
E- Basophil
Ans: B

Explanation:
Platelets release thrombosthenin which causes retraction of platelets.

89. Polycythemia vera different from other types of Polycythemia in:
A- Erythropoietin abnormality
B- Platelets defect
C- RBC production
D- WBC defect
Ans: A

Explanation:
In polychthemia vera EPO low vs Secondary polycythemia in which EPO high.

90. Cells least abundant in circulating blood:
A- Basophils
B- Pluripotent stem cells
C- T cells
D- B cells
Ans: B

Explanation:
Least Circulate in Blood – Pleuri potent Stem cell > Basophil (Clinical Book).

91. A Mother with blood group A+ gave birth to a baby with blood group O-. His father is O-. What will be chance of hemolytic reaction in newborn?
A- Newborn will not develop erythroblastosis faetalis
B- Newborn will develop temporary erythroblastosis faetalis
C- Newborn will develop permanent erythroblastosis faetali
D- Newborn will develop erythroblastosis faetalis after month
Ans: A

92. Which factor helps in initiation of both intrinsic and extrinsic coagulation pathway?
A- Ca++ factor 4
B- Thromboplastic
C- Factor 2
D- Factor 7
E- Factor 12
Ans: A

93. Hall mark of vitamin B12 deficiency is:
A- Peripheral neuropathy
B- Hypersegmented neutrophils
C- Macrocytic anemia
D- Megaloblastic
Ans: B

94. A boy presented with bleeding gums, epistaxis and petechiae on cornea, which test will b done for definitive diagnosis?
A- Bone marrow biopsy
B- Complete blood count
C- Cultures
D- Electrophoresis
Ans: A

95. The deficiency of Christmas factor causes?
A- Increase Bleeding time
B- Increase APTT
C- Increase PT
D- Decrese APTT
Ans: B

96. Child having bleeding after circumcision and raised level of APTT, Diagnose most likely is:
A- VWD
B- Haemophilia A
C- DIC
D- Sepsis
Ans: B

Explanation:
- Haemophilia: Raised APTT
- ITP: Raised BT
- VWD: Raised BT And APTT DIC
- DIC: Raised PT, APTT, BT &FDP

97. Small amount of blood loss for longer period of time:
A- Microcytic Hypochromic
B- Macrocytic Normochromic
C- Megaloblastic anemia
D- Normocytic Normocytic
Ans: A

98. A patient With Low HB, macrocytic RBC and hypersegmented neutrophils with raised MCV likely Diagnose is:
A- Iron deficiency anemia
B- Megaloblastic anemia
C- Thalasemia
D- Sideroblastic anemia
Ans: B

99. Natural anti thrombotic:
A- Heparin
B- Plasminogen
C- Rivaroxaban
D- Warfarin
Ans: A

Explanation:
- Natural antithrombin - Heparin
- Natural thrmobolytic - Plasminogen

100. Thrombin converting fibrinogen to fibrin release:
A- Fibrinopeptide
B- Plasminogen
C- Heparin
D- Mast cell
Ans: A

101. Patient has anemia and hypersegmented neutrophils are present on peripheral blood examination he is also having difficulty in balance which type of anemia he is suffering from?
A- Folic acid Deficiency
B- Iron Deficiency
C- Pernicious
D- B12 Deficiency
E- Autoimmune hemolytic
Ans: D

Explanation:
- Megaloblastic anemia Shows Hypersegmented Neutrphil
- Most common cause is -Folic acid Deficiency
- Anemia +Neurological sign -B12 Deficiency

102. A young girl with history of gum bleed and menorrhagia. Her peripheral blood smear shows large platelets and platelet count is 1,20000/L. What is the diagnosis?
A- TTP
B- ITP
C- Spurious thrombocytopenia
D- Bernard soulier syndrome
Ans: D

Explanation:
- ITP – Vaccination + Large platlets + marked low platlets
- Bernard – Large platlets + Normal or slight low platelets

103. Hb 4.5 with indirect jaundice 4 and reticulocytes 10 most likely:
A- IDA
B- Hemolytic anemia
C- Thalassemia
D- Siderblastic anemia
Ans: B

104. Most common cause of pernicious anemia:
A- Autoimmune Atrophic gastritis
B- Complete removal of stomach
C- Pancreatitis
D- Acute gastristis
Ans: A

105. Hair on end appearance on X – Ray what is the next appropriate test for diagnosis?
A- HB electrophoresis
B- Bone marrow biopsy
C- Bone scan
D- Peripheral blood smears
Ans: A

106. What is the most appropriate treatment of VWD?
A- FFP
B- Cryoprecipitate
C- Factor 9
D- Vitamin k
Ans: B

107. Which of the following has autosomal dominant inheritance?
A- G6PD
B- Thalassemia
C- Hereditary spherocytosis
D- Cystic Fibrosis
Ans: C

CamScanner

108. A boy had finger cut bleeding, which of the following is the first homeostatic response to control the bleeding:
A- Vasodilation
B- Endothelial contraction
C- Vasoconstriction
D- Endothelial retraction
Ans: C

109. Young girl 18 year age with malaise and weight loss from, last 6 month on peripheral smear blast cell is present and splenomegaly:
A- CML
B- CLL
C- ALL
D- Hairy luekemia
Ans: C

110. DIC is common presentation of:
A- AML
B- ALL
C- CML
D- CLL
Ans: A

111. What will be given in factor 9 deficiencies?
A- PCV
B- FFP
C- Octreotide
D- Cryoprecipitate
Ans: B

Explanation:
- Factor 9 alternative – FFP
- Factor 8 alternative – Cryoprecipitate
- Cryoprecipitate has – Factor 8+13
- FFP has – Factor 9

112. Patient having pallor fatigue raised mcv hyper segmented neutrophils most common cause:
A- B12 Deficiency
B- Folate Deficiency
C- Iron Deficiency
D- Calcium Deficiency
Ans: B

Explanation:
- Most common cause of megaloblastic anemia – Folate deficiency
- If Sign of peripheral neuropathy present then – B12 Deficiency.

113. Auer rods are positive in:
A- AML
B- ALL
C- Hodgkin Lymphoma
D- Non Hodgkin lymphoma
Ans: A

114. Pregnant lady come to clinic her first her HB level 12mg/dl after 2 months Her hb level is 10mg/dl what is the cause:
A- Heamodilution
B- Microcytic hypochromic anemia
C- Macrocytic anemia
D- Hemolytic anemia
Ans: A

115. A girl with finger cut main point where both extrinsic and Intrinsic pathway meet:
A- Factor 10
B- Platelet factor
C- Factor 7
D- Factor 9
Ans: A

116. Pregnant lady with koilonychias blood picture will show?
A- Decrease MCV MCH
B- Decrease MCV inc MCH and MCHC
C- Increase MCV dec MCH and MCHC
D- Increase MCV MCH
Ans: A

117. 18 year old female with menorrhagia epistaxis and markedly decreased platelet count with Giant platelets:
A- ITP
B- Bernard soulier syndrome
C- TTP
D- DIC
Ans: A

Explanation:
- ITP -Post Vaccine + Low Platlets count +Giant Platlets
- Bernard - Giant Platlets +Normal or Slight low platlets count

118. True about monocyte:
A- Develop from sam precursor with neutrophils
B- Develop by stimulation from erythropoietin
C- Move from blood stream to tissue and back to blood stream
D- Are active phagocytes in blood?
Ans: A

119. A 6 year old child presented with who complain bleeding after minor injury his mother give history of profuse bleeding during the time of jarma (circumcision) which one give you clue of this condition:
A- PT
B- APTT
C- Factor 8 minor
D- BT
Ans: B

120. RBC breakdown will result in:
A- Increase biliverdin in feces
B- Increase urobilinogen in urine
C- Release of globulin
D- Release of iron which can be reutilized
Ans: D

121. Intravascular coagulation first activated factor:
A- Factor 12
B- Factor 8
C- Factor 9
D- Factor 2
Ans: A

122. PT is used for:
A- Beri beri
B- Jaundice
C- Scurvy
D- Haemophilia
Ans: B (Liver Disease)

123. During intravascular hemolysis, free hb binds with:
A- Hemopexin
B- Haptoglobin
C- Albumin
D- Globulins
Ans: B

124. 10 years old girl presented with swollen joints after history of trauma, clotting profile shows prolongation of BT and APTT she has most likely deficiency of:
A- Factor 8 minor components
B- Factor 8 major components
C- Factor 7
D- Hagman factor
Ans: B

125. Shape of RBCs is maintained through:
A- Integrins
B- Cdherins
C- Spectrin
D- Interleukins
Ans: C

126. In sickle cell anemia, RBCs are spherical shaped, it is due to defect in:
A- Cytoskeleton
B- Blood vessels
C- Spleen
D- Integral proteins
Ans: A

127. In case of thalassemia major:
A- Increased iron
B- Decrease iron
C- Decrease ferritin
D- Increase TIBC
Ans: A

Explanation:
(In case of thalassemia major there is increased iron, ferritin and decrease TIBC and transferrin)

128. Child is pricked by large bore needle, cause of excessive bleeding:
A- Thalasemia
B- Hemophilia
C- Von jerkie disease
D- ITP
Ans: B

129. A solider present with 3 months history of fever, easy faigue ability O/E hepatosplenomegaly and lymphadenopathy present. Labs reveal anemia hx of biten by fly, diagnosis?
A- CML
B- Flariasis
C- Schistosomiasis
D- Leishmaniasis
E- Malaria
Ans: D

130. A pragnant lady comes to you for antenatal checkup, having risk of preterm delivery, baby having low s.ferritin which deficiency?
A- Vit. B-12
B- Iron
C- Folic acid
D- Calcium
Ans: B

131. Repeated blood transfusion increases the risk of?
A- Hypercalcemia
B- Erythrosis
C- Air embolism
D- Hemosiderosis
Ans: D

132. Vitamin k affects which factors?
A- Factor 8
B- Factor 12
C- Factor 2
D- Factor 4
Ans: C

Explanation:
- Factor 2 7 9 10

133. A young female taking analgesics for back ache presented with gum bleeding epistaxis. She has fever 101 mild jaundice and hepatosplenomegaly. Hb 9 TLC 7000 neutropenia thrombocytopenia. On smear immature cells. Diagnosis?
A- Drug induced anemia
B- Aplastic anemia
C- Acute leukemia
D- Chronic viral hepatitis
E- Thalassemia minor
Ans: A

CamScanner

134. Fisherman presents with gum swelling and purpura. Likely cause:
A- Vitamin K deficiency
B- Vitamin B12 deficiency
C- Vitamin C deficiency
D- Vitamin D deficiency
Ans: C

Explanation:
- Fisherman With Anemia + Echymosis – Vitamic C deficiency
- Fisherman With Anemia – B12 Deficiency – Diphyllobothrium

135. Female hand cut with knife, doesn't heal properly since last two weeks, Wound is clean but presented with fever, Hb 5 RBS 130mg/dl what's the probable cause?
A- Anemia
B- Protein deficiency
C- Diabetes mellitus
D- Infection
Ans: A (Very low hb and wound clean so anemia better than infection)

136. Regarding platelet:
A- Count increase after splenectomy
B- Have a half-life of about 10 days
C- Count decrease after splenectomy
D- Half-life 15 days
Ans: A

Explanation:
- Platelets count increase after splenectomy
- Half-life is 4-5 days

137. Most common cause of inherited thrombophilia?
A- Protein c deficiency
B- Protein S deficiency
C- Factor V mutation
D- Antithrombin deficiency
Ans: C

138. A patient has tingling sensations n his peripheral body and lab investigation reveal raised MCV. What is the most probable pathology?
A- Pernicious anemia
B- Folic acid deficiency
C- Vitamin B12 deficiency
D- Vitamin C deficiency
Ans: C

139. No agglutinin is present in blood group:
A- AB+
B- AB–
C- O+
D- O-
Ans: A

140. 30 year old female patient with MCV less than 70 and low serum ferritin likely diagnose:
A- Iron deficiency anemia
B- Anemia of chronic disease
C- Sideroblastic anemia
D- Lead poisoning
Ans: A

141. A patient presented with splenomegaly upto T10 and increase WBC count with mature cells which translocation defect occur?
A- 9:22
B- 8:21
C- 14:1
D- None
Ans: A

Explanation:
For CML splenomegaly + Raise TLC + Mature granulocytes + pheledelphia chromosomes

142. Iron stored in the form of:
A- Ferritin
B- Ferrous
C- Ferric
D- Hemosiderin
Ans: A

Explanation:
- Iron Transport form – Transferrin
- Iron excess storage form – Hemosiderin
- Iron normal storage form – Ferritin

143. A patient having Polycythemia with facial congestion and splenomegaly likely raised in this patient is:
A- Increase ESR more than 50%
B- Increase Hematocrit
C- Increase RBC Mass
D- Increase RBC Concentration
Ans: C

144. What is the characteristic feature of disease G6PD deficiency?
A- Chronic hemolysis
B- Self-limiting hemolysis
C- Low haptoglobulin
D- Hemosiderinuria
E- Unconjugated bilirubin
Ans: B

145. Child with multiple transfusions enlarged spleen hematocrit 12 % likely suffering from:
A- Thalassemia major
B- Thalassemia minor
C- Sickle cell anemia
D- Iron deficiency anemia
Ans: A

146. A 20 yr old young girl presented with progressive pallor easy fatigueability and lethargy ,her peripheral blood film showed absolute lymphocytes with more than 85 % lymphocytes the most likely diagnosis is?
A- Acute lymphoblastic leukemia
B- Aplastic anaemia
C- Chronic lymphocytic leukemia
D- Infectious mononucleosis
Ans: D

147- Characteristic diagnostic test for folate deficiency in megaloblastic anemia by:
A- RBC folate level
B- Blood folate level
C- Megaloblastic erythropoiesis
D- Bone marrow folate
Ans: A

148- Hypercellular bone marrow is seen in:
A- Aplastic anemia
B- Myelodysplastic syndrome
C- Pernicious anemia
D- Fanconi anemia
Ans: B

149- Bone marrow tap of patient with ITP shows:
A- Increase megakaryocytes in bone marrow
B- Decrease megakaryocytes in bone marrow
C- Increase myoblast in marrow
D- Dry tap of bone marrow
Ans: A

150- 11 Years old child was presented with worsening pallor hepatosplenomegaly having HB of 5g/dl, most likely he is suffering from:
A- Iron deficiency anemia
B- Sideroblastic anemia
C- Thalassemia minor
D- Thalassemia major
Ans: D

151- Which factor activates after external injury?
A- Factor III
B- Factor VIII
C- Factor XII
D- Factor VII
Ans: D

Explanation:
This is extrinsic pathway involves factor VII. The intrinsic pathway is activated by trauma inside the vascular system, and is activated by platelets, exposed endothelium, chemicals, or collagen.

152- Most important test to differentiate iron deficiency anemia from beta thalessemia trait?
A- Serum ferritin
B- TIBC
C- HbF
D- HbA2
Ans: D

153- Regarding hereditary spherocytosis shape:
A- RBC membrane defect
B- RBC oval shape
C- RBC protein defect
D- Decreased osmotic fragility
Ans: A

154- Thalassemia in Pakistan:
A- 5%
B- 10%
C- 15%
D- 20%
Ans: A

155- Ineffective erythropoiesis occurs in:
A- Anemia of chronic disease
B- Erythro blastosis foetalis
C- HS
D- Sickle cell
E- B thalassemia
Ans: E

156- Christmas disease increase bleeding what will be raised?
A- APTT
B- BT
C- PT
D- Both PT & BT
Ans: A (Haemophilia B)

Explanation:
- Haemophilia - Raised APTT
- ITP - Raised BT
- VWD - Raised BT and APTT
- DIC - Raised PT, APTT, BT & FDP

157- Least cell in blood smear:
A- Lymphocytes
B- Monocytes
C- Basophils
D- Reticulocytes
Ans: C

158- Reed Sternberg cell seen in:
A- Hodgkin lymphoma
B- Lymphocyte depleted
C- Non Hodgkin
D- Lymphocyte rich
Ans: A

CamScanner

Explanation:

- Lymphocyte Rich – Best prognosis
- Lymphocyte Depleted – Poor prognosis
- Lymphocyte Predominance – Popcorn cell
- Nodular sclerosis – Lacunar cell
- Mixed cellularity – Abundant Eosinophils.

159- Characteristics of hogkin lymphoma:

A- Nodular spread
B- Contagious spread
C- Has leukemoid reacation
D- Associated with HTLV
Ans: B

160- VWF disease BT and APTT deranged problem:

A- Platelet aggregation
B- Platelet adhesion
C- Platelet production
D- All of the above
Ans: B

161- Most common cause of B12 deficiency in adult is?

A- Pancreatic insufficiency
B- Dietary intake
C- Celiac diseases
D- Pernicious anaemia
Ans: D

162- Poor prognostic factor for burn patient is:

A- DIC
B- Shock
C- Hypoxia
D- Hyponatremia
Ans: A

163- Rh negative mother delivered a baby at 34 weeks with anemia pallor. Baby died 6 hours after transfusion. Autopsy findings?

A- Basal ganglia staining
B- Cardiac malformations
C- Hydrops fetalis
D- None of the above
Ans: A

164- Regarding Neutrophils correct statement is:

A- Migrate into & out of blood
B- More phagocytic in blood stream
C- Decrease in infective condition
D- Decrease when corticosteroid given
Ans: B

165- Warfarin Mechanism of Action:

A- Competitively inhibits the vitamin K epoxide reductase complex 1 (VKORC1)
B- Non-competitively inhibits Vitamin D reductase
C- Directly inhibit Factor 12
D- Indirectly inhibit factor X
Ans: A

Explanation:

Warfarin competitively inhibits the Vitamin K epoxide reductase complex 1 (VKORC1), which is an essential enzyme for activating the vitamin K available in the body. Through this mechanism warfarin can deplete functional vitamin K reserves and therefore reduce the synthesis of active clotting factors.

166– Immediate reversal of Warfarin toxicity:

A- FFPs
B- Vitmain K
C- Whole blood
D- Platelets
Ans: A

Explanation:

Immediate reversal of Warfarin best choice would be both FFP & vitamin K but when one to choose it's FFP > Vitamin K.

167- A very young age patient presented with fever & his WBC were increased 5fl folds is most likely suffering from:

A- ALL
B- AML
C- CML
D- CLL
Ans: A

Explanation:

AML is commonly seen in young age patient.

168- Blood group antigens are:

A- Equally immunogenic
B- Present on Hb surface
C- Present on the RBC Surface
D- Autosomal dominant
Ans: C

Explanation:

Follow the following order for blood group antigens: RBC Surface > Glycoprotein > Immunogenic > Dominant Mendalian.

169- A pregnant lady presented with low MCV, Low MCHC, normal iron study profile which of the following need to be done in order to diagnose the case:

A- HbA2
B- Ferritin
C- Iron profile
D- Transferrin Saturation
Ans: A

170- Fibrinogen is converted to Fibrin which of the following product is released?

A- Fibrinopeptide A
B- FibrinoPeptide B
C- Laminin
D- Cadherin
Ans: A

Explanation:

Fibrionpeptide A is a 16-Amino acid cleavage product of thrombin induced proteolytic cleavage of fibrinogen.

171- A newborn after few hours of birth presented with active bleeding, which of the following could be the possible management:

A- Vitamin K Administration
B- Whole Blood
C- Platelets
D- Cryopreciptate
Ans: A

Explanation:

In a newborn the gut is sterilized & not properly developed that's why there is not enough bacteria to synthesis vitamin K.

172- Hodgkins disease spread to lymph nodes through:

A- Contagious spread
B- Non contagious Spread
C- Invasion
D- Distant spread
Ans: A

Explanation:

- Hodgkin's disease spread through contagious spread
- Non-Hodgkin's disease spread through non-contagious spread

173- A boy after circumcision has history of profuse bleeding, which of the following factor will confirm the diagnosis:

A- APTT
B- PT
C- Factor 8 (Minor
D- Factor 8 (Major)
Ans: C

Explanation:

- For hemophilia initial diagnosis is: APTT
- Confirmatory test for hemophilia: Factor 8 (Minor)

174- A 20 years pregnant lady who is Rh negative gives birth to Rh negative baby, shee has history of allergic reactions. Due to bleeding she was advised transfusion but she was transfused with Rh positive blood accidently. Which of the following is true:

A- Anti D antibodies must be given immediately to lady
B- Next baby may develop hemolytic Anemia
C- No reaction will occur
D- No need to give Anti D antibody
Ans: A

Explanation:

According to NICE guidelines any contact of Rh Positive blood with Rh negative mother or in case of any sort of placental abruption or delivery complication the mother must be transfused with Anti D on immediate basis.

175- A patient having ecchymosis & reduced platelet count is suffering from:

A- Hemophilia
B- ITP
C- TTP
D- VwD
Ans: B

176- Which of the following most common bleeding disorder from female carrier to male born?

A- VwD
B- Hemophilia
C- Bernard soulier syndrome
D- ITP
Ans: B

Explanation:

Hemophilia is X-Linked disorder that's transferred from mother to male babies.

177- A person living at a high altitude is most likely to have:

A- Increase Hemoglobin
B- Decrease Hemoglobin
C- Pedal edema
D- Renal failure
Ans: A

Explanation:

- People at high altitude have secondary polycythemia due to decrease PO2.

178- Child presents with active bleed from umbilical stump, which of the following vitamin deficiency?

A- Vitamin A
B- Vitamin K
C- Vitamin C
D- Vitamin D
Ans: B

CamScanner

Explanation:
- Newborn have deficient GIT flora that's why there's mostly vitamin K deficiency.

179- Blood stem cells maturation is stimulated by:
A- Erythropoetin
B- Growth Factors
C- Cortisol
D- Testosterone
Ans: B

Explanation:
- RBCs production is stimulated by Erytropoetin.
- Other cells are stimulated by Growth Factors.

180- Low MCV is seen in which of the following?
A- IDA
B- Thalassemia
C- Anemia Of chronic disease
D- Megaloblastic anemia
Ans: A

181- Platelet adhesion to endothelium is caused by:
A- Smooth endothelial surface
B- Rough endothelial surface
C- Increased Hydrostatic pressure
D- Thrombocytosis
Ans: B

182- Rh Blood group antigen present on:
A- Not present in tissues other than blood
B- Autosomal recessive
C- Present on Hemoglobin
D- Present on RBC surface
Ans: D

Explanation:
Rh blood group antigen is found on RBC surface > Glycoprotein > Immunogenic > Dominant Mendalian Inheritance.

183- Bradykinin involves which of the following system?
A- Kallikrin System
B- Coagulation pathway
C- Fibrinolytic System
D- None of the above
Ans: A

184- Aplastic anemia diagnosis is done by which of the following?
A- Bone marrow Biopsy
B- Blood Smear
C- CBC
D- USG
Ans: A

185- A boy with tender knee & bleeding history which of the following test will confirm the diagnosis?
A- BT
B- PT
C- Factor 8 Assays
D- Platelet count
Ans: C

Explanation:
- This is case of hemophilia & the confirmatory/diagnostic test is Factor 8 Assay while initial test is APTT.

186- Anti H antibodies are present in which blood group?
A- A +ve
B- B +Ve
C- OH
D- AB +Ve
Ans: C

187- Pregnant lady in 1st trimester having Hb of 10 gm/dl, on 3rd trimester having Hb of 9 gm/dl most likely due to:
A- IDA
B- Thalassemi
C- Physiological change
D- Sideroblastic Anemia
Ans: C

188- Before starting oral anticoagulant warfarin therapy, what test should be performed in order to analyze Warfarin activity?
A- PT/APTT
B- INR
C- APTT
D- PT/INR
Ans: D

189- Which of the following translocation is seen in AML?
A- t (8:14)
B- t (8:21)
C- t (9:22)
D- t (11:14)
E- t (X:18)
Ans: B

Explanation:
- 8 :14 burkitt lymphoma
- t(11;14) Mantle cell lymphoma (cyclin D1 activation)
- t(11;18) Marginal zone lymphoma
- t(14;18) Follicular lymphoma (BCL-2 activation)
- t(15;17) APL (formerly M3 type of AML)
- t(9;22) (Philadelphiachromosome)
- CML (BCR-ABL hybrid), ALL (less common);

190- B-Lymphocytes produce which type of cells?
A- Monocytes
B- T-cells
C- Neutrophils
D- Plasma Cells
Ans: D

191- A 64 years old female with fatigue, easy bruisibility after small cuts and recurrent infection alongside fever from 2 weeks. After investigations the report shows blast cells and Auer bodies in smear. What is the likely diagnosis?
A- Acute promyeloblastic leukemia
B- Acute lymphoblastic leukemia
C- Acute myeloid leukemia
D- Non Hodgkin lymphoma
E- Aplastic anemia
Ans: C

192- A 70 years old lady admitted into a hospital for long time is at high risk of developing:
A- Respiratory disease
B- Carcinoma
C- DVT
D- Aortic aneurysm
Ans: C

193- A young patient with Hb level: 4.5 g/dl WBC: 7000cells/cmm. Raised platelets and bilirubin. On blood smear there was polychromasia and raised relics. Diagnostic investigation will be:
A- Coomb's Test
B- Blood Culture
C- Urine Culture
D- Osmotic fragility test
Ans: A

194- What is the first step in hemostasis after a vascular injury?
A- Fibrin formation
B- Vascular vasodilation
C- Vascular vasoconstriction
D- Platelet aggregation
E- Complement system activation
Ans: C

195- A 48-year-old woman presents with fever from 3 days. She also complains about urinary frequency besides loin (flank) pain. The white blood cells count is 35,000/cmm. What is the next best step?
A- Urine culture
B- Blood culture
C- CBC
D- ESR
E- Urine and blood culture
Ans: E

196- A young patient underwent surgery of metallic valve replacement. He was sent home on regular drugs but he presented with nose bleed (epistaxis) just 2 hours later. His platelets and Hb counts are low and PT is prolonged. What is the cause?
A- Idiopathic
B- Traumatic
C- Drug-induced
D- Failed surgery
Ans: C

197- A patient presents to clinic with his Hb level being 4 g/dl and Coomb's Test positive. What is the cause?
A- G6PD Deficiency
B- Autoimmune Hemolytic Anemia
C- Megaloblastic anemia
D- Pernicious anemia
Ans: B

198- In ITP which derangement is most common?
A- Bleeding Time
B- PT
C- A-PTT
D- Hb level
Ans: A

199- 7th month pregnant lady with chronic ITP having ecchymosis and epistaxis. Her platelets count 5*10 and on full steroid dose what will be next suitable step?
A- IV immunoglobulin
B- Immunosuppressant's
C- Splenectomy
D- Steroids
Ans: A

200- A patient feels sensation of numbness in his extremities. His labs reveal Hb level 8g/dl, MCV 110 fl, Platelet count 50x10^9/L and TLC 3.4X10^3/L. What is the diagnosis?
A- Pernicious anemia
B- Sickle cell anemia
C- Normocytic anemia
D- Megaloblastic anemia
Ans: D

201- A patient presents with tingling sensation and spastic contraction, he is a case of:
A- Vitamin B12 deficiency
B- Tetany
C- UMN Lesion
D- LMN Lesion
Ans: B

CamScanner

202- Which of the followings is elevated in nasal polyps?
A- Macrophages
B- Neutrophils
C- Monocytes
D- Eosinophil
Ans: D

203- Arterial blood as compared to venous blood has:
A- Increase PO2
B- More packed cell volume
C- Decrease bicarbonate
D- Increase chloride
Ans: A
Explanation:
- Venous Blood has more HCO3
- In Venous blood RBC has more Cl &PCV
- Arterial Blood has more O2

204- A female presented with menorrhagia and her platelet count is 30,000 mcL, which antibody test should be done?
A- ANA
B- Antimitochondrial antibody
C- Antimicrosomal antibody
D- Heterophile sheep antibody
E- Antiplatelet antibody
Ans: E
Explanation:
She is a case of ITP.

205- Which of the following proteins maintain the biconcave shape of the RBC?
A- Spectrin
B- Band 3
C- Ankyrin
D- C3b
Ans: A

206- In uremic nephropathy there is:
A- Hypochromic Normocytic anemia
B- Normochromic Normocytic anemia
C- Micro chromic Normocytic anemia
D- Megaloblastic anemia
Ans: B

207- Which laboratory test would be suitable for Vitamin K related factors?
A- APTT
B- PT
C- BT
D- CT
Ans: B

208- The type of anemia that occurs gastrectomy is termed as:
A- Sickle cell anemia
B- Hemolytic anemia
C- Pernicious anemia
D- Normocytic anemia
Ans: C

209- The nature of agglutinins is:
A- Keratin
B- Albumin
C- Glycoprotein
D- Globulins
Ans: C

210- Which of the following is always low in anemia?
A- Low MCV
B- High TIBC
C- Low Hemoglobin
D- High hemoglobin
Ans: C
Explanation:
Low hemoglobin is found in all types of Anemia while MCV & TIBC maybe increased or decreased in various types of Anemia.

211- Increase PCO2 in venous blood, will lead to:
A- Decrease chloride concentration in RBC
B- Increase affinity for Hb
C- Decrease HCO3 concentration in blood
D- Increase volume of RBC
Ans: D

212- In Rh Blood group, Rh agglutinins:
A- Are always present in Rh negative blood
B- Are predominantly 1 gm
C- Are present on red cell membrane
D- Develop in Rh negative woman pregnant with Rh positive fetus
E- Do not cross the placenta in the trimester of pregnancy
Ans: D

213- Hemoglobin synthesis begins at which stage?
A- Early normoblast
B- Intermediate normoblast
C- Late normoblast
D- Reticulocyte
Ans: A
Explanation:
- Hemoglobin synthesis starts at Normoblast, prefer proerythroblast present in options
- In intermediate normoblast hemoglobin starts to appear
- In late normoblast nucleus disappear
- Reticulocyte contains the highest amount of Hemoglobin

214- Vitamin-K dependent factor:
A- Factor 12
B- Factor 5
C- Calcium
D- Prothrombin
Ans: D
Explanation:
Vitamin K dependent factors are 2, 7, 9, 10.

215- Normal adult hemoglobin:
A- Gower Hb
B- HbA
C- HbF
D- HbS
E- HbA2
Ans: B

216- A patient with HB 6, platelet count 450,000, with hyper cellular bone marrow, diagnosis is:
A- Drugs using for anemia
B- Leukemia
C- Iron def. anemia
D- G6pd def.
E- Acute blood loss
Ans: C

217- A young female presented with fever 101 degree, gum bleeding, petechiae and epistaxis. Best test to diagnose is:
A- CBC
B- Bone marrow biopsy
C- Coagulation profile
D- CT/BT
E- Electrophoresis
Ans: B

218- Some neoplasms appear to develop from viral oncogenesis. Which of the following neoplasms is most likely to arise in this manner?
A- Retinoblastoma
B- Small cell carcinoma
C- T-cell leukemia
D- Prostatic adenocarcinoma
E- Hepatic angiosarcoma
Ans: C

219- 41% hematocrit means:
A- 41% of formed elements are RBC
B- 41% of blood is Hb
C- 41% of blood volume is RBCs,WBCs,and platelets.
D- None of the above
Ans: A

220- An 11 years old boy presented with bleeding after minor trauma. Her siblings have same issue. His Pt. time is normal but Aptt and bleeding time is prolonged. What is the cause?
A- Platelet Deficiency
B- Intrinsic pathway
C- Extrinsic pathway
D- Liver failure
Ans: B
Explanation:
This is the case of Von willebrand disease which is intrinsic pathway coagulation defect i.e. dec. level of vW factor so no platelet plug is formed despite of normal Platelet count.

221- A six years old girl presented with iron deficiency anaemia. Her spleen is palpable and frontal bossing is also present. What is the cause of her illness?
A- Malaria
B- Iron deficiency Anemia
C- Thalasemia major
D- Megaloblastic Anemia
Ans: C

222- An old patient presented to the emergency room for a fatigue, dyspnea and chest pain which started yesterday morning. He has been experiencing cough with sputum from many years.WBC 10,000,Hematocrits 25.4%,Haemoglobin 8.4 g/dL,MCV85 fL,Platelets 154,000 and Glucose 124 mg/dL.The clinical scenario is most consistent with which type of anemia?
A- Folate deficiency
B- Megaloblastic anemia
C- Anemia of chronic disease
D- Thalassemia
E- Iron deficiency anemia
Ans: C
Explanation:
Normocytic- Normochromic Anemia

223- A 60-year-old man w/ fatigue, weakness, and exercise intolerance. Labs: Hemoglobin 9.1 mg/dL, Ferritin 9 ng/mL, Mean corpuscular volume (MCV) 110 fL. Diagnosis:
A- Iron Deficiency Anemia
B- Megaloblastic Anemia
C- Sideroblastic Anemia
D- Auto immune haemolytic Anemia
Ans: B

CamScanner

224- A patient with massive spleen. Spleen was palpable below 10th ICS:
A- Myelofibrosis
B- Thalassemia
C- Sickle cell anemia
D- Aplastic anemia
Ans: A

225- Which of the following is consequence of polycythemia Vera?
A- Myelodysplastic syndrome
B- Iron deficiency
C- Megaloblastic
D- Sickle cell
Ans: A.

226- A child with erythroblastosis fetalis having blood group A+ve need Exchange blood transfusion which blood to give?
A- A negative
B- A positive
C- O negative
D- B negative
E- B positive
Ans: A

227- Warfarin affects which of the following pathway of coagulation?
A- Extrinsic
B- Intrinsic
C- Common pathway
D- Extrinsic + Intrinsic
Ans: A

228- A patient with Hb 8, TLC 3.5, PLT 90×10^9. Spleen enlarged 3cm. What investigation you will do to confirm cause of Hypersplenism?
A- Bone marrow biopsy
B- CT spleen
C- UsG abdomen
D- CBC
Ans: A

229- The chance of bleeding in a patient with epidural will be greatest in:
A- Patient on warfarin
B- Heparin
C- LMWH
D- Aspirin
Ans: C

230- An Anemic lady with raticulocyte 10% Jaundice. Peripheral smear shows small spherocytes. Test for diagnosis:
A- Direct coomb's test
B- Indirect coomb's test
C- RBC survival study
D- ANA Antibody
Ans: C

231- As compared to the arterial blood, the venous blood has more:
A- Dissolved oxygen
B- Hemoglobin
C- PH
D- Packed cell volume (PCV)
E- Red cell count
Ans: D

Explanation:
- Venous Blood has more HCO3
- In Venous blood RBC has more Cl &PCV
- Arterial Blood has more O2

232- Following is true regarding blood group antigens:
A- Are present on Hb molecule.
B- Are secreted in saliva
C- Are called agglutinins.
D- Are enzymes.
E- Inherited as autosomal recessive.
Ans: B

233- Monocyte macrophages derived from:
A- Bone marrow
B- Spleen
C- Thymus
D- Lymphoid tissue
Ans: A

234- Normal amount of iron in adult female:
A- 1 gram
B- 2 gram
C- 3 gram
D- 4 gram
Ans: B

235- Regarding lymphocytes:
A- Increase in bacterial infection
B- Not affected by hormones
C- Are monocytes
D- Increase in viral infection
Ans: D

236- Pulse oximeters:
A- Are based on boyle's law
B- Can derive carbon dioxide levels
C- Can differentiate deoxyhemoglobin from oxyhemoglobin
D- Can't differentiate methhemoglobin from oxyhemoglobin
E- Use a single wave length of red light
Ans: D

237- Vitamin K directly influences the reaction:
A- Conversion of fibrinogen to fibrin
B- Prothrombin to thrombin
C- Activation of factor 4
D- Formation of fibrinogen
Ans: B

238- Type of anemia in acute blood loss:
A- Microcytic
B- Normocytic
C- Macrocytic
D- Anemia of chronic disease
Ans: B

239- Continuous transfusion for thalassemia side effect:
A- Hemochromatosis
B- Hyperkalemia
C- Hypokalemia
D- Hypercalcemi
Ans: A

Explanation:
- Massive Transfusion – Hyperkalemia
- Multiple or Continous – Hemochromatosis
- Repeated Transfusion – Hypocalcemia
-

240- Side effects of dicumarol is
A- Delayed clotting
B- Increase bleeding time
C- Decrease clotting time
D- Abnormal clotting
Ans: A

Explanation:
Dicumarol
- Increase PT or Clotting time
- Increase Bleeding tendency

Dimercaprol
- Increase BT

241- 25 year female patient present with re current venous thrombosis and 1 episode of pulmonary embolus her PT , APTT and BT normal, the risk factor for her condition
A- Factor V
B- OCP
C- Protein C Deficiency
D- Anti thrombin 3
Ans: B

242- 9 months old girl was vaccinated 2 weeks back, now presents with rash all over body, fever and CBC report showing Hb 13.5g/dl, wbc 6 x 10 and decreased platelets Peripheral smear shows large platelets. What is the diagnosis?
A- TTP
B- ITP
C- SLE
D- DIC
E- Bernard soulier syndrome
Ans: B

Explanation:
- Vaccination + Low Platelets + Giant Platelets – ITP
- Normal or slight Low Platelets + Giant Platelets + Bernard Soulier Syndrome

243- 19 years old female of southern origin gives birth at 35th weaks baby is slightly hydropic, peripheral blood smear shows nucleated RBCs and some erythrocytes , marked anisocytosis , poikilocytosis eliptocytosis, what's is diagnose
A- Sickle cell
B- Alpha thalassemia
C- Hereditary eliptocytosis
D- G6PD deficiency
Ans: B

244- Patient presented with painful leg ulcer and having howell jolly bodies on smear what is likely diagnose:
A- Hemolytic anemia
B- Sickle cell anemia
C- Pernicious anemia
D- Herditry spherocytosis
Ans: B (FA +Robins)

245- Which of the following decrease in pregnancy?
A- AT3
B- Factor 12
C- Factor7
D- Protein C
E- Factor VIII
Ans: A (Prefer Protein S)

Explanation:
Increase
- Factor VII
- Factor VIII
- Factor X
- VW Factor
- Fibrinogen
- Plasminogen
- a2 macroglobulin

Remain same
- Factor V
- Thrombin(II)
- Protein C
- Anti-thrombin (Rarely decrease by 15%)

Decrease
- Protein S (Fall by 50%)
- Anti-thrombin may fall rarely but mostly remain unchanged.

246- Female patient with Rheumatic fever taking methotrexate develops megaloblastic anemia due to
A- Cobalmine deficiency
B- Viatmin C deficiency
C- Folate deficiency
D- Vitamin K deficiency
Ans: C

CamScanner

247- A Sailor man presented with fever rash on elbow and generalized cervical lymphadenopathy with TLC of 7230 what is suitable diagnose?
A- Infectious Mononucelosis
B- Malaria
C- CML
D- Sarcoidosis
E- Mediterranian Fever
Ans: A

248- Girl comes with increased fatigability with increased pigmentation on all body and splenomegaly having hb 8.1 MCV 58 MCHC 38 and Ferritin 2000. What is suitable management
A- Blood transfusion
B- Defroxamine
C- Zinc
D- Platelets transfusion
E- Dimercaprol
Ans: B

249- In hereditary spherocytosis what is true
A- Cytoskeleton deformity
B- Cartilage defect
C- Collagen defect
D- Cell defect
Ans: A

250- A child has history of pica now having pallor, fatigue and low Hb what is suitable diagnose?
A- B12 Deficiency
B- Thalassemia
C- Iron Deficiency anemia
D- Folate Deficiency
E- Sideroblastic anemia
Ans: C

251- Factor 2,7,9 and 10 deficiency seen in
A- Vitamin C deficiency
B- Vitamin B deficiency
C- Vitamin D deficiency
D- Vitamin K deficiency
E- Vitamin E deficiency
Ans: D

252- 40 year old man with back pain, apple green birefringence & congo stain positive on damage to kidney with monoclonal antibody present He is most likely suffering from?
A- SLE
B- Multiple Myeloma
C- RA
D- Scleroderma
Ans: B

253- Heparin activates which of the following?
A- Factor X
B- Factor IX
C- Anti thrombin 3
D- Plasminogen
Ans: C
Explanation:
- It activates – Antithrombin 3
- It inhibit – Factor X

254- A 2 year old boy present to you he was operated for acute abdomen and found intestinal obstruction with intussusception.His small bowl surgery done.He has now presented to you with anemia and anglular glossitis:
A- Vitamkn B 12 deficincy
B- Iron deficiency anemia
C- Vitamin K deficiency
D- Vitamin C deficiency
E- Vitamin E deficiency
Ans: B

255- Hodgkins lymphoma with mixed cellularity associated with which virus?
A- Parvo virus
B- Adeno virus
C- EBV
D- HPV
Ans: C (FA)

256- A 5 years old male child presented with epistaxis, gum bleeding and bleeding time more than 20 minutes and increased APTT most suitable diagnosis is:
A- VWD
B- Hemophilia
C- Vitamin k deficiency
D- Vitamin c deficiency
E- Platelets defect
Ans: A
Explanation:
- APTT raised only – Hemophilia (Intrinsic Pathway)
- APTT and BT raised – VWBD (Intrinsic Pathway)
- All 3 raised – DIC
- Only BT raised – ITP (Low Platelets) or Platelets Function Defect (Platelets count normal)

257- A patient has anemia Raised MCV 110 he is also having difficulty in balance peripheral numbness and tingling sensation which type of anemia he is suffering from?
A- Magaloblastic anemia
B- Iron deficiency anemia
C- Thalassemia
D- Anemia of chronic disease
E- Sideroblastic anemia
Ans: A
Explanation:
- B12 deficiency cause megaloblastic anemia which is related to Neurological sign of DCML and Balance problem.

258- In caucasian people percentage of O blood group
A- 9%
B- 75%
C- 35%
D- 47%
E- 55%
Ans: D

259- Pregnant lady with complain of DVT at 8 weeks which drug can be given safely?
A- IV Warfarin
B- Oral Warfarin
C- Enoxaparin
D- IV Heparin
Ans: D

260- Factor 7,9 and 10 dependent on which vitamin
A- Vitamin A
B- Vitamin C
C- Vitamin K
D- Vitamin E
E- Vitamin B
Ans: C

261- Iron hemostasis maintained by
A- Transferrin
B- Hepcidin
C- Ferritin
D- Transcobalamine
Ans: B

262- 4 years old child with fever for 2 weeks, Epistaxis and diffuse lymphadenopathy.Hb=5.TLC 100, Platelets=10.This is mostly likely?
A- ALL
B- Infectious mononucleosis
C- Aplastic anemia
D- CLL
E- Hairy leukemia
Ans: A

263- Cause of Petechial hemorrhages <2mm is
A- Vitamin K deficiency
B- Vascular fragility
C- Liver disease
D- Thrombocytopenia
E- Hemophilia
Ans: D

264- In uremia what will increase
A- PT
B- APTT
C- BT
D- Platelets
E- CT
Ans: C

265- A 45-year-old man comes to the emergency department after a motor vehicle accident resulting in a liver hematoma. On the third hospital day, he becomes suddenly short of breath. His chest x-ray is normal, and he is diagnosed with a pulmonary embolus. What is the next best step in management?
A- Angiography
B- Embolectomy
C- Heparin
D- Inferior vena cava filter
Ans: C

266- Regarding O- blood group
A- Has antigen
B- Has No antigen
C- Universal recipient
D- Has no antibodies
Ans: B

267- Patient is suffering from megaloblastic anemia doctor advised inj vitamin B12 IM twice in a week due to deficiency of ?
A- Folic acid
B- Calcium
C- Iron
D- Cobalamine
E- Panthothenic acid
Ans: D

268- Patient presented in ER after RTA spleen was ruptured.Splenectomy done .what will be your findings on peripheral blood smear ?
A- Spherocytes
B- Howel jolly bodies
C- Pancytopenia
D- Blood clots
E- Immune complex formation
Ans: B

CamScanner

269- Factor 8 produced by ?
A- Endothelial cells
B- Parietal cells
C- Chief cells
D- Mucous cells
E- Serous cells
Ans: A

270- Patient started warfarin have petechiae and ecchymosis due to deficiency of:
A- Protien M
B- Protein C deficiency
C- Factor 10
D- Factor 9
Ans: B

271- Low dose aspirin inhibit:
A- Thromboxane A2
B- Cox synthesis
C- Platelet formation
D- Cox 3
Ans: A

272- To access prolonged liver disease in a patient, which test is performed ?
A- Albumin
B- AFP
C- PT
D- APTT
E- Factor V
Ans: A

273- Regarding Burkkit lymphoma true is:
A- Point mutation in RAS oncogene
B- Mutation in C-myc oncogenes
C- Transposition in BCL-2
D- Amplification in N-myc oncogenes
Ans: B

274- To check anti thrombin effect of Heparin which test is used
A- INR
B- PT
C- APTT
D- Factor IX assay
Ans: C
Explanation:
- Warfarin monitoring - INR >PT
- Heparin monitoring – APTT

275- Finger injury which activates kinin and also coagulation by which factor?
A- Histamine
B- Hagman factor
C- Factor 7
D- Factor 5
Ans: B

276- Platelets aggregation mediated by
A- Prostocyclin
B- Prostaglandin
C- Thromboxane A2
D- Endothelium
Ans: C

277- Low molecular weight heparin Inhibits which of the following?
A- Antithrombin 3
B- Factor 10
C- XII
D- Thrombin
Ans: B
Explanation:
- It Activates – Antithrombin 3
- It inhibit – Factor X

278- Most imp feature of platelet is
A- Plug formation
B- Granules
C- No nuclues
D- Derived from bone marrow
Ans: A

279- Which one controls iron homeostasis
A- Ferritin
B- Transferrin
C- Hemosiderin
D- Ferric
Ans: B

280- A patient of jaundice with Total bilirubin 10, direct 9, what is the cause
A- Criggler Najar
B- Gilbert Syndrome
C- Choledocholithiasis
D- Physiological jaundice
E- Cirhosis
Ans: C

281- A lady presented with Jaundice having gall stones which of the following investigation will confirm the diagnosis
A- CPK
B- Bilirubin
C- ALP
D- AST
E- ALT
Ans: C

282- Microcytic hypochromatic anemia ferritin and TIBC normal confirmation Investigation will be
A- Bone marrow boipsy
B- HbA2
C- HbF
D- CBC
Ans: B

283- In intrinsic damage, which factor causes activation of coagulation?
A- Factor 8
B- Factor 12 (Hagman Factor)
C- Factor 9
D- Factor 5
E- Thromboplastin
Ans: B
Explanation:
- Activation of extrinsic path way by Thromboplastin (Tissue factor)
- Activation of intrinsic pathway by –Factor 12

284- Macrophages formed by
A- Plasma cells
B- Histiocytes
C- Monocytes
D- Interferon
Ans: C

285- Woman comes with sudden onset of abdominal pain , low bp , tachycardiac , hb low , conjunctival icterus WBC normal platelets normal , spleen tip palpable . What triggered the above symptoms
A- Cold weather
B- Repeated transfusion
C- Parvo virus
D- Hot weather
Ans: A

286- 2 alpha, 2 beta is characteristic of
A- Fetal Hb
B- Adult Hb
C- Sickle cell anemia
D- Thalasemia
Ans: B

287- A patient has anemia Hb 6 and Raised MCV diagnose of macrocytosis is made by
A- B12 Level
B- Intrinsic factor level
C- Hypersegmented Neutrophils
D- Iron level
Ans: C

288- A patient after Accidents multiple lacerations large lacerations by compress bandge small site bleed after ten mints stop by which mechanism?
A- Hemostasis
B- Platelet plug formation
C- Vasoconstriction
D- Vasodilation
Ans: C

289- A patient has history of bleed and normal CT and Increase BT in
A- Vitamin K deficiency
B- Vascular fragility
C- Liver disease
D- Thrombocytopenia
E- Hemophilia
Ans: D

290- Low grade follicular lymphoma translocation is which of these?
A- t14:18
B- t11:22
C- t15:27
D- t8:21
E- t8:14
Ans: A
Explanation:
- AML – 8:21 and 15:17
- CML – 9:22
- Burkit Lymphoma – 8:14
- Mantle Cell Lymphoma – 11:14
- Follicular Lymphoma – 14:18
- Ewing Sarcoma – 11:22
- Prostatic Carcinoma – 7:21 and 17:21

291- End result of sepsis is
A- Tissue hypoxia
B- Cardiac shock
C- DIC
D- Embolism
E- Angina
Ans: C

292- Composition of normal blood.
A- 1% A2
B- 3% A2
C- 95% HBF
D- 95% A2
Ans: B

294- Treatment of GB syndrome is:
A- IV immuniglobulins
B- Steroids
C- Plasmapharesis
D- Splenectomy
Ans: C

295- Ewing sarcoma involves which chromosomes translocation translocation is which of these?
A- t14:18
B- t9:22
C- t11:22
D- t8:21
E- t8:14
Ans: C

CamScanner

Explanation:
- AML – 8:21 and 15:17
- CML – 9:22
- Burkit Lymphoma – 8:14
- Mantle Cell Lymphoma – 11:14
- Follicular Lymphoma – 14:18
- Ewing Sarcoma – 11:22
- Prostatic Carcinoma – 7:21 and 17:21

296- A lady in Third trimester having AB positive urgent FFP need to be transfused which blood can be used?
A- B positive
B- A positive
C- O negative
D- AB negative
Ans: D

297- A patient having beta thalessmia acute nasal bleeding and ecchymosis came to emergency wbc 18000. D dimer 300> and plt 70*109 what you will give?
A- Normal saline, antibiotics, ffp, Packed Rbcs , Transamine
B- Heparin, normal saline, packed rbs and platelets
C- Transamine, packed rbcs and platelets
D- Dextrose saline
Ans: A

298- Bernard soulier characteristic:
A- Defect in glycoprotein 2a/3b
B- Platelet aggregation
C- Abnormal Ristocetin test
D- Glycoprotein 3b
Ans: C

299- Factor used in vivo coagulation:
A- Factor 7
B- Factor 12
C- Factor 3 tissue thromboplastin
D- Factor 8
Ans: C

300- A patient has HCT 30% due to deficiency of:
A- Vitamins deficiency
B- Minerals deficiency
C- Hb deficiency
D- Cytoskeleton abnormality
Ans: D

301- Natural course of polycythemia vera:
A- Leads to Itching
B- Leads to myelofibrosis
C- Spontaneous remission
D- Benign
Ans: B

302- Thalassemia common in Pakistan:
A- Alpha thalassemia
B- Alpha hydrops
C- Beta thalassemia major
D- Beta thalassemia trait
Ans: D

303- A lady developed DVT after long flight. Test reveal deficient protein C how long will she need anticoagulant treatment:
A- Indefinitely
B- 6 months
C- Till thrombus resolves
D- 3 month
Ans: A

304- Specific of DIC:
A- Increase FDP
B- PT increase
C- Platelets decrease
D- APTT increase
Ans: A

305- Central cyanosis occurs when hb is less than how much percentage?
A- 3gm
B- 2gm
C- 4gm
D- 5gm
Ans: D

306- A child presented with bleeding after minor injury, his pt 14 and aptt 60 After labs investigations his factor 8 was 87% and factor 9 was 7% cause is:
A- Hemophelia A
B- Hemophelia C
C- Christmas disease
D- ITP
Ans: C

307- Patient with acute hepatitis was admitted previously and was given 1 packed RBCs due to low Hb and was sent home. One week later presented with jaundice Raised bilirubin 4 and other symptoms what is reason?
A- Drug induced hemolysis
B- Delayed hemolytic reaction
C- CMV
D- Hepatitis
E- Graft Vs host disease
Ans: B

308- Citrate is used in bleeding because:
A- Chealator of Ca
B- Deactivation of basic anticoagulant factors
C- Anti acids
D- Increase clotting
Ans: A

309- There is a bomb blast in the area it will affect which system?
A- Nose
B- GIT
C- Renal
D- Hematopoietic
Ans: D

310- A+ cant be tranfused to
A- AB-
B- A-
C- O-
D- O+
Ans: C

311- Patient present with bleeding, PT normal, BT normal and APTT raised, cause is
A- VWD
B- ITP
C- Platelets defect
D- Hemophilia
E- Antiphospholipid syndrome
Ans: D

312- Most sensitive indicator of DIC is
A- Bilirubin
B- Ferritin
C- Albumin
D- Fibrinogen peptide
Ans: D

313- Patient Hb 8 , MCV 100 and MCH 28 what is type of anemia
A- Microcytic
B- Normocytic normochromic
C- Macrocytic
D- Hemolytic
Ans: B

314- Pregnant lady in 1st trimester having Hb of 10 gm/dl, on 3rd trimester having Hb of 9 gm/dl most likely due to
A- IDA
B- Thalassemi
C- Plasma volume excess
D- Sideroblastic Anemia
Ans: C

315- Preoperative male having 21HB 65HCT what should be done
A- Hydroxyurea
B- Observe
C- Venesection
D- Phosphate chealation
Ans: C

316- Trephine biopsy is done for
A- Hodgkin lymphoma
B- Aplastic anemia
C- CML
D- IM
Ans: B

317- After gastrectomy which type anaemia occurs commonly
A- Iron deficiency anemia
B- Megaloblastic anaemia
C- Megaloblastic anaemia with folic acid deficiency
D- Sideroblastic Anemia
E- Thalassemia
Ans: A

Explanation:
- Partial gastrectomy – Iron deficiency anemia.
- Complete gastrectomy – megaloblastic anemia.
- Before 6 months – Iron deficiency anemia.
- After 6 months – Megaloblastic anemia
- Over all – Iron deficiency anemia > Megaloblastic anemia.
- Gastrectomy can produce pernious anemia like symptoms but not actual pernious anemia as it is autoimmune.

318- FFPs are used as treatment of what?
A- Warfarin toxicity
B- Vitamin K deficiency
C- Vitamin D deficiency
D- Vitamin C deficiency
Ans: A

319- A boy had extraction of deciduous teeth and now profusely bleeding.Which classic hemophilia factor missing?
A- Factor IX
B- Factor VIII (major)
C- Factor VIII (minor)
D- Factor X
E- Factor XII
Ans: C

Explanation:
- Classic Haemophillia – Factor 8 Minor
- VWD – Factor 8 Major

320- A patient with chronic HIV presented with intestinal obstruction, surgery done, mass eroding the intestine this is related to which of these
A- High grade B cell lymphoma
B- Plasmacytoma
C- Mets Adenocarcinoma
D- Hodgkin Lymphoma(Lymphocyte Predominant)
E- Multiple Myeloma
Ans: A

CamScanner

Explanation:
- High grade diffuse large B cell lymphoma commonly metastasize to GIT specially small intestine and cause obstruction

321- A 19 years old patient's bone marrow is classified by the FAB system as an L3 leukemia. Which of the following best describes this leukemia?
A- CLL
B- ALL
C- AML
D- CML
Ans: B

322- Blood transfusion reaction occurs when:
A- A transfused to AB
B- O transfused to B
C- A transfused to B
D- B transfused to AB
Ans: C

323- Basis of anemia of chronic disease is
A- Decreased formation of porphyrin
B- Decrease Transfer of stored iron
C- Increase resistance to iron
D- Increase hemoglobin metabolism
Ans: B

324- A patient after blood transfusion had hemolysis. What factor will have decreased level due to binding with hemoglobin
A- Hemepexin
B- Albumun
C- Haptoglobin
D- Globulin
E- Ferritin
Ans: C

Explanation:
- Heme bind with - Hemepexin
- Hb bind with –Heptoglobin

325- Patient is taking warfarin and starting to bleed what is treatment of it
A- Heparin
B- Platelets
C- TPA
D- Cryoprecipate
E- Vitamin K +FFP
Ans: E

Explanation:
- Immediate reversal of toxicity – Prothrombin complex concentrate (PCC) or FFP
- Long term or Antidote – Vitamin K

326- An lady presented with Hyperpigmentation and difficulty in maintaining balance. MCV 110 and Ferritin 600 and All rest labs normal what is likely cause is
A- Iron deficiency anemia
B- Sideroblastic anemia
C- Thalassemia
D- Microcytic anemia
E- Megaloblastic anemia
Ans: E

327- A boy with history of Sickle cell anemia having Hb 4.5 deeply jaundiced, Platelets 260000 and TLC 10000 and spleen is palpable diagnose is
A- Aplastic crisis
B- Painful crisis
C- Sequestration crisis
D- Hemolytic crisis
E- Aplasia
Ans: D

328- A child is only on fast food, presented with pallor & lethargy with Hb 8.5mg/dl, MCV 120 which deficiency is he likely have?
A- Vitamin B12 deficiency
B- Folic acid deficiency
C- Iron deficiency anemia
D- Vitamin C deficiency
E- Vitamin K deficiency
Ans: B

329- In granulopoises at which stage granules start to appear that resemble mature myeloid cells
A- Promyelocytes
B- Metamyelocyte
C- Myelocytes
D- Band cells
Ans: A

330- At which stage, RBC nuclei disappear?
A- Early Normoblast
B- Intermediate normoblast
C- Late Normoblast
D- Erythroblast
Ans: C

331- Patient presented with epistaxis and menorrhagia labs showing BT 14 min, APTT 60 secs, PT 15 sec, Diagnose:
A- ITP
B- Haemophillia
C- VWD
D- DIC
Ans: C

332- Factor 8 deficiency causes
A- VWD
B- Hemophillia
C- ITP
D- antiphospholipid syndrome
Ans: B

333- A patient after 1 year of gastrectomy has anemia fatigue and Raised MCV 110 he is also having peripheral numbness and tingling sensation which type of anemia he is suffering from?
A- Pernicious anemia
B- Iron deficiency anemia
C- Thalassemia
D- Anemia of chronic disease
E- Sideroblastic anemia
Ans: A (No option of Vitamin B12 deficiency or megaloblastic anemia if present prefer that)

334- Regarding thalassemia true is:
A- Defect in ratio of chains
B- Defect in alpha globin synthesis
C- Defect in beta globin synthesis
D- Any of the above
Ans: C

335- Which of following is system is affected 1st by radiation
A- Muscular
B- Hematopoietic
C- Reproductive
D- CNS
E- Respiratory
Ans: B

336- In Sickle cell anemia child has painful abdomen and Legs and low hb.He has history of repeated blood transfusions. Which haemoglobin will be seen?
A- HBF
B- HBA2
C- HBS
D- HBA
Ans: C

337- Largest cell in blood is which of among following?
A- Basophil
B- Megakaryocyte
C- Neutrophil
D- Lymphocye
E- Monocyte
Ans: E

Explanation:
Largest cell in blood - Monocyte
Largest cell in bone marrow - megakaryocyte
Overall - Megakaryocyte > Monocyte

338- A patient with microcytic hypochromic anemia. Presented with spoon shaped nails and target cells present what is the diagnosis?
A- IDA
B- Thalassemia
C- HS
D- Anemia of chronic disease
Ans: A

339- Megaloblastic anemia feature is:
A- Cabbot rings
B- Oval Macrocytes
C- Howel jowel bodies
D- Thrombocytopenia
E- Leukopenia
Ans: B

340- A 10 year old boy presented with pallor, easy fatiguability, Hb 8mg/dl MCV low what is diagnose?
A- Iron deficiency anemia
B- Megaloblastic anemia
C- Normocytic normochromic anemia
D- Sideroblastic anemia
E- Thalassemia
Ans: A

341- Which is Thrombolytic agent
A- Fibrinogen
B- Plasmin
C- Binding to ADP receptors
D- Fibrin
Ans: B

342- In megaloblastic anemia there is damage of
A- Chief cells
B- Serous cells
C- Mucous cells
D- Parietal cells
Ans: D

343- Child with multiple transfusions, Failure to thrive having enlarged spleen, HCT 12% is likely suffering from
A- Thalassemia major
B- Thalassemia minor
C- Iron deficiency anemia
D- Sickle cell anemia
E- Myelofibrosis
Ans: A

CamScanner

344- A 58 years old male presented 10 days after coronary artery bypass surgery with purpura. Blood test revealed platelets count of 35000 , PT 11 Sec , APTT 24 sec and normal red cell morphology. Most likely cause of purpura is

A- Heparin Induced Thrombocytopenia
B- Idiopathic thrombocytopenic purpura
C- Drug Induced Thrombocytopenia
D- Post transfusion purpura
E- Thrombotic thrombocytopenic purpura
Ans: C

Explanation:

In Heparin induced Thrombocytopenia APTT will be prolonged

345- A child after 2 weeks of vaccination develops petechiae and presented with bleeding and has platelet count of 10000 the diagnosis is?

A- TTP
B- HUS
C- ITP
D- Idiopathic
E- Bernard Soulier
Ans: C

Explanation:

- ITP – Vaccination + Large platelets + marked low platelets
- Bernard – Large platelets + Normal or slight low platelets

346- A patient has anemia and hypersegmented neutrophils are present on peripheral blood examination what is cause

A- Folic acid deficiency anemia
B- Iron deficiency anemia
C- Thalassemia
D- Anemia of chronic disease
E- Sideroblastic anemia
Ans: A

347- A person with megaloblastic anemia with oval macrocytes and intrinsic factor given diagnosis will be

A- Ascorbic acid deficiency
B- Cobalmin deficiency
C- Riboflavin deficiency
D- Thiamine deficiency
Ans: B

348- Female patient was transfused with blood, after 3days became dyspneic and died Most like due to:

A- ABO incompatibility
B- RH incompatibility
C- Bacterial contamination of blood
D- Hemolytic reaction
Ans: A

349- Which factor present in serum which others produce and consume

A- Factor 8
B- Factor 7
C- Factor13
D- Factor12
Ans: B

350- 60 years male with splenomegaly inguinal lymphadenopathy, reed sternberg cells. Blood show lymphocytes eosinophils

A- Hodgkin stage 1
B- Hodgkin stage 3
C- Hodgkin stage 4
D- Hodgkin nodular
Ans: B

351- Bite Cells present in:

A- Sickle cell anemia
B- G6PD
C- Hemolytic anemia
D- Thalassemia
Ans: B

352- A thalassemia major boy required multiple transfusion what Hb level should be present before every transfusion

A- 9mg/dl
B- 8mg/dl
C- 11mg/dl
D- 12mg/dl
Ans: A

353- In pregnancy iron deficiency anemia is best diagnosed by:

A- Serum ferritin
B- Serum ferritin + increase TIBC
C- Serum transferrin
D- None
Ans: A (Davidson)

354- A man has noted scleral icterus for 4 days, malaise for one month O/E mild tachycardia and vitals normal rest of physical exam unremarkable lab finding show Hct 25%

A- Intravascular hemolysis
B- Increased iron absorption
C- Type 1 DM
D- Pulmonary Squmous cell carcinoma
E- Systemic Hypertension
Ans: A

355- Radiation can effect blood cells because these cells are:

A- Rapidly dividing
B- Slowly dividing
C- Non nucleated
D- None
Ans: A

356- The most common initial presentation of hemophilia patient is:

A- Epistaxis
B- Hemarthroses
C- Ecchymosis
D- Hematemasis
E- Bleeding from circumcision site
Ans: E>A

357- RBC formation in 20 weeks occur in:

A- Spleen
B- Liver
C- Bone marrow
D- Placenta
E- Umbilical cord
Ans: B

358- Mother and child have hypochromic anemia what is cause

A- Megaloblastic anemia
B- Iron deficiency anemia
C- Folate deficiency
D- B12 deficiency
Ans: B

359- After 12 months of mitral valve replacement surgery, patient complains of pallor and dark colored urine. What is the cause?

A- Microangiopathic hemolytic anemia
B- Macroangiopathic hemolytic anemia
C- Sideroblastic anemia
D- Iron deficiency anemia
E- Thalassemia
Ans: B (FA)

360- A patient presented with diarrhea petechiae and thrombocytopenia and also having raised creatinine with raised unconjugated bilirubin cause is

A- Hepatitis
B- TTP
C- CKD
D- ITP
Ans: B

361- Philadelphia chromosome related translocation is associated with?

A- CML
B- AML
C- ALL
D- CLL
Ans: A

362- Regarding Erythrocytes true is:

A- Hydrolysed when placed in hypertonic soln
B- Produce ankyrin&spectrin
C- Use carbohydrate aerobically
D- Increase viscosity of blood
E- Cell membrane is fragile due to pressure of glycoprotein
Ans: D

363- Which of following deficiency is present in hemophilia A:

A- Anti-hemophilia globulin
B- Hageman factor
C- Tissue factor
D- Plasma thromboplastin
E- Fibrin stabilizing factor
Ans: A

364- Hemophilia patient will have:

A- PT :11 seconds
B- APTT: 60 seconds
C- Platelets : 210000
D- BT :20 min
Ans: B

365- Intrinsic pathway is activated by

A- Contact of tissue collagen when it comes in contact
B- Factor X
C- Tissue factor
D- Factor VII
Ans: A

366- A patient presented with splenomegaly up-to T-10 and increase WBC count with mature cells which gene involved:

A- BCR-AML
B- BCR-ABL
C- ABL-TCR
D- AML-TCR
Ans: B

367- A blood group has which of following?

A- Anti B antibodies
B- Anti A antibodies
C- Predispose to paptic ulcer
D- AB antibodies
E- Peptic ulcer
Ans: A

Explanation:

- A blood group has Anti B antibodies and associated with Gastric carcinoma

368- After bone marrow transplant best cell for engraftment include:

A- Proliferative cells
B- Static cells
C- Labile cells
D- Stem cells
Ans: D

CamScanner

369- A male child has bleeding disorder his cousin also had history of hemophilia what is way to diagnose the disease early:
A- Peripheral smear
B- Coagulation profile
C- Bone marrow biopsy
D- Complete blood count
Ans: B

370- Cells less than 1 percent in blood?
A- Pericytes
B- Late normoblast
C- Reticulocyte
D- Monocytes
E- Megaloblast
Ans: C

371- Boy having hemarthrosis and his uncle had same problem what is cause:
A- Von willbrand deficiency
B- VitaminnK deficiency
C- Hepatitis
D- Consumptive coagulopathy
Ans: D

372- Part of Reticuloendothelial system include:
A- Pancreas
B- Kupffer cells of liver
C- Monocytes
D- Plasma cells
Ans: B

373- Patient Presented with fever and altered mental status and peripheral smear shows schistocytes what is likely cause
A- HUS
B- TTP
C- HSP
D- ITP
Ans: B

Explanation:
Thrombotic thrombocytopenic purpura
- Typically females
- Inhibition or deficiency of ADAMTS13
- Triad of thrombocytopenia (Low platelets), microangiopathic hemolytic anemia (Low Hb, schistocytes, Raise LDH), acute kidney injury (Increase Cr) + Fever and Neurological symptoms

Hemolytic-uremic syndrome
- Typically children
- Commonly caused by Shiga-like toxin from EHEC (serotype O157:H7) infection
- Triad + Bloody Diarrhea

374- A patient develops fatigue and pallor. On CBC she has MCV 115 and MCHC 30. On inquiry patient told that in the past she had undergone gastrectomy 4 years back. Now what is treatment option in this patient?
A- Iron Supplements
B- Injection Vitamin B12
C- Injection Folic acid
D- Oral Vitamin B12 and Folic acid
Ans: B

Explanation:
- Partial Gastrectomy – Iron Deficiency anemia.
- Complete Gastrectomy – Megaloblastic anemia so inj Vitamin B12 should be given
- Before 6 months –Iron Deficiency anemia.
- After 6 months – Megaloblastic anemia
- Over all – Iron Deficiency anemia > Megaloblastic anemia.
- Gastrectomy can produce Pernious anemia like symptoms but not actual Pernious anemia as it is Autoimmune.

375- The imbalance in haemostasis in case of Uremia due to:
A- Hypofibrinogemia
B- Factor 8 deficiencies
C- Protein C deficiency
D- Platelet function defect
Ans: D

376- In burn patient there is fever bleeding diathesis and hypotension Diagnosis is
A- Sepsis
B- DIC
C- Decrease factor 8
D- Hypovolumic shock
Ans: B

377- 2 alpha and 2 gamma chains?
A- Portland Hb
B- Gower Hb
C- Adult Hb
D- Fetal Hb
Ans: D

378- 52 years man with lytic lesion in bone, back pain and weakness apple green birefringence & Congo stain positive on damage to kidney is most suitable investigation to reach diagnose is:
A- Immunoelectrophoresis
B- Protein electrophoresis
C- Hb electrophoresis
D- Benze Jones Proteins
E- ELISA
Ans: B

379- In ITP true:
A- Increase PT
B- Increase APTT
C- Increase BT
D- Increase FDP
Ans: C

380- VWF plays a role in haemostasis by following way:
A- By platelet adhesion to collagen
B- Bind with collagen and receptors on platelet
C- Produce TXA2
D- Produce Prostaglandin
Ans: A

381- FFP are used as treatment of what?
A- Thrombocytopenia
B- Vitamin K deficiency
C- Vitamin D deficiency
D- Vitamin C deficiency
Ans: A

382- Which Hodgkin lymphoma has best prognosis:
A- Hodgkin lymph predominance lymphoma
B- Lymphocyte depleted
C- Non Hodgkin
D- Lymphocyte rich
Ans: D

Explanation:
- Lymphocyte Rich – Best prognosis
- Lymphocyte Depleted – Poor prognosis
- Lymphocyte Predominance – Popcorn cell
- Nodular sclerosis – Lacunar cell
- Mixed cellularity – Abundant Eosinophils.

383- Regarding Anemia true is:
A- Hb concentration decrease
B- O2-carrying capacity decrease
C- Total O2-content decrease
D- PO2 remains normal
E- Saturation of O2 remains normal.
Ans: B

384- Adult Hb beta chain replaced in fetus by:
A- Alpha
B- Gamma
C- Delta
D- Both Gamma and delta
Ans: B

385- Anemic patient HB 6. 2, platelets 450,000 TLC Normal range bone marrow shows erythroid hyperplasia:
A- Acute blood loss
B- Leukemia
C- Iron deficiency anemia
D- Anemia of CRF
Ans: C(CML should be if present)

386- In Christmas disease:
A- Bleeding increase
B- Clotting time decrease
C- PT increase
D- Coagulation normal
Ans: A

387- In sickle cell anemia pathogenesis is
A- Increase Blood loss
B- Polymerization and RBC damage
C- Decrease RBC formation
D- Increase beta globin chains
Ans: B

388- A patient presented with Hyperpigmentation and difficulty in maintaining balance. MCV 105 and and All rest labs normal what is likely cause is:
A- Iron deficiency anemia
B- Sideroblastic anemia
C- Thalassemia
D- Microcytic anemia
E- Megaloblastic anemia
Ans: E

389- 10 Year old child present with lump on forhead Mass excised from forehead microscope shows anastomosis of vessels and single layer of endothelium it is most likely:
A- Lipoma
B- Hemingioma
C- Sarcoma
D- Fibroma
Ans: B

390- Mother is O negative, father is O positive, 2nd child died with hydrops fetalis, blood group of baby will be:
A- B positive
B- O positive
C- A positive
D- A negative
Ans: B

391- Chemical responsible for coagulation in DIC:
A- Vitamin K
B- Fibrin
C- Alteplase
D- Fibrinogen
Ans: D

392- Important factor in coagulation to begin
A- Smooth Endothelium
B- Rough Endothelium
C- Prostacyclin
D- NO
Ans: B

CamScanner

393- A child has history of pica now having pallor, fatigue diagnosed as iron deficiency anemia what should be given?
A- B12
B- B6
C- Iron Supplement
D- Folate
E- B12
Ans: C

394- A female has active bleed and platelets 5000mcl what should be next treatment:
A- Immunoglobulins followed by Platelets Transfusion
B- 1 mega unit transfusion
C- Splenectomy
D- Immunoglobulins
Ans: B

395- In Sickle cell disease, abnormal RBCs removed by:
A- Liver
B- Spleen and sinosidal capillaries
C- Thymus
D- Bone marrow
Ans: B

396- Patient came with left hypochondrium pain on palpation splenomegaly was found how will confirm the hypersplenism?
A- CT scan spleen
B- Bone marrow aspiration
C- Ultrasound abdomen
D- CBC
E- RFT
Ans: B

397- In Pregnant woman at term. Which type of anemia occur:
A- Sideroblastic anemia
B- Megaloblastic anemia
C- Iron deficiency anemia
D- Thalassemia
Ans: C

398- 17 years old boy there is ecchymosis on small Injury with only increase in CT and all other investigations are normal (PT, BT, APTT normal). What is the cause?
A- Vitamin K deficiency
B- Non thrombocytopenic purpura
C- Hemophilia
D- ITP
Ans: B

399- Which of the following translocation is seen in CML?
A- t(8:14)
B- t(8:21)
C- t(9:22)
D- t(11:14)
E- t(X:18)
Ans: C

400- 25 Year old patient present with complains of dizziness sob and blue discoloration of extremities of two days. Cyanosis of lips and extremities noted. Which investigation should be used?
A- Xray
B- Echo
C- ECG
D- Spectroscopic examination of HB
Ans: D

401- Most imp characteristic feature of VWD is:
A- Increase APTT
B- Increase BT
C- Increase platelet count
D- Increase PT
Ans: B

402- Common cause of prolong BT is:
A- Thrombocytopenia
B- Hemophillia
C- Vitamin D deficiency
D- Vitamin C deficiency
Ans: A

403- Most common cause of deranged PT/APTT:
A- Kidney disease
B- Hemophilia
C- Liver disease
D- ITP
Ans: C

404- What is the most appropriate treatment of Hemophilia?
A- FFP
B- Cryoprecipitate
C- Factor 9
D- Vitamin k
Ans: B

405- Regarding Hodgkin disease?
A- Lymphocyte depleted are more common in young
B- Males have better prognosis
C- Bony lesions are lytic
D- Extra Manifestations are more common than Hodgkin lymphoma.
Ans: B

406- A young male had an RTA which resulted in a femur fracture. He died 5 days later autopsy showed cerebral petechiae. Diagnosis is:
A- Sepsis
B- Fat embolism
C- Pulmonary embolism
D- Myocardial dysfunction
Ans: B

407- Vitamin K deficiency causes increase in:
A- PT
B- BT
C- CT
D- None
Ans: A

408- Heinz bodies are found in:
A- Hereditary spherocytosis
B- G6PD deficiency
C- Pyruvate kinase deficiency
D- Cirrhosis
Ans: B

409- Patient after penetrating abdominal injury on antibiotics for 12 weeks therapy and 3week TPN with echymosis platelet normal PT 14 cause:
A- Sepsis
B- Vitamin K deficiency
C- Vitamin A deficiency
D- Zinc deficiency
Ans: B

410- Follicular lymphona gene involved will be:
A- BCL-2
B- C-MYC
C- BCR ABL
D- T(9:22)
Ans: A

411- Patient having proteinuria and occasional hematuria. Cause of Generalized body swelling:
A- Increase hydrostatic pressure
B- Increase oncotic pressure
C- Lymph obstruction
D- Decrease plasma oncotic pressure
Ans: D

412- Polycythemia is caused by:
A- Increase Erythropoietin
B- Increase red cell mass
C- Decrease red cell mass
D- Increase GFR
Ans: B

413- Characteristic feature of haemophilia:
A- Tissue bleeding
B- Epistaxis
C- Ecchymosis
D- Petechial hemorrhage
Ans: A

414- Anti sera agglutinates with B and D and plasma has anti A antibodies which blood group it is?
A- A-ve
B- A+ve
C- O-ve
D- O+ve
E- B+
Ans: E

415- Fisher man presents with complain of weakness and early fatigue. He use to have only fish and rice in his diet. His baselines show Hb 7.8gm, MCV 105. What could be the likely cause?
A- Microcytic anemia
B- Macrocytic anemia
C- Iron deficiency anemia
D- Sideroblastic anemia
Ans: B
Explanation:
Fisherman with anemia + Echymosis – Vitamin C deficiency
Fisherman with Anemia +Raised MCV – B12 Deficiency (Macrocytic) – Diphyllobothrium

416- Leukocyte alkaline phosphatase activity decreased in:
A- Acute inflammation
B- Liver failure
C- Pregnancy
D- CML
E- Leukemoid reaction
Ans: D

417- Which one is most antigenic?
A- Heparin
B- Tissue thromboplastin
C- Tissue Plasmogen activator
D- Streptokinase
Ans: D

418- A 2 years old child presented in out patient deptt. with fever pallor nd bowel disturbnce. Labs revealed Hb 5.6, MCV 107, MCH 340, MCHC 36. What investigation will confirm diagnosis?
A- Intrinsic factor antibodies
B- Serum vit B12
C- Serum Vit B6
D- Serum B9
Ans: A

CamScanner

419- A patient has weakness and dysphagia fatigue and low Hb 6 g/dl mcv 68 and much 28 what is suitable diagnose?
A- B12 Deficiency
B- Thalassemia
C- Iron Deficiency anemia
D- Folate Deficiency
E- Sideroblastic anemia
Ans: C

420- Hemophilia diagnosed by:
A- Prothrombin time
B- Partial thromboplastin time
C- CT
D- Bleeding time
E- Platelet count
Ans: B

421- Prothrombin time detects following clotting factors?
A- 1,2,5,7,10
B- 2,3,8,9,10,11
C- 3,9,10
D- 2,7,9,10
E- 5,7,89, 10
Ans: A

422- Most common acquired thrombotic disorder is due to?
A- Factor 8
B- Factor 7
C- Factor V laiden
D- Anti phospholid syndrome
E- Factor 8 inhibitor
Ans: D

423- Which of the following factor is involved in eliciting DIC
A- Factor 5
B- Factor 12
C- Factor 10
D- Tissue thromboplastin
Ans: D

424- Lymphocytes normal percentage in the blood?
A- B lymphocytes 50%
B- T lymphocytes 80 – 90%
C- B lymphocytes 90% and T lymphocytes 10%
D- T lymphocytes 20%
E- B lymphocytes 10 – 20%.
Ans: B> E

425- Burkit lymphoma translocation is which of these?
A- t14:18
B- t11:22
C- t15:27
D- t8:21
E- t8:14
Ans:

426- Which of the following is an indication for platelet transfusion?
A- ITP
B- TTP
C- Aplastic Anemia with Platelet count 40,000
D- Post transfusion purpura
E- HUS
Ans: C

427- A Female patient presented with epistaxis and petechiae. BT and CT were normal. What is the first investigation to identify the cause?
A- APTT
B- PT
C- Platelet count
D- LFTs
E- Anti-Factor 8
Ans: C

428- A mother with thalassemia major came for antenatal counselling. You will tell her about the baby that
A- 25% normal, 50% minor, 25% major
B- 25% minor, 50% normal, 25% major
C- 25% major, 50% normal, 25% minor
D- 50% major, 50% minor
E- 25% major, 75% normal
Ans: A

429- A patient has Family history of thrombo emoblism which test should be done in him
A- D Dimer
B- PT
C- APTT
D- BT
Ans: A

430- Which factor remains in the serum even after hemostasis?
A- 8
B- 3
C- 13
D- 7
E- 10
Ans: D

431- A 29 year female presents with lethargy and irritability for the last 5 yrs. Labs revealed Hb of 9.6, MCV 70 and MCHC low with normal WBC and PLT count. She was prescribed iron supplements but after 2 months she has Hb 10.2 Which lab investigations should be ordered to find the underlying cause of persistent anemia?
A- Total iron binding capacity
B- Hb electrophoresis
C- Retic count
D- Ferritin levels
E- Bone marrow biopsy
Ans: B

432- Diagnosis of iron deficiency anemia is by which of the following?
A- Serum iron and tibc
B- Serum ferritin+Microcytosis
C- Hb electrophoresis
D- CBC
Ans: B (Davidson)

433- Christmas disease will have defect in
A- Prothrombin time
B- Partial thromboplastin time
C- Tissue factor
D- Bleeding time
E- Anti hemophilia globulin
Ans: B

434- A person with Blood group A will have
A- A antiglobinogen on erythrocytes membrane
B- Anti A antiglobulin in plasma
C- B antiglobinogen on erythrocytes membrane
D- Anti B antiglobilin on erythrocytes membrane
Ans: A

435- A patient is being prepared for tonsillectomy , which of the following test must be done
A- Throat swab culture
B- Hemoglobin level
C- Platelet count
D- PT/APTT
Ans: D

436- A boy came with the complain of multiple brusises and echymosis on the skin and recurrent epistaxis . His BT and CT is normal which other thing you would like to check first of all ?
A- Urea level
B- Hemoglobin levels
C- Platelet count
D- Billirubin level
Ans: C

437- 4 years old girl with history of bleeding in family and CBC reportshowing Hb 13.5g/dl, wbc 6 x 10 anddecreased platelets 85x 10³/L. Investigation shows megakaryocytes. What is thediagnosis?
A- TTP
B- ITP
C- SLE
D- DIC
E- Bernard soulier syndrome
Ans: B

438- Factor in both intrinsic and extrinsic pathway activation is
A- Tissue thromboplastin
B- Factor 10
C- Factor 7
D- Factor 2
Ans: B

439- Monitoring of extrinsic pathway is related to
A- Heparin
B- Warfarin
C- APTT
D- BT
Ans: B
Explanation:
- Heparin monitoring is done by – APTT (Intrinsic Pathway)
- Warfarin monitoring is – INR > PT (Extrinsic Pathway)

440- Vessel walls are damaged Artery layer from inner to outside damage will be:
A- Tunica media, Intima and Adventitia
B- Tunica intima, media and adventitia
C- Tunica adventitia, media and intima
D- Tunica Medial, adventitia and intima
Ans: B

441- Massive blood transfusions leads to
A- Hypercalcemia
B- Hyponatremia
C- Hypocalcemia
D- Hyperkalemia with decrease NH4
Ans: D

442- Patient Presented with fever, decrease platelets and bloody diarrhea peripheral film shows schistocytes what is likely cause
A- HUS
B- TTP
C- HSP
D- ITP
Ans: A

443- In Vitamin K deficiency following factors deficiency occur
A- 1,2,5,7,10
B- 2,3,8,9,10,11
C- 3,9,10
D- 2,7,9,10
E- 5,7,89, 10
Ans: D

CamScanner

444- A pregnant lady in her first trimester with Hb 9.0g/dl, MCV 50 & Ferritin in normal range. Investigation to be done?

A- HbA2
B- HbF
C- HbA & HbF
D- Bone marrow Biopsy
Ans: A

445- Intrinsic pathway is activated by factor

A- Tissue thromboplastin
B- Factor Xi
C- Factor VII
D- Factor V
Ans: B(No option of factor XII)

446- Platelets are usually transfused at room temperature

A- To optimize their function
B- To avoid allergy
C- To cause R-L Shift
D- To prevent hemolysis
Ans: A

447- In hemostasis the word Gain is for:

A- Negative feedback
B- Exaggeration of the Positive feedback
C- Exaggeration of the negative feedback
D- Positive feedback
Ans: C

448- In Christmas disease increase bleeding what will be raised?

A- APTT
B- BT
C- PT
D- Both PT & BT
E- Decrease Anti hemophlic globulin
Ans: A (Haemophilia B)

Explanation:

- In All hemophiliA- APTT raised
- In Hemophilia A(Classic) - Decrease Anti hemophilic globulin or factor 8
- In Hemophilia B(Christmas disease) - Decrease plasma thromboplastin component or factor IX or Christmas factor
- In Hemophilia C(Rosenthal syndrome) - Decrease plasma thromboplastin antecedent or factor XI

449- Massive blood transfusions leads to

A- Hypercalcemia
B- Hyponatremia
C- Hypocalcemia
D- Hypokalemia
Ans C (Only Suitable)

Explanation:

- Massive Transfusion – Hyperkalemia
- Multiple or Continous –

Hemochromatosis

- Repeated Transfusion – Hypocalcemia

450- Intrinsic pathway activated by which factor

A- 2
B- 7
C- 11
D- 10
Ans: C

451- Treatment of severe thalassemia major is

A- Iron therapy
B- Regular blood transfusions schedule
C- Splenectomy
D- Folate therapy
Ans: B

452- Patient is taking oral anticoagulant which factor is used to monitor the effect

A- APTT
B- PT
C- Factor 3 level
D- Thrombin level
E- BT
Ans: B

Explanation:

- For Heparin - APTT
- For Warfarin (Oral anticoagulant) -INR> PT

553- A patient has weakness , pallor , Dysphagia and Fatigue . He is having low Hb 6g/dl and peripheral smear shows microcytic hypochromic cells . Suitable diagnose is

A- Thalassemia anemia
B- B12 deficiency anemia
C- Folate deficiency anemia
D- Iron deficiency anemia
E- Sideroblastic anemia
Ans: D

454- A 65year patient presents with jaundice. On workup HB 4.5, WBC: 7000 cells/cmm. Raised platelets , increase bilirubin, increase retic count 9%, smear shows polychromasia and clumps, what test to confirm diagnosis?

A- Coombs test
B- Hb electrophorosis
C- Osmotic fragility test
D- G6PD
E- Bone marrow biopsy
Ans: A

(Better question although repeated)

455- Multiple blood transfusions leads to

A- Hypercalcemia
B- Hyponatremia
C- Hypocalcemia
D- Hypokalemia
E- Hemolytic anemia
Ans: C (Only suitable)

Explanation:

- Massive Transfusion – Hyperkalemia
- Multiple or Continous – Hemochromatosis
- Repeated Transfusion – Hypocalcemia

456- A 25 years old lady had Metallic Mitral Valve replacement 2 weeks after she was sent home on routine medications. She reported to causality with two hours history of severe epistaxis. She looked pale, rest of Clinical Examination wasunremarkable. Investigation HB 6.5%, TLC 7500/CUMM, Platelets75000/CUMM, PT 5, INR 5.5. The most likely cause of her bleeding is:

A- Drug Induced
B- Idiopathic
C- Infection
D- Thrombocytopenia
E- Trauma
Ans: A

457- Treatment of diffuse large B cell lymphoma is:

A- Surgery
B- Surgery + radio
C- Radio
D- Surgery and chemotherapy
Ans: D

458- Pathogenesis of DIC:

A- Impaired fibrinolytic system
B- Vessel Damage
C- Consumption of Clotting Factors
D- Inhibition of Coagulation cascade
Ans: A

459- Primigravida 20 year old presented to doctor at 8 weeks of Gestation.She want to Test her fetys for thalassemia major. They had cousin marriage. Both husband and wife have thalassemia minor. Which test can be done for prenatal diagnosis of thalassemia?

A- CVS
B- Amniocentesis
C- HbA2 after birth
D- PCR of both parents for mutated gene
E- Fetal blood sampling
Ans: A

460- A patient presented with jaundice.O/E scleral icterus & splenomegaly found. Investigations reveal an Hb level of 4.5g/dL & a bilirubin level of 4 along with increased Retic Count. He is most likely suffering from:

A- Iron deficiency anemia
B- Hemolytic anemia
C- Thalassemia
D- Sideroblastic anemia
E- Sicke thalassemia syndrome
Ans: B

461- Female patient with a family history of venous thromboembolism. She has come to your clinic for further information. Which is the most sensitive investigation will you order?

A- Platelet count
B- PT
C- APTT
D- Platelet Count
E- D-Dimers
Ans: E

462- 4 years old girl with history of bleeding in family and CBC reportshowing Hb 13.5g/dl, wbc 6 x 10 anddecreased platelets 85x 10⁹/L. Investigation shows megakaryocytes. What is thediagnosis?

A- TTP
B- ITP
C- SLE
D- DIC
E- Bernard soulier syndrome
Ans: B

463- A male presented to OPD with 104 fevers for last 4 days and gives history of using Anti-malarial She has been passing cola color urine for the last 1 day with deranged LFTs and increased unconjugated bilirubin. What is the cause?

A- Gucose 6 phosphate deficiency
B- Black Water fever
C- Drug induced jaundice
D- Paroxysmal nocturnal hemoglobinuria
E- Glucose 6 phosphate dehydrogenase deficiency
Ans: E

464- Blood group agglutinogens are:

A- Transferred Through X Chromosome
B- Present on Hb surface
C- Present on Erythrocyte Surface
D- Secreted in Saliva
E- Glycoprotein in nature
Ans: C

CamScanner

Explanation:
Follow the following order for blood group antigens: RBC Surface > Glycoprotein > Immunogenic > Dominant Mendalian

465- Why platelets are given at room temperature?
A- For maximum effect of Platelets
B- To reduce Allergic Reaction
C- To Lessen Platelet Count
D- To prevent Hemolysis
E- To prevent transfusion reaction
Ans: A

466- Most common inherited thrombotic disorder is due to?
A- Factor 8
B- Prothrombin Deficiency
C- Factor V laiden
D- Anti phospholid syndrome
E- Factor 8 inhibitor
Ans: C

Explanation:
- Factor V mutation(Laden) leads to -- Thrombosis
- Factor V deficiency leads -- Bleeding
- Factor 12 deficiency leads -- Thrombosis.
- Most common acquired thrombotic disorder is -- Anti-phospholipid syndrome
- Most common Inherited coagulopathy -- VWBD
- Most common inherited Thrombotic disorder is -- Factor V Mutation (Laden)

467- Pregnant lady in 1st trimester having Hb of 10 gm/dl, on 3rd trimester having Hb of 9 gm/dl most likely due to
A- IDA
B- Thalassemi
C- Normal Physiological Change
D- Sideroblastic Anemia
Ans: C

468- A girl had 0.5 cm laceration on her index finger. What's the first factor that comes in contact with vascular basement membrane injury and activates both coagulation and the kinin system?
A- Antithrombin
B- Antihemophilic Factor
C- Histamine
D- Tissue thromboplastin
E- Hageman factor
Ans: E

469- A woman develops venous thrombosis.She will have deficiency of which endogenous antocoagulant?
A- Factor V
B- Protein C
C- Factor VIII
D- Thrombin
E- Prothrombin
Ans: B

470- A 60-year-old man w/ fatigue, weakness, and exercise intolerance. Labs: Hemoglobin 9.1 mg/dL, Ferritin 9 ng/mL, Mean corpuscular volume (MCV) 120 fL. Diagnosis:
A- Iron Deficiency Anemia
B- Megaloblastic Anemia
C- Sideroblastic Anemia
D- Auto immune haemolytic Anemia
Ans: B

471- A 20 year old girl presents with progressive pallor, easy fatiguibility and lethargy. Her blood film showed absolute lymphocytosis TLC 20x10^9/L with more than 85% lymphocytes. The most likely diagnosis is:
A- ALL
B- Aplastic anemia
C- CLL
D- Infectious mononucleosis
E- Whooping Cough
Ans: D

472- A female Patient present with fatigue, easy bruisibility after small cuts and recurrent infection alongside fever from 2 weeks. After investigations the report shows blast cells and Promyelocyte in smear. Suspected Diagnose is indicated by which translocation
A- 9:22
B- 8:14
C- 11:14
D- 15:17
E- 14:18
Ans: D (Robins)-AML

Explanation:
- AML – 8:21 and 15:17
- CML – 9:22
- Burkit Lymphoma – 8:14
- Mantle Cell Lymphoma – 11:14
- Follicular Lymphoma – 14:18
- Ewing Sarcoma – 11:22
- Prostatic Carcinoma – 7:21 and 17:21

473- Anti phospholipid characteristics is
A- Anti Russel venom
B- Anti parietal venom
C- Bleeding tendency
D- None
Ans: A

474- Warfarin monitoring done by
A- PT/APTT
B- BT
C- APTT
D- INR
Ans: D

475- A 60-year-old man with fatigue, weakness, and exercise intolerance. Labs: Hemoglobin 9.1 mg/dL, Ferritin 9 ng/mL, Mean corpuscular volume (MCV) 115 fL. What will be seen on histology
A- Macrocytosis
B- Microcytosis
C- Normal reticulocyte
D- Mixed Microcytosis and macrocytosis
Ans: A

476- A 6 Years old boy presented with Complains of Lethargy, Weakness & Fatiguability. Examination reveals pallor. Investigations reveal an Hb level of 6g/dL. He is most likely suffering from:
A- Megaloblastic Anemia
B- Sideroblastic Anemia
C- Anemia of chronic disease
D- Aplastic Anemia
E- Iron deficiency Anemia
Ans: E

477- An old man presented with history of Fever & Weight loss.Investigations reveal a WBC count of 25×10° WBC and 90% Lymphocytosis.Best method to diagnose:
A- Bone Marrow Aspiration
B- Trephine biopsy
C- Montoux Test
D- Serial CBCs
Ans: B

478- A 57 year Old patient presented with complains of Pruritis, tinnitus,Blurred Vision with burning sensation in fingers & toes alongwith rash. Symptoms agarvate after taking hot Bath. What will be the likely diagnosis?
A- Aplastic Anemia
B- Hereditary Spherocytosis
C- Polycythemia Vera
D- Sarcoidosis
E- Thalassemia minor
Ans: C

479- 12 y/o male known case of sickle cell anemia presents with severe abdominal pain and jaundice .Cause of Sickling?
A- Hemolysis
B- Hypercoagulability
C- Hyperbilirubinemia
D- Endothelial injury
Ans: A

480- Beta thalasemia minor manifests mostly as?
A- Increased HbF
B- Increased Hb with abnormal beta chains
C- Hb with mixed Beta & Delta chains
D- Increased HBH
E- Increased Alpha chains
Ans: C

481- A patient with swelling of knee joint and decreased mobility. APTT prolonged- Which of the following affects the platelets to cause above findings:
A- vWD
B- Wiskott Aldrich Syndrome
C- Hemophilia A
D- Bernard Soulier disease
E- TTP
Ans: C

482- A boy presented with bleeding after finger cut. Investigations reveal increased BT. PT, APTT & platelet count were normal. What is the cause?
A- Hageman Factor Deficiency
B- ITP
C- Platelet function defect
D- Coagulation factor deficiency
E- Fibronogen deficiency
Ans: C

483- A patient after coronary bypass surgery came with complaints of purpura & petechial hemorrhages. On investigations, Bleeding time prolonged- Findings are due to:
A- TTP
B- Drug induced coagulopathy
C- Post Surgical thrombocytopenia
D- ITP
E- Glanzmann thrombasthenia
Ans: C

484- A patient presents with subcutaneous red rashes and purpura and massive splenomegaly. Symptoms resolved with splenectomy . Findings are due to:
A- Idiopathic Purpura
B- Hereditary spherocytosis
C- Thrombocytopenia
D- Sickle cell Anemia
Ans: B

485- A pregnant lady with history of lethargy delivered a baby who was listless. Serum ferritin is low on investigations. Cause:
A- Iron deficiency
B- Folate deficiency
C- B12 deficiency
D- Thalassemia
E- Vitamin D deficiency
Ans: A

CamScanner

486- Warfarin differs from Heparin?
A- Monitoring by PT
B- Heparin can be given in IV infusion form
C- It has Rapid onset of action
D- Toxicity reversed by Protamine Sulphate
Ans: A

487- A Mother with blood group A- gave birth to a baby with blood group O+ .His father is O+.Immune antigen testing can be done by:
A- Rh antigen
B- Kappa antigen
C- ABO
D- Bombay phenotype
Ans: C

488- Female patient pale lethargic does not took any antenatal care during delivery bleed alot. Which nutrient deficiency in both baby and mother
A- Vitamin K
B- Iron
C- Calcium
D- Magnesium
Ans: B

489- What type of Anemia is present in case of Chronic blood loss:
A- Normocytic Normochromic
B- Microcytic Hypochromic
C- Megaloblastic Anemia
D- Macrocytic Hypochromic Anemia
Ans: B
Explanation:
- Initially Normocytic normochromic then microcytic hypochromic

490- A young boy has Factor 8 deficinecy. Which one can be used as an alternative for him?
A- FFP
B- Prothrombin complex
C- Cryoprecipitate
D- Platelets
Ans: C

491- Which one is rich in Cryoprecipitate?
A- Factor VIII
B- Factor IX
C- Factor X
D- Factor IV
Ans: A

492- Which of the following haemoglobin (Hb) will be defective in a case of beta thalassemia trait?
A- HbF
B- HbA1c
C- HbA2
D- HbH
E- HbS
Ans: C

493- A patient has tingling sensations n his peripheral body and lab investigation reveal raised MCV. What is the most probable pathology?
A- Pernicious anemia
B- Folic acid deficiency
C- Vitamin B12 deficiency
D- Vitamin C deficiency
Ans: C

494- Hodgkin Lymphoma most commonly associated with EBV
A- Nodular sclerosing
B- Mixed cellurity
C- Lymphcyte Rich
D- Lymphocyte Poor
Ans: A

495- Acute intravascular hemolysis is diagnosed by?
A- Decreased Haptoglobin
B- Reticulocytosis
C- Increased TIBC
D- Increased indirect biliubin
E- Hemoglobinuria
Ans: A

496- A young boy has petechiae & bruises with normal BT & CT.Which investigation should be done?
A- CBC
B- Platelet count
C- APTT
D- Trephine biopsy
Ans: B

497- Intrinsic pathway is activated by factor
A- Factor XIII
B- Factor XI
C- Factor VII
D- Factor VIII
E- Facor IX
Ans: B(No option of factor XII)

498- Nor A or B, neither Ab antigen present Blood group is?
A- O-ve
B- AB-ve
C- O+ve
D- AB+ve
Ans: A

499- Most rapidly acting thrombolytic:
A- Streptokinase
B- Enoxaparin
C- Heparin
D- Plasminogen
E- Fibrin
Ans: D

Explanation:
- Natural antithrombin – Heparin
- Natural thrmobolytic – Plasminogen
-

500- Which of the following is a possible reason for a false positive result in an anti-D agglutination test?
Failure to read the instructions
A- Agglutination occurring rapidly
B- Over sample in the test tube
C- Improper sample collection
D-
Ans: B

501- Old age patient with dec Hb, RBC increased, WBC increased, platelets increased with hyperplastic bone marrow with weakness and lethargy, what's your diagnosis:
CRF
A- Megaloblastic anemia
B- CML
C- ALL
D- AML
E-
Ans: C

502- A patient experianced RTA a donor was called he has AB+ blood group. What are features of AB+ blood group
A- Lack A and B antigen
B- Do not have RH blood group
C- No antibodies
D- Has A and B antigen
Ans: D

503- An elderly woman presents with low hemoglobin, high mean corpuscular volume (MCV), and ataxia. What is the most likely cause of these symptoms?
A- Folate deficiency
B- Vitamin B12 deficiency
C- Iron deficiency anemia
D- Chronic kidney disease
E- Thalassemia
Ans: B

504- Treatment of diffuse large B cell lymphoma is:
A- Surgery
B- Surgery + radio
C- Radio
D- Surgery and chemotherapy
Ans: D

505- When the Activated Partial Thromboplastin Time is prolonged and the Prothrombin Time is normal, which clotting factor is most likely involved?
A- Factor I
B- Factor V
C- Factor VII
D- Factor VIII
E- Factor X
Ans: D

506- A patient presents with mucosal bleeding and easy bruising. Which of the following is the most likely cause of these symptoms?
A- Thrombocytosis
B- Thrombocytopenia
C- Polycythemia
D- Leukocytosis
E- Leukopenia
Ans: B

507- The conversion of fibrinogen to fibrin is catalyzed by which of the following enzymes?
A- Thrombin
B- Plasmin
C- Factor VII
D- Factor XIII
E- Tissue plasminogen activator (tPA)
Ans: A

508- 25 Year woman previously healthy presented with complain of echymosis and epistaxis from 25 days and platelet count 12* 10(9) and hyperplasia of megakaryocytes diagnosis is:
A- Septicemia
B- ITP
C- TTP
D- Hemorrhage
E- Postpartum hemorrhage
Ans: B

509- 10 years old child presents with ecchymosis, most imp initial test?
A- APTT
B- CBC
C- Platelet count
D- BT
Ans: C (If not in option then CBC)

510- A 30-year-old woman, 12 weeks pregnant, presents with a miscarriage accompanied by significant vaginal bleeding. Laboratory results reveal coagulopathy, but she shows no signs of shock. What is the most appropriate management strategy?
A- Uterine evacuation alone
B- Uterine evacuation combined with Fresh Frozen Plasma (FFP)
C- Fresh Frozen Plasma (FFP) and Packed Red Blood Cells (PRBCs)
D- Packed Red Blood Cells (PRBCs) alone E- Uterine evacuation combined with intravenous fluids
Ans: B

CamScanner

511- Which of following has least hemoglobin concentration?

A- SVC
B- Umbilical vein
C- Umbilical artery
D- IVC
E- Pulmonary artery
Ans: E

512- A patient presented with diarrhea petechiae and thrombocytopenia and altered mental status and also having raised creatinine with raised unconjugated bilirubin cause is

A- Hepatitis
B- TTP
C- CKD
D- HUS
E- HSP
Ans: B

Explanation
Triad

1. Thrombocytopenia
2. Microangiopathic hemolytic anemia (Low Hb , Raised LDH and bilirubin with schistocytes)
3. AKI(Raised Cr)

HUS

Triad + Bloody diarrhea

TTP

Pentad --Triad + Fever +Neurological symptoms (Headache ,Seizure , delirium and coma)

HSP
Tetrad

1. Palpable petechial rash typically affecting buttocks and lower legs
2. Abdominal pain due to vasculitis involving the gastrointestinal tract
3. Arthralgia
4. Renal disease(Raised Cr) with visible or non-visible haematuria, with or without proteinuria(Protein in urine)

513- Bunard soulier characteristic:

A- Defect in glycoprotein 2a/3b
B- Platelet aggregation
C- Platelets do no aggregate in response to Ristocetin test
D- Glycoprotein 3b
Ans: C

514- Female patient pale lethargic does not took any antenatal care during delivery bleed alot. Which nutrient deficiency in both baby and mother

A- Vitamin K
B- Iron
C- Calcium
D- Magnesium
Ans: B

515- A 19 year old patient presented with iron deficiency anemia due to unknown source of blood loss and dark urine at several ocassions having jaundice , Hb 9g/dl and Retic counts 10%) What could be the cause?

A- Dietary deficiency
B- Hereditary spherocytosis
C- Paroxysmal nocturnal hemoglobinuria
D- G6PD deficiency
Ans: C

516- A lady in third trimester having AB Positive needs urgent FFP to be Transfused Which blood can be used?

A- B positive
B- A positive
C- O negative
D- AB negative
Ans: D

517- Patient had RTA and got splenic rupture for which splenectomy was done What is seen in this patient:

A- Thrombocytopenia
B- Howel Jolly bodies
C- Erythrocytopenia
D- Reticulocytopenia
E- Fragmentation of RBCs
Ans: B

518- Woman with blood group RH -ve and give birth to o -ve baby.Newborn has mismatch hemorrhage disease Mother should take what to prevent hemolytic disease of new born in next baby?

A- Anti D Immunoglobulin
B- No Reaction in next Pregnancy
C- No Need to give Anti D Antibodies
D- Tetanus prophylaxis
Ans: A

519- Increased Serum Ferritin & Decreased TIBC in:

A- Iron deficiency Anemia
B- Anemia of Chronic disease
C- Thalassemia
D- Sideroblastic Anemia
E- Hemolytic Anemia
Ans: B

520- In traumatic patient, hypothermia leads to increased bleeding. Cause? November 2024

A- Affecting Blood Viscosity
B- Decreasing effect of Clotting factors
C- Decreasing Platelet function & Numbers
D- Disseminated Intravascular Coagulation
Ans: C

Explanation:

- In trauma patients, hypothermia is a well-known cause of coagulopathy (impaired blood clotting). The primary mechanism is the reduction in the enzymatic activity of clotting factors, which are temperature-sensitive and function optimally at normal body temperature and decrease platelets function and numbers. Hypothermia slows down the coagulation cascade, leading to prolonged bleeding

521- Female with Increased ESR, Hypergammaglobulinemia, Gamma Globulins will cause; November 2024

A- Lysis of RBCs
B- Increase Sedimentation
C- Decrease Sedimentation
D- Repel RBCs
E- Increased Rouleux Formation
Ans: E

522- Most important features of HELLP syndrome is

A- Normal APTT
B- Thrombocytopenia
C- Anemia
D- Hyperpyrexia
E- All of the above
Ans: B

523- A patient's CBC shows Hb. 5.6 g/dL, platelets. 140,000/µL, and PT/aPTT at the upper normal limit. What is the most appropriate transfusion option?

A- Fresh Frozen Plasma (FFP)
B- Fresh Whole Blood
C- Whole Blood
D- Packed Red Blood Cells (PRBCs)
Ans: D

524- Characteristic feature of beta thalessemia trait?

A- Normal Serum ferritin
B- TIBC
C- HbF
D- HbA2
Ans: D

525- Activated platlets secrete:

A- Thromboxane A2+ ADP
B- Thromboxane A2+ Fibrinogen
C- Fibrinogen+ADP
D- Thromboxane
E- ADP
Ans: A

526- Which of the following blood group transfusions has the highest risk of developing ABO incompatibility?

A- A-ve to A+
B- A-to O-
C- A to AB
D- B to AB
E- O-to O+
Ans: A

Explanation:

- ABO incompatibility occurs when the donor's blood type has antigens that the recipient's immune system recognizes as foreign. In this case, transfusing A-negative blood to an A-positive recipient can lead to a reaction due to the Rh factor incompatibility if anti-D antibodies are present in the donor's blood. Other options, like A to AB, are compatible as AB individuals are universal plasma recipients for ABO groups.

527- What is true about adult hematopoiesis?

A- 75% erythroid series
B- 75% myeloid
C- 75% lymphoid
D- Sternum hematopoiesis complete at 20 years
E- All long bone hematopoiesis complete after 21 years
Ans: B

528- A boy fell down while playing & developed swelling of knee. His brother also has similar disease.

A- Hemophilia
B- VWD
C- Idiopathic Thrombocytopenic Purpura
D- TTP
Ans: A

529- A patient presents with History of Joint Swelling. Investigations reveal prolonged aPTT. His uncle has similar medical History But Sister is all fine. What is the most likely cause?

A- Coagulation factor deficiency
B- Platelet adhesion defect
C- Qualitative platelet defect
D- Quantitative platelet defect
Ans: A

CamScanner

530- An 8-year-old girl presents with bleeding tendencies. O/E Splenomegaly found. Investigations revealed anemia, thrombocytopenia, and leukopenia. Bone marrow examination reveals hypocellularity, and a diagnosis of aplastic anemia is made. A Mitomycin C test is performed.What is the likely finding?

A- Normal chromosomes
B- Chromosomal/DNA breakage
C- Trisomy
D- Monosomy
E- Isochromosome
Ans: B

531- A 70-year-old patient presents with a black toe that developed one week ago. On examination, the platelet count is 1,000,000/μL (10 lakh). What is the most likely cause?

A- Reactive thrombocytosis
B- Essential thrombocytosis
C- Thrombocytopenia
D- Disseminated intravascular coagulation (DIC)
Ans: B

532- A child with thalassemia major receiving 4-weekly blood transfusions developed High grade fever. Lab results showed: Hemoglobin (Hb): 5g/dL, Platelets: 70000, APTT: 50 sec Raised WBC count. The child was diagnosed with a transfusion reaction leading to secondary DIC. What is the appropriate treatment?

A- Low-dose heparin, cryoprecipitate
B- Normal saline, platelet concentrate
C- Normal saline, cryoprecipitate, FFP
D- Normal Saline, FFP, Antibiotic
Ans: C

533- If anti-D immunoglobulin is administered to the mother for Rh incompatibility, which type of antibody will be present in the newborn?

A- IgG
B- IgM
C- IgA
D- IgE
E- igD
Ans: A

534- Patient with Ant A and Rh negative blood group = B -ve A pregnant female requires an urgent blood transfusion. Her husband offers to donate blood, but the cross match results show that the recipient has Anti- A antibodies, Anti-B antibodies, and Anti- Rh antibodies, while the donor has Anti- A antibodies, no Anti- B antibodies, and no Anti- Rh antibodies. What is the recipient's blood group?

A- O+
B- O-
C- AB-
D- A-
E- AB+
Ans: B (First aid)

Explanation:
- Blood Groups and ABO Classification
- RBC Type AB ABO
- Group
- Antigens
- on RBC
- Surface A B A & B None
- Antibodies
- in Plasma Anti-B Anti-A None Anti-A
- &
- Anti-B

535- Which of the following is seen in peripheral blood smear of thalassemia patient?

A- Microcytic hypochromic anemia
B- Macrocytic hypochromic anemia
C- Normochromic hypochromic anemia
D- Normochromic normocytic anmeia
E- Micrcytic hyperchromic anemia
Ans: A

536- A teenager has Hb 8g/dl and needs blood transfusion every 4 weeks to maintain his Hb levels what is the most suitable blood transfusion in this case

A- Whole blood
B- Platelets
C- Red cell concentrate
D- FFPs
E- Leukocyte depleted blood
Ans: E

537- A child present in OPD with lethargy, CBC was ordered which shows Hb as 9.5g/dl, TLC was 3100, Platelets were 250000 and neutrophils shows multiple lobes which of he following is your diagnosis

A- Vitamin B12 deficiency
B- Vitamin B9 deficiency
C- Vitamin B1 deficiency
D- Vitamin C deficiency
E- Vitamin B3 deficiency
Ans: B

538- Most common presentation of thrombocytopenia is

A- Petechial hemorrhage
B- Joint hematoma
C- Purpuric patches'
D- Epistaxis
Ans: A

539- A young girl with history of gum bleed and menorrhagia. Her peripheral blood smear shows large platelets and platelet count is 45000 What is the diagnosis?

A- TTP
B- ITP
C- Spurious thrombocytopenia
D- Bernard soulier syndrome
Ans: B

Explanation:
- ITP – Vaccination + Large platelets + marked low platelets
- Bernard – Large platelets + Normal or slight low platelets

540- O-ive recepient transfused with O+ive Blood.Hemolysin is related to which Immunoglobulin in acute phase?

A- IgA
B- IgG
C- IgM
D- IgE
Ans: C

541- Coagulation is started by.

A- Factor III
B- Factor VIII
C- Factor XII
D- Factor VII
Ans: D

542- Which of the following is consequence of polycythemia Vera?

A- Myelodysplastic syndrome
B- Portal Vein thrombosis leading to Budd-Chiari syndrome
C- Myelofibrosis
D- Resolves with Iron supplementation
E- Progresses eventually to Essential thrombocythemia
Ans: C (Kumar and Clerk medicine)

Explanation:
Polycythemia Vera develops into
- Myelofibrosis in 30% of cases & into
- Acute myeloblastic leukaemia in 5% as part of the natural history of the disease

543- A patient presents with anemia, Ovalo-macrocytosis, and hypersegmented neutrophils on peripheral blood smear. Severe anemia and thrombocytopenia are also noted. What is the most likely cause?

A- Vitamin B12/folic acid deficiency
B- Thalassemia
C- Anemia of chronic disease
D- Iron deficiency Anemia
E- Pernicious Anemia
Ans: A

544- A female patient presents with symptoms of lethargy and fatigue, laboratory findings reveal hemoglobin of 7g/dl and MCV of 78fl and MCH of 25pg these CBC result is indicative of

A- Microcytic hypochromic anemia
B- Microcytic hyperchromic anemia
C- Normocytic normochromic anemia
D- Macrocytic normochromic anemia
E- Macrocytic hypochromic anemia
Ans: A

545- A post splenectomy patient is suffering from high grade fever, multiple bruises involving whole body, WBC 49X 10, Neutrophils 98%, what will you see in blood picture

A- FDP decreased, Platelets increased, PT normal, APTT increased
B- FDP increased, Platelets decreased, PT increased, APTT increased,
C- FDP decreased,platelets increased,PT Decreased,APTT increased
D- FDP increased,Platelets normal,PT decreased,APTT increased
Ans: B

546- A patient present with signs and symptoms of DIC which of the following used for correction of DIC

A- RED cell concentrate(RCC)
B- Cryoprecipitate
C- FFP
D- Antibiotics
E- Normal saline
Ans: C

547- A female patient present in OPD which complain of fever bleeding from gums and nose from 4 months for which CBC was ordered CBC report shows normal Hb was low TLC count was 9-12k and platelets were 1000000/microliter which of the following is your diagnosis

A- Polycythemia rubra vera
B- Essential thrombocytosis
C- Reactive thrombocytosis
D- Myloproliferative disorder
Ans: B

CamScanner

548- A child presented with bleeding after minor injury, his PT 14 and APTT 60 ,BT normal which of the following is likely cause
A- Hemophilia A
B- DIC
C- TTP
D- ITP
E- VWD
Ans: A

549- A female patient presents with the history of Nose & Gum bleeds. On examination, Splenomegaly & a Bone Marrow Aspirate shows dry tap. Investigations reveal the following findings: Hemoglobin (Hb): 10.3 g/dL, Total Leukocyte Count (TLC): 14,000 and Platelet Count: 1,000,000 (10^6/µL) What is the most likely diagnosis?
A- Myeloproliferative Disorder
B- Polycythemia
C- Leukemia
D- Essential thrombocytosis
E- Reactive Thrombocytosis
Ans: A

550- A woman presented with a black-colored foot. Two weeks later, she was found to have platelet levels of 1000000. Most probable Diagnosis?
A- Essential thrombocytosis
B- Reactive thrombocytosis
C- ITP
D- vWbd
Ans: A

551- Which cells when transfused to b+ patient will have least chance of reaction:
A- Packed RBCs of O+
B- Whole blood O+
C- Whole blood AB+
D- Whole Blood AB-
Ans: A

Explanation:
- A B+ patient has B antigens and Rh (D) antigen on their red blood cells, and they produce anti-A antibodies in their plasma.
- O+ blood lacks A or B antigens but has the Rh (D) antigen, making it compatible with a B+ recipient's plasma.
- Since it is packed RBCs (no plasma), it does not introduce anti-B antibodies, minimizing the chance of a reaction.

Whole Blood O+:
- Contains anti-B antibodies in the plasma, which would attack the B antigen on the recipient's RBCs, causing a reaction.

Whole Blood AB+:
- Contains both A and B antigens, which are incompatible with the recipient's anti-A antibodies, causing a reaction.

Whole Blood AB- :
- Although it lacks the Rh (D) antigen, it contains both A and B antigens, which are incompatible with the recipient's anti-A antibodies

552- Rapidly acting thrombolytic agent?
A- Heparin
B- Tissue thromboplastin
C- Tissue Plasminogen activator
D- Streptokinase
E- Urokinase
Ans: C

553- A boy presents with prolonged bleeding after trauma. His younger brother has a similar bleeding issue, but his sister is unaffected. Laboratory investigations reveal increased clot lysis time after administration of plasmin along with raised APTT. What is the most likely diagnosis?
A- Hemophilia A
B- Factor 8 Deficiency
C- Factor 9 Deficiency
D- vWd
Ans: B

554- A child presents with hematuria ,a palpable purpuric rash, and abdominal pain. What is the most likely underlying diagnosis?
A- HSP
B- ITP
C- TTP
D- HUS
Ans: A

555- What blood group is least likely to exhibit transfusion reaction with B+
A- O+whole blood
B- O+ PCV
C- B-
D- AB-
E- A-
Ans: B

556- A patient is suffering from Christmas disease needs to undergo a surgical procedure. Which of the following can be used
A- Fresh Frozen plasma
B- Cryoprecipitate
C- Whole blood
D- Plasma only
E- RCC
Ans: A

557- A teenager child present with severe purpura. Which of the following could be the reason for his condition
Platelet count 20000
A- Platelet count 90000
B- Immune Purpura
C- Histamine Release
D- C
Ans:

558- Patient had a fever for 5 days and has had an indwelling catheter during the whole time. What investigation would you perform to isolate the organism
Blood culture
A- Urine culture
B- Urine Culture and Blood Culture
C- CBC
D- Xray KUB
E- C
Ans:

559- Which of the following is most important for causing bleeding in DIC
A- Dec platelets and fibrinogen
B- Dec FDP
C- Membrane damage and increase permeability
D- Increase FDP
Ans: A

560- A female patient from a hilly area presents with lethargy & pallor. Investigations reveal a hemoglobin of 8 g/dL, an MCV of 75 fL, What is the likely deficiency causing these symptoms?
A- Iron
B- Calcium
C- Phosphorus
D- Magnesium
Ans: A

561- A 17-year- old boy presents with a rapid onset of widespread purpura all over his body. What is the most likely diagnosis?
A- Vitamin C deficiency
B- Platelet count: 20 × 10⁹/L
C- Platelet count: 90 × 10⁹/L
D- Decreased Factor VIII
E- Increased capillary permeability
Ans: B

562- A 64 years old female with fatigue, irritability after small cuts and recurrent infection alongside fever from 2 weeks. After investigation the report shows blast cells and aeur bodies in smear.What is the likely diagnosis.
A- Acute promyelocytic leukaemia
B- Acute lymphoblastic leukaemia
C- Acute myeloid leukaemia
D- Non-hodgkin lymphoma
E- Aplastic anemia
Ans: A

563- A patient with liver disease (LD) presents with Hb 10 g/dL, platelet count 90,000, and PT 20 seconds. What should be done first before performing a liver biopsy?
A- Correct PT to 13 seconds
B- Increase Platelet count to 100k
C- Perform a biopsy without correction
D- Administer vitamin K
Ans: A

564- The most common deficient factor is
A- Factor 8
B- Factor 9
C- Factor 11
D- Factor 12
Ans: A

565- A patient with bleeding, Labs show APTT 38 sec, PT 11 sec and BT 4 min Cause is:
A- Factor 9 deficiency
B- Factor 7 deficiency
C- Vit k deficiency
D- VWB disease
E- Factor 12 deficiency
Ans: A

566- Thalessemia major charateristic feature:
A- Hypersplenism
B- Defect in hemoglobinization of Rbcs
C- Hemolysis
D- Ineffective Erythropoiesis
Ans: D

567- A 60 years old with diagnosed CML, has presented with joint pain. What will be the initial investigation
A- ESR
B- Serum uric acid levels
C- ANCA
D- RA factor
Ans: B

CamScanner

568- A male patient presents with increased MCH, RBC, and MCHC, reddish appearance, and decreased erythropoietin levels. What is the most likely diagnosis?
A- Megaloblastic anemia
B- Polycythemia rubra vera
C- Secondary polycythemia
D- SLE
E- Myelofibrosis
Ans: B

569- Which of the following peripheral blood findings is associated with lead poisoning?
A- Megaloblastic anemia
B- Basophilic stippling
C- Microangiopathic changes
D- Lead line
E- Leukocytosis
Ans: B

570- A 2 years old child presented with paleness, & bowel disturbance.Labs reveal HB 5.6g/dL, MCV 107fL.Investiagtion of Choice:
A- Deficiency of lactate dehyrogenase
B- Serum Vitamin B-12 Levels
C- Anti-IF Antibody
D- Hb electrophoresis
Ans: B

571- A child with history of increased bleeding from stump presented with complains of Bleeding gums, his sister also facing similar issues. PT 16/13 sec APTT 60 sec, BT 20 sec.Decreased Factor 8 & ristocetin.Normal platelets. Cause?(Medicine Feb 2025)
A- vWd
B- Hemophilia
C- Vasculitis
D- ITP
E- Pseudo von willibrand
Ans: A

572- Which of the following is a tumor marker for Acute Lymphoblastic Leukemia (ALL)?(Medicine Feb 2025)
A- CD10
B- CD19
C- CD8
D- CD6
Ans: A

573- A patient presents with a blocked ureter. Which of the following effects on renal function would you expect? (Medicine Feb 2025)
A- Increased GFR, increased filtration fraction, and increased urine output
B- Decreased GFR, increased filtration fraction, and decreased urine output
C- Increased GFR, decreased filtration fraction, and increased urine output
E- Decreased GFR, decreased filtration fraction, and decreased urine output
Ans: D

574- A patient presents with recurrent jaundice, elevated indirect bilirubin, and low haptoglobin levels. What is the most likely diagnosis?(Medicine Feb 2025)
A- Hepatitis
B- Dubin-Johnson syndrome
C- Hemolytic anemia
D- Gilbert's syndrome
Ans: C

575- Which of the following tests is typically used to detect the Duffy blood group? (Medicine Feb 2025)
A- Enzyme-linked immunosorbent assay (ELISA)
B- Flow cytometry
C- Direct antiglobulin test (DAT)
D- Indirect antiglobulin test (IAT)
F- Coombs test
Ans: D

576- An elderly patient with a history of easy bruising over the past six months presents with thigh trauma and experiences continuous bleeding during surgery. Coagulation studies show prolonged PT and APTT, low fibrinogen, and thrombocytopenia. What is the most likely diagnosis?(Medicine Feb 2025)
A- Occult carcinoma
B- Sepsis and Disseminated Intravascular Coagulation (DIC)
C- Accidental Heparin administration during surgery
D- Warfarin use prior to surgery
E- Hemophilia A
Ans: B

577- A man presented with generalized body swelling for two weeks. Physical examination shows thick waxy skin hepatomegaly and enlarge kidney. 24 h/urinary protein was 4g/day. Kidney biopsy shows apple colored birefringence fibril under congo red stain. What is diagnosis(Medicine Feb 2025)
Hepatitis
A- Alzeihmer's
B- Malaria
C- TB
D- Multiple myeloma
E-
Ans: E

578- A patient presents with abdominal pain and joint pain, and the reticulocyte count is elevated. What is the most likely finding? (Medicine Feb 2025)
A- HbS
B- HbA
C- HbF
D- HbA2
Ans: A(Sickle cell crisis)

579- A newborn presents with bleeding tendencies. Which clotting factors are most likely deficient? (Medicine Feb 2025)
A- 2,7,9,10,
B- 7,10,11
C- 3,7,9,10
D- 2,7,12
Ans: A

580- Man with blood Group B-ve presented in ER requiring blood trasfusion, what blood could be transfused to him? (Medicine Feb 2025)
A- O-ve
B- AB+ve
C- B+ve
D- A+ve
Ans: A

581- A patient presents with increased cell lines and tear-drop-shaped cells on a blood smear. What is the most appropriate investigation?(Surgery Feb 2025)
A- CD31
B- CD36
C- c-MPL gene
D- JAK2 Mutation
Ans: D(Robins)
Explanation:
- Of pathogenic and possible therapeutic importance, the same JAK2 mutation that is found in polycythemia vera is present in around half of cases of primary myelofibrosis
- The peripheral blood smear is markedly abnormal. Red cells often exhibit bizarre shapes (poikilocytes, teardrop cells), and nucleated erythroid precursors are commonly present along with immature white cells (myelocytes and metamyelocytes), a combination of findings referred to as "leukoerythroblastosis." Abnormally large platelets often are present as well.
- The spleen usually is markedly enlarged, sometimes weighing as much as 4000 g, from the extensive extramedullary hematopoiesis

582- A 14 year old patient present in OPD with gum bleeding her sister also has same problem Ristocetin assay <30% and factor 8 <5% which of the following bleeding disorder boy is suffering from(Surgery Feb 2025)
A- Hemophilia
B- Christmas disease
C- DIC
D- Factor v deficiency
E- VWB disease
Ans: E

583- Dangerous about sepsis is(Surgery Feb 2025)
A- DIC
B- Low fibrinogen
C- Peripheral vasodilation
D- Vasoconstriction
Ans: A

584- 45 year old male presents with weight loss , fatigue and mild splenomegaly ,A peripheral blood shows tear drop cells an increased white cells count with immature myleocytes and basophlia what else u will find in this this patient(Surgery Feb 2025)
A- Philadelphia chromosomes
B- Jak 2 mutation
C- CALR mutation
D- Auer rods
Ans: A

585- A new born after birth is pricked at heel for checking blood glucose level but bleeding was not stopped for 30 minutes. What is the reason(Surgery Feb 2025)
A- Vitamin k deficiency
B- Hyperglycemia in mother
C- Hyperglycemia in baby
D- Hemophilia
E- vitamin A deficiency
Ans: A

CamScanner

586- A patient presents with joint pain,abdominal pain,and hepatosplenomegaly which of the following conditions is the most likely diagnosis(Surgery Feb 2025)
A- Hemoglobin S disorder
B- Hemoglobin C disease
C- Hereditary spherocytosis
D- Thalassemia
E- vitamin B12 anemia
Ans: A

587- Iron binds in ferrous form with(Gynae & Obs Feb 2025)
A- Transferrin
B- Ferritin
C- Hemoglobin
D- Hemosedrin
Ans: C

588- Which of the following is characteristic feature of thalaseemia major(Gynae & Obs Feb 2025)
A- HbF
B- HbA2
C- Microcytosis and hypochromasia
D- Increase pokliocytosis and anisocytosis
E- Serum feritin
Ans: A

589- A young boy has petechiae , bruises and epistaxis with normal BT & CT.Which investigation should be done? (Gynae & Obs Feb 2025)
A- CBC
B- Platelet count
C- Trephine biopsy
D- APTT
Ans: B

590- Tissue bleeding can be caused by several factors which of the following is most likely associated with tissue bleeding(Gynae & Obs Feb 2025)
A- Deficiency of coagulation factors
B- Thrombocytopenia
C- Impaired blood vessel integrity
D- Liver dysfunction
Ans: A

591- True regarding Blood group A(Gynae & Obs Feb 2025)
A- A agglutinogen on RBC surface
B- A agglutinogen in plasma
C- A agglutinin on RBC surface
D- B agglutinin on RBC surface
Ans: A

592- Which of the following is management of a woman with symptoms of DIC; Hb is 9g/dl, PT and APTT are raised; (Gynae & Obs Feb 2025)
A- Whole blood
B- RBC concentrate
C- FFP
D- Fresh whole blood
E- Cryoprecipitate
Ans: C

593- Which of the following base pair mutation occurs in sickle cell disease; (Gynae & Obs Feb 2025)
A- Adenine to thymine
B- Thymine to adenine
C- Cytosine to guanine
D- Guanine to adenine
E- Adenine to cytosine
Ans: D

594- If a G6PD deficient patient has children with a partner who has normal G6PD levels what will be the genetic outcome for their children? (Gynae & Obs Feb 2025)
A- 50% affected, 50% normal
B- All children will be normal
C- All males affected, No females affected
D- All females affected, No males affected
Ans: A

595- Which antigen is primarily responsible for RH incompatibility?(Gynae & Obs Feb 2025)
A- D antigen
B- C antigen
C- Lewis antigen
D- Kell antigen
Ans: A

596- A young boy is admitted with swelling in his knees. He is diagnosed with Christmas disease. Which of the following should be given to him as treatment? (Gynae & Obs Feb 2025)
A- Cryoprecipitate
B- Factor IX
C- Factor VIII Major
D- Factor XII
E- Factor VIII Minor
Ans: B

597- Vitamin B12 and folic acid supplementation in megaloblastic anemia leads to the improvement of anemia is due to (Radiology Feb 2025)
A- Increased DNA synthesis in bone marrow
B- Increased hemoglobin production
C- Erythroid hyperplasia
D- Increased iron absorption
Ans: A

598- A blood group contains: (Radiology Feb 2025)
A- A agglutinogen in plasma
B- B agglutinins in plasma
C- A Agglutinin In plasma
D- B Agglutinin in Serum
Ans: D

599- Which of the following findings is diagnostic of iron deficiency anemia? (Radiology Feb 2025)
A- Increased TIBC, decreased serum ferritin
B- Decreased TIBC, decreased serum ferritin
C- Increased TIBC, increased serum ferritin
D- Decreased TIBC, increased serum ferritin
Ans: A

600- A patient having history of bleeding and increased BT, increased aPTT? (Radiology Feb 2025)
A- VWD
B- Hemophilia A
C- **Vasculitis**
D- DIC
Ans: A

601- A patient had jejunal resection 4 months ago and now presents with weakness, low hemoglobin, and MCV >100. What is the most likely deficiency?(Radiology Feb 2025)
A- Vitamin B12 deficiency
B- Folate deficiency
C- Anemia of Chronic Disease
D- Sideroblastic Anemia
Ans: B

602- Regarding vWF, what is true? (Anesthesia Feb 2025)
A- Weight = 80,000 kDa
B- Binds Factor VII
C- Is a lipoprotein/glycoprotein
D- Synthesized in endothelium
Ans: D

603- Duffy antibodies investigation: (Anesthesia Feb 2025)
A- Normal temperature saline
B- Polyethylene glycol
C- Polygeline
D- RBCs & papain stain
Ans: B

604- Protein preventing RBC lysis/damage? (Anesthesia Feb 2025)
A- Tubulin
B- Spectrin
C- Collagen
D- Elastin
Ans: B

605- Appropriate indication for plasma therapy? (Anesthesia Feb 2025)
A- Hypoalbuminemia
B- Warfarin toxicity
C- Nephrotic syndrome
D- Thrombocytopenia
E- DIC (Disseminated Intravascular Coagulation)
Ans: B

606- A patient is diagnosed with generalized lymphadenopathy and large B-cell lymphoma. What is the treatment of choice? (Anesthesia Feb 2025)
A- Surgery alone
B- Surgery followed by chemotherapy
C- Surgery followed by radiotherapy
D- Radiation alone
E- Chemotherapy
Ans: E

607: A 15-year-old patient presents with pallor, weakness, and fever. Laboratory tests reveal a t(15;17) translocation. According to the WHO classification, what is the most likely diagnosis? (Anesthesia Feb 2025)
A- Acute lymphoblastic leukemia, minimally differentiated
B- Acute lymphoblastic leukemia, undifferentiated
C- Acute promyelocytic leukemia (APL)
D- Acute myeloblastic leukemia without maturation
E- Chronic myeloid leukemia
Ans: C

608- Stored blood has
A- Thrombocytosis
B- Acedemia
C- Hypernatremia
D- Hypokalemia
Ans: B

CamScanner

MUSKULOSKELETAL PATHOLOGY QUICK HINTS

Osteoprosis

- ✓ Trabecular (spongy) and cortical bone lose mass despite normal bone mineralization and lab values
- ✓ Most commonly due to bone resorption related to decrease estrogen levels and old age.
- ✓ Diagnosed by bone mineral density measurement by DEXA (dual-energy X-ray absorptiometry)

Osteopetrosis

- ✓ Due to defective Osteoclast failure of normal bone resorption that result in thick Dense bone that become prone to fracture
- ✓ Mutations in carbonic anhydrase II
- ✓ X-rays show diffuse symmetric sclerosis (bone-in-bone, "stone bone)

Osteomalacia/rickets

- ✓ Defective mineralization of osteoid or cartilaginous growth plates Most commonly due to vitamin D deficiency.
- ✓ In adult - It is osteomalacia
- ✓ In Child - It is Rickets
- ✓ X-rays show osteopenia and pseudofractures
- ✓ Children with rickets have pathologic bow legs (genu varum), bead-like costochondral junctions (rachitic rosary) craniotabes (soft skull)
- ✓ Decrease vitamin D Decrease serum Ca2+ Increase PTH secretion result in Low serum PO4
- ✓ Hyperactivity of osteoblasts Raised ALP.

Osteitis deformans/Paget disease

Increased osteoclastic activity followed by osteoblastic activity

Stages of Paget disease:

1. Lytic—osteoclasts
2. Mixed—osteoclasts + osteoblasts
3. Sclerotic—osteoblasts
4. Quiescent—minimal osteoclast/osteoblast activity

- ✓ Hat size can be increased due to skull thickening
- ✓ Hearing loss is common due to skull deformity.
- ✓ Mosaic pattern of bone
- ✓ May cause High output cardiac failure due to AV shunt
- ✓ Increase Risk of Osteosarcoma
- ✓ Long bone Chalk Stick fracture
- ✓ Treated with Bisphosphonates
- ✓ All Labs normal except raised ALP

Bone tumor

- ✓ Metastatic more common
- ✓ **Giant cell tumor** (Soap bubble appearance +Osteoclast like cells) - Epiphysis
- ✓ **Osteosarcoma** (Codman triangle - Periodteum elevation + sunburst appearance) + Malignant Osteoblast seen - Metaphysis
- ✓ **Osteochondroma** (most common benign) - Metaphysis
- ✓ **Ewing sarcoma** (onion skin) t(11;22) (fusion protein EWS-FLI1) - Diaphysis
- ✓ **Osteoblastoma** occurs in - Vertebrae
- ✓ **Osteoid osteoma** – Cortex of long bones + Has radiolucent osteoid core.

Osteoarthritis

- ✓ Mechanical—wear and tear destroys articular cartilage
- ✓ **Improve with rest**
- ✓ Osteophytes (bone spurs) form
- ✓ Development of Heberden nodes (at DIP) and Bouchard nodes (at PIP), and 1st CMC
- ✓ **Spare MCP**

Rheumatoid Arthritis

- ✓ Autoimmune—inflammation C induces formation of **pannus**
- ✓ HLA-DR4 associated
- ✓ ⊕Rheumatoid factor (IgM antibody that targets IgG Fc region; in 80%)
- ✓ Anti CCP more specific
- ✓ Pain, swelling, and morning stiffness lasting > 1 hour, improving with use
- ✓ Erosions, juxta-articular osteopenia cervical subluxation, ulnar finger deviation, swan neck boutonniere
- ✓ **Involves MCP, PIP, wrist**
- ✓ **Spare DIP or 1st CMC**
- ✓ **Caplan Syndrome** - RA + Pneumoconiosis
- ✓ **Felty Syndrome** - RA +Splenomegalay + Neutropenia)

Gout

- ✓ Acute inflammatory monoarthritis caused by precipitation of **monosodium urate crystals** in joint
- ✓ Joint is swollen, red, and painful. Classic manifestation is painful MTP joint of big toe (podagra)
- ✓ Crystals are **needle shaped and ⊖ birefringent** under polarized light (yellow under parallel light, blue under perpendicular light)

Calcium pyrophosphate deposition disease(Pseudo gout)

- ✓ Usually idiopathic, sometimes associated with hemochromatosis, hyperparathyroidism, joint trauma.
- ✓ Most commonly affected joint is the knee.
- ✓ Chondrocalcinosis (cartilage calcification) on x-ray.
- ✓ Crystals are **rhomboid and weakly ⊕ birefringent** under polarized light (blue when parallel to light)

Sjogren syndrome

- ✓ Autoimmune disorder characterized by destruction of exocrine glands (especially lacrimal and salivary) by lymphocytic infiltrates
- ✓ Predominantly affects females
- ✓ 40–60 years old.
- ✓ **Associated** with rheumatoid arthritis, SLE, systemic sclerosis
- ✓ Complication include Dental caries , MALT lymphoma and delivery of baby with neonatal lupus
- ✓ **Antibodies: SS-A (anti- Ro) and/or SS-B (anti-La)**
- ✓ Bilateral parotid enlargement with dry eyes and dry mouth

Septic arthritis

- ✓ S aureus, Streptococcus, and Neisseria gonorrhoeae are common causes
- ✓ Synovial fluid purulent (WBC > 50,000/mm3)

Seronegative spondyloarthritis

HLA B27 associated

- ✓ Psoriatic arthritis
- ✓ Associated with skin psoriasis and nail lesions.
- ✓ Dactylitis and "pencil-in-cup" deformity of
- ✓ DIP on x-ray

Ankylosing spondylitis

- ✓ Symmetric involvement of spine and sacroiliac joints
- ✓ Ankylosis (joint fusion), uveitis, aortic regurgitation.
- ✓ Bamboo spine (vertebral fusion) seen

Inflammatory bowel disease

- ✓ Crohn disease and ulcerative colitis are often associated with spondyloarthritis.

Reactive arthritis

Classic triad:

1. Conjunctivitis
2. Urethritis
3. Arthritis

- ✓ Associated with infections by Shigella, Campylobacter, E coli, Salmonella, Chlamydia, Yersinia.

CamScanner

SLE

- ✓ Organ damage primarily due to a type III hypersensitivity reaction and, to a lesser degree, a type II hypersensitivity reaction
- ✓ Associated with deficiency of early complement proteins (eg, C1q, C4, C2)
- ✓ Affect Mitral >Aortic valve
- ✓ Butterfly rash , Arthritis , Serositis and Photosensitivity
- ✓ Associated with Lib man sac endocarditis
- ✓ Terminal neoplasm associated with non bacterial thrombotic endocarditis

Cause of death in SLE

1. Kidney disease (Most common)
2. Accelerated CAD
3. Immune complex

- ✓ Anti DsDNA detect disease progression
- ✓ Anti Smith also positive
- ✓ Associated with sjogren(Anti SSA +) can cause neonatal lupus
- ✓ Associated with Anti phospholipids syndrome
- ✓ Characterized by thrombosis (arterial or venous) or spontaneous abortion along with laboratory findings of

1. Lupus anticoagulant,
2. Anticardiolipin,
3. Anti-β2 glycoprotein I antibodies.

Polymyositis

- ✓ Progressive symmetric proximal muscle weakness, characterized by endomysial inflammation with CD8+ T cells. Most often involves shoulders.

Dermatomyositis

- ✓ Clinically similar to polymyositis,
- ✓ Perimysial inflammation and atrophy with CD4+ T cells.
- ✓ Gottron papules , Heliotrope rash "Shawl and face" rash
- ✓ Darkening and thickening of fingertips and sides resulting in irregular,"dirty"-appearing marks.
- ✓ Increase Risk of Occult malignancy
- ✓ ⊕Anti-Mi-2 (helicase) highly specific
- ✓ ⊕Anti-Jo-1 (histidyl-tRNA synthetase), ⊕ anti-SRP (signal recognition particle)

Vasculitides

Large Vessel

Temporal(Giant Cell) Arteritis

- ✓ Unilateral headache, possible temporal artery tenderness, jaw claudication with Focal granulomatous inflammation with raised ESR
- ✓ Most commonly affects branches of carotid artery.
- ✓ Temporal artery biopsy diagnostic
- ✓ Associated with polymyalgia rheumatica
- ✓ Takayasu arteritis "Pulseless disease" (weak upper extremity pulses)
- ✓ Granulomatous thickening and narrowing of aortic arch and proximal great vessels with raised ESR

Medium size Vessel

Buerger disease (thromboangiitis obliterans)

- ✓ Intermittent claudication. May lead to gangrene , autoamputation of digits,
- ✓ Associated with smoking And Raynaud Phenomenon

Kawasaki disease (mucocutaneous lymph node syndrome)

- ✓ Occur in children
- ✓ **CRASH**
- ✓ Conjunctival injection, **R**ash , **A**denopathy (cervical) **S**trawberry tongue , **H**and- foot changes (edema, erythema), fever.
- ✓ May develop coronary artery aneurysms thrombosis or rupture can cause death

Polyarteritis nodosa

- ✓ Associated with Hep B(30%)
- ✓ GI symptoms Abdominal pain and melena
- ✓ Neurological dysfunction and renal damage
- ✓ Involves renal and visceral vessels, not pulmonary arteries.
- ✓ Transmural inflammation with fibrinoid necrosis.
- ✓ String of pearls appearance
- ✓

Small Vessel

Bachet Syndrome

- ✓ Recurrent aphthous ulcers, genital ulcerations, uveitis, erythema nodosum
- ✓ Pracipitater by HSV or Parvo
- ✓ **Associated with HLA-B5**
- ✓

Eosinophilic granulomatosis with polyangiitis(Churg-Strauss syndrome)

- ✓ Sinusitis and peripheral neuropathy (eg, wrist/foot drop)
- ✓ Asthma with eosinophilia
- ✓ MPO-ANCA/p-ANCA, increased IgE level.

Granulomatosis with polyangiitis(Wegener Granuloma)

Triad:

1. Focal necrotizing vasculitis
2. Necrotizing granulomas in **lung**(Hemoptysis) and **upper airway**(Nasal perforation and sinusitis)
3. Necrotizing glomerulonephritis(Hematuria and RBC Cast)

- ✓ PR3-ANCA/c-ANCA (anti-proteinase 3).

Immunoglobulin A vasculitis (Henoch-Schönlein purpura.)

- ✓ Most common childhood systemic vasculitis. Often follows URI.
- ✓ Classic **triad** of Henoch-Schönlein purpura

1. Hinge pain (arthralgias)
2. Stomach pain (abdominal pain associated with intussusception)
3. Palpable purpura on buttocks/legs

- ✓ Associated with IgA nephropathy (Berger disease).

Microscopic polyangiitis

- ✓ Necrotizing vasculitis commonly involving lung, kidneys, and skin with pauci-immune glomerulonephritis and palpable purpura.
- ✓ No granuloma and Nasopharyngeal involvement
- ✓ MPO-ANCA/p-ANCA (anti- myeloperoxidase).

Mixed cryoglobulinemia

- ✓ Often due to viral infections, especially HCV.
- ✓ Precipitate in the Cold.
- ✓ Mixed IgG and IgM immune complex deposition.
- ✓ Triad of palpable purpura, weakness, arthralgias.

Raynaud phenomenon

- ✓ Decrease blood flow to skin due to arteriolar (small vessel) vasospasm in response to cold or stress
- ✓ Color change from white (ischemia) to blue (hypoxia) to red (reperfusion).
- ✓ Called Raynaud disease when **Primary** (idiopathic), Raynaud syndrome when **Secondary** to disease process such as mixed connective tissue disease, SLE, or CREST syndrome

Scleroderma

Can involve pulmonary (interstitial fibrosis,), GI (esophageal dysmotility and reflux), Renal and cardiovascular

Diffuse scleroderma

- ✓ Widespread skin involvement, rapid progression, early visceral involvement. Associated with **anti-S 70 antibody (anti-DNA topoisomerase-I antibody) andanti-RNA polymerase III.**

Limited scleroderma

- ✓ Limited skin involvement confined to fingers and face.

Also with CREST syndrome:

- ✓ Calcinosis cutis

- ✓ Anti-Centromere antibody
- ✓ Raynaud phenomenon
- ✓ Esophageal dysmotility
- ✓ Sclerodactyly
- ✓ Telangiectasia.
- ✓ More benign clinical course.

Myasthenia Gravis

- ✓ **Myasthenia gravis** -- Antibodies' against postsynaptic voltage gated cannels
- ✓ Diagnostic test -- **ACH receptor antibodies**
- ✓ Most accurate/confirmatory/gold standard -- **EMG**
- ✓ Initial drug for Myasthenia gravis --**Neostigmine**
- ✓ DOC For maintained therapy -- **Pyridostigmine**
- ✓ **Physostigmine** – Crosses BBB immediately and Increase Acetylcholine
- ✓ **In Lambert eaten Syndrome** – Antibodies are directed against Calcium channels
- ✓ Associated with Thymoma
- ✓ Show Type 2 HS

MUSKULOSKELETAL PATHOLOGY

1- **Patient with maxillary swelling. On radiology radiolucent and radio-opaque, and ground glass appearance diagnose is**
A- Ameloblastoma
B- Osteomyelitis
C- Fibrous dysplasia
D- Osteoarthritis
Ans: C

2- **A 35 year female having malar rash and positive anti ds DNA now develops proteinuria, foamy urine & hematuria. The most likely cause will be:**
A- Nephrotic syndrome
B- Amyloidosis
C- Cystitis
D- Glomerulonephritis
E- Lupus nephritis
Ans: E

3- **A patient presented with dry eyes and dry mouth most suitable investigation for diagnose is:**
A- Anti SSA
B- Anti DsDNA
C- Anti RNA
D- ANA
Ans: A

Explanation:
- Anti SSA and SSB -Sjogren
- Ant DsDNA -SLE
- ANA -General marker of Autoimmune disease

4- **Bone remodeling is done by:**
A- Osteocyte
B- Osteoclast
C- Osteoblast
D- Osteoblast + Osteoclast
Ans: D

Explanation:
- Osteoblast – Form Bone matrix
- Osteoclast – Resorption of Bone matrix
- Osteocyte – Maintain Bone integrity
- Bone Dimineralization – PTH
- Bone Mineralization – Vit. D
- Bone Remodeling Vitamin – Vit. C

5- **Fundamental defect in SLE:**
A- Some reaction to hydralazine
B- Tissue antigens against
C- Failure of B & T cells for tolerance to self-antigen
D- Due to anti centromere antibodies
Ans: C

6- **A 35 years old female presents with 6 month Hx of fingers turning pale in cold (Raynaud's phenomenon) also having mild dyspnea with no wheeze, B/L pleural effusion, creatinine was high urea also raised, ANA positive. What is the diagnosis?**
A- Discoid lupus erythematous
B- Progressive Systemic Sclerosis
C- SLE
D- Sjogren Syndrome
E- RA
Ans: B

7- **A 35 years old female presents with 6 month hx of fingers turning pale in cold (Raynaud's phenomenon) also having mild dyspnea with no wheeze, tight skin with mild enlarge spleen, creatinine was high urea also raised, ANA positive. HB 10 WBC and platelets normal what is the diagnosis?**
A- Discoid lupus erythematous
B- Progressive Systemic Sclerosis
C- SLE
D- Sjogren Syndrome
E- Scleroderma
Ans: E (Kaplan)

8- **A female developed proximal symmetrical muscle weakness power of 3/5 and anti jo antibodies were positive. What other feature is most likely associated with it?**
A- Arthralgia
B- Arthritis
C- Skin rash
D- Cardiac failure
E- Renal failure
Ans: C (Dermatomyositis)

9- **A female complained of body aches. Having malar rash. Her ANA is also positive. What is likely diagnose?**
A- Dermatomyositis
B- Systemic Sclerosis
C- RA
D- SLE
E- OA
Ans: D

10- **A young girl develops rash on cheeks & nose There is no other complaint Biopsy of the skin reveals IgG deposits in the rash but the surrounding skin is normal. Serum ANA is Positive. Which other findings associated with it?**
A- Collagen Decrease
B- Compliment Level Decrease
C- Compliment Level Increase
D- C1 Esterase
Ans: B

CamScanner

Explanation:
- Early compliment deficiency (C1-4) – Increase risk of recurrent pyogenic sinus respiratory infection and SLE
- Terminal compliment deficiency (C5 – 9) – Increase risk of neisseria bacteremia.

11- A Patient K/C of lumbago presents with left sided chest pain non radiating cardiac enzymes are normal On exam tenderness on 5th and 6th rib at post side of intercostal space diagnose is:
A- Chostochondritis
B- MI
C- Aortic aneurysm
D- Pericarditis
E- Myocarditis
Ans: A

12- An astronaut in space for very long time is at risk to develop which chronic problem?
A- Polycythemia
B- Decrease lung compliance
C- Decrease bone mass
D- Decrease surfactnct
E- Secondary polycythemia
Ans: C (Space shift osteopenia)

13- 26 year old female presented with complain of her fingers turning white then blue then red when exposed to cold. What is she suffering from?
A- Crest syndrome
B- Raynauds phenomenon
C- Sjogrens disease
D- SLE
E- Sjogren syndrome
Ans: B

14- A girl presented with malar butterfly rash, joint pain and repeated history of abortion ANA + what is diagnose?
A- Rheumatoid arthritis
B- SLE
C- Bachet disease
D- Sjogren syndrome
E- Reactive arthritis
Ans: B

15- 35 year old female presented with difficulty in swallowing. There is loss of wrinkles on her skin and she has difficulty eating with her hands and typing on the computer what is the diagnosis
A- Dermatomyositis
B- CREST Syndrome
C- Polymyositis
D- M.G
E- Ryanoid phenomenon
Ans: B

16- 33 years old female is found to have hematuria and proteinuria in urinalysis. She is not complaining of dysuria abdominal pain or any other urinary symptoms you notice on exam that her face looks cachexic. Her buccal fat pads are absent and her eyes appear shrunken which of the following is the likely diagnosis?
A- Type 2 membranoproliferative glomerulonephritis
B- Lupus nephritis
C- Acute glomerulonephritis
D- Type 1 membranoproliferative glomerulonephritis
Ans: B

17- Most common tumor of bone in second decade of life:
A- Osteochondroma
B- Chondrosarcoma
C- Osteosarcoma
D- Giant cell tumor
E- Ewing Sarcoma
Ans: C

18- Carpal tunnel syndrome causes compression of which nerve?
A- Ulnar nerve
B- Radial nerve
C- Muskulocutaneous nerve
D- Median nerve
E- Axillary nerve
Ans: D

19- 52 years man with lytic lesion in bone, back pain and weakness apple green birefringence & congo stain positive on damage to kidney is most suitable investigation to reach diagnose is:.
A- Immunoelectrophoresis
B- Protein electrophoresis
C- Hb electrophoresis
D- Benze Jones Proteins
E- ELISA
Ans: B

Explanation:
Multiple myeloma shows green birefringence when stained with congo red stain and diagnose by Protein Electrophoresis.

20- In multiple myeloma what is increased?
A- Plasma cells.
B- M proteins
C- Phosphate
D- Sodium
E- B cells
Ans: B

21- Osteosarcoma involves which site?
A- Diaphysis
B- Metaphysis
C- Epiphysis
D- Diaphysis and Epiphysis
Ans: B(FA)

Explanation:
- Giant cell tumor (Soap bubble appearance) - Epiphysis
- Osteosarcoma (Codman triangle sunburst appearance) + Osteochondroma (most common benign) - Metaphysis
- Ewing sarcoma (onion skin) – Diaphysis
- Osteoblastoma occurs in - Vertebrae
- Osteoid osteoma – Cortex of long bones +
- Has radiolucent osteoid core.

22- Periarticular erosions are characteristic of which disease?
A- Rheumatoid Arthritis
B- Osteo arthritis
C- Paget disease
D- Osteoprosis
E- Multiple myeloma
Ans: A

23- A lady present with recurrent abortion in Gynae OPD which Antibody should be tested for her condition?
A- Anti SSA
B- Lupus anticoagulant
C- Anti SSB
D- ANA
E- Anti Smith
Ans: B

Explanation:
Antiphospholipid syndrome causes recurrent abortion characterized by following three antibodies.
1. Lupus anticoagulant
2. Anticardiolipin antibody
3. Anti Beta 2 Glycoproteins-I antibody

24- Mature bone is formed of which type of crystals?
A- Calcium hydroxyapatite
B- Calcium carbonate
C- Calcium oxalate
D- Calcium phosphate
Ans: A

25- A young pragnant lady with the history of recurrent abortion and thrombosis, which condition is most likely suffering fro/m?
A-
B- Immune Thrombocytopenic purpura
C- SLE
D- Anti phospholipid antibody syndrome
Ans: DIC
C

26- A female complained of body aches. Having malar rash. Her ANA is also positive. What next investigation to confirm it?
A- Anti ds DNA
B- Anti cardiolipin
C- Anti CCP
D- Anti Ro
Ans: A

27- Sjogren is most commonly seen with:
A- Rheumatoid arthritis
B- SLE
C- Primary sclerosing
D- PBC
Ans: A (It is most common)

28- Osteoblastic activity marker is:
A- ALP
B- ALT
C- GGT
D- IL-10
Ans: A

29- Bone forming cells:
A- Osteoblasts
B- Fibroblast
C- Osteocyte
D- Osteocolast
Ans: A

Explanation:
- Osteoblast: Form Bone matrix
- Osteoclast: Resorption of bone
- Osteocyte: Maintain Bone integraity and matrix

30- What is true about dermatomyositis?
A- May be associated with CA Lung
B- Is a condition in which CS are contraindicated
C- May occur in acute form in children
D- Mainly affects women of 10-20 years
Ans: A

31- 40 year old man with back pain, apple green birefringence & congo stain positive on damage to kidney is most likely suffering from?
A- SLE
B- Multiple Myeloma
C- RA
D- Scleroderma
Ans: B

32- In multiple myeloma, immunoglobulin's are raised in the following order?
A- IgM, IgA, IgG
B- IgG, IgA, IgM
C- IgG, IgM, IgA
D- IgA, IgG, IgM
Ans: B (Robins)

CamScanner

Explanation:
- IgG 60%
- IgA 20-25%
- IgM 15% or rarely seen

34- A young male comes to you with the complain of severe right knee joint pain having some tumor which is composed of multinucleated giant cell and stromal cells which of the following appearance can be appreciated on X-RAY?
A- Soap bubble appearance
B- Onion skin appearance
C- Sunbursh appearance
D- Punched out leisons
Ans: A

35- A lady has diabetes and has pain in joint of her hand which is severe in morning and stiffness lasts more than 1hr likely due to:
A- Gout
B- Osteoarthritis
C- Rheumatoid arthritis
D- None
Ans: C

36- Bone mineralisation is done by:
A- Vit. C
B- Vit. D
C- PTH
D- None
Ans: B

Explanation:
- Bone Dimineralization – PTH
- Bone Minerlazation – Vit. D
- Bone Remodeling Vitamin – Vit. C
- Bone Remodeling – Osteoblast + Osteoclast

37- Recurrent abortion is important feature of:
A- SLE
B- Anti-phospholipid syndrome
C- Systemic sclerosis
D- Rheumatoid arthritis
E- Gonococcal arthritis
Ans: B

38- SLE affects which organ most?
A- Lungs
B- Joints
C- Liver
D- GIT
Ans: B

39- Soap bubble appearance on x – ray:
A- Osteomyelitis
B- Giant cell tumor
C- Ewing sarcima
D- Osteoma
Ans: B

40- Bence Jones protein is the feature of:
A- Multiple myeloma
B- Malihnant myeloma
C- Marfan syndrome
D- Digorge syndrome
Ans: A

41- Patient with chronic headache on one side, on examination temporal artery stiffness diagnosis:
A- Rheumatoid Arthritis
B- Giant Cell Arteritis
C- Kawsaki disease
D- Takayasu Arteritis
Ans: B

42- Which of the following investigation most sensitive for the SLE:
A- ANA
B- AMA
C- Anti Ds DNA
D- Anti Ro Antibodies
Ans: A

Explanation:
- Most sensitive test for SLE is: ANA
- Most Specific test for SLE is: Anti Smith > Anti DsDNA

43- A female presented with pain in hands and joints with morning stiffness most likely suffering from:
A- Osteoarthritis
B- Rheumatoid arthritis
C- SLE
D- Septic arthritis
Ans: B

Explanation:
- RA: Morning stiffness present
- OA: Morning stiffness if present less than 30 minutes

44- A 30 years old female patient developed proximal symmetrical muscle weakness, deltoid muscle biopsy shows necrosis with neutrophils, ANA was negative and Anti-Jo antibodies were positive what's the patient suffering from:
A- SLE
B- Dermatomyositis
C- RA
D- Sjogren syndrome
Ans: B

45- Patient presented with history of Arthritis & Urinary problem that was found to be HLA-B27 +Ve & associated with ocular problems:
A- Reiter's Syndrome
B- Ankylosing Spondylitis
C- UTI
D- Rheumatoid Arthritis
Ans: A

Explanation:
HLA B27 is associated with:
- Ankylosing Spondylitis
- Acute Anterior Uveitis
- Reactive Arthritis
- Enteric Arthropathy
- Psoriatic Arthritis

Reactive Arthritis formely known as Reiter's syndrome is a form of inflammatory arthritis that develops in response to an infection in another part of the body (Cross-Reactivity). Reiter's syndrome consist of Arthritis, uveitis & urethritis.

46- A female presented with a complaint of itching, dryness of eyes and mouth, dysphagia, angular fibrosis. Her X-ray shows interstitial fibrosis.Cause:
A- Sjorgensyndrome
B- Progressive systemic sclerosis
C- SLE
D- RA
Ans: B (Kaplan)

47- Which of the following is most common findings in Autoimmune conditions?
A- RA
B- Hematological
C- Malignancy
D- Skin Rash
Ans: B

48- Ewing sarcoma involves:
A- Diaphysis
B- Metaphysis
C- Epiphysis
D- Metaphysis and Epiphysis
Ans: A

Remember: GEOMED
- Giant cell tumor - **Epiphysis**
- Osteomyelitis- **Metaphysis**
- Ewing sarcoma - **Diaphysis**

49- Dysphagia is most commonly present in which of the following conditions?
A- SLE
B- Dermatomyositis
C- Scleroderma
D- Lesch-Nyhan Syndrome
Ans: C

50- Bones strength depends on which of the following?
A- Arrangement of collagens
B- Holes and gaps
C- Decrease density
D- Increase density
E- Bone matrix and mineral ratio
Ans: E

51- The ESR above 100 mm/hr. is in which of the following diseases?
A- Congestive heart failure
B- Polycythemia
C- Leukocytosis
D- Multiple Myeloma
Ans: D

52- During osteogenesis:
A- Osteoblasts secretes ALP
B- Osteocytes secrets ALP
C- Increase of serum calcium
D- Osteoclasts are bone-forming cells
Ans: A

53- A patient complains of hearing sound better in a noisy environment than a quite one, what is the cause?
A- Foreign body
B- Osteoma
C- Osteosclerosis
D- Traumatic bone cyst
Ans: C

54- Bone density is best assessed by:
A- Dexa scan
B- MRI
C- Ultrasound
D- X-ray
Ans: A

55- Osteoblastic activity is decreased by:
A- GH
B- Cortisol
C- Estrogen
D- PTH
Ans: B

56- A patient is diagnosed as case of Aplastic anemia. He is suffering from osteomyelitis the most likely organism?
A- Staphylococcus aureus
B- Streptococcus
C- Salmonella
D- E.coli
Ans : A

57- Assessment of muscle injury by:
A- Myoglobin
B- CKMB
C- CKBB
D- CKMM
E- LD
Ans: D

58- A child with retinoblastoma radiotherapy was given a second tumor arises in lower limb what could be the tumor:
A- Lymphoma
B- Osteosarcoma
C- Osteoblastoma
D- BCC
E- SCC
Ans: B

CamScanner

59- Which one of the following neurological condition is most commonly associated with Rheumatoid Arthritis?
A- Carpal tunnel syndrome
B- Meningitis
C- Peripheral neuropathy
D- Gillian barre syndrome
Ans: A

60- Specific appropriate diagnosis of primary gout by:
A- Urate crystals in the joints
B- Plasma urate
C- Urine urate
D- Urate creatine ratio
Ans: A

61- 50 years Old man with arthritis from last 5 years. Left and right cardiomyopathy and raised Ferritin. Which other investigation will help in Dx:
A- Anti-centromere antibodies
B- ESR more than 75
Ans: B

62- 65 years old female with bone fracture, diagnosed as osteoporosis what drug should be given?
A- SERM
B- Estrogen
C- Estrogen
D- Progesterone
Ans: A

63- Pannus is a feature of:
A- Rheumatiod artheritis
B- Ankylosing spondylitis
C- Osteoarthritis
D- Rieter syndrome
Ans: A

64- Patient presented with butterfly rash and proteinuria. The most diagnostic investigation would be:
A- Anti DS DNA
B- ASO titer
C- RE cells
D- Anti Ro
Ans: A

65- Patient with discoid rash arthritis and hemolytic anaemia what's most specific investigation?
A- ANA
B- Anti-ds DNA antibody
C- RNA studies
Ans: B

66- A young girl (15-25 years) develops rash on cheeks & nose when she goes in sun. There is no other complaint & the rash subsides when she is indoors. Biopsy of the skin reveals IgG deposits in the rash but the surrounding skin is normal. Serum ANA is negative. Most probable diagnosis is:
A- Discoid lupus
B- SLE
C- Progressive systemic sclerosis
D- Contact dermatitis
Ans: A

67- 70 years old man presents with myalgia, rash & arthralgia. Joints examination reveal no abnormality. Motor power is 5/5. ANA is positive with speckeled appearance. If anti-ribonucleoprotein RNP is also positive then the diagnosis is:
A- Mixed connective tissue disorder
B- Dermatomyositis
C- SLE
D- Polymyositis
Ans: A

68- Rheumatoid arthritis in pregnancy leads to:
A- MR
B- MS
C- Pulmonary regurgitation
D- TR
Ans: B

69- Which of following is different from others?
A- Chondrocytes
B- Chondroblasts
C- Osteoblasts
D- Osteoclasts
E- Osteocytes
Ans: D

70- Sjgorens syndrome patient ANA positive most serious long-term complication:
A- Glomerulonephritis
B- Pulmonary interstitial fibrosis
C- Muscle pain
D- Joint pain
Ans: B

71- Child with fever arthritis, rash and blindness:
A- Henoch schonlein purpura
B- Lyme disease
C- Chronis juvenile arthritis
D- Rheumatic fever/arthritis
Ans: C

72- Patient of rheumatoid arthritis has dry eyes and dry mouth. The cause is:
A- Autoimmune
B- Infection
C- Neoplasia
D- idiopathic
Ans: A

73- Anti-nuclear antibody is present in:
A- Lupus nephritis
B- Acute glomerulonephritis
C- Celiac disease
D- Hoshimotos thyroidits
Ans: A

74- Decrease in Complement levels occur in:
A- Rheumatoid arthritis
B- Ankylosing spondylitis
C- Systemic lupus erythematous
D- CKD
E- Liver disease
Ans: C

75- Malar rash seen with:
A- Decrease complement level
B- Increase complement level
C- Vasculitis
D- Decrease CD4 level
Ans: A

76- With rapidly repeated stimulus to a skeletal muscle activation of contractile mechanism occur repeatedly before any relaxation has occurred (Continuous contraction without relaxation) and individual response run into one another such response is called:
A- Tetanic contraction
B- Tetanus
C- Tetany
D- Spasm
Ans: A
Explanation:
- Tetanic contraction – No relaxation period
- Tetany – Has some relaxation in between

77- Patient presented with pericarditis , pleural effusion and joint pain which lab investigation used for screening
A- AMA
B- Anti Jo antibody
C- ANA
D- Anti SSA
Ans: C

78- A patient presented with malar rash Joint pain and Photosensitivity what other findings can be there
A- Ankylosing joint
B- Anuria
C- Leg ulcer
D- Pannus
Ans: A

79- Patient on dialysis develop osteoprosis due to increase osteoblastic activity of
A- PTH
B- Vitamin D
C- Calcitonin
D- Cortisol
Ans: A

80- A patient using steroid for very long time he is at risk of:
A- Hypoglycemia
B- Hypokalemia
C- Osteogenisis
D- Osteoporosis and fracture
Ans: D

81- A women Present with the problem of wrinkle of face dissapearance and joint movemente of hand is restricted on labs test her skin has increase dermis lyers and increase keratin
A- Dermatomyositis
B- CREST syndrome
C- Squamous cell CA
D- Basal cell CA
Ans: B

82- Osteonic canal running obliquely and transversely connecting the medullary cavity with the cortex:
A- Canaliculi
B- Lacunae
C- Howship lacunae
D- Volkman canal
Ans: D

83- A young thin lean boy with sign of tetany having blood Ca Level 6 (normal 8-9) and urine Excretion level is 50 (normal 24-300) What will be the cause?
A- Vitamin D deficiency
B- Primary hypoparathyriodism
C- CRF
D- Hyperparathyroidism
Ans: A

84- Mineral of the bone is:
A- Calcitonin
B- Hydroxyapatite
C- Calcium oxide
D- Calcium
Ans: B

CamScanner

85- Fracture of long bone will stop longitudinal growth
A- Epiphyseal plate
B- Epiphyseal line
C- Anatomical neck
D- Metaphysis
E- Diaphysis
Ans: A

86- Female with purpura on legs proteinuria burning sensation on hands and feets and dry mouth ANA profile negative diagnose is:
A- SLE
B- Henoch schonlein purpura
C- Mixed cryoglobulinemia
D- IgA nephropathy
Ans: C

87- 40 years old male with ulcerative colitis now there is exacerbation of GI symptoms. You can assess severity with?
A- Erythema nodosum
B- Anemia
C- Dose of Salazopyrin
D- Ankylosing spondylitis
E- Dysplasia on colonoscopy
Ans: D

88- Patient has nodules on extensor surface of both legs with skin rash on both shin. He is also having Hilar lymph node and eye involvement. Most likely diagnose is:
A- Bachet disease
B- Malaria
C- TB
D- Lofgren syndrome
Ans: D

89- Patient presented with joint symptoms, low grade fever, ANA screen was done but that was negative and only Anti RNP antibodies were positive. These are seen in?
A- Dermatomyocites
B- CREST
C- Polymyosites
D- SLE
E- Mix CT disorder
Ans: E

90- Female patient with pain in first metatarsophalyngeal joint due to:
A- Hypercalcemia
B- Gouty arthritis
C- Rheumatoid arthritis
D- Osteoarthritis
E- Hyperurcemia
Ans: B

91- Old age women presented with bluish discoloration of hand on cold exposure this is due to
A- Sclerosis
B- Primary Ryanaud phenomenon
C- Cervical rib
D- Hypercalcemia
Ans: B

92- M band is in multiple myeloma produced by what cells
A- Monocytes
B- Plasma cells
C- Macrophages
D- T cell
Ans: B

93- In Patient having Skin fibrosis and joint pain what finding will be seen
A- Excessive fibrosis
B- Joint deformity
C- Hemorrhage
D- More collagen
Ans: B

94- A patient presented with muscle weakness not improved with neostigmine auto antibodies against voltage gated Ca channel what is your diagnose?
A- Multiple sclerosis
B- Parkinson disease
C- Myasthenia gravis
D- Lambert eaten syndrome
Ans: D

95- What is the most dangerous complication of sjogren syndrome
A- Pancreatis
B- Lung abscess
C- B cell Lymphoma
D- Ca oral cavity
Ans: C

96- An Old man was playing with his grand son in garden experiences pain in his right toe he was febrile with redness in toe. His CRP positive, Culture negative and synovial fluid analysis negative for bireferengence diagnose is:
A- Osteoarthritis
B- Rhematoid arthritis
C- Acute Gout
D- Pseudogout
Ans: C

97- Test for myasthenia gravis?
A- ANA
B- Tensilon test
C- Ca stimulation
D- Edrophonium
Ans: D

98- Desease effect of Muscle relaxant seen in which of the following?
A- Multiple sclerosis
B- Parkinson disease
C- Myasthenia gravis
D- GB syndrome
Ans: C

99- A patient exhibits signs of Myasthenia Gravis, what is best confirmatory test in him?
A- Biopsy
B- EMG
C- Edrophonium
D- Ach receptors antibodies
Ans: B

100- A patient having muscle weakness which drug should be used to diagnose the case?
A- ANA
B- EMG
C- Ca stimulation
D- Edrophonium
Ans: D

101- A patient present with arthritis having joint pain and morning stifness with CCP being raised andANA negative. There is a precursorprotein which stains red on Congostain. What is the precursor protein?
A- Serum amyloid precursor protein
B- Serum amyloid associated protein
C- Lamba light chain
D- Transthyretin
E- Beta 2 microglobulin
Ans: B

102- Young girl presented with butterfly rash, and alopecia which investigation should be done?
A- CRP level
B- Serum complemnt C5 level
C- Anti RNP
D- Rheumatoid factor
E- ANA
Ans: E

103- A patient has malaria rash, petechiae and bodyache.On bone marrow aspirate, there is hyperplasia of megakaryocytes and ANA positive the most likely diagnosis is:
A- Immune thrombocytopenia with SLE
B- DIC
C- TTP
D- Myelodysplastic syndrome
E- ITP
Ans: A

104- SLE main effect on
A- Joint
B- Bone
C- Skin
D- Heart
Ans: A

105- A patient presented with Bilateral Ptosis with muscle wasting on mastication there is acetylcholine receptor suitable pathology is
A- Myasthenia Gravis
B- Eaton Lambort Syndrome
C- GBS
D- Polio
Ans: A

106- Patient was known case of Rheumatoid arthritis, but now she developed dry eyes dry mouth. What is the disease?
A- SLE
B- CREST syndrome
C- Osteoarthritis
D- Scleroderma
E- Sjogren syndrome
Ans: E

107- Sjogren syndrome marker is:
A- Anti SSA
B- Anti DsDNA
C- Anti RNA
D- ANA
E- HLA B27
Ans: A
Explanation:
Sjorgen markers involved anti RO (Anti SSA) and anti LA (Anti SSB)

108- Patient has muscle spasm at the end of the day, which test is used to help in diagnosis?
A- Tensilon
B- EMG
C- Edrophonium
D- Physiostigmine
Ans: B

CamScanner

109- HLA B27 is associated with:
A- Rey syndrome
B- Ankylosing spondylitis
C- R.A
D- SLE
E- Psoriatic arthritis
Ans: B >E

110- A female with dry eyes dry mouth having dysphagia , bilateral parotid swelling, on x ray pneumonitis.What is the likely cause?
A- Sjogren's syndrome
B- Primary systemic sclerosis
C- Rheumatoid arthritis
D- Osteoarthritis
Ans: B

111- A male with normal size skull and trunk and short extremities.Musculoskeletal growth occurs in which of following genetic disease?
A- Klinter syndrome
B- Achondroplasia
C- Down syndrome
D- Turner syndrome
E- Edward syndrome
Ans: B

112- A patient having history of Fever , cough and myalgias . He is having bony pain. Now symptoms has progressed to bone and there is iliac bone mass . ALP is normal and no other tumor markers was raised. What is the likely cause?
A- Teratoma
B- Chondroma
C- Bone tb
D- Neuroma
Ans: C

113- A 35 years old female presents with 6 month hx of fingers turning pale in cold (Raynaud's phenomenon) also having mild dyspnea with no wheeze, with mild enlarge spleen, creatinine was high urea also raised, ANA positive. HB 10 WBC and platelets normal. Which antibody will be raised
A- Anti SSA
B- Anti SSB
C- Anticentromere
D- AMA
E- Antimicrosomal
Ans: C

114- A female with dry eyes dry mouth having dysphagia, bilateral parotid swelling, on x ray pneumonitis what is likely cause
A- Sjogren's syndrome
B- Primary systemic sclerosis
C- Rheumatoid arthritis
D- Osteoarthritis
Ans: B

115- A lady presented with Malar rash, Anemia, Thrombocytopnia & recurrent 4 abortions in Gynae OPD .Which Antibody should be tested for her condition?
A- Anti russel Antibody
B- Anti Cardiolipin antibody
C- Anti DsDNA
D- ANA
E- Anti Smith
Ans: B

116- Woman after cast applied develop pain red tender hot leg this is due to
A- Cellulitis
B- Vasculutis
C- Complex regional pain syndrome type 1
D- Complex regional pain syndrome type 2
Ans: A

117- An astronaut in space for very long time is at risk to develop which chronic problem?
A- Polycythemia
B- Decrease lung compliance
C- Bone demineralization
D- Decrease surfactant
E- Decreased O2
Ans: C (Space shift osteopenia)

118- Low serum compliment is seen in which condition
A- SLE
B- Ankylosing spondylitis
C- Rheumatoid arthritis
D- Multiple sclerosis
E- Dermatomyositis
Ans: A

119- 40 year old man with back pain, apple green birefringence & congo stain positive on damage to kidney is most likely suffering from?
A- SLE
B- Multiple Myeloma
C- RA
D- Scleroderma
Ans: B

120- A 35 years old patient presented with bone fracture. On lab investigation vitamin d level were reduced likely cause is
A- Scurvy
B- Osteoprosis
C- Osteopetrosis
D- Osteoarthritis
Ans: B

121- A patient has Bilateral parotid swelling and has dysphagia and oral lesions what is mechanism
A- Autoimmune
B- SLE
C- Metastatic
D- Compliment mediated
Ans: A

122- Patient on antirheumatic drugs develop cutaneous manifestation due to?
A- Sjogren syndrome
B- Vitamin deficiency
C- SLE
D- Osteoarthritis
Ans: C

123- Patient with SLE for 6 Years Having deranged Cell indices, Now Lethargic. Diagnosis can be done by:
A- Hb Electrophoresis
B- Bone marrow biopsy
C- Anti-Globulin Antibody
D- Anti DsDNA
Ans: D

124- 52 years man with lytic lesion in bone, back pain,Hematuria and weakness along with apple green birefringence & congo stain positive on damage to kidney. He is most likely having:
A- Amyloidosis
B- SLE
C- Rhematoid arthritis
D- Scleroderma
Ans: A

125- Sjogren Syndrome" is associated with increased risk of Having:
A- Rheumatoid arthritis
B- Non Hodgkin Lymphoma
C- Scleroderma
D- Hashimoto's Thyroiditis
E- MALT Lymphoma
Ans: A

126- Secondary ossification present in
A- Epiphysis
B- Epiphyseal plate
C- Diaphysis
D- Metaphysis
Ans: A

127- Sjogren syndrome is associated with Risk of developing:
A- lupus erythematosus
B- Rheumatoid arthritis
C- Hashimoto thyroiditis
D- Hodgkin Lymphoma
E- Non Hodgkin Lymphoma
Ans: B

128- A female presented with Mild fever & Painful Swollen Joints. She is most likely suffering from:
A- Osteoarthritis
B- Rheumatoid arthritis
C- SLE
D- Septic arthritis
Ans: D

Explanation:
- **RA.** Morning stiffness present
- **OA.** Morning stiffness if present less than 30 minutes

129- A 56 year old woman presents with bone pain diffuse demineralization of bone hypercalcemia, anemia, hypergammaglobulinemia, proteinuria and normal serum Alkaline phosphatase the set of findings is most suggestive of
A- hyperparathyroidism
B- Multiple myeloma
C- Paget disease of bone
D- Osteomalacia
Ans: B

130- A 50- year- old female underwent a DEXA scan, which showed a T-score of -2.6 at the hip joint. Her BMI is 14. What should be the next step in management?
A- Vitamin D injection
B- Repeat DEXA scan
C- Calcium supplementation
D- Raloxifene
E- Tamoxifen
Ans: C

131- A Young man presented with history of Limitation in Movements of Hip Joints. On X-Ray, Fusion of Sacro-Iliac Joints & Ankylosis. Which findings will help reach the diagnosis?
A- HLA B-27
B- Rheumatoid Factor
C- ANA positivity
D- ANCA positivity
Ans: A

CamScanner

132- A patient is a diagnosed case of Anterior Uveitis with Hypopyon. What is most common non infective cause of anterior uveitis?
A- Bechet Disease
B- HLA B-27
C- Chlamydia
D- S.Aureus
Ans: B > A

133- A 4-year-old child sustained a knee injury of the Right Leg involving the metaphysis after a fracture from an RTA (road traffic accident). The child has tender swelling, effusion in the knee, and redness over the diaphysis. After knee aspiration, a slab was placed. What is the likely effect of the effusion and swelling in the knee?
A- Increase epiphyseal blood supply
B- Decrease epiphyseal blood supply
C- Prevent reduction
D- Interference with reduction
E- Myositis Ossificans
Ans: B

134- A woman presents with a rash around the eye, bradycardia, and joint pain. Her lab results show positive Anti-SSA and Anti-SSB antibodies. What is the most likely diagnosis?
A- Mixed Connective Tissue Disease
B- Sjögren's Syndrome
C- Scleroderma
D- Systemic Lupus Erythematosus (SLE)
Ans: B

135- A young girl presented with malar rash, polyarthritis swelling in hand sensitive to heat and cold ,what is next most sensitive investigation?
A- CRP level
B- ANA
C- Anti RNP
D- Rheumatoid factor
Ans: B

136- A 20 year old patient present with right tibia Pain on investigation epiphysio metaphysis junction has giant cells and streaks of cells
A- Osteosarcoma
B- Giant cell tumour
C- Osteochondroma
D- Ewing sarcoma
Ans: B
Explanation:
Giant cell tumour=Epiphysis
Osteosarcoma and osteochondroma=Metaphysis
Ewing sarcoma=Diaphysis

137- A female patient, who has recently given birth present with dry skin, dry mouth and decreased secretions. Laboratory results shows Anti-SSA(Ro. and Anti-SSB (La. antibodies these finding are suggestive of which of the following
A- Sjogren's syndrome
B- Rhematoid arthritis
C- Multiple myloma
D- SLE
E- Mixed connective tissue disorder
Ans: A

138- A male patient presents with bilateral knee pain ,accompanied by scaly rashes over the lower limb and trunk, joint aspiration from knee was performed, revealing specific findings based on clinical presentation and diagnostic clues, the most likely diagnosis is
A- SLE
B- Osteoarthritis
C- Gouty arthritis
D- Psoriatic arthritis
E- RA
Ans: D

139- A patient presents with pink circular rash on the limbs and trunk, joint pain, periarticular erosions, Osteophytes and bilateral knee swelling along with morning stiffness as well. Investigations reveal Raised TLC. What is the most likely diagnosis?
A- Psoriatic arthropathy
B- SLE-induced arthritis
C- Rheumatoid arthritis
D- Reactive arthritis
E- Osteoarthritis
Ans: A

140- Hyperextensible Joints due to Defective?
A- Collagen
B- Elastin
C- Protein
D- Fibrillim
Ans: A(Ehlar Danlos Syndrome)

141- A neonate born to a mother with Systemic Lupus Erythematosus (SLE) develops bradycardia due to congenital heart block. Which maternal autoantibody is directed against neonate's heart?
A- Anti-histone
B- Anti-Ro
C- Anti-dsDNA
D- Anti-Smith
E- Anti-La
Ans: B

142- A patient with osteoporosis and osteoclastic activity hormone involved would be:
A- Parafollicular Cells
B- Principal cells of Thyroid
C- Principal cells of PTH
D- TSH
Ans: C

143- Plasma exchange is commonly used in treatment of which of the following condition
A- GBS
B- Mysthenia gravis
C- Multiple sclerosis
D- Parkinson's disease
E- Polio
Ans: A

144- Expansion of Molar teeth. Moth eaten appearnace with chondrocytes
A- Odontogenic Myxoma
B- Chondrosarcoma
C- Chorioma
D- Odynoma
Ans: A

145- 12year old child presents with fever,and joint pain ,on investigation RF was negative but elevated ESR later he gave history of sore throat 3 weeks ago what is your diagnosis?(Medicine Feb 2025)
A- Rheumatic heart disease
B- Rhematoid arthritis
C- Osteoarthritis
D- Septic arthritis
Ans: A

146- A female patient,presents in OPD with dry cough,dry mouth and dry eyes patient also reports fatigue and joint pain on lab findings RA was negative which of the following is most likely diagnosis(Medicine Feb 2025)
A- Sjogren's syndrome
B- Rhematoid arthritis
C- Multiple myloma
D- SLE
E- Mixed connective tissue disorder
Ans: A

147- Which of the following is similarity between RA and SLE (Surgery Feb 2025)
A- Autoimmune disease
B- Caused by viral infection
C- Primarily effects the lungs
D- Can be cured by antibiotics
Ans: A

148- A patient presents with spontaneous pain in the big toe accompanied by a loss of movement in the metatarsophalangeal joint. What investigation should be performed to diagnose the underlying condition?(Gynae & Obs Feb 2025)
A- X-ray of the joint
B- Rheumatoid factor (RA factor)
C- Synovial fluid analysis
D- Serum uric acid levels
E- Serum calcium
Ans: D

149- Glycoprotein Lubricin in joints produced by(Radiology Feb 2025)
A- Synovial A
B- Synovial B
C- Fibroblast
D- Collagen
E- Articular chondrocyte
Ans: B

150- ASO titer raised in?(Radiology Feb 2025)
A- Rheumatic fever
B- Rheumatic heart disease
C- SLE
D- Sjogren Syndrome
Ans: A

151- A man lifted heavy weight few days ago. On examination there is loss of lordosis of spine and pain below the spine. Diagnosis ?(Anesthesia Feb 2025)
A- Lumbar muscle strain
B- Lumbar disc herniation
C- Ankylosing spondylitis
D- Spinal compression fracture
Ans: B

CamScanner

ENDO PATHOLOGY QUICK HINTS

Diabetes Inspidus

Central
- ✓ Decrease ADH

Nephrogenic
- ✓ Normal or Increase ADH that cant act on renal tubules

Findings in both
- ✓ Urine specific gravity < 1.006
- ✓ Urine osmolality < 300 mOsm/kg
- ✓ Serum osmolality > 290 mOsm/kg
- ✓ Hyperosmotic volume contraction

Acromegalay/Gigangitism
- ✓ Excess GH in adult is acromegalay
- ✓ Excess GH in Child is Gigantism
- ✓ Impaired glucose tolerance (insulin resistance)
- ✓ Increase risk of colorectal polyps and cancer
- ✓ Increase Serum IGF-1

SIADH

Increase ADH causeExcessive free water retention which leads to Euvolemic hyponatremia with continued urinary Na+ excretion

Diagnostic criteria
- The patient is clinically euvoleumic (no clinical evidence of oedema or dehydration)
- Plasma sodium (<134mmol/l) and osmolality (280mosmol/kg)
- Urine sodium(>20mmol/l) and osmolality(>100mosmol/kg)
- Normal adrenal , thyroid and renal function)

Hypothyroidism

- ✓ Increase Cholestrol
- ✓ Decrease Free T 3 T 4
- ✓ Increase TSH

Hashimoto thyroiditis
- ✓ Most common cause of hypothyroidism in iodine sufficient regions
- ✓ Antithyroid peroxidase (antimicrosomal) and antithyroglobulin antibodies associated with it
- ✓ Associated withHLA-DR3, HLA-DR5 and increase risk of non Hodgkin lymphoma
- ✓ Hürthle cells and lymphoid aggregates with germinal centers.
- ✓ Non tender thyroid

Postpartum thyroiditis
- ✓ Self-limited thyroiditis arising up to 1 year after delivery
- ✓ Lymphocytic infiltrate with occasional germinal center formation.
- ✓ Painless thyroid

Congenital hypothyroidism(Cretinism)
- ✓ Most common cause is thyroid dysgenesis
- ✓ Findings (6 P's): Pot-bellied, Pale, Puffy-faced child with Protruding umbilicus, Protuberant Tongue , and Poor brain development.

Subacute granulomatous thyroiditis (de Quervain)
- ✓ Self-limited disease often following a flu-like illness (eg, viral infection).
- ✓ Increase ESR, jaw pain, very **tender thyroid** and granulomatous inflammation

Riedel thyroiditis
- ✓ Thyroid replaced by fibrous tissue and inflammatory infiltrate
- ✓ Fibrosis may extend to local structures (eg, trachea, esophagus), mimicking anaplastic carcinoma
- ✓ Fixed, hard (rock-like), painless goiter.

Hyperthyroidism

- ✓ Decrease Cholestrol
- ✓ Increase Free T3 T4
- ✓ Decrease TSH
- ✓

Grave Disease
- ✓ Most common cause of Hyperthyroidsim
- ✓ Diffuse goiter
- ✓ Exopathalmos occur due to thyroid stimulating immunoglobulin

Toxic multunodular goiter
- ✓ Focal patches of hyperfunctioning follicular cells distended with colloid working independently of TSH

Thyroid storm
- ✓ Presents with agitation, delirium, fever, diarrhea, coma, and tachyarrhythmia (cause of death). May see increase LFTs.
- ✓ Treat with the 4 P's: β-blockers (eg, Propranolol), Propylthiouracil, corticosteroids (eg, Prednisolone), Potassium iodide (Lugol iodine)

Goiter

***Nodular**: toxic multinodular goiter, thyroid adenoma, thyroid cancer, thyroid cyst.*

***Smooth/diffuse:** Graves disease, Hashimoto thyroiditis, iodine deficiency, TSH-secreting pituitary adenoma*

Thyroid cancer

Papillary CA
- ✓ Associated with radiation
- ✓ Most common
- ✓ Psomomma bodies and orphan anie eye nucleus
- ✓ Slow growing
- ✓ Spread via lymphatic
- ✓ Best prognosis

Follicular CA
- ✓ Invade Capsule
- ✓ Vascular Spread
- ✓ 2nd Best Prognosis

Medullary CA
- ✓ Release calcitonin + MEN 1 and men 2 associated + Poor prognosis
- ✓ Congo red staining

Anaplastic CA
- ✓ Very poor prognosis + Highly undifferentiated
- ✓ In aged patients

Hypoparathyroidism

Pseudohypoparathyroidism 1A(Maternal)
Physical findings: Albright hereditary osteodystrophy (shortened 4th/5th digits ,short stature, round face, subcutaneous calcifications, developmental delay)
Labs: Increase PTH, Decrease Ca2+, Increase PO4

Pseudopseudohypoparathyroidism(Paternal)
Physical findings: same as Albright hereditary Osteodystrophy
Labs: Normal PTH, Ca2+, PO4

Hyperparathyroidism

Primary
- ✓ Due to parathyroid adenoma and Parathyroid hyperplasia
- ✓ Increase PTH , ALP and urinary CAMP
- ✓ Increase Ca and Decrease Phosphate
- Osteitis fibrosa cystica associated with it

CamScanner

Secondary
- ✓ Hyperplasia due to low Ca
- ✓ Increase PTH and ALP
- ✓ CKD common cause result in decrease Ca and Increase Phosphate
- ✓ Rest causes of Secondary result in Decrease Ca and phosphate

Tertiary
- ✓ Refractory (autonomous) hyperparathyroidism resulting from chronic kidney disease.
- ✓ Increase PTH and Ca

	T4	TSH	TRH
Primary hypothyroidism	↓	↑	↑
Pitutary hypothyroidism (secondary)	↓	Normal or↓	↑
Hypothalmaic hypothyroidism (tertiary)	↓	↓	↓

Diabetes Mellitus

- ✓ Type 1 associated with HLA DR 4 and DR 3

Impaired Glucose Tolerance
- ✓ Fasting - < 7.0mmol/L (< 126mg/dL)
- ✓ 2h **after glucose** - 7.8–11.0mmol/L (140–199mg/dL)

Diabetes
- ✓ Fasting - ≥ 7.0mmol/L (≥ 126mg/dL)
- ✓ 2h **after glucose** - ≥ 11.1mmol/L(≥ 200mg/dL)

Ketones
- ✓ Ketones bodies include – Acetone, Acetoacetate and beta hydroxybutyrate
- ✓ Acetone – Fruity smell
- ✓ Acetoacetate – Detected in urine
- ✓ Acetyl CoA precursor of – Ketone bodies
- ✓ HMG CoA lyase for – Ketone production
- ✓ HMG CoA reductase for – Cholestrol synthesis.

Adrenal Insufficiency

Primary
- ✓ Low Aldosteron and cortisol
- ✓ Hyponatremia volume contraction
- ✓ Hyperkalemia
- ✓ Metabolic acidosis
- ✓ Hyperpigmentation

Acute
- ✓ Waterhouse-Friderichsen syndrome
- ✓ Waterhouse-Friderichsen syndrome common Cause is N. Meningitidis

Chronic
- ✓ Autoimmune(Western) and TB(Developing world)

Secondary
- ✓ Decrease Pituitary ACTH
- ✓ No Hyperpigmentation
- ✓ No Hypokalemia(Due to Preserve RAAS)

Tertiary
- ✓ Seen in patients with chronic exogenoussteroid use, precipitated by abrupt withdrawal
- ✓ Aldosterone synthesis unaffected.

Hyperaldosteronism

Primary(Conn syndrome)
- ✓ Due to Adrenal adenoma and Adrenal hyperplasia
- ✓ Increase Aldosterone so Increase Sodium decrease K and H ions

Secondary
- ✓ Seein in renovascular hypertension, juxtaglomerular cell tumors (renin-producing), and edema (eg, cirrhosis, heart failure, nephrotic syndrome).

Cushing Syndrome/Disease

Cushing Syndrome

Increase Cortisol due to a variety of causes:
- ✓ Exogenous corticosteroids decrease ACTH bilateral adrenal atrophy Most common cause.
- ✓ Primary adrenal adenoma, hyperplasia, or carcinoma decrease ACTH and atrophy of uninvolved adrenal gland.

Cushing disease
- ✓ ACTH-secreting pituitary adenoma (Cushing disease)

Findings
- ✓ Increase 24 urinary cortisol
- ✓ HTN and Hyperglycemia
- ✓ Cushing syndrome differ from obesity by Proximal myopathy >Abdominal striae

Pheochromocytoma

Most common tumor of the adrenal medulla in adults Derived from chromaffin cells (arise from neural crest)

Rule of 10's:
- ✓ 10% malignant
- ✓ 10% bilateral
- ✓ 10% extra-adrenal (eg, bladder wall, organ of Zuckerkandl)
- ✓ 10% calcify
- ✓ 10% kids

Episodic hyperadrenergic symptoms
- ✓ Pressure(Increase BP)
- ✓ Pain (headache)
- ✓ Perspiration
- ✓ Palpitations (tachycardia)
- ✓ Pallor
- ✓ Polycythemia (Due to raise EPO)

FINDINGS
- ✓ Increase catecholamines and metanephrines (eg, homovanillic acid, vanillylmandelic acid) in urine and plasma.
- ✓ Chromogranin, synaptophysin and NSE ⊕.
- ✓ Treated by Alpha blocker followed by beta blocker

Multiple Endocrine neoplasoa(MEN)

MEN 1
- ✓ Pituitary tumors (prolactin or GH)
- ✓ Pancreatic endocrine tumors
- ✓ Parathyroid adenomas

MEN 2A
- ✓ Parathyroid hyperplasia
- ✓ Medullary thyroid carcinoma
- ✓ Pheochromocytoma

MEN 2B
- ✓ Medullary thyroid carcinoma
- ✓ Pheochromocytoma
- ✓ Mucosal neuromas (oral/intestinal ganglioneuromatosis)

CamScanner

Pancreatic Islet Tumor

Insulinoma
- ✓ Tumor of pancreatic β cells leads to overproduction of insulin result *hypoglycemia*
- ✓ Low glucose and increase C peptide

Glucagonoma
- ✓ Tumor of pancreatic α cells leads to overproduction of glucagon.
- ✓ Presents with 6 D's: Dermatitis (necrolytic migratory erythema), Diabetes *(hyperglycemia)*, DVT, Declining weight, **D**epression, **D**iarrhea.

Somatostatinoma
- ✓ Tumor of pancreatic δ cells lead to overproduction of somatostatin decrease secretion of secretin, cholecystokinin, glucagon, insulin, gastrin, gastric inhibitory peptide (GIP).
- ✓ May present with diabetes/glucose intolerance, steatorrhea, gallstones, achlorhydria.

Carcinoid syndrome
- ✓ Carcinoid tumors arise from neuroendocrine cells most commonly in the intestine or lung.
- ✓ Prominent rosettes and chromogranin A ⊕ and synaptophysin ⊕
- ✓ Neuroendocrine cells secrete 5-HT lead to recurrent diarrhea, wheezing, right-sided valvular heart disease (eg, tricuspid regurgitation, pulmonic stenosis), niacin deficiency (pellagra).

Rule of thirds:
- ✓ 1/3 metastasize
- ✓ 1/3 present with 2nd malignancy
- ✓ 1/3 are multiple

Neuroblastoma
- ✓ Most common tumor of the adrenal medulla in children, usually < 4 years old. Originates from Neural crest cells.
- ✓ Neuroblastoma is Normotensive Can also present with opsoclonus-myoclonus syndrome ("dancing eyes-dancing feet").
- ✓ HVA and VMA (catecholamine metabolites) in urine. Homer-Wright rosettes seen
- ✓ Bombesin and NSE ⊕. Associated with amplification of N-myc oncogene

Random

- ✓ **Waterhouse-Friderichsen syndrome**- meningiococimemia with bilateral adrenal hemorhage due to DIC
- ✓ **21-hydroxylase deficiency** - ↑17KS,↓OH,hypotension, lose salt , female pseudohermpehrodite
- ✓ **11-hydroxylase deficiency** - ↑17KS,↓17OH,hypertension,retain salt, female pseudohermaphrodite
- ✓ **17-hydroxylase deficiency** -- ↑17KS,↓17OH,hypertension,retain salt, male pseudohermaphrodite
- ✓ If deficient enzyme starts with 1, it causes hypertension; if deficient enzyme ends with 1, it causes virilization in females.
- ✓ Normal dexamethasone surpression test – ↓ACTH, ↑cortisol , Cortsoil analogue
- ✓ **Zollinger-ellison syndrome**- malignant islet cell tumors secreting gastrin , peptic ulcer
- ✓ **Gigantism**- GH secreting pituitary adenoma before epiphysis have fused
- ✓ **Acromegaly**- GH secreting pituitary adenoma after epiphysis have fused
- ✓ **Sheehan syndrome** – ischemic infarct of pituitary following postpartum bleeding, susceptility to hypoperfusion , induced pituitary growth.usually presents withfaliureto lactate , absent menstruation.
- ✓ **Empty sella** syndrome- atrophy or compression of pituitary, ssociated with idiopathic intracranial hypertension, common in obese
- ✓ **Laron syndrome**- GH insensitivity, Growth failure
- ✓ Pituitary harmone inhibited by - Hyprerglycemia
- ✓ All 3 layers of adrenal cortex secrete – Corticosterone
- ✓ Post adrenalectomy patient dies 4 days after surgery due to deficiency of -Aldosterone
- ✓ Not a feature of GH deficeiencey – Cachexia
- ✓ Gigantism doesnot lead to – Mental retardation
- ✓ Common cause of death in acromegaly – Heart failure
- ✓ Drug of choice in acromegaly- Octerotide
- ✓ A patient presented with increase in calcium phosphate due to – Vitamin D toxicity
- ✓ A girl with polycystic ovarian syndrome will have increased - Insulin
- ✓ Increase plasma calcium associate

- ✓ Anti-Thyroid in 1st Trimester – PTU
- ✓ Anti-Thyroid in 2nd & 3rd Trimester – Methimazole
- ✓ Anti-Thyroid for Thyroid Storm -PTU
- ✓ Crosses Placenta and affect Fetus – Methimazole > PTU
- ✓ Initial test to differentiate b/w simple obesity & cushion Syndrome
- ✓ Increase VMA and catecholamine levels are seen in - Tumors of adrenal medulla
- ✓ Small Cell CA – Smoking + Most aggressive + Ectopic ACTH (Cushing syndrome) + Lambert Eaton syndrome + SIADH.
- ✓ Squamous Cell CA – Smoking (Most commonly)+ Hypercalcemia
- ✓ Ectopic thyroid produce by – Squamous Cell CA of Larynx
- ✓ Most common site of thyroglossal cyst- midline
- ✓ Diabetic retinopathy affects- arterioles
- ✓ Most common cause of Cushing syndrome- Adrenal Adenoma
- ✓ Low level of estrogen with high level of FSH in- Primary hypogonadism
- ✓ Common complication of DM – Dry gangrene
- ✓ Common complication of diabetic foot – Wet gangrene
- ✓ Common limb complication is – Dry gangrene

CamScanner

ENDO PATHOLOGY

1. Girl presented with palpitation & tachycardia with normal Sodium & K+ values:
A- Hypotension
B- Hyperaldosteronism
C- Hyperthyroidism
D- Pheochromocytoma
Ans: C

Explanation:
- As the lab values are normal for sodium & potassium so rest of sign & symptoms points toward hyperthyroidism.

2- Familial medullary carcinoma & history of hypertension:
A- Pheochromocytoma
B- Addison Disease
C- Adrenal Crisis
D- Essential HTN
Ans: A

3- Vitamin D formation decreases in:
A- Acute Renal Failure
B- Chronic Renal Failure
C- Acute Liver Failure
D- Acute metabolic disturbances
Ans: B

4- In hypothyroidism what will increase?
A- T3
B- T4
C- Both T3,T4
D- TSH
Ans: D

Explanation:
- In Hypothyroidism TSH will increase & T3,T4 will decrease
- In Hyperthyroidism TSH will decrease & T3,T4 will increase

5- Old male with weight loss & opacity in right lower lob with increase calcium & decrease phosphate diagnose is
A- Hyperparathyroidism
B- Hypoparathyroidism
C- Thyroid disorder
D- Pituitary disorder
Ans: A

6- Head Injury/Trauma leads to:
A- Central DI
B- Nephrogenic DI
C- Both
D- None
Ans: A

Explanation
Primary polydipsia
- Psychiatric illnesses
- hypothalamic lesions affecting thirst center

Central DI
- Idiopathic tumors (e.g., pituitary)
- infiltrative diseases (e.g., sarcoidosis)
- trauma
- surgery
- hypoxic encephalopathy

Nephrogenic DI
- Hereditary (ADH receptor mutation)
- drugs (e.g., lithium, demeclocycline)
- hypercalcemia
- hypokalemia

6- Radioisotope scan of thyroid indicated in:
A- Cold Nodule
B- Hyperthyroidism
C- Grave's Disease
D- Hodgkins Lymphoma
Ans: A

7- Supraoptic nucleus damaged what will be the result?
A- Increase & Dilute Urine
B- Decrease & Concentrated Urine
C- Decrease urine Formation
D- None
Ans: A

Explanation:
- Damaged to Supraoptic Nucleus will lead to decrease ADH secretion & that in turn will lead to less water absorption so increasing urine amount & making it dilute.

8- A middle aged woman with increased TSH, Low T3 & T4 and having overweight most likely due to
A- Over eating
B- Hypothyroidism
C- Hyperthyroidism
D- Hypopituitarism
Ans: B

Explanation:
- Increase TSH, Low T3 and T4 with overweight is most likely due to hypothyroidism.

9- A 60 years old known diabetic patient for last 20 years presented with rapidly progressive renal failure, most likely cause is
A- Amyloidosis
B- Diffuse glomeruloscelrosis
C- Kimmel stein wilson syndrome
D- UTI
Ans: C

10- A patient with Decrease serum calcium, increase serum phosphate and decrease urinary calcium seen in
A- Hypoparathyroidism
B- Hyperparathyroidism
C- Hypothyroidism
D- Hyperthyroidism
Ans: A

Explanation:
- PTH increases serum calcium and decrease serum phosphate level and when there's hypoparathyroidism serum calcium will decrease & serum phosphate will increase.

11- Which of the following test is best to check the function of thyroid gland
A- TSH
B- T3
C- T4
D- rT3
Ans: A

12- Patient who is known case of Hypothyroidism which of the following will increase in the blood
A- TSH
B- T3
C- T4
D- Cholesterol
Ans: D

Explanation:
- TSH can increase only in primary hypothyroidism but not in other cases while cholesterol is increase in all hypothyroidism cases so we prefer Cholesterol > TSH.

13- Which of the following is laboratory findings in case of hyperthyroidism:
A- Increase TSH
B- Increase T3
C- Increase rT3
D- Decrease T4
Ans: B

Explanation:
- In hyperthyroidism there will be Increase T3, T4 and Decrease TSH
- In hypothyroidism there will be decrease T3,T4 and increase TSH

14- A patient presented with episodic hypertension, headache, diaphoresis & palpitations what could be the possible cause:
A- Pheochromocytoma
B- CRF
C- Adrenal Tumour
D- Renal Cell Carcinoma
Ans: A

Explanation:
- The classic triad of Pheochromocytoma is headache, diaphoresis and palpitations though only 40% individuals present with these symptoms.

15- Most common risk of giving systemic steroids to diabetic patients:
A- Deranged diabetic control
B- Cataract
C- Neuropathy
D- Nephropathy
Ans: A

16- A 16 years old female presented with hypertension & increasing weight. Which of the following features would be most suggestive of cushing's syndrome rather than simple obesity:
A- Abdominal Striae
B- Acanthosis Nigricans
C- Buffalo Hump
D- Moon Face
Ans: A(Prefer Proximal myopathy)

17- Difference between dwarfism & cretinism, as the later has:
A- Less mental backwardness
B- Severe mental backwardness
C- More short stature
D- Less short stature
Ans: B

18- A patient with primary hyperthyroidism disease would most likely have decrease of which of the following?
A- TSH
B- T3
C- T4
D- rT3
Ans: A(FA)

19- A patient with striae, weight gain, acne, and excessive facial hair has high ACTH. What is the cause?
A- Primary increased ACTH production
B- Exogenous steroids
C- Thyroid problem
D- Decreased ACTH
Ans: A

20- Vitamin D resistant Rickets causes which of the following:
A- Hyperparathyroidism
B- Malabsorption syndrome
C- Fanconi syndrome
D- Megaloblastic Anemia
Ans: C(FA)

21- Investigation for Hashimotos thyroiditis include
A- Anti thyroglobulin & anti TPO
B- Anti T3
C- TFTs
D- Anti Thyroglobin
Ans: A(FA+Pathoma)

CamScanner

Explanation:
- Anti microsomal and anti thyroglobulin antibodies destroy parenchyma and are present in hashimotos.

22- A man with moon face and skin pigmentation alongside a buffalo hump includes:
A- Increase FSH
B- Increase MSH
C- Increase LH
D- Increase ACTH
Ans: D

23- A patient with osteoporosis and osteoclastic activity, hormone involved would be:
A- Calcitonin
B- Chalciferol
C- PTH
D- TSH
Ans: C

24- An 18y Male is brought to the hospital in an altered sensorium. He is taking slow, shallow breaths and His breath has a fruity smell. An ABG: pH=7.20, urine ketones +ve. What is the most probable dx?
A- HONK
B- DKA
C- Septic Shock
D- MI
Ans: B

25- A 45-year-old female presents with bone pain and parasthesia in the lower limbs. Her laboratory investigations were done and it showed Serum Calcium level: 2.60 mmol/L (2.10-2.65 mmol/L Normal), inorganic phosphates: 0.9mmol/L (0.8-1.9 mmol/L is Normal). ALP 385 IU/L (Normal: 120-365 IU/L) and the serum PTH levels were border-line raised; 6.1 mmol/L (Normal: 1.5-6.0). What is the most likely diagnosis?
A- Primary hyperparathyroidism
B- Pseudo hyperparathyroidism
C- Secondary hyperparathyroidism
D- Tertiary hyperparathyroidism
E- CRF
Ans: A (Golijan)
Explanation:
Ca and PTH in upper normal limit and phosphate in lower normal limit indicate early primary hyperparathyroidism.

26- Graves ophthalmopathy true is:
A- Optic nerve compression
B- Unilaterall involvement
C- Medial & lateral rectus muscle involved
D- Affects orbicularis muscle
Ans: A(Prefer Bilateral)

27- In diabetic patient common limb complication is?
A- Necrosis
B- Dry gangrene
C- Wet gangrene
D- Apoptosis
E- Infarction
Ans: B
Explanation:
- Common complication of DM – Dry gangrene
- Common complication of diabetic foot – Wet gangrene
- Common limb complication is – Dry gangrene

28- A 40 year old female with no respiratory or cardiac problems, has swelling in front of the neck and feels difficulty with breathing while in supine position; this is due to:
A- Asthma
B- Colloid goiter
C- Follicular carcinoma of goiter
D- Retrosternal goiter
Ans: D

29- Diabetic foot with ulceration and loss of sensation. The mechanism involved is
A- Vasculopathy
B- Neuropathy
C- Nephropathy followed by Vasculopathy
D- Vasculopathy followed by neuropathy
Ans: D

30- Supporting cells of pars nervosa:
A- Stores in nerve endings
B- Pitucityes
C- Astrocytes
D- Glial cells
Ans: B

31- A woman has hirsutism, hyperglycemia, and obesity, muscle wasting and increased circulating levels of adrenocorticotropic hormone. The most likely cause of her symptoms is
A- Primary adrenocortical deficiency
B- Pheochromocytoma
C- Cushing Disease
D- Treatment with exogenous glucocorticoids
E- Hypophysectomy
Ans: C

32- Child with frontal bossing, bowed legs and locked knees. It is seen in:
A- Vitamin D deficiency
B- Vitamin B deficiency
C- Vitamin C deficiency
D- Vitamin A deficiency
Ans: A

33- Defect in anterior pituitary is indicated by:
A- No menses
B- Uterine atrophy
C- Congenital adrenal hyperplasia
D- Hisutism
Ans: A

34- A 6 year old girl presented in medical emergency in Unconscious state.She had a history of diarrhoea 3 days ago.Her breath was fruity and serum glucose was 456mg/dl. What is Diagnosis?
HONK
A- Diabetes Mellitus
B- Diabetic Keto-acidosis
C- Renal Failure
D- Parasitic Infection
E-
Ans: C

35- A female is worried about a lump in her breast. She also has family history of Ca breast. What is main risk factor in her?
A- BRCA-1
B- Smoking
C- HNPPC
D- CA-125
Ans: A

36- Which of the following is not characteristic of hypopituitarism?
A- Cachexia
B- Infertility
C- Pallor
D- Low BMR
Ans: A

37- In 15 year old boy medullary carcinoma of thyroid is considered familial because of:
A- Age
B- Solitary
C- Metastasis
D- Increase secretion of hormone
Ans: A

38- Diabetic person with sensory abnormalities of foot developed ulcer of foot due to
A- Microangipathy
B- Angiopathy and neuropathy
C- Thrombosis
D- Atherosclerosis
Ans: B

39- Diabetic type 2 patient with increase urinary frequency, cause of urination?
A- Decrease reabsorption of glucose
B- Decrease reabsorption of water
C- Fixed specific gravity of urine
D- Decrease sensitivity of ADH on aquaporin
Ans: A

40- Most common cause of Fetal hypothyroidism:
A- Fetal Thyroid Dysgenesis
B- Maternal Hypothyroidism
C- Maternal IgG Crossing Placenta
D- Maternal Iodine Deficiency
Ans: A

41- Woman presented with headache, palpitations, hypertension and hyperglycemia. Examination ruled out DM. What can be the cause?
A- Insulin deficiency
B- ADH
C- Prolactin
D- Catecholamines
Ans: D

42- A Male having hypercalcemia, hyperparathyroidism and gastric ulcers related to
A- MEN1
B- Primary hyperparathyroidism
C- Zollinger Ellison Syndrome
D- Addison's Disease
Ans: A

43- Hypercalcemia is seen in malignancy which of following will be involved?
A- PThrp
B- Calcitonin
C- Calcitonin like peptide
D- ACTH
Ans: A

44- Diabetic patient came to ER insulin given what change will happen in blood?
A- Increased K in blood
B- Increased ketogenesis
C- Increased PH
D- Decrease PH
Ans: C

45- Pheochromocytoma has the following features except:
A- It is generally a benign tumour of adrenal medulla
B- Hypertension is generally presenting feature
C- It arises from embryonal nerve cells
D- 24-hour urinary measurement of catecholamine's is diagnostic
Ans: C

46- Onset of puberty is due to:
A- Increased estrogen receptor on ovary
B- Increased sensitivity of hypothalamus to estrogen
C- Pulsatile GNRH from pituitary
D- Increased progesterone
Ans: C

CamScanner

47- Patient c/o tingling sensation post thyroidectomy due to thyroid cancer which of following is likely cause
A- Cretinism
B- Myxedema
C- Tetany
D- High PTH
Ans: C

48- A man of 35 years presents with large hands and feet, large protruding lower jaw and big nose. He also complains of partial loss of field of vision. His fasting blood glucose is 150mg/dl. His height is 5'-8''. His cortisol, ACTH and thyroid hormones levels are normal. He is most likely suffering from:
A- Cushing's syndrome
B- Diabetes mellitus
C- Acromegaly
D- Gigantism
E- Myxedema
Ans: C

49- Testosterone lowest in:
A- Fetus
B- Infancy
C- Puberty
D- Old age
E- Preschool
Ans: E

50- 27 years old woman presented with the complaints of weight gain, amenorrhoea and fatigue. Last year, she experienced a complicated delivery requiring a 2units of blood transfusion. She was unable to breastfeed. On examination she has dry skin and hypotension. Which one of the following is the most likely diagnosis?
A- Conn disease
B- Sheehan syndrome
C- Addison syndrome
D- Nelson syndrome
Ans: B

51- Ca and Po4 balance maintained by:
A- PTH
B- Calcitonin
C- Aldosterone
D- Angiotensin 2
Ans: A

52- Damage to adenohypophysis will lead to:
A- Zona glomerulusa effected
B- Zona fasciculata effected
C- Zona reticularis effected
D- None of the above
Ans: B

53- Patient presenting with complaint of increase heart rate, intolerance to heat and rapid weight loss within a short duration of time. After delayed investigation patient was diagnosed to have hyperthyroidism, which of the following will determine the diagnosis:
A- High T3
B- High T4
C- Low TSH
D- Low Thyroxin
Ans: C

54- Calcitonin is released by tumor of which organ:
A- Parathyroid
B- Adrenal
C- Thyroid
D- HCC
Ans: C

55- Which of the following organ increases in size in CRF?
A- Parathyroid gland
B- Thyroid gland
C- Spleen
D- Liver
Ans: A

56- Patient presented with hypertension and hypokalaemia, cortisol and VMA normal, renin is decreased,aldosterone high. Patient is suffering from:
A- Cushing syndrome
B- Cushing disease
C- Conns syndrome
D- Addison's disease
Ans: C(Davidson +FA)

Explanation
Primary hyperaldosteronism (Conn syndrome)
- Hypokalemia
- Hypertension
- Inc aldosterone
- Dec renin

Secondary hyperaldosteronism
- Inc aldosterone
- Inc renin

Primary Adrenal insufficiency (Addison's Disease)
- Hypotension
- Hyperkalemia
- Increase pigmentation of skin

Cushing Disease
- Hypokalemia
- Central obesity with extremities wasting
- Moon faces
- Buffalo hump
- Spontaneous bruising
- Skin striae
- Proximal myopathy

57- 70-year-old women fallen from bed and femur was fractured, radiograph shows signs of osteoporosis. What is the probable cause?
Diminished Blood Supply
A- Decrease endocrine Activity
B- Disuse Atrophy
C- Decrease Nutrition
D-
Ans: B

58- Adrenocortical insufficiency with increase urine sodium due to
Unable to reabsorb from tubules
A- Problem in glomeruli
B- Pump failure
C- Increase sodium excretion because of raised
D- GFR.
Ans: A

59- A lady presented with agalactorrhea, amenorrhea indication high levels of prolactin. Which of the following structure is affected?
A- Pituitary gland
B- Hypothalamus
C- Thyroid gland
D- Adrenal gland
E- Neurohypophysis
Ans: A

Explanation:
- Prolactin is secreted by anterior pituitary gland under the influence of TRH from hypothalamus.
- Prolactinoma is the tumor of anterior pituitary gland that secretes excessive prolactin producing its effects as agalactorrhea, amenorrhea and loss of libido.

60- A lady with history of mild sore throat infection died. Autopsy report shows bilateral adrenal gland enlargement and cortical hemorrhage. Most likely organism involved was:
A- N. Meningitis
B- CMV
C- Mycobacterium tuberculosis
D- Histoplasma
E- S. Pneumoniae
Ans: A

61- Patient with decreased neutrophil, increased lymphocytes and increased eosinophils, increased ACTH likely diagnoses:
A- Cushing syndromes
B- Cushing disease
C- Ectopic ACTH
D- Leukemia
E- Addison's Disease
Ans: E

Explanation:
Addison Disease
- Low Neutrophil
- Increase lymphocyte
- Increase Eosinophil

Cushing Syndrome
Increase Cortisol cause
- Increase Neutrophil
- Decrease Lymphocyte
- Decrease Eosinophil

62- Slow growing thyroid tumor:
A- Papillary
B- Folicular
C- Medullary
D- Anaplastic
Ans: A(FA)

Explanation
Papillary carcinoma
- Slow growing
- Most common
- Previous irradiation
- Psammoma bodies
- Orphan eye nucleus
- Excellent prognosis

Medullary Carcinoma
- C cells
- Calcitonin Production
- Congo Red staining
- Associated with MEN 2A, 2B

Anaplastic Carcinoma
- Very poor prognosis
- In old age
- Invades local structure

Follicular Carcinoma
- Uniform follicles
- Hematogenous spread
- Invades capsule

63- A tall young girl (child) with history of secretion from breast on microscopy of anterior pituitary which cells are abundant?
A- Eosinophilic
B- Basophilic
C- Chromophobes
D- Pituticytes
Ans: A

64- After adrenalectomy patient's desire of which of the following increases:
A- Glucose
B- NaCl
C- Calcium
D- Lead
Ans: B

65- Female swelling infront of neck. Hypothyroid Dr orders some immunological test. What is the diagnosis?
A- Hashimoto thyroidits
B- Lymphoma
C- Subacute granulomatous thyroiditis
D- Riedel thyroiditis
Ans: A

CamScanner

66- Lady with loss of blood about 1500ml, after few weeks her serum ACTH level was low and later it was found that her adrenal gland size was reduced to 2 g (normal size 4-5) what is the cause?
A- Atrophy of medulla
B- Atrophy of cortex
C- Exogenous steroid
D- Hypertrophy of medulla
Ans: B

67- 30 years old patent weigh 70 kg presents with blood pressure 140/90 mmHg, pulse 80 bpm, glucose 88%, urine glucose ++, Na 140 mmol/dl and K 2.4 mmol/dl, diagnosis:
A- Primary hyperaldosteronism
B- Secondary hyperaldosteroinism
C- Addison's disease
D- Cushing disease
E- Cushing Syndrome
Ans: A

68- A 4-year-old boy came with fracture of arm. His test reveals Ca 2+: 6.8 mg/dl, urinary Ca was50, when BP cuff was applied he developed tetany, diagnosis??
A- Rickets
B- Primary hypoparathyroidism
C- Secondary hyperparathyroidism
D- Tertiary hypoparathyroidism
Ans: C

69- Myxedema is caused by:
A- Total lack of thyroid hormone
B- Partial lack of thyroid hormone
C- Lack of hypothalamic pituitary
D- ADH
Ans: A (Guyton)

70- Diabetic gangrene due to
A- Atheromas in arteries
B- Always start as moist necrosis
C- A/V fistula develop
D- Large arteries are always responsible
Ans: A

71- T4 in the blood Mostly binds with which plasma protein?
A- TBG
B- Thyroglobulin
C- T3
D- T4
Ans: A

72- Patient had hypocalcaemia and hyperphosphatemia, injection of PTH increased camp in kidney, cause is
A- Pseudo hypoparathyroidism
B- Hyperparathyroidism after surgery
C- Vit - D intoxication
D- Vit - D deficiency
Ans: A

73- 60 year male with fracture on X-ray osteoporosis is diagnosed, cause of osteoporosis in 60 years of age:
A- Nutritional deficiency
B- Endocrinological disturbance/ hormonal insufficiency
C- Disuse atrophy
D- Diminished blood supply
Ans: B

74- Low level of estrogen with high level of FSH cause is
A- Primary hypogonadism
B- Secondary hypogonadism
C- Tertiary hypogonadism
D- None
Ans: A

75- A patient has muscle tetanic contraction on 1st post-op day of thyroidectomy. This is due to:
A- Calcium excess
B- Hyperparathyroidism
C- Hypothyroidism
D- Hypocalcemic Tetany
Ans: D

76- Patient presented with Macroglossia, hyperglycemia, HTN which one is raised?
A- Corticotropes
B- Somatotroph
C- Prolactin
D- TRH
E- TSH
Ans: B

77- Patient had head injury, after that her urine osmolarity is 70 and plasma osmolarity is 302, after giving vassopressin, urine osmolarity increase and plasma osmolarity decrease:
A- Central DI
B- Nephrogenic DI
C- SIADH
D- Water deprivation
Ans: A

78- In nephrogenic diabetes, what will occur?
A- Urine osmolarity increase
B- ECF osmolarity increase
C- ECF volume increase
D- ECF osmolarity decrease
Ans: B

79- A known diabetic patient having poor control of blood sugar now develop edema due to:
A- High salt
B- Low albumin
C- Low BSR
D- High oncotic pressure
Ans: B

Investigation for Hashimotos thyroiditis is
A- Anti thyroglobulin & anti microsomal
B- Anti T3
C- TFTs
D- Anti Thyroglobin
E- Anti RNA
Ans: A(FA)

81- The cause of increase ketone bodies in diabetic is due to:
A- Insulin deficiency
B- TSH deficiency
C- High T3 and T4
D- Glucose deficiency
E- Glucagon deficiency
Ans: A
Explanation:
Normal Functions
- Anti Ketotic – Insulin
- Ketogenic – Glucagon

82- Addisons disease patient present in which emergency condition?
A- Hypertension
B- Coma
C- Hypokalemia
D- Hypernatremia
Ans: B (Addisonian crisis)

83- Antibodies are produced in exophthalmos which is due to?
A- TSI
B- Increase T3, T4
C- Increase T3
D- Increase bound form of T3, T4
Ans: A

84- Supraoptic nucleus lesion with loss of ADH will lead to:
A- High urine osmolarity
B- More loss of water in urine and low osmolarity
C- Less loss of water in urine
D- Concentrated urine
E- No effect on urine
Ans: B

85- Most common cause of Cushing syndrome?
A- Adrenal Adenoma
B- Thyroid Adenoma
C- Hepatic Adenoma
D- Renal Adenoma
E- Splenic Adenoma
Ans: A

86- In diabetes insipidus the correct parameter would be:
A- Decrease plasma osmolality
B- No change in osmolality of urine
C- Decreased urine osmolality
D- Increase urine osmolality
E- Decrease Reabsorption from PCT
Ans: C

87- Diabetic retinopathy affects which of the Following:
A- Veins
B- Arteriole
C- Venules
D- Arteries
E- Capillaries
Ans: B

88- Very poor prognosis shows by which Carcinoma
A- Follicular CA
B- Medullary
C- Papillary
D- Anaplastic
E- Goiter
Ans: D

89- A Patient presented with history of head trauma his urine osmolarity was decreased and develops symptoms of polydipsia and polyuria ADH analogue given which increase urine osmolarity cause is:
A- Nephrogenic diabetes insipidus
B- Central diabetes insipidus
C- SIADH
D- Psychogenic polydyspia
E- Water Deprivation
Ans: B

90- A young thin lean boy with sign of tetany having blood Ca Level 6 (normal 8-9) and urine Excretion level is 50 (normal 24-300) What will be the cause?
A- Vitamin D deficiency
B- Primary hypoparathyriodism
C- CRF
D- Hyperparathyroidism
Ans: A

91- A patient with cold intolerance increase cholesterol TFTs shows increase TSH decrease t3 t4 upon giving TRH there was exaggerated elevation in TSH diagnose is:
A- Hypothyroidism due to primary abnormality in thyroid
B- Hypothyroidism due to abnormality in pituitary
C- Hyperthyroidism due to abnormality in thyroid
D- Hypothyroidism due to primary abnormality in hypothalamus
E- Hyperthyroidism due to abnormality in hypothalamus
Ans: A
Explanation:
- TSH low increase on giving TRH – Hypothalamus problem
- TSH high and Raised on giving TRH – Thyroid Problem

92- PTH level does not change in:
A- Pseudohypoparathyroidism
B- Osteoporosis
C- Hyepervitaminosis D
D- Hyperoarathyroidism
Ans: B

Explanation
In osteoporosis
- Bone pain
- Normal calcium
- Normal phosphate
- Normal ALP

In osteomalacia
- Bone pain
- Low calcium
- Low phosphate
- High ALP

Paget's disease
- Bone pain
- Normal calcium
- Normal phosphate
- High ALP

93- A patient presented with episodic hypertension, headache, diaphoresis & palpitations and diagnosed as pheochromocytoma which will be less in the blood on lab report:
A- Pyrovate
B- Lactate
C- Fasting glucose
D- Insulin
E- Fatty acid
Ans: D

Explanation:
- In pheochromocytoma Catecholamine increase which act on Alpha 2 receptor thus decrease insulin and cause increase glucose.

94- A man having joint pain and renal stones with high level of calcium, high PTH, normal PTHrp, low phosphate and micro hematuria this is related to which of following?
A- Pseudohypoparathyroidism
B- Primary hyperparathyroidism
C- Secondary hyperparathyroidism
D- Vitamin D deficiency
E- Myeloma
Ans: B

95- Patient is having Palpitation and episodic headache and diagnosed with pheochromocytoma on investigation epinephrine metabolites are increased. Epinephrine influences carbohydrate metabolism by which mechanism?
A- Increased glycolysis
B- Increased gluconeogenesis
C- Increased glycogenolysis
D- Decrease glycogenolysis
E- Decrease glycolysis
Ans: C

96- Most common site of thyroglossal cyst:
A- Suprahyoid
B- Midline
C- Anterior triangle
D- Posterior triangle
Ans: B

97- Hypocalcemic patient is developing tetany what can be the life threatning complication that can happen:
A- Osteoprosis
B- Osteopenia
C- Laryngeal Spasm
D- Hypotension
Ans: C

98- Hypophysectomy done which cells will be effected?
A- Principle cells of thyroid
B- Chief cells of parathyroid
C- Principal cell of parathyroid
D- Cells of Adrenal Medulla
E- Beta Cells of Pancreas
Ans: A

99- 45-year-old woman having weight loss with Increase T3 T4 Decrease TSH most likely diagnose is:
A- Primary Hypothyroidism
B- Primary Hyperthyroidism
C- Secondary Hyperthyroidism
D- Tertiary Hyperthyroidism
E- Primary Hyperparathyroidism
Ans: B

100- A female presented with intense feeling of heat (hyperthermia) and her eyes were bulging outside (exophthalmos) and diagnose of Grave Disease made which of following associated with this condition?
A- Decrease HR
B- Cold intolerance
C- Increase O_2 Consumption
D- Increase TSH
E- Increase tri iodide
Ans: C(FA)

101- Patient having CNS symptoms, high insulin, high C peptide, low glucose, what is the cause?
A- Menigioma
B- DM
C- Trauma
D- Stress
E- Insulinoma
Ans: E(FA)

102- Woman having presented with protruding jaw, swollen hands and feet, headache it is due to which of following adenoma?
Adenoma of acidophilic cells
A- Adenoma of chromophobe cells
B- Adenoma of adenohypophysis
C- Adenoma of posterior pituitary
D- Adenoma of basophils
E- A
Ans: A

103- A patient having HbA1c 6.8 FBS 141 . What is Interpretation
A- Diabetes
B- Prediabetes
C- HONK
D- DKA
Ans: A(Davidson)

Explanation:
Impaired Glucose Tolerance
- **Fasting** - < 7.0mmol/L (< 126mg/dL)
- **2h after glucose** - 7.8–11.0mmol/L (140–199mg/dL)

Diabetes
- **Fasting** - ≥ 7.0mmol/L (≥ 126mg/dL)
- **2h after glucose** - ≥ 11.1mmol/L (≥ 200mg/dL)

104- 16-year-old with 15 year history of diabetes how to check long term glycemic control?
A- Fasting blood sugar
B- Glycosylated hemoglobin
C- Insulin level
D- Glucagon level
Ans: B

105- A lady with hirsuitism, hyperglycemia, HTN and increase ACTH what is the diagnosis?
A- Conns syndrome
B- Cushing disease
C- Hyperaldosteroniim
D- Cushing syndrome
Ans: B

106- Follicular carcinoma characteristic feature.
A- Encapsulated
B- Invades Capsule
C- Invades capillaries
D- Invades Arteries
Ans: B

Explanation (characteristics)
- Uniform follicles
- Hematogenous spread
- Invades capsule

107- A patient with HTN and on labs investigation VMA found in urine cause is:
A- Pheochromocytoma
B- CKD
C- Adrenal adenoma
D- Renal artery stenosis
Ans: A

Explanation:
- ↑ catecholamines and metanephrines (e.g., homovanillic acid, vanillylmandelic acid) in urine and plasma.

108- In diabetic patient acidosis is due to:
A- Decrease H
B- Decrease K
C- Decrease Bicarbonate
D- Decrease CO_2
Ans: C

109- Gigantism is associated with:
A- Disproportionate growth of tissue
B- Hyperkalemia
C- Hypocalcaemia
D- Hypophosphatemia
Ans: A

110- A DM patient with metabolic acidosis what will be seen?
A- Decrease PH
B- Increase PH
C- Increase HCO_3
D- Increase CO2
Ans: A

111- A person with skin pigmentation and central obesity came in follow up for evaluation he has acth level report that shows in decline pattern after dexamethasone test what's cause?
A- Cushing syndrome
B- Cushing disease
C- Exogenous steroid use
D- Ectopic steroid production
Ans: B

112- A young female is complaining of weight loss for the last five months, she is also suffering from menorrhagia, blood profile shows low levels of TSH, inc calcium and decrease phosphate likely diagnosis:
A- Primary hypothyroidism
B- Secondary hypothyroidism
C- Primary hyperthyroidism
D- Secondary hyperthyroidism
Ans: C

113- Diagnostic test for pheochromocytoma:
A- Increase cortisol
B- Dexamethasone suppression test
C- VMA in urine
D- Urine dipstick test
Ans: C

CamScanner

114- A female present with a lump in the Midline of neck, hoarseness of voice, Dysphagia, and having diarrhea, calcitonin raised diagnosis:
A- Papillary thyroid carcinoma
B- Medullary thyroid carcinoma
C- Follicular thyroid cancer
D- Hurtle cell cancer
Ans: B

115- Eyelid pathology involved in thyroid cancer is
A- Graves disease
B- Mysthenia gravis
C- Multinodular goiter
D- Papillary thyroid carcinoma
Ans: A

116- The most common carcinoma of thyroid is?
A- Medullary carcinoma
B- Papillary thyroid carcinoma
C- Follivular carcinoma
D- Transitional cell carcinoma
Ans: B

Explanation (characterestics)
- Slow growing
- Most common
- Previous irradiation
- Psammoma bodies
- Orphan eye nucleus
- Excellent prognosis

117- Pattern in tertiary hyperparathyroidism is
A- Decrease calcium and increaseparatharmnone
B- Both calcium and paratharmnone decreases
C- Both calcium and paratharmnone increases
D- Calcium increase and paratharmnone decrease
Ans: C

118- Patient comes to you with the complain of fatigue, joint pain, and nephrolithiasis diagnosed as a case of hyperparathyroidism on investigations what will you see?
A- Decrease serum calcium
B- Increase serum calcium and urinary phosphate
C- Decrease urinary phosphate
D- Increase serum phosphate
Ans: B

In case of hyperparathyroidism
There is increase of following:
- serum calcium
- urinary phosphate excretion
- urinary calcium excretion
- increase cyclic AMP
- increase bone resorption

119- Increase VMA and catecholamine levels are seen in:
A- Tumors of adrenal medulla
B- Tumors of renal parenchyma
C- Tumors of adrenal cortex
D- Pituitary adenomas
Ans: A

120- Histopathological slide made after right lobectomy and isthmusectomy for a solitary thyroid nodule, shows cell balls and amyloid deposits and foci of C cell hyperplasia most likely diagnosis is:
A- Anaplastic carcinoma
B- Follicular carcinoma
C- Lymphoma
D- Medullary carcinoma
E- Papillary carcinoma
Ans: D

121- One boy fell on grounds got fracture of arm tetany on checking bp Decrease serum calcium and normal urine calcium most likely cause:
A- Vit. D deficiency
B- Primary hyperparathyroidism
C- Secondary hyperparathyroidism
D- Hypoparathyroidism
Ans: A

122- A patient swelling in neck, bilateral exophthalmos and antithyroid antibodies present likely due to:
A- Graves' disease
B- Hashimoto's
C- Goiter
D- Thyrotoxicosis
Ans: A

123- Thyroidectomy performed after 10 days Patient presents with:
A- Low calcium and exaggerated muscle activity
B- High PO_4 and low Ca and tetany
C- Decrease parathyroid
D- Low Phosphate
Ans: B

124- Young women with puffy skin hoarseness of voice. her plasma TSH conc low. Inc. markedly when given TRH she probably has:
A- Hypothyroidism due to primary abnormality in thyroid
B- Hypothyroidism due to abnormality in pituatry
C- Hyperthyroidism due to abnormality in thyroid
D- Hypothyroidism due to primary abnormality in hypothalamus
E- Hyperthyroidism due to abnormality in hypothalamus
Ans: D

Explanation:
- TSH low increase on giving TRH – Hypothalamus problem
- TSH high and Raised on giving TRH – Thyroid Problem

Peripheral neuropathy secondary to diabetes, what is defective?
Perineurium
Endothelial cells
Epineurium
Endoneurium
B

Pituitary Tumors Associated with
MEN 1
MEN 2A
MEN 2B
MEN 2C
A

Explanation:
MEN 1
- Pituitary tumors (prolactin or GH)
- Pancreatic endocrine tumors—Zollinger
- Ellison syndrome
- Insulinomas
- VIPoma's
- glucagonomas (rare)
- Parathyroid adenomas

MEN 2A
- Parathyroid hyperplasia
- Medullary thyroid carcinoma
- Pheochromocytoma

MEN 2B
- Medullary thyroid carcinoma
- Pheochromocytoma
- Mucosal neuromas (oral/intestinal ganglioneuromatosis)

Prolactin induced hyperprolactinoma occur due to:
Increase dopamine
Decrease dopamine from hypothalamus
Increase Cortisol
Decrease Thyroxin
B (BRS)

Explanation:
- Dopamine is prolactin inhibitory factor if dopamine is decreased then prolactin will increase

A 16-year-old female presents with hypertension and increasing weight. Which of the following features would be most suggestive of Cushing's syndrome rather than simple obesity?
Hypoglycemia
Hypocalcemia
Hypergylcemua
Pot belly
Amenorrhea
C

129- A young man presented to you with the problem of no erection and gyneocomastia due to increase of which hormones
A- Gonadotrophic releasing harmone
B- Corticotrophic releasing harmone
C- TRH
D- Prolactin
E- ACTH
Ans: D

130- A 25 years old female complains of galactorrhea and secondary amenorrhea, her serum prolactin is 6000 with no other signs of compression what is likely diagnosis
A- Microprolactinoma
B- Pituitary adenoma
C- Macroprolactinoma
D- Craniopharymgioma
Ans: C

Explanation:
- <1000 – Stress or Drugs
- Between 1000 – 5000 – microprolactinoma
- >5000 – macroprolactinom
- Prolactin cause – Milk production
- High prolactin cause – Infertility and glactorrhea
- High prolactin cause – Decrease GnRH so inhibit ovulation

131- A patient having Thymoma with bilateral ptosis and proximal muscle weakness what test will help in diagnose?
A- Acetylcholine number
B- Acetylcholine receptor antibodies
C- Anti calcium channel antibodies
D- Anti Sodium channel antibodies
Ans: B

Explanation:
- Myasthenia gravis – Antibodies' against postsynaptic voltage gated cannels cause damage to Acetylcholine Receptor
- Diagnostic test – ACH receptor antibodies
- Most accurate/confirmatory/gold standard – EMG
- Initial drug for Myasthenia gravis – Neostigmine
- DOC For maintained therapy – Pyridostigmine.
- Physostigmine – Crosses BBB immediately and increase acetylcholine.

132- Female on steroid for 7 years came for tooth extraction. First to treat
A- Buffalo hump
B- Moon face
C- Hirtutism
D- Hyperglycemia
E- Mood changes
Ans: D

CamScanner

133- Propylthiouracil is the drug of choice in?
A- Graves disease with liver dysfunction
B- Graves disease with sle
C- Graves disease
D- Multinodular goitor
E- Graves disease in pregnancy
Ans: E (Davidson)

134- Pregnant female came in 5th month of pregnancy with thyrotoxicosis which drug should be given?
A- PTU
B- Methimazole
C- Beta blocker
D- Iodine
E- Thyroxine
Ans: B

Explanation:
- Anti-Thyroid in 1st Trimester – PTU
- Anti-Thyroid in 2nd & 3rd Trimester – Methimazole
- Anti-Thyroid for Thyroid Storm -PTU
- Crosses Placenta and affect Fetus – Methimazole > PTU

135- Medullary CA of thyroid spreads through?
A- Direct seeding
B- Blood
C- Lymph
D- Capsular
E- Arteriol
Ans: C

136- Follicular CA feature is
A- Vascular invasion
B- Psammoma bodies
C- Lymphatic invasion
D- Lymphatic Spread
Ans: A

137- Initial test to differentiate b/w simple obesity & cushion Syndrome??
A- Aldosterone test
B- 24 hours urinary cortisol
C- ACTH
D- Dexamethasone suppression test
Ans: B

138- Patient present with Anorexia, weight loss, abdominal pain, Sodium 130 Potassium 5.4 and Pigmentation most suitable diagnose is
A- Anorexia nervosa
B- Addison disease
C- Conn's syndrome
D- Cushing syndrome
Ans: B

139- In PCOS what causes increase in androgens?
A- Sertoli cells
B- Inhibin
C- LH
D- FSH
E- HCG
Ans: C

Explanation:
- LH and insulin mainly cause increase Androgen in PCOS

140- Increase plasma calcium associated with?
A- Increase 25 dihydroxycholecalciferol
B- Increase PTH
C- Decrease PTH
D- Increase Phosphate
Ans: B

141- 68 years old women with poor dietary habits and sedentary life style having fracture of femur neck most suitable cause is:
A- Post menopausal Estrogen deficiency
B- Decrease vitamins
C- Sedentary life
D- Rest
E- Malnutrition
Ans: A

142- A girl with polycystic ovarian syndrome will have increased?
A- Insulin
B- Glucose
C- ACTH
D- Growth hormones
E- TSH
Ans: A

143- A patient present with HTN , Palpitation and Headache what will be the findings
A- Increase cortisol
B- Increase Glucogon
C- VMA in urine
D- Increase Proteins
Ans: C

144- A patient presented with increase in calcium phosphate due to which of the following?
A- Milk alkali syndrome
B- Vitamin D toxicity
C- Vitamin A toxicity
D- RTA
Ans: B

145- Patient has developed multinodular goiter this is due to:
A- Free t3 t4
B- Low t3 t4
C- Fluctuating TSH
D- Fluctuating LATS
E- High T4
Ans: C

In clinical setting 50males with increase BP what to check:
Ambulatory 24hr bp
TSH
Metanephrine
Cortisol
Ans: C

Female patient presented with increased menstrual bleeding. Imaging shows endometrial hyperplasia. It is more likely due to excess of which hormone.
Estrogen
Progestrone
LH
FSH
Ans: A

Feature of primary adrenal insufficiency is:
Hyperkalemia
Hypokalemia
Hypertension
Hyponatremia
Hypercalcemia
Ans: A

Explanation
Primary Adrenal insufficiency (Addison's disease)
Hypotension
Hyperkalemia
Increase pigmentation of skin

Patient present with history of schizophrenia came with high prolactin >1000 what is cause of its increase prolactin?
Microprolactinoma
Macroprolactinoma
Due to phenothiazine drug
Stress
Ans: A

Explanation:
<1000 -- Stress or Drugs
Between 1000 – 5000 -- Microprolactinoma
>5000 – Macroprolactinoma

A diabetic patient with type 4 Hyperlipidemia having Cholesterol 8mmol and triglyceride increased which among following best describes this
Apo A deficiency
ApobE deficiency
LPL deficiency
LDL defective
Insulin resistance
Ans:

151- 30 years lady with weight loss for 3 months weakness and palpitations. Na 128 K 5.2,HCO32 and TSH 0.6 what is the cause
A- Iatrogenic
B- Addison's
C- Hyperthyroidism
D- Renal failure
E- Diabetes
Ans: B

152- 35 years old female with type 1 diabetes had a fracture of forearm due to osteoporosis. The cause could be deficiency of
A- Insulin
B- Estrogen
C- Progesterone
D- Cortisol
Ans: A

153- Patient is complaining of headache and nausea and taking anti depressant having low Sodium Likely cause
A- CCF
B- Pulmonary edema
C- Hypernatremia
D- SIADH
Ans: D

154- After Hypophysectomy which cells will be effected?
A- Follicular cells of thyroid
B- Chief cells of parathyroid
C- Principal cell of parathyroid
D- Cells of Adrenal Medulla
E- Beta Cells of Pancreas
Ans: A

155- A Patient presented with Bone pain and Fractures Labs show High Parathyroid hormone this is mostly raised in which of following
A- Cancer
B- Pseudohypoparathyroidism
C- Precocious puberty
D- CCF
E- Adrenal Failure
Ans: B

156- Pregnant female had decrease level of T3 T4 and increase TSH. Lymphocytes are also found in aspirate.It is related to
A- Thyroid cancer
B- Grave disease
C- Thyroid storm
D- Hashimoto
E- Idiopathic
Ans: D

CamScanner

Explanation:
- Hashimoto is common cause of Hypothyroidism and has Hürthle cells and lymphoid aggregates with germinal centers

157- Most common complication of diabetes mellitus is
A- Dry gangrene
B- Wet gangrene
C- Fibrinoid necrosis
D- Red infarction
E- Caseous necrosis
Ans: A

Explanation:
- Common complication of DM – Dry gangrene
- Common complication of diabetic foot – Wet gangrene
- Common limb complication is – Dry gangrene

158- 32 years old disease female patient with very low cortisol what questions you will ask to know the cause of low cortisol
A- Taking OCP
B- Taking steroid
C- Taking Cortisol
D- Taking GH
Ans: B

159- Hormone raised in acute Injury is
A- Thyroid hormone
B- Epinephrine
C- Cortisol
D- Growth hormone
E- Insulin
Ans: C

160- A patient presented with internal female genitalia, external male genitalia and shows adrenal cortical hyperplasia. Which of the following hormones is deficient?
A- 11 beta hydroxylase
B- 17 hydroxylase
C- 21 alpha hydroxylase
D- Aldolase
Ans: C

161- Addisons disease patient present with which feature?
A- Hypertension
B- Hyperkalemia
C- Hypokalemia
D- Hypernatremia
Ans: B

162- In Grave disease Exophthalmos is due to:
A- Increase TSI
B- Increase T3 and T4
C- Increase TSH
D- Increase free thyroxine
Ans: A

163- In Grave disease Exophthalmos is due to deposition of
A- Glycosaminoglycan
B- Increase T3
C- Fats
D- Proteins
Ans: A

164- Tumor marker of medullary carcinoma?
A- CEA
B- AFP
C- Calcitonin
D- Beta HCG
Ans: C

165- If posterior pituitary is affected what will decrease:
A- GH
B- Glucagon
C- TSH
D- ADH
Ans: D

166- Appropriate test for growth Hormone deficiency:
A- Fasting early morning GH
B- 2 hours Post prandial
C- Insulin stimulation test
D- Insulin suppression test
Ans: C

167- Femlae patient having weight gain feels sleepy her thyroid profile awaited ANA positive what is likely cause:
A- Hypothyroidism
B- SLE
C- Discoid lupus
D- Rheumatoid arthritis
E- DM
Ans: A

168- Women with hyperthyroid feature with goitre. Diagnosed with iodine deficiency. Cause of deficiency:
A- Decrease intake in water and food
B- Improper diet
C- Defective absorption
D- Increase absorption
Ans: B

169- What is likely cause of Secondary hyperaldosteronism:
A- ACTH
B- CRH
C- Cortisol
D- Renin
E- Ag2
Ans: D

170- Pregnant lady with decrease TSH, increase T3 + T4. Treatment in First trimester is:
A- Propranolol
B- PTU
C- Procaine
D- Bupivacaine
Ans: B

Patient with absent uterus enlarged clitoris, blind ended vagina likely due to:
X-linked disease
Congenital adrenal hyperplasia
Testicular feminization
Androgen insensitivity syndrome
Ans: D

In DM Post prandial period there is?
Increase Glucose and insulin
Decrease Glucose and increase insulin
Increase Glucose and glucagon
Decrease Glucose and insulin
Ans: A

Hypokalemic metabolic alkalosis leading to volume expansion is seen in:
Conn syndrome
ACTH secreting tumor
Primary adrenal insufficiency
None
Ans: A

A woman has cold intolerance which test to be done to know hypothyroidism
ACTH
T3
TSH and Free T4
Calcitonin
Iodine level
Ans: C

In SIADH true is:
Increase plasma osmolarity
Increase urine osmolarity
Decrease urine osmolarity
Unchange plasma osmolarity
Ans: B

A diabetic patient present with nausea, headache, who is receiving anti-depressants drugs becomes Polyuric and His sodium is low. The most likely diagnosis:
Psychogenic polydipsia
Central diabetes insipidus
Hypoglycemia
Nephrogenic diabetes insipidus
Syndrome of inappropriate antidiuretic hormone (SIADH)
Ans: D

Explanation:
These drugs can damage kidney result in nephrogenic diabetes insipidus
While SIADH does not cause polyuria rather absorb water result in concentrated urine

177- In a patient with Diabetes Insipidus (with complete absence of ADH) Daily GFR is 150 litres without treatment. His urine flow will be approximately
A- 10L/day
B- 20L/day
C- 3L/day
D- 5L/day
E- 75L/day
Ans: A

178- A 30 years old female presented to OPD with excess hair growth, hypertension, hyperglycemia, hyperpigmentation, increased depression, edematous face, increased fat on chest & trunk, it's likely due to excess of:
A- Cortisol
B- ACTH
C- GnRH
D- LH
Ans: B

179- Antibodies in thyroid disease:
A- ANA
B- Antithyroid receptor antibodies
C- Antimitochondrial antibodies
D- Lupus antibodies
Ans: B

180- C cell related to which one of following:
A- Lung Carcinoma
B- Papillary CA of thyroid
C- Medullary CA of thyroid
D- HCC
D- Prostate CA
Ans: C

181- Mineralocorticoid secreting tumor, serum finding will be:
A- Hypocalcemia
B- Hypercalcemia
C- Acidemia
D- Hyperkalemia
E- Hyponatremia
Ans: A

Explanation:
- In Mineralocorticoid secreting tumor due to high aldosterone which cause Increase H secretion result in metabolic alkalosis.
- Normally H ions and Ca compete for binding with Albumin as H ions is already secreted so Ionized Ca will bind Albumin result in low Serum Calcium (Hypocalcemia)

182- What is the initial test commonly used to differentiate between simple obesity and Cushing's syndrome?
A- Serum glucose tolerance test
B- 24 hour urinary cortisol test
C- High dose Dexamethasone suppression test
D- Serum cortisol levels
E- Low dose Dexamethasone suppression test
Ans: B

CamScanner

183- Hyperthyroidism clinical signs are due to which on of following?
A- Increase oxygen requirement
B- Increase lipolysis
C- Increase carbohydrates absorption
D- Increase proteolysis
Ans: B

Explanation:
Excessive thyroid hormone levels stimulate lipolysis. As a result, individuals with hyperthyroidism often experience weight loss, despite an increased appetite, as their body utilizes stored fat for energy. This can lead to muscle wasting and a range of other symptoms associated with increased metabolic activity.

184- Increase ADH causes:
A- High urine osmolarity, high plasma osmolarity
B- High urine osmolarity than plasma osmolarity
C- Low urine osmolarity than plasma osmolarity
D- Low urine osmolarity, low plasma osmolarity
Ans: B

185- In hyperthyroidism Tachycardia is due to:
A- Adrenaline
B- Cortisol
C- Atropine
D- GH
Ans: A

186- A patient 7 year old boy presented in drowsiness His urine osmolarity 600 mosm, urea 15, Na 110 and K 3.4 likely cause is:
A- SIADH
B- Dehydration
C- Addisons disease
D- Nephrogenic Diabetes insipidus
Ans: A

187- A Patient after CVA has loss of appetite to food and drink and tendency to throw cause of his Dec thirst is:
A- Vasopressin
B- Stimulation of lateral hypothalamus
C- Stimulation of medial hypothalamus
D- None
Ans: A

188- A patient has episodic hypertension a d catecholamines tumors due to which cells Involvement:
A- Zona fasiculata
B- Zona glomerulosa
C- Zona reticularis
D- Chromaffin cells
Ans: D

189- A patient has Adrenal gland mass and Chatecholamine increase level this is likely:
A- Malignant medullary CA
B- Benign medullary CA
C- Diffuse hyperplasia
D- Atrophy
Ans: B

190- There is no edema due to inc aldosterone because of:
A- Increase Na/k activity of thick Ascending limb
B- Decrease thirst mechanism
C- Escape mechanism
D- Increase ADH
E- Decrease ANP
Ans: C

191- 25 Years old Patient having depigmented Skin lesion on back, lips and cheeks. There is family history of Diabetes. What is suitable pathogenesis of this disease?
A- Local reaction
B- Abnormal keratinocyte metabolism
C- Genetic disease
D- Autoimmune
Ans: D

192- A patient with Addison disease presented in emergency with which complication:
A- Hyperglycemia
B- Hypokalemic metabolic alkalosis
C- Malignant HTN
D- Hyperkalemic Paralysis
E- Hypernatremia
Ans: D

193- 11 years old boy having polydipsia, polyphagia, polyuria, weight loss with fasting hyperglycemia. What is the diagnosis?
A- Non obese NIDDM due to insulin resistance
B- Non obese NIDDM due to decreased insulin
C- IDDM
D- Diabetes insipidus p
E- Mature onset diabetes of Young
Ans: C

194- Characteristics of SIADH is:
A- Increase plasma osmolarity
B- Hyperosmolar urine
C- Decrease urine osmolarity
D- Unchange plasma osmolarity
Ans: B

195- Patient has complaint of Polyuria but blood glucose level and ADH are normal cause is:
A- Nephrogenic DI
B- Central diabetes insipidus
C- SIADH
D- ADH deficiency
Ans: A

196- A 02 years old child presented with a midline swelling just below the hyoid bone. The swelling was noticed at 03 months of age and is slowly increasing in size, with no movements on protrusion of tongue, the condition most likely is:
A- Accessory thymic tissue
B- Branchial cyst
C- Cranipharngioma
D- Ectopic thyroid gland
E- Thyroglossal duct cyst
Ans: D

Explanation:
Thyroglossal duct cyst will move with protrusion of the tongue & protrusion of tongue test is positive while in ectopic thyroid gland there will be no movement of the swelling with protrusion of tongue and hence, protrusion test is negative.

197- Effect of giving T4 to girl with hypothyroidsm is:
A- Decrease Respiratory rate
B- Increase respiratory rate
C- Decrease Oxygen consumption
D- Increase CO2 production
Ans: B

198- Feature of mineralocorticoid tumor is:
A- Hyperkalemia
B- Hypokalemia
C- Hypotension
D- Hyponatremia
E- Hypercalcemia
Ans: B

199- Ectopic thyroid hormone is realsed by:
A- Carcinoma of stomach
B- Small cell lung cancer
C- Adenocarcinoma
D- Carcinoma of bronchus
Ans: D

200- Potassium is 3meq/L due to increased:
A- Cortisol
B- GH
C- Aldosterone
D- TSH
E- Glucagon
Ans: C

201- In hyperthyroidism whic receptor will effect heart:
A- Alpha receptor
B- Cardiac beta adrenergic
C- Cardiac alpha
D- M receptor
Ans: B

202- Post adrenalectomy patient died due to Deficiency of:
A- Norepinephrine
B- Aldosterone
C- Testosterone
D- Epinephrine
Ans: B

203- A patient presented with severe metabolic alkalosis, BP was 190/110 (hypertension) and hypokalemia due to:
A- Addison's disease
B- Increase aldosterone levels
C- Adrenal hyperplasia
D- Secondary hyperaldosteronism
Ans: B

204- 69 year old woman having fracture due to:
A- Decrease progesterone
B- Decrease estrogen
C- Increase Cortisol
D- Decrease GH
Ans: B

205- Sentinel biopsy of axillary lymph node in a suspected breast cancer case is done to:
A- Avoid the axillary dissection
B- Confirm the ultimate prognosis of disease
C- To avoid metastasis
D- To know metastasis
Ans: A

206- Apatient has bradycardia and low bp. On investigation has low t3 t4 and increased tsh, how will you manage the patient?
A- Levothyroxine
B- Propylthiouracil
C- Methimazole
D- Iodine
Ans: A

207- Absolute and only indication of thyroid scan in thyroid neoplasms is to detect?
A- Ectopic thyroid tissue
B- Metastatic tumor rests
C- Cold nodule
D- Retrosternal extension
Ans: C

208- Which of the following is a feature associated with Cushing syndrome?
A- Blood glucose
B- Muscle wasting
C- Hypokalemia
D- Hypotension
Ans: B

209- Due to Severe stress, what will Increase?
A- ACTH
B- Cortisol
C- Catecholamines
D- Dopamine
Ans: B

Explanation:
- Stress Hormone – Cortisol >ACTH
- Stress + Vasoconstriction – Catecholamine
- Early stress hormone – CRH >ACTH >Cortisol

CamScanner

210- Growth spurt at puberty due to Factor released from?
A- Hypothalamus
B- Ant pituitary
C- Posterior Hypothalamus
D- Gonads
Ans: A

211- Calcitonin is Released from:
A- Chief cells
B- Follicular cells
C- Parafollicular cells
D- Chromaffin cells
E- Tracheal ring
Ans: C

212- 55 year old female with family history of diabetes having fasting sugar 156 & 161 on 2 occasions. She is Asymptomatic what should be done
A- Oral hypoglycemics
B- Oral hypoglycemic+inslulin
C- Life style modifications(Weight Reduction+Diet Control)
D- Only insulin
Ans: C

213- Hypocalcemia is associated with?
A- Myocardial Irritation
B- Acidosis
C- Hypomagnesemia
D- Hyperparathyroidism
Ans: A

214- Na+/K+ Pump stimulated by:
A- Epinephrine
B- Glucagon
C- GH
D- Insulin
Ans: D

215- On In utero study its revealed that there is absent vagina and testes with development of scrotum cause is
A- Increased LH
B- Decreased Testosterone
C- Decreased Estrogen
D- Testosterone producing tumour in mother
Ans: D

216- A female is worried about a lump in her breast. She also has family history of Ovarian carcinoma in her mother. What is main risk factor in her?
A- BRCA- 1
B- Smoking
C- HNPPC
D- CA-125
E- MLH-2
Ans: A

217- Increased ionized calcium indicates?
A- Chronic renal failure
B- Parathyroid adenoma
C- Pathological fracture
D- Hypoparathyroidism
Ans: B

218- A26 year old healthy woman with regular menstrual cycle was a passenger in bus which met an accident.She was uninjured but her husband and son died in ensuing. years her menses ceased and she had frequent nightmares about the accident the most likely reason for her amenorrhea is
A- Decrease CRH secretion
B- Decrease dopamine secretion
C- Increase CRH secretion
D- Increase growth harmone secretion
Ans: B
Explanation:
- Decrease dopamine will cause more prolactin to be released and which will inhibit gnrh this result in amenorrhea .

219- A patient of follicular thyroid carcinoma , it will mainly metastasize to ?
A- Brain
B- Vertebral column
C- Adrenals
D- Liver
E- Lungs
Ans: E

220- Patient presented with single soliditory nodule. On investigation oval nuclei seen it is
A- Medullary CA thyroid
B- Follicular CA thyroid
C- Papillary CA thyroid
D- Anaplasic CA thyroid
Ans: C

221- Nitrogen balance in acute abdominal surgery patient
A- Nitrogen loss is increase in burn patient as compared to major abdominal surgery
B- Its by cortisol
C- Nitrogen loss is increased in major abdominal surgery
D- Its increase by GH
Ans: C

222- A female Patient presented with complaint of increase heart rate, intolerance to heat with sweating, Moist hands & palms and diarrhea. Lab values are: Ca: Normal, PTH: Normal, Urea Normal, Phosphate: Normal. Which of the following can be the probable diagnosis?
A- Hyperthyroidism
B- Hashimoto's thyroiditis
C- De Quervain Thyroiditis
D- Carcinoid Syndrome
E- Thyrotoxicosis
Ans: E

223- Female having tremors, Increased Heart rate & Rapid weight loss. Investigations will show:
A- Increased T3,T4 & Increased TSH
B- Increased T3,T4 & Decreased TSH
C- Decreased T3,T4 & Increased TSH
D- Increased T3,T4 & Decreased TSH
Ans: B

224- Pituitary tumor causes most commonly which of the following affect?
A- Increase Dopamine
B- Increase Prolactin
C- Decrease Prolactin
D- Decrease Dopamine
E- Increase Glucagon
Ans: B

225- A lady came into opd with raised bp 160/90 her serum electrolyte k 3.9 her sister also had the same complians in pregnancy. What can be the possible diagnosis?
A- Cushing disease
B- Cushing syndrome
C- Geller syndrome
D- Sheehan syndrome
Ans: C

226- A pregnant lady has following Sugar levels On
1 h 6.4 mmol
2h 8.3 mmol
3h 7.2 mmol
What is likely cause
A- Gestational diabetes
B- Impaired glucose tolerance
C- Diabetes
D- Normal
Ans: B

227- After how long HBA1C should be repeated to estimate long term control of blood sugar?
A- 6 Months
B- 2 Months
C- 4 Months
D- 1 Month
E- 3 Months
Ans: E

228- In mineralocorticoid excess antagonist act on which site
A- PCT
B- Against aldosterone receptor
C- Against ADH receptor
D- Loop of Henle
Ans: B

229- A patient presented with Heat intolerance, Diarrhea on & off Associated with being anxious. On investigations, T3 & T4 Increased, TSH decreased & increased level of TSI. Diagnosis?
A- Hashimoto thyroiditis
B- De Quervain thyroiditis
C- Graves disease
D- Reidel thyroiditis
E- Hypothyroidism
Ans: C

230- 60 Years old lady presented with fracture of hip bone. Which supplement might be beneficial for the lady?
A- Ergocalciferol
B- 1,25(OH) 2 Cholecalciferol
C- 24,25 dihyroxycholecalciferol
D- Calcium
Ans: A

231- In Cushing syndrome following occur
A- Lymphocytosis
B- Neutropenia
C- Eosinopenia
D- Leukocytosis
Ans: C

232- A female patient presented with hirsutism, obesity and buffalo hump. She is diagnosed as Cushing syndrome . What other feature will be present
A- Hypotension
B- Hyperglycemia
C- Hypoglycemia
D- Decrease weight
Ans: B

233- 60 Years old lady presented with fracture of hip bone. Which supplement might be beneficial for the lady?
A- Ergocalciferol
B- 1,25(OH) 2 Cholecalciferol
C- 24,25 dihyroxycholecalciferol
D- Calcium
Ans: A

234- Patient presented with single soliditory nodule. On investigation oval nuclei seen it is
A- Medullary CA thyroid
B- Follicular CA thyroid
C- Papillary CA thyroid
D- Anaplasic CA thyroid
Ans: C

235- Which of the following will be Present in hypothyroid patient?
A- Weight loss
B- Heat Intolerance
C- Protein loss
D- Increase Cholesterol
E- Increased Lipolysis
Ans: D

CamScanner

236- Antibodies are produced in exophthalmos which is due to?
A- TSI
B- Increase T3, T4
C- Increase T3
D- Increase bound form of T3, T4
E- Low T3 & T4
Ans: A

237- Patient having Congestive cardiac failure. Secondary hyperaldosteronism is caused by:
A- Angiotensin 2
B- Renin
C- ADH
D- Cortisol
E- ACTH
Ans: B

Explanation:
Primary hyperaldosteronism (Conn syndrome)
- Hypokalemia
- Hypertension
- Inc aldosterone
- Dec renin

Secondary hyperaldosteronism
- Inc aldosterone
- Inc renin

Primary Adrenal insufficiency (Addison's Disease)
- Hypotension
- Hyperkalemia
- Increase pigmentation of skin

Cushing Disease
- Hypokalemia
- Central obesity with extremities wasting
- Moon faces
- Buffalo hump
- Spontaneous bruising
- Skin striae
- Proximal myopathy

239- Female having cold intolerance & Rapid weight gain. Investigations will show:
A- Increased T3,T4 & Increased TSH
B- Increased T3,T4 & Decreased TSH
C- Decreased T3,T4 & Increased TSH
D- Increased T3,T4 & Decreased TSH
Ans: C

240- Increased Pigmentation in skin is associated with:
A- ACTH
B- Cortisol
C- GH
D- TSH
Ans: A

241- Which one is a feature of Cushing syndrome?
A- Hyperglycemia
B- Muscle wasting
C- Hyperkalemia
D- Hypotension
Ans: A

242- A patient presents with myxedema. Which of the following findings would you most likely observe in this patient?
A- Hypocholesteremia
B- Hypercholesterolemia
C- Sweating
D- Hyperglycemia
E- Tachycardia
Ans: B

243- An old woman with short height, Peri-Oral Anesthesia,Tingling Sensations, having blood Ca Level 6 (normal 8-9), Low Phosphate, High PTH, Raised ALP & Normal Creatinine.What will be the cause?
A- Vitamin D deficiency
B- Primary hypoparathyriodism
C- Secondary Hyperparathyroidism
D- Primary Hyperparathyroidism
E- Malabsorption
Ans: A

244- Mass Left to Midline in neck,diagnosed as a firm Cold nodule with normal adjacent surroundings & Thyroid function Diagnosis:
A- Thyroglossal Duct cyst
B- Papillary Carcinoma
C- Follicular Adenoma
D- Medullary Carcinoma
Ans: C

245- Patient had a stroke followed by loss of appetite and thirst and was throwing things around Loss of thirst is due to increase in?
A- Vasopressin
B- Stimulation of Lateral hypothalamus
C- Angiotensin 2
D- Stimulation of Medial Hypothalamus
E- Increased Extracellular Volume
Ans: A

246- Earliest of all , indicator of low ca level in the body is
A- Ca+ level
B- Tetany
C- Chronic renal failure
D- 25 Vitamin D3 level
E- Pathological fracture
Ans: B

247- A patient presents with heat intolerance, weight loss, and laboratory findings showing elevated TSH and TRH levels. What is the most likely diagnosis?
A- Grave's disease
B- Primary thyrotoxicosis
C- Tumor of the hypothalamus
D- Tumor of the pituitary
Ans: C

248- A 50 years old patient had complaint of macroglossia, hyperglycemia and polyuria. MRI shows Tumor of pituitary gland. Which type of group is involved in the origin of this tumour ?
A- Thyrotrophs
B- Somatotrophs
C- Corticotrophs
D- Gonadotrophs
Ans: B

249- A thin lean child presents with low calcium levels and phosphate levels at the upper limit of normal (0.9 mmol/L). What should be checked in the serum to confirm the diagnosis?
A- Parathyroid Hormone (PTH)
B- Albumin
C- Vitamin D
D- Cortisol
Ans: A

Explanation:
- The combination of low calcium and high-normal phosphate suggests a possible parathyroid disorder, such as hypoparathyroidism or pseudohypoparathyroidism. Serum Parathyroid Hormone (PTH) levels will help establish the diagnosis.

(Normal Values)
- **Total serum calcium**: 8.5–10.5 mg/dL (2.12–2.62 mmol/L)
- **Ionized calcium** (biologically active form): 4.5–5.6 mg/dL (1.12–1.40 mmol/L)
- **Phosphate:**
- **Serum phosphate**: 2.5–4.5 mg/dL (0.81–1.45 mmol/L)

250- Patient know case of hypothyroidism taking levothyroxine 50mg 2 tablets before breakfast. Now he presented with his symptoms coming back including Cold intolerance & Constipation. What will you check now?
A- TSH
B- T3
C- T4
D- TSI
Ans: A

251- 1, 25(OH)2 regulated by:
A- Calcium
B- Phosphate
C- PTH
D- Cortisol
Ans: C

252- A patient swelling in neck, bilateral Exophthalmos. Antibodies against:
A- Thyroid Receptors
B- Thyroid Gland
C- TSI
D- Anti-TPO
Ans: A

253- A 45-year-old female presents with bone pain and parasthesia in the lower limbs. Her laboratory investigations were done and it showed Low Serum Calcium level: & High inorganic phosphates and the serum PTH levels were border- line raised. PTH given but no increase in phosphate levels. Diagnosis?
A- Primary hyperparathyroidism
B- Pseudo hyperparathyroidism
C- Secondary hyperparathyroidism
D- Tertiary hyperparathyroidism
E- CRF
Ans: A (Golijan)

254- A woman presents with cold intolerance, a symptom suggestive of hypothyroidism. Which test should be performed to confirm the diagnosis of hypothyroidism?
A- ACTH
B- Thyroid Profile
C- TSH
D- Calcitonin
E- Iodine level
Ans: C(Ganong)

Explanation:
- Serum TSH is the **investigation of choice**;a high TSH level confirms primary hypothyroidism. A low free T4 level confirms the hypothyroid state (and is also essential to exclude TSH deficiency if clinical hypothyroidism is strongly suspected and TSH is normal or low)

255- A patient with an XX karyotype presents to the outpatient department (OPD). On examination, the external genitalia appear male, while an ultrasound reveals the presence of a uterus and ovaries. Laboratory findings show serum sodium (Na) at 135 mEq/L and evidence of adrenal hyperplasia. Which enzyme deficiency is most likely responsible for this presentation?
A- 21- hydroxylase deficiency
B- 11β- hydroxylase deficiency
C- 17α- hydroxylase deficiency
D- 5α- reductase deficiency
E- Müllerian inhibiting substance deficiency
Ans: A

256- Which of the following hormones has the greatest effect on muscle strength & Cause Muscle hypertrophy?
A- Cortisol
B- Prolactin
C- Testosterone
D- Estradiol
E- Dihydrotestosterone (DHT)
Ans: C

CamScanner

257- Which of the following is clinical manifestation of cushing syndrome
A- Hypotension
B- Hypoglycemia
C- Muscle wasting
D- Hypertonia
E- Acne and hirsutism
Ans: C

258- Patient presents with weight loss, palpitation, heat intolerance, diarrhea on lab investigation what will be low
A- TSH
B- Reverse T3
C- Bound T3
D- Free T3
E- Free T4
Ans: A

259- A 20-year-old female presented with right sided cervical lymphadenopathy. She was completely asymptomatic. Histological examination reveals a metastatic tumor. The most likely primary carcinoma thyroid in this patient is:
A- Anaplastic carcinoma
B- Follicular carcinoma
C- Medullary carcinoma
D- Papillary carcinoma
Ans D

260- Patient presented with Fatigue & Hypotension. O/E, Skin pigmentation is visible. Investigation reveal: Aldosterone Decreased ,Cortisol↓ ,ACTH ↑ Decreased Na+ and Increased K+
A- Adenoma of Adrenal Cortex
B- Autoimmune destruction of Adrenal cortex
C- Hyperplasia of adrenal cortex
D- Malignant Tumour of Medulla
Ans: B

261- A patient presented with Fatigue, Headache, Ptosis & Weakness. Investigations reveal T3= 0.2 ug/dL, Free T4= 0.1 ug/dL, TSH= 0.4. ug/dL, Increased Catchecholamines and Increased FSH/LH. Most suitable diagnosis:
A- Hypothalamic Hemorrhage/Thrombosis
B- Hypopituitarism due to AIDS
C- Pituitary Tumour
D- Pituitary apoplexy
Ans: D

262- Which the following inhibit insulin secretion
A- Glucagon
B- Secretin
C- Beta adrenergic antagonist
D- Hyperglycemia
E- Beta agonist
Ans: C(Guyton)

263- A 30y old female patient present history of thyroidectomy few years back now present with laboratory findings which includes increase calcium ,low HPO4 levels and increase PTH and increase which of the following condition she is suffering from
A- Primary hyperparathyroidism
B- Secondary hyperparathyroidism
C- Vitamin d toxicity
D- CRF
E- Pseudohypoparathyroidism
Ans: A

264- A 30 year old male patient was present in OPD with complains of diarrhea ,weight loss ,palpitations on investigations TSH was low and T4 was raise thyroid biopsy shows columnar epithelium of follicles there was overlapping nuclei and pushed to periphery these histological feature shows which of the following
A- Thyroid adenoma
B- Hashimoto thyroditis
C- Medullary carcinoma
D- Follicle filled with colloid
E- Papillary carcinoma
Ans: A

265- 19-year- old girl presents with a lack of height increase(4 Feet 2 inches after puberty. She has a normal blood profile and blood sugar levels, with no other issues. Which hormonal abnormality is most likely to be observed?
A- Increased Somatostatin
B- Decreased IGF- 1
C- Deranged T3 & T4
D- Increased Insulin
Ans: B

266- After thyroid surgery patient presents with carpopedal spasm and dec calcium most likely cause is
A- Iatrogenic hypoparathyroidism
B- Tetanus
C- secondary hypoparathyroidism
D- Pseudohypoparathyrodism
Ans: A

267- A Patient presented with midline neck mass & weight loss. Microscopy shows prominent nucleoli & increase nucleus size and cosimophila Most probable diagnosis?
A- Anaplastic Carcinoma
B- Papillary Carcinoma
C- Follicular Carcinoma
D- Hurthle adenoma
E- Medullary carcinoma
Ans: B(Robins)

Explanation:
- The diagnosis of papillary carcinoma is based on nuclear features even in the absence of a papillary architecture.
- The nuclei of papillary carcinoma cells contain very finely dispersed chromatin, which imparts an optically clear appearance, giving rise to the designation ground glass or Orphan Annie eye" nuclei.
- In addition,invaginations of the cytoplasm may give the appearance of intranuclear inclusions

268- A mother brings her young infant her mother gave history that he is Lethargic and not tolerating breastfeed and slow development since birth Which of the following lab tests would you like to perform
A- TSH and urinary chromatography
B- Thyroid Function Test
C- Urinary light chromatography
D- Tissue enzymes essay
E- TSH with calorimeter
Ans: A

269- 27 years old woman presented with the complaints of weight gain, amenorrhoea and fatigue. Last year, she experienced a complicated delivery requiring a 2units of blood transfusion. She was unable to breastfeed. On examination she has dry skin and hypotension. Which one of the following is the most likely diagnosis?
A- Conn disease
B- Panhypopituitarism
C- Addison syndrome
D- Nelson syndrome
E- Pituitary adenoma
Ans: B

270- A patient swelling in neck, bilateral Exophthalmos. Antibodies against:
A- Thyroid Receptors
B- Thyroid Gland
C- TSI
D- Anti-TPO
Ans: A

271- A patient has diagnosed Prolactinoma. She has now menstrual cycle' irregularity due to?
A- Decreased GnRH
B- Decreased FSH & LH
C- Decreased Dopamine Secretion
D- Inadequate prolactin from Hypothalamus
E- Due to pressure on gonadotrophs
Ans: A

272- 2 Kids have history of staying at home mostly & away from sunlight.What will be decreased?
A- 25-Hydoxycholecalciferol
B- Calcium
C- 1,25 dihydroxycholecalciferol
D- Phosphate
Ans: C

273- Medullary carcinoma spreads via which of the following route
A- lymphatics
B- Vascular route
C- Direct invasion of adjacent tissue
D- Perineural spread
Ans: B(Bailey and love)
Explanation:
Involvement of Lymph nodes occurs in 50-60% Of the cases of medullary carcinoma and blood born metastases are common

274- Which of the following cancer is most commonly associated with hyperthyroidism
A- Squamous cell carcinoma
B- Small cell carcinoma
C- Large cell carcinoma
D- Adenocarcinoma
E- Metastatic carcinoma
Ans: A

275- A patient present with signs and symptoms of hyperthyroidism On histopathology there are by an increased number of thyroid follicles,reduced cytoplasm and a vacuolated appearance
A- Thyroid carcinoma
B- Thyroid adenoma
C- Hashimoto thyroiditis
D- Graves' disease
Ans: B

276- 55 year old female with history of chronic inflammatory disorder has been receiving long term treatment of steroid present in OPD with complain of dizziness ,fatigue ,weakness and decrease wound healing which of the following is responsible for her symptoms
A- ACTH
B- Glucocorticoid
C- Mineralocorticoid
D- ADH
E- Androgens
Ans: B

277- A women underwent cholecystectomy, after which her pulse increased, thyroid function test revealed that low TSH, low t3 AND T4 slightly increased which of the following is most likely diagnosis
A- Hypothyroidism
B- Hyperthyroidism
C- Subclinical thyroid
D- Sick euthyroid syndrome
Ans: D

CamScanner

CamScanner

Explanation:

- Sick euthyroidism usually presents with low serum TSH,raised T4 and normal or low T3 in a patient with systemic illness who doesnot have clinical evidence of thyroid disease.these abnormalities are caused by decreased peripheral conversion of T4 To T3 altered levels of binding proteins and their affinity for thyroid harmons and often reduced secreation of TSH.As the thyroid function tests are difficult to interpret in pateints with non-thyoid illness.it is wise to avoid performing TFTs during systemic illness and reevaluated TFTs after recovery of patient

278- In which of the following Conditions, Parathyroid hormone remains normal

A- Osteoporosis
B- CRF
C- Parathyroid adenoma
D- Pseudohypoparathyroidism

Ans: A

279- A patient presented with severe metabolic alkalosis, BP was 150/90 (hypertension) and serum Na 150 meq/ L and potassium was 3 meq/L there is increased aldosterone level in his blood:

A- Addison's disease
B- Primary hyperaldosteronism
C- Adrenal hyperplasia
D- Secondary hyperaldosteronism
E- Primary hyperparathyroidism

Ans: B

280- Which of the following metabolite of Vitamin D is used for laboratory assessment

A- 1,25 Vit. D3
B- 24,25 Cholicalciferol
C- Calcium
D- 25 hydroxylase (OH)

Ans: D

281- Vitamin D regulated by:

A- PTH
B- 25 Hydroxycholecalciferol
C- Po4 Levels
D- Calcium
E- Calcitonin

Ans: A

282- Vitamin D status assessed by Which of the following metabolite?

A- 25 OH cholecalciferol
B- 1,25 Vit. D3
C- 24,25 Cholicalciferol
D- Calcium
E- 1 OH Calciferol

Ans: A

283- Raised ACTH Will Lead to:

A- Hypercholesterolemia
B- Hyperpigmentation
C- Hypoglycemia
D- Weight Loss
E- Ketogenesis

Ans: B

284- A patient having bacterial infection, sufferer of DM having increase neutrophil decrease lymphocytes decrease eosinophils which of following condition is likely:

A- Cushing syndrome
B- Addison disease
C- Conns' Syndrome
D- Pheochromocytome

Ans: A

285- Patient develop sudden severe headache accompanying with palpitations anxiety and sweating during the episode her bp was 200/140 pulse was 56 beats /min and serum K was 3.4 meq/L . Excess of which hormone?

A- Cortisol
B- Angiotensin 2
C- Nor epinephrine
D- Aldosterone

Ans: C (Pheochromocytoma)

286- A patient presented with hyperglycemia increase lymphocytes and eosinophils due to?

A- Cushing syndrome
B- Diabetes Mellitus
C- Addison disease
D- Hypertension

Ans: A

287- A woman of 40 Years of age presents with feelings of being lethargic & Unwell for 3 months.She has history of weight loss & Diarrhea as well. Which investigation will u do?

A- ACTH
B- Calcitonin
C- MSH & T4
D- TSH & Free T4
E- TRH & GnRH

Ans: D

288- A patient experiences muscle pain and stiffness ten days after thyroidectomy. What could be the cause?

A- Hyperkalemia
B- Hypercalcemia
C- Hypomagnesemia
D- Hypokalemia
E- Hypocalcemia

Ans: E

which means the stomach is not stimulated by food intake.

gastrointestinal symptoms like ... gas, and cramps, as well as fatigue from nutrient deficiencies like iron and B12.

289- Female with milky discharge from nipples. On CT scan, a very small microprolactinoma was found. She also developed amenorrhea and infertility. Cause is?

A- Dopamine
B- Pressure effects on FSH and LH cells of pituitary
C- Decreased gonadotrophin releasing hormone
D- Increased FSH and LH

Ans: C

290- A 12-year-old child came to opd he seems to be 7 years old. He has mental retardation cause of this abnormality is

A- Thyroid horme
B- Growth hormone
C- Adrenal insufficiency
D- Cushing's syndrome
E- Vitamin D deficiency

Ans: A

291- First initial management for DKA?

A- IV insulin +Normal saline
B- Oxygen inhalation
C- Bicarbonate administration
D- Diuretic

Ans: A

292- A male presents with impaired erections and feels ashamed of his enlarged breasts. What is the most likely cause?

A- Excessive GnRH
B- Increased melatonin production
C- Increased growth hormone (GH)
D- Excessive corticotropin

Ans. D

Explanation:

- Excessive **corticotropin (ACTH)** can lead to conditions like **Cushing's syndrome**, where hormonal imbalances may cause gynecomastia, erectile dysfunction, and psychological distress. Elevated cortisol levels disrupt normal gonadal hormone regulation, leading to these symptoms

293- A 50 years old patient had complaint of macroglossia, hyperglycemia and polyuria. MRI shows Tumor of pituitary gland. Which type of group is involved in the origin of this tumour ?

A- Thyrotrophs
B- Somatotrophs
C- Corticotrophs
D- Gonadotrophs

Ans: B

C- Hepatic vasculature
D- Portal vasculature

Ans: D

294- A patient presents with hyponatremia and a history of a car accident followed by spleen surgery. What could be the most likely cause of the hyponatremia?

A- Aldosterone
B- Cortisol
C- Central DI
D- SIADH

Ans: D

295- Man with DKA, ketones in urine, what will be diagnostic?

A- Increased glucose in urine, increase ketone bodies in urine.
B- Increased glucose with increased albumin in urine
C- Increased Blood glucose with increased ketones in urine
D- Increased Blood glucose with decreased ketones in urine
E- Decreased Blood glucose with Increased ketones in urine

Ans: C

296- A patient presents with episodic hypertension due to cell damage in the adrenal gland. Which cells or region are most likely affected?

A- Zona fasciculata
B- Zona glomerulosa
C- Zona reticularis
D- Chromaffin cells

Ans: D (Robins)

Explanation:

- Episodic hypertension is a hallmark feature of pheochromocytoma, a tumor arising from the chromaffin cells of the adrenal medulla. Chromaffin cells secrete catecholamines (e.g., epinephrine and norepinephrine), which lead to paroxysmal hypertension when overproduced.
- Zona fasciculata is responsible for glucocorticoid (e.g., cortisol) production and is not directly linked to episodic hypertension.
- Zona glomerulosa regulates mineralocorticoid (e.g., aldosterone) secretion, primarily affecting fluid balance and steady-state blood pressure, not episodic hypertension.
- Zona reticularis produces androgens.

Better

297- A man with Type 1 Diabetes missed his insulin doses for 2 days and presented to the Emergency Room in a drowsy state, showing signs of Diabetic Ketoacidosis (DKA).Which hormone deficiency is primarily responsible for his condition?

A- Insulin
B- Cortisol
C- Aldosterone
D- NorEpinephrine

Ans: A

C- Dubin Johnson Syndrome
D- Liver Parenchymal Injury

Ans: B

298- Screening tool for diabetic peripheral neuropathy:
A- 6 minute walk test
B- capillary refill time
C- ankle brachial reflex
D- Monofilament testing
E- Two point discrimination
Ans: D

299- If glucose is less than 80mg what will be released in body in response
A- Insulin
B- Glucagon
C- Cortisol
D- ADH
E- Aldosterone
Ans: B

300- 56 year old man present with confusion ,headache and nausea On examination bp was 130/85mmhg and HR is 88bpm lab findings shows plasma osmolarity was 300 urine osmolarity was 1200
A- SIADH
B- DI
C- hyperaldosteronism
D- Acute renal failure
E- water deprivation
Ans: E

301- What is true about Melatonin
A- Causes pigmentation
B- Derived from serotonin
C- Released in morning
D- Causes ovulation
Ans: A

302- Female presented with complains of severe headache & uncontrolled hypertension. Labs show K 3.4mEq/L.Most probable cause is
A- Conn Syndrome
B- Pheochromocytoma
C- Addison disease
D- Cushing Syndrome
Ans: A

303- A patient present in OPD with complain of constipation ,weight gain ,lactating problems and dry skin and hairs
A- Hypothyroidism
B- Pan hypopituitism
C- Hyperthyroidism
D- Hyperpituitism
Ans: A

304- XX karyotype patient present in opd On examination externaf genitalia of male on ultrasound uterus and ovaries were present lab findings was Na 135 and there is adrenal hyperplasia which enzyme is deficient
A- 21 hydroxylase deficiency
B- 11beta hydroxylase deficiency
C- 17 hydroxylase deficiency
D- 5-alpha reductase deficiency
E- Mullarian inhabitor deficiency
Ans: A

305- A 60-year-old businessman is evaluated by physician for his high BP which was 185/130,His plasma aldosterone level is high. On imaging there was mass in adrenal medulla which of the following is commonly associated with
A- Hypokalemia
B- Hyperkalemia
C- Hyperglycemia
D- Hypercalcemia
E- Hypoglycemia
Ans: A

306- A patient Known case of thyroid disease being treated with Propylthiouracil (PTU) presents with fever ,which of the following investigation you will order
A- Bone marrow biopsy
B- TFTs
C- Blood culture
D- CBC
Ans: D

307- A female lady diagnosed case of Sheehan syndrome now present in OPD with light headache, dizziness, anxiety these symptoms are due to which of the following harmone
A- ACTH
B- TSH
C- FSH
D- LH
Ans: A

308- A patient with hypothyroidism on thyroxine therapy comes for follow-up. What is the best investigation to assess thyroid function?
A- Serum T3
B- Serum T4
C- Thyroid scan
D- Serum TSH
Ans: D

Explanation:
- Serum TSH is the most reliable test to monitor thyroid function and adequacy of thyroxine therapy in hypothyroid patients. It reflects the body's response to thyroid hormone levels and guides dose adjustments

309- bone pain and paresthesia in the lower limbs. Her laboratory investigations were done and it showed Serum Calcium level: 2.60 mmol/L (2.10-2.65 mmol/L Normal), inorganic phosphates: 0.9mmol/L (0.8-1.9 mmol/L is Normal). ALP 385 IU/L (Normal: 120-365 IU/L) and the serum PTH levels were border-line raised: 6.1 mmol/L (Normal: 1.5-6.0). What is the most likely diagnosis?(Medicine Feb 2025)
A- Primary hyperparathyroidism
B- Pseudo hyperparathyroidism
C- Secondary hyperparathyroidism
D- Tertiary hyperparathyroidism
E- CRF
Ans: A (Golijan)

Explanation:
Causes of Hyperparathyroidism and Corresponding Laboratory Values

Diagnosis	Cause	PTH	Ca^{2+}	Phos	Vit D
1° Hyperparathyroidism	parathyroid adenoma, parathyroid hyperplasia, parathyroid carcinoma	↑/→	↑	↓	↑
2° Hyperparathyroidism	low vitamin D (calcitriol), chronic kidney disease	↑	↓/→	↑ (CKD), ↓/→ (low vit D)	↓
3° Hyperparathyroidism	post-kidney transplant, parathyroid hyperplasia	↑	↓	↑	↓

Better

310- Which of the following tests is most helpful in diagnosing Graves' disease, an autoimmune condition causing hyperthyroidism?(Medicine Feb 2025)
A- Serum T3 level
B- Serum T4 level
C- Anti-TSH receptor antibodies (TRAb)
D- TSH level
E- Anti-ACh receptor antibodies
Ans: C

311- A patient with hyperthyroidism has already started treatment and is due for a follow-up. Which of the following tests is most appropriate for monitoring the effectiveness of treatment?(Surgery Feb 2025)
A- Thyroid peroxidase antibodies (TPO)
B- Free triiodothyronine (FT3)
C- Thyroid-stimulating hormone (TSH)
D- Free thyroxine (FT4)
Ans: C

312- Investigation for Hashimotos thyroiditis include(Surgery Feb 2025)
A- Anti thyroglobulin & anti TPO
B- Anti T3
C- TFTs
D- Anti Thyroglobin
Ans: A(FA+Pathoma)

Explanation:
- Anti microsomal and anti thyroglobulin antibodies destroy parenchyma and are present in hashimotos

313- A patient with Sheehan syndrome presents with dizziness, fatigue, and tiredness. Which hormone deficiency is primarily responsible for these symptoms?(Radiology Feb 2025)
A- TSH
B- GnRH
C- Cortisol
D- ACTH
Ans: D

314- A patient presents with symptoms of hyperthyroidism along with a gritty sensation in the eyes. What is the most likely diagnosis? (Radiology Feb 2025)
A- Grave's disease
B- Toxic multinodular goiter
C- Hashimoto's thyroiditis
D- Subacute granulomatous thyroiditis
Ans: A

315- How can malignant hyperthermia be differentiated from thyroid storm? (Radiology Feb 2025)
A- Presence of tachycardia
B- Sudden rise in temperature
C- Malignant hyperthermia occurs only after anesthesia exposure
D- Elevated creatine kinase (CK) levels in malignant hyperthermia
Ans: C

316- A young person from a northern region presents with lethargy, laziness, and cold intolerance. What is the most likely underlying cause?(Anesthesia Feb 2025)
A- Thyroid gland dysfunction
B- Dietary iodine deficiency
C- Pituitary gland dysfunction
D- Autoimmune thyroiditis
Ans: B

CamScanner

317- Anti-thyroid peroxidase (TPO) antibodies are commonly found in which of the following conditions?(Anesthesia Feb 2025)
A- Rheumatoid arthritis (RA)
B- Hashimoto's thyroiditis
C- Systemic lupus erythematosus (SLE)
D- Subacute thyroiditis
Ans: B

318- A patient with Addison's disease is at risk for which potential complication? (Anesthesia Feb 2025)
A- Hyperkalemic paralysis
B- Malignant hypertension
C- Peripheral circulatory collapse
D- Polycythemia
Ans: A

319 In DKA, from which of the following are ketone bodies synthesized? (Anesthesia Feb 2025)
A- Carbohydrates
B- Proteins
C- Lipids
D- Amino acids
Ans: C

320- Patient has autoimmune hypothyroidism & Addison's. What is the diagnosis? (Anesthesia Feb 2025)
A- APS Type 1
B- MEN 2A
C- MEN 2B
D- Schmidt Syndrome
E- Carpenter Syndrome
Ans: D

321- A young patient presented with sore throat fever and goiter. On examination his throat was congested, fever was 102F and goiter was observed. Labs showed TSH down, T3, T4 normal. What drug will you prescribe?(Anesthesia Feb 2025)
A- Methimazole
B- PTU
C- Co amoxiclav
D- Propranolol
Ans: D

322- A 10-year-old girl has recurrent headaches relieved by paracetamol. Imaging shows a tumor in the pineal gland. What is the most common tumor at this site? (Anesthesia Feb 2025)
A- Pineocytoma
B- Pineoblastoma
C- Germinoma
D- Glioma
Ans: C

323- A young boy presents with DKA-like symptoms.Low insulin will cause?"(Anesthesia Feb 2025)
A- Increased lipogenesis
B- Ketone body formation
C- Decreased gluconeogenesis
D- Increased glycogenesis
E- Decreased fatty acid oxidation
Ans: B

324- Melanin deposition causes which pigmentation?(Anesthesia Feb 2025)
A- Flesher rings
B- Kaiser Fleisher ring
C- Haab's Stria
D- Krukenberg spindle
Ans: D

325- Pleiomorphic adenoma, the most common benign tumor of the salivary glands, arises from which germ layer? (Anesthesia Feb 2025)
A- Benign tumor of **endodermal** origin
B- Benign tumor of **ectodermal** origin
C- Benign tumor of **mesodermal** origin
D- Benign tumor of **mixed origin**
Ans: D

326- Patient with Myxodema will present with:
A- Weight loss
B- Heat Intolerance
C- Protein loss
D- Increase Cholesterol
E- Increased Lipolysis
Ans: D

REPRODUCTION PATHO QUICK HINTS

Androgen insensitivity syndrome(Testicular Feminization)

- ✓ Defect in androgen receptor resulting in Female-appearing genetic male (46,XY DSD)
- ✓ Female external genitalia with scant axillary and pubic hair, rudimentary vagina
- ✓ Well developed Breast , Absent Uterus , Ovaries and fallopian tubes due to persistence of anti-Müllerian hormone from testes.

Adrenogenital Syndrome(CAH)

- ✓ Defect in Cortisol production due to low Cortisol, ACTH and Androgen increase result in Male Appearing of genetic Female(46XX)
- ✓ Virilization , Ambiguous genitalia with Enlarge Clitoris
- ✓ In Urine High 17 ketosteriods low cortisol and high pregnenolone

Different enzyme involved

- ✓ If deficient enzyme starts with 1, it causes hypertension; if deficient enzyme ends with 1, it causes virilization in females.
- ✓ 17 alpha hydroxylase cause hypertension , start with 1
- ✓ 21-hydroxylase cause virilization in females , end with 1
- ✓ 11β-hydroxylase cause virilization + hypertension both , because start with 1 and also ends with 1

Mole vs partial mole

Complete Mole	Partial Mole
46XX, 46XY	69XXX,69XXY,69XYY
Enucleated egg + Single sperm	2 Sperm +1 Egg
Hydropic villi	Some villi hydropic
No fetal part	Fetal part present
Increase 3 fold B HCG	Slight increase B HCG
HonycombCluster of grapes and Snow Storm	Only fetal parts on imaging

Ovarian Tumor

- ✓ Present with abdominal distention, bowel obstruction, pleural effusion.
- ✓ Associated with BRCA 1 &2

Epithelial tumors

Serous cystadenoma
- ✓ Benign. Most common ovarian neoplasm.

Mucinous cystadenoma
- ✓ Benign. Multiloculated, large. Lined by mucus-secreting epithelium
- ✓ Can result in pseudomyxoma peritonei

Brenner tumor Usually
- ✓ Benign. Solid, pale yellow-tan tumor that appears encapsulated. "Coffee bean" nuclei on H&E stain.

Serous carcinoma
- ✓ Most common malignant ovarian neoplasm. Psammoma bodies.

Mucinous carcinoma
- ✓ Malignant. Rare. May be metastatic from appendiceal or other GI tumors.

CamScanner

Germ cell tumors

Mature cystic teratoma(Dermoid Cyst)
- ✓ Benign. Most common ovarian tumor in young females.
- ✓ Cystic mass with 3 germ layers (eg, teeth, hair, sebum)
- ✓ Monodermal form with thyroid tissue (struma ovarii) may present with hyperthyroidism.

Immature teratoma
- ✓ Malignant, aggressive. Contains fetal tissue, neuroectoderm. Commonly diagnosed before age 20.

Dysgerminoma
- ✓ Malignant. Most common in adolescents. Equivalent to male seminoma "Fried egg" cells
- ✓ Tumor markers: Increase HCG &LDH.
- ✓ Associated with down syndroma

Yolk sac tumor(Endodermal sinus tumor)
- ✓ Malignant, aggressive. Yellow, friable (hemorrhagic) mass.
- ✓ 50% have Schiller-Duval bodies
- ✓ Tumor marker: Increase AFP.
- ✓ Occurs in children and young adult females.

Sex cord stromal tumors

Fibroma
- ✓ Benign Bundle of spindle-shaped fibroblasts.
- ✓ Meigs syndrome—Triad of ovarian fibroma, ascites, pleural effusion.

Thecoma
- ✓ Benign. May produce estrogen.
- ✓ Usually presents as abnormal uterine bleeding in a postmenopausal Female.

Sertoli-Leydig cell tumor
- ✓ Benign. Small, grey to yellow-brown mass.
- ✓ May produce androgens result in virilization (eg, hirsutism, male pattern baldness, clitoral enlargement).

Granulosa cell tumor
- ✓ Most common malignant sex cord stromal tumor.
- ✓ Often produces estrogen and/or progesterone. Present with Breast tenderness and post menopausal bleeding
- ✓ Call-Exner bodies
- ✓ Tumor marker: Increase inhibin.

Endometriosis

- ✓ Endometrium-like glands/stroma outside endometrial cavity, most commonly in the ovary (frequently bilateral), pelvis, peritoneum (yellow-brown "powder burn" lesions)
- ✓ In ovary, appears as endometrioma (blood-filled "chocolate cysts"

May be due to
- ✓ Retrograde flow
- ✓ Metaplastic transformation of multipotent cells,
- ✓ Transportation of endometrial tissue via lymphatic system.
- ✓ Characterized by cyclic pelvic pain, bleeding, dysmenorrhea, dyspareunia, dyschezia (pain with defecation), infertility; normal-sized uterus.

Adenomyosis - Extension of endometrial tissue (glandular) into uterine myometrium

Endometritis
- ✓ Due to Retained product of conception
- ✓ Chronic endometritis show plasma cells

Endometrial Hyperplasia
- ✓ Caused by Excess Estrogen
- ✓ Lead to Carinoma especially with Atypia

Endometrial carcinoma

- ✓ Most common gynecologic malignancy. Presents with irregular vaginal bleeding. Two types:

Endometrioid
- ✓ Most cases caused by unopposed estrogen exposure due to obesity, but alsoassociated with early menarche, late menopause, nulliparity.
- ✓ Histology shows abnormally arranged endometrial glands.

Serous
- ✓ Associated with endometrial atrophy in postmenopausal females. Aggressive. Psammoma bodies often seen on histology.
- ✓ Formation of papillae and tufts

Leiomyoma (fibroid)
- ✓ Most common tumor in females.
- ✓ Often presents with multiple discrete tumors
- ✓ Whorled pattern of smooth muscle bundles with well-demarcated borders on histology

Leiomyosarcoma
- ✓ Malignant proliferation of smooth muscle arising from myometrium
- ✓ Usually in postmenopausal females.
- ✓ Exam shows single lesion with areas of necrosis

Breast Pathology

Fibrocystic Changes

Sclerosing adenosis
- ✓ Acini and stromal fibrosis, associated with calcifications. Slight increase risk for cancer.

Epithelial hyperplasia
- ✓ Cells in terminal ductal or lobular epithelium. Increase risk of carcinoma with atypical cells.

Inflammatory
- ✓ Mastitis -Occur during breast feeding and Staph Aureus most common cause

Benign tumors

Fibroadenoma
- ✓ Most common in females < 35 years old. Small, well-defined, mobile mass
- ✓ Tumor composed of fibrous tissue and glands.

Intraductal papilloma
- ✓ Small fibroepithelial tumor within lactiferous ducts, typically beneath areola.
- ✓ Most common cause of nipple discharge (serous or bloody).
- ✓ Slight Increase risk for cancer.

Phyllodes tumor
- ✓ Large mass of connective tissue and cysts with "leaf-like" lobulations

Breast cancer

- ✓ Commonly postmenopausal. Often presents as a palpable hard mass A most often in the upper outer quadrant.
- ✓ Invasive cancer can become fixed to pectoral muscles, deep fascia, Cooperligaments, and overlying skin result in nipple retraction/skin dimpling.
- ✓ Triple negative (ER ⊖, PR ⊖, and HER2/neu ⊖) form more Aggressive

Risk factors

Female
- ✓ Increase Age
- ✓ Family History
- ✓ BRCA 1 &2
- ✓ Increase Estrogen Exposure(Nulliparity)
- ✓ Post menopausal obesity
- ✓ Lack of Breast feeding

CamScanner

Males
- ✓ BRCA2 mutation
- ✓ Klinefelter syndrome

Non invasive

Ductal carcinoma in situ
- ✓ Early malignancy without basement membrane penetration. Usually does not produce a mass.
- ✓ Increase Risk of Breast cancer in same breast and quadrant

Comedo carcinoma
- ✓ Subtype of DCIS.
- ✓ Cells have high-grade nuclei with extensive central necrosis and dystrophic calcification.
- ✓ Involves caseous necrosis

Cribriform Carcinoma
- ✓ Subtype of DCIS
- ✓ Show Cookie Cutter appearance

Lobular carcinoma in situ
- ✓ Decrease E-cadherin expression. No mass or calcifications
- ✓ Increase risk of cancer in either breast

Paget disease
- ✓ Extension of underlying DCIS/invasive breast cancer up the lactiferous ducts and into the contiguous skin of nipple lead to eczematous patches over nipple and areolar skin

Invasive

Invasive Ductal
- ✓ Most common type of invasive breast cancer.
- ✓ Firm, fibrous, "rock-hard" mass
- ✓ Histology Show Duct Cell formation in desmoplastic Stroma
- ✓ Classic stellate morphology

Subtypes

A-Mucinous Carcinoma
- ✓ Formation of Large Extracellular mucuin(Tumor float in mucus Sheets)
- ✓ Occur in old age

B-Tubular Carcinoma
- ✓ Formation of Tubules that lack Myoepithelial cells

C-Medullary Carcinoma
- ✓ Large, anaplastic cells growing in sheets with associated lymphocytes and plasma cells.
- ✓ Well circumsized Can mimic Fibroadenoma

D-Inflammatory Carcinoma
- ✓ Dermal lymphatic space invasion
- ✓ Breast pain with warm, swollen, erythematous skin around exaggerated hair follicles (peau d'orange)
- ✓ Lack Palpabe Mass
- ✓ Often mistaken for mastitis or Paget disease

Invasive lobular
- ✓ Due to Decrease E-cadherin expression orderly row of cells ("single file") And No duct formation.
- ✓ No desmoplastic response.
- ✓ Often **bilateral** with multiple lesions in the same location.

Penile Pathology

Squmous Cell Carcinoma

Risk factors
- ✓ Phimosis commonly linked with Penile cancer
- ✓ Bowen Disease
- ✓ Bowenoid Papulosis

- ✓ Uncircumcized Male
- ✓ HPV

Hydrocele

Congenital hydrocele (Communicating)
- ✓ Common cause of scrotal swelling A in infants, due to incomplete obliteration of processus vaginalis.

Acquired hydrocele(Non Communicating)
- ✓ Scrotal fluid collection usually secondary to infection, trauma, tumor. If bloody then hematocele.

Spermatocele
- ✓ Cyst due to dilated epididymal duct or rete testis.
- ✓ Paratesticular fluctuant nodule.

Hypospadiasis/Epispadiasis

Hypospadius
- ✓ Abnormal opening of penile urethra on ventral surface of penis
- ✓ Defect in Urigenital Fold
- ✓ Hypospadias is more common than epispadias.
- ✓ Associated with inguinal hernia, cryptorchidism, chordee (downward or upward bending of penis)
- ✓ Can be seen in 5α-reductase deficiency.

Epispadius
- ✓ Abnormal opening of penile urethra on dorsal surface of penis
- ✓ Defect in position of Genital Tubercle
- ✓ Exstrophy of the bladder is associated with Epispadias.

Testicular tumors

Germ cell Tumors

Seminoma
- ✓ Young age Malignant Painless, homogenous testicular enlargement
- ✓ Most common testicular tumor.
- ✓ Analogous to ovarian dysgerminoma
- ✓ Watery cytoplasm and "fried egg" appearance on histology.
- ✓ Increase placental ALP (PALP). Raised LDH rarely Beta HCG elevated
- ✓ Highly radiosensitive.
- ✓ Good prognosis

Teratoma
- ✓ Painless testicular tumor
- ✓ Mature stem cells present

Yolk sac tumor(Endodermal sinus tumor)
- ✓ Malignant, aggressive. Yellow, mucinous. **Schiller-Duval bodies** resemble primitive glomeruli.
- ✓ Increase AFP is highly characteristic.
- ✓ Most common testicular tumor in children < 3 years old.

Embryonal carcinoma
- ✓ Malignant. Painful, hemorrhagic mass with necrosis.
- ✓ May be associated with Increase HCG and normal AFP levels when **pure**
- ✓ Increase HCG and AFP when **Mixed**
- ✓ Worse prognosis than seminoma

Choriocarcinoma
- ✓ Malignant. Disordered syncytiotrophoblastic and cytotrophoblastic elements. Hematogenous metastases to lungs(Cannon ball Metastasis) and brain.
- ✓ Increase HCG. May produce gynecomastia, symptoms of hyperthyroidism (α-subunit of hCG is identical to α-subunit of LH, FSH, TSH).

Non–germ cell tumors

Leydig cell tumor
- ✓ Mostly benign. Golden brown color contains Reinke crystals

CamScanner

- ✓ Produces androgens or estrogens leads to precocious puberty, gynecomastia.

Sertoli cell tumor

- ✓ Also called androblastoma (arises from sex cord stroma).
- ✓ Mostly benign.

Primary testicular lymphoma

- ✓ Malignant, aggressive. Typically diffuse large B-cell lymphoma.
- ✓ Common in Old Age
- ✓ Painless Testicular tumor
- ✓ Raised LDH

Prostate

- ✓ Median-Structurally largest lobe
- ✓ Lateral-Anatomically largest lobe
- ✓ Peripheral-Largest zone

CA prostate

- ✓ Peripheral zone / Posterior lobe Metastasize to Vertebral column and brain by Anterior Intervertebral venous plexus(Batson)
- ✓ Prostatic acid phosphatase (PAP) and PSA are useful tumor markers (Increase total PSA, with Decrease fraction of free PSA).
- ✓ Metastases in bone indicated by lower back pain and increase serum ALP and PSA.

BPH

- ✓ Median lobe / Transitional zone
- ✓ Increase Frequency of Urine , Unable to start and stop urine
- ✓ Characterized by smooth, elastic, firm nodular enlargement (hyperplasia not hypertrophy) of periurethral (lateral and middle) lobes,
- ✓ Lead to Bladder hypertrophy , Hydronephrosis and UTI
- ✓ Increase Total and Free PSA

Polycystic Ovary Syndrome

- ✓ Hyperinsulinemia and/or insulin resistance hypothesized to alter hypothalamic hormonal feedback response
- ✓ Increase LH:FSH, increase androgens (eg, testosterone)
- ✓ Common cause of decrease fertility in females.
- ✓ Enlarged, bilateral cystic ovaries presents with amenorrhea/oligomenorrhea,hirsutism, acne, fertility.
- ✓ Associated with obesity, acanthosis nigricans.
- ✓ Increase risk of endometrial cancer

Random

- ✓ Cervical Dysplasia – HPV>IUCD
- ✓ Cervical Metaplasia – Multiparity>IUCD
- ✓ Cervical Cancer - HPV 16 >18
- ✓ Pap Smear is initial screen for Cervical Cancer
- ✓ Colposcopy and Biopsy best and diagnostic test for Cervical cancer
- ✓ E6 gene product (inhibits TP53) and E7 gene product (inhibits pRb)
- ✓ **Koilocytes** are pathognomonic of HPV infection.
- ✓ Common Cause of Anovulation is Pregnancy >PCOS>Obesity
- ✓ Cryptorchidism Increase Risk of Malignancy >Infertility
- ✓ **Varicocele** is Dilation of pampinIform plexus often left sided can cause infertility. Do not transalluminate
- ✓ **Testicular torsion** Characterized by acute, severe pain, high-riding testis, and absent cremasteric reflex. ⊖ Prehn sign.
- ✓ Common Cancer endometrial > ovarian > cervical

- ✓ **Prognosis** of Cancer - Cervical >Endometrial > Ovarian
- ✓ High Estrogen OCP Prolong/Long term use cause in post menopausal – Endometrial CA
- ✓ Estrogen Containing OCP Increase risk of – Thromboembolism(DVT)
- ✓ Mixed HRT containing both Estrogen and Progesterone cause – Breast CA(Robins) > DVT
- ✓ Low estrogen OCP cause – Hepatic Adenoma
- ✓ For Breast CA in premenopausal women and also in selected post menupausal women - Tamoxifen
- ✓ For Breast CA in postmenupaual women only -- Aromatase inhibitors
- ✓ In prevention of breast cancer in high risk women (Strong family history , risk of IHD and osteoporosis) -- Raloxifen
- ✓ Elevated HCG in – Choriocarcinoma , Hydatiform mole , gestational trophoblastic tumors
- ✓ Oligohydromnios could lead to – Potter yndrome
- ✓ Most common ovarian mass in young female – Follicular cyst
- ✓ Spindle shaped tumors that are desmin positive – Sarcoma bortyroides
- ✓ Bent penis due o acquired fibrous tssue formation – Peyonie's disease
- ✓ DES used in pregnancy leads to – Clear cell carcinoma
- ✓ **Testicular swelling, ill lined granular sheets, bands and microcysts – Leydig cell tumor**
- ✓ **In primary syphilis best specimen for diagnosis is – Genital sore**
- ✓ **Electrolyte disbalance in Hyperemesis gravidum is - Hypokalemia**
- ✓ **Peau'd orange appearance of breast occurs in malignancy of breast due to distortion of -** Suspensory Ligaments of Breast

CamScanner

REPRODUCTION PATHOLOGY

1. A 40year patient with painless testicular mass, Doctor decided for radiotherapy, which on is sensitive to radiation?

A- Lymphoma
B- Seminoma
C- Germ cell tumor
D- Embryonal Carcinoma
Ans: B

Explanation:

Regarding sensitivity to radiotherapy:

- Lymph node tumor > Seminoma > Glioma > Craniopharyngioma
- Old Age + Painless testicular tumor + Raised LDH – Lymphoma
- Old Age + Painless testicular tumor + Mature Stem cells – Teratoma
- Young + Painless testicular tumor + Raised LDH+ Radiosensitive – Seminoma
- Least Radio Sensitive Blood Cell – Platlets
- Most Radio Sensitive Organ – Skin
- Least Radio Sensitive Organ – Vagina
- Most Radio Sensitive Mucosa – Intestinal
- Radiation induced Brain malignancy – Meningioma
- Overall radiation induced CA – Leukemia

2. Which of following is IUCD complication?

A- Ca cervix
B- Vaginal discharge
C- Metaplasia of endocervix
D- Dysplasia
E- Anaplasia
Ans: B

Explanation:

- Irregular vaginal bleeding > Prulent Discharge

3. Female gravida 3, para 2 Previous 2 child have some karyotype abnormality, but female physically normal this is related to

A- Deletion of q arm
B- Isochromosomes
C- Robertsonian
D- Inversion Chromatid
Ans: C

4. Biopsy of specimen CA showing fibrovascular septa, and scattered calcifications giving like sand grain appearance. Which tissue most likely it is?

A- Lung
B- Colon
C- Breast tissue
D- Thyoid
Ans: C

5. A woman and man have history of recurrent pregnancy, their clinical and genetic history is unremarkable, but all pregnancies end up still birth how will you investigate?

A- Southern blot
B- Tandem mass spectroscopy
C- Next generation sequencing
D- Karyotyping
E- FISH
Ans: D

6. Most cheapest & cost effective easy method for screening of cervical cancer:

A- Tumor marker
B- Biopsy
C- Pap Smear
D- Vaccination
E- Cone Biopsy
Ans: C

7. Female 28 weeks gestation diagnosed with polyhydramnios on USG Which of Following associated with it?

A- Duodenal atresia
B- Club foot
C- Pulmonary hypoplasia
D- IUGR
E- Cleft Palate
Ans: A

Explanation:

Causes of Polyhydramnios

- Dudenal/Esophageal Atresia
- Anencephalay
- Maternal Diabetes

Causes of Oligohydramnios

- Renal Agenesis
- Uteroplacental insufficiency

8. Phenotypically female having primary amenorrhea and karyotype XY what is diagnose:

A- 5Alpha reductase deficiency
B- Androgen insensitivity syndrome
C- Adrenogenital
D- Turner syndrome
Ans: B

9. A 48years old female having no menstruation from 6 month most likely reason is:

A- Decrease estrogen increase FSH and LH
B- Decrease estrogen increase FSH decrease LH
C- Increase estrogen and increase FSH
D- Increase estrogen and decrease FSH and LH
Ans: A

10. A young male having scrotal mass and raised LDH probable diagnosis is which of following?

A- Hydrocele
B- Omphocele
C- Testicular lymphoma
D- Seminoma
E- Teratoma
Ans: D

Explanation:

- Old Age + Painless testicular tumor + Raised LDH – Lymphoma
- Old Age + Painless testicular tumor + Mature Stem cells – Teratoma
- Young + Painless testicular tumor + Raised LDH – Seminoma

11. Effect of multiparty on cervix is:

A- Metaplasia
B- Dysplasia
C- Anaplasia
D- Hypertrophy
Ans: B

Explanation:

- Multiparity – CA Cervix and Adenomyosis
- Nulliparity – CA Endometrium and Endometriosis

12. 20 weeks pregnant women with miscarriage presented with nipple discharge what is possible cause?

A- Pregnancy induced prolactinoma
B- Autoimmunity
C- Ovarian Failure
D- High GnRH
Ans: A

13. 70 year lady with vaginal bleeding D/C on exam type of precancerous change highest chance of developing endometrial CA and will be indication for hysterectomy is:

A- Metaplasia
B- Dysplasia
C- Complex hyperplasia with Atypia
D- Hyperplasia
E- Hyperplasia with Typia
Ans: C

14. A Young girl with bilateral ovarian mass consist of hair and teeth diagnose is:

A- Lymphoma
B- Cystic hygroma
C- Choriocarcinoma
D- Brenner tumor
E- Teratoma
Ans: E

15. A patient with ambiguous genitalia and karyotype 46xx diagnosis is:

A- CAH
B- Mixed gonadal dysgenesis
C- Testicular feminization syndrome
D- Androgen insensitivity syndrome
Ans: A

16. Patient presented with penile discharge, upon pressing urethra white discharge oozed out, thepatient was diagnosed as Neisseria gonorrhea which complication can now occur?

A- Sacroilitis
B- Aortitis
C- Epididymitis
D- Prostatitis
Ans: C

17. 58 years old obese and diabetic lady underwent endometrial sampling for post-menopausal bleeding historyreveal moderately differentiated endometrial adenocarcinoma the most common pattern of spread is:

A- Lymphatic spread
B- Direct extension to adjacent structures
C- Exfoliation of malignant cells via fallopoan tube
D- Hemtogenous spread
Ans: B (Most common direct spread)

18. A patient with Delayed puberty having small testis with Large legs and Gynecomastia and Karyotype is 47 XXY most suitable diagnose is:

A- True Hermaphrodite
B- Down Syndrome
C- Marfan Syndrome
D- Klinefelter Syndrome
E- Edward Syndrome
Ana: D

19. Which of following tumor spread through hematogenous route most commonly?

A- Small cell CA of lung
B- Medullary CA of thyroid
C- Oat cell carcinoma of lung
D- Endometrial carcinoma
E- Intraductal Carcinoma of breast
Ans: D

20. A man with normal external genitalia married but had no kids he had normal ejaculation period but semen analysis showed azospermia cause may be in:

A- Epidydymis
B- Sertoli cell Defect
C- Defect of Vas deference
D- Seminiferous tubules
E- Defect in Prostate
Ans: B

CamScanner

Explanation:
- Decrease FSH and LH result in azospermia And
- FSH in male is produced by Sertoli cells.

21. A 45y old patient is bleeding from the nipple but no mass is palpable no axillary Lymphnode palpable what is the likely cause of this condition?
A- Ductal CA in situ
B- Invasive lobular carcinoma
C- Intraductal papilloma
D- Fibrocystic Change
E- Fat Necrosis
Ans: C

22. A patient presented with urgency of urine, Fever and Lethargy. He gave history of Weight loss and Diagnosed as a case of Bladder Carcinoma. The causative organism is which of following?
A- Compylobacter
B- Schistostoma
C- E. coli
D- EBV
Ans: B

Explanation:
- Transitional bladder CA – Smoking > Amines > Hydrocarbon
- Squamous Cell Bladder CA – Schistostoma > Stones > Indwelling catheter

23. 17 ketosteroid increase in:
A- Conns syndrome
B- Adrenogential syndrome
C- Cushing syndrome
D- Addison Disease
E- Marfan Syndrome
Ans: B

Explanation:
In Adrenogenital Syndrome
- High 17 ketosteriods low cortisol and high pregnanolone

24. Young patient with beta HCG increased++ and alpha feto protein normal and tumor treated with radiotherapy having which of following tumor?
A- Yolk Sac Tumor
B- Mixed Germ Cell Tumor
C- Seminoma
D- Lymphoma
E- Teratoma
Ans: C

25. A patient presented with Sleep disturbance, increase weight increase appetite and genital hypoplasia likely cause is:
A- Craniopharyngioma
B- Kallman syndrome
C- Tunrer syndrome
D- Klinfilter syndrome
Ans: A

26. A lady had obstructed labor for 2 days, LSCS done, folley passed for 14 days, urine started leaking after 10 days, what could be the cause?
A- Vesico vaginal fistula
B- UTI
C- Stress incontinence
D- Urge incontinence
E- Ureter damage
Ans: A

27. Patient having complain of urgency and dysuria and raised PSA and diagnosed as prostate carcinoma it involves which of the following lobe most commonly:
A- Anterior
B- Posterior
C- Lateral
D- Median
E- Inferior lobe
Ans: B

Explanation:
- Structurally largest lobe – Median
- Anatomically largest lobe – Lateral
- Largest zone – Peripheral
- CA prostate – Peripheral zone and Posterior lobe
- BPH – Transitional zone and median lobe.

28. A young boy presented with painless swelling in the scrotum with no other complication, he gave history of hit by ball very hard on scrotal area 4 months back what is possible diagnose:
A- Hydrocele
B- Hematoma
C- Hemartoma
D- Hematocele
Ans: A

29. Most commonly diagnosed breast cancer:
A- Phylloids tumor
B- Fibroadenoma
C- Intraductal pappiloadenoma
D- Invasive ductal carcinoma
Ans: D (FA +Pathoma)

30. An old lady presented with bone pain. Lab reveals normal Calcium, Phosphorous and PTH. Lady is having osteoporosis what is etiology of this:
A- High Progesterone
B- Low Estrogen
C- Low FSH
D- Low Calcitonin
Ans: B

31. Husband wife want to conceive what will you counsel them about chance of pregnancy?
A- When estrogen level decrease
B- During menestruation
C- At time of LH surge
D- At secretory phase
Ans: C

32. Genotype in child what's true
A- Xy indicated a one bar body
B- Xxx have wide space hip
C- Xx/yy trye harmapharadite
D- Xxy are true Hermaphrodite
E- XO is normal female
Ans: D

33. Couple married 2 year ago female did not conceive her menstural cycle is normal. The phase which indicate the ability of an girl when ovulation start is
A- At menarche
B- After 1 year
C- After 2 year
D- After 3 year
E- After 4 year
Ans: A

34. 6 years old girl presented to OPD with excessive facial & chest hair, adult size external genitalia & deepening of voice. She also gives history of two siblings death suffering from same condition which test would best confirm the diagnosis:
A- Karyotyping
B- FSH and LH
C- Testosterone
D- Dexa suppression test
E- 17 hydroxy progesterone
Ans: E

35. The number of maternal death to the live birth:
A- Maternal mortility ratio
B- Maternal mortility rate
C- Neontal mortality ratio/Maternal ratio
D- Neonatal mortality rate/Maternal rate
Ans: A

Explanation:
- **Maternal mortality ratio** is the number of maternal deaths per live births
- **Maternal mortality rate** is the number of maternal deaths in a given period of population of women who are of reproductive age

36. A Post Menuopasual lady having lieomyoma present with abnormal uternie bleeding her cytology report reveal Increase endometrial stroma and Few Glands what is likely cause:
A- Apotosis
B- Atrophy
C- Hyperplasia
D- Hypertrophy
E- Dysplasia
Ans: B

Explanation:
- More stroma than glands – Atrophy
- More glands than stroma –Hyperplasia

37. Female with infertility married for 10 years, irregular menses 2 – 3 times per year, facial hair and obesity. What is at risk of developing?
A- Cushing disease
B- Endometrial carcinoma
C- Type 1 DM
D- Adrenal atrophy
E- Addison Disease
Ans: B

38. 60 year old man presented in opd with complain of hematuria and inc urinary frequency on DRE there is stony hard mass felt that is prostate lymphatic drainage of it:
A- Deep inguinal
B- Internal iliac and Sacral
C- Superficial inguinal
D- Common iliac
E- Para aortic
Ans: B

39. A young girl 9 years old having normal menstruation, enlarged clitoris due to
A- CAH/ Androgenital
B- CNS Tumor
C- Gondal tumor
D- Vaginal tumor
Ans: A

40. 30 week pregnant lady tell that she has consumed moderate amount of alcohol during 1st trimester what is risk to baby?
A- Microcephaly
B- Delayed birth
C- Edward Syndrome
D- Epicanthal fold
E- Short Nasal Bridge
Ans: A

CamScanner

41. HSV 2 causes which of following?
A- CA Cervix
B- CA Endometriam
C- CA Ovary
D- CA Breast
Ans: A

Explanation:
- HSV 1 – Herpes labialis , Keratitis and Encephlitis
- HSV 2 – Herpes Genitalis and CA Cervix

42. 68 years old women with poor dietary habits and sedentary life style having fracture of femur neck most suitable cause is:
A- Post menopausal low estrogen
B- Decrease vitamins
C- Sedentary life
D- Rest
E- Infection
Ans: A

43. Female with oligomenorrhea karyotype 46XX/45X0 associated features is:
A- Wide nipple and depressed nasal bridge
B- Gonadal dysgenesis
C- Short staure, prominent simin crease
D- Webbed neck
Ans: B

44. Gold standard investigation for placenta previa?
A- Pelvic USG
B- Pelvic MRI
C- Transvaginal USG
D- Doppler USG
E- Examination under GA
Ans: C

45. Factor link With Penile CA?
A- Hypopadis
B- Phimosis
C- Bowens disease
D- Lichen planus
Ans: B

46. A woman was asked to go for hysterectomy after endometrial biopsy because of:
A- Atypical endometrial hyperplasia
B- Granuloma
C- Typical Changes of Benign
D- None
Ans: A

47. Ovary tumor with different tissue in:
A- Seminima
B- Teratoma
C- Lymphoma
D- Granulosa tumor
Ans: B

48. A Female patient with bone fracture and abnormal menses cause is:
A- Low Progesteron
B- Low estrogen
C- Low HCG
D- None
Ans: B

49. CA cervix caused by:
A- HSV
B- HPV
C- CMV
D- EBV
Ans: B

50. Increase AFP Seen in:
A- Lymphoma
B- Yolk Sac Tumor
C- Seminoma
D- None
Ans: B

	Seminoma	Yolk sac tumor	Chorio carcinoma	Teratoma	Embryonal Carcinoma
PALP	↑	-	-	-	-
AFP	-	↑↑	-	-/↑	-/↑
B-Hcg	-/↑	-/↑	↑↑	-	↑

51. Partial hydatiform mole how to present:
A- 46Xy
B- 47xxy
C- 69xxy
D- 47XXX
Ans: C

52. Breast fat necrosis most common cause:
A- Infection
B- Trauma
C- Malignancy
D- Inflammation
Ans: B

53. Tumor containing all the three germ cell layers is:
A- Yolk sac tumor
B- Seminoma
C- Teratoma
D- Granulosa cell tumor
Ans: C

54. When a patient undergoes bilateral oophorectomy hysterectomy what will happen?
A- Increase estrogen
B- Increase LH
C- Decrease estrogen
D- Decrease FSH
Ans: C

Explanation:
When a patient undergoes bilateral oophorectomy with hysterectomy and estrogen levels drops and it require estrogen replacement therapy and decrease estrogen leads to osteoporosis

55. Prostate cancer first metastasizes to:
A- Liver
B- Breast
C- Brain
D- Bone
Ans: D

56. A normal looking girl came to you with primary amenorrhea o/e having short blind vagina, with normal vulva, scanty pubic hair growth and normal breast and absent uterus her type of karyotype is:
A- 46XX
B- 47XY
C- 46XY
D- 45O
Ans: C

57. A young female having bilateral ovarian mass on histopath mass consist of hairs, teeth, epithelial cells, cartilages and gut cells diagnosis:
A- Sex chord tumor
B- Endodermal sinus tumor
C- Cystic teratoma
D- Dysgerminoma
E- Choriocarcinoma
Ans: C

58. Antibodies against FSH in male will cause:
A- Increase Sperm count
B- Decreasec Sperm count
C- Decrease Bone growth
D- Decrease Prolactin
Ans: B

59. A 18years old girl present with hx of amenorrhea otherwise normal appearance and secondary sexual characteristics. On USG absent ovaries and uterus. What is the cause?
A- Turner syndrome
B- Androgen Insensitivity Syndrome
C- Klinfilter syndrome
D- Down syndrome
Ans: B

60. 18-year-old girl with lump in right breast non tender no enlarged lymph node noted diagnosis:
A- CA in situ
B- Invasive ductal Ca
C- Fibroadenoma
D- Traumatic
Ans: C

61. Spermatogenesis is stimulated by:
A- FSH
B- Testosterone
C- LH
D- FSH and testosterone
Ans: D

62. Patient with adrenogenital syndrome?
A- High 17 ketosteroids high cortisol high pregnelone
B- High 17 ketosteriods low cortisol and low pregnelone
C- Low 17 ketosteriods high cortisol and high pregnolone
D- Low 17 ketosteriod high cortisol and low pregnolone
E- High 17 ketosteriods higg cortisol and low pregnolone
Ans: B

63. A patient has gynaecomastia and tall karyotyping is xxy 47:
A- Klinefilter syndrome
B- Turner syndrome
C- Down syndrome
D- Patau syndrome
Ans: A

64. One of the following drugs causes endometrial hyperplasia:
A- Progesterone hormone
B- Clomiphene citrate
C- Estrogens
D- Combined oral contraceptive pills
E- Bromocriptine
Ans: C

65. An old man had urine incontinence and he did'nt do anything for treatment for few years. So what was the type of problem?
A- Prostate CA
B- Benign prostate hyperplasia
C- Uretheral stricture
D- Bladder CA
Ans: B

CamScanner

66. A girl with normal secondary sexual development with secondary amenorrhea on Usg uterus absent. Defect is in:
A- Paramesonephric duct
B- Mesonephric duct
C- Seminal vesicle
D- None
Ans: A

Explanation:
- Paramesonephric duct (Mullerian Duct) give raise to female genital structures like Fallopian tube, Uterus & upper 1/3rd of Vagina.

67. Female at gestational age 34 having symphysio-fundal height of 28 weeks. Cause may be?
A- Anencephaly
B- Esophageal atresia
C- Renal agenesis
D- Tracheo esophageal fistula
Ans: C

Explanation:
- If Gestational age is more than Fundal height then – Renal Agenesis and Oligohydramnios.
- If Gestational age is less than fungal height then – Esophageal atresia, Hydrocephalus and polyhydramnios.

68. In a Pregnant lady to diagnose early neural tube defect, which one of the following used?
A- Ultrasound
B- Amniocentesis
C- CVS
D- B HCG
E- X-ray abdomen
Ans: A

69. An old man presented with urinary symptoms, after examination, doctor made a diagnosis of benign prostate hypertrophy, which zone of prostate is involved in this condition:
A- Central zone
B- Peripheral zone
C- Transitional zone
D- Anterior zone
Ans: C

70. Old aged man with testicular swelling & raised LDH is most likely suffering from:
A- Seminoma
B- Lymphoma
C- Embryonal Carcinoma
D- Yolk Sac tumor
Ans: B

Explanation:
- Old aged male with raised LDH is suffering from Lymphoma
- Young aged male with Raised LDH is Seminoma
- As general seminoma > Lymphoma

71. Leiomyoma is:
A- Benign Epithelial tumour
B- Benign mesenchymal tumour
C- Malignant tumour
D- None of the above
Ans: B

72. A 20 year old lady has amenorrhea for the past 6 months but otherwise reportedly normal, cause:
A- Anovulation
B- PCOS
C- Precocious Puberty
D- Granulosa Cell Tumor
Ans: A

73. A lady who has Normal Menstrual cycle of 28 days and now since 12 hrs her estradiol level is on peak and progesterone is not detectable. Whatcan be the possible cause?
A- Beginning of menstruation
B- Ovulation
C- Degeneration of corpus leuteum
D- Secretory Phase
Ans: B

Explanation:
- As the estrogen level is high & Progesterone isn't detectable this is most likely ovulation phase that leads to LH surge.

74. Ectopic pregnancy diagnosis is done by which of the following?
A- Transabdominal USG
B- TVS (TransVaginal USG)
C- CT Scan Abdomen
D- X-Ray Abdomen
Ans: B

75. Eight years old girl with well developed breast and pubic hair is due to:
A- Granulosa cell tumor
B- CAH
C- Theca cell tumor
D- Normal
Ans: A

76. In adrenogenital syndrome urine contains which substance?
A- 17-alpha ketosteroids
B- 18- alpha ketosteroids
C- 24,25 progesterone
D- 24 pregnolone
Ans: A

77. Most common side effect of IUCD:
A- PID
B- Purulent discharge
C- Irregular vaginal bleeding
D- Infections
Ans: C

78. Low level of cholesterol in premenopausal women and protection from thromboembolism is done by:
Progesterone
A- HCG
B- FSH
C- LH
D- Estrogen
E-
Ans: E

79. Prolong use of ocp will increase risk of:
A- Thromboembolism
B- Breast cancer
C- Endometrial carcinoma
D- Ovarian carcinoma
Ans: A

80. Female of 35 yr present with increase central obesity hyperpigmentation over the body which one is responsible for her changes?
A- Fsh
B- Acth
C- Lh
D- TRH
Ans: B

81. Most serious side effects of estrogen in postmenopausal:
A- Thromboembolism
B- Endometrial Ca
C- Breast Ca
D- Ovarian carcinoma
Ans: B

82. Lady is in labor, she has been administered oxytocin but she is not responding to it, the reason lies in the fact of:
A- Decrease oxytocin receptors on myometrium
B- Resistance to oxytocin
C- No oxytocin receptors present at all
D- Drug interaction
Ans: A

83. Failure rate of IUCD is:
A- 2-5 %
B- 3-5 %
C- 10%
D- Less than 1%
Ans: D

84. In developmental stages scanty hair, coarse triangular shaped hairline appears in:
A- Stage 1
B- Stage 2
C- Stage 3
D- Stage 4
Ans: C

85. Granulosa cell tumour has:
A- Call Exener Bodies
B- Estrogen Bodies
C- Lutein Cyst
D- Asteroid bodies
Ans: A

86. Which of the following is true hermaphrodite?
A- XXY
B- XXX
C- XYY
D- XO
Ans: A

87. Turner syndrome is associated with:
A- Normal Ovaries
B- Streak Ovaries
C- Postural Hypotension
D- Anemia
Ans: B

88. 6 years old girl presented to OPD with excessive facial & chest hair, adult size external genitalis & deepening of voice. She also gives history of two siblings death suffering from same condition which test would best confirm the diagnosis:
A- 17 Alpha Hydroxylase deficiencies
B- 21 Hydroxylase
C- 12 Beta Hydroxylase
D- 22 Hydroxylase
Ans: B

89. Mother worry about her young daughter who has loss of pubic and axillary hair with secondary sexual character cause is
A- DHEA
B- Estrogen
C- Progesterone
D- Androstendione
Ans: A

90. An eight year old girl brought by mother with breast development and appearance of pubic/ axillary hair cause is
A- Gonadal tumours
B- CNS tumour
C- Congenital adrenal hyperplasia
D- Idiopathic
Ans: C

CamScanner

91. 40 Weeks pregnant women have irregular uterine contractions which of following drugs will be beneficial for this lady?
A- Progesterone
B- Estrogen
C- Oxytocin
D- Prolactin
E- LH
Ans: C

92. Pap smear positive by:
A- HPV 18
B- HPV 16
C- Chlamydia
D- Trichomonas
Ans: B

93. Most important cause of male infertility:
A- Kline filter syndrome
B- Cryptorchidism
C- Down syndrome
D- Malunion of ejaculatory duct
E- Edwards
Ans: B(Robins)

94. Which of the following zone is most commonly involved in BPH?
A- Peripheral zone
B- Middle zone
C- Anterior zone
D- Central/periurethral zone
Ans: D

95. In a 60 year old female with breast cancer and osteoporosis HX of ischemic heart disease which should be given?
A- Raloxifen
B- Bisphosphonates
C- Vitsmin D
D- Calcium
Ans: A

96. In which of the following AFP is raised?
A- Seminoma
B- Teratoma
C- Embryonal carcinoma
D- Sertoli cell tumor
Ans: C
Explanation
- AFP raised in Embryonal carcinoma and Yolk sac tumor

97. Long term use of HRT with positive family history of breast CA. Now increased risk of developing?
A- Breast CA
B- Endometrial CA
C- Lung carcinoma
D- Cervical carcinoma
Ans: A

98. In female Patient of HIV Virus cause which of following
A- Endometrium ca
B- Ovarian
C- CA Cevix
D- Leukemia
Ans: C

99. Primigravida taking iron tablets, lots of fresh green vegetables, what deficiency she is at risk:
A- $Ca\ 2^{+}$
B- Vit. B12
C- Folic acid
D- Phosphate
E- Vitamin A
Ans: A

100. A Pregnant lady visited gynecologist for Dilatation n curettage on microscopic examination which type of precancerous change will be indication for hysterectomy?
A- Squamous
B- Complex hyperplasia
C- Simple hyperplasia
D- Metaplasia
Ans: B

101. A case of Androgen insensitivity syndrome was referred to your clinical. What investigation you will not do in this case?
A- Serum 17 OH progesterone
B- Testosterone level after stimulation with HCG
C. Dihydrotestosterone after stimulation with HCG
D- FSH and LH
E- Ultrasound abdomen
Ans: C

102. Married man had no children for few years and was diagnosed as sterile with azospermia. What is investigation of choice?
A- Serum FSH and serum LH
B- Serum prolactin
C- Serum testosterone
D- Semen analysis
Ans: A

103. Secondary oocyte is surrounded by corona radiata, which of the following layer contributes to the formation of corona radiata?
A- Granulosa cells
B- Theca internal cells
C- Theca external cells
D- Germ cells

104. Progesterone works in contraceptive pills by:
A- Spermicidal action
B- Induces uterine contraction
C- Inhibits ovulation
D- Inhibits maturation of ovarian follicles
Ans: C

105. Pineal gland tumor compression in 10 years old boy causes decreased secretion of melatonin what could be other possibility in this patient:
A- Delayed puberty
B- Early puberty
C- Increase serotonin
D- Increase Tryptophan
Ans: B

106. In the absence of 17 a-hydroxylase, which of following conversion reaction will be stopped:
A- Cholesterol to progesterone
B- Progesterone to prognolone
C- Stuff, check book for its deficiency
D- Stoppage of pregnolone to 17 hydroxyprogestrone
Ans: D

107. Patient with Irregular PV bleeding of 42 years old with uterine hyperplasia shows
A- Inc progesterone
B- Decrease estrogen
C- Increase estrogen
D- Increase prolactin
Ans: C

108. A non-pregnant patient has fasting glucose 122 after OGT 1 hour 198 and 2 hrs 194. Diagnosis?
A- Normal glucose tolerance
B Impaired DM
C-- Sec d.m
D- Over d.m
E- Something lag
Ans: B

109. Mother of 12 children with progressive dizziness and fatigue with angular stomatitis since 3 months with low mcv cause?
A- Iron deficiency anemia
B- Megaloblastic anemia
C- Aplastic anemia
D- Vitamin C deficiency
Ans. A

110. External genitalia of male development are due to?
A- Dihydrotestosterone
B- Testosterone
C- Estogen
D- Progesterone
Ans. A
Explanation
- External genitilia - DHT
- Internal genitilia - Testosterone

111. Female has menopause at age of 46 year significant possibility of her daughter to have menopasuse at this age is
A- 3 times
B- 2 times
C- 5 times
D- 10 times
Ans: B

112. A women presented with vulvur itching and pinkish purulent discharge. What is the cause is
A- Trichomonas vaginalis
B- Chlamydia
C- Gonorrhea
D- Lactobacillus
Ans: A

113. A lady with per vaginal bleeding, history of bleeding disorders and having dead fetus First step in management would be ?
A- Blood transfusion
B- Clotting studies
C- Streptokinase therapy
D- Platelets transfuion
E- Evacuation
Ans: E

114. A 32 years old G2+P1+0 presented with Gestational Amenorrhea of 33 weeks. She complains of severe headache and vomiting. Her Bp is 180/90mmHg. She also has history of Fits during last pregnancy. Which antihypertensive drug you will immediately give to this patient?
A- MgSo4
B- Hydralazine
C- Methyl Dopa
D- Captopril
E- Diuretic
Ans: B (Ten Teachers)
Explanation:
- DOC in pregnancy induced HTN – Labetalol >Methyldopa
- DOC in Hypertensive Emergency – Hydralazine >Labetalol
- For Eclampsia – MgSO4
- In this question asking drug to immediate lower BP so Hypertensive emergency asked so Hydralazine

CamScanner

115. A lady with 36 weeks pregnancy which one decreases?

A- Respiratory rate
B- Tidal Volume
C- Inspiratory capacity
D- TLC
E- Vital Capacity

Ans: D (Gyne obs textbook)

Explanation:

Respiratory Changes Remain Same:

- Respiratory rate
- Vital Capacity

Increase:

- Tidal volume
- Minute ventilation
- Inspiratory Capacity

Decrease:

- TLC &FRC
- Residual Volume

116. Positive nitrogen balance is seen in

A- Starvation
B- Malnutrition
C- Imediately after post surgery
D- Normal pregnancy

Ans: D

117. A new born baby is born to a 20 year old primigravida. On examination the baby has amputated limb. The most likely cause is

A- Cord prolapse
B- Alcoholism in mother
C- Umbilical knots
D- Amniotic bands

Ans: D

118. A 27 year old male having testicular tumor of non seminomatous type lab findings will be

A- PSA
B- Acid phosphatase
C- B-HCG
D- Fructose

Ans: C

119. A lady suffering from CA breastundergo total mastectomy developedema of right lower limb which of the following can be the reason of this edema?

A- Decrease plasma protein
B- Increase hydro static pressure
C- Lymphatic obstruction
D- Metastatic involvement of lymph nodes
E- Venous obstruction

Ans: C

120. A lady with 26 weeks gestation has uterine height of 24 weeks. On sonography there is no fetal parts and shows snow storm appearance, Likely Diagnose is

A- Choriocarcinoma
B- Complete mole
C- Partial mole
D- Down Syndrome
E- Edward Syndrome

Ans: B

Explanation:

Complete Mole	Partial Mole
46XX, 46XY	69XXX,69XXY,69XYY
Enucleated egg + Single sperm	2 Sperm +1 Egg
Hydropic villi	Some villi hydropic
No fetal part	Fetal part present
Increase 3 fold B HCG	Slight increase B HCG
Honycomb Cluster of grapes and Snow Storm	Only fetal parts on imaging

121. Electrolyte imbalance in hyperemesis gravidarum is:

A- Hyponatremia
B- Hypoglycemia
C- Hyperkalemia
D- Hypokalemia
E- Hypernatremia

Ans: D

122. Study on STD's , one group of boys had penile ulcers and other group had no ulcers , non ulcerating lesions were due to:

A- Chlamydia
B- Candida
C- Gonorrhea
D- Troponema pallidum

Ans: C

123. Stage 4 CA cervix drains which lymph node?

A- Inguinal
B- Internal illiac
C- External illiac
D- Common iliac
E- Pudendal

Ans: B

124. Peau'd orange appearance of breast occurs in malignancy of breast due to distortion of:

A- Lobules of Breast
B- Suspensory Ligaments of Breast
C- Lymphatics of Breast
D- Longitudnal Ligament of Breast

Ans: B

125. A male with history of sexual activity present with painless elevation and irregular eversion on scrotum may metastasize to brain and not being treated likely condition is:

A- Condyloma
B- Lymphogranuloma
C- Syphlis
D- Nisseria

Ans: C

126. Primigravida died during delivery due to some complication. Most common cause in our country is:

A- Malnutrition
B- Sepsis
C- Hemorrhage
D- Tb

Ans: C

127. 4 year old child present with testicular swelling, ill lined granular sheets, bands and microcysts, most likely it is:

A- Choriocarcinoma
B- Leydig cell tumor
C- Seminoma
D- Yolk sac tumor

Ans: B

128. Young female having pain in inferolateral region of abdomen prior to 2 weeks of onset of menstruation, but hemodynamically stable, Diagnosis is

A- Ectopic pregnancy
B- Mittelschmerz
C- Acute appendicitis
D- Chronic appendicitis

Ans: B

129- Primigravida having family history of PIH of mother and Sister percentage in primary Gravida would be

A- 14.1%
B- 12.3%
C- 14.2%
D- 5%

Ans: B

130- Female 17 year old 5'2 height with primary amenorrhea, absent secondary sexual characteristics O/E well develop Normal breast and Blind Vagina. USG confirm absent of uterus. Most likely karyotype of this is

A- 47XXY
B- 46XY
C- 45XO
D- 47XXX
E- 45XX

Ans: B (Androgen Insensitivity Syndrome)

131- Post menupausal women with 5cm adnexal mass an incidental finding on u/s endometrium is 2.5 cm thick the adnexal mass is most likely

A- Endometrial CA
B- Granulosa cell tumor of ovary
C- Mucinous cyst adenoma
D- Serous cyst adenoma

Ans: B

132- A girl presented with odema of hand, Swollen neck which chromosome abnormality might have occured

A- XXX
B- XXY
C- XO
D- YY
E- XOO

Ans: C

133- A 26-year-old woman is brought to the emergency department because of an 8-hour history of severe back and abdominal pain and mild but persistent vaginal bleeding. Ultrasonography of the abdomen shows a 2-cm ectopic pregnancy in the ampulla. The ampulla has ruptured into the surrounding tissue. Fluid from this rupture will most likely be found in which of the following locations?

A- Lesser peritoneal cavity
B- Mesometrium
C- Pouch of Douglas
D- Uterine cavity
E- Vagina

Ans: C

134- A girl with polycystic ovarian syndrome will have increased?

A- Insulin and LH
B- LH
C- ACTH
D- Growth hormones
E- TSH

Ans: A

Explanation:

- LH and insulin mainly cause increase androgen in PCOS.
- p5 develop rigors chills sudden lower abdominal

135- G6 pain, white watery vaginal discharge most suitable Diagnose is:

A- Chrioamionitis
B- UTI
C- Toxoplasmosis
D- Pyelonephritis
E- Appendicitis

Ans: A

CamScanner

136- 8 Year old girl with breast development and early pubic hair precocious puberty) Parents should be conselled that
A- No treatment
B- Tell Parents detail and its consequences
C- It will heal
D- No risk
Ans: B

137- A sexually active 23-year-old man with multiple sex partners has dysuria and a yellow urethral exudate. Gram stain of the exudate shows numerous neutrophils, many that contain intracellular gram-negative diplococci. He has had three similar episodes of urethritis over the past 2 years. Which of the following properties of the infecting organism best explains the reinfection?
A- Antigenic variation
B- Catalase
C- Inhibition of B-lymphocyte function
D- Inhibition of T-lymphocyte function
E- Polysaccharide capsule
Ans: A

138- After delivery of 4th baby mother had amorrhea fatigue and gradual loss of pubic and axillary hair due to
A- Pituitary tumor
B- Amylodosis
C- Pituitary Necrosis
D- TB
Ans: C

139- Complete mole is:
A- Diploidy
B- Triploidy
C- Monoploidy
D- Tertraploidy
Ans: A
Explanation:
- Complete mole – Diploidy
- Partial mole – Triploidy

140- Mother has history of hemolytic disease of new born and now she is having 26 weeks of pregnancy. What should be done?
A- Check fetal Rh D antigen
B- Mother's serial antibodies
C- Indirect coombs on mother
D- None of above
Ans: B

141- Early diagnose of preeclampsia done by:
A- Cortisol monitoring
B- HbA1c
C- Early BP monitoring
D- Regular LFT
Ans: C

142- A female with breast mass of 5 x6 cm rubbery mass large sheets of cells and calcium spicules likely diagnose is
A- Phylloid tumor
B- Fibroadenoma
C- Ductal carcinoma
E- Lobular carcinoma
Ans: B

143- Cervical pap smear shows 2/3rd epithelium has atypical, disorganized cells with loss of polarity, high N/C ratio and pleomorphism
A- Moderate dysplasia
B- Carcinoma in situ
C- Metaplasia
D- Carcinoma
Ans: A

144- Ovarian CA tumor marker is
A- CEA
B- CA 15-3
C- CA 19-9
D- AFP
E- CA 125
Ans: E

145- A patient with testicular tumor and primitive glomerular structure is most likely
A- Lymphoma
B- Seminoma
C- Embryonal carcinoma
D- Teratoma
Ans: D

146- An Old patient presents with enlarged prostate and there is marked increase in PSA up to 20ng/ml having weight loss MRI done and bony metastasis observed. What is the route of spread of prostate CA to vertebrae?
A- Lumbar plexus
B- Pampiniform plexus
C- Vertebral venous plexus
D- Pelvic plexus
E- Sacral plexus
Ans: C
Explanation:
- CA prostate – Peripheral zone / Posterior lobe + Metastasize to Vertebral column and brain by Anterior Intervertebral venous plexus.
- BPH – Median lobe / Transitional zone

147- Patient presented with testicular mass. It was diagnosed as a yolk sac Tumor. What is follow up marker for this patient?
A- AFP
B- HCG
C- LDH
D- HCG +LDH
Ans: A

148- A female came with her son who presented with one testicle absent. On Examination you found Right testes normal and swelling in left inguinal region. What is the risk
A- Bleeding
B- Infection
C- Atrophy
D- Precursor affect
E- Malignancy
Ans: E

149- A baby presented with enlarge clitoris and sex chromatin positive diagnosis is
A- Ovarian dysgensis
B- Turner syndrome
C- Klinfilter syndrome
D- Congenital adrenal hyperplasia
Ans: D

150- True Hermaphrodite karyotype is
A- XY
B- XO
C- XYY
D- YY
E- XX/XX
Ans: A
Explanation: XX >XX/XY>XXY

151- Which is the Pre eclampsia triggering factor ?
A- Fetal Endothelial dysfunction
B- Fetoplacental circulation compromise
C- Release of factor from placenta
D- Low oxygen
Ans: A

152- 55 year old man with painless testicular swelling and LDH raised what is your diagnosis?
A- Teratoma
B- Choriostoma
C- Lymphoma
D- Mixed tumor
E- Granulosa cell tumor
Ans: C
Explanation:
- Old Age + Painless testicular tumor + Raised LDH – Lymphoma
- Younge Age + Painless testicular tumor + Raised LDH - Seminoma
- Old Age + Painless testicular tumor + Mature Stem cells – Teratoma

153- A patient has complete mole(Hydatiform mole) And grape like appearance on Ultrasound what investigation will be done
A- Increase AFP
B- Increase CEA level
C- Increase beta HCG
D- Low HCG
E- Increase CA 19-9
Ans: C

154- A Girl presented to her physician with concern both her mother and sister died of metastatic breast cancer before 40 year age She is worried about herself which of the following gene is mutated
A- Multiparity
B- APC
C- RAS
D- BRCA-1 Mutation
E- Fibroadenoma
Ans: D

155- Rh -ve mother start developing antibodies against rh +ve baby
A- Last trimster of 1st pregnancy
B- Last trimster of 2nd pregnancy
C- After delivery of 1st baby
D- After confirmation of 2nd pregnancy
Ans: C

156- At birth a baby girl has meconium in her vagina and no anal opening. What type of birth defect does she have?
A- Imperforate anus
B- Imperforate anus with rectoanal fistula
C- Imperforate anus with rectovaginal fistula
D- Rectoanal fistula
E- Rectovaginal fistula
Ans: C

157- Tumour known to secrete excesive estrogen
A- Granulosa theca cell tumour
B- Endometrial CA
C- Cervical CA
D- Cervical Polyp
Ans: A

CamScanner

158- A patient with obstructive azoospermia may have raised
A- IgA
B- IgM
C- IgG
D- IgA
E- IgE
Ans: C

Explanation:
Genitourinary Infection- IgA
Obstructive Azospermia – IgG

159- A 60 years old women is brought with bleeding per vagina. She is diabetic & hypertensive & one year back she was diagnosed as having carcinoma of breast. What can be most probable diagnosis for this bleeding p/v?
A- Carcinoma of colon
B- Carcinoma of endometrium
C- Endometrial metaplasia
D- Carcinoma of cervix
E- Cervical erosion
Ans: B

160- Clear cell tumor of ovary is:
A- Mucous carcinoma
B- Serous carcinoma
C- Theca tumor
D- Granulosa tumor
E- Acinous carcinoma
Ans: B

161- A female patient Delivered a baby Bay has tuft of hairs at back mother was taking diet rich in proteins and carbohydrates but deficient in fruits and vegetables. What is the reason of this condition?
A- Iron deficiency
B- Folic acid deficiency
C- Vitamin B12 deficiency
D- Vitamin K deficiency
E- Vitamin E deficiency
Ans: B

162- A primigravida presented in Labour for 2 hr at -2 station. Ultrasound showed a dead hydrocephalous baby.where would gynaecologist insert the needle to drain the CSF?
A- Anterior fonatanalle
B- Posterior fontanalle
C- Saggital suture
D- Coronal suture
E- Lateral fontanale
Ans: A

163- A 35 years old lady recently lost her husband in a car accident she was psychologically disturbed and developed amenorrhea the most likely cause is
A- Decrease prolactin
B- Increase CRH
C- Decrease dopamine
D- Decrease ACTH
Ans: C

Explanation:
- Dopamine normally inhibit prolactin and control mood when decrease dopamine result in increase prolactin that cause amonorrhea

164- In hydrocele fluid accumulated in
A- Tunica Albugenia
B- Tunica Vaginalis
C- Tunica Media
D- Scrotum
E- Parietal peritoneum
Ans: B

165- Multigravida came with bleeding due to failure of coagulation due to intra uterine fetus death. what is the initial management?
A- Evacuation
B- Heparin
C- Warfarin
D- Coagulation profile
Ans: A

166- 60 year old man with painless testicular swelling, biopsy shows mature stem cells. What is your diagnosis?
A- Teratoma
B- Choriostoma
C- Lymphoma
D- Mixed tumor
E- Granulosa cell tumor
Ans: A

167- Which of the following liver disease is most fatal in pregnancy?
A- Acute viral hepatitis
B- Drug induced hepatitis
C- Fatty liver of pregnancy
D- Intrahepatic cholestatis
E- Obstructed jaundice
Ans: C

168- A pregnant women at 14 week of gestation complaones of hyperemesis gravidarum along with the passage of vesicles and bleeding per vaginally what is your diagonisis?
A- Abortion
B- Ectopic pregnancy
C- GTD
D- Appendicitis
Ans: C

169- After miscarriage female bleed heavily what is best regimen for management
A- Antibiotics, ffp, Packed Rbcs, Evacuation and transmine
B- Heparin, normal saline, packed rbs and platelets and evacuation
C- Transamine, packed rbcs and platelets
D- Dextrose saline
Ans: A

170- 24 year old woman pregnant in second trimester pregnancy terminate, spontaneous abortion occur how many chromosome will be present
A- 69
B- 47
C- 46
D- 23
Ans: A

171- A girl with cyclical lower abdominal pain every month with amenorrhea presented to you.P/a exam normal.Hymen ring normal
A- Didelphys uterus
B- Bicornuate uterus
C- Imperforate hymen
D- Cervical atresia
E- Vaginal septum
Ans: D

Explanation:
- There will be no amenorrhea in Didelphys uterus and bicornuate uterus.
- Hymen ring will be bluish in color in Imperforate hymen.
- Normal hymen ring less likely in Imperforate hymen and vaginal septum.
- Cervical atresia can present with Lower cyclic abdominal pain and amenorrhea with normal hymen ring.

172- During childbirth, if there is a significant decrease in anal tone, what diagnostic test can be used to assess and monitor the anal sphincter function?
A- Ultrasound imaging
B- X-ray examination
C- Magnetic resonance imaging (MRI)
D- Anal manometry
E- Transvaginal scan
Ans: D

173- Boy with sudden increase in height, 2n dary sexual characteristics and enlarge penis with gonadotrophins are normal, lesion of:
A- Leydig cell tumors
B- Pituitary
C- Increase gonadotrophins
D- Hypothalamua
Ans: A

174- A pregnant lady came with premature rupture of membrane she is suspected to have chorioamnionitis. To confirm intra amniotic infection which test should be done?
A- Amniotic fluid culture
B- Cytokine
C- IL 8
D- IL 6
E- TNF
Ans: D

175- Bilateral testes removed will result in
A- Anxiety
B- Lose of libido
C- Increase sex drive
D- Increase testosterone
E- Irritability and hot flashes
Ans: B

176- An Old patient presents with enlarged prostate and there marked weight loss MRI done and bony metastasis and lytic lesion observed. What finding will be there?
A- Increased AFP
B- PSA >11.2
C- Raised Estradiol
D- Increase CEA
Ans: B

177- There is variation in incidence of preeclampsia most significant change in fall of this is due to:
A- Unanimous definition of disease
B- Decrease induction of Labour
C- Decrease edema of pregnant women
D- Fall in maternal and perinatal mortality
Ans: A

178- Band syndrome causes:
A- Oligohydramnios
B- Polyhydramnios
C- Atresia
D- Anencephlay
Ans: A

179- Most common cause of subfertility?
A- Autoimmune
B- Anovulation
C- Premature ovarian failure
D- Low FSH
Ans: B

CamScanner

180- A 24 years old married female having secondary amenorrhea her FSH n LH levels are high, u/s of pelvis doesn't show any abnormality. What can be possible cause?

A- Ovarian tumor
B- Autoimmunity
C- Gonadal failure
D- Dysgerminoma
Ans: C

181- A female Pregnancy got terminated at 20th week now having nipple discharge after procedure this is most likely:

A- Hyperprolactinoma of pregnancy
B- Prolactinoma
C- Drug induced prolactinoma
D- None
Ans: A

182- Old age patient having recurrent UTI PSA 3.5 on DRE enlarged firm prostate this is likely:

A- Pyelonephritis
B- Prostate Adenocarcinoma
C- Urethritis
D- BPH
Ans: B

183- 27 years old woman presented with the complaints of weight gain, menorrhoea and fatigue. Last year, she experienced a complicated delivery requiring a 2units of blood transfusion. She was unable to breastfeed. On examination she has dry skin and hypotension. Which one of the following is the most likely diagnosis?

A- Conn disease
B- Sheehan syndrome
C- Addison syndrome
D- Nelson syndrome
Ans: B

184- Patient at 20 weeks gestation, passing clots and vesicles, what finding will be present?

A- Increase AFP
B- Increase CEA level
C- Increase beta HCG
D- Low HCG
E- Increase CA 19-9
Ans: C

185- Ovarian Cancer first metastasizes to:

A- Another ovary
B- External iliac nodes
C- Uterus
D- Inguinal lymph nodes
E- Paraaortic lymph nodes
Ans: E

186- Progesterone is given to patient what's will be it's complication?

A- Acne
B- Premenstrual tension
C- Swelling
D- Hump
E- Mastalgia
Ans: E

187- After how much time repeated semen analysis should be done

A- 1 month
B- 2month
C- 4 month
B- 2 weeks
Ans: A

188- Indication to start treatment of complete mole?

A- Age above 30
B- Beta HCG>20000
C- Increase B-HCG at first sample
D- No treatment
Ans: B

189- The pathogenesis behind Hydatidiform mole is ?

A- Abnormal trophoblastic proliferation
B- Decrease vascular supply
C- Abnormal conception
D- Karyotyping abnormality
Ans: A

190- A patient presented at 20 weeks of gestation with passage of grape like masses,clots and vesicles.What lab finding will be present?

A- Increased AFP
B- Increased CEA
C- Increased Beta HCG
D- Low Beta HCG
E- Inc CA 19.9
Ans: C

better

191- Female having family history of Hypertension. Her sister also had preeclampsia. What are chances of preeclampsia in primigravida

A- 2.3%
B- 5.7%
C- 12.3%
D- 14.1%
E- 14.5%
Ans: C

better

192- A 65 years old diabetic lady presented with a history of post menopausal bleeding for 7 months. She has been hypertensive for 6 years. She had her menopause 7 years back. Now her endometrial thickness is 15mm. What's your diagnosis?

A- Adenomyosis
B- Endometriosis
C- Simple hyperplasia
D- Cystic hyperplasia
E- Adenocarcinoma
Ans: E

193- Risk to stop Estrogen therapy in postmenopausal female after giving it for 3 years:

A- HTN
B- Migraine
C- DVT
D- Liver Disease
E- Endometriosis
Ans: C

194- A 6 year old girl with axillary and pubic hair and vaginal spotting. There is no development of secondary sexual characteristics. What's the diagnosis?

A- Congenital adrenal hyperplasia
B- Granulosa theca cell tumor
C- Sertoli leydig cell tumor
D- Dermoid cyst
E- Idiopathic Precocious Puberty
Ans: B

195- 16 weeks pregnant lady with ultrasound finding of increased amniotic fluid. She was advised to do Beta HCG and after two weeks AFP. Later on AFP comes out to be raised. What is likely diagnosis

A- Spina bifida occulta
B- Renal ageneis
C- Down syndrome
D- Anencephlay
E- Dextrocardia
Ans: D

196- A 27 year old male having testicular tumor of non seminomatous type lab findings will be

A- PSA
B- Acid phosphatase
C- B-HCG
D- Fructose
F- ALP
Ans: C

Better

197- After vasectomy ductus defrence ligated on upper part of scrotum. Ejaculate after 2 months will contain:

A- Seminal and prostatic fluid
B- Sperms + Seminal Fluid
C- Sperm count decrease
D- Prostatic fluid and sperm only
E- Sperm+Seminal Fluid+Prostatic Fluid
Ans: A

better

198- A young male having scrotal mass and raised LDH probable diagnosis is which of following?

A- Hydrocele
B- Omphocele
C- Testicular lymphoma
D- Seminoma
E- Teratoma
Ans: D

Explanation:

- Old Age + Painless testicular tumor + Raised LDH – Lymphoma
- Old Age + Painless testicular tumor + Mature Stem cells – Teratoma
- Young + Painless testicular tumor + Raised LDH – Seminoma

better

199- A female having curdy white vaginal discharge along with intense itching.I swap sample shows pseudohyohae.Casuative agent?

A- Gonnorhera
B- Syphlis
C- Candida albicans
D- Chlamydia
Ans: C

200- A26 year old healthy woman with regular menstrual cycle was a passenger in bus which met an accident.She was uninjured but her husband and son died in ensuing years her menses ceased and she had frequent nightmares about the accident the most likely reason for her amenorrhea is

A- Decrease CRH secretion
B- Decrease dopamine secretion
C- Increase CRH secretion
D- Increase growth harmone secretion
Ans: B

Explanation:

- Decrease dopamine will cause more prolactin to be released and which will inhibit gnrh this result in amenorrhea

CamScanner

201- After cesarean section, female presented with incontinence and there is a significant decrease in anal tone, what diagnostic test can be used to assess and monitor the anal sphincter function?
A- Ultrasound imaging
B- X-ray examination
C- Magnetic resonance imaging (MRI)
D- Anal manometry
E- Transvaginal scan
Ans: D
Better

202- 40 year female with heavy bleeding since six month on /off, endometrial biopsy shows endometrial hyperplasia cause is:
A- LH
B- FSH
C- Estrogen
D- Progesterone
E- Prolactin
Ans: C

203- Patient came with generalized edema. Urine complete examination reveal Proteinuria. Cause of Edema in Kidney disease is:
A- Portal HTN
B- Low Oncotic Pressure
C- Increase hydrostatic pressure
D- Increase oncotic pressure
Ans: B
Explanation:
- Peripheral edema in CLD due to – Loss of albumin (Low oncotic pressure)
- Ascities in CLD due to – Portal HTN
- Renal origin Edema due to – Loss of albumin (Low oncotic pressure) + Can be salt and water retention.
- Nephrotic syndrome edema due to Hypoalbuminemia
- Nephritic Syndrome edema due to – Salt and water retention
- Pedal edema in CHF and HTN due to – Increase hydrostatic pressure
- In CHF edema worsened by – Sodium and water retention

204- A CSS officer presents with a deranged semen analysis report showing a pH of 7.2, a sperm count of 14 million, and low motility. He is concerned about his results. After what duration should his semen analysis be repeated?
A- Repeat sperm count in 2 weeks
B- In 8 weeks
C- In 12 weeks
D- As soon as possible
E- In 10 weeks
Ans: C

205- Testes develop at:
A- 38 Weeks
B- 26 Weeks
C- 32 Weeks
D- 40 Weeks
Ans: C

206- Sperm synthesis temperature:
A- 28'C
B- 42'C
C- 36'C
D- 20'C
Ans: C

207- A 32-year-old woman presents with irregular periods and is diagnosed with a prolactinoma. What is the most likely cause of her irregular menstrual cycles?
A- Diminished dopamine levels
B- Pressure effects on FSH & LH secretion
C- Suppression of GnRH secretion
D- Increased estrogen levels
Ans: C

208- 34 Years old female patient, Having children, presents with oligomenorrhea. U/S shows Bilaterally enlarged ovaries What other symptoms might this patient exhibit?
A- Increase in estrogen
B- Hirsutism
C- Increased FSH & LH
D- Decreased FSH & LH
E- Prolactinoma
Ans: B(PCOS)

209- A 2 years old child presented with bilaterally undescended testes. Investigation of Choice.
A- MRI
B- CT Scan
C- USG Abdomen
D- Karyotyping
E- Contrast
Ans: C

210- A male patient was presents in OPD, On physical examination he is tall and has small testes and has gynecomastia which of the following investigation will reach the diagnosis
A- Bar body
B- Ultrasound
C- CT scan
D- Karyotyping
E- FSH and LH

211- year old male patient present in surgery OPD with a right inguinal mass On physical examination cough sign was negative , transillunination test was negative and surgeon cannot get above the swelling which is your diagnosis
A- Testicular tumor
B- Hydrocele
C- Hematoecle
D- Inguinal hernia
Ans: A

212- In a twin gestation, one fetus is noted to have significantly lower amniotic fluid index of 3 as (AFI) compared to the other twin who is having AFI of 17. O/E, Symphysio Fundal height is corresponding to 34 weeks. What is the most likely risk?
A- Twin-twin transfusion syndrome (TTTS)
B- Intrauterine growth restriction (IUGR) of the second twin
C- Intrauterine growth restriction (IUGR) of the First twin
D- Oligohydramnions
E- Renal Agenesis
Ans: B

213- An unmarried young woman presents to the ER with heavy menstrual bleeding, severe abdominal pain, and fluid in the pouch of Douglas. On laparoscopy, a brown clot is observed in the ovary. What is the most likely diagnosis?
A- Ruptured ovarian cyst
B- Ruptured ectopic pregnancy
C- Pelvic Inflammatory disease
D- Adenomyosis
Ans: A(Ruptured Endometriotic Cyst)

214- Pregnant woman Presents with Increasing Bp. Investigations reveal Elevated liver Enzymes & Low platelets. Hb was 10g/dL and bilirubin 1.4mg/dL(Normal: 0.1-1.2mg/dL).Diagnosis:
A- HELLP
B- Eclampsia
C- Pre Eclampsia
D- Cholestasis of pregnancy
Ans: A

215- A 30 year old female patient presented in Gynae OPD with vaginal bleeding On ultrasound there was grape like mass diagnose as a case of complete mole through which of the following u will monitor the patient
A- Beta-HCG
B- AFP
C- CBC
D- WBC count
E- Karyotyping
Ans: A

216- Female with 2 kids wants contraception. Failure rate of IUCD is:
A- 2- 5 %
B- 3- 5 %
C- 10%
D- Less than 1%
Ans: D
Explanation:
Intrauterine contraceptives (Cu- IUD, LNG-IUS)
- Last 3–10 years (or more) depending on type, woman's age at insertion.
- Failure rate less than 1 in 100
- Prevent fertilization.
- Impair cervical mucus.
- Inhibit implantation.
Better

217- On In utero study its revealed that there is absent vagina and testes with development of scrotum cause is
A- Increased LH
B- Decreased Testosterone in mother
C- Decreased Estrogen
D- Testosterone producing tumour in mother
Ans: D

218- 6- year-old male child presents with hirsutism and ambiguous genitalia. Laboratory findings reveal elevated urinary 17-ketosteroids and an abnormal XX chromosome karyotype. What is the most likely diagnosis?
A- Congenital Adrenal Hyperplasia
B- Androgen insensitivity syndrome
C- Mixed Gonadal Dysgenesis
D- Fetal aromatase deficiency
Ans: A

219- woman with a family history of ovarian carcinoma in her mother presents with complaints of irregular menstrual periods. A histopathological examination of the ovary is performed. Which type of ovarian follicle is most likely to be observed?
A- Primordial follicle
B- Primary follicle
C- Pre-antral follicle
D- Antral follicle
Ans: A
Explanation:
- Primordial follicles are the most abundant follicles in the ovary, especially in premenopausal women. They remain in a quiescent state until activated during the menstrual cycle.
- In women with irregular periods, hormonal imbalances can disrupt follicular development, leading to a predominance of primordial follicles on histopathological examination

CamScanner

220- A 45-year-old woman presents with abdominal pain and vaginal bleeding. A hysterectomy is performed and shows a benign tumor of the uterus derived from a smooth muscle cell forming spindles on Histology of Endometrium. What is the appropriate diagnosis?

A- Angiomyolipoma
B- Leiomyoma
C- Rhamdomyoma
D- NF1
E- Leimyosarcoma
Ans: B

221- A patient with known histroy of Left sided varicocele having Sperm's motility of 15% & total sperm count is 10 million. Which condition is he suffering from?

A- Azoospermia
B- Oligospermia
C- Asthenoozospermia
D- Teratoazoospermia
Ans: C

Explanation:

- **Asthenozoospermia** refers to reduced sperm motility. In this case, the patient's sperm motility is only 15%, which is significantly lower than normal.
- **Azoospermia**: Refers to the complete absence of sperm in the semen, which is not the case here (sperm count is 10 million).
- **Oligospermia:** Refers to a low sperm count (less than 15 million sperm/mL), and while the sperm count is low in this patient, the defining feature here is poor motility, not just the low count.
- **Teratozoospermia**: Refers to an abnormally high percentage of sperm with abnormal morphology, which is not mentioned in this case

222- A patient had uncomplicated C section with pfannenstiel incision. After 1 week, she presented with fever, hypotension and tenderness. O/E foul smelling discharge from vagina. Investigation reveal normal TLC. Cause is

A- Chorioamniotis
B- Nectrozing fasciitis
C- Septic thrombophlebitis
D- Pelvic hematoma
E- Myxedema peritonei
Ans: A

223- A male presents with infertility. All lab values, including testosterone, LH, and FSH, are normal, while prolactin is borderline raised (28). What is the most likely cause of infertility?

A- Hypogonadotropic hypogonadism
B- Primary hypogonadism
C- Antibodies against testes/testosterone
D- Blockage at the level of vas deferens
E- Hyperprolactinemia
Ans. D

224- A female antenatal patient at 18 weeks of pregnancy presents with intense abdominal pain and tenderness. On examination, Irregular abdominal girth & the fundal height corresponds to 24 weeks. Investigations reveal TLC count of 1500/ul. Urine R/E shows 4 pus cells.What is the most likely cause of her condition?

A- Pregnancy with fibroid
B- Twisted ovarian cyst
C- UTI
D- Acute appendicitis
Ans: A

225- A 25 Years old obese married woman presented with infertility for 2years. On examination hirsutism and acne was present. Labs showed in LH: FSH ratio 3:1 Most common cause of PCOS:

A- Premature ovarian failure
B- Prolactinoma
C- Hypothyroidism
D- PCOS
Ans: D

226- A 14 year old female patient presents in Gynae OPD with cyclical abdominal pain and primary amenorrhea on examination secondary sexual characteristics were well developed and on abdominal examination there was palpable abdominal mass on vaginal examination there was pinkish intact hymen membrane which of following is your diagnosis

A- Didelphys uterus
B- Bicornuate uterus
C- Imperforate hymen
D- Cervical atresia
E- Transverse Vaginal septum
Ans: D

Explanation:
There will be no amenorrhea in.
Didelphys uterus and bicornuate uterus.
Hymen ring will be bluish in color in.
Imperforate hymen.
Normal hymen ring less likely in
Imperforate hymen and vaginal septum.
Cervical atresia can present with Lower cyclic abdominal pain and amenorrhe with normal hymen ring.
Better

227- A 6-hour-old baby boy has been born to primigravida after 8 hours in the 2nd stage of labor and a low APGAR score. He is limp, dusky, and grunting. The profiles of ABGs most likely reflect his clinical condition is:

A- pH - 7.21; PCO2 - 72 mmHg; O2 sat. - 52%; HCO3 - 28 mmol/l
B- pH - 7.23; PCO2 - 42 mmHg; O2 sat. - 55%; HCO3 - 14 mmol/l
C- pH - 7.28; PCO2 - 48 mmHg; O2 sat. - 78%; HCO3 - 17 mmol/l
D- pH - 7.19; PCO2 - 55 mmHg; O2 sat. - 75%; HCO3 - 16 mmol/l
E- pH - 7.43; PCO2 - 40 mmHg; O2 sat. - 92%; HCO3 - 27 mmol/l
Ans: A

Explanation:
This baby is presenting with clinical signs of perinatal asphyxia and respiratory distress, which can result from prolonged second-stage labor and low APGAR scores.
Key points to analyze the ABG profile:

- Low pH (Acidosis): Indicates acidemia, which can occur due to hypoxia and respiratory distress.
- High PCO2 (Respiratory Acidosis): Suggests hypoventilation and CO2 retention.
- Low O2 saturation (Hypoxemia): Consistent with poor oxygenation due to asphyxia and respiratory failure.
- HCO3 (Bicarbonate): Elevated or normal initially, as the kidneys haven't yet compensated for acute respiratory acidosis

228- The female counterpart of seminoma, a common germ cell tumor in males, is(Medicine Feb 2025)

A- Embryonal carcinoma
B- Immature teratoma
C- Dysgerminoma
D- Yolk sac tumor
Ans: C

229- A female patient on hormone replacement therapy (HRT) presents with kidney stones. Which component of HRT is most likely responsible?(Medicine Feb 2025)

A- Estrogen
B- Progesterone
C- Testosterone
D- Cortisol
Ans: A

230- The presence of anti-FSH autoantibodies will lead to a decrease in which parameter? (Medicine Feb 2025)

A- Sperm count
B- Testosterone
C- DHEA
D- LH
Ans: A

231- A 55-year-old woman presents with hot flashes, night sweats, and vaginal dryness. Laboratory tests show elevated FSH levels and an ultrasound reveals atrophic ovaries. What is the most likely diagnosis?(Surgery Feb 2025)

A- Polycystic ovary syndrome (PCOS)
B- Premature ovarian failure
C- Menopause
D- Ovarian cancer
Ans: C

232- Which of the following is cause of increased androgens in PCOs?(Gynae & Obs Feb 2025)

A- Elevated insulin and LH
B- Elevated LH only
C- Estrogen
D- FSH
Ans: A

233- Which of the following is management of women undergoing postpartum haemorrhage after vaginal delivery if her Hb is 6.5g/dl and APTT 35s and PT is 11s (Gynae & Obs Feb 2025)

A- FFP
B- Cryoprecipitate
C- RBC concentrate
D- Whole blood
E- Fresh whole blood
Ans: C

234- 40 years old females presents with bloody discharge from nipples ,no symptom of pruritus on examination of breast no any mass was palpable ,on lab investigation prolactin was normal which of the following is your diagnosis? (Gynae & Obs Feb 2025)

A- Ductal ectasia
B- Intraductal papilloma
C- Fibrocystic breast disease
D- Breast Ca
Ans: B

CamScanner

235- 26 year old female presents with normal menstrual history now presents with Deepening of voice, acne, hirsutism, irregular menses, On abdominal examination right ovarian mass(both compact and cystic components) palpable likely cause is: (Gynae & Obs Feb 2025)

A- Granulosa cell tumour
B- Sertoli leydig cell tumour
C- Pituitary adenoma
D- Serous adenocarcinoma
Ans: B

236- A 13 year old girl with menarche at age 10, now presents with oligomenorrhea and a right ovarian compact mass of about 8 cm, most likely cause is: (Gynae & Obs Feb 2025)

A- Granulosa cell tumour
B Sertoli ledig cell tumour
C- Pituitary adenoma
D- Mature Teratoma
Ans: A

237- A male underwent vasectomy, and he was fine and discharged after 4 days. but he was suggested to use for contraception until? (Gynae & Obs Feb 2025)

A- 8weeks
B- Until surgery scars recovers
C- Until next menstruation period of his partner
D- Until semen is sperm free
E- Until vasogram shows occlusion
Ans: D

238- A 27 year old female patient presents in active labour with 7cm cervical dilation undergoes a manual amniotomy. Shortlyafter the procedure, she develops vaginal bleeding, and the fetal heart rate drops to 100bpm, what is the most appropriate next step in management? (Gynae & Obs Feb 2025)

A- Perform Simpson forceps delivery
B- Apply ventose cup for assisted delivery
C- Observe and wait for fetal heart rate return to 110bpm
D- Proceed with immediate C section
F- Blood transfusion reaction

239- A 28 year old female patient in a labour is exhausted and requires an assisted vaginal delivery which of the following is most important factor in determining the choice of instruments?(Gynae & Obs Feb 2025)

A- Indication, training and experience
B- Maternal consent, training and experience with the instruments
C- Written consent, Training, and experience
D- Experience & Material
Ans: A

240- A postpartum women experiences excessive bleeding, after delivering a normal, healthy placenta. What is the most appropriate initial management? (Gynae & Obs Feb 2025)

A- Bimanual compression
B- Fundal (uterine) massage
C- Empty clots from the uterus and vagina
D- IV access
E- Laproscopy
Ans: B

241- How menopause is defined? (Gynae & Obs Feb 2025)

A- Amenorrhea for 1 year and hot flashes
B- Amenorrhea for 1 year and atrophied ovaries
C- Decreased levels of estrogen and progesterone
D- Increased levels of FSH and LH
Ans: A

242- A 25 years old female patient presents with per vaginal spotting since last night, her urine pregnancy test is positive, on Ultrasound there is a mass adjacent to the ovary what is your diagnosis?(Gynae & Obs Feb 2025)

A- Ovarian Torsion
B- Tubal pregnancy (Ectopic)
C- Ovarian Cyst
D- Pelvic Inflammatory disease
Ans: B

243- A couple is on ovulation induction for 3 months, they want to know the fate of all developing follicles, which of the following best describes their outcome?(Gynae & Obs Feb 2025)

A- Degeneration
B- Atresia
C- Regression
D- Ovulation
Ans: B

244- A woman presents with a complaint of dyspareunia and dry vagina which of the following treatment you will advised her?(Gynae & Obs Feb 2025)

A- HRT
B- use water based or silicon based lubricants during intercourse
C- Topical Estrogen Cream
D- Antibiotics
Ans: B

245- 25yrs old multiparous–woman presented with lower abdominal pain, on histology it showed solid cystic areas intermixed but on Laparoscopy it was semisolid with brown Centre & diagnosed as chocolate cyst. Treatment of Choice:

A- Ascard
B- Clomiphine
C- Danazol (Endometrioma)
D- OCPS
Ans: C

246- Which of the following are male type features in PCOS(Gynae & Obs Feb 2025)

A- Weight gain
B- Acne
C- Obesity
D- Histrutism
Ans: D

247- A pregnant woman diagnosed with IUD fetus and thrombosis what is most appropriate next step in management? (Gynae & Obs Feb 2025)

A- Immediate delivery
B- Start anticoagulation
C- Immediate C section
D- Discharge her and ask her to follow up in next week
Ans: A

248- A 25y old female patient presents with 8 Weeks abortion which of the following hormonal levels are decrease in this patient causing miscarriage? (Gynae & Obs Feb 2025)

A- Progesterone
B- Estrogen
C- FSH
D- LH
E- HCG
Ans: A

249- Onset of puberty is due to: (Gynae & Obs Feb 2025)

A- Sensitivity to estradiol
B- Increased production of gonadotropins
C- Decrease in gonadal hormones
D- FSH
E- LH
Ans: B

250- To distinguish between primary and secondary hypogonadism in a patient with a tumor and decreased testosterone, which parameter is most relevant?(Radiology Feb 2025)

A- Luteinizing hormone (LH)
B- Estradiol
C- Follicle-stimulating hormone (FSH)
D- Prolactin
Ans: A

251- Which of the following is a protective factor against endometrial carcinoma in an obese woman?(Anesthesia Feb 2025)

A- Smoking
B- Polycystic ovary syndrome (PCOS)
C- Late menarche
D- Diabetes
E- Sedentary lifestyle
Ans: C

252- A young man is diagnosed with a testicular tumor. After resection, it was classified as non-seminomatous. Which of the following markers will be elevated? (Anesthesia Feb 2025)

A- ALP (Alkaline Phosphatase)
B- Acid Phosphatase
C- Beta-hCG
D- PSA (Prostate-Specific Antigen)
Ans: C

253- A female patient presents with a feelingof fullness in the lower pelvis/abdomen and is diagnosed with glandular ovarian carcinoma. Histopathological examination reveals that all the tumor tissue has the same microscopic morphology. How would this tumor be classified?"(Anesthesia Feb 2025)

A- Well-differentiated
B- Poorly differentiated
C- Moderately differentiated
D- Undifferentiated
Ans: A

254- A person is taking Oxygen. He will be Exhausted at:

A- 100 oxygen for 24 hrs
B- 100 oxygen for 72 hrs
C- 100 oxygen at 1 ATM
D- 100 oxygen at 760air
Ans: C

CamScanner

DERMATOLOGY QUICK HINTS

- ✓ Most Common Skin CA - BCC
- ✓ BCC occur on Upper Lip
- ✓ BCC shows Palisading pattern
- ✓ SCC occur on Lower lip
- ✓ Most Common BCC type is -Nodular
- ✓ Shaft of Hair composed of - Cortex
- ✓ 26- The distinctive arrangement of collagen fibers in the skin is predominantly found in - Reticular layer
- ✓ In Acanthosis layer effected is -Spinosum
- ✓ After injury layer heal first is - Stratum basale
- ✓ Risk factor of Malignant melanoma is - Sunlight >Xeroderma pigmentosa
- ✓ Melanoma marker – S100
- ✓ Most aggressive cancer – Melanoma
- ✓ Metastasis of melanoma is by - Vertical growth
- ✓ Melanoma invade orbital cavity through – Emissary veins
- ✓ Rarely metastasize - Melanoma
- ✓ Rarely metastasize – BCC
- ✓ Lentigo melanoma – face
- ✓ Nodular melanoma - trunk
- ✓ Lentiginous melanoma – palm and sole
- ✓ Solar lentigo – Liver spot in elderly , Increased melanocytes
- ✓ Most common type of melanoma is - Superficial spreading
- ✓ Lentiginous melanoma – palm and sole
- ✓ Hairy leukoplakia associated with – HIV
- ✓ Lichen planus associated with – HCV
- ✓ PAN is associated with – HBV
- ✓ Most Common Pre-malignant lesion – Leukoplakia
- ✓ Most Lethal Pre-malignant lesion – Erythroplakia
- ✓ Most Common Pre-malignant Condition – Submucosal Fibrosis
- ✓ Most Lethal Pre-malignant Condition - Lichen planus
- ✓ Skin disorder eith IgG antibody against desmosome – Pemphigus vulgaris
- ✓ Lichen planus incidence – 1-10%
- ✓ Lichen planus into malignancy – 10-15%
- ✓ Premalignant Nevus -Dysplastic nevus>congenital nevus>compound nevus>intradermal nevus>junctional nevus
- ✓ Most common nevus in children – Junctional
- ✓ Most common nevus in Adults - Intradermal
- ✓ White patch – Leukoplakia
- ✓ Red patch – Erythroplakia
- ✓ Stevens johnson syndrome – Erythema multiforme involving mouth
- ✓ Macule - Flat lesion with well-circumscribed change in skin color < 1 cm
- ✓ Patch - Macule > 1 cm
- ✓ Papule - Elevated solid skin lesion < 1 cm
- ✓ Plaque - Papule > 1 cm
- ✓ Vesicle - Small fluid-containing blister < 1 cm
- ✓ Bulla - Large fluid-containing blister > 1 cm
- ✓ Pustule - Vesicle containing pus
- ✓ Wheal - Transient smooth papule or plaque
- ✓ Scale - Flaking off of stratum corneum
- ✓ Crust – Dry exudate

Ulcer

- ✓ Curling ulcer by Inhalation burn
- ✓ Cushing Ulcer by Brain injury(Raised ICP)
- ✓ Marjolin Ulcer by External Burn(Squamous cell carcinoma of Skin)
- ✓ Mortorells Ulcer by Hypertension
- ✓ HSV-1 Ulcer - Punched out
- ✓ Edge of tubercles ulcer - Undermined

Venous ulcer

- ✓ Gaiter area (ankle to midcalf)
- ✓ Typically over malleoli

Arterial ulcer

- ✓ Distal toes
- ✓ Anterior shin
- ✓ Pressure points

Neuropathic ulcers

- ✓ Bony prominences (eg, metatarsal heads, heel)

CamScanner

DERMATOLOGY

1- A patient with H/O of 3rd degree burn stratum corneum, spinosum and lucidum acute loss will lead to:
A- Acute water loss
B- Pressure sensation effect
C- Sebum
D- Hair follicle rupture
E- Temperature loss
Ans: A

2- A fire fighter develops blisters on arm with little skin damage, what degree of burn it is?
A- 1st degree
B- 2nd degree
C- 3rd degree
D- 4th degree
E- 5th degree
Ans: B

3- Risk factor for the development of malignant melanoma is
A- Nitrosamine
B- Xeroderma pigmentosa
C- Congenital Navus
D- Lichen Planus
Ans: B

4- A child has bald patch on scalp since birth. which is Leathary. On microscope there is papillomatosis projection's in epidermis. Dermis has abundance of sebaceous glands. What is the serious complication?
A- Basal cell CA
B- Squamous cell CA
C- Keratocanthoma
D- Scaling alopecia
E- Proliferating Trichilemmal Cyst
Ans: A(Sebaceous Nevus Induced)

5- A lady accidentally cut her finger in kitchen she brought to hosp and wound is sutured dr assured her that healing take place which of the following layers heal first?
A- Statum basale
B- Statum Spongiuosm
C- Stratum Lucedium
D- Steatum Granulosum
Ans: A

6- In acanthosis, which layer of oral mucosa is involved?
A- Basal
B- Cornium
C- Spinosum
D- Granulosum
E- Superficialis
Ans: C

7- Marjolin ulcer seen in:
A- Tb
B- Sqeumous cell CA of skin
C- Inhalational burn
D- HTN
Ans: B

Explanation:
- Curling ulcer by – **Inhalation burn**
- Cushing Ulcer by – **Brain injury (Raised ICP)**
- Marjolin Ulcer by – **External Burn (Squamous cell carcinoma of Skin)**
- Mortorells Ulcer by – **Hypertension**

8- Most common skin cell cancer:
A- BCC
B- SCC
C- Actinic keratitis
D- Bowen disease
Ans: A

9- A patient having markely inflamed leisons with clearly demarcated border on right cheek, across the nose and left cheek, these are raised leisons with well demarcated line of differentiation diagnosis:
A- SLE
B- Cellulitis
C- Typical erypsipelas
D- Impetigo
Ans: C

10- A farmer with horn like lesion on forehead due to:
A- Acanthosis
B- BCC
C- Melanoma
D- SCC
Ans: A

11- Which of the following is the Premalignant leisons of oral cavity?
A- Lichen planus
B- Apthous ulcers
C- Leukoplakia
D- Submucosal fibrosis
Ans: C

Explanation:
- Most Common Pre-malignant lesion - **Leukoplakia**
- Most Lethal Pre-malignant lesion - **Erythroplakia**
- Most Common Pre-malignant Condition - **Submucosal Fibrosis**
- Most Lethal Pre-malignant Condition - **Lichen Planus**

12- Most common cause of squamous cell carcinoma?
A- Bowens disease
B- Marjolin ulcer
C- Actinic keratosis
D- Leukoplakia
Ans: A

Explanation:
- Overall Bowen Disease > Actinic Keratosis. But on Cheeks Actinic Keratosis occur and it needs Excision
- So if cheek mention then actinic (Davidson + Goljan)

13- Neoplastic disease associated with all except
A- Dermatomycositis
B- Acanthosis nigricians
C- Necrobiosis lipodica
D- Thrombophelibitis migrans
Ans: C

14- Premalingnat nevus is
A- Compound nevus
B- Intra l nevus.
C- Junctional nevus
D- BCC
Ans: A(as there is no option of dysplastic or congenital giant nevus)

Explanation:
Premalignant Nevus
- Dysplastic nevus>congenital nevus > compound nevus > intradermal nevus > junctional nevus

15- Commonest Malignancy associated with acanthosis nigricians
A- Intestine
B- Stomach
C- Uterus
D- Lungs
E- Breast
Ans: B

16- Which one is most pre-malignant?
A- Compound nevus
B- Intra l nevus
C- Seborrhaic keratosis
D- Dysplastic nevus
Ans: D

Explanation:
Premalignant Nevus
- Dysplastic nevus > congenital nevus > compound nevus > intradermal nevus > junctional nevus

17- Patient has sustained burn that isvery painful with blisters . healing of burn will take place from which layer of skin
A- Basal layer of epidermis
B- Upper dermis
C- Lower dermis
D- Keratinized layer
Ans: A

18- Hairy leukoplakia associated with
A- HIV
B- HBV
C- HCV
D- Leukemia
E- Candidiasis
Ans: A

Explanation:
- Hairy leukoplakia associated with – HIV
- Lichen planus associated with – HCV
- PAN is associated with - HBV

19- First line of defese against microbial agents provided by
A- Skin
B- Blood
C- Blood
D- Bones
Ans: A

20- Lesar trelat sign seen in
A- Suberrhoic keratosis
B- Psoriasis
C- Melanoma
D- Tenia capitis
E- Pyoderma
Ans: A

21- Patient has finger like projections on upper lid , histopathological report showsepithileal cells along with fibrous element , diagnose is ?
A- Papilloma
B- BCC
C- SCC
D- Lichen planus
E- Malignant Melanoma
Ans: A

22- Lichen planus percentage of causing malignant lesion?
A- 1 – 5%
B- 6%
C- 10 – 15%
D- 15 – 20%
E- 20 – 25%
Ans: C

Explanation:
- Lichen planus incidence – 1-10%
- Lichen planus into malignancy – 10-15%

CamScanner

23- Shaft of hair is mainly composed of:
A- Stratum corneum
B- Stratum basale
C- Corneum &basale
D- Cortex of hair
Ans: D

24- The distinctive arrangement of collagen fibers in the skin is predominantly found in:
A- Reticular layer
B- Dermis
C- Hypodermis
D- Papillary Layer
E- Epidermis
Ans: A

25- Melanoma marker
A- S100
B- S200
C- Neurobillin
D- GFAP
E- Vimentin
Ans: A

26- Water proofing of skin is done by
A- Keratin
B- Desmin
C- Vemintin
D- Dextrin
Ans: A

27- Statement true about lichen planus
A- Inflammatory
B- Infectious
C- Benign
D- Pre malignant
Ans: D

28- Slow growing malignant tumor
A- BCC
B- SCC
C- Adenocarcinoma
D- Melanoma
Ans: A

Explanation:
- Melanoma marker – S100
- Most aggressive cancer – Melanoma
- Rarely metastasize – BCC
- Most common skin cell cancer – BCC

29- Wickmann striae are features of
A- Psoriasis
B- Lichen planus
C- Candidiasis
D- Leukoplakia
E- BCC
Ans: B

30- Female with Polyuria , polydipsia , and yellow plaque on leg , diagnosis
A- Erythema nodusum
B- Sarcoidosis
C- Necrobiosis lipodica
D- Suberrhoic keratosis
Ans: C

31- White patch in buccal mucosa indicates:
A- Candidiasis
B- Erythroplakia
C- Submucosal fibrosis
D- Leukoplakia
Ans: D

Explanation:
- White patch – Leukoplakia
- Red patch – Erythroplakia

32- Common premalignant condition:
A- Lichen planus
B- Submucosal fibrosis
C- Leukoplakia
D- Erythroplakia
Ans: B

33- Lentigo melanoma occurs on
A- Face
B- Palm
C- Sole
D- Trunk
Ans: A

Explanation:
- Lentigo melanoma – face
- Nodular melanoma - trunk
- Lentiginous melanoma – palm and sole

34- Commonest cause of premalignant change in mouth in adults
A- Lichen planus
B- Submucosal fibrosis
C- Leukoplakia
D- Erythroplakia
E- Chronic ulcer
Ans: E

35- Patient with Flat lesion with well-circumscribed change in skin color < 1 cm on lips, diagnosis
A- Papule
B- Patch
C- Nodule
D- Plaque
E- Macule
Ans: E

Explanation:
- **Macule** - Flat lesion with well-circumscribed change in skin color < 1 cm
- **Patch** - Macule > 1 cm

- **Papule** - Elevated solid skin lesion < 1 cm
- **Plaque** - Papule > 1 cm
- **Vesicle** - Small fluid-containing blister < 1 cm
- **Bulla** - Large fluid-containing blister > 1 cm
- **Pustule** - Vesicle containing pus
- **Wheal** - Transient smooth papule or plaque
- **Scale** - Flaking off of stratum corneum
- **Crust** - Dry exudate

36- Molluscum conrtagasium cause by
A- Parvo virus
B- Adeno virus
C- Pox virus
D- Papilloma virus
Ans: C

37- Carcinoma which rarely metastasize
A- BCC
B- SCC
C- Melanoma
D- Adenocarcinoma
Ans: A

38- Superficial layer of skin
A- Stratum basale
B- Stratum spinosum
C- Stratum granulosum
D- Stratum lucidum
E- Stratum corneum
Ans: E

Explanation:
Come Let's get sun burn
- stratum corneum
- stratum lucidum
- stratum granulosum
- stratum spinosum
- stratum basale

39- Location Of melanocytes in skin
A- stratum corneum
B- stratum lucidum
C- stratum granulosum
D- stratum spinosum
E- stratum basale
Ans: E

40- Metastasis of melanoma by
A- Vertical growth
B- Horizanta growth
C- Depend on lymphatoc supply of area
D- None
Ans: A

41- Carcinoma shows palisading pattern
A- BCC
B- SCC
C- Melanoma
D- Adenocarcinoma
E- Papilloma
Ans: A

42- Child has multiple itchy popular lesion on the genitalia and fingers . similar lesions seen in younger brother . which of the following is most possible diagnosis
A- Scabies
B- Urticaria
C- Atopic dermatitis
D- Allergic contact dermatitis
Ans: A

43- Most common type of malignant melanoma
A- Superficial spreading
B- Acral leniguous
C- Lentigo melanoma
D- Nodular melanoma
Ans: A

44- Neuropathic ulcers occur in
A- Bony prominences
B- Distal toes
C- Anterior shin
D- Gaiter area
Ans: A

Explanation:
Venous ulcer –
- Gaiter area (ankle to midcalf)
- typically over malleoli

Arterial ulcer –
- Distal toes
- anterior shin
- pressure points

Neuropathic ulcers
- Bony prominences (eg, metatarsal heads, heel)

45- Patient Has Oral SCc with betel nut and pan chewing history, mouth lesion will be:
A- Leukoplakia
B- Erythroplakia
C- Sub mucosal fibrosis
D- Chronic ulcer
E- Basal cell carcinoma
Ans: C

46- UV exposure can cause which of the following?
A- Pulmonary fibrosis
B- Cataract
C- Lung cancer
D- Teratogenesis
Ans: B

CamScanner

47- Cause of edema in burn patient is due to which deficiency
A- Collagen
B- Albumin
C- Gamma globulin
D- Water
E- Dystrophin
Ans: B

48- Most common pre malignant lesion in adults ?
A- Sub mucosal fibrosis
B- Lichan planus
C- Chronic ulcer
D- Epulis
Ans: A

49- Which investigation should be done to differentiate nevus anemicus from segmental hypo melanosis?
A- Pin Prick
B- Wood lamp examination
C- Diascopy
D- Fungal scraping
E- Iodine Test
Ans: C

50- A young boy has Goose bumps due to:
A- Relaxation of erector pilli muscle
B- Contraction of erector pilli muscle
C- Epidermis
D- Eversion of hair follicles
Ans: B

51- Diabetic patient has hot red nodules with multiple site of discharge diagnosis is:
A- Fruncle
B- Carbuncle
C- Fistula
D- Cellulitis
Ans: C

52- A HIV patient develops lesion on skin his sex partner has similar lesions too which of following Skin CA associated with HIV?
A- Lymphoma
B- Kaposi sarcoma
C- Lymphogranuloma verenum
D- Burkitt lymphoma
Ans: B

53- Regarding burn surface:
A- Increase burn receptors on burn surface
B- Decrease burn receptor
C- Increase chloride on surface
D- Increase Discharge of Cations
Ans: A

54- Skin seen on slide regular arrangement of fibers with lipid droplets what is this layer
A- Stratum cornium
B- Stratum Basale
C- Stratum Spinosum
D- Stratum gangrenosum
Ans: C

55- In 90% cases of anthrax where lesion is found in
A- Heart
B- Vessel
C- Hemartoma
D- Skin
E- Lungs
Ans: D

56- In Skin damage which layer of skin will first regenerate:
A- Stratum basale
B- Stratum spinosum
C- Stratum granulosum
D- Stratum lucidum
Ans: A

57- A patient with H/O of 3rd degree Severe burn causing damage to spinosum granulosum and basalis affect will be:
A- Pressure sensation
B- Temperature sensation
C- Pain sensation
D- Cutaneous water loss
E- Errector pillae loss
Ans: D

58- A young medical technician had a history of acute eczematous dermatitis on his hands and wrist by wearing latex gloves. Skin was dry crusted and thickened. Eczematous reaction was cleared after 2 weeks but returned after 72 h back in job and started to grow. This is example of
A- Irritant dermatitis
B- Type I hepersensitivity
C- Type II hepersensitivity
D- Type III hepersensitivity
E- Type IV hepersensitivity contact dermatitis
Ans: E

59- Which skin layer helps in healing after knife injury?
A- Corneum
B- Basale
C- Spinosum
D- Stratum
Ans: B

60- Which of following is most aggressive carcinoma?
A- BCC
B- SCC
C- Melanoma
D- Leukoplakia
E- Lichen planus
Ans: C

Explanation:
- Most common Pre-malignant lesion – Leukoplakia
- Most lethal Pre-malignant lesion – Erythroplakia
- Most common Pre-malignant condition – Sub mucosal Fibrosis
- Most lethal Pre-malignant condition – Lichen planus
- Most aggressive CA – Melanoma

61- An old age shepherd having lesion on forehead involving 2-3 basal layers with acanthosis and atypia what is likely diagnosis: (Medicine Feb 2025)
A- Solar keratosis
B- SCC
C- BCC
D- Pigemented navei
Ans: A

62- Which of the following is the layer of epidermis only found in the Soles and palm(Medicine Feb 2025)
A- Stratum corneum
B- Stratum lucidum
C- Stratum basale
D- Stratum spinosum
E- Stratum granulosum
Ans: B

CamScanner

MEDIPEDIA

- For Online Practice of Mcq Use Medipedia Application From Play Store
- You can search any Mcq in this App on Search bar
- Exam Oriented Pattern of MCQs in this App
- You Can Save Quiz and continue from same MCQ
- Practice Mock Tests on this App

ANATOMY

UPPER LIMB QUICK HINTS

- ✓ Most Common Bone injured in Body – Clavicle
- ✓ Most Common Long Bone Fracture in Body – Clavicle
- ✓ Most Common Long Bone Fracture in Lower Limb – Tibia
- ✓ Most Common Carpal Bone Fracture – Scaphoid (Radial Artery)
- ✓ Most Common Dislocated Carpal Bone – Lunate (Median Nerve - Carpal Tunnel)
- ✓ Fracture of Hook of Hamate – Ulnar Nerve Damage (Cuboidal Tunnel)
- ✓ Anatomical Snuff box Pain – Radial Artery
- ✓ Fracture of Surgical Neck of Humerus – Axillary Nerve Damage
- ✓ Fracture of medial epicondyle – Ulnar Nerve Damage
- ✓ Fracture of Shaft of Humerus – Radia Nerve Damage
- ✓ Wrist Drop – Radial Nerve Damage
- ✓ Anterior Dislocation of Shoulder joint – Axillary Nerve Damage & Post Circumflexartery Damage
- ✓ Quadrangular Space injury -- Axillary Nerve Damage & Post Circumflex artery Damage
- ✓ Small Muscle of Hand supplied by –C8-T1 >Ulnar+Median> T1 > Ulnar
- ✓ Small Muscle of Hand affected lesion in– C8-T1 >Ulnar+Median> T1 >Ulnar
- ✓ Thenar Eminence wasting –Mediannerve lesion
- ✓ Hypothenar Eminence wasting –Ulnarnerve lesion
  - Thumb and index finger drains into infraclavicular nodes
  - Middle , ring and little finger drains into infraclavicular nodes
  - Clavicle receive weight by coracoclavicular joint and transmit to axial sekelton by costoclavicular joint
  - Ulnar nerve lies medial to brachial artrey in upper arm
  - Maximum 2 point discrimination on lips
  - Minimum 2 point discrimination on scapula
  - Minimum 2 point discrimination distance on lips
  - Maximum 2 point discrimination distance on scapula
  - Complete loss of intercostobrachial nerve will cause sensory loss of medial side of arm
  - Palmaris longus crossing superficial to flexor retinaculmn

Ulnar nerve(Musician nerve)

- ✓ Ulnar nerve damage at **Elbow** – Loss of Sensations in medial 1/3rd palmar and dorsalaspect + Hypothenar wasting
- ✓ Ulnar nerve damage at **Wrist** – Claw Hand
- ✓ In fracture of medial epicondyle ,fracture of clavicle and fracture of hook of hamate ulnar nerve is involved
- ✓ All Small muscle of hand wastingwithout lateral sparing -Lesion of C8-T1
- ✓ All Small muscle of hand wasting withlateral sparing -Lesion of Ulnar nerve

Median Nerve(Labourer nerve)

- ✓ Median nerve damage at **Elbow** – Hand of Benedict
- ✓ Median nerve damage at **Wrist** – Carpal tunnel Syndrome (Three and half digit onthumb sensation lost > Thenar muscle wasting)
- ✓ In median nerve damage – Opposition and abduction is not possible(Ape thumb) result in thumb adducted and laterally rotated
- ✓ In Median nerve injury -Patient cannot make fist
  - loss of sensory sensations on lateral palmar surface of hand and unable to flex finger is due to lesion of median nerve
  - carpal tunnel syndrome ,pronator trees syndrome and supracondylar fracture due to lesion of median nerve
  - in dislocation of lunate there is median nerve palsy
  - can't grip the cup of tea due to damage of median nerve

CamScanner

Radial nerve

- ✓ The radial nerve is very commonly damaged in the region of the radial (spiral) groove.
  In Saturday night palsy , midshaft fracture of humerus and fracture of lateral epicondyle radial nerve is involved
  Root of thumb is numb and can't open fist in injuiry of radial nerve

  Unable to extend thumb,metacarpophalangeal joint and thumb . but sensation is intact due to damage of deep branch of radial nerve
  Loss of sensation laterally on dorsum of hand due to injuiry of radial nerve

The common causes of injury are:

- ✓ Intramuscular injections in the arm(triceps)
- ✓ Sleeping in an armchair with the limbhanging by the side of the chair**(Saturday night palsy)** Or Pressure by acrutch (crutch paralysis) and
- ✓ Fractures of the shaft of the humerus
- ✓ This results in the weakness or loss ofpower of extension at the wrist (wristdrop) and sensory loss over a narrowstrip on the back of forearm, and on thelateral side of the dorsum of the hand and Numbness of root of thumb
- ✓ **Superficial terminal branch of theradial nerve** is closely related to theradial artery only in the middle one-thirdof the forearm. In the upper one-third,it is widely separated from the artery,and in the lower one-third it passesbackwards under the tendon of thebrachioradialis
- ✓ **Deep terminal branch (posteriorinterosseous)** soon enters the back ofthe forearm by passing through thesupinator muscle.
- ✓ Abduction of Arm upto 15 Degree – Supraspinatus (Suprascapular Nerve)
- ✓ Abduction of Arm upto 90 Degree – Deltoid (Axillary Nerve)
- ✓ Abduction of Arm Above 90 – Trapezius (Spinal Accessory Nerve) &SerratousAnterior (Long Thoracic Nerve)
- ✓ Scratching of Back – LattismusDorsi (Dorsal Thoracic Nerve)
- ✓ Chief Supinator of Hand -- Bicep Brachi
- ✓ Total Claw Hand – Lumbricals Paralysed
- ✓ Tendon Courses through Shoulder Joint – Long Head Bicep
- ✓ Head of Humerus Supplied by – Arcuate> Anterior Circumfex artery
- ✓ Neck of Humerus Supplied by – Posterior Circumflex artery
- ✓ Trapezius-Spinal Accessory Nerve
- ✓ Serratous Anterior- Long ThoracicNerve
- ✓ Lattismusdorsi – dorsal thoracic nerve(thoracodorsal)
- ✓ Deltoid- Axillary nerve
- ✓ Rhomboid major and minor - Dorsal scapular nerve
- ✓ Levator scapulae - C3 , C4 and Dorsal scapular nerve(C5)
- ✓ Pronation – Median nerve
- ✓ Supination – Musculocutaneous andradial nerv
- ✓ Deep palmar arch formed by Radial artery
- ✓ Superficial palmar arch formed by Ulnar artery
- ✓ Musculocutaneous nerve injury - Loss of Sensation of lateral surface of forearm
- ✓ Axillary nerve injury -Loss of Sensation of lateral surface of arm
- ✓ Main Branch of Subclavian that takes part in Shoulder joint anastomosis –Thyrocervical trunk
- ✓ Direct Branch of Subclavian that takes part in anastomosis around shoulder joint –Dorsal Scapular

Upper Trunk Injury(Erb's paralysis)

- ✓ Waiter tip Hand - Adducted and medially rotated , Extended and pronated

Lower Trunk injury(Klumpke's Paralysis)

- ✓ Horner syndrome
- ✓ Claw hand .

Regarding carpal bones

- Most Common Carpal Bone Fracture – Scaphoid(Radial Artery)
- Most Common Dislocated Carpal Bone – Lunate(Median Nerve- Carpal Tunnel)
- Fracture of Hook of Hamate – Ulnar Nerve Damage (Cubital Tunnel)
- Fracture of scaphoid- radial artrey
- Disclocation of lunate – median nerve palsy

Muscles causing movement of shoulder joint

Medial rotators of shoulder joint

- Subscapularis
- Teres major
- Latissmusdorsi

Lateral rotators of shoulder joint

- Infraspinatous
- Teres minor
- Post fibers of deltoid

Adductors of shoulder joint

- Pectoralis major
- Pectoralis minor
- Teres major and minor

Abductors of shoulder joint

- Suprapinatous muscle
- Muscles fiber of deltoid
- Trapezius

Flexors of shoulder joint

- Anterior fibers of deltoid
- Pectoralis major
- Biceps brachii
- Corachobrachialis

Extensors of shoulder joint

- Posterior fibers of deltoid
- Latissmusdorsi
- Teres minor

Muscles causes movements of forearm

Extensors of forearm at elbow joint

- Triceps
- Anconeus

Flexors of forearm at elbow joint

- Brachialis
- Biceps brachii
- Pronator teres
- Brachioradialis

Supinators of forearm at superior and inferior radioulnar joint

- Biceps brachii
- Supinator

Pronators of forearm at superior and inferior radioulnar joint

- Pronator teres
- Pronator quadratus
- Palmaris longus
- Flexor carpi radialis

CamScanner

Cubital fossa

Boundaries

- **Apex** - directed downwards
- **Base** - imaginaty line joining two epicondyles of humerus
- **Floor** - supinator muscle laterally , brachialis muscle medially
- **Roof** - skin , fascia and bicipital aponeurosis
- **Lateral** -brachioradialis muscle
- **Medial** – pronator teres

Contents from(medial to lateral)

- Median nerve
- Bifurcation of brachial artrey
- Tendon of biceps
- Radial nerve
- Supra tracheal lymph nodes

Joints and their types

- **Shoulder joint** - synovial ball and socket joint
- **Elbow joint** - synovial hinge joint
- **Superior and inferior radioulnar**- synovial pivot joint
- **Wrist joint** - synovial condyloid joint
- **Carpometacarpal joint** - synovial saddle joint
- **Metacarpophalangeal joint** - synovial condyloid joint
- **Interphalangeal** - synovial hinge joint

Breast Lymph

- ✓ Axillary lymph nodes - **75%**
- ✓ Internal thoracic(mammary) or Parasternal - **20%**
- ✓ Posterior intercostal - **5%**
- ✓ Axillary lymph node include Anterior or pectoral (Mainly), posterior, central, apical and lateral
- ✓ Sequence of **major** lymph node parallel along which vessel -- **Anterior axillary to pectoral**
- ✓ Sequence of lymph node parallel along which vessel -**Internal thoracic**
- ✓ **Nipple drainge -- Ant. axillary (Pectoral)**
- ✓ **Upper lateral -- Ant. axillary mainly**
- ✓ **Lower lateral(Inferior) -- Ant. axillary + Sub diaphragmatic + Internal mammary.**
- ✓ **Medial Quadrant** -- Mainly to **Internal mammary (Internal thoracic)**
- ✓ **Lower Inner Medial Quadrant – Inferior Phrenic (Sub Diaphragmatic)**
- ✓ **Tail of Breast – Posterior (Scapular) Lymph Node**
- ✓ **Path** of Axillary lymph flow --**Anterior and posterior**
- ✓ **Quadrant** of Breast Lymph -- **Medial and lateral**

Humerus Fracture

- ✓ Dislocation of Shoulder Joint – Axillarynerve
- ✓ Fracture anatomical neck of humerus –Radial nerve
- ✓ Fracture surgical neck of humerus –Axillary nerve and posterior circumflexhumeral artery
- ✓ Fracture shaft of humerus – Radial nerveand profunda brachii artery.
- ✓ Fracture medial epicondyle of humerus –Ulnar nerve and ulnar collateral artery.
- ✓ Supracondylar fracture of humerus –Median nerve and brachial artery.

UPPER LIMB

1- Laceration of thumb first node involved:

A- Supraclavicular
A- Infraclavicular
B- Axillary
C- Lateral axillary
D-

Ans: B

Explanation:

- Thumb and index finger drains into – Infraclavicular lymph nodes.
- Middle/ring/little finger drains into – Supraclavicular lymph nodes.

2- A patient with loss of flexion and supination nerve damaged is:

A- Musculocutaneous
B- Axillary
C- Radial
D- Median
E- Accessory

Ans: A

Explanation:

- Muculoctanous and radial forsupination.
- Median for pronation

3- Old lady cant grip cup of tea this is due to damage of which nerve?

A- Median nerve
B- Radial nerve
C- Ulnar nerve
D- Axillary nerve
E- Suprascapular nerve

Ans: A

4- Small muscle of hands supplied by which of the following?

A- C8
B- T1
C- T2
D- C6
E- C5

Ans: B

Explanation:

- Small Muscle of Hand supplied by – C8-T1 >Ulnar+Median> T1 > Ulnar
- Small Muscle of Hand affected lesion in – C8-T1 >Ulnar+Median> T1 >Ulnar
- Thenar Eminence wasting -Median nerve lesion
- Hypothenar Eminence wasting -Ulnar nerve lesion
- All Small muscle of hand wasting **without lateral sparing** -Lesion of C8-T1
- All Small muscle of hand wasting **with lateral sparing** -Lesion of Ulnar nerve

5- Man lifted heavy weight sudden pain in arm, on examination swelling inupper forearm of the muscle which is attached to radial tuberosity?

A- Biceps brachi
B- Brachioradialis
C- Anconeus
D- Supinator
E- Pronator

Ans: A

6- Medial longitudinal arch is supported by

A- Deltoid ligament
B- Lateral calcanocavicular ligament
C- Femoral ligamnet
D- Lateral meniscus ligament

Ans: A

7- Ulner nerve damaged at medial epicondyle.Which muscle will be effected?

A- Flexor pollicuslongus
B- Medial 2 lumbricals
C- Openenspollicus
D- All

Ans: B(BD)

Explanation:

- Ulnar nerve damage at Elbow – Loss ofSensations in medial 1/3rd palmar anddorsal aspect + Hypothenar wasting
- Ulnar nerve damage at Wrist – ClawHand
- Median nerve damage at Elbow – Handof Benedict
- Median nerve damage at Wrist – Carpaltunnel Syndrome

8- Patient can't perform supination of arm. Nerves of supination include:

A- Radial Nerve
B- Median Nerve
C- Musculocutaneous +Radial
D- Medial + Radial
E- Median

Ans: C

Explanation:

- Muculoctanous and radial for supination.
- Median for pronation

9- Following part of the brachial plexus has branches that supply the extensor muscles of the arm:

A- Lateral cord
B- Medial cord
C- Lateral & medial cords
D- Thoracodorsal
E- Posterior Cord

Ans: E

CamScanner

10- Which nerve runs along the radial artery in forearm?
A- Median nerve
B- Anterior interrosseus nerve
C- Deep branch of radial nerve
D- Superficial radial nerve
E- Ulnar nerve
Ans: D(BD)

Explanation:
- **Superficial terminal branch** of the radial nerve is closely related to the radial artery only in the middleone-third of the forearm. In the upper one-third, it is widely separated from the artery, and in the lower one-third it passes backwards under the tendon of the brachioradialis
- **Deep terminal branch (posterior interosseous)** soon enters the back of the forearm by passing through the supinator muscle

11- Common site of clavicle fracture is:
A- Medial 1/3rd and lateral 2/3rd
B- Lateral 1/3rd and medial 2/3rd
C- Mid of clavicle
D- Upper clavicle
E- Lower clavicle
Ans: B

12- Rotator cuff muscles include:
A- Deltoid, Supraspinatus,infraspinatus
B- Bicep, Supraspinatus, subscapularis, teres minor
C- Supraspinatus, Infraspinatus, Teres minor and Subscapularis
D- Subscapularis, Deltoid, Teres minor
Ans: C

13- Wrist joint is an example of:
A- Condylar type
B- Sadle type
C- Fibrous type
D- Plane type
E- Hinge joint
Ans: A

Explanation
- **Shoulder joint** - synovial ball and socket joint
- **Elbow joint** - synovial hinge joint
- **Superior and inferior radioulnar**- synovial pivot joint
- **Wrist joint** - synovial condyloid joint
- **Carpometacarpal joint** - synovial saddle joint
- **Metacarpophalangeal joint** - synovial condyloid joint
- **Interphalangeal** - synovial hinge joint

14- A women presented with whiplash injury during RTA resulting in damage to C5 and C6.Which function is affected most likely?
A- Extension of arm
B- Flexion of forearm
C- Abduction of shoulder
D- Adduction of shoulder
Ans: B

15- A patient had fracture of humerus.Now cannot raise his arm above shoulder and sensory loss on lateral surface of arm along with loss of abduction of arm. Which nerve is damaged?
A- Median nerve and Axillary
B- Radial nerve
C- Axillary and Suprascapular nerve
D- Ulnar nerve
E- Musculocutanous nerve
Ans: C

16- Deep injury in radial groove, which movement will be affected?
A- Abduction of fingers
B- Loss of sensation on the ventral part of lower thumb
C- Loss of extension of wrist resulting in wrist drop
D- Flexion of wrist
Ans: C

17- Which structures are damaged superficial to flexor retinaculum?
A- Flexor digitorum superficialis and ulnar artery
B- Ulnar nerve and ulnar artery
C- Median nerve
D- Musculocutaneous nerve
E- Radial nerve
Ans: B

18- Triceps muscles are innervated via which of the following nerve?
A- Axillary nerve
B- Thoracodorsal nerve
C- Radial nerve
D- Median nerve
E- Ulnar nerve
Ans: C

19- A young man was thrown off his motorcycle in a traffic accident.He landed on his shoulder.O/E, his arm was hanging by his side and he had lost sensations on the lateral aspect of arm. The most likely damaged structure is:
A- Axillary
B- Lateral pectoral
C- Dorsal and ventral root C5 and C6
D- Lower brachial plexus
E- Medial pectoral nerve
Ans: A

20- After mastectomy for breast carcinoma female developed winging of scapula, which is due to damage to
A- Axillary nerve damage
B- Long thoracic nerve damage
C- Radial nerve
D- Spinal Accessory nerve
E- Thorocodorsal nerve
Ans: B (BD+Grey's Anatomy)

Explanation:
- Because the long thoracic nerve passes down the lateral thoracic wall on the external surface of the Serratous anterior muscle, just deep to skin and subcutaneous fascia, It is vulnerable to damage. Loss of function of this muscle causes the inferior angle of scapula to elevate from the thoracic wall, resulting in characteristic - Winging of scapula
- **Trapezius** – Spinal accessory nerve
- **Serratous Anterior** – Long thoracic nerve
- **LattismusDorsi** – Dorsal thoracic nerve
- **Deltoid** – Axillary nerve

21- A patient had RTA, doctor found his dislocated shoulder joint. Which of the following nerve is likely to be damaged?
A- Median
B- Brachial pluxes
C- Musculocutaneos nerve
D- Ulnar nerve
E- Axillary nerve
Ans: E (KLM +BD)

22- A patient whose main trunk of radial nerve is damaged will present with:
A- Finger drop
B- Ok sign
C- Wrist drop
D- Loss of sensation over medial 2 ½ fingers
E- Loss of arm sensation
Ans: C

23- After RTA, a patient has Surgical neck of humerus fractured with loss of abduction and loss of sensation over proximal part of lateral arm. Which nerve is damaged?
A- Musculocutaneous nerve
B- Radial nerve
C- Axillary nerve
D- Median nerve
E- Ulnar nerve
Ans: C

Explanation:
- Dislocation of shoulder joint – Axillarynerve
- Fracture anatomical neck of humerus– Radial nerve
- Fracture surgical neck of humerus – Axillary nerve and posterior circumflexhumeral artery.
- Fracture shaft of humerus – Radialnerve and profunda brachii artery
- Fracture medial epicondyle of humerus– Ulnar nerve and ulnar collateralartery
- Supracondylar fracture of humerus – Median nerve and brachial artery

24- Radial nerve lies in:
A- Spiral groove of humerus
B- Front of medial epicondyle
C- Front of flexor retinaculum
D- Front of lateral epicondyle
E- Front of bicep tendon
Ans: A

25- All Interossei of hand supplied by which of the following nerve?
A- Median
B- Radial
C- Deep radial nerve
D- Deep ulnar nerve
E- Deep median nerve
Ans: D

26- A Young female complaining of numbness and paresthesia along with color changes in her left arm. There is no wasting of the interossei but altered sensation in the T1 distribution due to which of the following:
A- Raynaud's phenomenon
B- Osteoporosis of cervical spine
C- Pectusexcavitum
D- Spinal stenosis
E- Cervical Rib
Ans: E

27- Medial half of the breast drains into which lymph node group?
A- Anterior axillary
B- Internal thoracic group of lymph nodes
C- Supra clavicular lymph nodes
D- Medial and lateral axillary
E- Diaphragmatic
Ans: B(BD + KLM)

28- Breast upper lateral drainage:
A- Internal thoracic
B- Axillary
C- Deep cervical
D- Sub diaphragmatic
E- Inferior phrenic
Ans: B (KLM+BD)

CamScanner

29- Clavicle transmits weight to axial skeleton via:

a) Coracoclavicular ligament
b) Costoclavicular ligament
c) Sternoclavicular ligament
d) All

Ans: B

Explanation: Clavicle **Receive** weight of via Coracoclavicular ligament and **Transmit** to axial skeleton via Costoclavicular ligament.

30- Person having trauma, weakness of tricep muscle and loss of tricep jerk. Damaged area:

A- C4-5
B- C5-C6
C- C6
D- C6-T1

Ans: D (Radial Nerve)

31- A nerve is cut distal to head of radius bone result in loss of Extension at metacarpophalangeal joint and loss of abduction of thumb with no sensation loss. Which nerve is damaged?

A- Radial nerve
B- Deep branch of radial nerve
C- Ulnar nerve
D- Median nerve

Ans: B

32- Major breast lymph nodes parallel to:

A- Along axillary vessels to Pectoral nodes
B- Along intercostal vessels to posterior thoracic nodes
C- Along Apical Nodes
D- None of these

Ans: A

Explanation:

- Sequence of major lymph node parallel along which vessel – Anterior axillary to pectoral.
- Sequence of lymph node parallel along which vessel – Internal thoracic.
- Nipple drainage – Ant. axillary (Pectoral).
- Path of Axillary lymph flow – Anterior and posterior.
- Quadrant of Breast Lymph – Medial and lateral.

33- A 33 years young gentleman presented in orthopedic OPD with injury to shoulder region in a fall from 4 feet height, on x ray the joint is perfectly fine but on examination the patient cannot abduct his arm initially till 30 degree and after 30 degree passive movement by the surgeon,the patient is able to move his arm over the head.The likely muscle damaged is:

A- Deltoid
B- Serratus anterior
C- Trapezius
D- Supraspinatus
E- Teres major

Ans: D

34- A patient After middle clavicular fracture is unable to perform lateral rotation of arm, due to damage of which muscle?

A- Pectoralis major
B- Teres minor
C- Latissimus dorsi
D- Trepezius
E- Bicep brachi

Ans: B

35- Extensor carpi ulnaris supplied by:

A- Median nerve
B- Ulnar nerve
C- Anterior interosseous nerve
D- Posterior interosseous nerve
E- Axillar nerve

Ans: D

36- Female presented with CA breast. Mastectomy done.After removing fascia , Mucle also removed.Which of the following movement will be affected?

A- Abduction
B- Adduction
C- External rotation of scapula
D- Upward movement of First rib

Ans: C

37- Which of the following statement regarding ulnar nerve is true?

A- Ulnar nerve lies deep to flexor ratinaculum
B- Its lies medial to brachial artery in upper arm
C- It lies opposite spiral groove
D- Lies lateral to brachial artery

Ans: B

38- A patient has finger defect.On exam, sensory loss of dorsum of the thumb due to injury to which nerve?

A- Median
B- Radial
C- Musculocutaneous
D- Ulnar
E- Axillary

Ans: B

39- Pectoralis minor is not functioning due to damage of which of the following?

A- Upper Ribs
B- Medial end of Clavicle
C- Angle of Ribs
D- Coracoid Process of Scapula

Ans: D

Explanation:

- Origin – 3-5 Ribs
- Insertion – Coracoid process of scapula

40- Lateral cord of brachial plexus formed by which of the following?

A- One posterior division
B- One lateral division
C- Two anterior divisions
D- Two medial divisions

Ans: C

Explanation:

- **Lateral Cord** – Anterior division of upper and middle trunk
- **Medial Cord** – Anterior division of lower trunk
- **Posterior Cord** – Posterior division of middle and lower trunk

41- Pectoralis major flap will get blood supply from which of following?

A- Intercostal arteries
B- Thoracoacromial
C- Axillary artery
D- Thoracodorsal

Ans: B

42- Complete loss of intercostobrachial nerve will cause:

A- Sensory loss of medial side of arm
B- Sensory loss of 2nd ICS
C- Loss of preganglionic sympathatic
D- Loss of sweating on posterior side of arm

Ans: A

42- Ulnar nerve damage at medial epicondyle will cause:

A- Adductor pollicis damage
B- Little and ring finger claw
C- Abductor pollicis damage
D- Cubits varus

Ans: A

43- Acromioclavicular joint blood supply is:

A- Axillary artery
B- Infrascapular artery
C- Suprascapular and thoracoacromial artery
D- Axillary and acromial artery

Ans: C

44- A patient in road accident got injured on cervical vertebrae having Diminished triceps reflex and atrophy of muscle is due to spinal disc herniation at which of following site:

A- C2-3
B- C5-6
C- C6-7
D- L4-5
E- C8-T1

Ans: C

45- In shaft of humerus fracture,which artery and nerve will be injured?

A- Profundabrachi artery + Radial nerve
B- Brachial artery +Radial nerve
C- Radial artery +Median nerve
D- Ulnar arterty +Ulnar nerve

Ans: A

46- A patient is unable to extend his metacarpophalyngeal joint, abduct and extend his thumb, sensation is intact, which nerve is damage?

A- Radial nerve
B- Post interosseous nerve
C- Ulnar nerve
D- Median nerve
E- Musculocutaneous nerve

Ans: B

47- Anterior Interosseus Nerve is the branch of:

A Axillary Nerve
B Radial Nerve
C Median Nerve
D Musculocutaneous Nerve
E Ulnar Nerve

Ans: C

Explanation:

- Anterior Interosseus Nerve is the branch of Median Nerve
- Posterior Interosseus Nerve is the branch of Radial Nerve

48- Lymphatic drainage of medial quadrant of breast:

A- Axillary
B- Pectoral
C- Internal mammary
D- Sub diaphragmatic

Ans: C

CamScanner

49- Commonly fractured bone in hand:
A- Lunate
B- Hamate
C- Scaphoid
D- Radius
Ans: C

Explanation:
- Most Common Bone injured in Body – Clavicle
- Most Common Long Bone Fracture in Body – Clavicle
- Most Common Long Bone Fracture in Lower Limb – Tibia
- Most Common Carpal Bone Fracture – Scaphoid(Radial Artery)
- Most Common Dislocated Carpal Bone – Lunate(Median Nerve- Carpal
- Tunnel)
- Fracture of Hook of Hamate – Ulnar Nerve Damage (Cubital Tunnel)
- Anatomical Snuff box Pain – Radial Artery

50- Injury to Radial nerve at wrist leads to:
A- Wrist drop
B- Sensory loss on dorsal side of finger
C- Paralysis of adductor pollicis
D- Loss of supunation in extended position
Ans: B

51- Radial Pulse is palpated between which tendons?
A- Abductor Pollicis brevis & Longus
B- Abductor Pollicis Longus & Extensor Pollicis Longus
C- Adductor longus & Abductor Brevis
D- Abductor brevis & Flexor Tendon
Ans: B

52- Injury to lunate will damage:
A- Radial Nerve
B- Radial artery
C- Median nerve
D- Ulnar artery
Ans: C

Explanation:
Hook of hamate fracture – ulnar nerve palsy
Dislocation of lunate – median nerve palsy
Fracture of scaphoid – radial artery

53- Lateral Palmar Sensation lost &flexion of Index Finger lost in damage of:
A- Radial Nerve
B- Median Nerve
C- Ulnar Nerve
D- Axillary Nerve
Ans: B

Explanation:
- Lateral side of Palm sensation is Carried by median nerve along with flexion of index finger mainly by Median nerve through its supply to FDP & FDS

54- Fracture of Pisiform bone leads to damage to:
A- Radial artrey
B- Median nerve
C- Ulnar nerve
D- Radial nerve
Ans: C

55- Nerves involved in fracture of Humerus:
A- Radial, Ulnar, Median
B- Axillary, Ulnar, Median
C- Axillary, Radial, Ulnar
D- Axillary, Radial, Musculocutaneous
Ans: C

56- Common direction of shoulder joint dislocation:
A- Superior
B- Inferior
C- Anterior
D- Medial
Ans: C

57- Obese lady presented with myxedema.She is at risk of:
A- Fracture
B- Osteoporosis
C- Carpal tunnel syndrome
D- Tarsal Tunnel Syndrome
Ans: C

Explanation
- Carpal tunnel syndrome is commonly seen in pregnancy followed by myxedema.

58- Ulnar nerve injured at medial epicondyle will cause:
A- Hypothenar Wasting
B- Claw hand
C- Cubitus Varus
D- Cubitus Valgus
Ans: A

Explanation:
- Ulnar nerve damaged at elbow that's medial epicondyle level will lead to hypothenar wasting.
- Ulnar nerve damaged at wrist level will lead to claw hand.

59- Median nerve injury leads to:
A- Thenar wasting
B- Hypothenar wasting
C- Claw Hand
D- Carpal tunnel syndrome
Ans: A

Explanation
- Ulnar nerve damage at Elbow – Loss of Sensations in medial 1/3rd palmar and dorsal aspect + Hypothenar wasting
- Ulnar nerve damage at Wrist – Claw Hand
- Median nerve damage at Elbow – Hand of Benedict
- Median nerve damage at Wrist –Carpal tunnel Syndrome

60- Palpable lymph nodes in pectoral part of axillary nodes are most likely:
A- Upper outer quadrant breast
B- Medial quadrant breast
C- Whole breast
D- None
Ans: A

61 Numbness of the thumb is due to involvement of which dermatome?
A- C3
B- C4
C- C5
D- C6
E- T1
Ans: D

62- Winging of scapula due to damage to which nerve?
A- Long thoracic nerve
B- Accessory Nerve
C- Hypoglossal Nerve
D- Suprascapular Nerve
Ans: A

Explanation:
- Long thoracic nerve C5 C6 C7 , supply to serratus anterior

63- Lymphedema in hand after mastectomy Due to:
A- Vascular Invasion
B- Lymphatic Obstruction
C- Viral Infection
D- Pyogenic Condition
Ans: B

64- Lateral cord of brachial plexus supplies which of the following muscle?
A- Biceps Brachii
B- Deltoid
C- Serratus Anterior
D- Diaphragm
Ans: A

Explanation:
- The lateral cord of brachial plexus is made by confluences of anterior division of upper & middle trunk of brachial plexus and musculocutaneous nerve one of its branch supplies bicep brachii.

65- Dermatome supply of lateral hand:
A- T1
B- C8
C- C6
D- C7
Ans: C (RJ Last)

Explanation:
Dermatome levels
- C1 no skin supply
- C2 occipital region
- C3 neck
- C4 infraclavicular
- C5 lateral arm
- C6 lateral forearm and thumb
- C7 middle finger
- C8 little finger and distal medial forearm
- T1 T2 medial arm above and above elbow
- T3 thorax
- T4 nipple
- T7 subcoastal angle
- T8 rib margin
- T10 umblicus
- T12 lower abdomen
- L1 suprapubic and inguinal regions , upper buttock , penis
- L2 anteior thigh
- L3 anterior and medial thigh , knee
- L4 medial leg , medial ankle
- L5 lateral leg , dorsum of foot
- S1 lateral ankle
- S2 posterior leg , posterior thigh
- S3 sitting area of scrotum
- S4 perianal
- S5 behind anus and over coccyx

66- Small Hand muscles are supplied by:
A. Radial nerve
B. Ulnar Nerve
C. Median Nerve
D. Axillary Nerve
Ans: B

Explanation:
- Small Muscle of Hand supplied by – C8-T1 >Ulnar+Median> T1 > Ulnar
- Small Muscle of Hand affected lesion in – C8-T1 >Ulnar+Median> T1 >Ulnar
- Thenar Eminence wasting -Median nerve lesion
- Hypothenar Eminence wasting -Ulnar nerve lesion
- All Small muscle of hand wasting **without lateral sparing** -Lesion of C8-T1
- All Small muscle of hand wasting **with lateral sparing** -Lesion of Ulnar nerve

67- Opponens Pollicis is supplied by:
A- Axillary nerve
B- Median nerve
C- Ulnar nerve
D- Radial nerve
E- Musculocutaneous nerve
Ans: B

CamScanner

Explanation:
Branches in forearm
- Muscular branches - supplies pronator teres , flexor carpi radialis , palmaris longus and flexor digitorum superficialis muscle
- Articular branches- elbow joint
- Anterior interosseus nerve - flexor pollicis longus , pronator quadratus , lateral half of flexor digitorumprofundus , articular branches to wrist and carpal joints
- Palmar branch - skin over the lateral part of palm

Branchesin palm
- Muscular branches- abductor pollicis brevis , flexor pollicisbrevis , opponespollicis , 1st and 2nd lumbriclas
- Cutaneous branches - palmar aspect of lateral three and half fingers and distal half of dorsal aspect of each finger

68- A patient can't abduct & Adduct his fingers is due to damage of which of the following nerve:
A. Ulnar Nerve
B. Median nerve
C. Radial Nerve
D. Axillary Nerve
Ans: A

Explanation:
- Both DAB: Dorsal interosseous causing abdution& PAD: Palmar interoseous causing adduction are supplied by deep branch of the ulnar nerve.

69- A patient had RTA & Presented with difficulty in arm Abduction. Which of the following rotator cuff muscle is frequently damaged?
A- Suprapinatous
B- Infraspinatus
C- Teres major
D- Teres minor
E- Subscapularis
Ans : A

70- 1st and 2nd lumbricals are supplied by:
A- Median nerve
B- Ulnar nerve
C- Axillary nerve
D- Radial nerve
Ans: A

Explanation :
- 1st and 2nd lumbricals - median nerve
- 3rd and 4th lumbricals - deep branch of ulnar nerve

71- Breast Lateral Lymphatic drainage:
A. Pectoral (Axillary) Lymph Nodes
B. Posterior Axillary Lymph Nodes
C. Internal Thoracic Lymph Nodes
D. Supraclavicular Lymph Nodes
E. Infraclavicular Lymph Nodes
Ans: A

Explanation:
- Lateral lymphatic drainage of breast is mainly to pectoral lymph nodes & medical to internal thoracic lymph nodes.

72- Carpometacarpal joint is:
A- Hinge joint
B- Ball and socket joint
C- Saddle joint
D- Pivot joint
E- Condyloid joint
Ans: C

Explanation:
Joints of hand type
- **Shoulder joint** - synovial ball and socket joint
- **Elbow joint** - synovial hinge joint
- **Superior and inferior radioulnar** - synovial pivot joint
- **Wrist joint** - synovial condyloid joint
- **Carpometacarpal joint** - synovial saddle joint
- **Metacarpophalangeal joint** - synovial condyloid joint
- **Interphalangeal** - synovial hinge joint

73- Rhomboids are supplied by:
A- Axillary nerve
B- Infrascapular
C- Suprascapular
D- Subscapular
E- Dorsal scapular nerve
Ans: E

74- Humeral surgical neck fracture leads to damage to which artrey?
A- Profundabrachiiartrey
B- Anterior circumflex artrey
C- Posterior circumflex artrey
D- Brachial artrey
E- Axillary artrey
Ans: C

75- Lateral cord of brachial plexus supplies which of the following muscle:
A- Pectoralis major
B- Deltoid
C- Serratus Anterior
D- Intercostal muscle
Ans: A

76- Pectoralis major muscle action:
A- Adducts the arm
A- Adducts and rotate medially
B- Adducts, rotates medially and flexes the arm
C- Extensor of forearm
D- C
Ans:

77- Bicep brachi supplied by:
A. Radial nerve
A. Median nerve
B. Ulnar nerve
C. Musculocutaneous nerve
D. D
Ans:

78- Which of the following muscles transverses the shoulder joint:
A. Short head of bicep
B. Long head of bicep
C. Deltoid
D. Trapezious
Ans: B

79- A 26 years old female diagnosed case of myxedema presented with loss of sensations in thumb, wasting of thinner eminence, which of the followings is associated with his condition?
A- Cubital tunnel syndrome
B- Carpel tunnel syndrome
C- Ulnar nerve compression
D- Cervical rib
Ans: B

Explanation
- Burning, tingling, or itching numbness in your palm and thumb or index and middle fingers
- Weakness in hand and trouble holding things
- Shock-like feelings that move into fingers
- Tingling that moves up in arm

80- Which of the following is present in axilla:
A- Cords
B- Trunks
C- Roots
D- Divisions
Ans: A

81- Lymphatic's from the breast mostly goes to the axilla, involves which groups of axillary nodes:
A- Medial+lateral
B- Apical+medial
C- Superior+inferior
D- Anterior+inferior
Ans: A

82- Small Muscle of hands are supplied by:
A- Ulnar Nerve
B- Median Nerve
C- Radial Nerve
D- C8 -T1
Ans: D

Explanation:
- Small Muscle of Hand supplied by – C8-T1 >Ulnar+Median> T1 > Ulnar

83- Which of the following are flexors of metacarpophalangeal joints?
A- Interosseous
B- Lumbricals
C- Digitorium Superficial is
D- Biceps
Ans: B

84- A shoulder separation that involves the lateral end of the clavicle sliding onto the superior aspect of acromion would likely result from damage to:
A- Coaracoacromial ligament
B- Coracoclavicular ligament
C- Costoclavicular ligament
D- Manubrosternal ligament
Ans: B(Snell)

85- Which of the following helps in rotation of radio-ulnar joint?
A- Bicep
B- Tricep
C- Pronator teres & Supinator
D- Brachioradialis
Ans: C

86- Carpal tunnel syndrome causes:
A- Wasting of thenar eminence
B- Loss of sensation on lateral aspect of hand
C- Loss of sensation on medial aspect of hand
D- Loss of sensation on dorsal aspect of hand
Ans: B

87- Small muscles of hand & medial palmar surface of hand affected & Lateral part of thenar is spared.Which of the following nerve is damaged:
A- Median Nerve
B- Radian nerve
C- Ulnar Nerve
D- C8-T1
Ans: C

Explanation:
- As Medial side of the hand is affected & lateral side isn't effected the most likely nerve damaged is Ulnar nerve.

CamScanner

88- Median nerve is damaged.Which of the following function of thumb will be lost?
A- Extension
B- Opposition
C- Rotation
D- Adduction
Ans: B

Explanation:
- Opponenspollicis is a small muscle of hand that's act in opposition of the thumb & is supplied by recurrent branch of median nerve.

89- Supinator muscle damaged.Which of the following muscle is alternate muscle of supination:
A- Bicep
B- Tricep
C- Flexor Digitorium
D- Abductor pollicis
Ans: A

Explanation
Supinator of forearm
- Biceps brachii (chief)
- Supinator

90- A patient climbed a peak with a heavy bag on his shoulder after that he developed loss of adduction of arm with loss of flexion at elbow & loss of extension at wrist. Most likely damage occurs to which of the following?
A- Radial Nerve
B- Musculocutaneous nerve
C- Axillary Nerve
D- Upper Part of brachial plexus
Ans: D

Explanation:
- This is the case of Erb's Palsy (waiter's tip) resulted from traction or tear of upper trunk of brachial plexus (C5,C6) resulted in loss of abduction, lateral rotation, flexion & supination of arm.

91- Fracture involving radial groove of humerus will lead to:
A- Loss of sensation at the dorsum of root of thumb
B- Claw deformity
C- Extension of fingers
D- Loss of Opposition of thumb
Ans: A

Explanation:
- The Nerve running in the spiral or radialgroove of humerus is Radial nerve, if that's damage extension of fingers & arm will be lost along with loss of sensation of dorsum of arm & hand.

92- Most common complication after modified radical mastectomy is:
A- Hematoma
B- Anaphylaxis
C- Lymph edema
D- Wound dehiscence
Ans: C

93- Posterior dislocation of elbow will lead to damage of the following ligament?
A- Ulnar Collateral ligament
B- Radial ligament
C- Transverse Ligament
D- Lateral ligament
Ans: A

94- Axillary nerve supplies which of the following?
A- Deltoid
B- Serratus Anterior
C- Pectoralis Major
D- Bicep Brachii
Ans: A

Explanation:
Axillary nerve supply
- Articular branches- shoulder joint
- Anterior terminal branch - supplies the deltoid muscle and skin that covers its lower half
- Posterior terminal branch - Which supplies the teres minor and deltoid miscles and then becomes the • lateral cutaneous nerve of arm , which also supplies the skin over the lower part of deltoid muscle

95- Path from axillary lymph flow from breast has which two parts:
A- Medial and lateral
B- Superior and anterior
C- Anterior and Posterior
D- Lateral and Superior
Ans: C

96- Which one is related to posterior cord?
A- Anterior interosessous
B- Posterior interosessous
C- Ulnar
D- Radial
Ans: D

97- Accessory cervical rib is causing numbness and pain in the hand of a patient. Which part of the brachial plexus is associated with it?
A- C6
B- C7
C- C5
D- C8
E- T1
Ans: E

98- C5 and C6 roots of brachial plexus are damaged, the weakness would result in which muscle?
Infraspinatus
A- Extensor ulnaris
B- Flexor carpi ulnaris
C- Flexor Pollicis longus
D- Flexor Pollicis Brevis
E-
Ans: A

Explanation
- Infraspinatus and supra spinatus are supplied by supraclavicular nerve which root value is C5 C6

99- Girl of 11 year was referred to X-ray department for X ray of elbow joint to know age,So X-ray will be of:
A- Capitulum
B- Trochlea
C- Medial epicondyle
D- Lateral epicondyle
Ans: D

Explanation:
Age for ossification center(odd numbers)
- Capitulum - 1 year
- Radial head - 3 years
- Medial epicondyle - 5 years
- Trochlea - 7 years
- Olecranon - 9 years
- Lateral epicondyle - 11 years

100- A young patient with condylar fracture and as a result lost the abduction and extension of thumb and index finger. Damage is to which nerve
A- Radial nerve
B- Ulnar nerve
C- Median nerve
D- Musculocutaneous nerve
Ans: A

101- The ulnar nerve supplies:
A- Medial 1/3rd of the palmar hand
B- Medial 1/3rd of the dorsal hand
C- Medial 1/3rd of the palmar and dorsal hand
D- Medial 2/3rd of the palmar hand
Ans: C

102- Muscle which keeps the scapula opposite to chest wall?
A- Rhomboid major
B- Serratous Anterior
C- Levator scapulae
D- Deltoid
Ans: B

103- Injuiry to the external surface of elbow, structure involved will be:
A- Median nerve
B- Ulnar nerve
C- Axillary nerve
D- Radial nerve
Ans: D

104- Direct branch of subclavian artery taking part in shoulder joint anastomosis:
A- Suprascapular artery
B- Thyrocervical trunk
C- Transverse cervical artery
D- Thoracoacromal artery
E- Dorsal scapular artery
Ans: E

Explaination
- Main branch - thyrocervical trunk
- Direct branch - dorsal scapular artrey

105- A Patient has fracture of surgical neck of Humerous. Now he can't raise his arm above his shoulder and also has sensory loss on lateral surface of arm. Which of the following muscle damaged?
A- Teres minor
B- Teres major
C- Deltoid
D- Pectoral major
Ans: C

Explanation:
Deltoid muscle Abducts and laterally rotate arm. So, fracture of humerus of humerus at surgical neck, damage Axillary nerve that paralyses the deltoid muscle.

106- Which of the following muscle causes abduction of arm above 90?
A- Trapezious&Serratus Anterior
B- Deltoid
C- Supraspinatus
D- Infraspinatus
E- SCM
Ans: A

Explanation
- Suprapinatous muscle - prime mover upto 15
- Middle fibers of deltoid - upto 90°
- Trapezius - overhead abduction

107- Movement at radio-ulnar joint by which of following muscles?
A- Pronator & supinator
B- Flexor carpi ulnaris
C- Extensor carpi ulnaris
D- Biceps brachii
Ans: A

CamScanner

Explanation:

Pronators of forearm at superior and inferior radioulnar joint

- Pronator teres
- Pronator quadratus
- Flexor carpi radialis
- Palmaris longus

Supinators of forearm at superior and inferior radioulnar joint

- Bucepsbrachii (chief)
- Supinator

108- Which of the following is true regarding Median nerve in upper arm?

A- Medial to brachial artery in cubital fossa
B- Lateral to brachial artery in cubital fossa
C- inferior to brachial artery
D- superior to brachial artrey

Ans: A

Explanation:

boundaries

- **Apex** - directed downwards
- **Base** - imaginaty line joining two epicondyles of humerus
- **Floor** - supinator muscle laterally , brachialis muscle medially
- **Roof** - skin , fascia and bicipital aponeurosis

Contents from(medial to lateral)

- Median nerve
- Bifurcation of brachial artrey
- Tendon of biceps
- Radial nerve
- Supra tracheal lymph nodes

109- Structure crossing superficial to the flexor retinaculum

A- Median nerve.
B- Ulnar nerve
C- Flexor digitorum superficialis.
D- Flexor pollicis longus.
E- None of these

Ans: B

110- Only muscle supplied by superficial branch of ulnar nerve:

A- Palmaris brevis
B- Palmaris longus
C- Adductor pollicis
D- Flexor digitiminimi

Ans: A

111- The deep branch of radial nerve supplies all except:

A- Deep extensor of forearm
B- Long and medial head of triceps
C- Elbow joint
D- Interossi muscle of hand
E- Supinator muscle

Ans: D

Explanation

- Introssei of hands are supplied by ulnar nerve

112- Pectoralis minor is in front of which part of axillary artrey

A- 1st part of axillary artrey
B- 2nd part of axillary artrey
C- 3rd part of axillary artrey
D- 4th part of axillary artrey

Ans: B

113- Nerve supply of triceps muscle is

A- C6,7,8
B- C3,4,5
C- C2,3, C4
D- C1,2

Ans: A

114- A player was hit by a ball on the posterior and medial aspect of elbow joint with fracture of medial epicondyle and damage ulnar nerve.This would result in sensory loss over?

A- Lateral 2/3 over dorsal surface
B- Lateral 2/3 over palmer surface
C- Medial 1/3 over dorsal
D- Medial 1/3 over palmar and dorsal surface
E- Medial 1/3 over medial surface

Ans: D

115- Inferior angle of scapula:

A- T2
B- T4
C- T5
D- T6
E- T7

Ans: E

116- Mid shaft humerus fractured. Hand is flexed. Sensations dimished in lateral half of dorsum of hand:

A- Radial
B- Median
C- Ulnar
D- axillary
E- musculocutaneous

Ans: A

117- Patient in abducted hand is asked to move hand slowly and smoothly downward but he dropped hand suddenly by his side. Which muscle is most likely torn?

A- Deltoid
B- Supraspinatus
C- Subscapularis
D- Teres major
E- Pectoral

Ans: B

118- Which muscle is flexor of forearm and supplied by the radial nerve?

A- Brachialis
B- Brachioradialis
C- Flexor digitorum Profundus
D- Triceps brachii
E- Flexor carpi radialis

Ans: B

Explanation:

Flexors of forearm

- Brachioradialis
- Biceps brachii
- Pronator teres
- Brachialis

Extensors of forearm

- Triceps
- Anconeus

119- Superior radioulnar joint is:

A- Hinge joint
B- Ball and socket joint
C- Saddle joint
D- Pivot joint
E- Condyloid joint

Ans: D

Explanation:

Joints of hand type

- **Shoulder joint** - synovial ball and socket joint
- **Elbow joint** - synovial hinge joint
- **Superior and inferior radioulnar** - synovial pivot joint
- **Wrist joint**-synovial condyloid joint
- **Carpometacarpal joint** - synovial saddle joint
- **Metacarpophalangeal joint** - synovial condyloid joint
- **Interphalangeal** - synovial hinge joint

120- Brachial plexus block patient still feels pain on lateral aspect of forearm. Which nerve is spared?

A- Axillary nerrve
B- Musculocutaneous nerve
C- rafial nerve
D- median nerve
E- ulnar nerve

Ans: B

121- Long thoracic nerve supplies:

A- Lattisimusdorsi
B- Serratus anterior
C- rhomboid muscles
D- levator scapulae
E- subclavius muscle

Ans: B

Explanation:

- Dorsal scapular nerve C4 C5 supplies rhomboid muscles and levator scapulae
- Nerve to subclavius C5 C6 supplies subclavius muscle
- Long thoracic nerve C5 C6 C7 supplliesserratus anterior

122- Axillary artery is formed by:

A- Basilic vein and vena commitantes of brachial artery
B- Cephalic vein and vena commitantes of brachial artery
C- union of basillicvien and cephalic vien
D- median cuboidal vien

Ans: A

123- Lesion of C5/C6 in whiplash injury occurred, which function will be lost:

A- Flexion of elbow
B- Extension of elbow
C- Medial rotation of shoulder
D- Lateral rotation of shoulder
E- Abduction of shoulder

Ans: A

124- A lady presented with pain in shoulder and can't adduct and Medially rotate due to injury of:

A- Teres Major
B- Teres minor
C- Supraspinatu
D- Infraspinatus
E- Subscapularis

Ans: A

Explanation

Muscles producing movements of shoulder joint

Medial rotators of shoulder joint

- Subscapularis
- Teres major
- Latissmusdorsi

Lateral rotators of shoulder joint

- Infraspinatous
- Teres minor
- Post fibers of deltoid

Adductors of shoulder joint

- Pectoralis major
- Pectoralis minor
- Teres major and minor

Abductors of shoulder joint

- Suprapinatous muscle
- Muscles fiber of deltoid
- Trapezius

Flexors of shoulder joint

- Anterior fibers of deltoid
- Pectoralis major
- Biceps brachii
- Corachobrachialis

Extensors of shoulder joint

- Posterior fibers of deltoid
- Latissmusdorsi
- Teres minor

CamScanner

125- While taking blood sample at cubital fossa,which nerve is injured?
A- Median
B- Ulner
C- Radial
D- Musculocutaneous
E- Axillary
Ans: A

Explanation:
Contents from(medial to lateral)
- Median nerve
- Bifurcation of brachial artrey
- Tendon of biceps
- Radial nerve
- Supra tracheal lymph nodes

126- Patient can't flex index finger and lost sensation of lateral palmar surface.The nerve damaged is:
A- Median
B- Radial
C- Ulnar
D- Musculocutaneous
E- Axillary
Ans: A

127- Which muscle is supplied by both median and ulnar nerve
A- Pronator teres
B- Flexor digitorunsuperficialis
C- Palmaris longus
D- Flexor carpi radialis
E- Flexor digitorum Profundus
Ans: E

Explanation:
- Median nerve supply lateral half of flexor digitorumprofundus muscle
- Ulnar nerve supply medial half of flexor digitorumprofundus muscle

128- Blood supply of head of humerus:
A- Arcuate
B- Anterior circumflex
C- Post circumflex
D- Retinaculur
E- Medial circumflex
Ans: A > B

129- Abductor pollicis longus nerve supply:
A- Axillary
B- Median
C- Radial
D- Musculocutaneous
Ans: C

Explanations:
- Abductor polices brevis supplies via median nerve.
- Abductor polliceslongus supplies via radial nerve.

130- Lateral rotation of arm caused by which nerve?
A- Supracapular nerve
B- Axillary nerve
C- Radial nerve
D- Ulnar nerve
E- Spinal accessory nerve
Ans: B

131- Loss of abduction of arm, nerve involved:
A- Radial
B- Median
C- Musculocutaneus
D- Suprascapular
Ans: D

132- Patient presented with the lateral rotated arms and can't perform supination which part of brachial plexus involved?
A- Upper trunk
B- Middle trunk
C- Lower trunk
D- Inferior trunk
Ans: A

133- Along with deep Palmar arch,Which nerve runs?
A- Deep branch of radial nerve
B- Superficial branch of radial nerve
C- Deep branches of ulnar nerve
D- Superficial branches of ulnar nerve
E- Median nerve
Ans: C

134- Opposition of thumb with little finger is impaired, nerve damaged:
A- Ulnar
B- Radial
C- Median
D- Axillary
Ans: C

135- Injury to medial epicondyle results in injury to which nerve?
A- Radial Nerve
B- Median Nerve
C- Ulnar Nerve
D- Musculocutaneous Nerve
Ans: C

136- About axillary artery:
A- Lies posterior to pectoralis minor
B- Lies lateral to the lateral cord of brachial plexus
C- Lies lateral to the short head of bicep
D- Extends to the lowest border of pectoral's major
Ans: A

137- Axillary Fascia derived from:
A- Paravertebral fascia
B- Pretracheal fascia
C- Superficial layer of cervical fascia
D- Deep layer of cervical fascia
Ans: A

138- Ulnar nerve injury causes:
A- Loss of abduction and adduction of fingers
B- Loss of opposition of thumb
C- Wrist drop
D- Thinner muscles wasting
Ans: A

139- A girl after fight with her best friend, was unable to extend her all fingers she also noted that she can't abduct her thumb too:
A- Ulnar nerve injury
B- Median nerve injury
C- Radial nerve injury
D- Musculocutaneous nerve injury
E- axillary nerve injuiry
Ans: C

140- Cervical rib compression causes paralysis of short muscles of hands:
A- C8
B- T1
C- C6
D- C5
Ans: B

141- Sensory supply of neck from chin to supraclavicular is
A- C5, C6
B- C1, C2
C- C2, C3
D- C4 C5
E- C6 C7
Ans: C

142- A boy fell from a bike, and landed on his shoulder. He had his arm hanging by the side, and loss of innervation of lateral forearm. Which nerve is likely to be damaged
A- Lateral pectoral nerve
B- Medial pectoral nerve
C- Axillary nerve
D- Nerve roots C5, C6
Ans: D

143- What is the nerve supply of levator scapula?
A- C4, C5
B- Accessory nerve
C- Thoracodorsal
D- Posterior rami of spinal nerves
Ans: A
Explanation:
- Dorsal scapular nerve root value is C4 C5 which supplies the levator scapulae

144- Patient had sharp knife injury to posterior triangle of neck. Damage occurs to the most superficial muscle Which of the following could be damaged?
A- Sternoclenomastoid
B- Serratius anterior
C- Trapezius
D- Deltoid
Ans. C

Explanation:
Boudaries
- Anterior – posterior border of the sternocleidomastoid.
- Posterior – anterior border of the trapezius muscle.
- Inferior – middle 1/3 of the clavicle.

Contents
- Subclavianartrey (3rd part) and subclavianvien
- External jugular vien
- Brachial plexus
- Spinal part of accessory nerve
- Branches of brachial plexus

145- Carpal tunnel syndrome has which of the following features
A- Ulnar nerve damage
B- C8T1 leision
C- Loss of sensation of thenar
D- Flattened thenar
E- Flattened hypothenar
Ans. D

146- Absent bicep reflex and some sensory loss on lateral side due to damage of:
A- C5-C6
B- C3-C6
C- C6-T8
D- C6 - C7
Ans: A

Explanation:
- **Achilles reflex** - S1 , S2 (Buckle my shoe)
- **Patellar reflex** = L2-L4 ("kick the door")
- **Biceps and brachioradialis** reflexes = C5, C6 ("pick up sticks")
- **Triceps reflex** = C6, C7, C8 ("lay them straight")

147- Patient presented with weakness of all short muscles of hand and weak radial pulse.What is the diagnosis in this patient?
A- Ulnar nerve damage
B- Median nerve damage
C- C8-T1 leision
D- Cervical rib
E- 2nd rib
Ans: D

CamScanner

148- Anatomical neck of humerus fractured causes injury to a nerve. What will it effect?
A- Loss of abduction
B- Loss of adduction
C- Loss of circumduction
D- Loss of flexion
Ans: A

149- Axillary nerve injury most commonly in?
A- Lateral cord injury
B- Shoulder joint dislocation
C- Fracture of anatomical neck of humerus
D- Fracture of shaft of humerus
Ans. B

150- Adduction and abduction of finger lost. nerve damaged:
A- Deep branch of ulnar nerve
B- Deep branch of radial nerve
C- Superficial branch of radial nerve
D- Superficial branch of ulnar nerve
Ans: A

151- A patient with history of tingling sensation of hand and inability to grip things properly, also there is wasting of thenar muscles of hand, which nerve is involved?
A- Ulnar
B- Median
C- Radial
D- Musculocutaneous
Ans: B

152- In Quadrangular abscess, Nerve damaged is:
A- Radial Nerve
B- Ulnar
C- Axillary nerve
D- Brachial
Ans. C

153- A baby after an obstructed delivery presented with inability to abduct the arm, loss of flexion & loss of supination of arm at elbow joint due to damage to:
A- Upper Trunk of Brachial Plexus (C5-C7)
B- Lower Trunk of Brachial Plexus
C- Radial Nerve
D- Ulnar Nerve
Ans: A

Explanation:
In upper trunk of brachial. Plexus there is mostly damage to musculocutaneous, axillary and suprascapular nerve that leads to loss of abduction, flexion & supination of forearm.

154- Patient had asked to grip the card between the tip of index finger and thumb which nerve injury is checked in this test
A- Anterior interosessous
B- Posterior interosessous
C- Ulnar
D- Radial
Ans: A

Explanation:
- Thumb and index finger weakness and sensation intact lesion of – AnterioInterosseous nerve branch of median nerve
- Thumb and index finger weakness with lost sensation lesion of – Median Nerve
- Unable to Extend MCP and Thumb with intact Sensation lesion of – Posterior interosseous nerve branch of radial
- Unable to Extend MCP and thumb with lost sensation lesion of – Radial Nerve

155- Supernumerary cervical rib may cause the compression of:
A- Brachial plexus and subclavian blood vessels.
B- Thoracic duct
C- Inferior vena cava (IVC)
D- Thoracic aorta
E- Abdominal aorta
Ans: A

156- Regarding Breast:
A- 15 to 20 lactiferous ducts
B- Extends from 2 to 6 intercostal spaces
C- Tuboalveolar gland
D- Does not arise from place other than thorax.
Ans: A

157- Root value of axillary nerve:
A- C5, C6
B- C5, C6, C7
C- C3, C4
D- C1, C2, C3, C4, C5
Ans: A

Explanation
- Axillary nerve – C5, C6
- Radial nerve – C5, C6, C7, C8, T1
- Ulnar nerve – C8, T1
- Musculocutaneous nerve – C5 , C6 ,C7

158- Nerve supply of the lateral forearm is through
A- Median nerve
B- Radial nerve
C- Anterior anterosseus nerve
D- Musculocutaneous nerve
Ans: D

159- Circumduction is:
A- Adduction abduction flexion extension
B- Abduction adduction medial rotation lateral rotation
C- Flexion extension medial rotation lateral rotation
D- Adduction abduction flexion extension , medial rotation, lateral rotation
Ans: D

Explanation
Circumduction is combination of all movements

160- Structure crossing superficial to the flexor retinaculum
A- Median nerve.
B- Palmaris longus
C- Flexor digitorum superficialis.
D- Flexor pollicis longus.
Ans: B

161- A patient after fall on outstretched hand with trauma on wrist develops dislocation of lower portion of joint posteriorly and medially, most probably he has?
A- Fracture of neck of scaphoid bone.
B- Fracture of lunate.
C- Colle's Fracture
D- Fracture of ulna.
E- Fracture of metacarpal bone
Ans: C

162- Extensor carpi ulnaris supplied by:
A- Median nerve
B- Ulnar nerve
C- Anterior interosseous nerve
D- Radial nerve
E- Axillar nerve
Ans: D

163- Female with complains of wrist pain and numbness in index and ring finger movement of which hand muscle will be affected by involved nerve:
A- Adductor pollicis brevis
B- Abductor pollicesbrevis
C- Extensor pollicis brevis
D- Opponinisdigitiminimi
E- Abductor pollicis longus
Ans: B

164- Following part of brachial plexus is formed from anterior division of two trunks?
A- Medial cord
B- Posterior cord
C- Lateral cord
D- Median nerve
E- Axillary nerve
Ans: C

Explanation:
- Lateral Cord – Anterior division ofupper and middle trunk
- Medial Cord – Anterior division oflower trunk
- Posterior Cord – Posterior division ofmiddle and lower trunk

165- After damage to lateral thoracic wall, Elevation of lower angle of scapula. Patient hand cannot reach forward as previously. Nerve damaged is
A- Accesaory nerve
B- Axillary nerve
C- Long thoracic nerve
D- Thoracodorsal nerve
Ans: C

166- Medial attachment of flexor retinaculum
A- Pisiform bone
B- Trapezoid
C- Ulnar distal end
D- Sphenoid
Ans: A

167- Structure Prone to damaged in Quadrangular space?
A- Anterior cicumflex humeral artery
B- Brachial plexus
C- Posterior circumflex Humeral artery
D- Subclavian artery
Ans: C

168- Winging of scapula occurs due to involvement of which muscle?
A- Rhamboid major
B- Pectoralis minor
C- Serratus interior
D- Lattismusdorsi
E- Pectoralis major
Ans: C

169- After trauma on anatomical snuffbox patient having bleed and pain due to which structure damage?
A- Median nerve
B- Ulnar nerve
C- Radial artery
D- Radial nerve
E- Brachial artery
Ans: C

Explanation:
- Most common carpal bone Fracture – Scaphoid (Radial Artery)
- Most common dislocated carpal Bone – Lunate (Median Nerve – Carpal tunnel)
- Fracture of hook of hamate – Ulnarnerve damage (Cuboidal tunnel)
- Anatomical snuff box pain – RadialArtery
- The main contents of the anatomical snuffbox are the radial artery, superficial branch of the radial nerve, and the cephalic vein

CamScanner

170- Herniation between C5 C6 nerves injured:
A- C5
B- C6
C- C8
D- C2
Ans: B

171- Carpel tunnel syndrome, which one of these muscles is not affected in this ?
A- Opponens Pollicis
B- Abductor pollicis brevis
C- Palmaris longus
D- Pronator Quadratus
E- Abductor Digiti Minimi
Ans: E

172- Triceps reflex loss lesion is in:
A- Upper cervical
B- Lower cervical
C- Upper cervical and lower thoracic
D- Upper brachial plexus
Ans: B

173- Patient has little finger defect on examination, sensory loss of little finger due to injury of which nerve?
A- Median nerve
B- Radial
C- Musculocutaneous
D- Ulnar
E- Axillary
Ans: D

174- After fracture of clavicle, which ligament prevents dislocation of acromioclavicular joint?
A- Acromiclacicular
B- Croacoacromial
C- Transeverse humeral
D- Sternoclaclavicular
Ans: B

175- A boy fall by his left shoulder and then his arm is hanging and elbow is extended with arm medially rotated and Pronated due to damage of
A- Lateral portion of median nerve
B- Posterior part of brachial plexus
C- Upper trunk of brachial plexus
D- Radial nerve
E- Axillary nerve
Ans: C
Explanation:
- This is the case of Erb's Palsy (waiter'stip) resulted from traction or tear of uppertrunk of brachial plexus (C5,C6) resultedin loss of abduction, lateral rotation,flexion & supination of arm so arm position will be adducted , Medially rotataed , Extended and pronated.

176- A Child fell on outstretched hand, hook of hamate got fractured. Nerve injured is.
A- Axillary
B- Radial
C- Ulnar
D- Musculocutaneous
E- Median
Ans: C
Explanation:
- Most common carpal bone Fracture – Scaphoid (Radial Artery)
- Most common dislocated carpal Bone – Lunate (Median Nerve – Carpal tunnel)
- Fracture of hook of hamate – Ulnarnerve damage (Cuboidal tunnel)
- Anatomical snuff box pain – RadialArtery

177- C8 of brachial plexus derives root from?
A- Superior trunk
B- Middle trunk
C- Lateral cord
D- Posterior cord
Ans: D

178- Anterior shoulder joint dislocationcan cause damage to which nerve?
A- Musculocutaneous
B- Axillary nerve
C- Suprascapular nerve
D- Long thoracic nerve
E- Median nerve
Ans: B

179- Rhomboid major nerve supply is:
A- Axillary nerve
B- Long thoracic nerve
C- Dorsal scapular nerve
D- Radial nerve
E- Accessory nerve
Ans: C

180- Loss of sensations of thumb and index finger with wasting of thenar muscles most likely due to involvement of which nerve?
A- Ulnar nerve
B- Radial nerve
C- Median nerve
D- MCN
Ans: C

181- Person doing chin up raises his arm above head and than bring rod in front on chest. Which muscle helps:
A- Rhomboid major
B- Lattismus dorsi
C- Lavator scapula
D- Serratous posterior
E- Scalene anterior
Ans: B

182- A patient is having inferior axillary injury , he has difficulty in climbing and swimming.Which nerve is damaged:
A- Median nerve
B- Accessory nerve
C- Axillary nerve
D- Long thoracic
E- Thoracodorsal
Ans: E(KLM)

183- A man was trying to protect his face during a bank robbery he was stabed with knife in anterior forearm. On stitching his wound doctor found that he cant adduct his thumb which nerve is damaged:
A- Radial
B- Musculocutaneous
C- Median
D- Ulnar
Ans: D

184- A baby after an obstructed delivery presented with inability to abduct the arm, loss of flexion & loss of supination of arm at elbow joint due to damage to:
A- Klumpsky paralysis
B- Erb'spasly
C- Radial nerve
D- Ulnar Nerve
Ans: B

185- After injury patient complain that his arm cannot move forward as before this is due to lesion of which part of brachial plexus:
A- Upper trunk
B- Posterior cord
C- Posterior trunk
D- Lower cord
Ans: A

186- A patient has lateral chest wall blow injury beneath right arm after which vertebral column of scapula become prominents and moves posteriorly.Which nerve in close relation is damaged:
A- Accessory nerve
B- Axillary nerve
C- Long thoracic nerve
D- Thoracodorsal
Ans: C

187- A female suffering from breast carcinoma. On Investigation after surgery it is found that mets found in vertebrae. Which lymph node leads to metastasis in vertebrae?
A- Anterior Axillary
B- Sternal
C- Pectoral
D- Internal Thoracic
Ans: A

188- Which one is most commonly absent congenitally:
A- Serratus anterior
B- Pectoralis major
C- Pectoralis minor
D- Teres major
E- Teres minor
Ans: E

189- Upper lateral lymphatic drainage of breast includes which of the following?
A- Internal mammary
B- Subcapsular
C- Pectoral
D- Diaphragmatic
Ans: C (KLM +BD)
Explanation:
- Nipple drainage – Ant. axillary (Pectoral)
- Upper lateral – Ant. axillary or pectoral mainly
- Lower lateral (Inferior) – Ant. axillary + Sub diaphragmatic + Internal mammary.
- Medial quadrant – Mainly to internal mammary (Internal thoracic)
- Lower inner medial quadrant – Inferior phrenic (Sub Diaphragmatic)
- Tail of breast – Posterior (Scapular) lymph node

190- A doctor saw mass on mammography but could not palpate it, where could it be located?
A- Deep pectoral fascia
B- Axilla
C- Skin
D- Tail of breast
Ans: D

191- Latissimus Dorsi is paralysed.Which part of brachial plexus is involved:
A- Anterior cord
B- Lateral cord
C- Posterior cord
D- Whole trunk
Ans: C

CamScanner

192- A person got stab on upper arm and floor of Axilla which of following structure will be damage
A- Axillary nerve
B- Radial nerve
C- Intercostobrachial artery
D- Ulnar nerve
Ans: C

193- A patient came due to deep palmar arch bleeding.What to do to stop bleeding?
A- Compressing ulnar artery
B- Compressing radial artery
C- Compressing both radial and ulnar artery
D- Compressing Brachial artery
Ans: B

194- Injury to wrist resulted in swelling, bone fracture will be
A- Triquetrium
B- Scaphoid
C- Lunate
D- Pissiform
Ans: B

195- Following a difficult delivery a baby is noted to have unilateral loss of function of intrinsic muscles of hand with accompanying numbness along the inner aspect of the hand. Baby most probably has which of the following?
A- Erb's palsy
B- Klumpke's palsy
C- Duchenne muscular dystrophy
D- Proximal myopathy
Ans: B

196- Anterior tear in rotator cuff muscle, dye is given which accumulates on lateral border of scapula.Which bursa is involved?
A- Subscapular
B- Subacromial
C- Subcoracoid
D- Coracoclavicular
Ans: A

197- Middle carpal bone in proximal row:
A- Trapezium
B- Lunate
C- Capitate
D- Scaphoid
Ans: B

198- Adduction after abduction of shoulder Along gravity.Which muscle helps in adduction of shoulder?
A- Pactoralis minor
B- Rhomboid major
C- Lattismusdorsi
D- SCM
Ans: C

199- A patient has difficulty in climbing and during swimming can't do crawl which muscle is damage?
A- Serratus anterior
B- Trapezius
C- SCM
D- Pactoralis major
E- Lattismusdorsi
Ans: E (KLM)

200- A person who is unable to button and hold pen due to damage of which muscle
A- Abductor pollics
B- Abductor digiti
C- Opponencepollics
D- Adductor digitiminimi
E- Flezorpollicis
Ans: C

201- In median nerve damage,Which muscle is affected?
A- Adductor pollicis
B- 1st lumbrical
C- 4th lumbrical
D- Flexor dogitorumperfundus
Ans: B

202- Patient has loss of supination.Which of the following nerve injury is responsible for this?
A- Median nerve
B- Ulnar nerve
C- Musculocutaneous and median nerve
D- Radial and musculocutaneous nerve
E- Axillary nerve
Ans: D
Explanation:
- Pronation – Median nerve
- Supination – Musculocutaneous and radial nerve
- Supination done by biceps brachii and supinator muscle
- Biceps muscles supplied by Musculocutaneous and supinator is supplied by the radial nerve

203- Tricep reflex lost root value will be
A- C5-6
B- C4-5
C- C7-8
D- C6-7
Ans: C

204- Which structure passes superficial to transverse carpal ligament?
A- Median nerve
B- Ulnar nerve
C- Axillary nerve
D- Brachial artery
Ans: B

205- If radial trunk is cut at origin, what will happen?
A- Claw hand
B- Wrist drop
C- Dupytene contracture
D- Ape hand
Ans: B

206- Nerve compression between C5 and C6 compress which of following?
A- C4
B- C5
C- C6
D- C7
E- C3
Ans: C

207- Brachial plexus division done by
A- Clavicle
B- First rib
C- Axillary artery
D- Pectoralis minor muscle
E- Humerus
Ans: D

208- The divisions of the brachial plexus are placed deep to the:
A- 1st rib
B- Axillary artery
C- Clavicle
D- Pectoralis minor muscle
E- Scapula
Ans: C

209- Injury result in damage to anatomical snuff box, unable to move thumb, unable to abduct wrist, which muscle of extensor compartment is damaged?
A- Extensor digitorum
B- Extensor pollicis brevis
C- Extensor carpi radialis longus
D- Adductor brevis
E- Brachial artery
Ans: B

210- A person has weakness in adduction and medial rotation of shoulder.Muscle which can perform these actions is most likely?
A- Teres major
B- Teres minor
C- Supraspinatous
D- Subscapularis
E- Latissimus dorsi
Ans: A

211- Medial side of arm is supplied by?
A- Medial cord
B- Lateral cord
C- Musculocutaneous nerve
D- Median nerve
Ans: A

212- During Anasthesia,Supraclavicular part of Brachial plexus blocked.Which one will be affected?
A- Root
B- Axilla
C- Cords
D- Trunk
Ans: D

213- Patient took his hand forearm to scratch the back muscles but unable to fold arm and scratch the back of body muscle involved is
A- SCM
B- Latisimus dorsi
C- Serratus anterior
D- Trapezius
E- Scalene anterior
Ans: B
Explanation:
- Can't scratch his back , muscle damage - latissmusdorsi
- Can't scratch his back , nerve damage - thoracodorsal nerve (middle subscapular nerve)
- Can't comb his hairs , nerve damage - long thoracic nerve

214- In RTA, Damage to shoulder joint at the lower border of first rib will likely damage which artery?
A- Axillary artery
B- Subclavian artery
C- IJV
D- Lingual Artery
E- Maxillary artery
Ans: B

215- In cubital fossa,most lateral structure is:
A- Median nerve
B- Bifurcation of brachial artery
C- Bicep tendon
D- Radial nerve
Ans: D
Explanation:
From medial to lateral
- Median nerve, brachial artery, biceps tendon, radial nerve.

CamScanner

216- A 50 year old female has undergone mastectomy for Ca Breast. After Mastectomy, Patient is not able to extend, adduct and internally rotate the arm. There is damage to nerve supplying which muscle?

A- Latissimus Dorsi
B- Pectoralis Major
C- Teres Minor
D- Long head of Triceps
Ans: A

217- Surgical neck of humerus fractured. Damage to :

A- Median Nerve
B- Posterior circumflex artery
C- Musculocutaneous
D- Axillary artery
E- Radial Nerve
Ans: B

Explanation:

- Dislocation of Shoulder Joint – Axillary nerve
- Fracture anatomical neck of humerus – Radial nerve
- Fracture surgical neck of humerus – Axillary nerve and posterior circumflex humeral artery
- Fracture shaft of humerus – Radial nerve and profunda brachii artery.
- Fracture medial epicondyle of humerus – Ulnar nerve and ulnar collateral artery.
- Supracondylar fracture of humerus – Median nerve and brachial artery.

218- About carpal bones, the proximal row consists of the following except:

A- Scaphoid
B- Lunate
C- Capitate
D- Triquetral
E- Pisiform
Ans: C

219- In rotator cuff injury,patient is unable to do abduction at shoulder joint.Which of the following muscle will be damaged?

A- Infraspinatus
B- Supraspinatus
C- Teres major
D- Pect major
Ans: B

220- Axillary artery damaged in axillary Groove.Which branch will be affected?

A- Suprascapular artery
B- Circumflex artery
C- Brachial artery
D- Infrascapular artery
Ans: B

221- Fifth Metacarpal Fracture is:

A- Bennet Fracture
B- Boxer's fracture
C- Smith fracture
D- Erbs fracture
Ans: B

Explanation:

- Bennete fracture - Base of thum fracture 1st metacarpal
- Boxer Fracture -Fifth metacarpal fracture
- Smith fracture -Radius end fracture

222- Serratus anterior supplied by which nerve?

A- Axillary nerve
B- Ulnar nerve
C- Spinal part of accessory nerve
D- Long thoracic nerve
Ans: D

223- A female with complains of wrist pain &numbness in index & ring finger. The movement of which hand muscle will likely be affected:

A- Adductor pollicis brevis
B- Abductor pollicis brevis
C- Extensor pollicis brevis
D- Opponens digiti minimi
E- Abductor pollicis longus
Ans: B

224- Regarding radial nerve sensory supply?

A- Palmer area of hand
B- Medial two fingers
C- Lateral three and half finger
D- Whole hand
Ans: C

225- Lymphatic drainage of breast upper outer quadrant is

A- Central
B- Internal thoracic
C- External thoracic
D- Anterior Axillary
E- Diaphragmatic
Ans: D(KLM +BD)

Explanation:

- Nipple drainage -- Ant. Axillary (Pectoral)
- Upper lateral -- Ant. axillary mainly
- Lower lateral (Inferior) -- Ant. axillary + Sub diaphragmatic + Internal mammary.
- Medial Quadrant -- Mainly to Internal mammary (Internal thoracic)
- Lower Inner Medial Quadrant – Inferior Phrenic (Sub Diaphragmatic)
- Tail of Breast – Posterior (Scapular) Lymph Node
- Path of Axillary lymph flow –Anterior and posterior
- Quadrant of Breast Lymph – Medial and lateral

226- Humeral Anatomical neck fracture, which Nerve will be damaged?

A- Median nerve
B- Ulnar nerve
C- Posterior circumflex
D- Radial nerve
E- Axillary nerve
Ans: D

Explanation:

- Dislocation of shoulder joint – Axillary nerve
- Fracture anatomical neck of humerus– Radial nerve
- Fracture surgical neck of humerus – Axillary nerve and posterior circumflex humeral artery.
- Fracture shaft of humerus – Radialnerve and profunda brachii artery
- Fracture medial epicondyle of humerus– Ulnar nerve and ulnar collateralartery
- Supracondylar fracture of humerus – Median nerve and brachial artery

226- Median nerve route is:

A- Lateral to cubital fossal
B- Posterior to cubital fossal
C- Anterior to Brachial artery
D- Medial to cubital fossa
Ans: D

228- In cubital fossa,most medial structure is:

A- Median nerve
B- Bifurcation of brachial artery
C- Bicep tendon
D- Radial nerve
Ans: A

Explanation:
From medial to lateral

- Median nerve, brachial artery, biceps tendon, radial nerve.

229- Loss of flexion of forearm at elbow joint due to damage nerve is:

A- Radial
B- Musculocutaneous
C- Ulnar
D- Median
Ans: B

230- Dorsum of middle 3 hand fingers supplied by:

A- C4
B- T1
C- C6
D- C7
D- C8
Ans: D

231- Deep to flexor retinaculum median nerve compression which muscle will be spared:

A- Opponence pollicis
B- Flexor pollicis brevis
C- Abductor pollicis brevis
D- Flexor Carpi radilais
E- First Two lumbricals
Ans: D

232- The following structures pass posterior to the flexor retinaculum except:

A- Flexor digitorum superficialis tendons
B- Median nerve
C- Ulnar nerve
D- Flexor pollicis longus tendon
Ans: C

233- A patient has thenar atrophy and thumb opposition lost due to which nerve damage?

A- Radial nerve
B- Ulnar Nerve
C- Musculocutanos Nerve
D- Axillary Nerve
E- Median nerve
Ans: E

234- Cords of brachial plexus are named according to relation with?

A- Brachial artery
B- Axillary artery
C- Subclavin artery
D- Intercostal artery
E- Pectoralis major
Ans: B

235- Patient can't abduct, weakness in Biceps, Weakness in extension of wrist due to damage of:

A- Radial nerve
B- Axillary nerve
C- Musculocutaneous nerve
D- Median nerve
Ans: C

236- An old man while watching late night movie fell asleep in an armchair sofa. When woke up in the morning he was unable to grip a glass of water with his right hand. Which nerve is affected?

A- Axillary
B- Median
C- Post cord
D- Radial nerve
E- Ulnar nerve
Ans: D (Saturday night palsy)

CamScanner

237- Nerve responsible for fine movements of hand is:
A- Radial
B- Ulnar
C- Median
D- Posterior interosseous
E- Anterior interosseous
Ans: B

238- Following muscles have no action at wrist?
A- Brachioradialis
B- Bicep
C- Extensor Carpi radilais
D- Extensor Carpi ulnaris
Ans: A

239- Flattened thenar muscles due to damage of:
A- Radial Nerve
B- Median Nerve
C- Ulnar Nerve
D- Axillary Nerve
Ans: B

240- After trauma to scaphoid bone, patient having bleed and pain due to which structure damaged?
A- Median nerve
B- Ulnar nerve
C- Radial artery
D- Radial nerve
E- Brachial artery
Ans: C
Explanation:
- Most common carpal bone fracture – Scaphoid (Radial Artery)
- Most common dislocated carpal Bone – Lunate (Median Nerve – Carpal tunnel)
- Fracture of hook of hamate – Ulnar nerve damage (Cuboidal tunnel)
- Anatomical snuff box pain – Radial artery

241- Breast of adult female lies over?
A- Pectoralis major
B- Superior pectoral fascia
C- Pectoralis minor
D- Serratus anterior
Ans: B

242- A man in RTA had fractured medial side of clavicle pressing posteriorly on [illegible] sternoclavicular joint. Damage to [illegible]ructure will be done?

243- Lattismus dorsi nerve supply is:
A- Median nerve
B- Accessory nerve
C- Axillary nerve
D- Long thoracic
E- Thoracodorsal
Ans: E(KLM)

244- Medial collateral ligament damaged at elbow which nerve is involved:
A- Median nerve
B- Radial nerve
C- Ulnar nerve
D- Axillary nerve
Ans: C

245- Anterior and posterior circumflex humeral artery branches of:
A- Brachial artery
B- Intercostal artery
C- Axillary artery
D- Internal mammary artery
Ans: C

246- Claw hand produced by unopposed action of:
A- Flexor digitorum longus and flexor digitorum profundus
B- Extensor digitorum longus and extensor digitorum indices
C- Extensor digitorum and flexor digitorum superficialis
D- All
Ans: C

247- Clavipectoral fascia pierced by:
A- Basilic vein
B- Thyrocervical trunk
C- Medial thoracic artery
D- Lateral pectoral nerve
E- Cephalic vein
Ans: E

248- Powerful Supinator of forearm:
A- Bicep Brachii
B- Brachioradialis
C- Supinator
D- Tricep Brachii
Ans: A

249- Vesicles below clavicle and above sternal angle is related to:
A- C5,6
B- C7,8

250- Lastismus dorsi nerve supply:
A- Axillary nerve damage
B- Long thoracic nerve damage
C- Radial nerve
D- Spinal Accessory nerve
E- Dorsal scapular nerve
Ans: E

251- Which muscle fixes scapula to medial border of vertebral column?
A- Rhomboids
B- Serratus anterior
C- Latissimus dorsi
D- Pectoralis minor
Ans: A

252- All small muscles of hand supplied by:
A- Radial nerve
B- Ulnar nerve
C- Median nerve
D- Rami of T1
Ans: D
Explanation:
Small Muscle of Hand supplied by – C8-T1 >Ulnar+Median> T1 > Ulnar

253- Median nerve damaged superficial to flexor retinaculum, which lesion will occur?
A- Loss of opposition of thumb
B- Loss of abductor pollicis brevis
C- Loss of sensations of proximal middle and index finger
D- Loss of forearm sensation
Ans: A

254- Thumb flexion is caused by:
A- Anterior or posterior interosseal nerve
B- Deep branch of ulnar nerve
C- Superficial branch of ulnar nerve
D- Radial nerve
Ans: B

255- Cervical fascia encloses which muscle in it:
A- Scalene anterior
B- Scalene medius
C- Trapezius muscle
D- Serratus anterior
E- Lattisnus dorsi
Ans: C

266- Deltoid muscle nerve supply is:
A- Dorsal thoracic
B- Long thoracic
C- Median nerve
D- Axillary nerve
E- Ulnar nerve
Ans: D

267- Muscle attached by aponeurosis:
A- Palmaris longus
B- Orbicularis oculi
C- Gastrocnemius
D- Orbicularis
Ans: A

268- Posterior interosseous nerve supplies which muscles:
A- Bicep Brachi
B- Tricep Brachi
C- Anconeus
D- Supinator
Ans: D

269- Patient has weakness in flexion , supination and sensory loss on lateral side which of following nerve injury is responsible for this?
A- Brachial nerve
B- Ulnar nerve
C- Median nerve
D- Musculocutaneous nerve
E- Axillary nervee
Ans: D

170- Difficult to do venesection in cubital fossa from:
A- Median basalic vein
B- Cubital vein
C- Superficial communiting
D- Deep communicating
Ans: A

271- Losss of fingers extension and abduction after injury to Left Elbow due to damage of:
A- Post interosseous nerve
B- Ulnar nerve
C- Median nerve
D- Radial nerve
Ans: A

272- A patient is unable to open bottle cap his sensory sensation intact on thumb and index finger which nerve is likely damaged?
A- Ulnar nerve
B- Radial nerve
C- Median nerve
D- Musculocutaneous nerve
Ans: C

273- First rotator of arm is:
A- Infraspinatus
B- Teres minor
C- Supraspinatus
D- Scalene anterior
Ans: C

CamScanner

274- First group of lymph node of breast is
A- Behind pectoralis minor
B- Behind pectoralis major
C- Lateral to medial end of pectoralis minor
D- Deep in axilla related to Internal thoracic artery
Ans: D

275- In Lateral rotation of arm, muscle involved:
A- Teres major
B- Teres minor and infraspinatus
C- Chorachobrachialis
D- Bicep brachii
Ans: B

276- Medial side of scapula fractured which muscle is not damaged?
A- Supraspinatous
B- Infraspinatous
C- Rhomboid major
D- Rhomboid Minor
E- Levator scapulae
Ans: B

277- Most common site of rib fracture is:
A- Upper Ribs
B- Medial end of Clavicle
C- Angle of rib
D- Lateral end of rib
Ans: C

278- Which of the following muscles are involved in Erb's palsy?
A- Biceps, extensor metacarpal, pronator
B- Biceps, extensor digitorum, abductors
C- Bicep, latissimus dorsi, extensor metacarpal
D- Biceps deltoid, latissimus dorsi
E- Biceps, infraspinatous, brachialis, Deltoid
Ans: E

279- Extensor retinaculum second compartment contain which structure:
A- Abductor pollicis brevis
B- Extensor carpi radialis Longus
C- Flexor carpi radialis brevis
D- Extensor pollicis brevis
Ans: B

Explanation:
Extensor retinaculum 1st compartment has
- Extensor pollicis brevis
- Abductor pollicis longus

Extensor retinaculum 2nd compartment has
- Extensor carpi radialis longus
- Extensor carpi radialis brevis.

280- Sentinal Lymph node of Breast 1st drainage
A- Behind Pectorals major
B- Behind pectorals minor
C- Medial Bordes of Pectorals major
D- Along internal thoracic artery
Ans: D

281- A patient got injury after which he lost sensation of thumb , index and middle fingers with no loss of thenar or palmer sensation and loss of pincer grasp between thumb and index finger . Which of the following muscles is paralyzed
A- Policis longus
B- Opponens policis
C- Adductor policis brevis
D- Flexor Policis longus
Ans: B

282- Patient presented with complain of numbness of index finger and there is loss of sensation of index and middle finger due to damage of which nerve
A- Axillary nerve
B- Median nerve
C- Radial nerve
D- Ulnar nerve
Ans: B

283- A patient fell on outstretched hand and there is fracture of distal end of radius it is moved anteriorly and lateral this fracture is called
A- Colles fracture
B- Monteggia fracture
C- Galeze fracture
D- Bennate fracture
Ans: C

Explanation:
- **Bennete fracture** - Base of thum fracture 1st metacarpal
- **Boxer Fracture** -Fifth metacarpal fracture
- **Smith fracture** -Radius end fracture
- **Galeze fracture** - Middle to distal end of radius fracture with dislocation of radioulnar joint
- **Monteggia fracture** – Radial head dislocation and proximal ulna fracture

284- Damaged to the upper part of shoulder. The artery that is bleeding is a branch of which artery ?
A- Thyrocerevical trunk
B- Axillary
C- Maxillary
D- Brachial
Ans B

285- Thenar space abcess . Which structure will be affected
A- 1st lumbrical
B- Abductor policies
C- Ulnar nerve
D- Bicep brachi
Ans: A

286- Medial 2 lumbricals are fractured along with sensations & Function lost. Damage to which of the following nerve is probable?
A- Median nerve
B- Ulnar nerve
C- Axillary nerve
D- Radial nerve
Ans: B

Explanation
- 1st and 2nd lumbricals - median nerve
- 3rd and 4th lumbricals - deep branch of ulnar nerve

287- C5 and C6 roots of brachial plexus are damaged, the weakness would result in?
A- Loss of Abduction of fingers
B- Loss of sensation on the ventral part oflower thumb
C- Loss of extension at arm
D- Flexion of wrist
Ans: C

288- Deep to flexor retinaculum median nerve compression which muscle will be spared:
A- Opponence pollicis
B- Flexor pollicis brevis
C- Abductor pollicis brevis
D- Flexor Carpi radilais
E- First Two lumbricals
Ans: D

289- A patient after humerus fracture there is loss of sensation of hand and unable to open fist due to damage of which nerve
A- Axillary
B- Median
C- Radial
D- Ulnar
Ans: C

290- Injury result in damage to anatomical snuff box, unable to move thumb, unable to abduct wrist, which muscle of extensor compartment is damaged on lateral side ?
A- Extensor digitorum
B- Extensor pollicis previs
C- Extensor carpi radialis longus
D- Adductor brevis
E- Brachial artery
Ans: B

291- Patient standing with outstretched hands on his side, The line passing through Tip of scapula is at which verterbal level?
A- T2
B- T4
C- T5
D- T6
E- T7
Ans: E

292- Thoracodorsal nerve branch of
A- Lateral cord of brachial plexus
B- Medial cord of brachial plexus
C- Posterior cord of brachial plexus
D- Whole trunk of brachial plexus
Ans: C

293- Nerve compression between C5 and C6 compress which of following?
A- C4
B- C5
C- C6
D- C7
E- C3
Ans: C

Explanation:
- Nerve passes between C5 and C6 --C6
- Nerve Passes between L4 and L5 -- L4
- Disc Herniation between L4 and L5 affect which root -- L5
- Cervical roots till C7 exit above the vertebrae of corresponding number And C8 exit below Seven cervical vertebrae
- All thoracic and lumbar roots exit below the level of correspondent vertebrae
- In Disc Herniation though L 4 and L5 moves laterally as they move toward exit but symptoms usually occur due to L5 compression

294- Tricep muscle nerve supply is
A- Axillary nerve damage
B- Long thoracic nerve
C- Radial nerve
D- Spinal Accessory nerve
E- Thorocodorsal nerve
Ans: C

295- Sentinel lymph node of breast 1st drainage
A- Behind pectoralis major
B- Behind pectoralis minor
C- Medial border of pectoralis Major
D- Along internal thoracic artery
Ans: D

CamScanner

296- An individual was hit on dorsum surface of wrist joint which tendon might get damage while passing through Extensor retinaculum second compartment

A- Abductor pollicis brevis
B- Extensor carpi radialis Longus
C- Flexor carpi radialis brevis
D- Extensor pollicis brevis
Ans: B

Explanation:
- Extensor retinaculum 1st compartment has Extensor pollicis brevis
- Abductor pollicis longus
- Extensor retinaculum 2nd compartment has
- Extensor carpi radialis longus
- Extensor carpi radialis brevis.

297- A carpenter tightens the Nut by which muscle

A- Biceps brachi
B- Brachioradialis
C- Brachialis
D- Supinator
Ans: B

298- After mastectomy for breast carcinoma female developed loss of overhead abduction which is due to damage to

A- Axillary nerve damage
B- Nerve to Serratus anterior
C- Radial nerve
D- Spinal Accessory nerve
E- Thorocodorsal nerve
Ans: B

299- Patient presented with complain of numbness of index finger and there is loss of sensation of index and middle finger due to damage of which nerve

A- Axillary nerve
B- Median nerve
C- Radial nerve
D- Ulnar nerve
Ans: B

300- A female patient undergo radiotherapy of axilla due to Mets of breast Carcinoma. Now she is more prone to develop

A- Infection
B- Angiosarcoma
C- Metastatic CA
D- Abscess
Ans: B

301- A patient fell on outstretched hand and there is fracture of distal end of radius it is moved anteriorly and lateral this fracture is called

A- Colles fracture
B- Monteggia fracture
C- Galeze fracture
D- Bennate fracture
Ans: C

Explanation:
- Bennete fracture - Base of thum fracture 1st metacarpal
- Boxer Fracture -Fifth metacarpal fracture
- Smith fracture -Radius end fracture
- Galeze fracture - Middle to distal end of radius fracture with dislocation of radioulnar joint Monteggia fracture – Radial head dislocation and proximal ulna fracture

302- Damaged to the upper part of shoulder. The artery that is bleeding is a branch of which artery ?

A- Thyrocerevical trunk
B- Axillary
C- Maxillary
D- Brachial
Ans: B

303- In Malignancy of breast Nipple earliest lymph node to drain is

A- Internal mammary
B- Axillary
C- Apical
D- Intercostal
Ans: B

Explanation:
- Nipple drainge -- Ant. axillary (Pectoral)
- Upper lateral -- Ant. axillary mainly
- Lower lateral(Inferior) -- Ant. axillary + Sub diaphragmatic + Internal mammary.
- Medial Quadrant -- Mainly to Internal mammary (Internal thoracic)
- Lower Inner Medial Quadrant – Inferior Phrenic (Sub Diaphragmatic)
- Tail of Breast – Posterior (Scapular) Lymph Node

304- Path from axillary lymph flow to breast has which two parts:

A- Medial and lateral
B- Superior and anterior
C- Anteriorinferior to Posterolateral
D- Lateral and Superior
Ans: C

305- In carpal tunnel syndrome due to ulnar nerve involvement which muscle involved?

A- Abductor policis
B- Flexor carpi ulnaris
C- Extensor carpi ulnaris
D- Opponence pollicis
Ans: B

306- Injury to shoulder result in extended, medially rotated, pronated arm due to lesion of?

A- Upper trunk of brachial plexus
B- Lower trunk of brachial plexus
C- Musculocutaneous
D- Radial
Ans: A

307- Sensory Supply to medial one and half palmar and dorsal hand?

A- Radial
B- Medial
C- Ulnar
D- Musculocutaneous
Ans: C

308- Upper Outer lymphatic drainage of breast carcinoma includes which of the following?

A- Internal mammary lymph nodes
B- Subcapsular lymph nodes
C- Anterior Axillary lymph nodes
D- Diaphragmatic lymph nodes
Ans: C (KLM +BD)

309- A patient with hypothyroidism, has loss of sensation on palmar surface of index and middle finger. What other findings can be seen in this patient?

A- Loss of opposition of thumb
B- Loss of Little finger flexion
C- Loss of Sensation in hypothenar region
D- Loss of adduction of fingers
E- Sensory loss of index finger
Ans: A

Explanation:
- Carpal tunnel syndrome has these symptoms and signs which is commonly associated with pregnancy and hypotyroidism

310- Complete Crushed avulsion injury of Anterior compartment of arm will lead to:

A- Weak Supination
B- Loss of sensation on lateral side of arm
C- Complete Paralysis
D- Paralysis of Brachialis
Ans: A

311- Mastectomy of Patient done and a muscle was damaged after that patient can't adduct and extend and internally rotate the arm which muscle is damaged?

A- Serrartus anterior
B- Rhymbiod major
C- Pectoralis minor
D- Supraspinatus
E- Latismusdorsi
Ans: E

312- After trauma, patient loses sensory sensations on the lateral palmar surface of the hand and unable to flex index finger. Lesion in:

A- Median nerve
B- Radial nerve
C- Ulnar nerve
D- Axillary nerve
E- Musculocutaneous nerve
Ans: A

313- A patient presents with loss of lateral arm sensation, triceps muscle weakness, and loss of the triceps reflex. Which of the following is the most likely location of the nerve root damage?

A- C6-C7
B- C6-T1
C- C5-C6
D- C1-C2
Ans: A

314- Latissimus dorsi supplied by which part of brachial plexus:

A- Anterior
B- Posterior
C- Lateral
D- Upper
Ans: B

315- A person has sharp knife injury to upper medial aspect of arm, after which He is unable to Flex his elbow & having loss of cutaneous sensations on lateral aspect of forearm, the nerve injured is:

A- Median Nerve
B- Axillary nerve
C- Radial Nerve
D- Musculocutaneous Nerve
E- Ulnar nerve
Ans: D

CamScanner

316- A patient with a humeral fracture experiences nerve damage. After the injury, you are evaluating the potential for nerve regeneration. Which part of the nerve is least likely to regenerate successfully?
A- Nerve body
B- Proximal to the axon
C- Distal to the axon
D- Proximal to the dendrite
Ans: C

317- Young present with medial 2/3rd clavicle fracture medial part of clavicle is raised upward and anterior direction. Which muscle raised this clavicle part?
A- SCM
B- Trapezius
C- Accessory muscle
D- Long thoracic
Ans: A

318- Mastectomy of Patient done and a muscle was damaged after that patient can't adduct and extend and internally rotate the arm which muscle is damaged?
A- Serrartus anterior
B- Rhymbiod major
C- Pectoralis minor
D- Supraspinatus
E- Latismusdorsi
Ans: E

319- Injury result in damage to anatomical snuff box, unable to move thumb, unable to abduct wrist, which muscle of extensor compartment is damaged on lateral side?
A- Extensor digitorum
B- Extensor pollicis previs
C- Extensor carpi radialis longus
D- Adductor brevis
E- Brachial artery
Ans: B

320- A patient with inability to tight the screw and there is loss of supination muscle damage will be
A- Tricep
B- Biceps brachii
C- Coarcobrachilis
D- Pronator Teres
Ans: B

321- Injury to medial cord of brachial plexus weakness in flexion nerve involved would be
A- Brachial nerve
B- Ulnar nerve
C- Median nerve
D- Musculocutaneous nerve
Ans: D

322- Palmar aspect of hand injury leading to Pisiform damage Which structure lateral to pisiforum will be affected?
A- Ulnar artery and nerve
B- Flexor Carpi Radialis
C- Cutaneous branch of Median nerve
D- Flexor Carpi Ulnaris
Ans: D

323- Paralysis of Latissimus Dorsi Muscle:
A- Injury to Posterior cord of Brachial Plexus
B- Injury to Upper trunk of Brachial Plexus
C- Injury to Lower trunk of Brachial Plexus
D- Injury to Lateral trunk of Brachial Plexus
Ans: A

324- Winging of scapula due to damage to which nerve?
A- C5,6,7
B- C5,6,7,8,T1
C- C5,C6
D- C7,C8
Ans: A
Explanation:
- Long thoracic nerve C5 C6 C7 , supply to serratus anterior

325- A person cant open bottles.This is due to damage of which nerve?
A- Median nerve
B- Radial nerve
C- Ulnar nerve
D- Axillary nerve
E- Suprascapular nerve
Ans: A

326- The synovial sheath of the flexor pollicis longus muscle forms the
A- Thenar space
B- Radial bursa of the wrist
C- midpalmar space
D- Ulnar Bursa of the wrist
E- Digital synovial sheath for the index finger
Ans: B

327- While taking blood sample at cubital fossa which nerve is most likely to be injured?
A- Median
B- Unlar
C- Radial
D- Musculocutaneous
Ans: A

328- Patient is asked to grip the card between the index finger and thumb, Patient is unable to hold card between thumb and index finger, He Can't maintain Grip & drops the Card. Which nerve injury is checked in this?
A- Anterior interosseous nerve
B- Posterior interosseous nerve
C- Ulnar Nerve
D- Radial Nerve
E- Deep branch of Ulnar nerve
Ans: C
Explanation:
- If the patient is asked to grip a piece of paper between the thumb and the index finger, he or she does so by strongly contracting the flexor pollicis longus and flexing the terminal phalanx (Froment's sign)

329- A patient undergoes a mastectomy, during which a muscle located beneath the fascia is removed. Which movement is most likely to be affected?
A- Abduction of the arm
B- External rotation of the shoulder joint
C- Adduction of the arm
D- Flexion of the arm
Ans: A

330- A patient fell & experience anterior dislocation of shoulder joint but the range of Motion is not affected. Which of the following structures provides dynamic stabilization to glenohumeral joint?
A- Rotator cuff muscles
B- Coracohumeral ligament
C- Glenoid cavity
D- Glenohumeral Ligament
Ans: A

331- A patient presents with a swelling on the posterior aspect of the hand that becomes prominent on wrist flexion. There are no signs of inflammation, and the transillumination test is positive. What is the most likely diagnosis?
A- Lipoma
B- Ganglion cyst
C- Abscess
D- Cellulitis
Ans: B

332- Following a difficult delivery a baby is noted to have unilateral loss of function of intrinsic muscles of hand with accompanying numbness along the inner aspect of the hand. Baby most probably has which of the following?
A- Erb's palsy
B- Klumpke's palsy
C- Duchenne muscular dystrophy
D- Proximal myopathy
Ans: B

333- A young patient presents with a fracture of the medial two- thirds of the clavicle. The medial part of the clavicle is displaced upward and anteriorly. Which muscle is responsible for raising this part of the clavicle?
A- Sternocleidomastoid (SCM)
B- Trapezius
C- Accessory muscles
D- Long thoracic muscle
Ans: A

334- Major breast lymph nodes are parallel to which vessel
A- Along axillary vessels to axillary nodes(pectoral)
B- Along intercostal vessels to posterior thoracic nodes
C- Along internal thoracic artery to internal thoracic nodes
D- Along the axillary vessels to supraclavicular lymph nodes
Ans: A
Explanation:
- Sequence of major lymph node parallel along which vessel – Anterior axillary to pectoral.
- Sequence of lymph node parallel along which vessel – Internal thoracic.
- Nipple drainage – Ant. axillary (Pectoral).
- Path of Axillary lymph flow – Anterior and posterior.
- Quadrant of Breast Lymph – Medial and lateral

335- A patient is unable to abduct and adduct the fingers but sensation are intact which of the following is effected
A- Median nerve
B- Superficial branch of Ulnar nerve
C- Radial nerve
D- Axillary nerve
E- Deep branch of ulnar nerve
Ans: E

CamScanner

336- First part of Axillary artery ends at
A- Upper border of teres major
B- Upper border of pectoralis major
C- Upper border of pectoralis minor
D- Lower border of pectoralis minor
E- Lower border of teres major
Ans: C

Explanation:
- Axillary artery begins at the lateral border of the first rib as a continuation of the subclavian arteryand at the lower border of the teres major muscle ,it becomes the brachial artery
- The pectoralis minor muscle crosses in front of the artery and thus divides into three parts
- First part starts from the lateral border of the first rib to the upper border of the pectoralis minor muscle
- Second part lies posterior to the pectoralis minor muscle
- Third part starts from the lower border of the pectoralis minor muscle to the lower border of the teres major muscle
- (Ref:snell anatomy)

337- A patient is unable to touch his thumb to little finger due to damage of which of the following nerve
A- Median nerve
B- Radial nerve
C- Axillary nerve
D- Ulnar nerve
E- Musculocutaneous nerve
Ans: A

338- Median nerve injury at flexor retinaculum leads to:
A- Fattening of thenar eminence
B- Hypothenar wasting
C- Claw Hand
D- Cubital tunnel syndrome
Ans: A

339- Patient is unable to extend his thumb at metacarpophangeal joint where is the problem
A- Extensor pollicis longus
B- Extensor pollicis brevis
C- Flexor pollicis longus
D- Abductor pollicis longus
Ans: A

340- A carpenter can't do screw- tightening movements and loses supination. Which muscle is responsible?
A- Brachioradialis
B- Biceps brachii
C- Triceps
D- Pronator Teres
E- Supinator
Ans: B (RJ Last)

Explanation:
- Supination is the more powerful action and account is taken of this in the design of screws, which are tightened by supination.
- Supination is carried out by the biceps and supinator, the former being the stronger provided the elbow is in the flexed position.
- The muscles producing pronation are principally pronator uadratus and pronator teres

341- Patient with history of Midshaft traum to humerus leading to radial nerve damage. Which of the following will be affected?
A- Inferior part of deltoid sensation lost
B- Strip of posterior forearm sensation lost
C- Anterior palmar medial 3 fingers lost sensation
D- Lateral Palmar Sensation Lost
Ans: B

342- A carpentar damaged his Median nerve involving 1st & 2nd Lumbricals. Which muscle is involved?
A- 1st lumbrical
B- Abductor pollicis brevis
C- Extensor carpi ulnaris
D- Flexor Digitorum Profundus
Ans: A

Explanation:
- 1st and 2nd lumbricals - median nerve
- 3rd and 4th lumbricals - deep branch of ulnar nerve

343- A woman sustained trauma to the middle finger of her hand while spreading a bedsheet. Following the injury, her finger remains permanently flexed, and she is unable to fully extend the distal phalanx. Most Likely Diagnosis:
A- Trigger finger
B- Mallet finger
C- Boutonniere deformity
D- Distal phalanx Fracture
Ans: B

344- A patient with a wrist injury/laceration, previously treated by a quack, now presents with loss of sensation over the lateral two- thirds of the palmar surface of the hand. Which muscle is affected by the damaged nerve?
A- Adductor Pollicis
B- Abductor Pollicis Longus
C- 1 & 2 dorsal Interossei
D- 1st Lumbrical
Ans: D

345- A patient underwent Modified Radical Mastectomy with level 3 Lymph node dissection. A radiotherapy is planned post surgery. What will be its side effect?
A- Lymphedema
B- Shoulder weakness
C- Infection
D- Inflammation
Ans: A

346- A 26 year female patient present with a breast mass on clinical examination mass was freely moveable and non tender and does not attach to underlying structures all laboratory investigations was normal what should be the next step in management
A- Mammogram
B- Ultrasound
C- FNAC
D- CT scan
Ans: B (Bailey and Love)

Explanation:
- Mammography
- The sensitivity of mammography increases with age as the breast becomes less dence.
- Ultasound
- Ultrasound is particularly useful in younger age wiomen with dense breasts in whom mammograms are difficcult to interpret and in distinguishing cysts from well solid lesions .It can also be used to lacalize impalpable areas of breast pathology

347- Which of the following nerve injury causes Shoulder drop
A- Median Nerve
B- Ulnar Nerve
C- Musculocutanos Nerve
D- Axillary Nerve
E- Radial Nerve
Ans: D

Explanation:
- Dislocation of Shoulder Joint – Axillary nerve
- Fracture anatomical neck of humerus – Radial nerve
- Fracture surgical neck of humerus – Axillary nerve and posterior circumflex humeral artery
- Fracture shaft of humerus – Radial nerve and profunda brachii artery.
- Fracture medial epicondyle of humerus – Ulnar nerve and ulnar collateral artery.
- Supracondylar fracture of humerus – Median nerve and brachial artery

348- A patient has a radial nerve injury but does not exhibit wrist drop. Which muscle is most likely spared?
A- Extensor policis longus
B- Extensor pollicis brevis
C- Extensor carpi ulnaris
D- Extensor carpi radialis longus (ECRL)
Ans: D

Explanation:
- The radial nerve innervates the muscles responsible for wrist extension.
- Wrist drop occurs when the extensor muscles of the wrist are paralyzed due to radial nerve injury.
- The Extensor Carpi Radialis Longus (ECRL) is often spared because:
- It is innervated proximal to the radial nerve bifurcation into the superficial and deep branches.
- This early innervation ensures its function remains intact even in cases of distal radial nerve injury.
- The ECRL maintains partial wrist extension, preventing wrist drop

349- Patient was hitchhiking with a maladjusted rucksack. He woke up with loss of both elbow flexion and wrist extension while his arm was ABDUCTED. What structure was likely injured
A- Upper brachial plexus injury
B- Lower Brachial Plexus Injury
C- Axillary nerve Injury
D- Brachial Nerve
Ans: A

350- A student complains of shoulder pain after a long study session, what nerve will you excise to alleviate her symptoms
A- Accessory spinal nerve
B- C2
C- C3
D- phrenic nerve
E- Thorcodorsal nerve
Ans: B

351- Which of the following Complication is Specific to radical mastectomy
A- Lymphedema of the arm
B- Winging of scapula
C- Phrenic nerve damage
D- Brachial plexus of arm
Ans: B

CamScanner

352- Which muscle is supplied by the Dorsal Scapular Nerve?
A- Supraspinatus
B- Levator Scapulae
C- Trapezius
D- Latissimus Dorsi
E- Deltoid
Ans: B

353- Which of the following movement will be lost if trapezius muscle is injured
A- Protraction of scapula
B- Loss of lateral rotation
C- Pulling scapula medially
D- Elevation of scapula
E- Adduction
Ans: D

354- A Diabetic patient presents with sensation loss at the Tip of Index Finger which of the following Nerve is Likely involved
A- Median Nerve
B- Ulnar Nerve
C- Radial Nerve
D- Axillary Nerve
E- Musculocutaaenous nerve
Ans: A

355- Young female child fell on her outstretched hand. She was looked after by her mother she noticed tenderness around the 'anatomical snuff box' area. Which of the following bone is most likely fractured in this patient
A- Lunate
B- Hamate
C- Scaphoid
D- Pisiform
E- Trapazium
Ans: C
Explanation:
- Most common carpal bone Fracture – Scaphoid (Radial Artery)
- Most common dislocated carpal Bone – Lunate (Median Nerve – Carpal tunnel)
- Fracture of hook of hamate – Ulnar nerve damage (Cuboidal tunnel)
- Anatomical snuff box pain – Radial Artery

356- Injury to medial epicondyle resulting in Inability to abduct & adduct the hand & unable to place the paper between fingers. Injury to which nerve?
A- Radial Nerve
B- Median Nerve
C- Ulnar Nerve
D- Musculocutaneous Nerve
E- Lateral Cutaenous Nerve
Ans: C
Explanation:
- Both DAB: Dorsal interossei causing Abduction &
- PAD: Palmar interossei causing adduction are supplied by deep branch of the ulnar nerve

357- Fracture at proximal radius leading to deep branch damage, no wrist drop occurred.Which muscle is damaged?
A- Extensor carpi radialis longus
B- Extensor carpi radialis brevis
C- Extensor pollicis longus
D- Extensor pollicis Brevis
Ans: B

358- A patient is unable to abduct and adduct the fingers and also unable to adduct the thumb but sensation are intact which of the following is effected
A- Median nerve
B- Superficial branch of Ulnar nerve
C- Radial nerve
D- Axillary nerve
E- Deep branch of ulnar nerve
Ans: E

359- If brachial artery is cut Compensation of hemorrhage is by which of the following (Medicine Feb 2025)
A- Arterioles
B- Veins and venules
C- Capillaries
D- Lymphatics
Ans: A

360- Dye injected into anteriolateral shoulder after rotator cuff is likely found in (Medicine Feb 2025)
A- Subacromial bursa
B- Subscapular bursa
C- Ulnar bursa
D- Glenohumeral joint space
E- Olecrenon bursa
Ans: A

361- A patient is unable to adduct and medially rotate the shoulder joint. Which muscle is most likely damaged?(Medicine Feb 2025)
A- Deltoid
B- Latissimus dorsi
C- Teres major
D- Supraspinatus
Ans: C

362- Which of the following is the most reliable diagnostic method for detecting a scaphoid fracture? (Medicine Feb 2025)
A- CT scan
B- MRI or delayed X-ray
C- Initial X-ray
D- Ultrasound
Ans: B

363- A 35 year old patient sustains a mid humerus fracture complicated by nerve damage ,the effected nerve shows degeneration in one of its parts which part of the nerve is most likely degenerate following such a injury (Medicine Feb 2025)
A- Distal part of axon
B- Proximal part of axon
C- Cell body of the neuron
D- Myelin sheath
E- Nerolema
Ans: A

364- A 55 year old fmale who underwent mastectomy and level 3 axillary clearance now presents with arm swelling ,discomfort and restricted movement several weeks post surgery ,which of the following is most likely complication (Surgery Feb 2025)
A- Lymphatic obstruction
B- Seroma
C- Infection
D- Hematoma
E- Phlebitis
Ans: A

365- Herniation between C5, C6 leads to injury to? (Surgery Feb 2025)
A- C6 spinal nerve roots
B- C5 white rami
C- C6 white rami
D- C5 spinal nerve roots
Ans: A

366- Posterior cord of brachial plexus supply which of the following muscle (Surgery Feb 2025)
A- Latissimus dorsi
B- Pectoralis minor
C- Pectoralis major
D- Rhomboids
E- Suprainspinatus
Ans: A

367- A patient sustains an injury to the lower brachial plexus. Which of the following muscles is most likely to be paralyzed? (Surgery Feb 2025)
A- Flexor carpi radialis and Flexor digitorum profundus
B- Abductor pollicis longus and Extensor pollicis brevis
C- Extensor carpi radialis and Extensor digitorum
D- Opponens pollicis and Pronator teres
Ans: C

368- 35 year old complains of shoulder weakness and difficulty lifting objects overhead on examination, pushing against the wall reveals a medial lifted scapula on right side which of the following nerves is most likely injured (Gynae & Obs Feb 2025)
A- Long thoracic nerve
B- Axillary nerve
C- Accessary nerve
D- Dorsal scapular nerve
E- Thoracodosrsal nerve
Ans: A

369- A patient presents with swelling on the anterior aspect of the arm and experiences tingling in the lateral digits, yet the sensation over the thenar eminence remains intact. To relieve the pressure, a superficial incision is planned. Which nerve is most likely being targeted?(Radiology Feb 2025)
A- Ulnar nerve
B- Superficial branch of the median nerve
C- Median nerve
D- Radial nerve
Ans: B

370- A baby was spun around by the father and now presents with the hand in a semi-prone position while sitting. Injury to which joint is most likely? (Radiology Feb 2025)
A- Proximal radioulnar joint
B- Distal radioulnar joint
C- Humeroulnar joint
D- Scaphoid joint
Ans: A

371- A 45-year-old office worker presents with numbness, tingling, and pain in the first three fingers of her right hand, which worsens at night. She also reports weakness in her grip and frequent dropping of objects. On examination, there is thenar muscle atrophy.Which of the following tests is most commonly used to diagnose this condition?(Anesthesia Feb 2025)
A- Phalen's test
B- Tinel's sign
C- Finkelstein's test
D- Allen's test
Ans: A

CamScanner

372- A lady presents with pain on the dorsum of her wrist that radiates to her index finger for the past three months. Her symptoms are suggestive of a single nerve injury. Which nerve is most likely affected? (Anesthesia Feb 2025)

A- Median nerve
B- Ulnar nerve
C- Radial nerve
D- Musculocutaneous nerve

Ans: C

373- A tennis player presents with weakness in thumb movements. The posterior/deep branch of the radial nerve is trapped by which muscle? (Anesthesia Feb 2025)

A- Anconeus
B- Supinator
C- Brachioradialis
D- Extensor carpi radialis brevis
E- Pronator teres

Ans: B

LOWER LIMB QUICK HINTS

- ✓ Most commonly dislocated bone in the lower limb is – Patella
- ✓ Most common neuropathy in the lower limb is -- Compression of common peroneal nerve against neck of fibula
- ✓ Longest muscle in the body is – Sartorius
- ✓ Thickest nerve in the body is -- Sciatic nerve
- ✓ Largest bone of the body is -- Femur
- ✓ Largest & most complicated Joint in the body is -- Knee joint
- ✓ Largest sesamoid bone in body is – Patella
- ✓ Most common dislocated bone in lower limb - Patella
- ✓ Strongest ligament in the body is -- iliofemoral ligament
- ✓ Strongest tendon in the body is -- Tendocalcaneus
- ✓ Largest synovial cavity in the body is synovial cavity of the -- Knee joint
- ✓ Most commonly nerve used in the body for grafting is -- Sural nerve
- ✓ Most commonly used vein in body for grafting is -- Great saphenous vein
- ✓ Most commonly used muscle in the body for grafting is -- Plantaris & Palmaris longus
- ✓ Most common liagament tear of knee - MCL
- ✓ **Locking** muscle for knee is -- Quadriceps Femoris
- ✓ **Unlocking** muscle for knee is -- Popliteus
- ✓ **ACL injured** – Anterior Dislocation of Tibia
- ✓ **PCL injured** – Posterior Dislocation of Tibia
- ✓ **ACL injured** – Posterior Dislocation of Femur
- ✓ **PCL injured** – Anterior Dislocation of Femur…
- ✓ **Ankle Sprain(Inversion)** Ligament Injured – Lateral ligament >Anterior Talofibular >Calcaneofibular
- ✓ **Excessive Eversion** ligament Injured – Tibial Collateral (Medial)
- ✓ Dorsiflexion of foot by tibialis anterior and peroneus tertius
- ✓ Able to stand on toes but painful– Plantaris Rupture
- ✓ Can't stand on toes – Achiles Rupture
- ✓ Pain on walking and relieved by rest artery involved is -Popliteal artery
- ✓ Inversion by - Tibialis anterior and posterior
- ✓ Eversion by -Peroneus longus , Brevis and Tertius
- ✓ Inversion and eversion at subtalar joint
- ✓ Saphenous nerve accompany Great saphenous vein
- ✓ Sural nerve accompany small saphenous vein
- ✓ Deep peroneal nerve accompany anterior tibial artery
- ✓ **Head of Femur** Supplied by in **Adults** – Retinacular > Medial Circumflex artery
- ✓ **Head of Femur** Supplied by in **Child** – Obturator artery
- ✓ **Neck of Femur** Supplied by – Medial &Lateral Circumflex artery
- ✓ **Foot Drop** – Common peroneal nerve Injured
- ✓ Plantar surface of foot is supplied by– Posterior tibial nerve
- ✓ After RTA patient unable to dorsiflex and evertfooT , nerve damage – Common peroneal neve
- ✓ Nerve damage in blow to lateral side of knee- Common peroneal
- ✓ Femoral arterial pulse – Mid inguinal point
- ✓ CPN normal function is dorsiflexionand eversion so when tibial nerve gotdamage CPN function enhanced andFoot become permanent dorsiflexedand everted.
- ✓ After RTA short leg and lateral rotated damage of - Neck of femur
- ✓ Remnant of Epiphyseal plate -**Epiphyseal line**
- ✓ Limb growth affected if fracture of - **Epiphyseal plate**
- ✓ Linea Aspera medial lip join pectineal line and lateral lip join Gluteal tuberosity.
- ✓ Hip and knee both Flexed – Sartorius
- ✓ Hip Flexed and knee Extend – RectusFemoris
- ✓ Hip Extend and Knee Flexed –Semitendinous
- ✓ Hip extend without knee flexed –Adductor Magnus
- ✓ Abduction of hip joint limited by-Pubofemoral ligament

CamScanner

- ✓ Extension of hip joint limited by -illeofemoral ligament
- ✓ Flexion of hip joint with knee extendedis limited by - Hamstring muscles
- ✓ Flexion of hip joint with knee flexed islimited by - Anterior abdominal wall
- ✓ Bone without muscular attachement – Talus
- ✓ Largest bone of foot – Calcaneum
- ✓ Most common tarsal bone fracture – Calcaneum
- ✓ Nerve affected in tarsal tunnel syndrome – Tibial
- ✓ Girl with high heels fall and her ankle ligament stretched – lateral ligament
- ✓ Injection Given in **Superior Lateral** Compartment to avoid Damage to **–Sciatic Nerve**
- ✓ Site of Pelvis sink its opposite sitemuscle will be damaged
- ✓ **Right Pelvis Sink** – Left Gluteus medius + minimus Damage
- ✓ Difficulty in standing from sitting –Gluteus maximus damage (Inferiorgluteal nerve).
- ✓ Waddling Gate – Gluteus medius andminimus damage (Superior glutealnerve)
- ✓ After femoral hernia repair, swelling over incision site due to damage of - Femoral vein
- ✓ **Inferior inguinal ligament thickened to form -** Fascia of thigh
- ✓ Femoral artery pulsation at midinguinal point
- ✓ Gluteal maximus form gluteal folds
- ✓ All muscles of anterior compartment of thigh supplied by femoral nerve except – Psoas muscle
- ✓ All lumbricals and introssei supplied bylateral plantar nerve except – 1st lumbrical
- ✓ Nerve spared in epidural anasthesia – S1 , S2

Medial longitudinial arch

Muscles

- ✓ Flexor hallucis longus (Bowstring)
- ✓ Tibialis Posterior
- ✓ Tibialis Anterior
- ✓ Flexor digitorum longus
- ✓ Abductor hallucis
- ✓ Medial half of flexor digitorum brevis

Support

- ✓ Main Ligament for medial longitudinal arch - Calcaneonavicular
- ✓ Main support of medial longitudinalarch overall/Anteriorly – Talus.
- ✓ Main support of medial longitudinalarch posteriorly – Calcaneum

Lateral longitudinal arch

Muscles

- ✓ Tendon of peroneus longus (Mostimportant)
- ✓ Lateral two tendons of flexor digitorumlongus
- ✓ Lateral half of flexor digitorumbrevisand abductor digiti minim
- ✓ Peroneus brevis and tertius

Support

- ✓ Main support of lateral longitudinalarch – Cuboid

Structures passing through lesser sciatic foramen

- ✓ Nerve to obturator internus
- ✓ Tendon of obturator internus
- ✓ Pudendal nerve
- ✓ Internal pudendal vessels

Structures passing through greater sciatic foramen

Above piriformis

- ✓ Superior gluteal nerve
- ✓ Superior gluteal vesssels

Below piriformis

- ✓ Sciatic nerve
- ✓ Posterior cutaneous nerve of thigh
- ✓ Inferior gluteal nerve
- ✓ Inferior gluteal vessels
- ✓ Internal pudendal vessel
- ✓ Pudendal nerve
- ✓ Nervw to obturatorinternus
- ✓ Nerve to quadratus femoris

Femoral triangle

wedge-shaped area formed by a depression between the muscles of the thigh. It is located on the medial aspect of the proximal thigh.

- ✓ Lateral border- Sartorius
- ✓ Medial border- Adductor Longus
- ✓ Base or superior border-Inguinal Ligament
- ✓ Apex – joining of medial and lateral border
- ✓ Floor – (medial to lateral) APPI (adductor longus, pectineus, psoas major and illiacus muscles).
- ✓ Roof - formed by the fascia lata, superficial fascia, and the skin

Contents of the femoral triangle (NAVEL) lateral to medial

- ✓ N Femoral Nerve
- ✓ A Femoral Artery
- ✓ V Femoral Vein
- ✓ E Femoral Canal (Empty Space)
- ✓ L Lymphatics

Joints of lower limb

- ✓ Hip joint – synovial ball and socket joint
- ✓ Knee joint – synovial hinge variety
- ✓ Synovial joint – Synovial Plane gliding
- ✓ Inferior tibiofibular – Fibrous
- ✓ Ankle joint – Synovial Hinge variety
- ✓ Subtalar – Synovial Plane

Joints causing muscles movements

Movement at hip joint

Extension

- ✓ Gluteus maximus
- ✓ Hamstring muscles

Flexion

- ✓ Sartorius
- ✓ Rectus femoris
- ✓ Iliopsoas

Lateral rotation

- ✓ Piriformis
- ✓ Obturator externus
- ✓ Obturator internus
- ✓ Quadratus femoris
- ✓ Superior and inferior gamellius

Medial rotation

- ✓ Gluteus medius
- ✓ Gluteus minimus
- ✓ Tensor fascia lata

Adduction

- ✓ Adductor longus
- ✓ Adductor brevis
- ✓ Adductor magnus

Abduction

- ✓ Gluteus medius
- ✓ Gluteus minimus
- ✓ Sartorius

CamScanner

- ✓ Piriformis
- ✓ Tensor fascia lata

Movement at knee joint

Flexors

- ✓ Semimemberanosus assist by gracilis, sartorius , popliteus
- ✓ Semitendinosus
- ✓ Biceps femoris

Extension – Quadriceps femoris muscle
Latreal rotation – Biceps femoris
Medial rotation – semitendinosus, semimeberosus

LOWER LIMB

1- Lateral side of foot is supplied by:
A- L3
B- S1
C- L4
D- T1
Ans: B

2- A boy fell from height, compression of sole of foot of which of following
A- Anterior arch of foot
B- Superior arch of foot
C- Tendon of peroneus longus
D- Inferior arch of foot
Ans: A

3- A boy had fall from height of 10 feet his talus bone was fractured. Talus is related to which arch in the foot:
A- Medial
B- Lateral
C- Medial and Horizontal
D- Horizontal
E- Vertical
Ans: A(BD)

Explanation:
- Main Support of Medial Longitudinal arch overall/Anteriorly – Talus.
- Main Support of Medial Longitudinal arch Posteriorly – Calcaneum.
- Main Support of Lateral Longitudinal Arch – Cuboid

4- Vertical group of inguinal lymph nodes receive drainage from?
A- Lower limb
B- Upper limb
C- Anal canal
D- Big Thumb
E- Rectum
Ans: A

5- A patient unable to rotate foot medially but can rotate laterally.Which group of muscles damaged:
A- Tibialis anterior/tibialis posterior
B- Tibialis ant/ flexor digitorum
C- Flexor pollicis longus
D- Tibialis posterior/Flexor Hallucis longus
Ans: A

6- External oblique muscle forms which ligament that lies in between the anterior superior iliac spine and pubic symphysis?
A- Lacunar ligament
B- Inguinal ligament
C- Femoral ligament
D- Scrotal ligament
Ans: B

7- A Patient with C Section 5 weeks ago and at the site of scar there is hard, tender, irregular swelling due to:
A- Incisional hernia
B- Scarring and deformation
C- Infection
D- Protruded omentum
Ans: B

8- Knee extended and locked in midstance position, due to lesion in which nerve?
A- Sciatic
B- Obturator
C- Femoral
D- Tibial
E- Popliteal
Ans: C

Explanation:
- Femoral nerve lesion cause Quadricep weakness. To prevent excessive flexion of knee particularly during midstance position patient compensate by maintaining knee in Extension and lock the knee in Extension thus reduces the need for activation of Quadriceps muscle

9- Which vein is used in Venepuncture:
A- Small Sephnous vein
B- Great sephanous vein
C- Sural Nerve
D- Femoral
Ans: B

10- Damage to the common peroneal nerve results in inability to:
A- Evert and dorsiflex the foot
B- Plantar flex the foot
C- Invert the foot
D- Loss of innervation of medial side of the leg
Ans: A

11- Small saphenous vein is accompanied by
A- Sural Nerve
B- Tibial Nerve
C- Femoral Nerve
D- Sciatic Nerve
E- Obturator Nerve
Ans: A

Explanation:
- Saphenous nerve accompany Great saphenous vein
- Sural nerve accompany small saphenous vein
- Deep peroneal nerve accompany anterior tibial artery

CamScanner

12- Great saphenous vein passes through which of the following?
A- Fossa ovalis
B- Inguinal canal
C- Femoral canal
D- Pubic tubercle
Ans: A

Explanation:
Great Saphnous vein passes through Opening in Fascia lata in thigh called Saphnous opening(Fossa ovalis

13- An old patient presents with short leg which is laterally rotated.Which fracture is suspected?
A- Tibia
B- Pubis
C- Neck of Femur
D- Sacrum
E- Hip joint dislocation
Ans: C

14- Neck of femoral hernia lies:
A- Medial and below pubic tubercle
B- Lateral and below pubic tubercle
C- Medial and below inguinal ligament
D- Lateral and below inguinal ligament
Ans: B

15- A Multiparous woman having non tender swelling in front of thigh below inguinal ligament, it is expansile and pulsatile, no history of fever and enlargement on Straining.Most likely Diagnosis is:
A- Femoral hernia
B- Saphenavarix
C- Femoral artery aneurysm
D- Psoas abscess
E- Inguinal hernia
Ans: C

16- A female patient presented with Incisional hernia. Which layer comesout first after skin and subcutaneous fats?
A- Cremesteric Fascia
B- Transversalis Fascia
C- Internal onlique
D- Rectus Abdominis
E- Conjoint tendon
Ans: B

17- Terminal branch of anterior tibial artery is which of the following?
A- Lateral Plantar Artery
B- Fibular Artery
C- Dorsalis Pedis Artery
D- Perforating Branch of Fibular Artery
E- Peroneal artery
Ans: C

Explanation:
Dorsalis pedis artery is the continuation of anterior tibial artery at the level of ankle joint

18- A man has been rejected by army due to flat foot.Medial arch of foot has main support from which muscle?
A- Peroneus longus
B- Peroneus Tertius
C- Lateral Flexor digitorim
D- Tibialis anterior and posterior
E- Flexor Hallucis longus
Ans: E (Grey's anatomy)

Explanation:
Medial longitudinial arch
Muscles
- Flexor hallucis longus (Bowstring)
- Tibialis Posterior
- Tibialis Anterior
- Flexor digitorum longus
- Abductor hallucis
- Medial half of flexor digitorum brevis

Lateral longitudinal arch
Muscles
- Tendon of peroneus longus (Most important)
- Lateral two tendons of flexor digitorum longus
- Lateral half of flexor digitorumbrevis and abductor digiti minim

19- During Anasthesia,Which nerve is commonly injured in lower limb?
A- Median nerve
B- Ulnar nerve
C- Common peroneal nerve
D- Sciatic nerve
E- Femoral nerve
Ans: C

Explanation:
- Over all – Ulnar >CPN
- Upper limb – Ulnar nerve
- Lower limb – CPN

20- Popliteal fossa lymph nodes involved in infection.Primary site infected will be:
A- Lateral dorsal surface of foot
B- Medial side of foot
C- Medial side of calf
D- Posterior side of calf
E- Medial side of thigh
Ans: A

21- Deep plantar artery is branch of:
A- Popiliteal
B- Peroneal
C- Posterior interosseous
D- Anterior interosseous
E- Dorsalis pedis
Ans: E

22- Which vascular part of fibula is used for bone grafting?
A- Middle
B- Upper
C- Lateral
D- Medial
Ans: A

23- L5 root value damage results in which of the following?
A- Ankle drop
B- Weak dorsiflexion
C- Loss of eversion
D- Loss of sensory supply
Ans: B

24- Footballer got injury to lateral malleolus. What will happen?
A- Loss of eversion
B- Loss of inversion
C- Loss of sensation of foot
D- Loss of planterflexion
E- Loss of sensation of dorsum of foot
Ans: A

25- On upper part of piriformis,which one passes?
A- Superior gluteal artery
B- Inferior gluteal artery
C- Inferior epigastric artery
D- Genital branch of genitofemoral nerve
E- Superior epigastric artery
Ans: A

Explanation:
Above Piriformis
- Superior Gluteal nerve
- Superior Gluteal vessel

Below Piriformis
- Inferior Gluteal nerve and vessel
- Sciatic nerve
- Posterior cutaneous nerve of thigh
- Nerve to quadratus femoris and obturator internus
- Pudendal nerve
- Internal pudendal vessel

26- Pain due to ovary felt at medial side of thigh due to which nerve involvement?
A- Obturator
B- Sciatic
C- Femoral
D- Pudendal
E- Tibial
Ans: A

27- Highest point of iliac crest at level of:
A- L5
B- L4
C- Anterior superior iliac spine
D- Inguinal ligament
E- Posterior spine
Ans: B

28- During Right inguinal hernia surgery, which structure is most probably seen
A- Pampiniform plexus
B- Spermatic cord
C- Femoral vien
D- Obturator vein
E- Femoral artery
Ans: A

29- Abduction of hip joint is limited by:
A- Pubofemoral
B- Ileofemoral
C- Ischiofemoral
D- Hamstring muscle
E- Abdominal wall
Ans: A

Explanation:
- Abduction of hip joint limitedby- Pubofemoral ligament
- Extension of hip joint limited by - illeofemoral ligament
- Flexion of hip joint with knee extendedis limited by - Hamstring muscles
- Flexion of hip joint with knee flexed is limited by - Anterior abdominal wall

30- Which of the following muscle causes hip and knee flexion?
A- Sartorious
B- Adductor magnus
C- Semitendinous
D- Gracilis
E- Semi membranous
Ans: A

Explanation:
- Hip and knee both flexed – Sartorius
- Hip flexed and knee extend – Rectus femoris
- Hip extend and knee flexed – Semitendinous
- Hip extend without knee flexed – Adductor magnus

31- Saphnous nerve is terminal branch of which of the following?
A- Tibial nerve
B- Posterior Cutaneous Femoral nerve
C- Superficial Peroneal nerve
D- Anterior Cutaneous femoral nerve
E- Sciatic nerve
Ans: B

CamScanner

32- Linea aspera of femur joins upward and medially to:
A- Pectineal line
B- Intertrochanteric line
C- Gluteal tuberosity
D- All
Ans: A (Grey's Anatomy)
Explanation:
- Linea aspera medial lip joinpectineal line and lateral lip join glutealtuberosity.

33- Which of the following ligament limits extension of Hip joint?
A- Pubofemoral
B- Ileofemoral
C- Ischiofemoral
D- Hamstring muscle
E- Abdominal wall
Ans: B
Explanation:
- Abduction of hip joint limited by – Pubofemoral ligament
- Extension of hip joint limited by – illeofemoral ligament
- Flexion of hip joint with knee extended is limited by – Hamstring muscles
- Flexion of hip joint with knee flexed is limited by – Anterior abdominal wall

34- Soleus muscle nerve supply is:
A- Femoral
B- Popliteal
C- Sural
D- Tibial
E- Obturator
Ans: D

35- Psoas muscle insertion is at:
A- Greater trochanter
B- Lesser trochanter
C- Tubercle
D- Shaft
E- Ilialtuberosities
Ans: B

36- Referred pain from ureteric colic is felt in thigh due to the involvement of the following nerve:
A- Subcostal
B- Iliohypogastric
C- Ilioinguinal
D- Genitofemoral
Ans: D
Explanation:
- Referred pain to groin and Loin byillioHypogastric and illioinguinal Nerve
- Referred pain to Thigh and Testicle byGenitofemoral Nerve

37- A patient presented with foot drop.Nerve involved?
A- Common peroneal nerve
B- Superficial peroneal
C- Femoral nerve
D- Obturator nerve
E- Tibial nerve
Ans: A

38- Athlete ran and felt pain in leg.Next day, he noticed swelling around the ankle joints although painful but able to stand on toes?
A- Plantaris
B- Acchiles
C- Politeus
D- Plantaris
Ans: A
Explanation:
- Able to stand – Plantaris
- Can't stand – Achiles

39- Patient in 40s presented with dilated and tortuous superficial veins with no other abnormality present. What's the cause?
A- Congenital absence
B- Incompetence/ incomplete closure of valves
C- Valve degeneration
D- increase pressure of vien
Ans: B

40- A player had an injury on lateral side of knee, which artery is at risk of damage?
A- Anterior tibial artery
B- Posterior tibial artery
C- Obturator artery
D- Femoral artery
Ans: A

41- Femoral pulse can be felt at:
A- Femoral canal
B- Mid inguinal point
C- Adductor canal
D- Mid part below inguinal canat
Ans: B
Explanation:
The femoral artery is a continuation of the external iliac artery. It begins behind the inguinal ligament where it lies midway between the anterior superior iliac spine and the pubic symphysis.

42- Tibial portion of sciatic lost, flexion of knee possible due to:
A- Long head of bicep femoris
B- Short head of bicep femoris
C- Tibialis anterior
D- Tibialispoaterior
Ans: B

43- Muscle attached by aponeurosis:
A- Palmaris longus
B- Orbicularis oculi
C- Gastrocnemius
D- Orbicularis
Ans: A

44- Blood supply to head of femur:
A- Medial Circumflex
B- Retinacular
C- Reticular
D- Tibial
Ans: B
Explanation:
- Head of Femur Supplied by in Adults – Retinacular > Medial Circumflex artery
- Head of Femur Supplied by in Child – Obturator artery
- Neck of Femur Supplied by – Medial & Lateral Circumflex artery

45- Artery running with deep peroneal nerve:
A- Posterior Tibial
B- Anterior Tibial
C- Femoral
D- Obturator
Ans: B

46- Patient in RTA has fracture of neck of fibula presented with inability to do eversion and dorsiflexion of foot. The damage has occurred to which nerve?
A- Peroneus longus
B- Peronuesbrevis
C- Tibial nerve
D- Common peroneal nerve
Ans: D

47- Patient sustained injuries in RTA, and then presented with gait problem. On examination he was asked to stand on his left leg, while doing so his Right pelvis sinks. Which of the following is most probably damaged?
A- Left gluteus maximus
B- Left gluteus medius
C- Right glutuesmedius
D- Right gluteus minimus
E- Right gluteus maximus
Ans: B

48- Adductor longus nerve supply?
A- Anterior part of obturator nerve
B- Posterior part of obturator nerve
C- Femoral nerv
D- Tibial Nerve
Ans: A

49- Adult femoral head blood supply?
A- Medial and lateral circumflex artery
B- Obturator artery
C- Neutrient artery
D- Tibial
Ans: A (No retinacular in options)
Explanation:
In adult
- Head of Femur by – Retinacular >Medial Circumflex
- Neck of Femur by – Medial And Lateral Circumflex
- In Avascular necrosis of Head of Femur – Medial Circumflex (FA)

In Child
- Head of femur by – Obturator

50- The muscle involved in unlocking of knee joint is:
A- Poplitius
B- Quadricep
C- Gluteus maximus
D- Gluteus Minimus
Ans: A
Explanation:
- Locking - Quadriceps
- Unlocking – Popliteus

51- Long head of bicep femoris is innervated by:
A- Fibular nerve
B- Femoral nerve
C- Tibial nerve
D- Deep peroneal nerve
Ans: C
Explanation:
- Short Head by fibular branch of sciatic nerve
- Long head is innervated via tibial nerve also the branch of sciatic nerve

52- Muscle causing eversion of foot:
A- Tibialis anterior
B- Tibialis posterior
C- Extensor digitorum longus
D- Peroneus longus
Ans: D

53- Which of the following is intra articular
A- Popliteus
B- MCL
C- LCL
D- Bicep femoris
Ans: A

54- Inguinal ligament is formed by the aponeurosis of:
A- External oblique muscle
B- Internal oblique muscle
C- Pisiforms
D- Transverse abdominus
Ans: A
(Inguinal ligament is formed by external oblique muscle and continuous with fascia lata of thigh).

CamScanner

55- Deltoid ligament restricts:
A- Dorsiflexion
B- Plantar flexion
C- Inversion
D- Eversion
Ans: D

Explanation:
Deltoid ligament plays and important role in ankle joint stability and it restrict lateral shifting and anterior displacement of talus.

56- Muscle responsible for dorsiflexion:
A- Tibialis anterior
B- Tibialis posterior
C- Gastroocenemius
D- Rectus femoris
Ans: A

57- Patient had difficulty in standing and waddling gait.Nerve involved:
A- Sciatic nerve
B- Femoral nerve
C- Obturator nerve
D- Superior gluteal nerve
Ans: D

Explanation:
- Difficulty in standing from sitting – Gluteus maximus damage (Inferior gluteal nerve).
- Waddling Gate – Gluteus medius and minimus damage (Superior gluteal nerve).

58- Infection of big toe is carried to which of the following lymph nodes:
A- Medial group of superficial inguinal lymph node
B- Lateral group of superficial inguinal lymph node
C- Vertical group of superficial inguinal lymph node
D- Femoral lymph nodes
Ans: C

59- Foot drop involves which nerve:
A- Sciatic nerve
B- Sup peroneal nerve
C- Anterior tibial nerve
D- Dorsalis pedis nerve
Ans: A

Explanation:
Sciatic nerve is the main that supplies all the muscles of leg below the knee if the muscles are paralyzed due to nerve injury it causes foot drop or planter flexion of foot , other brancges of sciatic nerve causes same condition are common peroneal nerve and Snell 604

60- Superficial inguinal ring is formed by
A- Psoas facia
B- Facia transversalis
C- External oblique aponeurosis
D- Internal oblique muscle
Ans: C

Explanation:
- Deep inguinal ring is formed by - fascia transversialis
- Superficial inguinal ring is formed by - external oblique aponeurosis

61- Which of the following is not attached to greater trochontner?
A- Gluteus maximus
B- Gluteus medius
C- Gluteus mininus
D- Obturaterinternus
E- Priformis
Ans: A (All the given muscle attach to greater tronchentor except gluteus maximus

Explanation
- **Origin:** Outer surface of iliac, coccyx, sacrum and sarcotuberous ligament
- **Insertion:** Iliotibial tract

62- Eversion of foot is caused by
A- Tibialis anterior
B- Proneus Longus
C- Tibialis posterior
D- Flexor polices longus
Ans: B

Explanation:
- Tibialis anterior à Strongest dorsiflexor of foot
- Tibialis posterior à Plantarflexion + Inversion
- Flexor Hallucis longus à Plantar Flexion of big toe

63- Root value of femoral nerve:
A- L1 – L2
B- L2 – L4
C- S1
D- T10 – T12
Ans: B

64- Adductor canal pus compression causes damage to which structure:
A- Femoral vein
B- Saphenous nerve
C- Superficial femoral artery
D- Sural Nerve
Ans: A

65- Cremasteric muscle nerve supply:
A- Genitofemoral
B- Bemoral
C- Obturato
D- None
Ans: A

66- A young boy is brought to the hospital after a bicycle accident and possible pelvic fracture. While awaiting a computed tomography (CT) scan of his pelvis, a physician proceeds with a focal neurologic examination. In testing the child's reflexes, which of the following nerves would carry afferent impulses of the cremasteric reflex?
A- Subcostal Nerve
B- Lateral Femoral Cutaneous Nerve
C- Genito-femoral Nerve
D- Iliohypogastric Nerve
E- Femoral Nerve
Ans: C

Explanation:
- Afferent – Femoral Branch of genitofemoral nerve and illioinguinal nerve.
- Efferent – Genital branch of genitofemoral nerve

67- Aponeurosis of internal oblique muscle forms:
A- Conjoint tendon
B- External oblique
C- Tranversfascua
D- Deep ring
Ans: A

Explanation:
- Conjoint tendon is formed by medial fibers of Internal oblique with fusion of fibers from transversusabdominus.
- Cremasteric fascia is deep continuation of internal oblique.

68- If a patient develops fracture of head of fibula, nerve damaged that will lead to foot drop will be:
A- Tibial nerve
B- CPN
C- Femoral nerve
D- Sciatic nerve
Ans: B

69- 60-year-old develop pain in calf muscles after walking 100yards Pain due to:
A- Popliteal artery
B- Popliteal vein
C- Tibial artery
D- Femoral artery
Ans: A

70- Loss of Knee Jerk due to damage to
A- L3
B- L4
C- L5
D- L6
Ans: A

Explanation:
- Bicep Jerk – C6
- Tricep Jerk – C7
- Knee Jerk – L3
- Knee Cap – L4
- Ankle Jerk – S1

71- Anterior cruciate ligament injury tibia dislocation
A- Anterior
B- Anteromedial
C- Anterolateral
D- Posterior
Ans: A

Explanation:
- ACL injured – Anterior Dislocation of Tibia
- PCL injured – Posterior Dislocation of Tibia
- ACL injured – Posterior Dislocation of Femur
- PCL injured – Anterior Dislocation of Femur

72- Numbers of valves in saphenous vein:
A- 20
B- 15
C- 10
D- 30
Ans: A

73- Footballer had a hard blow on lateral side of knee, the structure likely damaged is:
A- Lateral collateral ligament
B- Anterior cruciate ligament
C- Medial collateral ligament
D- Medial meniscus
Ans: C

74- Structure damaged at neck of fibula:
A- Anterior tibial artery
B- Posterior tibial artery
C- Tibial nerve
D- Tibial artery
Ans: A

75- Abdominal contents bulge through vaginal process with covering of spermatic cord?
A- Direct
B- Indirect
C- Femoral
D- Umbilical
Ans: B (Snell)

76- Regarding L4 dermatome:
A- Front of Foot
B- Front of calf
C- Skin around knee
D- Medial side of calf
Ans: C (Includes the knee caps)

CamScanner

77- **Fracture of acetabulum posterolaterally which bones are fractured?**
A- Pubis
B- Sacrum
C- Ischium & ilium
D- Public symphysis
Ans: C

78- **Medial to femoral hernia:**
A- Femoral vein
B- Lacunar ligament
C- Femoral artery
D- Femoral nerve
Ans: B

Explanation:
- Anterior – Inguinal ligament
- Posterior – Pectineal ligament
- Medially – Lacunar ligament
- Laterally – Femoral vein

79- **Muscles of abduction of Hip:**
A- Gluteus medius +Minimus
B- Gluteus Maximus
C- Obturator internus
D- Piriformis
Ans: A

80- **32-year-old carpenter fell from the roof. The lateral longitudinal arch of his foot was flattened from fracture and displacement of the keystone for the arch. Which of the following bones is damaged?**
A- Calcaneu
B- Cuboid bone
C- Head of the talus
D- Medial cuneiform
E- Navicular bone
Ans: B

Explanation:
- Main Support of Medial Longitudinal arch overall/Anteriorly – Talus.
- Main Support of Medial Longitudinal arch Posteriorly – Calcaneum.
- Main Support of Lateral Longitudinal Arch – Cuboid.

81- **Venous thrombosis most commonly present in:**
A- Lung
B- Leg
C- Heart
D- SVC
Ans: B

82- **Femoral artery is branch of:**
A- Internal illiac artery
B- External illiac artery
C- Internal pudendal
D- External pudendal
Ans: B

83- **Most common source of pulmonary embolism is**
A. Femoral vein
B. Popliteal vein
C. Saphenous vein
D. Superficial veins
Ans: A

Explanation:
- DVT common in – Popliteal vein
- Embolism source – Femoral vein

84- **A 35 year old male laborer presented with acute sudden pain starting from the lower lumber are and radiating along the posterior aspect of the left lower limb, his symptoms started after lifting heavy container 03 days back, on examination straight leg raising is restricted to only 30 degree on the left side decreased sensation along lateral boarder of left foot weakness of left flexor hallucis longus and diminished ankle jerk this patient has compression of which of the following:**
A- S1 root
B- S3 root
C- S4 root
D- S5 root
E- Sciatic nerve
Ans: A

85- **Head of femur blood supply in children:**
A- Retinacular Artery
B- Circumflex Artery
C- Obtruator Artery
D- Arcuate Artery
Ans: C

Explanation:
- Head of femur blood supply in children: Obtruator artery
- Head of femurblood supply in adults: Retinacular Artery

86- **Nerve that passes through superficial inguinal ring:**
A- Sciatic Nerve
B- Femoral Nerve
C- Ilioinguinal Neve
D- Obtruator Nerve
Ans: C

87- **Femoral sheath is formed by**
A- Fascia Ilica& Fascia Transversalis
B- Fascia Lata& Fascia Iliaca
C- Fascia Posas&Iliaca
D- None
Ans: A

88- **Squash Player lesser trochanter of femur injured which of the following muscle damaged**
A- Psoas
B- Sarotrius
C- Gluteus medius
D- Gluteus Maximus
Ans: A

Explanation:
Psoas muscle is attached to lesser trochanter of femur and will be damaged if lesser trochanter is damaged.

89- **Stability of knee joint is by:**
A- Vastus Medialis
B- Vastus Lateralis
C- Sarotrius
D- Adductor
Ans: B

Explanation:
- Stability of knee joint is by Vastus Lateralis
- Stability of Patella is by Vastus Medialis

90- **Supply of lateral skin of knee:**
A- Obturator nerve
B- Femoral nerve
C- Sciatic Nerve
D- Common perioneal nerve
Ans: B

Explanation:
The innervation to the lateral knee skin is variable from either the lateral femoral cutaneous nerve or branches of the femoral nerve.

91- **Which of the following is the main pillar of medial longitudinal arch of the foot:**
A- Talus
B- Calcaneum
C- Cuboid
D- Cuneiform
Ans: A

92- **Blow at anterior inferior iliac spine, muscle damaged in pelvic avulsion:**
A- Sartorious
B- Rectus Femoris
C- Obturator internus
D- Hamstrings
Ans: B

Explanation:
- Avulsion at inferior iliac spine muscle damaged: Rectus Femoris
- Avulsion at superior iliac spine muscle damage is: Sarotrius

93- **Operating on the inguinal hernia, surgeon found that the hernia is immediately medial to inferior epigastric artery, what type of hernia was the surgeon operating**
A- Indirect inguinal hernia
B- Direct inguinal hernia
C- Femoral hernia
D- Umbilical hernia
Ans: B

Explanation:
- Direct inguinal hernia lies medial to epigastric vessels.
- Indirect inguinal hernia lies lateral to epigastric vessels.

94- **Lateral side of foot and from the back and lateral side of calf lymphatic drains into:**
A- Vertical group Lymph node
B- Horizontal group lymph nodes
C- Inguinal lymph nodes
D- Popliteal lymph nodes
Ans: D

95- **Which of the following nerve supplies obtruator externus muscle:**
A- Anterior division of obtuator nerve
B- Posterior division of obtruator nerve
C- Femoral nerve
D- Sciatic nerve
Ans: B

Explanation:
Obtruatorexternus muscle is supplied by the posterior division of the obtruator nerve (l3 and l4) originating from the lumber plexus.

96- **Superficial thrombophlebitis involves which of the following?**
A- Saphenous Vein
B- Deep veins
C- Asymptomatic
D- Perforators
Ans: A

97- **Which of the following Hernia is associated with herniation through Hesselbach's triangle?**
A- Indirect Inguinal hernia
B- Direct Inguinal hernia
C- Femoral hernia
D- Lumber Hernia
Ans: B

Explanation:
- Direct inguinal hernia occurs through hesselbach's triangle & lies medial to Inferior epigastric vessels.
- Indirect Inguinal hernia lies lateral to inferior epigastric vessels.

CamScanner

98- At Mc Burney's point during appendectomy, the structure likely to be damaged is:
A- Femoral Nerve
B- Iliohypogastric Nerve
C- Deep Circumflex Artery
D- Superficial Circumflex Artery
Ans: B

Explanation:
- If structure or nerve mentioned then: Iliohypogastric nerve.
- If artery mentioned then: Deep Cirumflex Artery.

99- Which of the following muscle leads to Knee flexion & hip extension?
A- Sarotrius
B- Semitendinous
C- Adductor magnus
D- Rectus Femoris
Ans: B

Explanation:
- Hip & Knee flexion: Sartortius.
- Hip flexion & Knee extension: Rectus Femoris.
- Hip Extension & Knee Flexion: Semitendinosus.
- Hip Extension without knee flexion: Adductor Magnus.

100- Common peroneal nerve relation to bicep femoris tendon in popliteal fossa:
A- Medial
B- Lateral
C- Anterior
D- Posterior
Ans: A

101- Which of the following muscle flexes the hip joint?
A- Gluteus Maximus
B- Adductor magnus
C- Semimembraneous
D- Psoas
Ans: D

102- An old man falls from the bed, fractured the neck of femur. Cause of osteoporosis:
A- Poor diet
B- Decrease blood supply
C- Old age
D- Hormonal insufficiency
Ans: D

103- The nerve supply to the gracillis muscle is from:
A- Pudendal nerve
B- Iliohypogastric nerve
C- Obturator nerve
D- Both obturator and pudendal nerves
Ans: C

104- The nerve that causes dorsiflexion of the foot
A- Popliteal nerve
B- Deep peroneal nerve
C- Tibialnerv
D- Saphenous nerv
E- Superficial peroneal nerve
Ans: B

105- Medial border of inguinal triangle is formed by:
A- Lateral boarder of rectus abdominis
B- Inguinal ligament
C- Inferior epigastric vessels
D- Medial boarder of rectus abdominis
Ans: A

Explanation:
- Medial boarder is formed by Rectus abdominis
- Lateral boarder is formed by inferior epigastric vessels
- Inferior boarder is formed by inguinal ligamen

106- A patient with Sciatic nerve compression, root value is
A- S1
B- S2
C- S6
D- S4
Ans: A

107- Superficial inguinal LN drains:
A- Lower body of uterus
B- Cervix
C- Vagina above hymen
D- Ureter
E- Vagina below hymen
Ans: E

Explanation:
The vaginal orifice in a virgin possesses a thin mucosal fold called the Hymen. The hymen usually consists of tags.
- Upper1/3rd drain into ext. and int. iliac node
- Middle1/3rd drain into the internal iliac node
- Lower1/3rd into the superficial inguinal node

108- Root value of femoral and Obturator nerve?
A- L2 – L3
B- S1 – S2
C- T2 – T6
D- L1 – L2
E- L2 – L3 – L4
Ans: E

109- Damage to lateral thigh lateral popliteal nerve and eversion lost related to
A- L2
B- L3
C- Sciatic
D- L4
Ans: D

110- Dual nerve supply to which muscle?
A- Soleus
B- Quadratus femoris
C- Adductor Magnus
D- Gastrocnemius
Ans: C(BD)

111- Dorsum of foot is supplied by which of the following nerve?
A- Sural
B- Saphenous
C- Tibial
D- Superficial peroneal
Ans: D

112- Inversion of foot by which muscle?
A- Peroneus longus.
B- Peroneus tertius.
C- Tibialis posterior & anterior
D- Gastrocnemius
Ans: C

113- A young man presents with complain of low grade fever, generalized weakness, backache and swelling in front of thigh. On examination he has swelling above and below the inguinal ligament which disappears on lying down diagnosis?
A- Aneurysm of femoral Artery
B- Femoral hernia
C- Inguinal hernia
D- Psoas abcess
E- Sphenavarix
Ans: D

114- Regarding the pubic symphysis, what type of joint is?
A- Fibrous
B- Condyloid
C- Synovial
D- Primary Cartilaginous
E- Secondary Cartilaginous
Ans: E

Explanation:
Secondary cartilaginous joint examples
- Pubic symphysis
- Intervertebral joint
- Mandiburosternal joint

115- Patient having positive trendelenburg sign muscles involved:
A- Gluteus maximus
B- Sartorius muscle
C- Gluteus medius and minimus
D- Psoas
Ans: C

116- If contents go into processes vaginalis, and through the spermatic cord, what hernia?
A- Direct inguinal hernia
B- Umbilical hernia
C- Femoral hernia
D- Indirect inguinal hernia
Ans: D

117- A young lady complains of lower limb pain radiating to the back of the thigh below knee joint upto medial melleolus which root value of nerve involved:
A- L1
B- L2
C- L3
D- L4
E- L5
Ans: D

Explanation:
L4 dermatome supplies the medial side while L5 the lateral side

118- Regarding vessels of lower limb:
A- Cruciate anastmosis is b/w femoral artery and external iliac artery
B- Short saphenous starts from medial side of foot
C- Long saphenous ends in mid thigh
D- Femoral vein is lateral to femoral canal
Ans: D

119- In some children Dorsalis pedis Artery is missing congenitally. Then dorsum of foot will be supplied by which artery
A- Plantar Arch
B- Lateral plantar artery
C- Peroneal artery
D- Medial plantar artery
E- 1st metatarsal Artery
Ans: C

CamScanner

120- A child with infection blood is need for lab studies. Vensection done. Which structure will be damage
A- Saphenous nerve
B- Common peroneal nerve
C- Superficial peroneal nerve
D- Tibial nerve
Ans: A

121- Patient presented with injury to lower legs, it was fond that tibial part of sciatic nerve was damaged but still there was some flexion remaining in knee, what nerve is there:
A- Short head of bicep femoris
B- Long head of bicep femoris
C- Obturatorartrey
D- Retinaculurartrey
Ans: A

122- A 30 year female presented to ER after accident with short left leg and rotated laterally what is cause
A- Hip dislocation
B- Inferior gluteal N damag
C- Sup gluteal N damage
D- Femur Neck Fracture
Ans: D

123- Gluteus Maximus:
A- Covers pyriformis
B- Arises from gluteal tubercle
C- Supplied by inferior gluteal nerve
D- Supplied by superior gluteal nerve
Ans: C

124- Regarding Vastus medialis:
A- Supplied by femoral branch
B- Attached to intertrochanteric line
C- Attached to petala
D- Attached to medial tubrcl with vastsintermedius and adductor magns
Ans: A

125- Most effective in preventing DVT:
A- Intermittent Pneumatic compressions
B- Low dose of LMWH
C- Low dose of unfractioned heparin\
D- Warfarin
Ans: A

126- Regarding Great saphenous vein:
A- Forms behind medial malleolus
B- Ends at 3.5cm below and lateral to pubic tubercle
C- Receives only one tributary before joining femoral vein
Ans: B

127- A woman developed sciatic nerve compression at L5, what will happen?
A- Weakness of plantar flexors
B- Weakness of dorsiflexors
C- Absent ankle reflex
D- Brisk ankle relex
Ans: B

128- Peroneal artery is branch of
A- Posterior tibial artery
B- Lateral plantar artery
C- Medial plantar artery
D- Anterior tibial artery
Ans: A

129- Structure from medial to lateral in femoral triangle:
A- Nerve, Artery, Vein
B- Vein, Artery, Nerve
C- Nerve, Vein, Artery
D- None
Ans: B

Explanation:
Remember the word "VAN" for Structures from medial to lateral in femoral triangle that's vein, artery & nerve.

130- Inversion and eversion of foot on which joint:
A- Subtalar joint
B- Calcaneocuboid.
C- Talonavicular
D- Calcaneofibular joint
Ans: A

131- Which of the following muscle is a flexor of thigh at the hip joint?
A- Gracilis
B- Obturator externus
C- Adductor brevis
D- Psoas major
A- Tensor fasciae latae
Ans: D

132- Newly born child having ossification center at which of following?
A- Distal end of femur
B- Proximal end of tibia
C- Proximal end of humerus
A- Proximal Ulna
Ans: A

133- Gracilis muscle is innervated by which of the following?
A- Obturator nerve
B- Sciatic nerve
C- Pudendal nerve
D- Femoral nerve
B- Tibial
Ans: A

134- Adductor canal formed by
A- Vastus medialis and Adductor of thigh
A- Vastus lateralis
B- Gluteus maximus and medius
C- Adductor and Gluteus maximus
D-
Ans: A

135- A patient got Leg injury while going on a lift. Dorsiflexion lost due to Damaged nerve?
A- Superficial peroneal
B- Deep peroneal
C- Common peroneal at fibular neck
D- Tibial Nerve
Ans: C

136- Which of following muscle causes Extension without Knee Flexion?
A- Sartorious
B- Adductor magnus
C- Semitendinous
D- Gracilis
E- Semi membranous
Ans: B

Explanation:
- Hip and knee both Flexed – Sartorius
- Hip Flexed and knee Extend – RectusFemoris
- Hip Extend and Knee Flexed – Semitendinous
- Hip extend without knee flexed –Adductor Magnus

137- Lateral part of foot damaged during drill exercise of army cadet in PMA. Lymphatic drainage of it:
A- Superficial inguinal
B- Internal illiac
C- External illiac
D- Popliteal
A- Paraaortic
Ans: D

138- In femoral hernia neck of sac lies below and lateral to
A- Inferior epigastric artery
B- Inguinal ligament
C- Femoral nerve
D- Pubic tubercle
Ans: D

139- Bone that is devoid of Muscle attachment?
A- Lateral cuneiform
B- Medial cuneiform
C- Talus
D- Cuboid
E- Navicular
Ans: C

140- Nerve supply to lower limbs originate from
A- Lumbar + Sciatic nerve
B- Lumbar + Femoral nerve
C- Femoral nerve
D- Sciatic nerve
E- Lumbar plexus
Ans: A

141- Person playing cricket hit hard by ball on anterior surface of thigh which vessels is damaged ?
A- Popliteal artery
B- Tibial artery
C- Obturatory artery
D- Femoral profunda artery
Ans: D

142- Femoral hernia lies ?
A- Above inguinal ligament
B- Below inguinal ligament
C- Below lucnar ligament
D- Above lucnar ligament
E- Above pubic tubercle
Ans: B

Explanation:
- Inguinal hernia above and medial to inguinal ligament
- Femoral hernia below and lateral to inguinal ligament

143- Which nerve runs inferiorly along with anterior tibial artery ?
A- Tibial
B- Sural
C- Deep peroneal
D- Sciatic
Ans: C

144- Nerve supply of medial side of knee ?
A- L2
B- L3
C- L4
D- L5
Ans: C

145- Gluteal region injection site is
A- Superomedial quadrant
B- Superolateral quadrant
C- Inferolateral quadrant
D- Inferomedial quadrant
Ans: B

146- Lumbar hernia protrudes from
A- Superior lumber triangle
B- Inferior lumber triangle
C- Medial to intercostal
D- Lateral to intercostal
Ans: B

CamScanner

147- **Inferior inguinal ligament thickened to form:**
A- Fascia of abdomen
B- Fascia of thigh
C- Fascia of pelvis
D- Lacunar ligament
E- Inguinal sac
Ans: B

148- **Which one passes through sciatic notch?**
A- Adductor longus
B- Adductor magnus
C- Tibial nerve
D- Piriformis
Ans: D

Structure through Greater Sciatic Notch
- Piriformis

Above Piriformis
- Superior Gluteal nerve
- Superior Gluteal vessel

Below Piriformis
- Inferior Gluteal nerve and vessel
- Sciatic nerve
- Posterior cutaneous nerve of thigh
- Nerve to quadratus femoris andobturator internus
- Pudendal nerve
- Internal pudendal vessel

Through Lesser Sciatic Notch
- Tendon and nerve of Obturator internus
- Pudendal nerve
- Internal PudendalVes

149- **Nerve damaged in blow to lateral side of knee?**
A- Sciatic nerve
B- Common peroneal nerve
C- Tibial nerve
D- Sural nerve
E- Femoral nerve
Ans: B

150- **Anterior dislocation of Tibia ligament damaged is:**
A- Anterior cruciate ligament
B- Posterior cruciate ligament
C- Collatral ligament
D- Both Anterior Posterior
E- Deltoid ligament
Ans: A

Explanation:
- **ACL injured** – Anterior Dislocation ofTibia
- **PCL injured** – Posterior Dislocation ofTibia
- **ACL injured** – Posterior Dislocation ofFemur
- **PCL injured** – Anterior Dislocation ofFemur

151- **A patient after sciatic nerve injury is having difficulty from sitting to standing position.Which muscle will be likely injured?**
A- Gluetal muscles
B- Hamstring
C- Popliteus
D- Obturator internus
Ans: B

Explanation:
- Difficulty in standing from Sitting -Gluteus maxmimus damage
- Difficulty in standing from sitting + Sciatic nerve injury -Hamstring damage

152- **70-year-old women fallen from bed & femur was fractured, radiograph shows signs of osteoporosis. What is the probable cause?**
A- Diminished Blood Supply
B- Decrease Endocrine Activity
C- Disuse Atrophy
D- Decrease Nutrition
Ans: B

153- **Posterior cruciate Ligament resists:**
A- Anterior displacement of Tibial
B- Posterior displacement of femur
C- Anterior displacement of Fibula
D- Posterior displacement of tibia
Ans: D

154- **In adults, Injury to neck of femur.Which artery will be damaged?**
A- Medial Circumflex
B- Lateral circumflex
C- Retinacular artery
D- Posterior circumflex Artery
Ans: A (FA)

155- **Boy jump from height and talus is injured now has pain in foot. What will happen now?**
A- Deltoid ligament weakness
B- Medial longitudinal arch affected
C- Lateral longitudinal arch affected
D- Transverse arch affected
E- Lateral ligament affected
Ans: B

Explanation:
- Main support of medial longitudinalarch overall/Anteriorly – Talus.
- Main support of medial longitudinalarch posteriorly – Calcaneum.
- Main support of lateral longitudinalarch – Cuboid

156- **Patient presents with severe pain inthe ankle and develops ecchymosis on the second day. He can stand on his toes but its painful what is the cause:**
A- Rupture of Achilles tendon
B- Rupture of plantaris tendon
C- Rupture of tibial tendon
D- Medial Malleolous damage
E- Lateral Malleolous damage
Ans: B

Explanation:
- Able to stand – Plantaris Rupture
- Can_t stand – Achiles Rupture

157- **Plantaris is supplied by which nerve?**
A- Peroneal nerve
B- Femoral nerve
C- Obturator nerve
D- Tibial nerve
E- Popliteal nerve
Ans: D

158- **After Automobile accident female cannot flex and medially rotate thigh while climbing and Running due to damage:**
A- Tensor Fascia latae
B- Quadratus femoris
C- Gastrocnemius
D- Sartorius
Ans: D

159- **After femoral hernia repair, swelling over incision site due to damage of?**
A- Femoral vein
B- Femoral artery
C- Inferior epigastricartey
D- Sephanous vein
Ans: A

160- **Injury by a pierced rod lateral to tendon of extensor hallucus longus .Which artery will be injured?**
A- Femoral
B- Anterior Tibial
C- Dorsalis pedis
D- Popliteal
E- Posterior Tibial
Ans: C

161- **Loss of anterior thigh sensation due to damage**
A- Tibial nerve
B- Sciatic nerve
C- Obturator nerve
D- Gluteal nerve
E- Femoral branch of genitofemoral nerve
Ans: E

162- **Plantar surface of foot cutaneous innervation?**
A- Sural nerve
B- Sephanous nerve
C- Posteior tibial nerve
D- Deep peroneal nerve
Ans: C

163- **In Achilles tendon rupture, patient unable to do:**
A- Dorsiflexion
B- Planterflexion
C- Lateral rotation
D- Medial rotation
Ans: B

164- **Weaver's bottom is:**
A- Pateller bursitis
B- Prepattelar bursitis
C- Ischial bursitis
D- Olecrenon bursitis
Ans: C

165- **Hip fracture in area associated with sartorius:**
A- Anterior superior iliac spine
B- Ishial spine
C- Ilium
D- Pubis
Ans: A

166- **A patient came after RTA, having lesion at L5 and sciatica. What are the findings:**
A- Flaccid paralysis
B- Absent knee jerk
C- Positive babinski sign
D- Spastic paralysis
E- Upgoingplantars
Ans: A

167- **Nerve to ligamentum teres capitus is:**
A- Femoral
B- Obturator
C- Medial temporal
D- Lateral circumflex femoral
Ans: B

168- **Sole of foot sensation disturbance and loss of plantar flexion due to involvement of which nerve?**
A- Tibial nerve
B- Sural nerve
C- Sciatic nerve
D- Femoral nerve
E- Popliteal artery
Ans: A

CamScanner

169- Anterior dislocation of femur on tibia. Ligament damaged is:
A- Anterior cruciate ligament
B- Posterior cruciate ligament
C- Collatral ligament
D- Both Anterior Posterior
E- Deltoid ligament
Ans: B

Explanation:
- ACL injured – Anterior dislocation of tibia
- PCL injured – Posterior dislocation of tibia
- ACL injured – Posterior dislocation of femur
- PCL injured – Anterior dislocation of Femur

170- After trauma, there is injury to illioinguinal nerve there will be
A- Lateral thigh sensation lost
B- Loss of Dorsiflexion
C- Cremasteric reflex and Medial thigh sensation lost
D- Loss of Testicular reflex and lateral thigh sensation
Ans: C

171- After Sciatic nerve injury which muscle will be spared?
A- Bicep femoris
B- Adductor Magnus
C- Semitendinous
D- Gluteus maximus
Ans: D

172- Ball Hit on anterior thigh there will be damage to
A- Tibial nerve
B- Profunda femoris
C- Obturator nerve
D- Sciatic nerve
E- Sural nerve
Ans: B

173- A person who got bullet injury on Posterior thigh which muscle will be spared
A- Bicep femoris
B- Semitendinous
C- Semimembranous
D- Gluteus maximus
Ans: D

174- Thigh adducted, medially rotated and flexed by:
A- Sartorious
B- Gluteus maximus
C- Semimembranous
D- Obturator internus
Ans: A

175- A patient whose cuboid bone crushed by & run over accident by light vehicle which muscle will be affected
A- Tibialis anterior
B- Peroneus Longus
C- Peroneus Tertius
D- Tibialis posterior
Ans: D

176- Sprained ankle resulting from excessive eversion most likely demonstrates which structure is damage?
A- Talofibular ligament
B- Deltoid ligament
C- Tendon calcaneus
D- Interosseus ligament
Ans: B

Explanation:
- Inversion (Ankle Sprain) Ligament damage – Lateral Ligament>Talofibular >Calcaenofibular
- Eversion Ligament Damage – Medial Collateral (Tibial collateral ligament) or Deltoid ligament

177- Pain of indirect inguinal hernia is due to compression of which nerve in inguinal canal?
A- Iliohypogastric
B- Ilioinguinal
C- Femoral
D- Obturator
Ans: B

178- Injection given 2cm below and lateral to the pubic tubercle. Damaged nerve will be
A- Femoral
B- Obturator
C- Tibial
D- Sciatic
E- Sural
Ans: B

179- Content most likely to be seen in inguinal canal of female is
A- Suspensory ligament
B- Cardinal ligament
C- Round ligament and ilioinguinal nerves
D- Spermatic cord
E- Spermatic cord and inguinal nerve
Ans: C

Explanation:
- In male - Spermatic cord
- In Female - Round ligament and illioinguinal nerves

180- Deep inguinal ring is formed by which of the following?
A- Fascia transversalis
B- Fascia transversalis and conjoinedtendon
C- Conjoined tendon
D- External oblique fascia
E- Internal oblique fascia
Ans: A

Explanation:
- Deep inguinal ring - Fascia transversalis
- Superficial inguinal ring - External oblique

181- Nerve supply of Obturator internus is from
A- Tibial nerve
B- Femoral plexus
C- Sacral plexus
D- Sciatic nerve
E- Lumbar plexus
Ans: C

182- Structure not in spermatic cord but present in Inguinal canal:
A- Pampinoform plexus
B- Epididymys
C- Illioinguinal nerve
D- Ductus deference
Ans: C

183- Trauma to Lateral side of foot, lymphatics involved will be:
A- Vertical group LN
B- Popliteal LN
C- Horizontal LN
D- Medial group LN
Ans: B

184- Lymphatic drainage of tumour at anal verge:
A- Superficial inguinal LNs
B- Deep inguinal LNs
C- Lumbar lymph nodess
D- Pelvic lymph nodes
Ans: A

185- Which muscle cause Hip flexion and medial rotation
A- Sartorius
B- Semitendinous
C- Adductor Magnus
D- Psoas major
Ans: D

186- Patient has Fracture of Knee or femur distal end will cause injury to which deep structure in popliteal fossa
A- Popliteal artery
B- Popliteal vein
C- Nerve
D- Lymphatic's
Ans: A

187- Adductor muscles of thigh are supplied by:
A- Femoral nerve
B- Obturator nerve
C- Sciatic nerve
D- Common fibular nerve
Ans: B

188- Dorsalis pedis is terminal branch of
A- Tibialis posterior
B- Popliteal
C- Tibialis anterior
D- Femoral
Ans: C

189- Waddling gait is caused by damaged to which of the following nerve?
A- Inferior gluteal nerve
B- Superior gluteal nerve
C- Sciatic Nerve
D- Femoral Nerve
Ans: B

Explanation:
- Site of Pelvis sink its opposite site muscle will be damaged
- Difficulty in standing from sitting – Gluteus maximus damage (Inferior gluteal nerve).
- Waddling Gate – Gluteus medius and minimus damage (Superior gluteal nerve)

190- Deep peroneal nerve supplies which muscle?
A- Tibialis posterior
B- Gastrocnemius
C- Sartorius
D- Popliteus
E- Extensor digitorum longus
Ans: E

191- Loss of inversion of foot,Nerve involved will be:
A- Common peroneal nerve
B- Deep peroneal nerve
C- Superficial peroneal nerve
D- Femoral nerve
E- Tibial nerve
Ans: E

Explanation:
Dorsiflexion + Eversion - CPN
Plantarflexion + Inversion - Tibial nerve

192- Great saphenous vein graft taken from
A- Lateral malleolus
B- Tibial tuberosity
C- Posterior to Lateral melleolus
D- Anterior to medial malleolus
Ans: D

CamScanner

193- A patient present with foot drop and unable to do dorsiflexion and eversion of foot which nerve is damaged?
A- Sciatic nerve
B- Tibial nerve
C- Common peroneal nerve
D- Sural nerve
E- Femoral nerve
Ans: C

194- Meniscal tear occurs in
A- Full knee extension
B- Mid Extension
C- Fully flexed knee and Lateral rotation
D- Partial hip rotation
Ans: C

195- A patient has difficulty in going downhill due to involvement of which muscle
A- Popliteus
B- Adductor Longus
C- Biceps femoris
D- Sartorius
Ans: D

196- Main support of longitudinal arch of foot is formed by which structure?
A- Head of Talus
B- Sustantaculum Tali
C- Cuboid
D- Medial cuneiform
E- Calcaneum
Ans: A (No specific arch mention)
Explanation:
- Main support of medial longitudinal arch overall/Anteriorly – Talus.
- Main support of medial longitudinal arch posteriorly – Calcaneum.
- Main Support of Lateral Longitudinal Arch – Cuboid

197- Athlete playing high jump now presented with pain in gluteal region. On examination he cannot flex hip and extend knee at same time. Damage to which of the following?
A- Avulsion of anterior iliac spine
B- Ischial tuberosity fracture
C- Pubic symphysis fracture
D- Neck of femur fracture
Ans: A

198- A runner has pain upon moving against resistance at knee joint which muscle will be damaged
A- Soleus
B- Psoas
C- Popliteus
D- Gluetus
Ans: C

199- Foot is permanently dorsiflexed and everted. Which nerve is damaged?
A- Common Peroneal Nerve
B- Superficial Peroneal Nerve
C- Deep Peroneal Nerve
D- Saphenous Nerve
E- Tibial Nerve
Ans: E

Explanation:
- CPN normal function is dorsiflexion and eversion so when tibial nerve got damage CPN function enhanced and Foot become permanent dorsiflexed and everted.

200- A patient had trauma on duty doctor is unable to find vein for cannula which vein is best for IV in lower limb?
A- Small Sephnous vein
B- Great sephanous vein
C- Sural Nerve
D- Femoral
Ans: B

201- Lower limb supplied by:
A- MCA
B- ACA
C- PCA
D- Basilar
Ans: B

202- Structure passing above piriformis is:
A- Inferior gluteal nerve
B- Pudendal nerve
C- Sciatic nerve
D- Superior gluteal nerve
E- Femoral nerve
Ans: D
Explanation:
Structure through Greater Sciatic Notch
- Piriformis

Above Piriformis
- Superior Gluteal nerve
- Superior Gluteal vessel

Below Piriformis
- Inferior Gluteal nerve and vessel
- Sciatic nerve
- Posterior cutaneous nerve of thigh
- Nerve to quadratus femoris and obturator internus
- Pudendal nerve
- Internal pudendal vessel

Through Lesser Sciatic Notch
- Tendon and nerve of Obturator internus
- Pudendal nerve
- Internal Pudendal Vessel

203- Fracture of head of femur, lead to avascular necrosis of head artery involved is which of following?
Lateral circumflex
A- Descending branch lateral circumflex
B- Medial Circumflex Artery
C- Femoral Artery
D- Tibial Artery
E- C
Ans: C
Explanation:
In adult:
- Head of femur by – Retinacular >Medial circumflex
- Neck of femur by – Medial and Lateral circumflex
- In avascular necrosis of head of Femur medial circumflex (FA)

In Child:
- Head of femur by – Obturator

204- A patient got injury on medial side of knee and there is loss of sensation on medial side of leg and foot due to damage of which nerve:
A- Femoral nerve
B- Obturator nerve
C- Saphenous nerve
D- Tibial nerve
Ans: C

205- Common peroneal nerve damage at:
A- Shaft of femur
B- Neck of fibula
C- Neck of femur
D- Angle of Tibia
Ans: B

206- Herniation causes loss of ankle reflex which of following is root value of knee jerk?
A- L1-2
B- L2-3
C- L4
D- L4-5
E- S1
Ans: E

207- Knee reflex root value is:
A- L2
B- L4
C- S1,2
D- S3,4
Ans: B

208- The vein that is used in coronary bypass:
A- Femoral vein
B- Tibial vein
C- Popliteal vein
D- Great sephaneous vein
Ans: D

209- In Arterior tibial syndrome involving musculofascial compartment which artery involved?
A- Popliteal artery
B- Dorsal padis artery
C- Anterior tibial artery
D- Posterior tibial artery
Ans: C

210- Women works with bend knees, swelling and pain of knee due to involvement of:
A- Infrapatellar bursa
B- Popliteal bursa
C- Prepatellar bursa
D- Semitendenous bursa
Ans: C

211- What is palpated Midway between Ischial tuberosity and greater trochanter:
A- Piriformis
B- Tibial nerve
C- Sciatic nerve
D- Superior gluteal artery
Ans: C

212- Structure related to medial meniscus:
A- ACL
B- PCL
C- Tibial collateral ligament
D- Medial ligament
Ans: C

213- Deep peroneal nerve runs between:
A- 3rd and fourth toe space
B- First and 2nd toe space
C- Medial to ankle
D- Along fifth toe
Ans: B

214- Which of the following muscles is attached on lesser trochanter of femur?
A- Gluteus maximus
B- Glutues minimus
C- Gluteus medius
D- IlioPsoas muscle
Ans: D

215- Which of following muscle causes hip Flexion with knee extended?
A- Sertorius
B- Rectus femoris
C- Semitendinosus
D- Gracilis
E- Semi membranous
Ans: B
Explanation:
- Hip and knee both flexed – Sartorius
- Hip flexed and knee extend – Rectus femoris
- Hip extend and knee flexed – Semitendinous
- Hip extend without knee flexed – Adductor magnus

CamScanner

216- During Hip Surgery vessel to head of femur ligated which artery is main source of this vessel?
A- Internal iliac
B- External iilac
C- Popliteal
D- Tibial
E- Femoral
Ans: E

217- Wood fell down on laborers dorsum of foot between 1st and 2nd metatarsal bone- Artery most like damaged will be:
A- Dorsalis pedis
B- Medial plantar
C- Lateral plantar
D- Arcuate
Ans: A

218- Venesection of patient done now which nerve is likely to be damaged
A- Superficial peroneal nerve
B- Deep peroneal nerve
C- Sural nerve
D- Tibial nerve
E- Femoral nerve
Ans: C

Explanation:
Venesection is done on great saphenous vein mostly which is accompanied by Sural nerve so it likely to be damaged

219- A woman who is bedridden having SOB develop thromboembolism most likely source is:
A- Popliteal vein
B- Deep veins of legs
C- Saphenous vein
D- Tibial vein
Ans: B

220- Myotome of muscles causing extension of knee:
A- L5-6
B- L2-L3
C- L4-5
D- L5-S1
Ans: B

221- Most powerful flexor of hip:
A- Adductor Magnus
B- Sartorius
C- Gluteus medius
D- Iliopsoas
Ans: D

222- Great sephanous vein is approached at which site?
A- Anterior to medial malleolus
B- Posterior to medial malleolus
C- Lateral to medial malleolus
D- Medial to lateral malleolus
Ans: A

223- Heavy bleeding after injury between base of 1st and 2nd tarsal bones, which artery is involved?
A- Popiliteal
B- Peroneal
C- Posterior interosseous
D- Anterior interosseous
E- Dorsalis pedis
Ans: E

224- Injury of adductor hallucis, artery related is?
A- Popiliteal
B- Peroneal
C- Posterior interosseous
D- Anterior interosseous
E- Dorsalis pedis
Ans: E

225- Nerve supply of medial plantar side of foot:
A- Tibial nerve
B- Sural nerve
C- Sciatic nerve
D- Femoral nerve
Ans: A

226- Which one passes through greater sciatic foramen?
A- Adductor longus
B- Adductor magnus
C- Tibial nerve
D- Piriformis
Ans: D

Structure through Greater Sciatic Notch
- Piriformis

Above Piriformis
- Superior Gluteal nerve
- Superior Gluteal vessel

Below Piriformis
- Inferior Gluteal nerve and vessel
- Sciatic nerve
- Posterior cutaneous nerve of thigh
- Nerve to quadratus femoris andobturator internus
- Pudendal nerve
- Internal pudendal vessel

Through Lesser Sciatic Notch
- Tendon and nerve of Obturator internus
- Pudendal nerve
- Internal PudendalVes

227- Which of the following is posterior division of sacral plexus?
A- Nerve to quadratus femoris
B- Iuperior gluteal nerve
C- Inferior gluteal nerve
D- Common peroneal nerve
E- Tibial nerve
Ans: D

228- There is History of fracture, patient's knee flexors relaxed, examiner grasps tibial heads with both hands, leg moves anteriorly. Which ligament is damaged?
Lateral meniscus
A- Posterior cruciate ligament
B- Medial meniscus
C- Anterior cruciate ligament
D-
Ans: D

229- Sesamoid bone is:
A- Clavicle
B- Patella
C- Femur
D- Fibula
E- Larynx
Ans: B

Explanation:
Sesamoid bone - Patella
Sesamoid cartilage - Ala of nose >Larynx

230- If you palpate midway between ischial tuberosity and greater tromchanter it will be right above:
A- Superior gluteal nerve
B- Piriformis
C- Sacrospinous ligament
D- Infraspinous ligament
Ans: A

231- Patient is not able to perform plantar flexion due to damage of which nerve:
A- Femoral nerve
B- Sciatic nerve
C- Tibial nerve
D- Femoral nerve
E- Superficial peroneal nerve
Ans: C

232- Deep and anterior structure in popliteal fossa:
A- Popliteal artery
B- Poplitial vein
C- Tibial nerve
D- Common peroneal nerve
Ans: A

233- Plantar arch is branch from:
A- Popiliteal
B- Peroneal
C- Posterior interosseous
D- Anterior interosseous
E- Dorsalis pedis
Ans: E

234- Playing child got ankle sprain resulting in damage to:
A- Lateral malleolus
B- Medial malleolus
C- Menisci tear
D- Both a& b
Ans: A

235- Medial arch of foot is supported by which ligament?
A- Calcaneonavicular
B- Deltoid
C- Calcaneofibular
D- Talofibular
Ans: A

236- Muscles have different classifications according to their actions and features they are divided in different groups and sub groups, according to one classification, which of the following muscle is white muscle:
A- Masseter
B- Temporalis
C- Gastrocnemius
D- Buccinators
Ans: C

237- Loss of dorsiflexion and sensation on lateral dorsum due to damage of:
A- Sciatic nerve
B- Femoral nerve
C- Tibial nerve
D- Deep peroneal nerve
Ans: D

238- Structure passing through fossa ovalis is:
A- Small sephnous vein
B- Femoral vein
C- Great sephnous vein
D- Femoral artery
Ans: C

239- A primigravida with prolong labour in lithotomy position was unable to walk properly after delivery. She could not dorsiflex her right foot, which nerve got pressed?
A- Common peroneal
B- Sacral plexus
C- Sciatic nerve
D- Disc slipped
Ans: A

240- Common peroneal nerve related to bicep femoris:
A- Medially
B- Posteriorly
C- Anteriorly
D- Laterally
Ans: A

CamScanner

241- Femoral hernia gets strangulated due to?
A- Compression of femoral vein
B- Compression of femoral artery
C- Narrow neck of sac
D- Wide neck of sac
Ans: C

242- Directly related to hip joint
A- Inferiorly Obturator Externus
B- Sciatic Nerve Anteriorly
C- Psoas Bursa Posteriorly
C- Gluteus Medius
D- Inferiorly/Posteriorly
Ans: A

243- Knee reflex root value is:
A- L2
B- L3-4
C- S1,2
D- S3,4
Ans: B

244- Strongest ligament in body is:
A- Ischiofemoral
B- Iliofemoral
C- Pubofemoral
D- Rectofemoral
E- Puborectal
Ans: B

245- A patient has Pus in lumbar area which spread down. Which muscle is involved?
A- Sartorius
B- Psoas
C- Quadratus
D- Gluteus
Ans: B

246- Operating on the inguinal hernia, surgeon found that the hernia is immediately lateral to inferior epigastric artery, what type of hernia was the surgeon operating
A- Indirect inguinal hernia
B- Direct inguinal hernia
C- Femoral hernia
D- Umbilical hernia
Ans: A

247- Injection given at supero lateral quadrant to avoid damage to :
A- Sciatic nerve
B- Superior Gluteal nerve
C- Inferior gluteal nerve
D- Femoral nerve
Ans: A

248- Damage to adductor canal which structure will be spared ?
A- Femoral artery
B- Femoral vein
C- Sphenous nerve
D- Obturator nerve
Ans: D

Explanation:
- Adductor canal contain femoral artery , femoral vein and sephenous nerve and nerve to vastus medialis in upper part

249- In femoral hernia, Structure in femoral sheath?
A- Femoral canal
B- Femoral artery
C- Femoral vein
D- Obturator nerve
Ans: B

250- Medial menicsicus attached to knee through which liagment?
A- Lateral collateral
B- Anterior cruciate
C- Medial collateral
D- Posterior cruciate
Ans: C

251- A patient presents with massive thromboembolism. What's the site of it's origin ?
A- Popliteal veins
B- Deep veins of upper limb
C- Femoral artery
D- Tibial artery
Ans: A (Only suitable)

252- A lady presents after a trauma in a lift, on examination loss of dorsal sensation of Left foot with loss of dorsiflexion and loss of eversion at talotarsal joint . Which of the following nerve is damaged
A- Deep peroneal nerve
B- Common peroneal nerve
C- Deep peroneal nerve at neck of fibula
D- Sciatic nerve leision at mid thigh
Ans: B

253- A 25 Year old male with swelling at left inguinal region with positive cough impulse it moves when ispilateral testes is retracted downward it is painful this is likely
A- Congenital Encysted Hydrocele
B- Inguinal hernia
C- Femoral hernia
D- Incisional hernia
Ans: B

254- Patient did hyperextension of lower limb and now in semiflexed position due to involvement of?
A- Medial menisci
B- Patellar bursa
C- Posterior cruciate ligament
D- Anterior cruciate ligament
Ans: D

255- In injury to thigh ,what will be damaged at apex of femoral triangle?
A- Femoral artery
B- Femoral vein
C- Femoral nerve
D- Profunda femoris artery
Ans: D

256- A patient got firearm injury to lower limb and develop foot drop there is loss of dorsiflexion due to damage at
A- Shaft of femure
B- Neck of fibula
C- Neck of femur
D- Angle of Tibia
Ans: B (CPN damage)

257- While walking muscle that supports the opposite leg to be straight
A- Obturator internus
B- Obturator medius
C- Gluteus medius
D- Adductor Magnus
Ans: C

258- A person got ankle injury result in damage to medial malleolus and deltoid ligament this occur due to which of these
A- Lateral rotation
B- Inversion of foot
C- Excessive eversion of foot
D- Medial rotation of thigh
Ans: C

259- Most medial in popliteal Fossa:
A- Popliteal artery
B- Popliteal vein
C- Saphenous nerve
D- Femoral nerve
Ans: A

260- Most superficial content in adductor canal:
A- Femoral vein
B- Femoral artery
C- Popliteal artery
D- Sephnous vein
Ans: A

261- Abdominal pain and distension and absent cremasteric reflex due to
A- Iliohypogastric
B- Ilioinguinal
C- Genitofemoral
D- Posterior cutaneous nerve of thigh
Ans: C

262- Which of the following is attached to medial meniscus?
A- Tibial Collateral Ligament
B- Anterior Cruciate Ligament
C- Posterior Cruiciate Ligament
D- Medial Ligament
E- Popliteus
Ans: A

263- Unconscious boy of age 11, brought in the state of shock in Emergency. No peripheral vein accessible. Which vein of lower limb will be chosen for venesection in emergency?
A- Dorsal venous arch
B- Femoral vein
C- Great saphenous
D- Popliteal
E- Small saphenous
Ans: C

264- Sprained ankle resulting from excessive Inversion most likely demonstrates which structure is damage?
A- Anterior Talofibular ligament
B- Deltoid ligament
C- Tendon calcaneus
D- Interosseus ligament
E- Calcaneonavicular ligament
Ans: A

Explanation:
- Inversion (Ankle Sprain) Ligament damage – Lateral Ligament>Talofibular >Calcaenofibular
- Eversion Ligament Damage – Medial Collateral (Tibial collateral ligament) or Deltoid ligament

265- A patient got trauma on lower limb and there is loss of sensation on medial side of knee with pain extending to toe.Which nerve will be damaged?
A- Deep peroneal
B- Superficial peroneal
C- Tibial
D- Femoral
E- Sephnous
Ans: E

CamScanner

266- Which of the following major vessels gives main contribution in anastomosis around hip joint?
A- Internal iliac
B- Femoral
C- External iliac
D- Obturator
E- Pudendal
Ans: B

267- Patient has hx of renal TB. Fascia above & below thigh continuous with fascia of
A- Iliopsoas
B- Rectus femoris
C- Obturator fascia
D- Cremasteric fascia
Ans: A

268- Adductor Magnus is supplied by
A- Femoral nerve
B- Sciatic nerve
C- Obturator nerve
D- Tibial nerve
E- Common peroneal nerve
Ans: C

269- Bicep femoris supplied by
A- Femoral nerve
B- Sciatic nerve
C- Obturator nerve
D- Tibial nerve and Common peroneal nerve
E- Deep peroneal nerve
Ans: D

270- A lady presents after a trauma in a lift, on examination loss of dorsal sensation of Left foot with loss of dorsiflexion and loss of eversion at talotarsal joint. Which of the following nerve is damaged
A- Deep peroneal nerve
B- Common peroneal nerve
C- Deep peroneal nerve at neck of fibula
D- Sciatic nerve leision at mid thigh
Ans: B

271- Indirect inguinal hernia occurs due to defect in:
A- Conjoint tendon
B- Transversalis Fascia
C- Lucunar ligament
D- External oblique muscle
Ans: A (only suitable)

272- Operating on the inguinal hernia, surgeon found that the hernia is immediately lateral to inferior epigastric artery, what type of hernia was the surgeon operating
A- Indirect inguinal hernia
B- Direct inguinal hernia
C- Femoral hernia
D- Umbilical hernia
Ans: A

273- In Ankle injury patient got faint due to injury to
A- Lateral calcaneus
B- Body of talus
C- Tail of talus
D- Neck of talus
E- Lower end of fibula
Ans: E

274- Which muscle gets Dual blood supply by Tibial portion and CPN portion of Sciatic nerve
A- Adductor Magnus
B- Bicep femoris
C- Semitendinosus
D- Gluteal maximus
Ans: B

275- Lateral wall of deep ring of inguinal canal attaches
A- Transversus abdominis
B- Internal oblique
C- Fascia transversalis
D- External oblique
Ans: C

276- Damage to adductor canal which structure will be spared
A- Femoral artery
B- Femoral vein
C- Sphenous nerve
D- Obturator nerve
Ans: D

Explanation:
Adductor canal contain femoral artery , femoral vein and sephenous nerve and nerve to vastus medialis in upper part

277- In case of excessive inversion anterior talocalcaneal ligament is usually damage, along with it which fracture will most likely present
A- Lower end of tibia
B- Lower end of fibula
C- Lower end of femur
D- Upper end of femur
Ans: B

278- Sciatic and obturator nerve both supply which muscle
A- Gluteus maximus
B- Gluteus Longus
C- adductor Longus
D- Adductor Magnus
Ans: D

279- Superficial inguinal ring" is formed by?
A- Fascia transversalis
B- Internal oblique aponeurosis
C- Fascia transversalis and conjoined tendon
D- Rectus Sheath
E- External oblique aponeurosis
Ans: E

280- Patient did hyperextension of lower limb and now in semiflexed position due to involvement of
A- Medial menisci
B- Patellar bursa
C- Posterior cruciate ligament
D- Anterior cruciate ligament
Ans: D

281- Sprained ankle resulting from excessive Inversion most likely demonstrates which structure is damage?
A- Lateral ligament
B- Deltoid ligament
C- Tendon calcaneus
D- Interosseus ligament
E- Calcaneonavicular ligament
Ans: A

Explanation:
- Inversion (Ankle Sprain) Ligament damage – Lateral Ligament>Talofibular >Calcaenofibular
- Eversion Ligament Damage –Medial Collateral (Tibial collateral ligament) or Deltoid ligament

282- A patient got firearm injury to lower limb and develop foot drop there is loss of dorsiflexion due to damage at
A- Shaft of femure
B- Neck of fibula
C- Neck of femur
D- Angle of Tibia
Ans: B (CPN damage)

283- Patient sustained injuries in RTA, and then presented with gait problem. On examination he was asked to stand on his Right leg, while doing so his left pelvis sinks. Which of the following is most probably damaged?
A- Left gluteus maximus
B- Right gluteus medius and minimus
C- left glutuesmedius
D- Right gluteus minimus
E- Right gluteus maximus
Ans: B

Explanation:
- Site of Pelvis sink its opposite site muscle will be damaged
- Difficulty in standing from sitting – Gluteus maximus damage (Inferior gluteal nerve)
- Waddling Gate – Gluteus medius and minimus damage (Superior gluteal nerve)

284- While walking muscle that supports the opposite leg to be straight
A- Obturator internus
B- Obturator medius
C- Gluteus medius
D- Adductor Magnus
Ans: C

285- Which Ligament stabilizes the Hip joint? When u stand the ligament is taut & when you sit the ligament is relaxed?
A- Iliofemora Ligament
B- Pubofemoral Ligament
C- Ischiofemoral Ligament
D- Sacrotuberous Ligament
E- Sacrospinous Ligament
Ans: A

286- During Right inguinal hernia surgery, Which structure is most probably seen?
A- Pampiniform plexus
B- Spermatic cord
C- Femoral vien
D- Obturator vein
E- Femoral artery
Ans: A

287- Greatar sciatic foramen is located near greater sciatic notch.Which structure passes through it?
A- Piriformis
B- Gluteus maximus
C- Gluteus medius
D- Obturator externus
Ans: A

Explaination:
Structures passing through greater sciatic foramen
Above piriformis
- Superior gluteal nerve
- Superior gluteal vesssels

Below piriformis
- Sciatic nerve
- Posterior cutaneous nerve of thigh
- Inferior gluteal nerve
- Inferior gluteal vessels
- Internal pudendal vessel
- Pudendal nerve
- Nerve to obturator internus
- Nerve to quadratus femoris

CamScanner

288- Hyperextension of leg above table caused by
A- Sartorius
B- Semimembranous
C- Rectus femoris
D- Gluteus minimus
Ans: C

289- Injury to knee with semiflexed, femur moved posteriorly cause damage to which ligament?
A- Anterior cruciate
B- Posterior cruciate
C- Medial Collateral
D- Lateral Collateral
Ans: A
Explanation:
- ACL injured – Anterior Dislocation of Tibia
- PCL injured – Posterior Dislocation of Tibia
- ACL injured – Posterior Dislocation of Femur
- PCL injured – Anterior Dislocation of Femur

290- Which muscle action primarily causes the shortened and laterally rotated limb in a neck of femur fracture?
A- Rectus femoris
B- Iliopsoas
C- Adductors
D- Gluteus maximus
E- Gluteus medius
Ans: B

291- A boy had fall from height of 10 feet his talus bone was fractured. What will be affected
A- Medial longitudinal arch
B- Lateral longitudinal arch
C- Inversion
D- Eversion
E- Transverse arch
Ans: A(BD)
Explanation:
- Main Support of Medial Longitudinal arch overall/Anteriorly – Talus.
- Main Support of Medial Longitudinal arch
- Posteriorly – Calcaneum.
- Main Support of Lateral Longitudinal Arch – Cuboid

292- Stab injury to thigh with nerve damaged in adductor canal?
A- Femoral nerve
B- Sciatic nerve
C- Popliteal nerve
D- Obturator nerve
Ans: A

293- Medial Boundary of Inguinal Canal is formed by:
A- Lateral wall of Rectus Abdominus muscle
B- Lateral wall of Transversus Abdominus muscle
C- Lateral To inferior Epigastric Vessels
D- Lateral ineternal intercostal
Ans: A

294- A woodworker presented with Injury at the base of 1st and 2nd metatarsal bone.Artery damaged will be:
A- Medial Plantar artery
B- Dorsalis Pedis artery
C- Lateral plantar artery
D- Anterior Tibial artery
Ans: B

295- Unconscious boy of age 11, brought in the state of shock in Emergency. No peripheral vein accessible- Which vein of lower limb will be chosen for venesection in emergency?
A- Dorsal venous arch
B- Femoral vein
C- Great saphenous
D- Popliteal
E- Small saphenous
Ans: C

296- A boy was standing and his friend pushed him from behinD- The hip bent forwarD- What structure prevents femoral head to displace in anterior direction?
A- Ischiofemoral
B- Iliofemoral
C- Pubofemoral
D- Rectofemoral
E- Punorectal
Ans: B

297- A man stand from sitting poistion which reflex involve
A- Stretch reflex
B- Flexor reflex
C- Vestibular reflex
D- Spinal reflex
Ans: B

297- Lumber plexus supply which muscle
A- Adductor of thigh
B- Abductor of thigh
C- Abdominal muscles
D- Gluteal muscles
Ans: A

298- A patient whose patellar tendon struct +ve anterior drawer singn with leg pulled anteriorly is seen clinically in knee joint when there is?
A- Damage to fabular collateral ligaments
B- Damage to tibial collaterl ligaments
C- Damage Anterior cruciate ligaments
D- In patellar fracture
Ans: C

299- Muscle responsible for dorsiflexion:
A- Tibialis Anterior
B- Tibialis posterior
C- Gastroocenemius
D- Rectus femoris
Ans: A
Explanation:
Dorsiflexion of foot by:
- Tibialis anterior
- Peroneus tertius

300- A patient develops a swollen and tender lymph node in his popliteal fossa. An infected skin lesion in which of the following sites would most likely induce lymphadenopathy in this region?
A- Lateral side of the dorsum of the foot
B- Lateral side of the thigh
C- Medial side of the leg below the knee
D- Medial side of the sole of the foot
Ans: A

301- In a patient, hernia becomes obvious on coughing, lying medial to pubic tubercle:
A- Direct hernia
B- Indirect hernia
C- Umblical hernia
D- Epigastric hernia
Ans: A

302- In a patient with damage to the deep plantar arch, which of the following is affected?
A- Posterior tibial artery
B- Dorsalis pedis artery
C- Fibular artery
D- Anterior tibial artery
E- Medial plantar artery
Ans: B

303- Nail on wood fell down on laborers dorsum of foot between 1st and 2nd metatarsal bone- Artery most like damaged will be:
A- Dorsalis pedis
B- Medial plantar
C- Lateral plantar
D- Arcuate
Ans: A

304- Which nerve is responsible for numbness in the medial thigh and medial leg?
A- Sural
B- Saphenous
C- Tibial
D- Gluteal
E- Femoral
Ans: B

305- A patient presents with sudden onset of severe gluteal pain and discomfort. Upon examination, it is noted that the pain seems to radiate to the posterior aspect of the thigh. The physician suspects that a gluteal spasm may be compressing nearby structures.Which artery is most likely to be compressed or affected by a gluteal spasm in this case?
A- External iliac artery
B- Internal iliac artery
C- Femoral artery
D- Popliteal artery
Ans: B

306- A patient whose +ve anterior drawer singn with leg pulled anteriorly is seen clinically in knee joint when there is ?
A- Damage to fabular colateral ligaments
B- Damage to tibial colaterl ligaments
C- Anterior cruciate ligaments
D- In patellar fracture
Ans: C

307- A patient with injury to neck of fibula and there is Loss of dorsiflexion and sensation on lateral dorsum due to damage of
A- Sciatic nerve
B- Femoral nerve
C- Tibial nerve
D- Deep peroneal nerve
Ans:

308- Stab injury to anterior thigh leading to loss of knee jerk and medial thigh sensation lost nerve involved would be
A- Tibial nerve
B- Femoral nerve
C- Sephnous nerve
D- Sciatic nerve
E- Sural nerve
Ans: B

309- Hernia medial to Pubic tubercle crossing deep inguinal ring is:
A- Direct Inguinal Hernia
B- Indirect Inguinal Hernia
C- Femoral Hernia
D- Umbilical hernia
Ans: A

CamScanner

310- Which ligament prevents extensive flexion at hip joint with knee Extended?
A- Ischiofemoral
B- Iliofemoral
C- Pubofemoral
D- Rectofemoral
E- Punorectal
Ans: B

311- All of the following attach to greater trochanter except
A- Gluteus maximus
B- Obturator internus
C- Gluteus Medius
D- Gluteus Minimus
E- Piriformis
Ans: A

312- A patient presents with a right groin swelling located lateral and inferior to the pubic tubercle. What is the most likely diagnosis?
A- Hydrocele
B- Indirect hernia
C- Femoral hernia
D- Varicocele
Ans: C

313- Boy while playing damaged Medial meniscus. What will happen?
A- Damage to MCL
B- Swelling & Dislocation at patella
C- Locking of Knee
D- Unlocking of Knee
Ans: C

314- A trauma patient with severe bleeding is pale and hypotensive. Peripheral IV access is not achievable, and the femoral vein cannot be located for cannulation as it is extremely weak. What is the next step to administer fluids?
A- Saphenous vein (cutdown)
B- Central venous line through the subclavian vein
C- Femoral vein cutdown
D- Interosseous Line
Ans: B

315- If medial meniscus is damaged, what will happen:
A- Femur rotates on tibia
B- Spontaneous locking and unlocking phenomena
C- Do not repair quickly
D- Tibia rotates on femur
Ans: D

316- Patient presented with complain of Backache. Longest nerve Sciatic nerve arise from
A- Lumbar plexus
B- Sacral plexus
C- Lumbosacral plexus
D- Coccygeal plexus
E- Thoracolumbar plexus
Ans: C

317- A boy sustains an injury to the sole of his foot, resulting in profuse bleeding from the plantar artery. The injured plantar artery is a branch of which artery?
A- Peroneal artery
B- Anterior tibial artery
C- Dorsalis pedis artery
D- Posterior tibial artery
Ans: D

318- Massive pulmonary embolism arises from
A- Popliteal vein
B- Femoral artery
C- Saphenous vein
D- Tibial vein
E- Pelvic vein
Ans: A(no femoral vein was in options, if present then prefer that)

Explanation:
- DVT – Popliteal vein
- Embolism – Femoral Vein

319- Which of the following muscle will effected if sciatic nerve is damage
A- Hamstrings
B- Illiopsoas muscle
C- Gluteal muscles
D- Adductor longus
E- Quadriceps
Ans: A

320- Danger area of buttok region
A- Gluteal muscles
B- Sciatic nerve
C- Piriformis muscle
D- Superior gluteal nerve
E- Sacral plexus
Ans: B

321- A patient with a history of Spinal tuberculosis develops an infection that spreads through the fascia in the thigh. This infection is continuous with the fascia from the lumbar spine and eventually extends to the groin and inguinal region. Which muscle or fascia is most likely involved in this scenario?
Iliopsoas
A- Rectus femoris
B- Obturator fascia
C- Cremasteric fascia
D- Adductor Magnus
E-
Ans: A

322- A patient with history of Trauma. O/E, There is Loss of eversion but can dorsiflex along with Loss of sensations on dorsum of foot. Which muscle will be most likely affected by lesion of the involved nerve?
A- Tibialis anterior
B- Fibularis tertius
C- Fibularis longus
D- Tibialis Posterior
E- Abductor Hallucis
Ans: C

Explanation:
The clinical scenario describes a lesion of the superficial fibular (peroneal) nerve, which is responsible for foot eversion and provides sensory innervation to the dorsum of the foot.
- The loss of eversion indicates involvement of muscles innervated by the superficial fibular nerve, specifically:
- Fibularis longus
- Fibularis brevis
- The ability to dorsiflex suggests that the deep fibular (peroneal) nerve, which innervates the dorsiflexors (e.g., tibialis anterior), is intact

323- Women works with bend knees, swelling and pain of knee due to involvement of:
A- Infrapatellar bursa
B- Popliteal bursa
C- Prepatellar bursa
D- Semitendenous bursa
E- SuprA- patellar bursa
Ans: C(Snell)

Explanation:
- Bursitis is inflammation of a bursa (e.g., inflammation of the prepatellar bursa, or "housemaid's knee," may occur as the result of trauma from repeated kneeling on a hard surface)

324- Surgeon was doing Femur & Hip transplant surgery. If all the arteries of cruciate anastomosis are ligated in a patient undergoing femur head joint implantation, which artery will still supply femoral head?
A- 1st perforating branch
B- Inferior gluteal artery
C- Superior gluteal artery
D- Lateral circumflex femoral artery
E- Medial circumflex femoral artery
Ans: C

Explanation:
- The cruciate anastomosis is situated at the level of the lesser trochanter of the femur and, together with the trochanteric anastomosis, provides a collateral connection between the internal iliac and the femoral arteries.
- The following arteries take part in the anastomosis.
- Inferior gluteal artery
- Medial femoral circumflex artery,
- Lateral femoral circumflex artery,
- First perforating artery, a branch of the profunda artery.

325- Wood fell down on laborers dorsum of Foot near nail between 1st and 2nd metatarsal bone-Artery most like damaged will be:
A- Dorsalis pedis
B- Medial plantar
C- Lateral plantar
D- Anterior tibial
E- Peroneal artery
Ans: A

326- Patient has history of trauma to Gluteal region after which adduction of thigh is lost. Which of the following nerve is responsible for loss of Adduction?
A- Obturator Nerve
B- Femoral Nerve
C- Sciatic Nerve
D- Tibial Nerve
E- Inferior Gluteal Nerve
Ans: A

327- Nerve supply of the obturator externus
A- Posterior branch of obturator nerve
B- Femoral nerve
C- Lateral Cutaneous femoral Nerve
D- Nerve to obturator internus
E- Sciatic nerve
Ans: A

CamScanner

328- The Femoral Pulse is most likely palpated at
A- Mid Inguinal point
B- At apex of femoral triangle
C- In the middle of the thigh
D- Just lateral to the pubic tubercle
E- Mid point of inguinal ligament
Ans: A

Explanation:
- The femoral artery is a continuation of the external iliac artery. It begins behind the inguinal ligament where it lies midway between the anterior superior iliac spine and the pubic symphysis(Mid inguinal point)

329- Extension of Hip is restricted By
A- Iliofemoral ligament
B- Sacrotuberous ligament
C- Sacroiliac Ligament
D- Ischiofemoral ligament
E- Pubofemoral ligament
Ans: A

Explanation:
- Abduction of hip joint limited by – Pubofemoral ligament
- Extension of hip joint limited by – Illeofemoral ligament
- Flexion of hip joint with knee extended is limited by – Hamstring muscles
- Flexion of hip joint with knee flexed is limited by – Anterior abdominal wall

330- Which of the following nerve supply the vastus lateralis muscle
A- Obturator nerve
B- Femoral nerve
C- Sciatic nerve
D- Illioinguinal nerve
E- Pudendal nerve
Ans: B

331- Saphenous nerve is branch of
A- Lateral cutaneous nerve of leg
B- Medial cutaneous nerve of leg
C- Obturator nerve
D- Superficial peroneal nerve
E- Femoral nerve
Ans: E

332- Damage to the obturator nerve would result in the loss of motor supply to which of the following muscles?(Medicine Feb 2025)
A- Gluteus maximus
B- Sartorius
C- Gracilis
E- Semimembranosus
Ans: C
Nerve

333- A patient presents with pain and tenderness in the posterior knee region. Which muscle or tendon is most likely affected? (Medicine Feb 2025)
A- Plantaris
B- Gastrocnemius
C- Popliteus
D- Hamstrings
Ans: C

334- A man presents with a fibular fracture, but the common peroneal (fibular) nerve is not damaged. He has lost the ability for eversion, but there is no foot drop. Which muscle is most likely damaged? (Surgery Feb 2025)
A- Tibialis anterior
B- Tibialis posterior
C- Fibularis longus
D- Fibularis tertius
E- Adductor longus
Ans: C

Explanation:
The fibularis longus muscle is primarily responsible for foot eversion, along with the fibularis brevis. Since eversion is lost in this patient, it indicates damage to these lateral compartment muscles.
The lack of foot drop suggests the integrity of the anterior compartment muscles (e.g., tibialis anterior, fibularis tertius) and the common peroneal nerve.
- Tibialis anterior is involved in dorsiflexion, not eversion.
- Tibialis posterior is responsible for foot inversion.
- Fibularis tertius assists in dorsiflexion and eversion, but eversion loss is mainly due to fibularis longus and brevis damage.
- Adductor longus is unrelated to the foot and controls thigh adduction

335- A 55 years old Diabetic patient presents with chronic ischemic foot pain. Doppler ultrasound reveals occlusion of dorsalis pedis artery, with compensatory blood supply from artery of posterior leg, which artery is providing collateral circulation? (Gynae & Obs Feb 2025)
A- Anterior tibial artery
B- Posterior tibial artery
C- Popliteal artery
D- Peroneal artery
Ans: B

336- Which nerve is primarily involved in Tarsal Tunnel Syndrome? (Gynae & Obs Feb 2025)
A- Lateral plantar nerve
B- Medial plantar nerve
C- Posterior tibial nerve
D- Anterior tibial nerve
Ans: C

337- Tb spine, swelling above and below same side inguinal ligament. Which muscle fascia involved in tracking pus? (Radio Feb 2025)
A- Gluteus maximus
B- Psoas major
C- Sartorius
D- Adductor magnus
E- Adductor longus
Ans: B

338- Measuring BP from dorsalis pedis in standing position, what will be observation ? (Radio Feb 2025)
A- Higher than radial
B- Lower than radial
C- Equal to radial BP
D- Unpredictable variation
Ans: A

339- Doctor asked a junior to check the patellar reflex. Where to hit? (Anesthesia Feb 2025)
A- Medial collateral ligament
B- Medial patellar retinaculum
C- Lateral patellar retinaculum
D- Patellar ligament
Ans: D

340- Patient with ankle sprain due to excessive inversion while playing. Ligament damaged? (Anesthesia Feb 2025)
A- Deltoid
B- Anterior talofibular
C- Posterior talofibular
D- Calcaneonavicular
Ans: B

341- Common peroneal nerve most commonly damage at (Anesthesia Feb 2025)
A- Behind neck of fibula
B- where is divides into superficial and deep peroneal nerves
C- In the popliteal fossa
D- At Proximal thigh
E- Lateral auspect of knee
Ans: A

Explanation:
Injury to neck of fibula results in injury to:
- Anterior tibial artery
- Common peroneal (fibular.

342- Which of the following layer is encountered immediately after the transverse abdominus muscle in the abdominal wall (Anesthesia Feb 2025)
A- Fascia transversalis
B- Rectus abdominus
C- External oblique muscle
D- Rectus sheath
E- peritonuem
Ans: A

343- Adductors of thigh nerve supply? (Anesthesia Feb 2025)
A- Femoral nerve
B- Sciatic nerve
C- Obturator nerve
D- Tibial nerve and Common peroneal nerve
E- Deep peroneal nerve
Ans: C

CamScanner

Bronchopulmonary segment

- ✓ Aerated by tertiary bronchus
- ✓ Independent of each other
- ✓ Lower air divisions - 23
- ✓ Each segment has its own artery and brochus
- ✓ Right lung has 10 bronchopulmonary segments
- ✓ Left lung has 10bronchopulmonary segments

Random

- ✓ Infection anterior to paratracheal fascia spread to – Anterior mediastinum
- ✓ Thoracic duct drains into – Confluence of left subclavian and left jugular
- ✓ Arches over root of right lung – Azygous vein
- ✓ Loops around arch of aorta – Left recurrent laryngeal nerve
- ✓ Compression effects on esophagus by enlargement of – Left atrium
- ✓ Dilatation of aortic arch will compress – Left bronchus.
- ✓ Apex of Lung involve collapse segment will be -Apical superior
- ✓ Neurovascular bundle lies between Internal & innermost intercostal muscles
- ✓ Arterial emboli mostly arises from – Left atrium
- ✓ Left or right dominant supply of heart is determined by -- Posterior interventricular(Descending) artery.
- ✓ Great Cardiac vein accompany -- Left ant. Descending Artery
- ✓ Middle Cardiac vein accompany -- Post. Interventricular artery
- ✓ Small Cardiac vein accompany – Marginal artery
- ✓ Ant. Cardiac vein drains directly into -- RT. Atrium
- ✓ Left lobe – 5cm
- ✓ Right Lobe – 2.5cm
- ✓ Pain of angina from heart is carried by -- Sympathetic nerves
- ✓ Pain of pericarditis is carried by -- Phrenic nerve
- ✓ Fibrous Pericardium and Parietal layer of Serous Pericardium is supplied byPhrenic nerve
- ✓ Costal pleura – Intercostal Nerve
- ✓ Mediastinal pleura – Purely Phrenic Nerve
- ✓ Diaphragmatic pleura – Dome by partly by Phrenicnerve and peripheral part by Lower Sixintercostal nerve.
- ✓ Phrenic nerve damage – IpsilateralDiaphram paralysis >Loss of central tendon sensation
- ✓ Visceral layer of serous pericardium is called Epicardium
- ✓ Cervical rib arises from C7 And Compress T1
- ✓ Thoracic vertebrae – Heart shaped
- ✓ Lumbar vertebrae – Kidney shaped
- ✓ Patient can survive mechanical ventilation is lesion below – C5
- ✓ Epicardium supplied by – Coronary Artery
- ✓ Pericardium supplied by – Pericardiophrenic artery
- ✓ Visceral pericardium – Vagus nerve
- ✓ Fibrous pericardium – Phrenic nerve
- ✓ Anterior 2/3rd IV Septum supplied by – LAD (LCA)
- ✓ Posterior 1/3rd IV Septum supplied by – PDA (RCA)
- ✓ Left Circumflex supply – Left atrium and left Ventricle
- ✓ SA node located in – Upper one third Sulcus terminalis
- ✓ SA node located in – Sub Epicardium
- ✓ AV node located in – Endocardium
- ✓ Conducting system – Subendocardium
- ✓ Anterior 2/3 of interventricular septum is supplied by anterior interventricular artery (LADA) which is branch of left coronary artery.
- ✓ Posterior 1/3 is supplied via posterior interventricular artery (PDA) which is the branch of right coronary artery.

- ✓ Common site for fracture of rib- Angle of rib
- ✓ True Ribs – 1-7
- ✓ False Ribs – 8-10
- ✓ Floating Ribs –11-12
- ✓ Structure infront of root of lungs: Phrenic Nerve
- ✓ Structure behind the root of lungs: Vagus Nerve
- ✓ Structure which arches over root of right lung: Azygous Vein
- ✓ Structure which arches over root of left lung: Arch of Aorta
- ✓ **IVC Blocked Above Azygous vein** dilation in – Azygous vein > Left Gastric Vein
- ✓ **IVC Blocked Upto Azygous vein** dilation in – Right Ascending Lumber vein & RightSubcostal Vein
- ✓ **IVC Blocked Below Azygous vein** dilation in – Ascending Lumber vein
- ✓ T3 to T6 – Oblique Fissure of Lung
- ✓ T4 – 5 – Bifurcation of Trachea, Dermatome Nipple, Extent of Trachea = C6 to T4
- ✓ C3 – Hyoid in erect position
- ✓ C2 - C3 (C2>C3)Tracheal ring – Tracheostomy Level Adults
- ✓ C3 - C4 (C3>C4)Tracheal ring – Tracheostomy Level Children
- ✓ C6 – Cricoid Level (Esophagus and Trachea Starts)
- ✓ C2-3 — Supraclavicular
- ✓ C3-4 – Infraclavicular
- ✓ Esophagous Passed through -- Left Crus of Diaphragm (Big Snell)
- ✓ Medial Arcuate ligament formed by -- Psoas Muscle
- ✓ Median Arcuate ligament formed by – Right & Left Crura
- ✓ Moderator band is present in Right ventricle
- ✓ Neurovascular bundle located at lower border of uppe rib
- ✓ Thoracocentesis site - Lower border of 9th ICS and upper border of 9th Rib in mid axillary line
- ✓ The Superior Cervical Ganglion is located opposite the second and third cervical vertebrae.
- ✓ The inferior Cervical ganglion is located opposite to fourth and sixth cervical vertebrae.
- ✓ The middle cervical ganglion is the smallest of the three cervical ganglia and is occasionally absent, it's placed opposite to sixth cervical vertebrae.
- ✓ In Horner syndrome damage segement is: T1-T4
- ✓ Structure is injured behind the sternum - Internal thoracic
- ✓ Pericardiocentesis is best performed by passing a needle through - The 5th intercostal space left to sternum

Thoracic duct empties into

- ✓ Venous system near union of left internal jugular vein and left subclavian vein
- ✓ Left venous angle
- ✓ Origin of left brachiocephalic vein

Trachea

- ✓ Continuation of larynx at lower border of cricoid cartilage (c6)
- ✓ Bifurcates at the level of T4-T5
- ✓ 5 inch in length and 1 inch in diameter
- ✓ **Arterial supply** – inferior thyroid artery (upper 2/3rd), Broncial artery (lower 1/3rd)
- ✓ **Venous supply** – Inferior thyroid vein
- ✓ **Lymphatic drainage** – pre tracheal lymph nodes , para tracheal lymph nodes , inferior deep cervical lymph nodes

Relation in superior mediastinum

1. Anterior- sternum , thymus , let brachicephalicvien , origins of brachiocephalic , left common carotid artrey and arch of aorta
2. Posterior - esophagus and left recurrent larangeal nerve
3. Right side - azygousvien , right vagus nerve and pleura
4. Left side - arch of aorta , left common carotid , left subclavian arteries, left vagus nerve , left phrenic nerve and pleura

CamScanner

Esophagus

- ✓ Begins at lower border of cricid cartilage
- ✓ Passes through diaphragm at level of T10
- ✓ Ends in the orifice of stmoch at level of T11 vertebrae

Constrictions

1. At the beginning of cricopharangeal segment
2. Crossed by aortic arch and left principal bronchus
3. When passes through opening in diaphragm

- ✓ **Arterial supply** – inferior throid artery (upper 3rd) , thoracic and bronchial branches of descending thoracic aorta (middle 3rd) , left gastric atrey (lower 3rd).
- ✓ **Venous supply** – inferior thyroid vein , azygous vein , left gastric vein
- ✓ **Lymphatic drainage** – Deep cervical lymph nodes , superior and posterior mediastinal lymph nodes, left gastric and celiac lymph nodes

Respiration Muscles

- ✓ **Muscle of Quite Inspiration** – Diaphram and External Intercostal
- ✓ **Muscle of Forced Inspiration** – SCM &Serratous Anterior, Scalenus anterior &Medius and Pect minor
- ✓ **Quite Expiration** – Passive and by Elastic Recoil of Lung
- ✓ **Muscle of Forced Expiration** – Internal Intercostal
- ✓ **Accessory Muscle of Expiration** –Abdominal muscles (External Oblique , Rectus abdominis)
- ✓ External intercostal can be used in Quite inspiration as well as forceful inspiration
- ✓ After RTA injury to Cervical Region **difficulty in breathing** due to damage of – **Diaphragm**
- ✓ After RTA patient is having forceful expiration and **Abdomen is moving** with respiration due to – **External oblique**
- ✓ **Vertical** diameter increase by –Diaphragm
- ✓ **AP diameter** increase by – External intercosal assisted by internal and innermost intercosatal

Openings in diaphragm

- ✓ **T10 --Esophageal opening** - transmits esophagus, right and left vagus nerves , esophageal branches of left gastric vessels , and the lymphatic vessels from the lower 3rd of esophagus
- ✓ **T12 --Aortic opening** - transmits the aorta , thiracic duct and azygousvien
- ✓ **T8 --Caval opening** - transmits IVC and terminal branches of right phrenic nerve

Mediastnum contents

- ✓ **Anterior Mediastinum** – Thymus , Upper SVC , Left CCA , Left subclavian , Phrenic , Vague , Left RLN Cardiac nerve , Trachea , Esophagous and arch of aorta Thoracic duct and sympathetic trunk
- ✓ **Middle Mediastinum** – Remain of thymus ,Sternopericardial ligament Pericardium ,Phrenic nerve and trachea bifurcation
- ✓ **Posterior Mediastinum** - Descending thoracic aorta , Esophagous , Thoracic duct , Azygous and Hemiazygous vein , Vagus nerve and Splanchnic nerves

Foreign body

- ✓ Foreign body in supine – Apical(Superior) segment of right lower lobe.
- ✓ Foreign body in sitting/standing(Upright) – Posterior basal segment ofright lower lobe.
- ✓ Foreign body in right lateral – Posteriorsegment of right upper lobe.
- ✓ Foreign body in left lateral – Inferiorlingular of left upper lobe.

Heart Borders and Surfaces

Borders

Four Borders

- ✓ Right Border formed by -- Right Atrium and on Xray by SVC +Right atrium
- ✓ Left Border formed by – Left ventricle
- ✓ Superior Border formed by – Right and Left Atria
- ✓ Inferior **Border** Formed by –**Right Ventricle >Left Ventricle**

Surfaces

Four Surfaces

- ✓ Anterior (Sternocostal) Surface formed by – Right Ventricle
- ✓ Inferior (Diaphragmatic) Surface formed by – Left Ventricle >Right Ventricle
- ✓ Right Pulmonary Surface formed by – Right Atrium
- ✓ Left **Pulmonary** Surface(Cardiac Impression) formed by –**Left Ventricle**

Apex

- ✓ Formed by Inferolateral part of Left ventricle
- ✓ Posterior to left 5th ICS 9cm from Median plane

Base

- ✓ It is Heart Posterior Aspect
- ✓ Formed by Left Atrium >Right Atrium

Heart Circulation

Right Coronary Artery

Origin : Right Aortic Sinus

Branches:

SA Nodal artery – Supply SA Node and Pulmonary trunk

Right Marginal artery – Supply Right ventricle and Apex

Posterior Interventricular (Descending)Artery(67%)- Supply Right and left Ventricle and Posterior 1/3rd IVS

AV Nodal artery – Supply AV Node

Left Coronary Artery

Origin: Left Aortic Sinus

Branches:

SA Nodal artery –Supply Left atrium and SA Node

Left Anterior Interventricular(Descending) Artery - Supply Right and left Ventricle and Anterior 2/3rd IVS , Bundle of His and Apex(More than Right Marginal)

Circumflex Artery –Supply Left atrium and Left Ventricle

Left Marginal- Supply Left Ventricle

Posterior Interventricular (Descending)Artery(33%)- Supply Right and left Ventricle and Posterior 1/3rd IVS

Conclusion

RCA Supplies

- ✓ Right Atrium + Most Right Ventricle + Part of Left Ventricle(Diaphragmatic Surface)
- ✓ Posterior 1/3rd IVS
- ✓ SA Node(60%) +AV Node(80%)
- ✓ Some Part of Left Bundal Branch

LCA Supplies

- ✓ Left Atrium + Most Left Ventricle
- ✓ Part of Right Ventricle
- ✓ Anterior 2/3rd IVS including AV Bundle(Right Bundal Branch + Part of Left Bundal Branch)
- ✓ SA Node(40%)

CamScanner

THORAX

1- Thoracic duct drains into which of the following?
A- Left brachiocephalic vein
B- Right brachiocephalic vein
C- Brachiocephalic trunk
D- Junction of left subclavian & internal jugular vien
E- Right Subclavian
Ans: D

2- Conducting system of heart is located in which of following
A- Sulcus terminalis
B- Moderator band
C- Sub epicardium
D- Sub endocardium
E- Left atrium
Ans: D

Explanation:
- SA node located in – Upper one third Sulcus terminalis
- SA node located in – Sub Epicardium
- AV node located in – Endocardium
- Conducting System – Sub Endocardium

3- Posterior one third interventricular septum is supplied by:
A- RMA
B- LAD
C- LCX
D- RCA
E- LCA
Ans: D

Explanation:
- Anterior 2/3 of interventricular septum issupplied by anterior interventricular artery(LADA) which is branch of left coronary artery.
- Posterior 1/3 is supplied via posteriorinterventricular artery (PDA) which is thebranch of right coronary artery.

4- An emphysematous patient developed dullness on percussion note, hyper resonant chest, trachea shift to the opposite side, what investigation Should be done?
A- ECG
B- EEG
C- Chest X-ray
D- CBC
E- Biopsy
Ans: C

5- Clinical significance of supernumery ribs is which of following?
A- Compress Radial artery
B- Compress Other ribs
C- Compress Brachial Plexuses and Subclavian Vessels
D- Compress Median Nerve
E- Compress Axillary Nerve
Ans: C

6- Content of Middle mediastinum is which of following?
A- Descending Aorta
B- Hemiazygous
C- Thymus
D- Azygous
E- Bifurcation of trachea
Ans: E (Snell)

Explanation:
- **Anterior Mediastinum** – Thymus , Upper SVC , Left CCA , Left subclavian , Phrenic , Vague , Left RLN Cardiac nerve , Trachea , Esophagous and arch of aorta Thoracic duct and sympathetic trunk
- **Middle Mediastinum** – Remain of thymus ,Sternopericardial ligament
- **Middle Mediastinum** – Pericardium ,Phrenic nerve and trachea bifurcation
- **Posterior Mediastinum** - Descending thoracic aorta , Esophagous , Thoracic duct , Azygous and Hemiazygous vein , Vagus nerve and Splanchnic nerves

7- A 3 years baby inhaled something after that he had SOB o/e breath sound on the right were normal while on left side they were absent CXR confirmed foreign body lodged in left lower bronchus , diagnosis ?
A- Trachea deviated
B- Situs inversus
C- Left bronchus collapse
D- Alveoli collapse
Ans: B

8- A 68 year old male has copious amounts of fluid in the left pleural cavity due to acute pleurisy. When you examine him as he sits up in bed (trunk upright) , where would the fluid tend to accumulate in?
A- Costomediastinal recess
B- Cupola
C- Hilar reflection
D- Middle mediastinum
E- Costodiaphragmatic recess
Ans: E

9- Female with heart disease downward traction of her AV valves cannot be made which structure is damaged:
Pectinate muscles
A- Annulus fibrosis
B- Septomarginal band
C- Chorda tendinae
D- Crista terminalis
E-
Ans: D

10- Pericardiocentesis location for strawcolored fluid is which of following?
A- Caudal sternum region at medial end of4th and 5th costal cartilage
B- Left parasternal 3rd intercostal space
C- Midclavicular line
D- Midaxial line
E- Right parasternal 2nd Intercostal space
Ans: A

11- Descending thoracic artery begins at the lower border of:
A- T4
B- T5
C- L5
D- L4
Ans: A

12- Surgeon performing tracheostomy on baby.He will care because there are chances of injury to which of following?
A- Left Brachiocephalic trunk
B- Left Brachiocephalic vein
C- Superior thyroid vein
D- Recurrent Laryngeal nerve
E- Internal Laryngeal nerve
Ans: B

Explanation:
- Most Common Cause of Bleed DuringTracheostomy – Inferior Thyroid Vein
- Most Common Cause of Heavy BleedDuring Tracheostomy – Anterior Jugular Vein
- In Child during Tracheostomy Risk ofdamage to - Left Brachiocephalic vein andRight brachiocephalic Trunk (Innominateartery)
- During Tonsillectomy Bleed due to Tonsilararterty , Palatine vein andascending Pharyngeal Artery
- Most Common Nerve injured during Thyroidectomy-ELN
- Most Common Nerve injured during Tracheostomy-RLN

13- Coronary sinus drains how much coronary blood flow?
A- 2/3rd of veins
B- 1/3rd of veins
C- Half of blood
D- Whole blood
E- Less than 1/3rd
Ans: A

14- Sinus Branch to SA Node is branch of which of following?
A- LCX
B- Aorta
C- RCA
D- LCA
E- PDA
Ans: C

15- Women presented with Pericarditis pain that increase with respiration. Pain from fibrous and parietal pericardium carried by which of the following nerve?
A- Vagus
B- Lower 6 intercostal nerve
C- Phrenic nerve
D- Upper intercostal nerve
E- Internal thoracic nerve
Ans: C

16- Right bundle branch of conducting system of the heart is present in:
A- Septomarginaltrabeculae
B- Chorda tendanae
C- Supraventricular crest
D- Septal papillary muscles
E- Christa terminalis
Ans: A (KLM +Grey's)

Explanation:
- **SA Node** – Upper 1/3rd of Sulcus Terminalis and Upper Right atrium
- **AV Node** -- Lower part of Inter atrial septum or Atrioventricular septum
- **AV Bundle** -- Membranous IV septum
- **RBB** -- Septo Marginal Trabaculae
- **LBB** – Muscular Part of IV septum
- **SA Node** – Sub Epicardium
- **AV Node** – Endocardium
- **Conducting system** – Sub Endocardium

17- Patient is undergoing some surgery of spleen surgeon has to take care of costo diaphragmatic recess what is the level of Costodiaphragmatic recess?
A- T10 ICS midaxillary line
B- T11 ICS midaxillary line
C- T10 ICS midclaclavicular line
D- T9 ICS mid clavicular line
Ans: A

CamScanner

18- What will be shown on PA view after barium meal and patient has esophageal constriction?
A- Arch of aorta
B- Right crus of diaphragm
C- Left crus of diaphragm
D- Bronchi
E- Trachea
Ans: A

19- Sternal angle (Angle of Louis) at which vertebral level?
A- T2
B- T4-5
C- T6
D- L1
E- C8
Ans: B

20- What is present in Right atrium?
A- Papillary muscle
B- AV septum .
C- Chorda tendie
D- Moderator band
E- Septomarginal band
Ans: B

21- Right crus of diaphragm are attached to:
A- L1
B- L1-3
C- L4
D- L4-4
E- S1-3
Ans: B

22- In growing embryo, the mesothelium covering the lungs forms:
A- Pleuroperitoneal membrane
B- Pleuropericardial membrane
C- Parietal pleura
D- Visceral layer of pleura
E- Fibrous pericardium
Ans: D

23- A boy after blunt trauma to eye,Present to you with lower orbit fracture, crackling sound on palpation and blood accumulation diagnose is:
A- Orbital edema
B- Surgical emphysema
C- Foreign body
D- Fracture bone pieces
Ans: B

24- Branch of intercostal nerve is
A- Thoracic motor
B- Peritoneal motor
C- Peritoneal sensory
D- Musculophrenic
Ans: C

25- Which of the following is more appropriate regarding Esophagus?
A- Upper 2/3rd Muscular Layer is Skeletal + Smooth
B- Lower Third has Simple Columnar Epithelium
C- Stratified Squamous Epithelium through out
D- Squamous Cell Carcinoma common in lower 1/3rd
Ans: C

Explanation:
- Middle 1/3rd of Esophagus is Mixed that's both Muscular & Smooth Muscle
- Esophagus is having Stratified Squamous Epithelium throughout its whole length
- Adenocarcinoma of Esophagus is Common in lower 1/3rd of Esophagus.

26- Upper Esophageal Blood Supply:
A- Superior thyroid artery
B- Inferior thyroid artery
C- Internal thoracic
D- Celiac artery
Ans: B

Explanation:
- Upper 1/3rd: Inferior thyroid Artery.
- Middle 1/3rd: Thoracic Aorta.
- Lower 1/3rd: Left Gastric Artery.

27- Structure passing through esophageal opening of Diaphragm
A- Azygous Vein
B- Thoracic Duct
C- Phrenic nerve
D- Right Vagus nerve
Ans: D

Explanation:
- **Esophageal opening(T10)** - transmits esophagus, right and left vagus nerves , esophageal branches of left gastric vessels , and the lymphatic vessels from the lower 3rd of esophagus
- **Aortic opening(T12)** - transmits the aorta , thoracic duct and azygous vien
- **Caval opening(T8)** - transmits IVC and terminal branches of right phrenic nerve

28- Phrenic Nerve Main Root Value:
A- C2
B- C3
C- C4
D- C5
Ans: C

29- Patient came with Gunshot injury to cervical region & difficulty in breathing, muscle damaged:
A- Serratus Anterior
B- Diaphragm
C- External Intercostal Muscle
D- Internal Intercostal Muscle
Ans: B

30- Venous drainage of heart is mainly by:
A- Great Cardiac Vein
B- Anterior Cardiac Vein .
C- Middle Cardiac Vein
D- Coronary Sinus
Ans: D

31- Apex of Heart blood supply:
A- Marginal Artery
B- Anterior interventricular Artery
C- Circumflex Artery
D- PAD
Ans: B

32- Right Ventricle characteristic feature is:
A- Pulmonary Trunk arises
B- Aorta Arises
C- Partial pressure of oxygen increases
D- Partial Pressure of CO2 decreases
Ans: A

33- Nerve lying lateral to trachea:
A- Recurrent Laryngeal Nerve
B- Vagus Nerve
C- External Laryngeal Nerve
D- Internal Laryneal Nerve
Ans: B

34- Location of SA Node:
A- Lower part of Atrium
B- Upper Right Atrium
C- Upper Left Atrium
D- Close to Ventricles
Ans: B

Explanation:
- SA node is located in upper part of right atrium in the upper part of Sulcus terminalis.

35- Which vein drains directly into superior vena cava?
A- Azygous Vein
B- Hemiazygous Vein
C- Lumber Vein
D- Sacral Vein
Ans: A

Explanation
Azygousvien joins directly in the posterior aspect of superior vena cava

36- Right border of heart is formed by:
A- Right Atrium
B- Right Ventricle
C- Left Atrium
D- Left Ventricle
Ans: A

Explanation:
Right boarder of heart is formed by right atrium on CXR then RA+SVC.

37- Surgeon wants to know the anatomy of chest what's located in anterior mediastinum?
A- Aorta
B- Azygous Vein
C- Esophagus
D- Thymus
Ans: D

38- Epicardium is:
A- Visceral Layer of Serous Pericardium
B- Parietal Layer of Serous Pericardium
C- Parietal Layer of Myocardium
D- parietal layer of myocardium
Ans: A

39- Major supply of Interventricular septum:
A- Anterior Interventricular Artery
B- Posterior Interventricular Artery
C- Circumflex Artery
D- RCA
Ans: A

Explanation:
- Major portion of interventricular septum that's anterior 2/3rd is supplied by anterior interventricular septum while posterior 1/3rd is supplied by posterior interventricular artery.

40- During surgery profuse bleeding from transverse cervical artery which of the following to be ligated:
A- Thyrocervical Trunk
B- Aorta
C- Vertebral Artery
D- Carotid Artery
Ans: A

Explanation:
- The transverse cervical artery is the next branch off the thryocervical trunk.

41- Child aspirated peanut become suddenly cyanosed and start coughing most common region where foreign body gets stucked in?
A- Right superior lobe
B- Right inferior lobe
C- Left superior lobe
D- Left inferior lobe
E- Left ingual
Ans: B (FA + High Yield anatomy)

Explanation:
- Foreign body in supine – Apical(Superior) segment of right lower lobe.
- Foreign body in sitting/standing(Upright) – Posterior basal segment ofright lower lobe.
- Foreign body in right lateral – Posteriorsegment of right upper lobe.
- Foreign body in left lateral – Inferiorlingular of left upper lobe.

CamScanner

42- Collateral branch of intercostal nerve:
A- Gives lateral cutaneous branch
B- Runs in subcostal space
C- Run in intervertebral space
D- Supply muscle
Ans: A

Explanation:
- Each intercostal nerve gives off a collateral branch to the inferior part of the intercostal space and a lateral cutaneous branch to the side of the chest. In addition to being distributed to muscle and skin, branches are given to the parietal pleura, mammary gland and periostum of the ribs.

43- A patient presented in semi-conscious condition with subclavian steal syndrome, blood supply to which artery is causing this condition:
A- Internal carotid artery
B- Vertebral artery
C- Maxillary artery
D- Facial artery
E- External carotid artery
Ans: B

44- A 25 years old male encountered RTA diagnosed with fracture of ribs, which of the following is the site of a rib that could be fractured commonly:
A- Angle of the rib
B- Body of the rib
C- Neck of the rib
D- Tubercle of the rib
Ans: A

45- A person got a stab wound 3cm vertical on lateral right side of linea alba, initially he was fine but then developed hypotension & shock. Which vessel is most likely damaged:
A- IVC
B- Superior mesenteric Artery
C- Inferior Mesenteric Artery
D- Abdominal Aorta
E- Ileal branch of superior mesenteric artery
Ans: A

Explanation:
- The surface marking of the inferior vena cava is a vertical line 2.5 cm – 3 cm to the right of the midline from the intertubercular plane to the sixth costal

46- Anterior Surface of heart is formed by:
A- Right Ventricle
B- Left Ventricle
C- Right Atrium
D- Left Atrium
Ans: A

Explanation:
- Right boarder of heart is formed by: Right Atrium
- Left boarder of heart is formed by: Left Ventricle
- Inferior boarder of heart is formed by: right Ventricle
- Sternocostal (anterior) surface of heart is formed by: right ventricle
- Diaphragmatic (inferior) surface of heart is formed by: left ventricle
- Base (posterior) surface of heart is formed by: Left Atrium

47- Which of the following is the direct branch of subclavian artery that take part in the shoulder joint anastomosis:
A- Dorsal scapular artery
B- Suprascapular artery
C- Thyrocervical trunk
D- Thoraco-acromial artery
Ans: A

Explanation:
- Dorsal scapular artery is the direct branch of subclavian artery that takes part in shoulder joint anastomosis.
- Thyrocervical trunk is the main branch but it doesn not take part in shoulder joint anastomosis, but through its branch called suprascapular artery.

48- Which of the following is the origin of external oblique muscle:
A- Ribs 3 – 4
B- Ribs 4 – 5
C- Ribs 5 – 12
D- Ribs 12
Ans: C

Explanation:
- External oblique originates from lower 8 ribs and insert on xiphoid process , limea alba , pubic crest , pubic tuburcle and illiac crest

49- During thyroidectomy superior thyroid artery is ligated. The nerve likely to be injured:
A- External Laryngeal nerve
B- Internal Laryngeal nerve
C- Recurrent Laryngeal nerve
D- Superior Laryngeal nerve
E- Vagus nerve
Ans: A

Explanation:
- If superior artery is ligated the nerve most likely to be damaged is external laryngeal nerve.
- If inferior artery is ligated the nerve most likely to be damaged is recurrent laryngeal nerve.
- During thyroidectomy the nerve most commonly damaged is external laryngeal nerve.

50- Muscles of back are supplied by:
A- Dorsal rami
B- Dorsal Primary rami
C- Intercostal nerve
D- Long thoracic nerve
Ans: B

51- Which of the following arches over root of right lung?
A- Aorta
B- IVC
C- Azygous Vein
D- Vagus Nerve
Ans: C

Explanation:
- Structure infront of root of lungs: Phrenic Nerve
- Structure behind the root of lungs: Vagus Nerve
- Structure which arches over root of right lung: Azygous Vein
- Structure which arches over root of left lung: Arch of Aorta

52- Sympathetic beta adrenergic leads to which of the following?
A- Increase Airway resistance
B- Decrease Airway resistance
C- Increase Bronchoconstriction
D- Decrease Heart rate
Ans: B

53- Notching on CXR is seen in:
A- Aortic arch aneurysm
B- Pre ductal coarctation of Aorta
C- Post ductal coarctation of Aorta
D- Bicuspid Aortic Valve
Ans: C

Explanation:
- Notching on CXR due to dilated intercostals arteries eroding the lower boarders of ribs.

54- After RTA with multiple ribs fracture which of the following must be the first treatment
A- Fluid Replacement
B- Blood Replacement
C- Platelets
D- FFPs
Ans: A

55- Which of the following is present in posterior most opening of diaphragm?
A- IVC
B- Azygous vein
C- Aorta, thoracic duct & azygous vein
D- Hemiazygous Vein
Ans: C

Explanation:
The posterior most opening of diaphragm contains ATA (Aorta, Thoracic Duct & Azygous Vein).

56- Sternocostal surface of heart is formed by:
A- Right Ventricle
B- Left Ventricle
C- Right Atrium
D- Left Atrium
Ans: A(KLM)

Explanation:
- Sternocoastal surface is called anterior surface
- Right boarder of heart is formed by: Right Atrium
- Left boarder of heart is formed by: Left Ventricle
- Inferior boarder of heart is formed by: right Ventricle
- Sternocostal (anterior) surface of heart is formed by: right ventricle
- Diaphragmatic (inferior) surface of heart is formed by: left ventricle
- Base (posterior) surface of heart is formed by: Left Atrium

57- Which of the following is correct relation of phrenic nerve?
A- Left phrenic nerve descends anterior to the left lung root
B- Right phrenic nerve descends posterior to the left lung root
C- Phrenic nerve passes posterior to lung
D- None of the above
Ans: A

58- Which of the following structure does aorta compresses at Aortic hiatus?
A- Accessory vagus
B- Esophagus
C- IVC
D- Azygous & thoracic duct
Ans: D

Explanation:
- Aorta Passes at T12 level along with Azygous & thoracic duct, and these can be compressed in case of aortic dilatation & aneurysm. ATA= Aorta, Thoracic Duct, Azygous Vein.

59- Congenital diaphragmatic hernia occurs due to:
A- Absence of pleuorperitoneal membrane
B- Incomplete pleuroperitoneal membrane
C- Defective pleuroperitoneal membrane
D- Defective pleuropericardial membrane
Ans: B

CamScanner

60- Which of the following nerve is damaged during ligation of inferior thyroid artery?
A- External Laryngeal nerve
B- Internal Laryngeal nerve
C- Recurrent Laryngeal nerve
D- Glossopharyngeal nerve
Ans: C

Explanation:
- External laryngeal nerve is at risk while ligating superior thyroid artery.
- Recurrent laryngeal nerve is at risk while ligating inferior thyroid artery.

61- Important finding at angle of Louis:
A- Opening of Azygous vein in SVC
B- Opening of Azygous vein in IVC
C- Joining of SVC with Hemiazygous Vein
E- Joining of IVC with Hemiazgous vein
Ans: A

Explanation:
- The sternal angle (angle of louis) is formed by articulation of mandibutum with the body of sternum, It is an important surface landmark and it lies at the level of
- The 2nd coastal cartilage
- Interverteberal disc btw 4th and 5th thoracic vertebrae
- Junction of ascending aorta and aortic arch and the junction of aortic arch and descending aorta
- Bifurcation of trachea
- Junction of superior Mediastinum and inferior mediastinum

62- Commencement of trachea:
A- C3
B- C4
C- C5
E- C6
Ans: D

Explanation:
Trachea starts at C6 vertebrae and bifurcates at the level of T4 - T5 (sternal angle)

63- Posterior 1/3rd of interventricular septum artery accompanies which vein?
A- Great Cardiac Vein
B- Middle Cardiac Vein
C- Lesser Cardiac Vein
E- Coronary Sinus
Ans: B

Explanation:
- Posterior interventricular artery accompanies Middle cardiac vein.
- Anterior interventricular artery accompanies Great cardiac vein.
- Marginal artrey accompanies the small cardiac vien

64- Thoracic aorta passes posterior to:
A- Root of left lung
B- Root of right lung
C- Behind IVC
E- Behind Azygous Vein
Ans: A

65- Which part of lung only have two (02) bronchopulmonary segments?
A- Right Upper Lobe
B- Right Middle Lobe
C- Right Lower Lobe
D- Left Upper lobe
Ans: B

Explanation:
- Upper - 3
- Middle - 2
- Lower - 5

66- Quiet breathing with increase AP diameter due to which of the following muscle?
A- Diaphragm
B- External Intercostal muscle
C- Internal Intercostal muscle
E- Rectus Abdominis
Ans: B

Explanation:
- The muscle in quiet respiration is Diaphragm but here increase AP diameter that's not possible with diaphragm so here external interocostal muscle.

67- Eventration of diaphragm occurs due to improper function of:
A- Dorsal mesentery of esophagus and pleuroperitoneal membrane
B- Dorsal mesentery of esophagus&pleuropericardial membrane
C- Lateral muscular wall with pleuroperitoneal membrane
A- Ventral mesentery of esophagus& lateral body wall.
Ans: C

68- Branch of thyrocervical trunk is
A- Suprascapular
B- Internal thiravic
C- Deep cervical
D- Superior intercoastal
E- Vertebral artrey
Ans A

Explanation:
- BRANCHES OF SUBCLAVIAN ARTREY
mnemonic - **VIT C and D**
V - vertebral artery
I - internal thoravicartrey
T - thyrocervical trunk
1. Inferior thyroid artery
2. Suprascapulararrtrey
3. Transverse cervical artrey
C - costocervicalartrey
1. Superior intercoastalartrey
2. Deep cervical artrey
D - dorsal scapular artery

69- Interruption to cervical sympathetic chain resulted in Ptosis, Miosis&anhydrosis is due to
A- Horner Syndrome
B- CN III damage
C- CN VI damage
D- Pons Lesion
Ans: A

Explanation:
Horner syndrome is characterized by interruption of cervical sympathetic chain that results in partial ptosis, miosis and anhydrosis.

70- Which cervical ganglion is located opposite to 2nd cervical vertebrae?
A- Superior Cervical Ganglion
B- Inferior Cervical Ganglion
C- Middle Cervical Ganglion
D- None of the above
Ans: A

Explanation:
- The Superior Cervical Ganglion is located opposite the second and third cervical vertebrae.
- The inferior Cervical ganglion is located opposite to fourth and sixth cervical vertebrae.
- The middle cervical ganglion is the smallest of the three cervical ganglia and is occasionally absent, it's placed opposite to sixth cervical vertebrae.

71- On percussion of posterior aspect of chest along the scapular line in quiet respiration, the resonance extends down the level of:
A- 6th Rib
B- 8th Rib
C- 10th Rib
D- 12th Rib
Ans: C

72- Which of the following is the level of Xiphoid process?
A- T7
B- T8
C- T9
D- T10
Ans: C

Explanation:
T9 is the level of Xiphoid Process & T7 is dermatome.

73- First posterior intercostal vein drains into:
A- Superior vena cava
B- Azygous Vein
C- Brachiocephalic Vein
D- Subclavian Vein
E- Hemiazygous Vein
Ans: C

Explanation:
>1st posterior intercostal vein drain into - Brachiocephalic vein
>2-3 or some time 4th posterior intercostal veins drain into – Superior intercostal vein
>4-11 posterior intercostal veins drain into – Azygous veins
>Anterior intercostal vein drain into – Musculophrenic and internal thoracic vein.

74- Which of the following is Epicardium blood supply?
A- Pericardiophrenic Artery
B- Coronary Artery
C- Carotid Artery
D- Coronary Sinus
Ans: B

Explanation:
- Epicardium is supplied by Coronary artery > Pericardiophrenic artery.
- Pericardium is supplied by pericardiophrenic artery

75- Structure which lies anterior to trachea in thoracic cavity:
A- Arch of Aorta
B- Thoracic Duct
C- Jugular Vein
D- Esophagus
Ans: A

Explanation:
- Anterior- sternum , thymus , let brachicephalicvien , origins of brachiocephalic , left common carotid artrey and arch of aorta
- Posterior - esophagus and left recurrent larangeal nerve
- Right side - azygousvien , right vagus nerve and pleura
- Left side - arch of aorta , left common carotid , left subclavian arteries, left vagus nerve , left phrenic nerve and pleura

CamScanner

76- Infection of neck in front of pretracheal fascia will spread to:
A- Anterior mediastinum
B- Superior mediastinum
C- Inferior Mediastinum
E- Posterior Mediastinum
Ans: A

Explanation:
- Infection infront of pretracheal fascia spreads to: Anterior Mediastinum
- Infection posterior prevertebral fascia spreads to: Superior Mediastinum

77- Esophageal opening is located at which of the following:
A- T8
B- T10
C- T12
D- L1
Ans: B

Explanation:
- Inferior Vena Caval Opening: T8
- Esophageal Opening: T10
- Aorta Opening: T12

78- Which of the following is root value of phrenic nerve?
A- C3,4,5
B- C2,3,4
C- C3,4
E- C1,2
Ans: A

Explanation:
- Root value - C3 C4 C5
- main root - C4

79- Stony dull percussion note in found in which of the following?
A- Pneumoniae
B- Pleural effusion
C- Normal Lungs
E- Pnuemo
Ans: B

80- Ligation of thyrocervical trunk , area still perfuse due to
A- Superior thyroid
B- Middle thyroid
C- Suprascapular
D- Transverse cervical
Ans: A

81- Phrenic nerve avulsion at its origin will lead to:
A- Loss of sensation of central tendon of Diaphragm
B- Hemi diaphragm paralysis
C- Loss of respiratory reflex
D- Loss of respiration
Ans: B

Explanation:
Phrenic nerve avulsed at its origin will lead to:Hemi diaphragm sensory loss > Hemi diaphragm paralysis > Central tendon sensation lost.

82- A tall man on oxygen suddenly started being dyspneac due to:
A- Spontaenous Pneumothorax
B- Tension Pneumothorax
C- Cardiac Tamponade
D- COPD
Ans: A

83- Patient presents with red face and loss of sweating function. Which nerve supply is damaged?
A- Cervical sympathetic
B- Lesser splanchnic
C- Greater splanchnic
E- Least splanchnic
Ans: A

84- The accessory cervical rib is the outgrowth of which cervical vertebra:
A- C6
B- C7
C- C5
D- C8
F- T1
Ans: B

85- Conducting system of the heart comprises of:
A- Nicotinic fibers
B- Cholinergic fibers
C- Sympathetic fibers
D- Modified cardiac tissue
A- Adrenergic fibers
Ans: D

86- Trachea is descending in superior mediastinum, which structure runs to its right side?
A- Vagus nerve
B- Common Carotid Artery
C- Arch of aorta
D- Descending aorta
Ans: A

87- The initial structure of the lungs seen on bronchoscopy:
A- Anterior division of the Left upper lobe
B- Anterior division of the Right upper lobe
C- Posterior division of the right lower lobe
D- Posterior division of the right middle lobe
Ans: B

88- Posterior 1/3rd blood supply of heart:
A- LCA
B- RCA
C- LAD
D- Marginal Artery
Ans: B

89- An emphysema patient presents with decrease air entry on left side and trachea is shifted to the left. The investigation of choice in her will be:
A- CT Scan
B- MRI
C- CXR
D- Lung biopsy
Ans: C

90- Which of the following arteries lie behind the sternum?
A- Carotid artery
B- Subclavian artery
C- Internal thoracic artery
D- Intercostal artery
Ans: C

91- A 02 years old child presented with a midline swelling just below the hyoid bone. The swelling was noticed at 03 months of age and is slowly increasing in size, with no movements on protrusion of tongue, the condition most likely is:
A- Accessory thymic tissue
B- Branchial cyst
C- Cranipharngioma
D- Ectopic thyroid gland
E- Thyroglossal duct cyst
Ans: D

Explanation:
Thyroglossal duct cyst will move with protrusion of the tongue & protrusion of tongue test is positive while in ectopic thyroid gland there will be no movement of the swelling with protrusion of tongue and hence, protrusion test is negative.

92- Anteroposterior radiograph of heart will take part in it's formation:
A- SVC
B- Right ventricle
C- Left ventricle
D- Aorta
Ans: A

Explanation:
- AP view of heart will show SVC + right atrium but right atrium wasn't in option so SVC.
- SVC +Right atrium > SVC > Right Atrium.

93- What is passing through groove of mediastinum on left side?
A- Aorta
B- Esophagus
C- IVC
D- Azygous vein
Ans: B

94- A semiconscious patient aspirates while lying on his back the segment of the lung most likely affected would be:
A- Anterior segment of right upper lobe
B- Apical segment of right lower lobe
C- Posterior segment of left upper lobe
D- Base of Both Lungs
Ans: B

95- A patient is having pleural effusion from where pleural drainage should be done?
A- Upper border of 9thintercostal space at mid axillary line.
B- Lower border of 9thintercostal space at mid axillary line.
C- Lower border of 9thintercostal space at mid clavicular line.
D- Upper border of 9thintercostal space at mid clavicular line.
E- Diaphragmatic recess.
Ans: B

96- Dilatation of which of the following structure causes dysphagia by compressing on the esophagus?
A- LA
B- Aortic arch
C- Left bronchus
D- Trachea
Ans: A

97- Neurovascular bundle lies at
A- Upper border of rib
B- Lower border of rib
C- Lower end of intercostal space
D- Between external and internal intercoastal
Ans: B

98- Intercostal-brachial artery originates from which of following?
A- Arch of aorta
B- Anterior of descending aorta
C- Posterior lateral portion of descending aorta
D- Ascending Aorta
Ans: C

99- Costodiaphragmatic recess is present between?
A- Costal and diaphragmatic pleura
B- Costal & visceral pleura
C- Costal & Diaphragm
D- Diaphragm & Ribs
Ans: A

CamScanner

100- Circumflex artery supplies which of following?
A- Right Atrium
B- Right Ventricle
C- Left ventricle and anterolateral papillary muscle
D- Anterior surface of heart
Ans: C(FA)

101- Which of following is single motor supply muscle?
A- Diaphragm
B- Mylohyoid
C- Internal intercostal muscle
D- Levatorcostorum
E- External intercostal miscle
Ans: A

102- Blood supply of middle of oesophagus:
A- Superior thyroid
B- Descending thoracic aorta
C- Inferior thyroid
D- Left gastric
Ans: B

103- SA node is supplied usually by:
A- Left anterior descending artery
B- Right coronary artery
C- Circumflex artery
D- posterior interventricular
Ans: B

Explanation:
All conduction system of heart is supplied by RCA , only RBBB is supplied by LCA

104- What is site of tracheostomy?
A- C2 ring
B- C3 ring
C- C4 ring
D- C5 ring
Ans: A

Explanation
- In adults : C2 > C3 tracheal ring
- In childrens : C3 > C4 tracheal ring

105- Patient having ST elevation in lead 2 and complete heart block vessel involve
A- RCA
B- Right marginal artery
C- LAD
D- LCA
Ans: A

106- Regarding pulmonary varix:
A- Opens into left atrium
B- Opens into right atrium
C- Opens into left ventricle
D- Opens into right ventricle
Ans: A

Explanation:
Pulmonary varix is pulmonary Vein

107- Three segments apical, anterior and posterior in which lobe of lung
A- Right upper
B- Right middle
C- Right inferior
D- Left superior
Ans: A

Explanation:
- Upper : 3
- Middle : 2
- Lower : 5

108- 30 years old patient done with esophagectomy , stomach is mobilized to upper portion to anastomose with pharynx . Which artery is responsible for stomach suply now
A- Left gastric artery
B- Left gastroepiploic
C- Right gastroepiploic
D- Splenic
Ans: C

Explanation:
- If right gastroepiploic is not in option then, choose Right gastric artrey

109- During needle thoracotomy, what structure damaged first?
A- IC muscle
B- IC nerve
C- IC vein
D- IC artery
E- Internal thoracic artery
Ans: B

110- Right coronary artery after giving off marginal branch supplies:
A- AV node
B- SA node
C- Left atrium
D- Left ventricle
Ans: A

111- Left circumflex blocked. What affected?
A- Left atrium and left ventricle
B- Right atrium
C- Right ventricle
D- Right atrium and right ventricle
Ans: A

112- Thoracic aorta passes posterior to:
A- Median arcuate ligament
B- Lateral arcuate ligament
C- Medial arcuate ligament
D- Phrenicocolic ligament
Ans: A

113- Stab Injury at 6th costal cartilage on the right side of the sternum will pierce which of the following structure?
A- Right Atrium
B- IVC
C- SVC
D- Right Ventricle
Ans: A

Explanation:
- For 6th ICS -IVC
- For 6th costal cartilage -RA

114- Posterior mediastinal tumour can compress:
A- Thoracic Aorta
B- Thymu
C- Jugular vein
D- Azygous Vein
Ans: A

115- Pregnant lady is avoided to lay on right lateral side due to compression of:
A- Aorta
B- Azygous Vein
C- IVC
D- Ovaries
E- SVC
Ans: C

116- When measuring the CVP the reference point which best correlates to the right atrium is?
A- Anterior axillary line 4th intercostals space
B- Midaxillary line 3th intercostals space
C- Manubriosternal junction
D- Midaxillary line 5th intercostals space
Ans: C

Explanation:
Reference point can be 4th ICS but best correlates with Right atrium is Manubriosternal junction

117- Cardiac output measure by dye dilution method and dye should be measure in:
A- Right atrium
B- Aorta
C- Saphenous vein
D- Pulmonary artery.
Ans: B

118- Pain from lower inferior segment of diaphragm is carried by
A- Phrenic nerve
B- Subcostal nerves
C- Intercostal nerve
D- Vagus nerve
Ans: B

119- The subclavian vein joins the internal jugular vein to form the brachiocephalic vein at which of the following structures?
A- The outer border of first rib
B- Behind the sternal end of clavicle
C- Inner border of Rib
D- In front of clavicle
Ans: B

120- Narrowest point in pediatric airway:
A- cricoid
B- thyroid
C- trachea
D- false vocal cord
E- true vocal cords
Ans: A

121- Bundle of His is supplied by:
A- RCA
B- LAD
C- Rt marginal artery
D- LCA
Ans: A

122- Lymphatic drainage of thyroid:
A- Deep cervical lymph nodes
B- Axillary lymph nodes
C- Superficial cervical lymph nodes
D- Pre tracheal lymph nodes
E- Paratracheal lymph nodes
Ans: A

123- About Esophagus:
A- Passes through right crus of diaphragm
B- Covered by peritoneum on anterior & right surface
C- Grooves posterior surface of liver
D- Passes through left crus
Ans: D

124- Structure that passes through posterior mediastinum:
A- Descending Thoracic aorta
B- SVC
C- Thymus
D- phrenic nerves
E- Heart
Ans: A

Explanation:
POSTERIOR MEDIASTINUM CONTENTS:
mnemonic: DATES VP
D - descending thoracic aorta
A - azygousvien and hemiazygousvien
T - thoracic duct
E - esophagus
S - sympathetic trunk and splanchnic vessels
V - vagus nerve
P - posterior vessles and nodes

CamScanner

125- **Nerve Passes infront of pulmonary artery:**
A- Phrenic nerve
B- Bronchus
C- Recuurent laryngeal nerve
D- Pulmonary veins
Ans: A

126- **Superior Parathyroid gland:**
A- Supplied by sup thyroid artery
B- Lies at middle of posterior border/ surface of thyroid lobe at level of 1st tracheal ring
C- More variable in postion
D- Just anetrior to pretracheal fascia
Ans: B

127- **Peripheral nerve damaged, nerve will regenerate at the rate of:**
A- 0.1 mm/day
B- 0.3 mm/ day
C- 10mm/day
D- 0.4 mm/ day
E- 1.2 mm/day
Ans: B

128- **Ganglion found at T7 vertebra:**
A- Pteregopalatine
B- Geniculate
C- Thoracocervical
D- none
Ans: C

129- **Normal resonance at**
A- Right 2nd to 4th mid curricular line
B- Right 3rd to 4th mid clavicular line
C- Right 4th to 5th mid clavicular line
D- Right 5th to 6th mid clavicular line
Ans: A

130- **A needle piercing mid-axillary line will not damage:**
A- Levator Costrum
B- Internal intercostal muscle
C- External intercostal muscle
D- Innermost intercostal muscle
Ans: A

131- **About coronary circulation which is true:**
A- Veins have similar names with arteries
B- Arteries runs in respective atrioventricular grooves
C- Anastomosis occur at arteriolar level
Ans: B

132- **Which of the following veins drains into coronary sinus and itself becomes part of coronary sinus?**
A- Great cardiac vein
B- Middle cardiac vein
C- Small carfiacvien
D- Azygousvien
E- Hemizygousvien
Ans: A

133- **Shoulder pain referred from pleura:**
A- C3 C4 C5
B- C2 C3 C4
C- C1 C2 C3
D- C5 C6 C7
E- C6 C7 C8
Ans: A

134- **Both sides of 5th posterior intercostal spaces are supplied by:**
A- Thoracic aorta
B- Internal thoracic artery
C- Anterior intercoastal artery
D- Musculophrenicartrey
Ans: A

Explanation:
- Posterior intercostal artries of first 2 spaces are branches of superior intercoastal artery
- Posterior intercoastal arteries of lower 9 spaces are branches of thoracic aorta

135- **Muscle which opens glottis:**
A- Posterior Cricoarytenoid
B- Lateral Cricoarytenoid
C- Transverse arytenoid
D- Coricothyroid
E- Thyroarytenoid
Ans: A

Explanation:
Open -
- Posterior Cricoarytenoid

Close -
- Lateral Cricoarytenoid
- Transverse arytenoid
- Cricothyroid
- Thyroarytenoid

136- **About thoracic aorta:**
A- Starts at T4 on left side
B- Supply lungs, esophagus & pericardium
C- Supplies last 3 intercostal spaces
D- Supplies first 9 intercoastal spaces
Ans: B

137- **Land mark of thyroid gland is at the level of**
A- C3 to T1
B- C5 to T1
C- C6 to T7
D- C6 to T8
Ans: B

138- **Medial arcuate ligament formed by**
A- Psoas fascia
B- Quadratus lumborum
C- lumbar fascia
D- Diaphragm
Ans: A

Explanation:
- Median arcuate ligament - diaphragm
- Medial arcuate ligament - psoas fascia
- Lateral arcuate ligament - lumbar fascia

139- **Thyroglossal cyst common location:**
A- Above sternum
B- Thyrohyoid region
C- Intralingual
D- Suprahyoid
Ans: B (if infrahyoid prefer that)

140- **Heart shaped vertebrae:**
A- Thoracic vertebrae
B- Lumber vertebrae
C- Sacral vertebrae
D- Coccygeal vertebrae
Ans: A

Explanation:
- Heart in region , so thoracic vertebrae are of heart shape
- Kidney in lumbar region , so lumbar vertebrae are of kidney shape

141- **Surgeon operated lady for enlarged thyroid, he ligated the superior and inferior thyroid artries as close to pole as possible. After 2 weeks she presented with hoarseness. Most likely cause could be injuiry to**
A- Recurrent larangeal nerve
B- Internal larangeal nerve
C- External laryngeal nerve
D- Internal thoracic nerve
Ans: A

142- **About thyroid gland:**
A- Three paired arteries
B- Venous drainage to brachiocephalic and subclavian vein
C- Covered by prevertebral fascia
D- Isthmus is infront of cricoid cartilage
Ans: B

143- **Regarding Bronchopulmonary segment:**
A- Are not connected with each other
B- Aerated by primary bronchioles
C- Aerated by secondary bronchioles
D- Aerated by tertiary bronchus
Ans: D

144- **Deep cervical artery is a branch of:**
A- Thyrocervical trunk
B- Costcervical trunk
C- vertebral artrey
D- Internal thoracic artrey
E- Forsal scapular artrey
Ans: B

Explanation:
BRANCHES OF SUBCLAVIAN ARTREY
mnemonic - **VIT C and D**
V - vertebral artery
I - internal thoravicartrey
T - thyrocervical trunk
1. Inferior thyroid artery
2. Suprascapularartrey
3. Transverse cervical artrey
C - costocervical artery
1. Superior intercoastalartrey
2. Deep cervical artery
D - dorsal scapular artery

145- **Which of the following is branch of thyrocervical trunk**
A- Inferior thyroid artery
B- Internal thoracic artery
C- Vertebral artrey
D- Superior intercostal artery
E- Deep cervical artrey
Ans: A

146- **Thymus:**
A- Rich in lymphocytes
B- Regress after birth
C- Develop from 3rd and 4th pharyngeal pouches
D- Develop from 1st pharangeal pouch
Ans: A

147- **Anterior intercostal arteries which supply first 6 spaces are branches of**
A- Internal thoracic artrey
B- Musculophrenic artery
C- Superior intercoastal
D- Thoracic aorta
Ans: A

Explanation:
- Anterior intercoastalartries which supply first 6 spaces are branches of internal thoracic artrey
- Anterior intercoastalartreies which supplies the lower spaces are branches of Musculophrenic artery

148- **Heavy bleeding in Tracheostomy due to:**
A- A vein which drains into jugular vein
B- Inferior thyroid artrey
C- Due to isthmus
D- left gastric artrey
Ans: A

Explanation:
- Most Common Cause of Bleed During Thyroidectomy- Inferior Thyroid Vein
- Most Common Cause of Heavy Bleed During Thyroidectomy- Anterior Jugular vein> Isthmus
- During Tonsillectomy Bleed due to Tonsilar artery , Palatine vein and asceding Pharyngeal Artery

CamScanner

149- **Major penetrating injury to 4th intercostal space just on left side of sternum will damage:**
A- Right atrium
B- Intercostal muscle
C- Intercostal membrane
D- Intercostal nerve
Ans: B

150- **Regarding Intercostal nerves:**
A- Only supply skin
B- 12 in number
C- Supply only intercostal muscles
D- Associated with sympathetic chain
Ans: C

151- **Size of right bronchus**
A- 2.5 cm
B- 3.5 cm
C- 5cm
D- 6 cm
Ans: A
Explanation:
- Right bronchus - wider , shorter and more vertical than left , 2.5 cm
- Left bronchus - narrower , longer and more horizontal than right , 5cm

152- **Hyoid bone level**
A- C2
B- C3
C- C4
D- C5
E- C6
Ans: B

153- **Posterior surface of heart is supplied by how many arteries:**
A- Usually two in numbers
B- Usually three in numbers
C- Ant descending supply anterior surface
D- Interventricular artery
E- Right coronary artery
Ans: A

154- **Structure opens into right atrium ,except**
A- SVC
B- IVC
C- anterior cardiac veins
D- Coronary sinus
E- Right pulmonary veins
Ans: E

155- **If root of left lung is injured which structure will be spared?**
A- Vagus nerve
B- Azygous vein
C- Phrenic nerve
D- Pulmonary ligament
Ans: B

156- **Vagal stimulation of the heart causes:**
A- Increased heart rate
B- Increase PR interval
C- Increase force of heart contraction
D- Increased cardiac output
Ans: B

157- **30 yrs old person has stab wound on right side of chest. What will happen?**
A- Ipsilateral lung collapse and ipsilateral chest wall spring out
B- Ipsilateral lung collapse and contralateral chest wall collapse
C- No change in chest wall
D- Contralateral lung collapse and ipsilateral chest wall collapse
E- Ipsilateral lung collapse and contralateral spring out
Ans: A

158- **In the chest wall, neurovascular bundle lies between:**
A- External & internal intercostal muscles
B- Internal & innermost intercostal muscles
C- External and innermost intercoastal muscles
D- All of the above
Ans: B

159- **Blood supply of thymus:**
A- Inferior thyroid artery
B- Costocervical trunk
C- Thyrocervical trunk
D- Subclavian artery
Ans: A

160- **A patient with Pleural Effusion.On standing, You will see effusion in:**
A- Costodiaphragmatic recess
B- Cardiac Notch
C- Oblique fissure
D- Horizental Fissure
Ans: A

161- **With superior thyroid, which nerve lies:**
A- Recurrent laryngeal
B- External laryngeal nerve
C- Internal
D- Juglar
Ans: B

162- **Transverse diameter of rib cage:**
A- Diaphragm
B- Bucket handle movement
C- Pump handle movement
D- Joint movement
Ans: B

163- **Patient post thyroidectomy. Hoarseness of voice. Loosening of vocal cords. Damage to:**
A- Cricothyroid
B- Post cricoaretynoid
C- Thyroarytenoid
D- Lateral coricoarytenoid
Ans: A
Explanation:
- Muscle which tenses the vocal cord - coricothyroid
- Muscle which relaxes the vocal cord - thyroarytenoids

164- **Apex of lung reach:**
A- 2.5 cm above sternoclavicular
B- 4 cm above sternoclavicular joint
C- 2.5 cm above mid clavicle joint
D- 4 cm above mid clavicle point
Ans: C

165- **Partial thyroidectomy done carefully to preserve which structure posteriorly:**
A- Parathyroid gland
B- Recurrent laryngeal nerve
C- Superior thyroid artery
D- inferior thyroid artery
Ans: A

166- **Isthmus of thyroid is situated over which tracheal rings**
A- 1, 2, 3
B- 2, 3, 4
C- 1, 2
D- 2, 3
Ans: B

167- **Patient after posterior thyroidectomy develops hoarseness of voice. Examination reveals tense vocal cords. Which of the following is most likely damaged?**
A- Cricothyroid
B- Post cricoaretynoid
C- Thyroarytenoid
D- Lateral coricoarytenoid
Ans: C
Explanation:
- Muscle which tense the vocal cord - coricothyroid
- Muscle which relaxes the vocal cord - thyroarytenoids and vocalis

168- **An accessory cervical rib arising from transverse process of cervical vertebrae may cause damage to:**
A- C6
B- C7
C- C8
D- T1
Ans: D

169- **A man was involved in an RTA with multiple rib fractures. He has difficulty in breathing. You notice that his abdomen is moving more during breathing. Which of the muscle is helping him breathe?**
A- Diaphragm
B- External intercostal
C- External oblique
D- Internal intercostal
E- Transverses thoracic
Ans: C

170- **What is the length of left bronchus?**
A- 2.5cm
B- 3cm
C- 5mm
D- 5cm
Ans: D
Explanation:
- Right bronchus - wider , shorter and more vertical than left , 2.5 cm
- Left bronchus - narrower , longer and more horizontal than right, 5cm

171- **Thoracic duct block causes:**
A- Chylopericardium
B- Hemopericardium
C- Inc CVP
D- Dependent edema
Ans: A

172- **In 10 years old boy Thymus:**
A- Remains as Single Lobe
B- Extends from inferior border of thyroid to 4th Cervical
C- Supplied by superior thyroid artery
D- Supplied by RLN
Ans: B

173- **Gall bladder pain over neck due to:**
A- Sensory supply from mid cervical dermatome
B- Sensory supply from t10 dermatome
C- Sensory supply from splanchnic
D- Sensory supply feom T12 dermatome
Ans: A

174- **Vagus nerve passes through:**
A- Oesophageal opening
B- Caval opening
C- Aortic opening
D- From central tendon of diaphragm
Ans: A

175- **Phrenic nerve near its origin passes anterior to which muscle:**
A- Scalene anterior
B- Scalene Medius
C- Sternocleidomastoid
D- Scalene posterior
Ans: A

CamScanner

176- Right main bronchus as compared to left:
A- More wider
B- More prone to obstruction by foreign body
C- Oblique
D- more horizontal
E- more longer
Ans: A

177- Bifurcation of trachea at vertebral level?
A- C6
B- T4-T5
C- C7-T1
D- T5 - T6
Ans: B

178- Upper fibers of external intercostal interdigitate with?
A- Rectus abdominis
B- Serratus anterior
C- Latissmusdorsi
D- Sclane anterior
Ans: B

179- What is true about Broncho pulmonary segment?
A- 3,2,5
B- 3,4,5
C- 3,5,6
D- 2,3,4
E- 1,2,3
Ans: A

180- Which one is False Rib?
A- 4
B- 5
C- 6
D- 7
E- 8
Ans: E

Explanation:
- True ribs - upper 7
- False ribs - 8 to 10
- Floating ribs - 11 and 12

181- During development T lymphocyte are protected from autoimmune destruction by
A- Blood thymus barrier
B- Protected by hassles corpuscles
C- Plasma cells
D- Blood brain barrier
Ans: A

182- A person got infection. Pus in paravertebral fascia is from
A- Subarachnoid space
B- Pterygopalatine fossa
C- Infratemporal fossa
D- Para pharyngeal space
Ans: D(RJ Last)

183- Bronchogenic cyst is present in which compartments of mediastinum?
A- Anterior
B- Posterior
C- Medial
D- Middle
Ans: D(FA)

184- Child with absent breath sounds and have a portion of intestine in:
A- Abdominal wall defect
B- Hiatal hernia
C- Inguinal hernia
D- Pleuroperitoneal defect
Ans: D

185- Maximum two point discrimination distance is present in:
A- Lips
B- Scapula
C- Leg
D- Hand
Ans: B

Explanation:
- Maximum 2 point discrimination— Lips
- Minimum 2 point discrimination -Scapula
- Maximum 2 point Discrimination distance - Scapula
- Minimum 2 point Discrimination Distance - lips

186- IVC blocked upto Azygous vein dilation will be in:
A- Right ascending lumbar and right subcostal vein
B- Subcostal vein
C- Ascending lumbar vein
D- Azygous vein
Ans: A

Explanation:
- IVC blocked above aboveazygous vein dilation in – Azygous vein >Left gastric vein.
- IVC blocked upto azygous vein dilation in – Right ascending lumbar vein and right subcostal vein.
- IVC blocked below azygous vein dilation in – ascending lumbar vein.

187- Pericardiophrenic artery is branch of:
A- Phrenic artery
B- Intercostal artery
C- Internal thoracic artery
D- Superior epigastric artery
Ans: C

Explanation:
Pericardiocophrenic, Anterior intercostal branches Musculophrenic, Superior epigastric , Perforating branches are branches of internal thoracic artery

188- Muscle which increases lateral chest diameter during quite breathing?
A- Serratus anterior
B- Sternocleidomastoid
C- External intercostal
D- Trapezius
Ans: C

189- Gastric content in supine position aspiration will lodge in:
A- Right lower lobe
B- Right upper lobe
C- Right posterior lobe
D- Left Posterior lobe
Ans: A (FA+Grey'anatomy)

Explanation:
- Foreign body in supine – Apical (Superior) segment of right lower lobe.
- Foreign body in sitting/standing (Upright) – Posterior basal segment of right lower lobe.
- Foreign body in right lateral – Posterior segment of right upper lobe.
- Foreign body in left lateral – Inferior lingular of left upper lobe

190- Moderator band is found in:
A- Right atrium
B- Right ventricle
C- Left atrium
D- Left ventricle
Ans: B

Explanation:
Moderator band is the band of cardiac muscles also known as septal trabecula found in right ventricle of heart, its main function is to convey right atrioventricular bundle of the conducting system.

191- Which of the following are floating ribs?
A- 1st and 2nd
B- 6th
C- 10th
D- 10 – 12
Ans: D

Explanation:
- True - 1-7
- False - 8 to 10
- Floating - 11 12

192- Lateral wall of heart blood supply:
A- RCA
B- LCA
C- LCX
D- Marginal
Ans: C

193- Lower 9 posterior intercostal arteries are the branches of:
A- Arch or aorta
B- Decending aorta
C- Throcervival trunk
D- Suprascapular artery
Ans: B

Explanation:
- 1st and 2nd Post intercostal artery arise from Superior intercostal branch of costocervical trunk of Subclavian artery.
- Lower 9 arise from Back of thoracic aorta.

194- SA node is supplied by which nerve
A- Sympathetic supply via cardiac plexus
B- Parasympathetic via cardiac plexus
C- Sympathetic vis vagal nerve
D- Upper 4th intercoastal nerve
Ans: A

195- Median arcuate ligament formed from which structure
A- Dorsal mesentry
B- Crura of diaphargm
C- Stomodeum
D- Neural crest cell
Ans: B

Explanation:
- Median - diaphragm
- Medial - psoas fascia
- Lateral - lumbar fascia

196- Pain in pericarditis is due to?
A- Long thoracic nerve
B- Intercoastal nerves
C- Phrenic nerve
D- Vagus nerve
Ans: C

197- Hilum of the lung is recognized by:
A- Pulmonary ligament
B- Costomediastinal recess
C- Location of pulmonary artery and veins entering superior and anterior to bronchus
D- The point where trachea bifurcates
Ans: C

198- Pulmonary bronchi are supplied by bronchial and pulmonary arteries, which of the following are supplied by pulmonary arteries?
A- Parietal pleura
B- Visceral pleura
C- Parenchyma of lung
D- Alveoli
Ans: D

Explanation:
- There are two separate arterial system supplies the lungs

1- Non respiratory circuit-Bronchial arteries which supplies pleura and connective tissue of the lung

2- Respiratory circuit.-Terminal branches of pulmonary artery supplies the alveoli.

CamScanner

199- **Patient IVC blocked just above the emergence of azygous vein,Where will blood divert?**
A- Left gastric vein
B- Hepatic vein
C- Azygous vein
D- Splenic artery
Ans: C>A

Explanation:
- IVC Blocked Above Azygous vein dilation in – Azygous vein > Left Gastric Vein
- IVC Blocked Upto Azygous vein dilation in – Right Ascending Lumber vein & Right Subcostal Vein
- IVC Blocked Below Azygous vein dilation in – Ascending Lumber vein

200- **Anatomical location of apex of the heart:**
A- 4th intercostal space in midclavicular line
B- 5th intercostal space 8-9 cm left to sternal border in midclavicular line
C- 5th intercostal space in midaxillary line
D- 5th intercostal space 5cm left to sternal border in mid clavicular line
Ans: B

201- **Pure phrenic innervation to which part of pleura**
A- Diaphragmatic pleura
B- Mediastinal pleura
C- Costal pleura
D- Whole diaphram
Ans: B

Explanation:
- Costal pleura – Intercostal Nerve
- Mediastinal pleura – Phrenic Nerve
- Diaphragmatic pleura – Dome by Phrenic nerve and peripheral part by Lower Six intercostal nerve.

202- **Which of the following lymphoid structure does not contain lymph nodules?**
A- Spleen
B- Lymph node
C- Thymus
D- Peyers patches
Ans: C

203- **Relation of right vagus nerve with trachea while entering :**
A- Direct contact
B- Separated by recurrant laryngeal nerve
C- Azygos vein
D- Separated by phrenic nerve
Ans: A

204- **AV node blood supply by:**
A- LCA
B- RCA
C- LADA
D- None
Ans: B

Explanation:
All conduction system by RCA , Except RBBB by LCA

205- **Esophagus in thoracic area constricted:**
A- Due to arch of aorta
B- Left bronchus
C- Left crus of diaphragm
D- Bronchi
Ans: A

206- **Eparterial Bronchus supplies to:**
A- Right superior lobe
B- Right inferior lobe
C- Right middle lobe
D- Left lower lobe
E- Left upper lobe
Ans: A

Explanation:
- Eparterial bronchus - right superior lobar bronchus
- hyparterial bronchus is any bronchus originating inferior to the level of the pulmonary artery.

207- **Following Vein opens into right atrium:**
A- Anterior cardiac vein
B- Venae cordisminimi
C- Middle cardiac vein
D- Great cardiac vein
Ans: A

Explanation:
Anterior cardiac vein open directly to right atrium, while venae cordisminimi open into all chambers of heart and chiefly in right atrium

208- **Muscles used in quite inspiration:**
A- Rectus Abdominus
B- External intercostal muscles
C- External Oblique
D- Internal Intercostal
Ans: B

Explanation:
- Muscle of Quite Inspiration – Diaphram and External Intercostal
- Muscle of Forced Inspiration – SCM &Serratous Anterior
- Quite Expiration – Passive and by Elastic Recoil of Lung
- Muscle of Forced Expiration -- Internal Intercostal
- Accessory Muscle of Expiration – External Oblique

209- **Which structure is damaged when needle is inserted in lower border of rib?**
A- Nerve
B- Muscle
C- Vein
D- Artery
E- Lymphatic
Ans: A

210- **A man in RTA had fractured medial side of clavicle pressing posteriorly on right sternoclavicular joint. Damage to which nearby structure will be done?**
A- SVC
B- Trachea
C- Esophagus
D- Aorta
E- Heart
Ans: B

211- **Right Bronchial artery arises from thoracic aorta at:**
A- Second right intercostal space
B- Second left intercostal space
C- Right 3rd Posterior intercostal space
D- 5th intercostal space
Ans: C(KLM)

212- **Muscle attached posteriorly to the lateral arcuate ligament of diaphragm**
A- Quadratus lumborum
B- Piriform
C- Aorta
D- Psoas
E- illius
Ans: A

213- **Phrenic nerve supply mediastinal and diaphragmatic pleura and damage results in paralysis of diaphragm.Major contribution to phrenic nerve is which of the following?**
A- C6
B- C5
C- C4
D- C3
E- C7
Ans: C

214- **Pericardium is**
A- Visceral layer of fibrous pericardium
B- Parietal layer of Serous pericardium
C- Visceral layer of Serous pericardium
D- Present between Fibrous and Visceral layer
Ans: D

215- **Origin of inferior vena cava level is**
A- L5
B- L3
C- L1
D- T5
Ans: A

216- **Thoracic duct drains into:**
A- Right branchiocephalic vein
B- Left brachiocephalic vein
C- Celiac trunk
D- Left atrium
E- Junction of SVC and Azygous vein
Ans: B

Explanation:
Thoracic duct empties into
- Venous system near union of left internal jugular vein and left subclavian vein
- Left venous angle
- Origin of left brachiocephalic vein

217- **Aortic opening passes through which vertebral level on diaphragm?**
A- T8
B- T10
C- L5
D- T12
E- L2
Ans: D(Snell + KLM)

Explanation
- Vena caval opening – T8
- Esophageal opening T10
- Aortic opening – T12

218- **Absence of cartilage in respiratory and terminal ducts differentiates it from which of thr following:**
A- Conducting bronchioles
B- Terminal bronchioles
C- Trachea
D- Alveolar duct
E- Alveolar septum
Ans: C

219- **Cutaneous branches of cervical plexus include**
A- Lesser occipital and greater auricular
B- Greater occipital
C- Greater and lesser occipital
D- Lesser auricular and greater Occipital
Ans: A

220- **A patient with bronchogenic carcinoma posterior to left lung hilum which structure is likely to be damaged?**
A- Phrenic nerve
B- Vagus nerve
C- Esophagus
D- Recurrent Laryngeal nerve
E- Brachiocephalic trunk
Ans: B

CamScanner

Explanation:
- Azygous vein anterior to Right root oflung
- Aorta posterior to Left root lung
- Phrenic nerve anterior to root of lung
- Vagus nerve posterior to root of lung

221- In a normal person, which muscle is involved in forced expiration?
A- External intercostal
B- Internal intercostal
C- Diaphragm
D- Rectus abdominis
E- Elastic recoil
Ans: B

Explanation:
- **Muscle of quite inspiration** – Diaphram and external intercostal
- **Muscle of forced inspiration** – SCM &serratous anterior, scalenus anterior &Medius and pect minor
- **Quite expiration** – Passive and by elastic recoil of lung
- **Muscle of forced expiration** – Internal intercostal
- **Accessory muscle of expiration** – Abdominal muscles (external oblique, rectus abdominis).

222- Emboli in venous circulation will Lodge in:
A- Aorta
B- Pulmonary artery branches
C- Kidney
D- Heart
E- SVC
Ans: B

Explanation:
- Emboli First go to – IVC >Rightatrium
- Emboli first loadge in – Pulmonaryartery (Lung)

223- Xiphisternum is at level
A- At vertebral level T10
B- At vertebral level T9
C- At vertebral level T8
D- At Vertebral level T11
Ans: B

Explanation:
- Vertebral level - T9
- Dermatome - T7

224- Septomarginal band is present in
A- Left atrium
B- Right ventricle
C- Left ventticle
D- Atrial septum
E- Ventricle septum
Ans: B

225- Diaphragmatic pleura supplied by which of the following?
A- Phrenic
B- Phrenic and Intercostal
C- Intercostal
D- Vagus
E- Sympathetic
Ans: B

Explanation:
- Costal pleura – Intercostal Nerve
- Mediastinal pleura – Phrenic Nerve
- Diaphragmatic pleura – Dome by Phrenicnerve and peripheral part by Lower Sixintercostal nerve.

226- Regarding esophagous true is:
A- Upper 1/3rd has striated skeletal muscle
B- Entire esophagus has Striated muscle
C- 1/3rd has Squmous epithelium
D- 2/3rd has columnar epithelium
E- 2/3rd has Skeletal muscle
Ans: A

227- Patient after RTA doesnot need VENT support because his respiration is working properly.Where is the lesion ?
A- At C5
B- At C2
C- Below C5
D- Below C2
E- At C3
Ans: C

228- Area for mitral valve auscultation is which of the following?
A- Right second intercostal space
B- Left second intercostal space
C- Left 4th UCS left to sternum
D- Midclavicular line of Left 5thintercoastal
E- Midaxillary line of Left 4th intercostal space
Ans: D

229- Which lymphoid organ has paracarine action?
A- Thymus
B- Spleen
C- Lymph
D- Tonsils
E- Palatine tonsils
Ans: A

230- A lab boy giving demonstration on Pulmonary function tests.He inspires then forcefully expires.Which of the following is used for forceful expiration?
A- Diaphragm
B- External Intercostal
C- Elastic recoil
D- Rectus Abdominus
E- Seratous anterior
Ans: D

231- Large tumour in posterior mediastinum will compress:
A- Descending thoracic aorta
B- Arch of aorta
C- Azygos vein
D- Thymus
E- Phrenic nerve
Ans: A

232- A 63-year-old man came to emergency with complains of back pain, weakness and shortness of breath. On examination he has an aneurysm of the abdominal aorta at aortic hiatus of diaphragm. Which of the following would most likely be compressed?
A- Vagus nerve
B- Oesophagus
C- Azygos vein
D- Inferior vena cava
E- Phrenic nerve
Ans: C

Explanation:
- **Aortic opening (T12)** – Aorta, thoracicduct and azygous vein.
- **Esophagous opening (T10)** –Esophagous, Right and left vagus,lymphatics.
- **Caval opening (T8)** – IVC and Rightphrenic.

233- Irritation of the peritoneum covering the diaphragm produces pain,which usually is referred to:
A- Left arm
B- Epigastrium
C- Neck and shoulder
D- Inguinal region
E- Medial thigh
Ans: C

234- Left atrium and left ventricle supplied by which artery:
A- LADA
B- RCA
C- LCX
D- LCA
E- Marginal
Ans: C

235- Right Lower lobe has foreign body because it is:
A- It Is wider,shorter & vertical
B- It is horizontal wider
C- It vertical narrower longer
D- It is horizontal narrow long
Ans: A

236- Right atrium infarction involves which of following?
A- Septomarginal band
B- Moderator band
C- Pectinate muscle
D- Papillary muscle
E- Trabeculae
Ans: C

237- Aortic arch dilation will compress which structure?
A- Thoracic duct
B- Left bronchus
C- Right bronchus
D- Vagus nerve
E- Phrenic nerve
Ans: B

238- A patient with localized circumferential subendocardial lateral wall infarct which artery is involved?
A- Aorta
B- Pulmonary artery
C- LCX
D- Marginal
E- Muscular Branches of heart walls
Ans: C

Explanation:
- Inferior wall MI (RCA) – Leads 2, 3 and AVF
- Anterior wall MI (LAD) – Leads V1-V6
- Lateral wall MI (LCX) – Leads I, AVL, V5 and V6

239- In Horner syndrome,damaged segement is:
A- T5-6
B- T3-4
C- T1-4
D- T6-8
Ans: C

240- Stab wound to anterior chest after crossing inter costal muscle which structure will it first come in contact with
A- Endothoracic fascia
A- Parietal pleura
B- Visceral pleura
C- Costal pleural
Ans: A

241- A young man had injury to the neck with some sharp object 3yr ago he notices a buldging swelling above the clavicle on sneezing and coughing this swelling is most probably due to
A- Injury to deep fascia of neck
B- Damage to suprapleural membrane
C- Un-united first rib fracture
D- Damage deep cervical fascia
E- Damage vertebral fascia
Ans: B

CamScanner

242- A young man came with difficulty in pharyngeal swallowing.Which nerve is damaged?
A- II, V, VII, IX
B- V, VII, IX, X, XI
C- V ,VII, IX, X
D- IX, X, XI, XII
Ans: C

243- Clavipectoral fascia pierced by:
A- Cephalic vein
B- Thyrocervical trunk
C- Medial thoracic artery
D- Lateral pectoral nerve
And: A

244- True about thoracic duct:
A- Starts from the level of the twelfth thoracic vertebra (T12) and extends to the root of the neck.
B- Ends in external jugular vein
C- Ascend through caval opening at L5
D- Carries lymphatic drainage from lower limb
Ans: A

245- Which part of lung partially fills costodiaphragmatic recess and moves in and out during inspiration?
A- Lateral
B- Posteriobasal
C- Mediobasal
D- Inferiobasal
E- Lingula
Ans: E

246- A physician auscultates posteroinferior Border of lung at:
A- T6
B- T8
C- T10
D- T11
Ans: C

247- Both RLN severed.Which muscle will be spared?
A- Lateral circoarytenoid
B- Oblique arytenoid
C- Transverse arytenoid
D- Cricothyroid
Ans: D

248- Patient presented with shortness of breath, scratchy sound with no change in respiration. On echocardiography pericardial effusion is noted, which is best site to remove fluid?
A- Subcostal with needle angle superiorly
B- Supracostal with needle angle inferiorly
C- Left 5th intercostal space inferiorly
D- Subcostal with needle angle inferiorly
Ans: A

249- During tracheostomy which muscles are retracted laterally?
A- Sternohyoid and Sternothyroid
B- Stylohyoid
C- Sternothyroid
D- Omohyoid
E- Suprahyoid
Ans: A

250- Sentinel lymph node biopsy in CA breast from which nodes:
A- Anterior and pectoral
B- Medial plus lateral
C- Inferior
D- Parasternal
Ans: A

251- Complete loss of intercostobrachial nerve will cause
A- Sensory loss on Posterior side
B- Sensory loss of 2nd ICS
C- Loss of preganglionic sympathatic
D- Loss of sweating on posterior side of
E- Motor loss at 6th ICS arm
Ans: B

252- Stab Injury at 6th Intercostal space on the right side of the sternum will pierce which of the following structure?
A- Right Atrium
B- IVC
C- SVC
D- Right Ventricle
E- Left Ventricle
Ans: B
Explanation:
- For 6th ICS -IVC
- For 6th Costal cartilage – RA

253- Eparterial brochus supplies to
A- Left medial
B- Mediobasal segment
C- Posterior segment
D- Right main bronchus
Ans: D

254- Specific characteristics of right ventricle is:
A- Pulmonary trunk arises
B- Aorta terminates
C- Has 4 Valves
D- Great sephnous vein arises
Ans: A

255- Right lung has how many lobe
A- 5
B- 4
C- 3
D- 6
Ans: C

Explanation:
Right lung:
- Upper lobe – Apical, posterior and Anterior
- Middle lobe – Lateral and medial
- Lower – Superior, Anterior basal, Medial basal, Lateral basal and posterior basal.

Left Lung:
- Upper Lobe – Apical, posterior, anterior superior lingular and inferior lingular.
- Lower lobe – Superior, Anterior basal, medial basal, lateral basal and posterior basal

256- In 9th intercostal space ovarian CA surgery done which structure will be damage
A- Glosopharangeal
B- Diaphram
C- Percaddiophrenic artery
D- 9th intercostal nerve
E- 10 intercostal nerve
Ans: D

257- Regarding segmental bronchus true is
A- Secondary bronchus
B- Tertiary bronchus
C- Primary bronchus
D- Primary bronchi
Ans: B

258- Thyroid moves with swallowing due to which of following
A- Prevertebral fascia
B- Pretracheal fascia
C- Subcutaneous fat
D- Muscles
E- Cartilage
Ans: B

259- Vein accompanying left circumflex artery is which of the following?
A- Middle cardiac vein
B- Anterior cardiac vein
C- Posterior cardiac vein
D- Thoracic vein
E- Marginal artery
Ans: B
Explanation:
- Great Cardiac vein – Left ant. descending Artery (In anterior interventricular groove)
- Great cardiac vein some part courses between left and right ventricle called Anterior cardiac vein(Anterior intervnetricular vein) accompany – LCX (In left coronary sinus)
- Middle Cardiac vein accompany – Post. Interventricular artery
- Small Cardiac vein accompany – Marginal artery

260- During inspiration the muscle which increases the transverse diameter is:
A- Diaphragm
B- External intercostal
C- Innermost intercostal
D- Internal intercostal
E- Rectus Abdominis
Ans: B
Explanation:
- AP and transverse diameter increase by external intercostal

261- Nerve passing between C5 and C6:
A- C5
B- C6
C- C4
D- C3
Ans: B

262- A patient With RHF and dilated right atrium.Which structure will also be dilated along with it?
A- Chorda tendinae
B- Septomarginal band
C- Trabeculae
D- Papillary muscle
E- Coronary sinus
Ans: E

263- Left lower lobe differented from right upper lobe by:
A- Apical segment
B- Mediobasal
C- Lateral and medial
D- Inferior lingular
Ans: B

264- Blood supply of right middle lobe of lung is:
A- Intercostal artery
B- Bronchial artery
C- Vertebral artery
D- Internal carotid artery
Ans: B

265- While performing bronchoscopy first structure visualized beyond carina is?
A- Upper lobe bronchus
B- Superior segmental bronchus
C- Apical bronchus
D- Middle lobe bronchus
E- Inferior lobe bronchus
Ans: A

266- Anterior to right root of lung:
A- Aorta
B- Azygous vein
C- Phrenic Nerve
D- Vagus nerve
Ans: B

CamScanner

Explanation:
- Azygous vein anterior to Right root of lung
- Aorta posterior to Left root lung
- Phrenic nerve anterior to Root of lung
- Vagus Nerve posterior to Root of Lung

267- Surface of left lung contains groove for:
A- Vagus nerve
B- Arch of aorta
C- Esophagus
D- Azygous vein
E- Phrenic nerve
Ans: B

268- During the thoracic surgical procedure the surgeon should care the structure while ligating the internal thoracic artery the structure likely is:
A- Ipsilateral phrenic nerve
B- Contralateral phrenic nerve
C- Ipsilataral RLN
D- Contralateral RLN
Ans: A

269- Arch of aorta wholly lies in:
A- Superior Mediastinum
B- Posterior Mediastinum
C- Anterior Mediastinum
D- Neck
Ans: A

270- A cardiac surgeon performing open heart surgery, what structure he should be careful of in anterior mediastinum?
A- Aorta
B- Adrenal gland
C- Thymus
D- Jugular vein
Ans: C

271- In the aortic opening if Diaphragm is constricted which of the following structure will be compressed along with aorta?
A- Azygous veins and both phrenic nerve
B- Thoracic duct and vagus nerve
C- Azygous vein and vagus nerve
D- Inferior vena cava
E- Thoracic duct and azygous vein
Ans: E (Snell +KLM)

272- The first structure encountered by bullet after piercing chest wall muscles will be:
A- Vicersal pleura
B- Parietal pluera
C- Pleural space
D- Endothoracic fascia
Ans: D

273- Bronchogenic CA behind the root of left lung causes compression of which structure?
A- Phrenic nerve
B- Intercostal nerve
C- Esophagus
D- Recurrent Laryngeal nerve
E- Aorta
Ans: E

Explanation:
- Azygous vein anterior to Right root of lung
- Aorta posterior to Left root lung
- Phrenic nerve anterior to Root of lung
- Vagus Nerve posterior to Root of Lung

274- Abscess in prevertebral fascia will come
A- Superior mediastinum lateral to vertebral bodies
B- Superior mediastinum anterior to vertebral bodies
C- Superior mediastinum behind to vertebral bodies
D- Anterior Mediastinum
Ans: B

275- Anterior two third interventricular septum is supplied by:
A- Right marginal artery
B- Anterior descending artery
C- LCX
D- Right coronary artery
E- Left coronary artery
Ans: B

Explanation:
Anterior 2/3 of interventricular septum is supplied by anterior interventricular artery (LADA) which is branch of left coronary artery.
Posterior 1/3 is supplied via posterior interventricular artery (PDA) which is the branch of right coronary artery.

276- During thoracocentesis Sample taken at 9th ICS, risk of damage to which structure?
A- 9th IC nerve
B- 10th IC nerve
C- Phrenic nerve
D- Pericardiophrenic artery
E- Internal mammary artery
Ans: A

277- Muscle of forced expiration
A- Quadratus Lamborum
B- Diaphragm
C- External intercostal
D- Abdominal muscles
E- Elastic Recoil
Ans: D

278- Left ventricle ,LBB and RBB supplied by
A- RCA
B- LCA
C- Posterior interventricular artery
D- Right ventricular artery
Ans: B

279- A patient having MI Left circumflex artery infarction area involved will be:
A- Left atrium and left ventricle
B- Right atrium
C- Left ventricular
D- Right atrium
E- Inferior wall
Ans: A

280- Which artery block causes infarct at apex of heart?
A- RCA
B- Anterior interventricular artery
C- LCX
D- Marginal
E- LCA
Ans: B

281- Pulmonary artery supply:
A- Primary bronchi
B- Secondary bronchi
C- Tertiary bronchi
D- Alveoli
Ans: D

Explanation:
- Pulmonary artery supplies – Alveoli
- Left bronchus supplied by – bronchial branches from descending thoracic aorta
- Right bronchus from 3rd post intercostal artery arises from thoracic aorta.

282- Which is posterior relation of left lung hilum?
A- Phrenic nerve
B- Vagus nerve
C- Esophagus
D- Recurrent Laryngeal nerve
E- Brachiocephalic trunk
Ans: B

Explanation:
- Azygous vein anterior to right root of lung
- Aorta posterior to left root lung
- Phrenic nerve anterior to root of lung
- Vagus nerve posterior to root of lung

283- Penetrating chest trauma just to right of medial sternal border at 4th, 5th intercostal spaces pericardium and heart was injured, which chamber is affected?
A- Right atrium
B- Right ventricle
C- Left atrium
D- Left ventricle
Ans: A

284- Patient had an MI on ECG ST elevations in lead II, III and AVF are seen, vessel involved?
A- RCA
B- RCx
C- Marginal
D- LCA
E- LCx
Ans: A

285- Stab wound at left 5th ICS 4cm deep just lateral to sternum structure damage will be:
A- Hilum of Left lung
B- Left pleura
C- Pericardium
D- Left bronchus
E- IVC
Ans: C

286- Ligamentum arteriosum is found between:
A- Vagus nerve
B- Phrenic nerve
C- Right recurrent laryngeal nerve
D- Left pulmonary artery and arch of aorta
Ans: D

287- Which is anterior relation of root of lung:
A- Phrenic nerve
B- Vagus nerve
C- Oesophagus
D- Recurrent Laryngeal nerve
E- Brachiocephalic trunk
Ans: A

Explanation:
- Azygos vein anterior to right root of lung
- Aorta posterior to left root lung
- Phrenic nerve anterior to root of lung
- Vagus nerve posterior to root of lung

288- Which of the following nerve provides Motor Supply to the diaphragm?
A- Intercostal nerves
B- Phrenic nerve
C- Thoracodorsal nerve
D- Sympathetic nerves
Ans: B

289- 10th intercostal nerve passes rectus at the level of:
A- Epigastric region
B- Umbilicus
C- Just above suprapubic region
D- Left iliac region
Ans: B

CamScanner

290- Bronchopulmonary segments in left lung?
A- 9
B- 8
C- 7
D- 6
Ans: A (Prefer 10 in both lungs)

291- Apex of heart supplied by:
A- Right marginal
B- RCA
C- LCA
D- LCX
E- Left marginal
Ans: D

292- Vagus nerve pass through diaphragm at which level:
A- T8
B- T12
C- T10
D- T9
E- T6
Ans: C (Snell + KLM)

293- Four lumbar arteries arise from which of the following?
A- Internal illiac
B- External illiac
C- SMA
D- Aorta
E- Celiac artery
Ans: D

294- Which segment of the spinal cord provides the primary nerve supply to the lower respiratory tract, including the bronchi and bronchioles?
A- T1-T4
B- C1-C4
C- L1-L4
D- T4-T6
E- T6-T12
Ans: A

295- In Myocardial infarction, most common artery involved:
A- Right coronary artery
B- Marginal artery
C- LCX artery
D- Anterior descending interventricular artery
Ans: D

296- Person with atrial fibrillation, now cant speak and walk having exaggerated planter reflex which artery is involved:
A- MIddle cerebral artery
B- Anterior communicating artery
C- Pisterior cerebral artery
D- Vertebral artery
Ans: B

297- Greatest risk of pneumothorax by central venous catheter is when it is placed in:
A- Brachiocephalic vein
B- Left subclavian vein
C- Right subclavian vein
D- Intercostal vein
Ans: C

298- Right lung has bronchogenic carcinoma, middle lobe removed surgically, segments include:
A- Apical and Lingula
B- Medial and lateral
C- Inferior basal
D- Mediobasal And lateral
Ans: B

299- Difference between root of right lung from left lung is:
A- No of primary bronchi
B- No of artries
C- No of veins
D- No of nerves plexus
Ans: A

300- In quiet respiration muscle which increase vertical diameter of thorax is:
A- Diaphragm
B- External intercostal
C- Rectus abdominis
D- External oblique
E- Internal Oblique
Ans: A

301- Chest drain passed to the lower border of the rib, causes damage to:
A- Intercostal nerve
B- Intercostal vein
C- Intercostal artery
D- Intercostal muscles
Ans: A

302- Ductus arteriosus is present between:
A- IVC and pulmonary artery
B- Right pulmonary artery and aorta
C- Left pulmonary artery and IVC
D- SVC and Aorta
Ans: B

303- A young boy with repeated RTI has bronchopulmonary sequestrations which will show anomaly:
A- Bronchial anomaly
B- Veins anomaly
C- Segmental morphology
D- Bronchial symmetry
Ans: C

304- Which one of the following is true about heart?
A- RCA supplies condition system of heart
B- LAS supplies posterior 1/3rd IVS
C- LCA gives LCX and LAD
D- LCA gives RCA
Ans: C

305- Most common site of rib fracture is:
A- Upper Ribs
B- Medial end of Clavicle
C- Just anterior to angle of rib
D- Lateral end of rib
Ans: C

306- In Posterolateral infarct, artery involved?
A- Posterior interventricular artery
B- Posterior ventricular artery
C- Left circumflex
D- Left anterior descending
E- Left marginal
Ans: C

307- Between stomach body and pylorus what is present:
A- Fundus
B- Cardia
C- Antrum
D- Lesser sac
E- Greater sac
Ans: C

308- Intercostal nerves are from:
A- Scapular
B- Dorsal Rami of spinal nerves
C- Sub Scapular
D- Dorsal Subscapular
Ans: B

309- Regarding LCA true is:
A- Give LCX at anterior Interventricular groove
B- Supply SA node 90%
C- Supply AV node 80%
D- Give marginal artery
Ans: A

310- Thoracic duct starts at the level Of:
A- T8
B- T12
C- T10
D- T9
Ans: B

311- Posterior branch at aortic bifurcation is which of following?
A- External illiac artery
B- Median Sacral artery
C- Femoral artery
D- Tibial artery
E- Internal illiac artery
Ans: B

312- About Cardiac plexus:
A- Formed infront of trachea
B- Have preganglionic sympathetic fibers from superior cervical ganglia
C- Behind trachea
D- Contain both sympathetic and parasympathetic fibers
Ans: D

313- Posteriorly inferior limit of lung which we called posterior inferior lobe is at level of:
A- T10
B- T11
C- T12
D- T7
Ans: A

314- Right bundle branch supplied by
A- RCA
B- LCA
C- Posterior interventricular artery
D- Right ventricular artery
Ans: B

315- Bronchial artery arises from which level
A- T3-4
B- T5-6
C- T7-8
D- C6-8
Ans: B

316- From cranial to caudal in intercostal space is:
A- Artery , vein and nerve
B- Nerve , artery and vein
C- Vein,artery and nerve
D- Vein ,nerve
Ans: C

317- Mixed venous blood sample can be obtained from:
A- SVC
B- IVC
C- Right atrium
D- Right ventricle
E- Pulmonary arteries
Ans: E

CamScanner

318- Apex beat is located in:
A- 4th left intercostal space in midclavicular line
B- 3rd right intercostal space in midclavicular line
C- 5th right intercostal space in midclavicular line
D- 8-9 cm to the left of midline in the 5th intercostals space
Ans: D

319- Child present with absent breath sounds on left side. X-ray shows normal right side and portion of intestine on left side cause is:
A- Abdominal wall defect
B- Hiatal hernia
C- Inguinal hernia
D- Patent Pleuroperitoneal membrane
Ans: D

320- Nerve supply of pericardium?
A- Left Vagus nerve
B- Phrenic nerve
C- Glossopharyngeal nerve
D- Right Vagus nerve
Ans: **B**

321- What is posterior to root of left lung
A- Phrenic nerve
B- Subclavian vein
C- Azygous vein
D- Recurrent Laryngeal nerve
E- Vagus nerve
Ans: **E**

322- A neonate is brought by his mother with a complain of cesseation of breath on and off and blue discolouration of skin . On examination decrease chest movements on left side, on auscultation no breath sounds on left side . On x ray bowel loops are seen ?
A- TOF
B- Dextrocardia
C- Congenital Diaphragmatic hernia
D- TGA
Ans: **C**

323- Artery which supplies inferior thyroid gland is branch of
A- Suprascapular artery
B- Thyrocervical trunk
C- Transverse cervical artery
D- Thoracoacromal artery
E- Dorsal scapular artery
Ans: **B**

324- Intercostobrachial arteries arise from
A- Posterior division of Descending thoracic aorta
B- Ventral division of thoracic aorta
C- Dorsal division of thoracic aorta
D- Ascending aorta
Ans **A**

325- Which of the following is true regarding visceral pleura?
A- Sensitive to pain
B- Sensitive to stretch
C- Supply carried by lung autonomic nerves
E- Covered by mesothelium
Ans: **C**

326- In hiatal hernia repair which structure is at risk of damage
A- Azygous vein
B- Vagus nerve
C- Thoracic duct
D- Sympathetic
E- Superior epigastric vessel
Ans: B

327- Posteriorly inferior limit of lung which we called posterior inferior lobe is at level of:
A- 10th rib
B- 9th rib
C- 12 rib
D- 7th rib
Ans: A

328- After gunshot Bullet enter above manubriosternal joint and exit T4 which part will be least affected
A- Heart and Pericardium
B- Arch of aorta
C- Trachea
D- Esophagus
E- Thymus
Ans: D

329- Vein accompanying Left anterior descending artery is which of the following?
A- Middle cardiac vein
B- Anterior cardiac vein
C- Posterior cardiac vein
D- Great Cardiac vein
E- Marginal artery
Ans: D

Explanation:
- Great Cardiac vein – Left ant.Descending Artery(In anterior interventricular groove)
- Great cardiac vein some part courses between left and right ventricle called Anterior cardiac vein(Anterior intervnetricular vein) accompany --LCX(In left coronary sinus)
- Middle Cardiac vein accompany – Post.Interventricular artery
- Small Cardiac vein accompany – Marginal artery

330- Bronchopulmonary segments in Right Lung?
A- 7
B- 9
C- 8
D- 10
E- 12
Ans:

331- A Patient after Gastric content in supine position aspiration will lodge in which of following lobe:(repeated)
A- Apical segment of Right lower lobe
B- Right upper lobe
C- Right posterior lobe
D- Left Posterior lobe
E- Left Upper lobe
Ans: A

332- Posterior one third interventricular septum is supplied by:
A- RMA
B- LAD
C- LCX
D- RCA
E- LCA
Ans: D

Explanation:
- Major portion of interventricular septum that's anterior 2/3rd is supplied by anterior interventricular
- Artery branch of LCA while posterior 1/3rd is supplied by posterior interventricular artery branch of RCA

333- Surgeon doing open heart surgery blood oozing from Vein anteriorly with LAD:
A- Middle cardiac vein
B- Great cardiac vein
C- Small cardiac vein
D- Coronary sinus
Ans: B

Explanation:
- Great Cardiac vein – Left ant.Descending Artery(In anterior interventricular groove)
- Great cardiac vein some part courses between left and right ventricle called Anterior cardiac vein (Anterior intervnetricular vein) accompany --LCX(In left coronary sinus)
- Middle Cardiac vein accompany – Post.Interventricular artery
- Small Cardiac vein accompany – Marginal artery

334- In Left circumflex blocked. Which heart part affected?
A- Left atrium anterior
B- left ventricle posterior
C- Right atrium
D- Right ventricle
Ans: B

335- Surgeon did thoracic surgery and made incision just anterior to the sternum. Which of the following artery is most commonly at risk in this region?
A- Inferior Thyroid artery
B- Superior thyroid artery
C- Internal thoracic artery
D- Internal Carotid artery
E- Subclavian artery
Ans: C

336- A patient had surgery after which he had numbeness of forearm along with difficulty in movement of hand. He was diagnosed as subclavian steal syndrome.Blood supply to which artery is compromised?
A- Internal carotid artery
B- Maxillary artery
C- Vertebral artery
D- Internal jugular vien
E- Anterior Spinal artery
Ans: C

337- Medial arcuate ligament formed from which structure
A- Dorsal mesentry
B- Crura of diaphargm
C- Stomodeum
D- Neural crest cell
E- Psoas muscle
Ans: E

Explanation:
- Median - diaphragm
- Medial - psoas fascia
- Lateral - lumbar fascia

338- Superior laryngeal artery and internal laryngeal nerve passes between
A- Thyroid and cricoid
B- Thyroid and arytenoid
C- Hyoid and epiglots
D- Thyroid and hyoid
Ans: D

339- Medial arcuate ligament formed by
A- Thickening of Psoas fascia
B- Quadratus lumborum
C- Parotid Fascia
D- Diaphragm
E- Crus of Diaphragm
Ans: A

CamScanner

Explanation:
- Median arcuate ligament - diaphragm
- Medial arcuate ligament - psoas fascia
- Lateral arcuate ligament - lumbar fascia

340- Which nerve Lies in contact with superficial cardiac plexus?
A- Right Cervical Sympathetic trunk
B- Left Vagus nerve
C- Brachiocephalic vein
D- Recurrent Laryngeal Nerve
E- Right Vagus nerve
Ans: B

341- Patient in RTA with difficulty in breathing due to?
A- Ipsilateeal diaphragm paralysis
B- Bilateral phrenic damage
C- Intercostal damage
D- Bilateral vague damage
Ans: B

342- Length of right bronchus is
A- 2.5cm
B- 3 cm
C- 1 cm
D- 5 cm
Ans: A

Explanation:
- Right Bronchus - 2.5cm
- Left Bronchus - 5cm

343- Pericardiocentesis is best performed through which one of the following approach?
A- Infrasternal angle needle directed superiorly
B- Suprasternal angle needle directed inferiorly
C- The second intercostal space at the midclavicular line.
D- The second intercostal space at the right sternal angle.
Ans: A

344- During the thoracic surgical procedure the surgeon should care the structure while ligating the internal thoracic artery the structure likely is:
A- Ipsilateral phrenic nerve
B- Contralateral phrenic nerve
C- Aorta
D- Contralateral RLN
E- Vagus nerve
Ans: A

345- A young man had injury to the neck with some sharp object 3yr ago.He notices a buldging swelling above the clavicle on sneezing and coughing.This swelling is most probably due to
A- Injury to deep fascia of neck
B- Damage to suprapleural membrane
C- Un-United 1st rib fracture
D- None of the above
Ans: B

346- Groove on left lung is for:
A- Ascending aorta
B- Descending aorta
C- Esophagus
D- Azygous vein
E- Phrenic nerve
Ans: C

347- Parkinson's patient aspirate fluid on laying it goes in:
A- Posterior segment of right upper lobe
B- Apical segment of right lower lobe
C- Lateral segment of right upper lobe
D- Right upper lobe
Ans: B

Explanation:
- Foreign body in supine – Apical (Superior) segment of right lower lobe.
- Foreign body in sitting/standing (Upright) – Posterior basal segment of right lower lobe.
- Foreign body in right lateral – Posterior segment of right upper lobe.
- Foreign body in left lateral – Inferior lingular of left upper lobe.

348- Vein accompanying left anterior descending artery is which of following?
A- Middle cardiac vein
B- Anterior cardiac vein
C- Posterior cardiac vein
D- Great cardiac vein
E- Marginal artery
Ans: D

Explanation:
- Great Cardiac vein accompany – Left ant. Descending Artery
- Middle Cardiac vein accompany – Post. Interventricular artery
- Small Cardiac vein accompany – Marginal artery

349- Physician want to auscultate a pneumonia patient for pleural effusion at back for lower limit of lungs at tip of scapula, he will auscultate at which level:
A- T1
B- T5
C- T7
D- T9
Ans: C

350- Parkinson's patient presented with dyspnea after aspiration in supine posture, which lobe is affected:
A- Right lower lobe
B- Right upper lobe
C- Right posterior lobe
D- Left Posterior lobe
Ans: A

351- Stab wound just above the xiphisternal joint at fifth intercostal cartilage just to right will damage which structure?
A- Right ventricle
B- Right atrium
C- IVC
D- Liver
E- SVC
Ans: B

352- A patient with bronchogenic carcinoma posterior to left lung hilum which structure is likely to be damage?
A- Phrenic nerve
B- Vagus nerve
C- Esophagus
D- Recurrent Laryngeal nerve
E- Brachiocephalic trunk
Ans: B

Explanation:
- Azygous vein anterior to Right root of lung
- Aorta posterior to Left root lung
- Phrenic nerve anterior to root of lung
- Vagus nerve posterior to root of lung

353- What will be shown on PA view after barium meal and patient has esophageal construction?
A- Arch of aorta
B- Right crus of diaphragm
C- Left crus of diaphragm
D- Bronchi
E- Trachea
Ans: A

354- Patient IVC blocked just above the emergence of azygous vein will lead to dilation of:
A- Left gastric vein
B- Hepatic vein
C- Hepatic artery
D- Splenic artery
Ans: A

Explanation:
- IVC Blocked Above Azygous vein, dilation in – Azygous vein > Left Gastric Vein
- IVC Blocked Upto Azygous vein dilation in – Right Ascending Lumber vein & Right Subcostal Vein
- IVC Blocked Below Azygous vein, dilation in – Ascending Lumber vein
- Dilation of left gastric /blood will pooled back in left azygous vein

355- Left lower lobe lung differ from right upper lobe lung by not having:
A- Anterior basal
B- Medial basal
C- Apical Segment
D- Lateral basal
E- Posterior basal
Ans: C

Explanation:
- By not having – Apical Segment
- By having – Mediobasal

356- Congenital diaphragmatic hernia occur due to:
A- Absent Septum transversum
B- Incomplete pleuroperitoneal membrane
C- Defect in Right Muscle
D- Defect in Left Muscle
E- Central tendon defect
Ans: B

357- Thoracic duct drains into:
A- Junction of internal jugular and left subclavian vein
B- Junction of internal jugular and right subclavian vein
C- Right subclavian vein
D- Right internal jugular vein
E- Right brachiocephalic vein
Ans: A

358- Right Conus Artery supplies:
A- Infundibulum
B- SA Node
C- AV Node
D- Atria
Ans: A

Explanation:
- It supplies the smooth outflow tract of right ventricle(Netter atlas)

359- The pleuroperitoneal membrane contributes to the formation of:
A- Fibrous pericardium
B- Parts of the diaphragm
B- Separation of thoracic and abdominal cavities during embryonic development
D- Pleural cavity lining
Ans: B

Explanation:
Pleuroperitoneal Membranes
- These membranes fuse with the dorsal mesentery of the esophagus and the septum transversum.

CamScanner

- This fusion completes the partition between the thoracic and abdominal cavities and forms the primordial diaphragm. The pleuroperitoneal membranes represent relatively small portions of the neonate's diaphragm

360- A patient presents with a bullet injury to the cervical region and paralysis of the respiratory muscles leading to respiratory distress. Which structure is most likely affected?

A- Serratus Anterior
B- External Intercostal
C- Diaphragm
D- Internal Intercostal
Ans: C

361- Patient suffers a stab injury to the chest, leading to air escaping from the lung and the development of pneumothorax. What is the most likely outcome?

A- Lung collapses inward and the chest wall moves outward
B- Lung collapses inward, and the chest wall moves inward
C- Lung moves outward, and the chest wall moves inward
D- Lung moves outward, and the chest wall also moves outward
Ans: A

362- At which level of spinal cord injury is a patient most likely to experience difficulties with ventilatory function due to impairment of the respiratory muscles?

A- Above C3
B- Between C3 and C5
C- Below C5
D- Between T1 and T5
E- Below T6
Ans: B

363- Diaphragm is attached to which of the following fascia

A- Inominnate fascia
B- Alar fascia
C- Transvarsalis fascia
D- Sacral fascia
Ans: D

364- Patient came with diagnosed DVT with valve defect in lower libs. Which structure will have emboli lodged from this source?

A- Branches of pulmonary artery
B- Branches of pulmonary veins
C- Inferior Vena Cava
D- Heart
E- Spleen
Ans: A

365- Aorta Passes:

A- At root of Left Lung
B- Behind Medial arcuate Ligament
C- Behind Median arcuate Ligament
D- Behind Lateral Arcuate ligament
E- In Middle Mediastinum
Ans: B

366- True regarding "Descending thoracic aorta": (Medicine Feb 2025)

A- Begins at Left side of upper border of body of T4
B- Supplies pericardium, esophagus, and lungs
C- Supplies lower 8 intercoastal spaces on both sides
D- Becomes abdominal aorta at L2
E- Lies in middle mediastinum
Ans: B

Explanation:

- The descending thoracic aorta lies in the posterior mediastinum
- It begins at the lower border of the body of the fourth thoracic vertebra
- Posterior intercostal arteries branch off to the lower nine intercostal spaces on each side
- Subcostal arteries arise on each side and runalong the lower border of the 12th rib to enter the abdominal wall.
- Pericardial, esophageal, and bronchial arteries are small branches that distribute to these organs:
- It becomes abdominal aorta at the level of T12

367- Right intercostobrachial trunk arises from (Medicine Feb 2025)

A- Anterior to aorta
B- Arch of aorta
C- Anterolateral to descending thoracic aorta
D- Post lateral to descending thoracic aorta
E- Post to thoracic aorta
Ans: C

368- A Foreign body is more likely to lodge in the right main bronchus because (Medicine Feb 2025)

A- It is narrower, longer,and more horizontal
B- It is wider,shorter and more vertical
C- It is narrower,shorter and more vertical
D- It is wider, longer and more horizontal
E- It is wider,longer and more vertical
Ans: B(RJ Last

Explanation:

- The Right main bronchus is 2.5cm long and shorter, wider and more vertical
- The left main bronchus is 5cm long and narrower and more horizontal

Better

369- A patient sustained a Gun shot piercing injury from the sternal angle at 2nd intercostal space exiting at the T4 level in the back. Which structure is most likely spared? (Medicine Feb 2025)

A- Oesophagus
B- Trachea
C- Thymus
D- Arch of Aorta
E- Heart & Pericardium
Ans: D

370- A man sustained a shrapnel injury with some sharp object to the neck 3 months ago. He now presents with a lump in the supraclavicular region that appears after coughing & sneezing. What is the most likely cause? (Medicine Feb 2025)

A- Injury to deep fascia of root of neck
B- Injury to the suprapleural membrane
C- Injury to Prevertebral Fascia
D- Injury to PreCervical Fascia
E- Un-United 1st Rib
Ans: B

371- After Firearm injury, the bullet will be in which area after crossing the intercostal muscles (Medicine Feb 2025)

A- Endothoracic Fascia
B- Pleural Cavity
C- Parietal Pleura
D- Visceral Pleura
E- Subcutaneous tissue
Ans: A

Explanation:

Sequence of layers from outside to inside
1. Skin
2. Subcutaneous tissue
3. chest wall muscles
4. Ribs
5. Endothoracis fascia
6. Parietal pluera
7. Pleural cavity
8. visceral pluera

372- A 57-year-old male with intense chest pain, ruled out for cardiac pathology, is diagnosed with a hiatal hernia where the stomach herniates through the esophageal hiatus. Which part of the diaphragm directly borders this hernia? (Medicine Feb 2025)

A- Left dome of the diaphragm
B- Right dome of the diaphragm
C- Central tendonious insertion
D- Costal fibers
E- Sternal fibers
Ans: B

373- During biopsy of Spleen, Avoid injuring pleura which is present in Costodiaphragmatic recess at the level of: (Surgery Feb 2025)

A- 10th rib midaxillary Line
B- 12h Intercostal space midaxillary line
C- 12th intercostal space midclavicular line
D- 10th midclavicular line
Ans: A

374- Costal pleura separated from Internal thoracic wall by: (Surgery Feb 2025)

A- Vicersal pleura
B- Parietal pluera
C- Pleural space
D- Endothoracic fascia
Ans: D

375- 8 months baby presented with complains of dyspnea on lying. On examination decreased breath sounds on left. X-ray was done which showed intestinal loops on left side of the thorax. One of the characteristics finding of this condition: (Surgery Feb 2025)

A- Dextrocardia
B- Hiatal hernia
C- Absence of lung
D- Patent pleuro-peritoneal membrane canal
Ans: D

376- Regarding pulmonary varix: (Surgery Feb 2025)

A- Opens into left atrium
B- Opens into right atrium
C- Present at distal end of vein
D- Decreases blood flow during arterial phase
E- Increases Blood flow during venous phase
Ans: A

Explanation:

Pulmonary varix is pulmonary vein

377- A patient presents after a road traffic accident (RTA) with comfort on the left side of the chest and abdominal content herniation. Through which structure did the herniation most likely occur?(Surgery Feb 2025)

A- Aortic hiatus
B- Esophageal hiatus
C- Diaphragmatic Hiatus
D- Caval hiatus
Ans: C

378- Footballer developed sudden chest pain. O/E,hyperresonant Percussion note,Auscultation reveals decreased air entry on left side. Cause? (Gynae & Obs Feb 2025)

A- Left sided pneumothorax
B- Left sided pleural effusion
C- Right sided pneumothorax
D- Right sided pleural effusion
Ans: A

379- Angle of rib is related to (Gynae & Obs Feb 2025)

A- Neck of rib
B- Shaft of rib
C- head of rib
D- Articular surface of rib
Ans: A

CamScanner

380- A patient present with chest truma present with hyperresonance on left side of chest the most likely diagnosis is (Gynae & Obs Feb 2025)

A- Left pneumothorax
B- Hemothorax
C- Pulmonary efusion
D- Cardiac temponade
Ans: A

381- A patient presents with chest truma and exhibits paradoxical chest wall movement during respiration on examination his blood pressure is 90/60mmhg what is most likely diagnosis (Radiology Feb 2025)

A- Tension pneumothorax
B- Flail chest
C- Hemothorax
D- Cardiac temponade
E- Pulmonary embolism
Ans: B

382- Right lung has bronchogenic carcinoma, middle lobe removed surgically, segments include: (Radiology Feb 2025)

A- Apical and inferior Lingular
B- Medial and lateral
C- Inferior basal
D- Mediobasal And lateral basal
Ans: B(KLM Anatomy)

Explanation:

Right lung	Left lung
Upper lobe	Upper lobe
1 Apical	1 Apical
2 Posterior	2 Posterior
3 Anterior	3 Anterior
Middle lobe	
4 Lateral	4 Superior lingular
5 Medial	5 Inferior lingular
Lower lobe	Lower lobe
6 Superior(Apical)	6 superior(Apical)
7 Medial basal(cardiac)	7 Medial basal(cardiac)
8 Anterior basal	8 Anterior basal
9 Lateral basal	9 Lateral basal
10 Posterior basal	10 posterior basal

383- Which muscles are involved in forceful inspiration? (Radiology Feb 2025)

A- Diaphragm + SCM + External oblique + Serratus anterior
B- Diaphragm+ Internal intercostal
C- Diaphragm + External intercostal + SCM + Serratus anterior + Scalene muscle
D- Diaphragm +External Oblique
Ans: C (Only Suitable)

Explanation:

- Muscle of Quite Inspiration – Diaphram and External Intercostal
- Muscle of Forced Inspiration – SCM & Serratous Anterior, Scalenus anterior & Medius and Pect minor
- Quite Expiration – Passive and by Elastic Recoil of Lung
- Muscle of Forced Expiration – Internal Intercostal
- Accessory Muscle of Expiration –
- Abdominal muscles (External Oblique, Rectus abdominis.
- External intercostal can be used in
- Quite inspiration as well as forceful inspiration

384- A 30-year-old patient is brought to the emergency department after a road traffic accident (RTA). He complains of difficulty in breathing and decreased chest movements on the affected side. Chest X-ray reveals a radiolucent (black) shadow on one side. Rib fractures are also noted. What is the most likely cause of decreased chest movement? (Anesthesia Feb 2025)

A- Pneumothorax
B- Fluid in the pleural cavity
C- Hemothorax
D- Lung Abscess
Ans: A

385- A patient sustained a splinter injury from a blast, resulting in damage to the pericardium. During surgery, the pericardium was found to be damaged on the inferior side. The surgeon inserted her fingers into the pericardium to locate a piece of shrapnel, moving inferiorly, then upwards and to the right, where her fingers stopped at a cul-de-sac near the base of the heart, formed by a fold of the pericardium. What is the most likely location of her fingers? (Anesthesia Feb 2025)

A- Coronary sulcus
B- Coronary sinus
C- Oblique sinus
D- Costodiaphragmatic recess
E- Costomediastinal recess
Ans: C

Books N Beyond
YOUR EDUCATION PARTNER
HOME DELIVERY
FOR ALL OVER PAKISTAN

All kinds of Medical, Commerce, Engineering,
School Books, Nursing uniform,
Doctor Coat and Stationery Items are available.
SCRUB AND INSTRUMENT ALSO AVAILABLE
ALL BOOKS AVAILABLE
0311-1134466
0309-7271940
061-6217975
MCB Bank Road , 148-B,Near Chugtai Lab & Baba Tower,
Gulgasht Colony, Multan.

CamScanner

NISHTAR PUBLICATIONS (Pvt). Ltd.

Volume 2

FOURTH EDITION

DOUBLE "A" NOTES

for FCPS 1

Dr M. Khan

Complete Book for FCPS-1 MD/MS and NLE, NRE Basic Sciences

- Only Book with Feb 2025 FCPS-1 Papers
- Containing All Past Papers from 2015 Till Feb 2025
- Chapter wise Quick Hints of Physiology, Pathology and Anatomy taken from Standard Textbooks (BRS & FIRST AID) Separate section of neurology
- Special focus on Neuroanatomy quick hints and made easy
- Special focus on minor subjects quick hints
- Chapter wise MCQ's with explanation and authentic keys
- Errata update and all keys reviewed
- Exam oriented quick hints and explanation added

By:
Dr. Atif Afzal (AA)

BOOKS N BEYOND
BNB
HOME DELIVERY SERVES AVAILABLE FOR ALL OVER PAKISTAN
0311-1134466
0309-7271940
www.booksnbeyond.pk
booksnbeyond
booksnbeyond
MEDICAL BOOKS
SCHOOL BOOKS
UNIFORM
DR. COAT / SCRUBS
STATIONARY
BAGS
MCB Bank Road, 148-B, Near Chugtai Lab & Baba Tower, Gulgasht Colony, Multan.

CamScanner

TABLE OF CONTENTS

Sr No.	Topic	Page
26.	ABDOMEN	777
27.	PELVIS AND PERINEUM	822
28.	HEAD AND NECK	860
29.	BACK AND VERTEBRAL COLUMN	913
	SECTION 4	
	NEUROLOGY	
30.	CNS PHYSIOLOGY	919
31.	CNS PATHOLOGY	952
32.	NEUROANATOMY	982
	SECTION 5	
	MICROBIOLOGY	
33.	MICROBIOLOGY QUICK HINTS	1055
34.	BACTERIOLOGY	1059
35.	VIROLOGY	1094
36.	MYCOLOGY	1108
37.	PARASITOLOGY	1111
	SECTION 6	
	MINORS	
38.	BIOCHEMISTRY (Including Nutrition & Metabolism)	1120
39.	EMBRYOLOGY	1160
40.	HISTOLOGY	1192
41.	GENERAL ANATOMY	1205
42.	BIOSTATISTICS	1216
43.	BEHAVIORAL SCIENCES	1232
44.	PHARMACOLOGY	1242

CamScanner

ABDOMEN QUICK HINTS

Random

- ✓ T12 – Celiac Trunk
- ✓ L2 – Renal Artery
- ✓ L1 – Superior mesenteric artery
- ✓ L3 – Inferior Mesenteric Artery
- ✓ L4 – Bifurcation of Descending Aorta
- ✓ L5 -- Start of IVC
- ✓ Transpyloric Plane – Pylorus of Stomach, Fundus of Gallbladder, Hilum of Kidney, First
- ✓ part of Duodenum, Origin of SMA, Tip of 9th Costal Cartilage, Lower end of Spinal Cord.
- ✓ **Right Kidney anteriorly** Related to - Liver
- ✓ **Right Kidney Hilum** Anteriorly Related to - 2 nd Part Duodenum
- ✓ **Posterior to Right Kidney** – 12th Rib & Diaphragm
- ✓ **Anterior to Left Kidney** – Stomach & Pancreas
- ✓ **Posterior to Left Kidney** – 10th11th Ribs & Diaphragm
- ✓ **Anterior to Right Suprarenal gland** – IVC and Right lobe of liver
- ✓ **Posterior to Right Suprarenal gland** –Diaphragm
- ✓ **Anterior to Left Suprarenal gland** – Pancreas , Lesser sac and stomach
- ✓ **Posterior to Left Suprarenal gland** –Diaphragm
- ✓ 2nd Part of duodenum Attached posteriorly to – Transverse Mesocolon
- ✓ Right Accessory Hepatic Artery Branch of – SMA
- ✓ Superior Epigastric Artery Branch of – Internal Thoracic Artery
- ✓ Inferior Epigastric Artery Branch of – External iliac Artery
- ✓ Superficial Epigastric Artery Branch of – Femoral Artery
- ✓ External Fascia from external oblique
- ✓ Internal Fascia from fasciatransversalis
- ✓ Cremasteric from internal oblique
- ✓ Direct inguinal hernia occur at - Hesselbach triangle
- ✓ Surgeon performing inguinal hernia repair structure seen - Pampiniform plexus
- ✓ Deep ring formed by - Fascia Transverslis
- ✓ Superficial ring formed by - opening in external oblique aponeurosis
- ✓ Superficial ring traversed by - illioinguinal nerve
- ✓ Inguinal hernia above and medial to pubic tubercle
- ✓ Direct Hernia medial to – Inferior epigastric artery
- ✓ Indirect hernia lateral to – Inferiorepigastric artery
- ✓ Inferior epigastric artery lateral to –Direct hernia
- ✓ Inferior epigastric artery medial to –Indirect hernia
- ✓ Femoral hernia below and lateral to public tubercle
- ✓ Femoral hernia descend behind inguinal ligament
- ✓ In Femoral sheath most lateral structure is - Genital branch of femoral nerve >Femoral artery
- ✓ Out side femoral sheath lateral is - Femoral nerve
- ✓ In Incisional hernia first structure come out is - Transversalis fascia
- ✓ Bare area of liver limited by - Coronary ligament
- ✓ Medial to femoral hernia - Lacunar ligament
- ✓ Lacunar Ligament formed by - Inguinal ligamcnt extension
- ✓ Congenital diaphragmatic hernia is due to - Defective or incomplete pleuro peritoneal membrane
- ✓ Blood supply to adrenal gland via three sources Inferior phrenic ,Aorta and Renal artery
- ✓ Right adrenal gland seprated from kidney by perinephric fat
- ✓ During Esophagectomy Stomach mobilized and which artery used - Right Gastroepiploic artery >Right gastric artery
- ✓ Appendix most common position - Retrocecal
- ✓ Appendix Arterial supply - Illeocolic artery
- ✓ Appendix lymph - Mesoappendix

CamScanner

- ✓ During Appendectomy while giving incision at Mcburney point - illiohypigastric nerve and Deep circumflex artery
- ✓ Pain of appendix felt at umbilicus through T10 Sympathetic
- ✓ Left gastric from – Celiac
- ✓ Right gastric from – Hepatic
- ✓ Short gastric from – Splenic
- ✓ Left Gastroepiploic from – Splenic
- ✓ Right Gastroepiploic from – Gastrodudenal
- ✓ Most Common location of Duodenal Ulcer - **1st part of Duodenum**
- ✓ Perforation of posterior wall of duodenum Bleed by - **Gastro duodenal artery**
- ✓ Most common location of gastric ulcer near - **Incisura angular is on Leisure curvature.**
- ✓ Perforation of lesser curvature Bleed by - **Left gastric artery**
- ✓ Perforation of posterior wall of stomach Bleed by - **Splenic artery**
- ✓ Interlobar artery passes in between medullary pyramid and at the base of pyramid it turns, run parallel to base of pyramid and form Arcuate artery
- ✓ Renal columns contain—Interlobar Artery
- ✓ Capsule Contain – Interlobular Artery
- ✓ Glomerulus Contain – Interlobular Artery
- ✓ Hilum Contain – Segmental Artery
- ✓ Conjointtendon formed by internal oblique and transverse abdominis
- ✓ Femoral sheath is formed by fascia transversialis and fascia ilaica
- ✓ Abdominal angina caused by obstruction of superior mesenteric
- ✓ Gastric ulcer pain due to gastric splanchnic nerve
- ✓ Lesser omentum contains hepatic artery proper ,CBD and portal vein
- ✓ Greater omentum contains right and left gastroepiploic vessels and fat
- ✓ Pain sensations from gastric contents in lesser sac carried by greater splanchnic
- ✓ Fibers of gastric splanchnic nerves synapse in celiac ganglion
- ✓ Celiac trunk is impaired vessels of aorta
- ✓ Hematemesis in CLD patient involves left gastric vein
- ✓ Gastrosplenic junction lies at the level of T11
- ✓ Transverse mesocolon attaches posteriorly by 2nd part of deuodenum
- ✓ Structure not visible at T12 but visible at T11 behind the stomach is tail of pancreas
- ✓ Hepatic acinus is the functional unit of liver
- ✓ Inferior inguinal ligament thickened to form fascia of thigh
- ✓ Hulton valves located at sigmoid colon
- ✓ Difference between spleen and lymph nodes is splenic sinusoids
- ✓ Ascent of horseshoe kidney is prevented by inferior mesentric artery
- ✓ Right and left lobe of liver is divided by middle hepatic vein

Meckel diverticulum

Rule of 2

- ✓ Seen commonly in under 2 year
- ✓ 2% Population
- ✓ 2Feet proximal to iliocecal valve
- ✓ 2 inches long
- ✓ 2 types of mucosa (Ectopic gastricmucosa which usually bleed andPancreatic mucosa
- ✓ 2:1 Male predominance

Posterior Duodenal Wall and Pancreatic Rupture Fluid Leaks into

- ✓ Lesser Sac

Anterior Duodenal Wall Rupture Fluid Leaks into

- ✓ Right Posterior Subphrenic Space (Supine)
- ✓ Right Paracolic Gutter > RIF (Erect)
- ✓ Greater Sac

CamScanner

Ventral mesogastrium Derivatives

Falciform ligament

- ✓ Connect Liver to Anterior abdominal wall
- ✓ Contain Ligament teres

Hepatodudenal ligament

- ✓ Connect Liver to dudenum
- ✓ Contain Portal triad: proper hepaticartery, portal vein, common bile duct

Gastrohepatic ligament

- ✓ Part of lesser omentum
- ✓ Connect liver to Lesser curvature of stomach
- ✓ Contain Gastric vessel
- ✓ Part of Lesser omentum

Dorsal mesogastrium Derivatives

Gastrosplenic ligament

- ✓ Connect greater curvature and spleen
- ✓ Contain Short gastrics, left gastroepiploic vessels
- ✓ Part of Greater omentum

Gastrocolic ligament

- ✓ Connect greater curvature and Transverse colon
- ✓ Contain Gastroepiploic arteries
- ✓ Part of Greater omentum

Splenorenal ligament

- ✓ Connect Spleen to left pararenal space
- ✓ Contain Splenic vessel and tail of pancreas

Epiploic foramen (Winslow's foramen)

- ✓ It is a passage between greater and lesser sac.

Boundaries:

- ✓ Anteriorly – Hepatodudenal ligamenthaving portal triad
- ✓ Posteriorly – IVC
- ✓ Superiorly – Caudate lobe of liver
- ✓ Inferiorly – 1st part of duodenum

Lumbar triangle (of petit)

- ✓ **Anterior boundary** – Post border ofexternal oblique
- ✓ **Floor** – Internal oblique
- ✓ **Posterior boundary** – Anterior borderof lattismusdorsi
- ✓ **Below** – Iliac crest

Pancreas

- ✓ Posterior to **Head** of pancreas -- **IVC**
- ✓ **Posterior to Uncinate process --Aorta**
- ✓ Posterior to **neck** of pancreas – **Portal vein And SMV**
- ✓ **Anterior to uncinateprocress -- SMA**
- ✓ Superior to pancreas — **Splenic Artery**
- ✓ Most abundent cells in Pancrease -- **B cells**
- ✓ Type of **necrosis** in pancrease -- **FAT necrosis**
- ✓ **Tail** of pancreasc lies in -- **Spleno renal (Linorenal) ligament**
- ✓ **CA** most common in -- **Head of Pancreas**

Rectus sheath

Above the arcuate line

Anterior wall

- ✓ External oblique aponeurosis both lamina
- ✓ Anterior lamina of Internal oblique aponeurosis.

Posterior wall

- ✓ Posterior lamina of Internal oblique aponeurosis

CamScanner

- ✓ Transverse abdominis both lamina

Below the Arcuate line

Anterior wall

- ✓ Aponeuroses of all the three flat muscles of the abdomen The aponeuroses of the transversus and internal oblique are fused, but the external oblique aponeurosisremains separate

Posterior wall

- ✓ It is deficient The rectus muscle rests on the fascia transversalis

Foregut

Organs – esophagus , stomach , duodenum (1st and 2and parts) ,liver pancreas , biliary apparatus, gall bladder , spleen

Artrey – CA

Parasympathetic innervation-vagusnerve , CN X

Sympathetic innervation – paraganglionic (greater splanchnic nerve T5 - T9)

Post ganglionic – celiac ganglion

Sensory inervation- T5 - T9

Referred pain – epigastrium

Mid gut

Organs – deuodem(2nd , 3rd and 4th parts), jejuenum , ileum , cecum with appendix , Ascending colon , transverse colon (proximal 2/3rd)

Artrey– SMA

Parasympathetic innervation- vagusnerve , CN X

Sympatbetic innervation – paraganglionic (lesser splanchnic nerve T10 - T11)

Post ganglionic – superior mesentric ganglion

Sensory inervation- T10 - T11

Referred pain – umbilical

Hindgut

Organs – transverse colon (distal 1/3rd) , descending colon , sigmoid colon and rectum

Artrey – IMA

Parasympatbetic innervation – pelvic splanchnic nerve S2 - S4

Sympatbetic innervation – paraganglionic (lumbar splanchnic nerve L1 - L2)

Post ganglionic – inferior mesentric ganglion

Sensory innervation - L1 - L2

Referred pain – hypogastrium

Relations of kidney

RELATIONS OF RIGHT KIDNEY

anteriorly

1. Liver
2. Right colic flexure
3. Second part of deuodenun
4. Rt suprarenal gland

Posteriorly

1. Diaphragm
2. 12th rib
3. Psoas and quadratus lumborum
4. Costodiaphragmatic recess
5. Subcostal nerve
6. Transverse abdominis muscle
7. Iliohypogastric and ilioinguinal nerve

RELATIONS OF LEFT KIDNEY

anteriorly

1. Pancreas
2. Stomach

CamScanner

3. Spleen
4. Left suprarenal gland
5. Left colic flexure
6. Coils of jejunum

Posteriorly

1. Diaphragm
2. 11th and 12th rib
3. Psoas and quadratus lumborum
4. Costodiaphragmatic recess
5. Subcostal nerve
6. Transverse abdominis muscle

Inguinal canal

Extends from deep inguinal ring to superficial inguinal ring

- **Deep inguinal ring** – opening in fascia transversialis
- **Superficial inguinal ring** – defect in aponerosis of externaloblique
- **Contents-**
- Spermatic cord in males
- Round ligament of uterus in females
- Illioinguinal nerve
- **Boundaries –**

AnteriorExternal oblique aponeurosis(entire length) and origin of internal oblique muscles (lateral 1/3rd)
Superior wall Fibers of internal oblique and transverse abdominis muscle
Inferior Linguinal ligament and lacunae ligament
Posterior-Conjoint tendon medially and fascia transversialis laterally

- **HESSELBACH TRIANGLE BOUNDARIES**

- **Laterally** -inferior epigastricartrey
- **Medially** – lateral border of rectus muscle
- **Below** – inguinal ligament

Random about ligments

- Barearea of liver is limited by **coronary ligament**
- Ligament that connect deuodenojeujenal flexure to right crus of diaphragm is **ligament of treitz**
- Splenic vessels are present in **Lineorenal ligament**
- Structure immediately medial to femoral hernia is **lacunar ligament**
- **Medial umbilical ligament** contains remenant of umblicalartrey
- **Median umblical ligament** contains remenant of urachus
- **Lateral umblical ligament** contains inferior epigastricartrey and vein
- Structure attached to lumbar vertebrae is **anterior longitudinal ligament**

Referred pain

- Appendicitis – umbilicus
- Angina – arm , jaw
- Pancreatitis – back
- Diaphragm – shoulder
- Gall bladder – shoulder
- Acute cholecystitis – tp of shoulder

Nerve Supply of anterior abdominal wall muscles

External oblique – lower 6 thoracic, illiohypogastric and illioinguinal
Internal oblique – lower 6 thoracic, illiohypogastric and illioinguinal
Transevrsus - lower 6 thoracic, illiohypogastric and illioinguinal
Rectus abdominis – lower 6 thoracic nerves

CamScanner

Pyrimidalis - 12th thoracic nerve

Nerve supply of posterior abdominal wall muscles

Psoas – lumbar plexus
Quadratus lumborum – lumbar plexus
Illiacus – femoral nerve

LYMPHATIC SUPPLY

Stomach –right and left gastric , right and left gastroepiploic , short gastric
Deuodenum – upward via pancreaticodeuodenal nodes to gastrodeuodenal nodes and celiac nodes and downward to superior mesentric nodes
Jeujenum and illeum – Superior mesentric nodes via intermediate mesentric nodes
Large intestine – mesentric and superior mesentric nodes
Appendix – superior mesentric nodes
Ascending colon – colic and superior mesenteric
Transverse colon – proximal 2/3rd into colic and superior mesenteric nodes . distal 1/3rd into colic and infer mesentric
Descending colon – colic and inferior mesentric nodes
Sigmoid colon – colic and inferior mesentric nodes
Liver – celiac nodes and posterior mediastinal nodes
Gall bladder – celiac nodes
Suprarenal glands – lateral aortic nodes

Jejunum Vsillium

Jejunum	Illium
Deeper red	Paler pink
Thick and heavy	Thin and light
Greater vascularity	Lesser vascularity
Few Long Vasa recta	Many small Vasa recta
Less fat in mesentery	More fat in mesentary
Few Lymph nodules	Many Lymphoid nodules(Payer patches)
PlicaeCirculares(ValvulaeConniventes) Large &Tall	PlicaeCirculares(ValvulaeConniventes)Low&Spar

CamScanner

ABDOMEN

1- **A patient came to ER with severe electrolytes imbalance and dehydration, after initial resuscitation it was found out that she had a resection of a part of gut that she exactly not remember what that part is?**

A- Jejunum
B- Colon
C- Ileum
D- Stomach

Ans: C

Explantion:
Though Max absorption occur in Jejunum but Fluid loss will always from Colon and part of Gut remove which cause Fluid loss is ilium as when Jejunum is removed no Fluid loss will occur because ilium will Start absorbing Fluid but when Ilium removed then Colon will be over loaded so Ilium Removal will cause fluid loss through Colon (**Bailey and Love**).

2- **Small intestine intermittent pain is felt in:**

A- Epigastric region
B- Umbilicus
C- Just above suprapubic region
D- Left iliac reigon

Ans: B

Explanation
- Appendicitis – umbilicus
- Angina – arm , jaw
- Pancreatitis – back
- Diaphragm – shoulder
- Gall bladder – shoulder

3- **Intestinal infarction due to SMA blocks which part of large intestine spared?**

A- Appendix
B- Ileum
C- Asending colon
D- Descending colon

Ans: D

4- **Lesser omentum contains**

A- Hepatic duct
B- Splenic Artery and CBD
C- Hepatic artery proper, CBD and portal vein
D- Bile duct and Gastric artery

Ans: C

5- **Patient after RTA Fracture of 11 12 ribs left side hypotension cause is:**

A- Gall bladder injury
B- Spleen Rupture
C- Pancreass Rupture
D- Kidney injury

Ans: B

Explanation:
- Spleen located on left side at the level of 9-11 Ribs.

6- **The artery which has major blood supply to rectum is branch of:**

A- Inferior mesenteric
B- Superior mesenteric
C- Celiac
D- Right gastric

Ans: A (Superior rectal)

7- **In appendicitis pain around the umbilicus pass thorough:**

A- Sensory through T10
B- Sympathetic nerve at T10
C- Parasympathetic
D- Ilioinguinal nerve

Ans: B

8- **Anterior Relation of left adrenal gland:**

A- Liver
B- IVC
C- Aorta
D- Lesser sac
E- Duodenum

Ans: D

Explanation:
Left Adrenal
- Anterior – Lesser Sac, Pancreas and Stomach
- Posterior – Diaphragm

Right Adrenal
- Anterior – Right lobe liver and IVC
- Posterior – Diaphragm

9- **Appendicular artery branch of:**

A- Posterior cecal
B- Illiocolic artery
C- SMA
D- Celiac

Ans: B (RJ last)

10- **Capsule of kidney prevents spread of infection:**

A- True pelvis
B- False pelvis
C- Opposite kidney
D- Inferior pelvis

Ans: C

11- **A known old patient presents with Hemetemesis resulting from rupture of Esophagealvarices. Bleeding from which vessel:**

A- Superior mesenteric vein
B- Right gastric vein
C- Left gastric vein
D- Azygous vein
E- Inferior mesenteric vein

Ans: C

CamScanner

12- Meckel's diverticulum is commonly located at:

A- Mesenteric border of small intestine one meter above ileocaecal valve
B- Mesenteric border of small intestine two meter above ileocaecal valve
C- Antimesenteric border of small intestine one meter above ileocaecal valve
D- Antimesenteric border of small intestine two feet above ileocaecal valve

Ans: D

13- Pain sensation originates from the gastric contents in the lesser sac is carried by:

A- Leesersolanchmic
B- Greater splanchmic
C- Autonomus
D- Lower intercistal nerve
E- Phrenic

Ans: B

14- Patient presented with malabsorption and anemia and from which site maximum absorption occurs:

A- Ilium
B- Jejunum
C- Colon
D- Duodenum

Ans: B

15- Blood supply of first part of duodenum:

A- Gastroduodenal artery
B- Pancreatic artery
C- Inferior pancreatoduodenal artery
C- Superior mesenteric artery

Ans: A

Explanation:

- The proximal part of duodenum is supplied by gastro duodenal artery.
- While distal part of duodenum is supplied via superior mesenteric and inferior pancreatoduodenal artery

16- Gastro duodenal artery is the branch of:

A- Common hepatic artery
B- Splenic artery
C- Celeic trunk
D- Proper hepatic artery

Ans: A

17- Arteries arise from the posterior aspect of abdominal aorta:

A- Celiac trunk
B- Sacral arteries
C- Iliac arteries
D- Inferior mesenteric artery

Ans: B

18- Which one is the intraperitoneal organ?

A- Aorta
B- Pancreas
C- 1st part of duodenum
D- Second part of duodenum

Ans: C (All others are retroperitoneal organs)

19- Transverse colon attaches to posterior abdominal wall by:

A- Transverse mesolocolon
B- Ligamentum flavum
C- Intraperitoneal ligament
D- Gastro duodenal ligament

Ans: A

20- Which of the following is potentially related with transverse colon:

A- Second part of duodenum
B- Spleen
C- Pancreas
D- Greater curvature of stomach

Ans: A

21- During surgery on reaching hepatic duct one structure was seeing looping around and going towards the target organ. What structure is this?

A- Right hepatic duct
B- Left hepatic duct
C- Cystic duct
D- Right Hepatic artery

Ans: D

22- Fibres of greater splanchnic nerves synapse in:

A- Celiac ganglion
B- Superior mesenteric ganglion
C- Inferior mesenteric ganglion
D- Hypogastric plexus

Ans: A

23- A 25 year old man presented with the complaint of post prandial bloating & abdominal cramping. He has history of passing foul smelling stool. Which investigation will give us multiple information regarding the problem?

A- Stool C & S
B- Stool DR
C- Serum lipid profile
D- Ultrasound

Ans: B

Explanation:

- When sign of infection present choose Stool C/S aund to rule out mass or malignancy we do Stool D

CamScanner

24- As horse shoe kidney ascend from pelvis during fetal development, it remains low because get trapped under:

A- Superior mesentric artery
B- Aorta
C- Inferior mesenteric artery
D- Celiac
Ans: C

25- Inferior Boundary nf epiploic foramen is:

A- Inferior Vena cava
B- 1st part of dudenum
C- Liver
D- Caudate lobe
Ans: B

Explanation:
Epiploic foramen (Winslow's foramen)
- It is a passage between greater and lesser sac.

Boundaries:
- **Anteriorly** – Hepatoduedinal ligament having portal triad
- **Posteriorly** – IVC
- **Superiorly** – Caudate lobe of liver
- **Inferiorly** – 1st part of Duodenum

26- While doing surgery splenic vessel need to be ligated they are present in which ligament?

A- Gastro splenic
B- Hepatosplenic
C- Linorenal
D- Splenigastric
Ans: C

27- A young man sustained RTA with multiple rib fracture has difficulty in breathing u noticed that his is moving more during breathing which muscle help him in breathing?

A- Diaphragm
B- External oblique
C- External intercostal
D- Internal intercostal
E- Transverses
Ans: B

18- Pancreatic injury secretion goes into:

A- Lesser sac
B- Rt. paracolicguter
C- Left paracolicguter
D- Sub phrenic space
Ans: A

Explanation:
Posterior duodenal wall and pancreatic rupture fluid leaks into:
- Lesser Sac

Anterior duodenal wall rupture fluid leaks into:
- Right Posterior Subphrenic Space (Supine)
- Right Paracolic Gutter > RIF (Erect)
- Greater Sac

29- Tubular organ having aggregate of lympboid tissue:

A- Appendix
B- Ileum
C- Duodenum
D- Colon
Ans: A

30- Liver attaches to Anterior abdominal wall via:

A- Coronary ligament
B- Falciform ligament
C- Hepatogastric ligament
D- Inguinal ligament
Ans: B

31- Which of the following structure lies anterior to IVC?

A: Right testicular artery
B: Aorta
C: SMA
D: Right renal vein
Ans: A

Explanation:
Anterior to IVC:
- Right Testicular /Ovarian Artery
- 3rd Part of duodenum
- Root of Mesentry

Posterior to IVC:
- Right Renal Artery
- Right Celiac Ganglion
- Right Supra renal gland

32- Injury to the right side of the hepatoduodenal ligament causes injury to:

A: CBD
B: Portal vein
C: Hepatic artery
D: Hepatic vein
Ans: A

33- Lymphatic drainage of inflamed appendix:

A: Inferior mesenteric nodes
B: Superior mesenteric nodes
C: Celiac nodes
D: Internal iliac nodes
Ans: B

34- Left supra renal gland supplied by:

A- Inferior phrenic artery
B- Have posterior relation with pancreas
C- Left suorarenal vein drained into IVC
D- Superior mesentricartrey
Ans: A

CamScanner

35- During laporotomy which layer would surgeon encounter between peritoneal layer and transversus abdominis muscle?

A- Skin
B- Subcutaneous layer (fatty layer)
C- Transversalis fascia
D- External oblique
E- Internal oblique
Ans: C

Explanation:
Layers are
1. Skin
2. Subcutaneous layer
3. Superficial fascia
4. External oblique
5. Internal oblique
6. Transversalis muscle
7. Transversalis fascia
8. Peritoneum

36- Celiac plexus lies:
A- Anteriorly to Aorta
B- Anteriorly to IVC
C- At level of L3
D- Right crus of diaphragm
Ans: A

37- Which is unpaired vessel of aorta?
A- Celiac Trunk
B- Renal Artery
C- Ovarian Artery
D- Thyrocervical trunk
Ans: A

38- Pancreatica magna branch of:
A- Splenic artery
B- Hepatic artery
C- Celiac artrey
D- Inferior mesentricartrey
Ans: A

39- Hepatoduodenal ligament contains which of the following structure?
A- Celiac Trunk
B- IVC
C- Aorta
D- Portal Vein
Ans: D

40- Posterior to head of pancreas:
A- Stomach
B- Lesser sac
C- Splenic vessels
D- IVC
Ans: D

Explanation:
- Posterior to Head of pancreas – IVC
- Posterior to Uncinate process – Aorta
- Posterior to neck of pancreas – Portal vein And SMV
- Anterior to uncinate process – SMA
- Superior to pancreas — Splenic Artery
- Most abundent cells in Pancrease – B cells

41- Lymphatic drainage of fundus of stomach:
A- Celiac
B- Superior mesenteric nodes
C- Splenic nodes
D- Inferior mesenteric nodes
Ans: A

42- Inferior mesenteric artery is ligated which part of large intestine is affected:
A- Ascending and transverse
B- Transverse only
C- Transverse and descending colon
D- Descending and sigmoid colon
E- Ascending and descending colon
Ans: D

43- Posterior Boundary of epiploic foramen is:
A- Inferior Vena cava
B- 1st part of duodenum
C- Liver
D- Caudate lobe
Ans: A

Explanation:
Epiploic foramen (Winslow's foramen)
- It is a passage between greater and lesser sac.

Boundaries:
- **Antriorly**– Hepatoduedinal ligament having portal triad
- **Posteriorly** – IVC
- **Superiorly** – Caudate lobe of liver
- **Inferiority** – 1st part of Duodenum

44- Alcoholic patient with Pain referred to shoulder Structure from which pain arises is:
A- Liver
B- Gall bladder
C- Spleen
D- Pancreas
Ans: B

45- Notch at lesse curvature of stomach:
A- Pylorus
B- Antrum
C- Incisura angularis
D- Fundus
Ans: C

CamScanner

46- Anterior Relation of right adrenal gland:
A- Liver
B- IVC
C- Aorta
D- Lesser sac
E- Duodenum
Ans: B

Explanation:
Left Adrenal:
- Anterior – Lesser Sac, Pancreas and Stomach
- Posterior – Diaphragm

Right Adrenal:
- Anterior – Right lobe liver and IVC
- Posterior – Diaphragm

47- Which of the following is functional unit of Liver?
A- Lobule
B- Hepatocyte
C- Segment
D- Hepatic acinus
E- Sinusoids
Ans: D

48- Child having meckel diverticulum s having bleeding per rectum it is due to:
A- Volvulus
B- Intussusception
C- Ectopic gastric tissue
D- None
Ans: C

49- Main renal artery enters hilum at which level?
A- L3 – 14
B- L4 – 15
C- L1 – 2
D- L3
Ans: C

50- Renal capsule supplied by:
A- Interlobar artery
B- Interlobular artery
C- Segmental artery
D- Renal artery
Ans: B

Explanation:
- Renal columns contain — Interlobar Artery
- Capsule Contain – Interlobular Artery
- Glomerulus Contain – Interlobular Artery
- Hilum Contain – Segmental Artery

51- Nerve supply of rectus abdominis:
A- Lower six thoracic
B- Subcostal only
C- Last five intercostal, subcostal, ilioinguinal and illiohypogastric
D- Last five intercostal, subcostal and ilioinguinal only:
Ans: A

Explanation:
- Rectus abdominis – Lower six thoracic
- Transverse abdominis – Lower six thoracic and illiohypogastric and illinguinal nerve (L1).

52- Inferior epigastric artery lateral to which hernia?
A- Direct hernia
B- Indirect hernia
C- Umblical hernia
D- Epigastric hernia
Ans: A

Explanation:
- Direct Hernia medial to – Inferior epigastric artery
- Indirect hernia lateral to – Inferior epigastric artery
- Inferior epigastric artery lateral to – Direct hernia
- Inferior epigastric artery medial to – Indirect hernia

53- Celiac plexus level at:
A- L4
B- L3
C- T9
D- L1
Ans: D

54- Gastro easophageal junction lies at:
A- T11
B- T12
C- L1
D- L3
Ans: A

55- Regarding supra renal vein, which of the following is correct?
A- Right Supra renal vein drains into Renal vein
B- Left supra renal vein drains into renal vein
C- Both supra renal veins drain into renal vein
D- Right supra renal vein drains into common iliac vein
E- Left Supra renal vein drain into IVC
Ans: B

Explanation:
- Right renal, Supra renal, Gonadal and left renal all drain into – IVC
- Left Suprarenal and Gonadal vein drain into – Left renal vein.

CamScanner

56- Most important feature of meckel diverticulum is which of following:

A- Contain Pancreatic Tissue
B- Contain Ectopic Gastric Tissue and Pancreatic Tissue
C- 2 Feet Proximal to ileocecal valve
D- 4 Feet Proximal to ilium
E- Contain Splenic Mucosa

Ans: B

Explanation:

Rule of 2

- Seen commonly in under 2 year
- 2% Population
- 2Feet proximal to illiocecal valve
- 2 inches long
- 2 types of mucosa (Ectopic gastric mucosa which usually bleed and Pancreatic mucosa(May cause bleed). These two mucosa are important histological feature of Meckel diverticulum

57- Superficial epigastric artery is a branch of:

A- External iliac
B- Internal iliac
C- Internal Thorcic
D- Internal pudendal artery
E- Femoral

Ans: E(Snell)

Explanation:

- Superior Epigastric Artery Branch of – Internal Thoracic Artery
- Inferior Epigastric Artery Branch of – External iliac Artery
- Superficial Epigastric Artery Branch of – Femoral Artery

58- Pararenal fat is an extension of?

A- Renal fascia
B- Peritoneum
C- Fusion fascia
D- Transversalis fascia
E- Cremasteric fascia

Ans: A

59- Superficial fascia is mixture of:

A- Dense irregular and loose areolar
B- Loose Areolar and Adipose Tissue
C- Elastic and collagen fibres
D- Dense regular connective and areolar
E- Dense Elastic tissue

Ans: B

60- Patient have abdominal pain on sigmoidoscopy there is obstruction in upper part of sigmoid colon with ulcer patient have appendectomy scar that was done few year back cause of this is:

A- Crohn's disease
B- Ulcerative colitis
C- Diverticulosis
D- Fatty diet
E- Previous surgery

Ans: C

Explanation:

Though crohn disease has the same presentation as diverticulosis and has ulcer associated with it but diverticulosis may also be associated with ulcer and more commonly occur in sigmoid colon and crohn disease mostly in terminal ileum.

61- Patient presented with decrease peripheral pulsation with abdominal pain and creatinine kinase normal and pulsating abdominal mass with fasting glucose of 130 – 150 from last 20 years is most likely suffering from:

A- Thoracic aortic Aneurysm
B- Abdominal Aortic Aneurysm
C- Rupture of IVC
D- Common Iliac artery Aneurysm
E- Superior vena Cava Aneurysm

Ans: B

62- Patient has severe anaemia there's irregular shape and size of RBCs have been seen on the part of GIT. Which part of GIT is involved in this?

A- Fundus of Stomach
B- Colon
C- Duodenum
D- Pylorus of Stomach
E- Jejunum

Ans: C

Explanation:

- Iron and Calcium absorption – Duodenum
- Max water + electrolytes absorption – Jejunum
- Passive (Aldosterone independent) water absorption - Jejunum
- Absorption of Long chain FA - Jejunum
- Vitamin B12 and Bile Salts Absorption - Terminal ileum
- Absorption of Short chain FA - COLON
- Active (Aldosterone Dependent) water absorption - Colon

63- Transverse mesocolon is attached posteriorly by?

A- 2nd part of duodenum
B- Gastrohepatic ligament
C- Hepatoduodenal ligament
D- Splenorenal ligament
E- Lesser Sac

Ans: A

64- Left gastro epiploic artery is the branch of which of the following?

A- Splenic
B- Hepatic
C- Gastroduodenal artery
D- Gastric
E- Celiac

Ans: A

CamScanner

Explanation:
- Left gastric from – Celiac
- Right gastric from – Hepatic
- Short gastric from – Splenic
- Left Gastroepiploic from – Splenic
- Right Gastroepiploic from – Gastroduodenal

65- Which of the following structures is between celiac plexus and SMA?
A- Pancreas
B- Liver
C- Stomach
D- Spleen
Ans: A

Explanation:
Pancreas is anterior to Celiac plexus and SMA is anterior to Uncinate process of Pancreas so pancreas is between Celiac plexus and SMA.

66- Most common cause of bleeding in duodenal ulcer on posterior wall is by which artery?
A- Superior pancreatic duodenal artery
B- Inferior pancreatic duodenal artery
C- Gastro duodenal artery
D- Right gastroepiploic artery
E- Left gastroepiploic artery
Ans: C

Explanation:
- Perforation of posterior wall of duodenum Bleed by – Gastro duodenal artery.
- Perforation of lesser curvature Bleed by – Left gastric artery.
- Perforation of posterior wall of stomach Bleed by – Splenic artery

67- A medical student is examining a slide under the microscope but he is unable to differentiate the gallbladder different from the colon; the point which will help him in differentiating the gallbladder from colon histologically will be?
A- Muscular layer arranged in 3 layers in the gallbladder wall
B- Columnar epithelium in gallbladder wall
C- Peyer's patches in the gallbladder wall
D- No submucosa in the gallbladder wall
E- No serosa in the gallbladder wall
Ans: D

68- Left gastric artery is branch of which of following?
A- Celiac artery
B- Splenic artery
C- Hepatic artery
D- SMA
E- IMA
Ans: A

Explanation:
- Left gastric from – Celiac
- Right gastric from – Hepatic
- Short gastric from – Splenic
- Left gastrocpiploic from – Splenic
- Right gastroepiploic from – Gastroduodenal

69- Patient presented with RHC pain dermatome for cholecystitis include:
A- T3 – 9
B- T10 – 12
C- T7 – 9
D- T8 – T12
E- T7 – L1
Ans: C

70- Anterior to hilum of right kidney is:
A- Liver
B- Pancreas
C- 2nd Part of duodenum
D- Gall Bladder
E- Hepatic Flexure
Ans: C

Explanation:
- Anterior to Right kidney Hilum – 2nd part of duodenum
- Anterior to Right kidney – Liver

Explanation:
- A large part of upper part of the anterior surface is against the Liver and is separated from it by a layer of peritoneum.
- Medially, The descending(2nd) part of the duodenum is retroperitoneal and contacts the Kidney.
- Ref. Gray's Anatomy

71- Which of the following runs along the superior margin of Pancreas?
A- Splenic vein
B- Portal vein
C- Superior mesenteric vein
D- Splenic artery
E- Aorta
Ans: D

Explanation:
- Posterior to Head of pancreas – IVC
- Posterior to Uncinate process – Aorta
- Posterior to neck of pancreas – Portal vein And SMV
- Anterior to uncinate of pancress – SMA
- Superior to pancreas — Splenic Artery

72- Microscopic slide show Glands in tissue submucosa. Which organ is this?
A- Fundus of stomach
B- Duodenum
C- Jejunum
D- Ilium
E- Colon
Ans: B

CamScanner

73- Valvulae Conniventes is found in which part of GIT?
A- Ilium
B- Jejunum
C- Colon
D- Stomach
E- Sigmoid colon
Ans: B (KLM)

74- Hepatic veins drains into which of following?
A- IVC
B- Portal vein
C- Jugular vein
D- Renal vein
Ans: A

75- Which structure lies anterior to the uncinate process of pancreas?
A- Lesser sac
B- Superior mesenteric vessels
C- Greater sac
D- Portal triad
E- Aorta
Ans: B

Explanation:
- Posterior to Head of pancreas – IVC
- Posterior to Uncinate process – Aorta
- Posterior to neck of pancreas – Portal vein And SMV
- Anterior to uncinate process – SMA
- Superior to pancreas — Splenic Artery

76- Free margin of falciform ligament contains which of following?
A- Ligamentum teres
B- Portal vein
C- Ligamentum venosum
D- Ligament of treitz
E- Hepatic vein
Ans: A

77- Left gastric vein drains into:
A- Portal vein
B- SM vein
C- Splenic vein
D- Hepatic vein
E- Renal vein
Ans: A

78- Which one is more sensitive to pain?
A- parietal
B- visceral
C- all of the above
D- none of the above
Ans: A(RJ last)

79- Structure in front of 2nd part of duodenum is which of following?
A- Bile duct
B- Head of pancreas
C- Colic flexure
D- Transverse mesocolon
E- Quadrate lobe
Ans: D

Explanation:
2nd part Duodenum Relations
Anteriorly
- Transverse Colon and Mesocolon
- Right lobe of liver
- Fundus of Gallbladder
- Small intestine coil

Posteriorly
- Right kidney Hilum
- Right Ureter

Laterally
- Right Lobe of Liver
- Right Colic Flexure
- Ascending Colon

Medially
- Head of Pancreas
- Bile duct
- Main Pancreatic duct

80- Which of following vein dilated in portal Hypertension?
A- Left colic
B- Left suprarenal
C- Inferior epigastric
D- Superior mesenteric
E- Inferior phrenic
Ans: A

81- Posterior branch at aortic bifurcation is which of following?
A- External illiac artery
B- Median Sacral artery
C- Femoral artery
D- Tibial artery
E- Internal illiac artery
Ans: B

82- Rectus sheath above arcuate line is formed by:
A- Internal oblique and transverse abdominis
B- External and internal oblique aponeurosis
C- Transverse abdominis aponeurosis
D- Internal oblique aponeurosis
E- Rectus muscle
Ans: B(Grey's anatomy)

Explanation:
Above the arcuate line
Anterior wall
- External oblique aponeurosis both lamina
- Anterior lamina of Internal oblique aponeurosis.

CamScanner

Posterior wall

- Posterior lamina of Internal oblique aponeurosis
- Transverse abdominis both lamina

Below the Arcuate line

Anterior wall

- Aponeuroses of all the three flat muscles of the The aponeuroses of the transversus and the internal oblique are fused, but the external oblique aponeurosis remains separate

Posterior wall

- It is deficient The rectus muscle rests on the fascia transversalisthe arcuate line

83- A patient's intestine does not gets back to. Diagnosis is:

A- Gastroschisis
B- Omphalocele
C- Meckel's diverticulum
D- Intussusception
E- Volvulus
Ans: B

84- Artery Present at the base of pyramids:

A- Arcuate
B- Lobar
C- Interlobar
D- Interlobular
E- Segmental
Ans: A

Explanation:

- Interlobar artery passes in between medullary pyramid and at the base of pyramid it turn run parallel to base of pyramid and form Arcuate artery
- Renal columns contain—Interlobar Artery
- Capsule Contain – Interlobular Artery
- Glomerulus Contain – Interlobular Artery
- Hilum Contain – Segmental Artery

85- Artery with thick elastic fibres is:

A- Aorta
B- Pulmonary artery
C- Brachial artery
D- Femoral artery
E- Renal artery
Ans: A

86- At L1 level on CT scan shows which structure?

A- SMA origin from aorta
B- Inferior vena cava origin
C- Splenic vein passing above pancreas
D- Spleen
Ans: A

Explanation:

Transpyloric Plane at L1 – Pylorus of stomach, fundus of gallbladder, hilum of kidney, first part of duodenum, origin of sma, tip of 9th costal cartilage, lower end of spinal cord.

87- Patient in OT, surgery is undergoing. Patient needs bladder emptying, surgeon passed needle to upper surface of bladder vessel at risk of damage is:

A- Deep Circumflex artery
B- Superficial Circumflex artery
C- Inferior epigastric
D- Superior epigastric
E- Iliohypogastric
Ans: C

88- Lumbar triangle anterior boundary is formed by:

A- Posterior border of external oblique
B- Anterior border of external oblique
C- Latissimus Dorsi
D- External intercostal
E- Iliac crest
Ans: A

Explanation:

Lumbar triangle (of petit)

- **Anterior Boundary** – Post border of external oblique
- **Floor** – Internal oblique
- **Posterior Boundary** – Anterior Border of latissimus dorsi
- **Below** – Iliac crest

89- Gastric carcinoma involving the left upper side of stomach will spread first to which lymph node?

A- Superior mesenteric nodes
B- Celiac nodes
C- PancreaticoSplenic nodes
D- Inferior mesenteric nodes
E- Gastroepiploic nodes
Ans: C

90- Four lumbar arteries arise from which of following?

A- Internal illiac
B- External illiac
C- SMA
D- Aorta
E- Celiac artery
Ans: D

91- Lesser sac bounded by:

A- Superiorly there is caudate lobe of liver
B- Inferiorly there transverse colon
C- Posteriorly bounded by aorta
D- On left side there is epiploic foramen
E- On right side the is gastrosplenic ligament
Ans: A

92- Meckel's diverticulum is defect of which part of gut?

A- Jejunum
B- Ileum
C- Large intestine
D- Colon
E- Duodenum
Ans: B

CamScanner

93- Origin of External Oblique is:
A- Cartilage of 7-8 Ribs
B- External surface of Rib 5-12
C- 9th and 10th rib
D- External surface of Rib 1-4
E- Cartilage of 9 9-10 Ribs
Ans: B

94- Lesser and greater sac are separated all over except at one place:
A- Epiploic foramen
B- Laterally
C- Jugular foramen
D- Quadrate lobe
E- 1st part of Duodenum
Ans: A

95- In the transverse cut section which structure is not visible at T11 but visible at T12 behind the stomach?
A- Gallbladder
B- Spleen
C- Aorta
D- IVC
E- SVC
Ans: B (No option of Tail of pancreas)

96- A patient having esophageal mass During esophagectomy stomach is mobilised to the upper portion of thorax to anastomosis with pharynx which artery is mobilized for stomach supply?
A- Short gastric
B- Right gastric
C- Left gastric
D- Right gastroepiploic
E- Left gastroepiploic
Ans: D>B (Bailey)

97- In paramedian approach incision artery can be damaged is:
A- Inferior epigastric
B- Superior Epigastric
C- Internal illiac
D- External illiac
E- Uterine artery
Ans: A

98- External oblique fibres interdigitate with which of following:
A- Serratus anterior
B- Trapezius
C- Sternocleidomastoid
D- Latissimus dorsi
E- Rhomboid major
Ans: A

99- Iliolumbar is branch of which of the following?
A- Femoral artery
B- Tibial artery
C- Internal iliac artery
D- Abdominal aorta
E- Vesicle artery
Ans: C

100- CBD opens into
A- 1st part of deuodenum
B- 2nd part of deuodenum
C- 3rd part of deuodenum
D- jeujenum
Ans: B

Explanation:
Epiploic foramen (Winslow's foramen)
It is a passage between greater and lesser sac.
Boundaries:
- **Anteriorly** – Hepatoduodenal ligament having portal triad
- **Posteriorly** – IVC
- **Superiorly** – Caudate lobe of liver
- **Inferiorly** – 1st part of duodenum

101- Regarding houston valves true:
A- Transverse plicae
B- Semilunar valve of colon
C- Transverse valves of colon
D- Oblique valves
Ans: C

102- Portal vein is present in free edge of:
A- Epiploic foramen
B- Greater sac
C- Lesser omentum
D- Bild duct
Ans: C

103- Root value of thoracic splanchnic nerve in renal and supraenal plexus:
A- T5-L1
B- T1-T2
C- T2-T3
D- T3-T4
Ans: A

104- In duodenal ulcer,which lymph node is involved?
A- Superior mesenteric
B- Superior mesenteric + Celiac
C- Inferior mesenteric
D- Inferior mesenteric +Celiac
E- Celiac
Ans: E

Explanation:
Ulcer occur at 1st part which is mostly drain by Celiac lymph node.

CamScanner

105- Hepatodudonal contents include:
A- Hepatic artery. Portal vein and CBD
B- CBD only
C- Hepatic Duct
D- Hepatic artery and Hepatic Duct
Ans: A

106- Posterior relation of head of pancreas is:
A- PUJ
B- Pelvic brim
C- Psoas muscle
D- Opening at bladder
Ans: C

107- Which vein is tributary of portal vein?
A- Inferior epigastric artery
B- Superior rectal vein
C- Left renal vein
D- Hemiazygous vein
Ans: B

108- Tubular structure with absorptive surface area & numerous lymphoid tissues:
A- Appendix
B- Colon
C- Cecum
D- Rectum
Ans: A

109- On Radiograph Transverse cut section structure not visible at T11 but Visible at T12 behind the stomach:
A- Tail of Pancreas
B- Spleen
C- Aorta
D- IVC
Ans: A

110- Structure lying anterior to aorta:
A- Azygous Vein
B- Celiac plexus
C- IVC
D- IJV
Ans: B

111- Right gastroepiploic artery is branch of
A- Celiac
B- Gastroepiploic
C- Splenic
D- Hepatic
E- Gastrodeuodenal
Ans: E

Explanation
- Left gastric is branch of celiac truk
- Splenic is branch of celiac trunk
- Short gastric and left gastroepiploic are branches of splenic
- Cystic, right gastric , gastroduodenal , right and left hepatic are branches of hepatic artery
- Right gastroepiploic and superior pancreaticoduodenal are branches of gastroduodenal

112- Colon removed will lead to:
A- Electrolytes & Water Imbalance
B- Water Imbalance
C- Electrolyte Imbalance
D- Fatty Stool
Ans A

113- Bare area of the liver is limited by which of the following structures:
A. Ligamentum arteriosum
B. Falciform ligament
C. Coronary ligament
D. Ligamentum venosum
Ans: C

114- The endocrine portion of pancreas is derived from
A- Mesoderm
B- Endoderm
C- Ectoderm
D- Neuro ectoderm
Ans B

115- Short gastric arteries are branches of
A- Splenic
B- Celiac
C- Left gastric
D- Right gastiric
E- Gastrodeuidenal
Ans A

Explaination
- Left gastric is branch of celiac truk
- Splenic is branch of celiac trunk
- Short gastric and left gastroepiploic are branches of splenic
- Cystic, right gastric , gastroduodenal , right and left hepatic are branches of hepatic artery
- Right gastroepiploic and superior pancreaticoduodenal are branches of gastroduodenal

116- Most difficult complication to manage after Bartholin 2 srgery?
A- Subphrenicabcess
B- Paralytic ileus
C- Hemorhage
D- Dumping syndrome
Ans D

CamScanner

117- Pain caused by passage of stone going down the lower end of the left ureter , may be referred to:
A- Epigastric
B- Penis
C- Lumbar region
D- Hypogastric
Ans B

118- Left kidney is not related anteriorly to:
A- Diaphragm
B- Spleen
C- Stomach
D- Pancreas
E- Coils of jeujenum
Ans A

Explanation
RELATIONS OF RIGHT KIDNEY
anteriorly
1. Liver
2. Right colic flexure
3. Second part of deuodenun
4. Rt suprarenal gland

Posteriorly
1. Diaphragm
2. 12th rib
3. Psoas and quadratus lumborum
4. Costodiaphragmatic recess
5. Subcostal nerve
6. Transverse abdominis muscle
7. Iliohypogastric and ilioinguinal nerve

RELATIONS OF LEFT KIDNEY
anteriorly
1. Pancreas
2. Stomach
3. Spleen
4. Left suprarenal gland
5. Left colic flexure
6. Coils of jejunum

Posteriorly
1. Diaphragm
2. 11th and 12th rib
3. Psoas and quadratus lumborum
4. Costodiaphragmatic recess
5. Subcostal nerve
6. Transverse abdominis muscle

119- Lymphatic drainage of appendix:
A. Superior mesenteric lymph nodes
B. Inferior mesenteric lymph nodes
C. Iliac nodes
D. Celiac nodes
Ans: A

120- Ulcer on posterior wall of Gastric antrum will lead to acute abscess/Peritonitis in which of the following space?
A- Greater Sac
B- Lesser Sac
C- Right Sub hepatic Space
D- Right Posterior sub phrenic space
Ans: B

Explanation:
- Ulcer on posterior wall of duodenum or Gastric antrum will lead to fluid accumulation in: Lesser Sac
- Anterior duodenal perforation the contents will accumulates in: Posterior subphrenic space
- In erect posture in case of Duodenal perforation the contents will collect in: Right Iliac Fossa > Right Paracolic gutter

121- Female with arterial disease.Pulsatile mass on examination originating from
A- T11 - L1
B- T12 - L2
C- L1 - L3
D- L2 - L4
E- T8- T11
Ans: C

122- Segmentations in intestine are shown by:
A- Haustrations
B- Epiploicae appendices
C- Valvulae Conniventes
E- Peyer patches
Ans: A

123- Left Supra Renal vein drains into which of the following?
A- IVC
B- Left Renal Vein
C- Right Renal Vein
D- Common Iliac Vein
Ans: B

Explanation:
- Right Supra renal vein drains into IVC.
- Left Supra renal vein drains into left renal vein.

124- Which of the following is importance of Fusion fascia?
A- Position
B- Lymphatic Drainage
C- Vascular Structures
D- Innervation
Ans: A

Explanation:
- The avascular plane referred to as fusion fascia of Toldt is well known among laparoscopic colorectal surgeons, as it facilitates the dissection of the right mesocolon and peritoneum.

125- Bleeding into lesser omentum by damage to:
A- Left Gastric Artery
B- Gastroduodenal artery
C- Right Gastroepiploic artery
D- Celiac Trunk
Ans: A

CamScanner

126- 35 year old man with perforated gastric ulcer complains of pain in his stomach. it is observed that pain comes from peritoneal irritation by gastric contents in lesser sac , which of the following nerves contains sensory nerve fibers that conveys this sharp stabbing pain
A- Greater splanchnic nerve
B- Lower intercostal nerve
C- White rami communicates
D- Vagus nerve
Ans B

127- In appendicitis. Pain radiates to which of the following area?
A. Umbilicus
B. Pelvic region
C. Epigastric
D. Right Shoulder
Ans: A

Explanation
- Due to dermatomal supply pain of appendix is referred to umbilical area.

128- What is the relation of left renal vein anteriorly?
A- IVC
B- SMA
C- Phrenic nerve
D- Aorta
Ans: B

129- The pain from the gastric ulcers is referred to:
A- Epigastrium
B- Hypochondrium
C- Shoulder
D- Right iliac fossa
E- Umbilicus
Ans: A

130- 79 years old man suffering from ischemia of suprarenal galnds , this condition comes from rapid occulusion of direct branches of which of the following artries
A- Aorta , inferior phrenic , renal artries
B- Superior mesentric, inf mesenteric , renal artries
C- Inferior mesentric, renalartries , inferior phrenic
D- Renal , splenic and inferior mesenteric
E- Aorta , splenic and inferior phrenic
Ans A

131- Patient presented to the emergency room after multiple fractures. What will be the first intervention?
A- Fluid resuscitation
B- Take X-ray
C- Referral on the spot
D- CT Scan
Ans: A

132- A patient presented with severe fluid loss due to diarrhea that resulted in metabolic acidosis and hypokalemia. The site involved is:
A- Jejunum
B- Ileum
C- Stomach
D- Colon
Ans: D

133- About adrenal glands:
A- Left adrenal vein drains into renal vein
B- Right adrenal vein drains into renal vein
C- Left adrenal vein drains into IVC
D- Right adrenal vein drains left adrenal gland
Ans: A

134- While examining radiographs of 48 years patient , a physician is trying to distinguish the jeujenum from illeum . He has observed that jeujenum has
A- More fat in its mesentry
B- Shorter vasa recta
C- Few mesentric arterial arcades
D- Few plicae circularis
Ans: C

135- 67 year old man with history of cirrhosis was in seen in ER . In this patient with portal hypertension,Which of the following veins is most likely dilated?
A- Inferior phrenic
B- Superior phrenic
C- Suprarenal
D- Right colic
E- Inferior mesentric
Ans D

136- A patient who has undergone ileum Resection,What should b given?
A- Vitamin B12
B- Iron
C- Vitamin A
D- Vitamin E
E- Vitamin C
Ans: A

137- A diabetic patient with abdominal pain, severe vomiting and visible peristalsis and audible sound on examination, the condition is:
A- GERD
B- Achafasia
C- Crohn Disease
D- Pyloric stenosis
Ans: D

CamScanner

138- The surgeon will ligate all the arteries that send branches to stomach.Which of the following artries might be spared?
A- Left gastrocpiploicartrcy
B- Proper hepatic artery
C- Gastrodcuodenalartrcy
D- Inferior pancreaticoduodenal artery
E- Splenic artrcy
Ans D

139- Which part of the intestine does Entamoeba Histolytica reside in?
A- Duodenum
B- Jejunum
C- Transverse colon
D- Ascending colon
E- Cecum
Ans: E

140- Which of the following pair of veins forms a portocaval anastomosis?
A- Hepatic veins and IVC
B- Inferior and Superioe Epigastriv veins
C- Left and right gastric veins
D- Superior and middle rectal veins
Ans D

141- Artery present anterior to the 3rd part of the duodenum:
A- Inferior mesenteric artery
B- Superior mesenteric artery
C- Left Gastric artery
D- Celiac artery
Ans: B

142- A person got a stab wound 3cm vertically on lateral right side of linea alba.Initially, he was fine but then developed hypotension & shock. Which vessel is most likely damaged?
A- IVC
B- Superior mesenteric Artery
C- Inferior Mesenteric Artery
D- Abdominal Aorta
E- Ileal branch of superior mesenteric artery
Ans: A
Explanation:
- The surface marking of the inferior vena cava is a vertical line 2.5 cm – 3 cm to the right of the midline from the intertubercular plane to the sixth costal cartilage.

143- The most common organ injured during blunt trauma is:
A- Liver
B- Spleen
C- Pancreas
D- Kidney
Ans: A

144- The ecchymosis of flank seen in patients with acute pancreatitis is named after:
A- Trousseau
B- Cullen
C- Grey turner
D- Good Pasteur
Ans: C

145- Structure found 2 feet away from ileocecal junction,at anti-mesenteric border is most likely:
A- Omphalocele
B- Meckel's diverticulum
C- Volvulus
D- Gastroschisis
E- Intussusception
Ans: B

146- Downward displacement of enlarged spleen is prevented by?
A- Linorenal ligament
B- Phrenicocolic ligament
C- Sigmoid colon
D- Upper pole of right kidney
Ans: B

147- Free end of small intestine occupies:
A- Right upper quadrant
B- Left upper quadrant
C- Right iliac fossa
D- Lower infracolic part
Ans: A

148- Posterior relation of First part of duodenum is:
A- Aorta
B- IVC
C- Left Gastric Artery
D- Gastroduodenal artery
E- Splenic Artery
Ans: D

149- First 2 cm of duodenum is supplied by which artery ?
A- Right gastric Artery
B- Superior pancraticoduodenal Artery
C- Inferior pancraticoduodenal Artery
D- Celiac Artery
E- Hepatic Artery
Ans: A >B (BD)

150- Which structure lies anterior to pancreas?
A- CBD
B- SMA
C- Pylorus
D- Lesser Sac
E- 1st part of Duodenum
Ans: B

CamScanner

151- Ovarian artery is branch of:
A- Femoral
B- Celiac
C- Abdominal aorta
D- SMA
Ans: C

152- Renal pyramid is supplied by:
A- Interlobar artery
B- Interlobular artery
C- Inferior phrenic artery
D- Aorta
Ans: A

153- Portal vein to liver runs in which ligament?
A- Ligamentum teres
B- Hepatoduodenal
C- Phrenicocolic
D- Dorsolateral
Ans: B

154- Which structure lies anterior to inferior vena cava?
A- Portal Vein
B- Right gonadal vessel
C- Renal artery
D- Inferior phrenic artery
E- Sacral artery
Ans: B

155- Which of following structure is anterior to pancreas?
A- Right renal artery
B- Right renal vein
C- Left renal artery
D- SMA & SMV
E- IMA
Ans: D

156- Regarding Bile duct,Which of the following is true?
A- Posterior portal vein
B- Right to hepatic artery
C- Anterior to pancreas
D- Posterior to duodenum
Ans: B

157- Which of following structure is present between stomach and pancreas?
A- Lesser sac
B- Greater sac
C- Small intestine
D- Spleen
Ans: A

158- Terminal ileum resection causes
A- Increased water content in faeces
B- Decreased fat content
C- Increased bile salt absorption
D- Decreased water content in faeces
Ans: A

159- Pyloric ulcer ruptured abscess initially goes to:
A- Lesser sac
B- Right sub hepatic
C- Left sub hepatic
D- Greater sac
Ans: A

160- What lies posterior to uncinate process of pancreas?
A- Aorta
B- SMA
C- IVC
D- IMA
E- Celiac
Ans: A

Explanation:
- Anterior To uncinate process of pancreas is SMA
- Posterior To uncinate process of pancreas is Aorta
- Posterior To head of pancreas is IVC

161- A 50 year old man known to have hepatoma develops dependent edema with dilated abdominal walls veins. The most likely structure involved in this patient is:
A- Hepatic artery
B- Hepatic vein
C- Inferior vena cava
D- Portal Vein
E- Right side of the heart
Ans: C

162- Difference between right and left kidney?
A- Size
B- Weight
C- Colour
D- Relation at hilum
E- None
Ans: D

163- Vein dilated in Portal hypertension:
A- Left gastric vein
B- Inferior mesenteric
C- Inferior venal cava
D- Superior mesentric vein
Ans: A

CamScanner

164- Appendices epiploicae are present in:
A- Rectum
B- Duodenum
C- Sigmoid colon
D- Jejunum
Ans: C

165- Pancreatic insufficiency leads to deficiency of which of the following vitamins?
A- Vitamin C
B- Vitamin B3
C- Vitamin B1
D- Vitamin D
Ans: D

166- All of these supply the first 2cm of duodenum except:
A- Supraduodenal artery
B- Common hepatic artery
C- Gastro duodenal artery
D- Superior pancreaticoduodenal artery
E- Right gastroepiploic artery
Ans: D

167- Which structure is not present in lesser omentum?
A- Portal vein
B- Bile duct
C- Left gastric artery
D- Hepatic artery
Ans: C

168- After cholecystectomy,Drain placed in:
A- Left subphrenic compartment
B- Right paracolic gutter
C- Right subhepatic compartment
D- Right subphrenic compartment
E- Upper right infracolic compartment
Ans: C

Explanation
- Pancreatitis - Lesser sac
- Laprotomy – Right colic
- Cholecystectomy - Subhepatic

169- Pancreatic bed includes all except:
A- Splenic artrey
B- Left kidney
C- Left renal vein
D- Left crus of diaphragm
Ans: A

Explanation:
- Posterior to Head of pancreas-IVC
- Posterior to Uncinate process-Aorta
- Posterior to Neck of pancreas-Portal vein AndSMV
- Anterior to Uncinate process -SMA
- Superior to pancreas — Splenic Artery

170- Inferior epigastric artery is a branch of:
A- External iliac
B- Internal iliac
C- Sup epigastric
D- Internal pudendal artery
Ans: A

Explanation
- Inferior epigastric is branch of external illiac.
- The superior epigastric artery is a branch of the internal thoracic artery on each side. It forms deep to the sixth intercostal space on each side

171- Esophegectomy done.Stomach is mobilized to upper portion for anastomosis with pharynx.Which artrey is responsible for stomach supply now?
A- Right gastroepiploic artery
B- Right gastric artrey
C- Lest gastroepiploic artery
D- Left gastric artrey
E- Inferior mesentric artery
Ans A > B

172- Anterior duodenal perforation contents will move into?
A- Lesser sac
B- Right iliac fossa
C- Hepatorenal pouch
D- Right posterior sub phrenic
E- Right anterior sub phrenic
Ans: D

Explanation
- Ulcer on posterior wall of duodenum or Gastric antrum will lead to fluid accumulation in: Lesser Sac
- Anterior duodenal perforation, the contents will accumulate in: Posterior subphrenic space
- In erect posture in case of Duodenal perforation the contents will collect in: Right Iliac Fossa > Right Paracolic gutter

173- 1st branch of abdominal aorta:
A- IVC
B- Inferior phrenic
C- Celiac trunk
D- Splenic
E- Short gastric
Ans C

174- Three segments apical, anterior and posterior in which lobe of lung?
A- Right upper
B- Right middle
C- Right inferior
D- Left superior
Ans: A

CamScanner

175- **Which of following drains into superior mesenteric lymph nodes?**
A- Jejunum
B- Ileum
C- Small intestine
D- Large intestine
E- Rectum
Ans: A

176- **During endoscopy of a 32 yr old woman, ulcer found on posterior wall of stomach. It is likely to cause bleeding by causing damage to?**
A- Left gastric artery
B- Gastro duodenal artery
C- Splenic artery
D- right gastric artrey
Ans: C

Explanation
- Most Common location of Duodenal Ulcer: 1st part of Dudenum
- Perforation of posterior wall of duodenum: Bleed by Gastroduodenal artery
- Most common location of gastric ulcer: Near incisura angularis on Lessure curvature
- Perforation of lesser curvature: Bleed by Left gastric artery
- Perforation of posterior wall of stomach: Bleed by Splenic artery

177- **Tumor at Porta Hepatis.What is compressed?**
A- Common bile duct
B- Portal vein
C- Hepatic artery
D- Hepatic vein
Ans: B

178- **Contents from cecum to ileum are prevented by:**
A- Ileocecal valve
B- Ileocecal sphincter
C- Ileocecal pump
D- Pyloric sphincter
Ans: A

179- **About Small intestine, true is:**
A- 6 to 8 meters long
B- 7 to 9 meters long
C- 10 to 11 meters long
D- 8 inches
E- 6 inches
Ans A

180- **Common bile duct relation to pancreatic head:**
A- Posterior
B- Lateral
C- Medial
D- Anterior
Ans: A

181- **Supply of Foregut is primarily derived from:**
A- Celiac trunk
B- Superior mesentric
C- Inferior mesentric
D- Lumber artries
E- Median sacral
Ans: A

182- **Splenic artery course throughout:**
A- Along superior border of neck and body of pancreas posteriorly
B- Anteriorly to neck and body of pancreas
C- Anterior to head of pancreas
D- Inferior to head of pancreas
Ans: A

183- **Middle colic artery is a branch of:**
A- Superior mesentric artery
B- Inferior mesentric
C- Left colic
D- Inferior pancreaticodeuodenal artrey
E- Inferior phrenic
Ans: A

Explanation
Branches of superior mesentric
1. Jejunal
2. Illeal
3. Inferior pancreaticoduodenal
4. Right colic
5. Middle colic
6. Ileocolic

Branches of inferior mesenteric
1. Left colic
2. Sigmoid
3. Superior rectal

184- **Pancreas is anteriorly bounded from:**
A- Transverse colon
B- Bile duct
C- Portal vien
D- Splenic vien
E- Psoas muscle
Ans: A

Explanation
Anteriorly
1. Transverse colon
2. Attachment of transverse mesocolon
3. Lesser sac
4. Stomach

Posteriorly
1. Bile duct
2. Portal vien
3. IVC
4. aorta and prigin of SMA
5. left psoas muscle
6. Left suprarenal gland
7. Left kidney

CamScanner

185- Renal vein lies posterior to:
A- Aorta
B- Inferior vena cava
C- Superior mesentric vein
D- Suprior vena cava
E- None
Ans: C

Explanation
- Renal vien lies anterior to aorta and IVC
- renal vien lies posterior to pancreas and superior mesenteric vien

186- After total gastrectomy,Patient who receives no further treatment will usually develop?
A- Symptoms to decreased absorption of iron
B- Symptoms due to decreased absorptoon of Vitamin B12
C- Exaggerated fluctuations in plasma glucose levels after meals
D- Exaggerated fluctuations in blood volume
E- All of the above
Ans: B

187- Blood supply of gall bladder is:
A- Superior pancreatic duodenal artery
B- Sup mesenteric artery
C- Cystic artery
D- Right hepatic art
E- Left hepatic artery
Ans: C

188- Splenic vessels present in which ligament:
A- Phrenicocolic ligament
B- Splenorenal ligament
C- Cardinal ligament
D- Coronary ligament
E- Ligament of treitz
Ans B

189- Child with unilateral hydronephrosis. Site of obstruction:
A- Post ureteral stricture
B- PUJ
C- VUJ
D- lateral wall of pelvis
E- medial wall of pelvis
Ans: B

190- Transpyloric plane is located at
A- Lower border of L1
B- Upper border of L1
C- Lower border of T1
D- Lower border of T2
E- Upper border of L2
Ans A> E

Explanation
Located at L1 Lower border
Structure lies at level of transpyloric plane are:
1. Pylorus of stomach
2. Fundus o f gallbladder
3. First part of duodenum
4. Origin of SMA
5. Tips of 9th costal cartilages
6. Lower end of spinal cord

191- Left adrenal gland drains into:
A- Left renal vein
B- Right renal vien
C- IVC
D- aorta
E- SVC
Ans A

Explanation
- Left testicular vien also drams in left renal vien

192- Gall bladder pain is felt over neck due to:
A- Sensory supply from mid cervical dermatome
B- Sensory supply from T10 dermatome
C- Sensory supply fiom splanchnic
Ans: A

193- Nerve supply of anterior abdominal wall:
A- T7 – L1
B- T6 – T9
C- T4 – T5
D- T5 – T6
Ans; A

Explanation:
- Lower six intercostal nerves & first lumber nerve supply anterior abdominal wall

194- True about kidney and relations of different structures passing through it:
A- Left renal vien is posterior to aorta and left renal artrey
B- Perinephric fat is outside renal fascia
C- Adrenals not covered in fascia
D- Left renal vien is anterior to aorta and left renal artrey
Ans D

195- Posteriorly lesser sac has all of the following except:
A- Right kidney
B- Left suprarenal gland
C- Right suprarenal gland
D- Left kidney
Ans: A

196- Most common position of appendi:
A- Retrocecal
B- Subcecal
C- Pelvic
D- Pre ileal
E- Post ileal
Ans A

CamScanner

Explanation

- Retrocecal 64% - 11o' clock
- Pelvic 32% - 5o'clock
- Subcecal 2% - 6o' clock
- Pre ileal 1% - 2o' clock
- Post ileal 0.5% - 1 or 2o' clock

197- Direct inguinal hernia is located:

A- Medial to epigastric artery
B- Lateral to epigastric artery
C- Medial to inferior phrenic artery
D- Medial to inferior mesentric artery
E- Lateral to inferior phrenic artery
Ans A

198- Level of renal artery:

A- L1
B- L2
C- L3
D- L4
E- L5
Ans: B

Explanation

- T12 celiac trunk
- L2 – Renal Artery
- L1 – Superior mesenteric artery
- L3 – Inferior Mesenteric Artery
- L4 – Bifurcation of Descending Aorta
- L5 --Start of IVC

199- Highest potassium loss will be through:

A- Colon
B- Ileum
C- Stomach
D- Jejunum
Ans: A

200- Which one of the following structures is present at free edge of lesser omentum?

A- Bile duct, Cystic artery, Portal vein
B- Bile duct, Hepatic artery, Portal vein
C- Hepatic vein, Heaptic artery, Portal vein
D- Hepatic vein, Cystic artery, Portal vein
Ans: B

Explanation

Greater omentum contains

1. Rt and Lt gastroepiploic vessels
2. Fat

Lesser omentum contains

1. Portal vien
2. Bile duct
3. Hepatic artrey

201- Jejunum is supplied by:

A- SMA
B- IMA
C- Pancreaticoduodenal artery
D- inferior phrenic artrey
Ans: A

202- In open laparotomy,Surgeon recognizes left kidney by:

A- Dark color
B- Begins from T12 to L4
C- Anterior relation with stomach, pancrease, descending colon, spleen, jejunum
D- Anterior relation with pancrease, descending colon, spleen, jejunum
Ans: C

Explanation

RELATIONS OF RIGHT KIDNEY

anteriorly

1. Liver
2. Right colic flexure
3. Second part of deuodenun
4. Rt suprarenal gland

Posteriorly

1. Diaphragm
2. 12th rib
3. Psoas and quadratus lumborum
4. Costodiaphragmatic recess
5. Subcoastal nerve
6. Transverse abdominis muscle
7. Illiohypogastric and illioinguinal nerve

RELATIONS OF LEFT KIDNEY

anteriorly

1. Pancreas
2. Stomach
3. Spleen
4. Left suprarenal gland
5. Left cllic flexure
6. Coils of jeujenum

Posteriorly

1. Diaphragm
2. 11th and 12th rib
3. Psoas and quadratus lumborum
4. Costodiaphragmatic recess
5. Subcoastal nerve
6. Transverse abdominis muscle

203- Superior Mesenteric Artery is located at:

A- L1
B- T12
C- L3
D- L3
E- L5
Ans A

Explanation

- L2 – Renal Artery
- L1 – Superior mesenteric artery
- L3 – Inferior Mesenteric Artery
- L4 – Bifurcation of Descending Aorta
- L5 --Start of IVC

204- Ischemia from hepatic flexure to middle of transverse colon.Artery involved is:

A- Middle colic
B- Ileocolic
C- Superior mesenteric artery
D- Marginal artery
Ans: A

CamScanner

205- Supply of Midgut, Root value:
A- T8-T12
B- S2S3S4
C- T6-T9
D- Greater spanchnic nerve
Ans: A

206- Regarding sigmoid colon:
A- Continues as rectum at S5
B- Is infront of pelvic brim /Begins at pelvic brim
C- It does not have teniae coli
D- Receives innervation from S1-3
E- In sigmoid no mesocolon attached
Ans: B

207- Renal column has:
A- Minor calyx
B- Arcuate arteries
C- Interlobar arteries
D- interlobular arties
E- sigmoidal arties
Ans: C

208- Correct about Duodenum:
A- 1st, 2nd and 3rd part retroperiitonim
B- 3rd part related to right kidney
C- 25cm long
D- Contain arterial arcades
E- Ampula of vater opens in posterolateral
Ans C

209- Autonomic supply of jejunum:
A- Greater and lesser splanchnic nerves
B- Pelvic splanchnic nerves
C- Vagus nerve
D- Hypogastric nerves
Ans: A

210- Regarding Large intestine, Most Accurate is:
A- Caecum may have a diameter of 9cm
B- Transverse colon supplied by right colic
C- Appendix is rarely retro caecal
D- 20% have mesentery attached to ascending colon
E- Descending colon lies medial to left kidney Cecum
Ans A

211- True about Kidney:
A- Cuboidal epitheliurn in parietal layer of bowman capsule
B- Podocytes on visceral layer of bowman capsule
C- DCT longer than PCT
D- Glomerulus has single arteriole
Ans B

212- Right iliac fossa pain referred to umbilicus:
A- T 10
B- T 8
C- L 1
D- L2
E- L3
Ans: A

213- True statement regarding kidneys is:
A- Is wrapped in a fascial sheath alongwith its Adrenal gland
B- Hilum is at the level of L4
C- Pelvis of ureter lies between the renal artery & renal vein at the hilum.
D- Related posteriorly to ribs
Ans: A (RJ Last)

214- After successfully performing two adrenalectomies (removal of the adrenal gland), the surgical resident was disappointed to learn that he would be merely assisting at the next one. The chief of surgery told him: "I'm doing this one, since the one on the right side may be a little too difficult for you." The difficulty he envisioned stems from the fact that the right suprarenal gland is partly overlain anteriorly by the:
A- Aorta
B- Inferior vena cava
C- Left hepatic vein
D- Right crus of the diaphragm
E- Right renal artery
Ans: B

215- Surgeon doing open abdominal surgery, HO spills 1 L NS drip on patient's pelvic brim, fluid will go into?
A- Right left paracolic gutter
B- Spleen
C- Back
D- pancreas
Ans A

216- What comes from Vitelline duct:
A- Meckle diverticulum
B- Ligamentum arteriosum
C- Ligamentum venosum
D- Coronary ligament
E- Urachus
Ans A

217- Regarding Abdominal aorta, True is:
A- Commences at L1
B- Gives phrenic arteries at commencement
C- Gives supra renal arties bilaterally
D- Commences at L3
Ans: C

CamScanner

218- Nerve supply of transversus abdominis:
A- Lower intercostal nerves
B- Lower intercostal, liohypogastric, ilioinguinal
C- Lower intercostal,hypogastric,subcostal
D- 12th thoracic nerve
E- all of the above
Ans B

219- Which of the following is most appropriate about liver in late fetus?
A- Covers most of body
B- 5% of total body weight
C- Nodular liver
D- Absent
Ans: B (Langman)

220- Arterial branch of celiac trunk:
A- Right gastrodeuodenal
B- Gastrodeudenal
C- Right Epiploic
D- Proper Hepatic
Ans: D

221- True about IVC:
A- Commences at L5
B- Commences at L1
C- Commences at T1
D- Commences at L2
E- Commences at L3
Ans A

222- Liver weight
A- 1.4 kg
B- 2.4kg
C- 3.4 kg
D- 4.4 kg
Ans A
Explanation
- Liver weighs 1.4 kg
- It weighs 5% of total body weight at birth

223- Which of the following structures connects Liver to the lesser curvature of the stomach?
A- Lesser omentum
B- Peritoneal ligament
C- Hepatogastric ligament
D- Falciform ligament
Ans: C

224- SMA and IMA anastomose at which of these:
A- Celiac trunk
B- Splenic flexure
C- Marginal artery
D- Hepatic artery
E- Cystic artery
Ans: C

256- Pancreas , CBD & Gall bladder supplied by
A- Cystic artery and left hepatic artery
B- Right hepatic artery
C- Cystic artery and left gastric artery
D- SMA
Ans: A

225- Left accessary hepatic artery is branch of?
A- SMA
B- IMA
C- Inf'erior pancreatioduodenal
D- Gastroepipolic
Ans: A

226- Which vessel lies anterior to left lower portion of body of pancreas?
A- IVC
B- SMA
C- Common hepatic
D- IMA
E- Aorta
Ans: B

227- Cystic artery is the branch of:
A- Gastroduodenal artery
B- Right Gastric artery
C- Right hepatic artery
D- Left Hepatic artery
E- Left Gastric artery
Ans: C

228- A patient presented with pain in Right hypochondrium,Nasuea and jaundice. Pain is going to shoulder region and upper back.Which condition is associated?
A- Appendicitis
B- Hepatitis
C- UTI
D- Cholecystitis
E- Urethritis
Ans: D

229- Right and left lobe of liver is divided by:
A- Right hepatic vein
B- Left hepatic vein
C- Middle hepatic vein
D- Right portal vein
E- Left portal vein
Ans: C

230- Rights & Left subphrenic space is divided by?
A- ligament
B- Morrison pouch
C- Foramen of Winslow
D- Lesser omentum
Ans: A

CamScanner

231- Most dependent part in which drain is placed after cholecystectomy?
A- Right sub hepatic space
B- Right supra hepatic
C- Sub phrenic
D- Infra colic
Ans: A

232- Tributary of portal vein:
A- Inferior rectal veun
B- Hemiazygous
C- Inferior epigastic vein
D- Left renal vein
E- Lumbar veins
Ans: C

233- Maximum loss of Fluid occurs through which part of Gut?
A- Jejunum
B- Ilium
C- Colon
D- Duodenum
Ans: C(Bailey)

Explanation:
- Though Max absorption occur in Jejunum but Fluid loss will always from Colon and part of Gut remove which cause Fluid loss is ilium as when Jejunum is removed no Fluid loss will occur because ilium will Start absorbing Fluid but when ilium removed then Colon will be over loaded so ilium Removal will cause fluid loss through Colon (Bailey and Love).

234- Right Accessory hepatic artery arises from
A- Celiac
B- SMA
C- IMA
D- Short gastric
Ans: B

235- A patient has liver cirhosis. Route of hepatic biopsy is
A- T10 midaxillary line
B- T11 mid clavicular line
C- Subcostal angle
D- Substernal angle
Ans: A

236- Organ least likely to be affected in infarction:
A- Intestine
B- Pancreas
C- Kidney
D- Spleen
E- Liver
Ans: E

237- Nerve block for upper abdominal viscera:
A- Epidural
B- Celiac block
C- Lumbar sympathetic
D- Spinal
Ans: B

238- Pulsating abdominal aortic aneurysm most common site:
A- T12-L2
B- S2-4
C- S1-3
D- S4-5
Ans: A (No L1-3 option)

239- True regarding Relation of splenic artery?
A- Inferior to Pancreas
B- Runs along upper border of body of pancreas and tail
C- Parallel to spleen
D- Run at upper border of gall bladder
Ans: B

240- CA of tail of pancreas resected. Damage in which ligament occurs:
A- Gastrohepatic
B- Gastrosplenic
C- Falciform
D- Linorenal
E- Gastrodudenal
Ans: D

241- Main pancreatic duct opens into:
A- Dudenal first 2cm
B- 2nd part of medial dudenum
C- 1st part of lateral dudenum
D- 3rd part of dudenum
Ans: B

242- Structure at Medial side of Lesser omentum:
A- Hepatodudenal ligament
B- Gastriducdenal ligament
C- Falciform ligament
D- Hepatogastric ligament
Ans: D

Expanlation:
- Medial- Hepatigastric ligament
- Lateral -Hepatodudena ligament

243- Artery arising directly from the celiac truck:
A- Common hepatic artery
B- Hepatic artery proper
C- Gastroduodenal
D- Superior pancreaticoduodenal
Ans: A

CamScanner

244- Parts of CBD include:
A- Supraduodenal, Intraduodenal and Retroduodenal
B- Intraperitoneum
C- Retroduodenal and retropelvic
D- Supraduodenal and Retroduodenal
Ans: A

245- Supply of proximal bile duct is by which artery:
A- Right hepatic
B- Left hepatic
C- Cystic
D- Gastroduodenal
Ans: A

246- A patient with peptic ulcer has epigastric pain carried by which of the following nerve?
A- Intercostal nerve
B- Greater splanchnic nerve
C- Lesser splanchnic nerve
D- Least splanchnic nerve
E- Epigastrive artery
Ans: B

247- Nerve supply of intercostal muscles is
A- Dorsal scapular nerve
B- C2_C3
C- Dorsal rami of spinal nerves
D- Long thoracic nerves
Ans: B

248- Lymphatic drainage of greater curvature of stomach is:
A- Celiac node
B- Superior mesenteric node
C- Inferior mesenteric node
D- Paraaortic node
E- Splenic node
Ans: A

249- Stomach circular muscles get thicker in:
A- Fundus
B- Antrum
C- Pylorus
D- Cardiac
E- Gastroduodenal orifice
Ans: E>C

250- During Cholycystectomy,Which artery will be damaged?
A- Hepatic artery
B- Splenic artery
C- Aorta
D- Cystic artery
E- Celiac artery
Ans: D

251- Gastrosplenic ligament contains which of the following ?
A- Hepatic artery
B- Gastric vessel
C- Splenic vein
D- Splenic artery
E- Left Gastroepiploic artery
Ans: E(FA)

Explanation:
- **Splenorenal(Linorenal)** ligament has - Splenic artery ,vein and Tail of pancrease
- **Gastrosplenic** ligament has - Short gastric and left gastroepiploic vessel
- **Gastrohepatic** ligament has - Gastric vessel
- **Gastrocolic** ligament has - Gastroepiploic arteries
- **Hepatidudenal**ligament has - Portal triad: proper hepatic artery, portal vein, commonbile duct
- **Falciform** ligament has - Ligament teres hepatis and Patent paraumbilical vein

252- Surgeon accidently cut some nerve from vagal trunk.Which part of GIT will be least affected?
A- Cecum
B- Ascending colon
C- Sigmoid colon
D- Transverse colon
Ans: C

253- Carcinoma of head of pancreas will compress which of the following structure?
A- Hepatic duct
B- CBD
C- IVC
D- Hepatic vein
E- Portal vein
Ans: B

254- Commonest site of duodenal ulcer perforation is:
A- 1st part
B- At the junction of first and second part
C- 2nd part
D- Duodenal cap
Ans: A

255- A surgeon is performing pancreaticoduodenectomy, to prevent maximum blood loss which artery should be ligated anterior to 2nd part of duodenum?
A- Splenic artery
B- Superior pancreaticoduodenal artery
C- Inferior pancreaticoduodenal artery
D- Left gastroepiploic
E- Inferior mesenteric artery
Ans: C

CamScanner

256- A 58-year-old man is admitted to a hospital with severe abdominal pain, nausea and vomiting resulting in dehydration. Emergency CT scan reveals a tumour located between the celiac trunk and the superior mesenteric artery. Which of the following structures is likely compressed by this tumour?

A- Fundus of the stomach
B- Neck of the pancreas
C- Transverse colon
D- Hepatopancreatic ampulla
E- Duodenojejunal junction
Ans: B

257- A day following hysterectomy, a patient complains of severe pain in the right upper lumbar region of the back. Which of the following structures was most likely damaged during the surgery?

A- Inferior mesenteric artery
B- Internal iliac artery
C- Uterine artery
D- Pudendal nerve
E- Ureter
Ans: E

Explanation:
During hysterectomy ureter damage at
- **A>B>C**
- A-cardinal ligament (uterine vessel)
- B-Behind broad ligament
- C-At pelvic brim (ovarian artery)
- **Ureter damage at pelvic brim – While crossing common iliac vessel**
- **While removing ovary damage to – Internal iliac artery**

258- During fight, A person hit other with knife and causes Stab at stomach bed.Which artery will be damaged?

A- SMA
B- Hepatic artery
C- IMA
D- Splenic artery
Ans: D

259- Teenager playing with Gun suddeuly injured the other at right side just lateral to rectus abdominis at the level of 9th intercostal cartilage tip. Structure injured most likely is:

A- Fundus of gall bladder
B- Antrum of stomach
C- Right adrenal gland
D- Right ureter
E- Head of pancreas
Ans: A

260- Fenestrated capillaries mostly found in:

A- Skin
B- Spleen
C- Stomach
D- Kidney
E- Brain
Ans: D

Explanation:
- Fenestrated capillaries occur whereveractive filtration or absorption occurse.g. small intestine, kidney, Incillaryprocess of eye, in choroid plexus.

261- Sympathetic supply of jejunum is from?

A- L1, L2 nerves
B- S2, S3, S4 nerve
C- Greater and lesser splanchnic nerves
D- Pelvic splanchnic nerves
E- Vagus nerve
Ans: C

262- Surgeon identifies rectum in lower abdominal surgery by:

A- Appendices epiploecae
B- Located posterior to prostate
C- Forms medial wall of ischiorectal fossa
D- Presence of complete muscular coat
Ans: D

263- Abdominal muscles' nerve supply is which of the following?

A- T7-L1
B- T5-L1
C- T6-L2
D- T4-8
E- T10-L3
Ans: A

264- SMA switched to IMA at which of the following place?

A- Descending colon
B- Transverse colon
C- Sigmoid colon
D- Dudenum
E- Ilium
Ans: B

265- Due to IMA blockage,Which part of Intestine undergoes ischemia ?

A- Transverse colon and sigmoid colon
B- Descending colon and sigmoid colon
C- Descending colon and transverse colon
D- Dudenum and Ascending colon
Ans: B

266- In damage of Splenic artery,Which part of stomach will be affected?

A- Posterior
B- Lateral
C- Incisura
D- Gastric Fundus
Ans: D

CamScanner

267- Posterior to the third part of duodenum is:
A- Right kidney
B- Inferior vena cava
C- Liver
D- Head of pancreas
E- Lesser Sac
Ans: B

Explanation:
Anterior to 3rd part of duodenum
- Superior mesenteric vessels
- Small bowel mesentery

Posterior to 3rd part of duodenum
- Right Ureter
- Right Psoas muscle
- IVC
- Aorta

Superiorly
- Head of Pancreas

Inferiorly
- Coils of jejunum

268- Houlton,s valve located at
A- Sigmoid colon
B- Rectum colon
C- Ascending colon
D- Decendeing colon
Ans: A

269- Which of the following is formed from ventral and dorsal primordium?
A- Liver
B- Spleen
C- Pancreas
D- Gall bladder
A- Stomach
Ans: C

270- Gastroduodenal artery is branch of:
A- SMA
B- IMA
C- Splenic artery
D- Hepatic artery
E- Gastric artery
Ans: D

271- Accessory Pancreatic duct if present drains:
A- Lower Head of pancreas
B- Upper head of pancreas
C- Tail
D- Uncinate
E- Inferior
Ans: B(Snell)

272- Most common site of duodenal ulcer
A- Ampulla
B- Duodenal cap
C- Mid part
D- Mesentery
Ans: B

Explanation:
- Dudenal cap or ampulla is first part and common site for ulcer

273- Total abdominal hysterectomy done of woman and 1 L normal saline is used to wash the wound.It touches the pelvic brim and goes into:
A- Left Paracolic
B- Right paracolic
C- Subphrenic
D- Pelvis
Ans: C

274- Impotant structure in preventing reflux of cecal material into ileum:
A- Iliocecal valve
B- Perastalisis
C- Mucosal fold
D- Rectal fold
Ans: A

275- Left colic flexure related to:
A- Stomach
B- Kidney
C- Spleen
D- Liver
E- Intestine
Ans: C

276- Pbrenicolic ligament damaged.It supports which structure?
A- Liver
B- Kidney
C- Spleen
D- Gall bladder
E- Duodenum
Ans: C

277- Renal part which runs from renal cortex to medulla between renal columns is:
A- Renal Cortex
B- Renal pyramid
C- Bowman capsule
D- DCT
Ans: B

278- Artery running at the back or floor of stomach that is likely to cause bleeding is:
A- Gastroduodenal artery
B- Short gastric artery
C- Left gastric artery
D- Splenic artery
Ans: D

279- A patient having abdominal pain.Upon investigation,Distal 3rd of duodenum necrosed.Which artery is involved?
A- Superior pancreaticoduodenal
B- Celiac
C- Aorta
D- Inferior pancreaticoduodenal
Ans: D

CamScanner

280- While taking graft of rectus abdominis there is damage of suprapubic area there is risk of damage to which artery?
A- Deep Circumflex artery
B- Superficial Circumflex artery
C- Inferior epigastric
D- Internal iliac
E- Iliohypogastric
Ans: C

281- Lesser omentum contains
A- Hepatic duct
B- Splenic Artery and CBD
C- Hepatic artery proper, CBD and portal vein
D- Bile duct and Gastric artery
Ans: C

282- Stab wound on right side below and lateral to umbilicus will cause injury to?
A- Peritoneum
B- Hepatic vein
C- Hepatic artery
D- IVC
E- Renal artery
Ans: D

283- IVC forms at level of which vertebral body?
A- T10
B- L5
C- T8
D- L6
E- T12
Ans: B

284- During suprapubic catheterization,a transverse incision is given. Which of the following is most likely to he damaged?
A- Superior epigastric artery
B- Deep circumflex artery
C- Inferior epigastric artery
D- Femoral artery
E- Cremasteric artery
Ans: C

285- A man had penetrating injury in Right lumbar region. What is the sequence of layers to be pierced?
A- Skm, , Scarpa's fascia, Camper fascia external oblique aponeurosis, internal oblique aponeurosis
B- Skin, Camper's fascia, Scarpa's fascia, external oblique aponeurosis, internal oblique aponeurosis, transversus abdominis aponeurosis
C- Skin, Camper's fascia, external oblique aponeurosis, internal oblique aponeurosis
D- Skin, Scarpa's fascia, Camper's fascia, external oblique aponeurosis, internal oblique aponeurosis, transversus abdominis aponeurosis
E- Skin, Scarpa's fascia, external oblique aponeurosis, internal oblique aponeurosis
Ans

286- Adrenal medulla is supplied by:
A- Least splanchinic nerve
B- Lesser splanchinic nerve
C- Subcostal nerves
D- Greater splanchnic nerve
E- Intercosal nerve
Ans: D

287- Patient presented with bleeding from the posterior duodenal ulcer rupture. Which of the following artery is responsible for this?
A- Superior pancreaticoduodenal
B- SMA
C- Gastroduodenal artery
D- Celiac artery
E- Splenic
Ans: C

Explanation:
- Most common location of duodenalulcer 1st part of duodenum.
- Perforation of posterior wall ofduodenum bleeds by gastroduodenal artery.
- Most common location of gastric ulcernear incisura angularis on lesser curvature
- Perforation of lesser curvature bleedsby left gastric artery.
- Perforation of posterior wall ofstomach bleeds by splenic artery.

288- Liver is held in the upper part of a abdominal cavity by
A- Abdominal muscle tone
B- Attachment of hepatic veins to inferior vena cava
C- Attachment to diaphragm
D- Intra abdominal pressure
E- Peritoneal liganients
Ans: B

289- Lesser omentum:
A- Attaches to duodenum
B- Forms falciform ligament
C- Related to right renal gland
D- Left renal gland and left kidney
Ans: A

290- Anterior to left suprarenal gland is:
A- Liver
B- Lesser sac
C- Aorta
D- IVC
E- SVC
Ans: B

CamScanner

Explanation:
Left Supra renal gland
- Anterior: Pancreas, lesser sac and stomach
- Posterior: Diaphragm

Right Supra renal gland
- Anterior: Right lobe of liver and IVC
- Posterior: Diaphragm

291- Patient was diagnosed with liver disease and ascities and ascitic tap needs to be done. Needle passed in lower abdomen. Which artery should be avoided to cut?
A- Superior epigastric artery
B- Inferior epigastric artery
C- Cremasteric Artery
D- Celiac Trunk
E- Aorta
Ans: B

292- Child presents with pain in lumbar region. Stone at pelviureteric junction.Pain arising from which segment?
A- T11
B- L1
C- L2
D- L5
E- T10
Ans: C

293- Firearm injury to RIF which escaped through left lumbar region and affects root of mesentery.Artery affected will be:
A- Inferior phrenic
B- Superior phrenic
C- SMA
D- Celiac
Ans: C

294- A patient came with epigastric pain & heartburn.On endoscopy,Perforation of Ist part of duodenum was seen.Which artery is eroded in duodenal ulcer?
A- Gastroepiploic artery
B- Gastroduodenal artery
C- Right gastric artery
D- Left gastric artery
E- Splenic artery
Ans: B

Explanation:
- Most common location of duodenal ulcer 1st part of duodenum.
- Perforation of posterior wall ofduodenum bleeds hy gastroduodenalartery.
- Most common location of gastric ulcer near incisura angularis on lesser curvature.
- Perforation of lesser curvature bleedsby left gastric artery.
- Perforation of posterior wall of stomach bleeds by splenic artery

295- Structure damaged during hysterectomy during the ligation of uterine artery at the level of ischial spine is:
A- Ovarian artery
B- Urethra
C- Internal iliac artery
D- Ureter
Ans: D

296- Structure passeing anterior to third part of duodenum is:
A- Aorta
B- SMA
C- IMA
D- Cystic artery
E- Hepatic artery
Ans: B

297- A pathalogist wants to pass dye to the liver.It will reach through?
A- Ligamentum teres
B- Ligamentum arteriosum
C- Hepatoduodenal ligament
D- Ligamentim hepaticum
Ans: A

298- Blood supply of upper 2cm of duodenum by:
A- Inferior pancreaticoduodenal artey
B- Superior pancreaticoduodenal artey
C- Right gastric artery
D- Hepatic artery
E- Splenic artery
Ans: C(BD Churrasia)

Explanation:
Ist part supplied byArterial supply
1. Right Gastric artery
2. Supraduodenal artery of Wikie
3. Retroduodenal Branches of Gastroduodenal artery
4. Branches of Right Gastroepiploic artery

299- Nerve supply to adrenal medulla:
A- Postganglionic sympathetic
B- Parasympathetic
C- Preganglionic greater thoracic splanchnic
D- Lower thoracic
Ans: C

300- Abdominal angina is due to which artery block?
A- Celiac
B- SMA
C- IMA
D- Splenic
E- Gastric
Ans: B

CamScanner

301- The ascent of horse shoe shaped kidney is prevented by:
A- External iliac artery
B- Internal iliac artery
C- Superior mesenteric artery
D- Inferior vena cava
E- Inferior mesenteric artery
Ans: E

302- First branch of abdominal aorta:
A- Superior mesenteric
B- Celiac trunk
C- Suprarenal
D- Inferior mesenteric
Ans: B

303- Anterior to distal CBD is
A- Lesser sac
B- Greater sac
C- Omentum
D- Pancreas
Ans: D

304- Anteverted and anteflexed position of uterus is due to:
A- Transverse ligament
B- Uterosacral ligament
C- Round ligament
D- Cardinal ligament
Ans: C

305- On barium swallow feathery appearance in left abdomen is due to:
A- Jejunum
B- Ileum
C- Stomach
D- Liver
Ans: A

306- Inferior boundary of lumbar triangle is:
A- Posterior boundary by latissimus dorsi.
B- Iliac crest.
C- Posterior border of qudratouslamborum.
D- Posterior border of external obliquemuscle
E- Serratus anterior
Ans: B

Explanation:
Lumbar triangle (of petit)
- Anterior boundary – Post border ofexternal oblique
- Floor – Internal oblique
- Posterior boundary – Anterior borderof lattismus dorsi
- Iliac crest

307- Superior rectal artery is branch of:
A- SMA
B- Celiac artery
C- Inferior mesenteric
D- Internal pudendal
E- Internal iliac
Ans: C

Explanation:
- Superior rectal branch of – Inferiormesenteric artery
- Middle rectal branch of – Internaliliacartery which is branch of commoniliacartery
- Inferior rectal artery branch of – Internalpudendal artery

308- Aponeurotic fibers of internal oblique form which structure?
A- Transverse facialis
B- Internal oblique
C- External oblique
D- Conjoint tendon
E- Internal fascia
Ans: D

309- Main support of liver:
A- Falciform ligament
B- Peritoneal ligament
C- Diaphragm
D- Attachment of hepatic vessels with IVC
Ans: D>A

310- A surgeon during splenectomy ligated artery at hilum.If not ligated, then it could cause damage to:
A- Body of pancreas
B- Fundus of stomach supply
C- Head of pancreas
D- Alpha cells
Ans: B

311- Gastroduodenal artery found behind which of these:
A- Pancreas
B- Spleen
C- First part of dudenum
D- 4th part of dudenum
Ans: C

312- Liver carcinoma of inferior surface. Blood supply to this area is from:
A- SMA
B- Abdomina aorta
C- IVC
D- IMA
Ans: B

CamScanner

313- **Which vessel is involved in portal hypertension?**
A- Portal vein
B- SMA
C- IMA
D- IVC
Ans: A

314- **Short gastric artery is branch of which of the following?**
A- Celiac artery
B- Splenic artery
C- Hepatic artery
D- SMA
E- IMA
Ans: B

Explanation:
- **Left gastric from** – Celiac
- **Right gastric from** – Hepatic
- **Short gastric from** – Splenic
- **Left gastroepiploic from** – Splenic
- **Right gastroepiploic from** – Gastroduodenal

315- **Ureter crosses at:**
A- Bifurcation of common iliac
B- Anterior to psoas
C- Posterior to psoas
D- Anterior to mesentry
Ans: A

316- **Ligament of trietz attaches duodenum to which of the following:**
A- Inferior vena cava
B- Deudenojejunal flexure to Diaphragm
C- Jejunal flexure to IVC
D- Deudenum to abdominal wall
Ans: B

317- **3rd part of CBD in relation to pancreas?**
A- Lies posteriorly
B- Lies anteriorly
C- Embedded in pancreas
D- Lies medial to the head of pancreas
Ans: C>A

318- **A middle aged women presented in OPD with complaint of pain in the epigastric region posterior thoracic wall and right shoulder after a fatty meal.The pain is originating from:**
A- Appendix
B- Gall bladder
C- Kidney and ureter
D- Diaphragm
E- Spleen
Ans: B

319- **Preganglionic supply of adrenal gland is by:**
A- Greater thoracic splanchnic nerve
B- Lesser thoracic splanchnic nerve
C- Least thoracic splanchnic nerve
D- Posterior vagal trunk
E- Anterior vagal trunk
Ans: A

320- **Profuse bleeding after Cholycystectomy due to damage to which artery?**
A- Hepatic artery
B- Splenic artery
C- Aorta
D- Cystic artery
E- Celiac artery
Ans: D

321- **Which blood vessel primarily supplies the proximal portion of the common bile duct (CBD)?**
A- Superior mesenteric artery
B- Splenic artery
C- Hepatic artery
D- Gastroduodenal artery
Ans: C

322- **At which vertebral level does the renal artery typically enters the hilum of the kidney?**
A- T10
B- L2
C- L4
D- L3
Ans: B

323- **Mesentery enclosing fats are called?**
A- Haustrations
B- Villi
C- Appendices epiploicae
D- Payer's patches
Ans: C

324- **Rights & left sub phrenic space is divided by?**
A- Falciform ligament
B- Morrison pouch
C- Foramen of Winslow
D- Lesser omentum
Ans: A

325- **Patient underwent tubal ligation.Post operative,Her abdomen was reopened due to slippage of ligature and hemorrhage.Bleeding most probably from which artery?**
A- Ovarian Artery
B- Internal iliac Artery
C- Uterine artery
D- Ovarian vein
Ans: C

CamScanner

326- Blood supply to uterus is from:
A- Uterine artery
B- Ovarian artery
C- Ovarian +Uterine artery
D- Vesicle artery
Ans: C

327- Which branch of renal artery supplies network around glomerulus:
A- Interlobular
B- Interlobar
C- Segmental
D- Arcuate
Ans: A

Explanation:
- Renal columns contain — Interlobar Artery
- Capsule Contain – Interlobular Artery
- Glomerulus Contain – Interlobular Artery
- Hilum Contain – Segmental artery

328- Descent of ovary out of abdomen is prevented by:
A- Inguinal ligament
B- Rectus muscle
C- Narrow inguinal canal
D- Uterus
E- Bladder
Ans: D

Explanation:
- Ovary remain within pelvis due to --Broad ligament
- Prevent ovaries from falling down --Broad ligament
- Normal descent of ovary in early life which support ovary from further descent and remains within pelvis --Uterus

329- Middle esopbagous supplied by which of the following?
A- Inferior Thyroid artery
B- Descending thoracic aorta
C- Left Gastric artery
D- Celiac artery
E- Right gastric artery
Ans: B

Explanation:
- Upperesophagous – Inferior thyroid artery
- Middle esophagous – Descending thoracic aorta
- Lower esophagous – Left gastric artery

330- Esophagus passes through?
A- Aorta
B- Left crus of Diaphragm
C- Right crus of Diaphragm
D- Vagal opening
Ans: B

331- Ceoliac trunk branch is:
A- Common hepatic artery
B- Splenic artery
C- Marginal artery
D- Aorta
Ans: A

332- Infection in kidney pus upto gerota fascia, with fascia intact it can spread to:
A- Opposite kidney
B- Inferior to pelvis
C- Superior to pelvis
D- Any where
Ans: B

333- Small fat filled outpouches on external surface of colon are called:
A- Epiploic appendages
B- Haustrations
C- Teniae coliae
D- Diverticulum
Ans: A

334- After strangulated femoral hernia repair, Which one is at risk of damage:
A- Femoral vein
B- Femoral artery
C- Inferior epigastric artey
D- Sephanous vein
Ans: A

335- Transition from skeletal to smooth muscle in git occurs at:
A- Upper esophagus
B- Middle esophagus
C- Lower esophagus
D- Gastroesophageal junction
Ans: B

336- A bullet hit a person from superior iliac region and goes out at 4th lumbar region, there was massive blood on laparotomy. Which major vessel is hit at the root of mesentey?
A- Superior mesenteric vessel
B- Inferior mesenteric vessel
C- IVC
D- Aorta
Ans: C

337- Ureter damaged while ligating ovarian artery at:
A- Pelvic brim
B- 2cm from ischial spine
C- Behind Broad ligament
D- When crosses common iliac artery
E- At bifurcation of iliac vessels
Ans: A

CamScanner

338- Posterior wall gastric ulcer pain carried by:
A- Lesser Splanchnic Nerve
B- Greater Splanchnic Nerve
C- Least Splanchnic Nerve
D- Intercostal Nerve
Ans: B

339- Gluteal cramp due to Atherosclerosis of:
A- Internal iliac artery
B- External iliac artery
C- Aorta
D- Femoral nerve
E- Obturator nerve
Ans: A

340- Patient has history of fecaluria, which structure separates the bladder and rectum:
A- Dorsolateral ligament
B- Denonvilliar's Fascia
C- Perineal fascia
D- Perineal membrane
Ans: B

341- A surgeon was repairing tip of femoral hernia sac, which vessel is at risk of injury most commonly?
A- Medial circumflex femoral
B- Superficial epigastric artery
C- External iliac
D- Internal iliac
Ans: B

342- Splenic vein relation/ course is:
A- Inferior to pancreas
B- Superior to body and tail of pancreas
C- Lies in Head of pancreas
D- Lies in uncicate process
Ans: B

343- Lymph nodes related to descending and sigmoid colon?
A- Inferior mesenteric Lymph nodes
B- Superior mesenteric Lymph nodes
C- Celiac lymph nodes
D- Aortic lymph nodes
Ans: A

344- Relation of terminal CBD with head of pancreas:
A- Anterior
B- Superior
C- Lateral
D- Medial
E- Posterior
Ans: E

345- A surgeon while performing splenectomy,there was massive neerosis on fundal region of stomach. Which of the following vessels is injured during this procedure which supply the fundus of the stomach:
A- Short gastric arteries
B- Gastroduodenal artery
C- Hepatic artery
D- Cystic artery
Ans: A

346- In hematoemesis vessel running in ligament is not ligated . Which ligament it is:
A- Splenorenal
B- Hepatocolic
C- Hepatogastric
D- Splenogastic
Ans: C

347- Dudenum is in retroperitoneum:
A- All except 3rd part
B- All except first part
C- 3rd part only
D- Whole Dudenum
Ans: B

348- Surgeon nick hepatodudenal ligament during surgery from right side which structure Should be preserved?
A- Portal vein
B- CBD
C- Cystic artery
D- Gastric artery
E- Hepatic artery
Ans: B

349- Patient presents with pain in lumbarregion. Stone at pelviureteric junction.Pain arising from which segment?
A- T11
B- L1
C- T12
D- L5
E- S1
Ans: C

350- Related to sqaumaocolumnr junction true is:
A- Z line
B- GE junction
C- B ring
D- A ring
Ans: B

CamScanner

351- Cremasteric spermatic fascia is derived from:
A- External oblique
B- Internal obliquc
C- Fascia transversalis
D- Transversus abdominus
E- Superficial fascia
Ans: B

352- A newly married female came with Right iliac fossa pain Her TLC 12000 she has fever and vomiting Her LMP 3 weeks back likely diagnose
A- Appendicitis
B- Salpingitis
C- Uterine Fibroid
D- Ectopic
Ans: A

353- While doing surgery splenic vessel need to be ligated they are present inwhich ligament?
A- Gastro splenic
B- Hepatosplenic
C- Linorenal
D- Splenigastric
Ans: C

354- Structure present at free edge of Lesser omentum include
A- Hepatic duct
B- Splenic Artery and CBD
C- Hepatic artery proper, CBD and portal vein
D- Bile duct and Gastric artery
Ans: C

355- Artery accompanying lymph nodes along descending and sigmoid colon is
A- Left colic
B- IMA
C- SMA
D- Aorta
E- Celiac
Ans: B

356- An old man with perforated gastric ulcer complains of pain in his stomach, it is observed that pain comes from peritoneal irritation by gastric contents in lesser sac , which of the following nerves contains sensory nerve fibers that conveys this sharp stabbing pain
A- Greater splanchnic nerve
B- Lower intercostal nerve
C- White rami communicates
D- Vagus nerve
Ans: B

Explanation:
- Gastric pain - Greater splanchnic nerves
- Peritoneal irritation leading to gastric pain . lower intercostal nerves
- (only copy explanation as it is repeated)

357- While examining radiographs of 48 years patient, a physician is trying to distinguish the jeujenum from illeum. He has observed that jeujenum has
A- More fat in its mesentry
B- Shorter vasa recta
C- Few mesenteric arterial arcades
D- Few plicae circularis
Ans: C

358- During Surgery of Pheochromocytoma, Right Supra Renal vein is ligated to prevent surge of Catecholamines. Right Supra renal drains into which of the following?
A- IVC
B- Left Renal Vein
C- Right Renal Vein
D- Common Iliac Vein
Ans: A

Explanation:
- Right renal, Supra renal. Gonadal and left renal all drain into – IVC
- Left Suprarenal and Gonadal vein drain into – Left renal vein

359- Renal capsule is supplied by:
A- Interlobular artery
B- Arcuate artery
C- Intra lobular artery
D- Segmental artery
E- Directly from Kidney
Ans: A

Explanation:
- Renal columns contain — Interlobar Artery
- Capsule Contain – Interlobular Artery
- Glomerulus Contain – Interlobular Artery
- Hilum Contain – Segmental Artery

360- Lateral boundary of deep inguinal ring is made of:
A- Transversus abdominus
B- Fascia transversalis and conjoined tendon
C- Conjoined tendon
D- Fascia transversalis
Ans: D

361- A surgery is done.There is damage to suprapubic area leading to compromised blood supply to Internal thoracic artery.Rectus abdominus will still be supplied by:
A- Deep circumflex artery
B- Superficial Epigastric
C- Inferior epigastric artery
D- Musculophrenic artery
E- Deep Epigastric artery
Ans: C

CamScanner

362- Opening of Left gastric vein into
A- Portal vein
B- SM vein
C- Splenic vein
D- Hepatic vein
E- Renal vein
Ans: A

363- During hiatal hernia repair there is damage to nerve affecting intestine which part will be spared
A- Jejunum
B- Ilium
C- Ascending colon
D- Sigmoid colon
Ans: D

364- A person who was chronic alcoholic had hematoemesis, the damaged organ in this patient had neoplasm which extend to inferior surface blood supply to this area is from
A- SMA
B- Abdomina aorta
C- IVC
D- Celiac artery
E- Thoracic aorta
Ans: B

365- Perinephric fat is an extension of?
A- Renal fascia
B- Peritoneum
C- Fusion fascia
D- Transversalis fascia
E- Cremasteric fascia
Ans: A

366- Coelic block given to patient which part of intestine not affected
A- Dudenum
B- Jejunum
C- Sigmoid colon
D- ilium
Ans: C

367- Ulcer leak in posterior stomach wall with collection in lesser sac causing irritation will carry sensation by
A- Parasympathetic
B- Sympathetic
C- Greater splanchnic
D- Pelvic Splanchnic
Ans: C

368- Injury to medial most structure in hepatodeudenal ligament is
A- Hepatic artery
B- Portal vein
C- Bile duct
D- Hepatic vein
Ans: C

369- 38 years old lady presented with diarrhea water and electrolyte imbalance and weakness on further investigations she is dehydrated and part of her gut was respected 3 months back she doesn't remember which part the structure most likely resected is?
A- Large intestine
B- Ileum
C- Colon
D- Jejumum
E- Sigmoid
Ans: B (Bailey)

Explanation:
Though max absorption occur in jejunum but fluid loss will always from colon and part of gut remove which cause fluid loss is ilium as when jejunum is removed no fluid loss will occur because ilium will start absorbing fluid but when ilium removed then colon will be over loaded so ilium removal will cause fluid loss through colon (bailey and love).

370- During thoracic surgery, internal thoracic artery is ligated- To perfuse rectus abdominis, Flow increases to which artery:
A- Inferior epigastric
B- Superficial epigastric
C- External iliac
D- Superior mesenteric
E- Inferior mesenteric
Ans: A

371- Teenager playing with Gun suddenly injured the at right side just lateral to rectus sheath at the level of 9th intercostal cartilage tip. Structure injured most likely is:
A- Fundus of gall bladder
B- Adrenal Gland
C- 2nd Part of Duodenum
D- Right Kidney
E- Head of pancreas
Ans: A

Explanation:
The transpyloric plane, also known as Addison's plane, is an imaginary axial plane located midway between the jugular notch and superior border of pubic symphysis, at approximately the level of L1 vertebral body. It an important landmark as many key structures are visualized at this level, although natrurally there is anatomical variation. The structures traditionally thought of as lying in the transpyloric plane include:
- Pylorus of the stomach
- D1 part of the duodenum
- Duodeno-jejunal flexure
- Root of the transverse mesocolon

CamScanner

- Hepatic flexure of the colon
- Splenic flexure of the colon
- Fundus of the gallbladder
- Neck of the pancreas
- Hila of the kidneys
- Hilum of the spleen
- 9th costal cartilage
- Termination of spinal cord and superior portion of conus medullaris
- Origin of SMA
- Splenic vein joins superior mesenteric vein to form portal vein
- Cisterna chyli

372- During Cystoscopy, there's artery damaged which Is?

A- Superior mesenteric
B- Left gastric
C- Short gastric
D- Inferior mesenteric
E- Inferior epigastric
Ans: E

373- Which artery is involved in the anastomosis between the Superior Mesenteric Artery (SMA) and the Inferior Mesenteric Artery (IMA)?

A- Segmental artery
B- Marginal artery
C- Celiac trunk
D- Common iliac artery
Ans: B

374- Pain in the epigastric region is primarily carried by which nerve or nerve system?

A- Sympathetic splanchnic nerves
B- Parasympathetic splanchnic nerves
C- Abdominal visceral nerves
D- Phrenic nerve
E- Intercostal nerves
Ans: A

375- A patient undergoing ascetic tap for ascites, fluid at costodiaphragmatic recess where to pass needle?

A- T10 midaxillary
B- T10 mid clavicle
C- T9 mid clavicle
D- T8 mid clavicle
Ans: A

376- A 50 year old man known to have hepatoma develops dependent edema with dilated abdominal walls veins. The most likely structure involved in this patient is:

A- IVC
B- Hepatic artery
C- Portal vein
D- Bile duct
E- Renal vein
Ans: A

Explanation:

- Hepatoma will compress early Portal vein.
- In IVC blockage there will be dependent edema and dilated abdominal veins.
- In Portal vein compression there will be Ascities

377- Which vessel, when affected by a hematoma, is most likely to cause dilation of the abdominal veins?

A- Aorta
B- Internal jugular vein
C- Femoral artery
D- Inferior vena cava (IVC)
E- Renal artery
Ans: D

378- A patient came with acute intestinal obstruction for investigation xray is advised on x ray what will be the feature jejunum seen

A- Valvulae conniventes
B- Plicae circulares
C- Villi
D- Crypts of Lieberkühn
E- Ileocecal valve
Ans: A

379- Inferior mesenteric artery is ligated which part of large intestine is affected:

A- Ascending and transverse
B- Transverse only
C- Transverse and descending colon
D- Descending and sigmoid colon
E- Ascending and descending colon
Ans: D

380- Pampiniform Plexus Present in:

B- Spermatic cord
C- Inguinal Canal
D- Mesovarium
E- Deep Inguinal Ring
Ans: A

381- A patient came with epigastric pain heartburn on endoscopy perforation of 1st part of duodenum was seen which artery is erroded in duedenal ulcer?

A- Gastroepiploic artery
B- Gastroduodenal artery
C- Right gastric artery
D- Left gastric artery
E- Splenic artery
Ans: B

CamScanner

382- Proximal part of CBD is supplied by
A- Inf mesenteric artery
B- Sup mesenteric artery
C- Cystic artery
D- Right hepatic artery
E- Left hepatic artery
Ans: C

383- Structure present between celiac trunk and superior mesenteric artery is?
A- Pancreas
B- Stomach
C- Spleen
D- Duodenum
E- Liver
Ans: A

384- Superior pancreaticoduodenal artery is a branch of:
A- Short gastric artery
B- Gastroduodenal artery
C- Splenic artery
D- Left Gastric artery
Ans: B

385- A patient had bleeding due to a duodenal ulcer. While operating, the surgeon accidentally hit a vessel behind the posterior boundary of epiploic foramen, causing pooling of blood. Which vessel was damaged?
A- Splenic artery
B- Aorta
C- Splenic Vein
D- Portal vein
Ans: D(No option of IVC)

386- An elderly patient presents with Fever, Malaise & lower abdominal pain. O/E, there is tenderness in the left iliac fossa, and a history of loose stools with blood. What is the most appropriate investigation to perform?
A- X ray
B- Colonoscopy
C- Sigmoidoscopy
D- CT Abdomen
E- Barium enema
Ans: C

387- A patient Presented to ER with Pain in Right Iliac Fossa. A plan of appendectomy was being considered. O/E, Palpation of Left iliac fossa Elicited severe pain in Right Iliac fossa. Which sign is being mentioned in this scenario?
A- Rovsing sign
B- Obturator Sign
C- Psoas sign
D- Rebound Tenderness
Ans: A

Explanation:
- Rovsing's Sign: Pain in the right lower quadrant (RLQ) when palpating the left lower quadrant (LLQ), indicating appendicitis.
- Obturator Sign: Pain in the RLQ when the hip is flexed and internall rotated. suggesting irritation of the obturator internus muscle. often due to appendicitis.
- Psoas Sign: RLQ pain when the patient actively flexes their hip against resistance or when the hip is passively extended, indicating irritation of the psoas muscle, commonly seen in retrocecal appendicitis.
- Rebound Tenderness: Increased pain upon the sudden release of pressure during palpation, often indicating **peritoneal irritation, such as in appendicitis or peritonitis**

388- Patient Febrile with suspicion of Acute Appendicitis. Exploration reveals a hard 2.5cm yellowish colored mass on the base of Appendix. What to do next?
A- Remove the Appendix
B- Right hemicolectomy
C- Limited right hemicolectomy
D- Take tissue for Biopsy,Perform Wash out & Close the Abdomen
E- Right Extensive Colectomy
Ans: B

389- 3rd Part of CBD supplied by:
A- Cystic artery and left hepatic artery
B- Right hepatic artery
C- Cystic artery and left gastric artery
D- SMA
Ans: A

390- Hepatoduodenal ligament contains which of the following structure?
A- Celiac Trunk
B- IVC
C- Aorta
D- Hepatic Artery
Ans: D

391- A hernia located medial to the pubic tubercle and passing through the deep inguinal ring is most likely:
A- Indirect hernia
B- Direct hernia
C- Femoral hernia
D- Spigelian hernia
Ans: A

CamScanner

392- Acute kindly infection lymph drainage:
A- Inferior mesenteric lymph nodes
B- Inferior Phrenic lymph nodes
C- Lumbar lymph nodes
D- Internal Iliac lymph nodes
Ans: C

393- Demarcation of Upper GIT from Lower GIT is shown by:
A- Ligament of treitz
B- Superior mesenteric artery
C- Falciform ligament
D- Tail of pancreas
Ans: A

394- Tail of pancreas is present in which of the following ligament
A- Hepatoduodenal ligamnet
B- Gastrohepatic ligament
C- GastroColic ligament
D- Gastrosplenic ligamnet
E- Linorenal ligamnet
Ans: E (FA)

Explanation:
- Splenorenal (Linorenal. ligament has – Splenic artery, vein and Tail of pancrease
- Gastrosplenic ligament has – Short gastric and left gastroepiploic vessel
- Gastrohepatic ligament has – Gastric vessel
- Gastrocolic ligament has – Gastroepiploic arteries
- Hepatidudenal ligament has – Portal triad: proper hepatic artery, portal vein, common bile duct
- Falciform ligament has – Ligament teres hepatis and patent paraumbilical vein

395- Splenic artery relation to the pancreas
A- Behind the upper border of pancreas
B- Anterior to the tail of pancreas
C- Posterior to the tail of Pancreas
D- Behind the aorta
E- Anterior to body of pancreas
Ans: A

396- If SMA is occluded which structure will be spared
A- Ascending and transverse colon
B- Transverse colon
C- Descending & Sigmoid colon
D- Appendix
E- Ascending colon
Ans: C

Explanation:
- The superior mesenteric artery (SMA) supplies the midgut, which includes:
- The duodenum (distal to the major papilla) to the proximal two-thirds of the transverse colon
- The appendix, cecum, ascending colon, and the proximal transverse colon
- The descending colon and sigmoid colon are part of the hindgut, which is supplied by the inferior mesenteric artery (IMA). Therefore, these structures are spared in the event of SMA occlusion

397- Patient Underwent Mastectomy. Flap from suprapubic area of rectus abdominis used for Breast Reconstruction during surgery, which artery needs to be grafted along with it?
A- Superficial epigastric artery
B- Superior epigastric artery
C- Inferior epigastric artery
D- Internal Thoracic artery
E- Musculophrenic Artery
Ans: B(RJ Last)

Explanation:
- A pedicled flap of the upper part of the rectus muscle based on the superior epigastric artery—or a free flap of the lower part with anastomosis of the divided inferior epigastric artery to the internal thoracic artery—is used in reconstructive breast surgery. Superior epigastric artery is preferable.

398- A bullet hit a person from superior iliac region and goes out at 4th lumbar region, there was massive blood on laparotomy which major vessel is hit at the root of mesentery?
A- Right Renal vein
B- Inferior mesenteric vessel
C- Left renal vein
D- Aorta
E- Portal vein
Ans: D

399- Accessory pancreatic duct if present drains:
A- Lower part of head of pancreas
B- Upper part of head of pancreas
C- Uncinate Process
D- Tail of Pancreas
E- Neck of Pancreas
Ans: B

400- Blood supply of the fundus of the stomach?
A- Short gastric vessels
B- Right gastroepiploic artery
C- Splenic artery
D- Celiac Trunk
Ans: A(KLM and RJ Last)

CamScanner

Explanation:

- The stomach is supplied by branches from the coeliac trunk.
- The fundus and upper left part of the greater curvature receive about six short gastric arteries from the splenic artery
- The rest of the curvature is supplied by the left and right gastrocpiploic vessels
- A branch from the splenic artery, the posterior gastric artery, may also supply the stomach.

401- A young, muscular male who regularly performs strength training exercise in gym presents with a mass in the inguinal region, persisting for 6 months. The mass has now become tender and strangulated, leading to a diagnosis of an indirect inguinal hernia. What is the most likely cause?

A- Patent processus vaginalis
B- Weak abdominal musculature
C- Narrow walls of the inguinal canal
D- Wide ring in external Obliue
E- Patent pleuroperitoneal membrane
Ans: A

402- Surgeon was removing Carcinoma at tail of Pancreas. It will lead to damage of:

A- Lienorenal ligament
B- Gastrosplenic ligament
C- Greater Curvature
D- Falciform ligament
E- Gastroduodenal Ligament
Ans: A

Explanation:

- Falciform ligament
- Connects Liver to Anterior abdominal wall
- Contains Ligament teres
- Hepatoduodenal ligament
- Contains Portal triad:
- Proper hepatic artery, portal vein, common bile duct
- Gastrohepatic ligament
- Contains Gastric vessels & Part of Lesser omentum
- Gastrosplenic ligament
- Contains Short gastrics, left gastroepiploic vessels
- Part of Greater omentum
- Gastrocolic ligament
- Contain Gastroepiploic arteries
- Part of Greater omentum
- Splenorenal ligament
- Contains Splenic vessel and tail of pancreas

403- 60 years old patient Presented with Dyphagia for both Solids & Liuids along with Weight loss & Malaise. O/E. Enlarged Left supraclavicular lymph nodes. Esophagus barium study shows "Shouldering of esophagus." Investigation of choice:

A- CT
B- MRI
C- PET Scan
D- Endoscopic Biopsy
Ans: D(Carcinoma of Esophagus)

404- Vagus, parasympathetic & thoracic greater splanchnic end on?

A- Distal 1/3 of transverse colon
B- Sigmoid Colon
C- Junction of Transverse colon
D- Duodenojejunal Flexure
Ans: D

405- A 30 year old male patient present to the emergency department with history of abdominal pain that begin diffusely around the umbilicus and then migrated to RLQ he also reports fever ,nausea, and vomiting on physical examination rebound tenderness was positive later diagnosed as a case of acute appendicitis.which of the following is responsible for the reffered pain around the umbilicus (Medicine Feb 2025)

A- T11
B- T10
C- T8
D- T12
E- L1
Ans: B

406- A patient present aortic aneurysm at the its bifurcation while surgery on this aortic aneurysm which of the following structure is at the risk of damage (Medicine Feb 2025)

A- Ureter
B- Testicular artery
C- External iliac artery
D- Obturator nerve
Ans: A

407- Ischemia of lower third of Duodenum is artery involved is (Medicine Feb 2025)

A- Superior pancreatoduodenal artery
B- Inferior pancreatoduodenal artery
C- Supraduodenal artery
D- left gastric artery
E- Gastroduodenal artery
Ans: B

CamScanner

4[illegible]- Surgeon accidentally cut some nerve from vagal trunk. Which part of GIT will be least affected? (Medicine Feb 2025)

A- Ascending colon
B- Cecum
C- Transverse colon
D- Sigmoid colon
Ans: D

409- Right side of abdomen is not covered with sac. Diagnosis is: (Medicine Feb 2025)

A- Gastroschisis
B- Omphalocele
C- Meckel's diverticulum
D- Intussusception
E- Volvulus
Ans: A

Explanation:

- Gastroschisis occurs when body wall closure fails in the abdominal region. As a result, intestinal loops herniate into the amniotic cavity through the defect, which usually lies to the right of the umbilicus
- Omphalocele represents another ventral body wall defect but it does not arise from a failure in body wall closure. Instead, it originates when portions of the gut tube [the midgut] that normally herniates into the umbilical cord during the 6th to the 10th weeks [physiological umbilical herniation] fails to return to the abdominal cavity.Subsequently, loops of bowel, and other viscera, including the liver, may herniate into the defect. Because the umbilical cord is covered by a reflection of the amnion, the defect is covered by this epithelial layer. [In contrast, loops of bowel in gastroschisis are not covered by amnion because they herniate through the abdominal wall directly into the amniotic cavity

410- During a cholecystectomy, the cystic artery is damaged. Which vessel should be clamped to control bleeding? (Medicine Feb 2025)

A- Celiac trunk
B- Phrenic artery
C- Hepatic artery proper
D- Superior mesenteric artery
Ans: C

411- Structure damaged during Hiatal hernia surgery repair (Surgery Feb 2025)

A- Azygous vein
B- Thoracic duct
C- Vagus nerve
D- Sympathetic Nerves
E- Gastric artery
Ans: C

412- 45-year-old female with a history of a lower segment cesarean section (LSCS) 2 days ago presents with an epigastric swelling that appears on standing and coughing. On examination, no palpable defect is noted. What is the most likely diagnosis? (Surgery Feb 2025)

A- Epigastric hernia
B- Incisional hernia
C- Femoral Hernia
D- Paraumbilical hernia
Ans: B

413- A patient presented with pain & Absolute constipation. O/E , Abdominal distension & an incisional scar seen. On the right side of the scar.there is a swelling that is hulging outwards & tender. X-ray reveals Dilated small bowel loops & Multiple air fluid levels. Most probable diagnosis? (Surgery Feb 2025)

A- Acute Intestinal obstruction
B- Chronic Intestinal obstruction
C- Volvulus
D- Strangulated Incisional hernia
E- Obstructed Hernia
Ans: A

414- A patient develops abdominal bloating and constipation after surgery. Despite adequate hydration, there is no passage of flatus or stool after 72 hours of laparotomy. What is the investigation of choice?(Gynae & Obs Feb 2025)

A- USG abdomen
B- CT abdomen
C- MRI
D- X-ray abdomen erect and supine
Ans: D

415- A 30 year old male patient present in surgery OPD with indirect inguinal hernia he states that he went to gym daily and lift heavy weights which of the following is cause of hernia in this patient (Gynae & Obs Feb 2025)

A- Abdominal muscle weakness
B- Patent processes vaginalis
C- Chronic Constipation
D- Heavy lifting weight at gym
E- Trauma to groin at gym
Ans: B

CamScanner

416- A 40 Years old manual worker presents with a swelling in the groin. O/E: mass is found to be just above and lateral to the pubic tubercle. It is reducible. On applying pressure on the internal ring there is no cough impulse seen. What is the most probable dx? (Gynae & Obs Feb 2025)

A- Inguinal hernia
B- Hydrocele
C- Femoral hernia
D- Strangulated hernia
E- Lipoma
Ans: A

417- A female patient with the history of 3 sections presents with epigastric swelling and a non palpable defect and cough impulse positive the most likely diagnosis is (Gynae & Obs Feb 2025)

A- Incisional hernia
B- Epigastric hernia
C- Divarication of recti
D- Paraumblical hernia
E- Umblical hernia
Ans: C

418- A 45 year old male present with fever ,severe abdominal pain ,nausea,vomiting and constipation on examination there was irreducible lump in the lower abdomen which was tender ,ertbymatous and very painful what is most likely diagnosis (Gynae & Obs Feb 2025)

A- Strangulated hernia
B- Intestinal obstruction
C- Incarcerated hernia
D- Appendicitis
E- Abdominal wall hematoma
Ans: A

419- A child after RTA present in OPD having left flank pain on examination there was tenderness in left side BP was 90/60 which of the following investigation u will order (Radiology Feb 2025)

A- Sigmoidoscopy
B- Colonoscopy
C- CT abdomen
D- MRI
E- Ultrasound whole abdomen
Ans: C

420- A patient present with appendicitis and after 4 days ,a fluid collection is noted at caudal site the most appropriate management option (Radiology Feb 2025)

A- Open and drain the fluid
B- IV antibiotics
C- Placement of drain
D- Laproscopic drainage
Ans: C

421- During inguinal hernia repair surgery, which nerve is most at risk of injury?(Radiology Feb 2025)

A- Ilioinguinal nerve, iliohypogastric nerve, and genital branch of the genitofemoral nerve
B- Ilioinguinal nerve and genitofemoral nerve
C- Obturator nerve and lateral femoral cutaneous nerve
D- Femoral nerve and pudendal nerve
E- Sciatic nerve and posterior femoral cutaneous nerve
Ans: A

422- What might the cause of visceral pain in abdomen? (Anesthesia Feb 2025)

A- increase distension of viscera and contraction of viscera
B- stretch in capsule of viscera
C- pressure on ligaments mesentry and vessels
D- Ischemia of Visceral tissue
Ans: A

CamScanner

PELVIS AND PERINEUM QUICK HINTS

Random

- ✓ Tunica vaginalis derived from - Parietal peritoneum
- ✓ Needle passed to drain fluid from tunica vaginalis which layer not pierced - Tunica albugenia
- ✓ Bladder vessels lie in - Dorsolateral ligament
- ✓ Common site of Ectopic pregnancy -Ampulla of Fallopian Tube
- ✓ Least Common site for Ectopic pregnancy – Cervix
- ✓ Mediolateral episiotomy structure damage is – Bulbospongiosis
- ✓ Mediolateral episiotomy structure at risk of damage – Levator ani
- ✓ Median episiotomy structure damage is – External anal sphincter
- ✓ Paramesonephric duct (mullerian duct) give raise to female genital structures like fallopian tube. uterus & upper 1/3rd of vagina.
- ✓ Urogenital Sinus form Lower Vagina
- ✓ Coccygeal ligament start at LS2 and ends at coccyx , while coccygeal segment lies at L1
- ✓ Aneries at 5 and 7o' click position started bleeding due to blockage of **Bendoch Artrey**
- ✓ Arteries at 2 and 10o' click position started bleeding due to blockage of **Floch artrey**
- ✓ Hysterectomy is perfonned through transverse pubic incision known as – pfannensteil incision
- ✓ Myomectomy performed in which large fibroids rectus muscle to be transferred best possible incision known as – Midline incision
- ✓ Pain of ovarian tumor referred to thigh by **obturator nerve**
- ✓ Sensory supply to uterus reaches via – **Broad ligament**
- ✓ Weight bearing lines passes through ischial tuberosities
- ✓ Bladder separated from rectum by **Donoviller fascia**
- ✓ Landmark for pudendal nerve block – **ischial spine**
- ✓ External anal sphincter atteachd anteriorly to the perineal body
- ✓ In pelvic outlet Fracture – Acetabulum intact
- ✓ In Pelvis Fracture – Ischial tuberosity Intact
- ✓ Glans of Penis & Corpora is drained into Deep Inguinal Lymphatic Nodes while Skin of Glans Penis is drained into superficial inguinal lymphatic nodes
- ✓ Muscles part of levaror ani – Pubococcygeous > puborectalis
- ✓ Main support of uterus is: Lateral Cervical Ligament.
- ✓ Dynamic Support of uterus is: Pelvic Diaphragm.
- ✓ Associated support of Uterus is: Uterosacral Ligament
- ✓ Main support of pelvic viscera – levator ani
- ✓ Wedge shaped fibromuscular mass that separates urogenital and anal triangle is perineal body
- ✓ During pregnancy obliteration of uterine cavity occurs due to fusion of decidua peritalis and decidua capsularis
- ✓ Length of ureter is 25 to 30cm
- ✓ Length of follapian tube is 10cm
- ✓ Deep dorsal vein of penis drains to Santorini plexus (internal iliac or pudendal vein) and superficial into great saphenous vein
- ✓ Urorectum septum separates – rectum and urogenital sinus
- ✓ Man with multiple fractures of pelvis has no cutaneous sensations in urogenital triangle . The f nerve is most likely spared – illiohypogastric nerve
- ✓ Neck of bladder and proximal urethra is supplied by – Sympathetic L1- L2 via hypogastric plexus
- ✓ Structure act as a cnduit between peritoneal cavity and uterus - follapian tube
- ✓ Superficial external pudendal is branch of – femoral artery
- ✓ Urogenital diaphragm attached laterally to inferior ramus of pubis and ischial ramus
- ✓ Muscles which originates from lumbar region and goes into deep pelvis – Psoas

CamScanner

- ✓ After RTA Patient was on motorcyle fell down Damaged to symphis pubis Structure damaged with this is Levator ani
- ✓ Dartos fascia is extension of - smooth muscles

Pelvic inlet and pelvic outlet

Pelvic inlet is bounded
- ✓ Posterior – coccyx
- ✓ Lateral – illiopectinate lines
- ✓ Anterior – symphysis pubis

Pelvic outlet is bounded
- ✓ Posterior – coccyx
- ✓ Lateral – ischial tuberoisities
- ✓ Anterior – symphysis pubis

Pelvis

- ✓ Fmgers not Reachable to Sacral Promontory –**Android Pelvis**
- ✓ Fingers Reachable to Sacral Promontory –**Contracted Pelvis**
- ✓ Normal female pelvis is gynecoid pelvis
- ✓ Most common type of pelvis is gynecoid pelvis
- ✓ When transverse diameter of the pelvic inlet is slightly more tham AP diameter is gynecoid pelvis
- ✓ Transverse diameter is more than AP diameter in Platepelloid pelvis
- ✓ Least common type of pelvis is Platepelloid
- ✓ Male type wedge shaped pelvis is Android pelvis
- ✓ **True Conjugate** –Sacral Promontry to upper pubic Symphysis (11cm)
- ✓ **Obstetric Conjugate** –Sacral Promontry to middle or posterior pubic Symphysis (10.5cm)
- ✓ **Diagonal Conjugate**–Sacral Promontry to Lower pubic Symphysis (12cm)

Ovarian fossa boundaries

Superior – external iliac vien and arteries
Anterior – broad ligament of uterus
Posterior – ureter and internal iliac artery and vein
Inferior – obturator nerve artery and vein

Ureter

- ✓ **During Hysterectomy Ureter Damage at A > B > C**
  - A- Cardinal Ligament (Uterine Vessel)
  - B- Behind Broad Ligament
  - C- At Pelvic Brim (Ovarian artery)
- ✓ Ureter Damage at **Pelvic Brim** – While **crossing Common iliac Vessel**
- ✓ **While removing Ovary damage to – Internal iliac Artery**
- ✓ **Anterior** to Ureter – **Gonadal Vessel**
- ✓ **Posterior** to Ureter – **Iliac Vessel**
- ✓ Common Site of Lodging of ureteric stones **overall/Adults – Vesico ureteric Junction**
- ✓ Common Site of Lodging of ureteric stones in **Child – Pelvico ureteric Junction**
- ✓ Ureter **Narrows** at -- **Vesico ureteric Junction > Where it enters Bladder**
- ✓ Post hysterectomy pain structure ligated is ureter
- ✓ Lateral fornix of vagina related to ureter

CamScanner

Prostate

- ✓ Weight of prostate is 20gm
- ✓ Median-Structurally largest lobe
- ✓ Lateral-Anatomically largest lobe
- ✓ Peripheral-Largest zone
- ✓ CA prostate - Peripheral zone / Posterior lobe + Metastasize to Vertebral column and brain by Anterior Intervertebral venous plexus
- ✓ BPH - Median lobe / Transitional zone
- ✓ Prostate blood supply middle rectal and inferior vesical
- ✓ Prostate lymph drains into external iliac + internal iliac
- ✓ Prostate lymph nodes drain **mainly** into internal iliac
- ✓ Prostatic utricle analogue of uterus and vagina

Uterus Prolapse

- ✓ **1st Degree** – Decent of Cervix within Vagina
- ✓ **2nd Degree** –Decent of Cervix to Introitus
- ✓ **3rd Degree** –Decent of Cervix Outside Introitus
- ✓ **4th Degree(Procidentia)** -- Whole Uterus outside Introitus
- ✓ **In 1st and 2nd Degree – Uterosacral Ligament Damage**
- ✓ **3rd Degree – Uterosacral > Cardinal Ligament Damage**
- ✓ **4th Degree – Cardinal Ligament Damage**

Urethra

- ✓ **Neck** of female urethra lies above urogenital diaphragm
- ✓ Female urethra more prone to infection
- ✓ External uretheral meatus – Narrowest part
- ✓ Prostatic urethra – widest and most distensible
- ✓ Membranous urethra – Shortest and least dilatable urethra.
- ✓ **Bulbar** Urethra Rupture **(Below Urogenital Diaphragm)** urine into - **Superficial Perineal Pouch**
- ✓ **Membranous** Urethra Rupture**(At Urogenital Diaphram)** urine into - **Deep Perineal Pouch**
- ✓ **Prostatic** Urethra Rupture**(Above Urogenital Diaphram)** urine into - **Retropubic Space**
- ✓ **Penile** Urethra Rupture Urine into - **Scrotum> Anterior Abdominal Wall**

Sphinters

- ✓ **Internal anal sphincter** -Sympathetic(L1-2) and Parasympathetic(S2-4) through hypogastric plexus
- ✓ **Extern anal sphincter** - Inferior rectal branch of pudendal nerve(S2-4) and perineal branch of S4
- ✓ **Above Pectinate line anal canal** - Sympathetic(inferior hypogastric(L1-2) and Parasympathetic(S2-4)
- ✓ **Below Pectinate line anal canal** - Somatic(Inferior rectal-S2-4)
- ✓ **Internal urethral sphincter**- Parasympathetic pelvic splanchnic nerve(S2-4)
- ✓ **External urethral sphincter (sphincter urethra)** -Pudendal nerve(S2-4) cause voluntry control over micturation
- ✓ External anal sphincter attached anteriorly to the perineal body
- ✓ External urethral sphincter is present in urogenital diaphragm

Ischorectal fossa

- ✓ External anal sphincter attached anteriorly to the perineal body
- ✓ External urethral sphincter is present in urogenital diaphragm

Boundaries

- ✓ **Apex** – edge is formed by line of meeting of obturator internus and levator ani
- ✓ **Base** – skin
- ✓ **Anteriorly** – Posterior border of perineal memberane

CamScanner

- ✓ **Posteriorly** – gluteus maximus and sacrotuberous ligament
- ✓ **Medial wall** – sloping levator ani muscles and anal canal
- ✓ **Lateral wall**- lower part of obturator internus with covering obturator fascia

Contents

- ✓ Ischiorectal pad of fat
- ✓ Pudendal nerve and its branches
- ✓ Pudendal canal with its contents
- ✓ Internal pudendal vessles

Rectum vs Urinary Bladder

Urinary bladder nerve supply

- ✓ Peritonium covers superior and upper part of posterior surface rest all surfaces devoid of peritonium
- ✓ Motor supply by both sympathetic and Parasympathetic
- ✓ Sympathetic - through hypogastric nerve (T11-L2) cause relaxation of detrous muscle – Urine retention
- ✓ Parasympathetic- Through pelvic splanchnic nerve (S2-4) Cause contraction of detrous muscle – Micturition
- ✓ Pain Sensation of bladder pass through - Lateral Spinothalmic track
- ✓ Awareness of Bladder distension mediated by -DCML(Posterior Column)
- ✓ Pain and filling sensation of bladder by -Sympathetic

Rectum nerve supply

- ✓ Sympathetic(L1-2), Parasympathetic(S2-4) through superior rectal (inferior mesenteric) and Inferior hypogastric plexuses
- ✓ Distension of rectum carried by -Parasympathetic
- ✓ Pain of Rectum carried by -Sympathetic and parasympathetic

Gubernaculum

Remnant of Gubernaculum in female

- ✓ Upper Part – Round ligament of ovary
- ✓ Lower Part – Round ligament of Uterus

Remnant of Gubernaculum in male

- ✓ Upper Part – Degenerate
- ✓ Lower Part (Gubernaculum Testis) –Scrotal ligament

Perineal Poches(BD Churassia)

Contents of superficial perineal pouch

In males

- ✓ **Perineal body**
- ✓ Structure forming root of penis
- ✓ Bulbospongious and ischiocavernosus muscle
- ✓ Superficial transverse perineal muscles
- ✓ **Nerves** include Three set of branches from **perineal nerve** include Post scotal nerve ,branch to bulb of penis & muscular branches also Long perineal nerve from post cutaneous nerve of thigh present
- ✓ **Arteries** include Two branches of perineal artery namely, the posterior scrotal and transverse perineal
- ✓ **Internal pudendal artery** branches are Four branches from the **artery of penis** namely, artery to the bulb of penis, urethral artery, deep and dorsal arteries of penis
- ✓ Only ducts of bulbourethral gland

In females

- ✓ **Perineal body**
- ✓ Structure forming root of clitoris

CamScanner

- ✓ Bulbospongious and ischiocavernosus muscle
- ✓ Superficial transverse perinel muscles
- ✓ **Nerves** include Three set of branches from **perineal nerve** include Post labial nerve ,branch to bulb of vestibule & muscular branches also Long perineal nerve from post cutaneous nerve of thigh present
- ✓ **Arteries** includeTwo branches of perineal artery namely posterior labial and transverse perineal
- ✓ **Internal pudendal artery** branches are Four branches from the **artery of clitoris**, namely artery to bulb of vestibule, urethral artery, deep and dorsal arteries of clitoris
- ✓ Gtreater vestibular glands and ducts

Contents of deep perineal pouch

In males

- ✓ Membranous part of urethra & Sphincter urethrae
- ✓ **Nerves** include Dorsal nerves of penis & Muscular branches of **perineal nerve**
- ✓ **Arteries** include **Internal pudendal artery** branches are Four branches from the **artery of penis** namely, artery to the bulb of penis, urethral artery, deep and dorsal arteries of penis
- ✓ Deep transverse perineal muscles
- ✓ Bulbourethral glands

In females

- ✓ Part of urethra i.e Sphincter urethra & Vagina
- ✓ **Nerves** include Dorsal nerves of clitoris & Muscular branches of **perineal nerve**
- ✓ **Arteries** include **Internal pudendal artery** branches are Four branches from the **artery of clitoris**, namely artery to bulb of vestibule, urethral artery, deep and dorsal arteries of clitoris
- ✓ Deep transverse perineal muscles
- ✓ No glands

Lymphatics

- ✓ **Kidney**-Paraaortic /Lumbar
- ✓ **Ovaries** –Paraaortic
- ✓ **Tetses**- Retroperotoneal (Paraaortic/Lumbar) or Aortocaval and rarely iliac nodes
- ✓ **Prostate** – Mainly Internal iliac and also External iliac and Sacral
- ✓ **Vagina** – Internal and External iliac**(Upper 3rd)** , Internal iliac**(Middle)** and Superficial inguinal**(Lower 3rd)**
- ✓ **Cervix** – internal iliac = external iliac > internal iliac
- ✓ **Clitoris** – Deep inguinal
- ✓ **Urinary bladder** – internal and external iliac nodes
- ✓ **Uterine tubes** - internal iliac and paraaortic
- ✓ **Penis** – deep inguinal and external iliac nodes
- ✓ **Rectum** – pararectal nodes , inferior mesenteric nodes and nternal iliac nodes

Nerve supply of pelvic muscles

- ✓ **Piriformis and obturator internus** – Sacral plexus
- ✓ **Levator ani** – pudendal nerve and fourth sacral nerve
- ✓ **Coccygeous** – 4th and 5th sacral nerve

CamScanner

PELVIS AND PERINEUM

1- Patient had Road traffic car accident and had injury to spine and developed quadriplegia. His respiration and BP normal. After three months he came with blood pressure that fluctuates and raises high 180/110, and told that BP gets lowered when lower abdomen and bladder area is massaged and after passing urine, what is cause of increase BP?

A- Increase sensitivity to catecholamines because of upregulation of alpha receptors.
B- Exaggerated autoimmune reflexes because of regeneration process of spinal cord.
C- Filling of atonic bladder which is painful
D- Activation of pons
E- Increase Parasympathetic activity

Ans: A

2- Doctor is having more fear to do median episiotomy because of risk of damage to:

A- External anal sphincter
B- Levator ani
C- Bulbospongiosis
D- Perineal body

Ans: A

Explanation:

- Mediolateral episiotomy structure damage is – Bulbospongiosis
- Mediolateral episiotomy structure at risk of damage – Levator ani
- Median episiotomy structure damage is – External anal sphincter

---

3- A structure consist of glandular acini stratified columnar epithelium smooth muscles and connective tissue is most likely:

A- Urinary bladder
B- Prostate gland
C- Urethra
D- Adrenal gland
E- Submandibular

Ans: B

4- Dai delivered a baby hematoma develop in broad ligament is due to injury of:

A- Ovarian artery
B- Uterine artery
C- Internal illiac artery
D- Femoral artery
E- Obturator artery

Ans: B

5- Least dilatable part of the urethra is:

A- Membranous part
B- Prostate part
C- Spongy
D- All are equally dilatable
E- External urethral meatus

Ans: A

Explanation:

- Extemal uretheral meatus – Narrowest part
- Prostatic urethra – widest and most distensible
- Membranous urethra – Shortest and least dilatable urethra.

6- A Urologist doing transurethral surgery, 2 arteries at 5 and 7o' clock position started bleeding and his way blocked name of those arteries is:

A- Capsular artery
B- Uretheral artery
C- Floch's artery
D- Badenoch arteries
E- Branches of superior vesicle artery

Ans: D

Explanation:

- Badenoch artery – 5&7 clock
- Floch artery – 2 &10

7- A women presents with 40 weeks gestation cephalic presentation. The cervix is dilated upto 6cm and head is at 0 station. What is the landmark/reference point?

A- Ischial spine
B- Pubic tubercle
C- Symphysis pubis
D- Inguinal ligament
E- Mid inguinal

Ans: A

8- A female patient presented with pain hypochondrium Exploratory Laparotomy was done which showed that ovaries were attached to lateral pelvic wall which structure in this area has increased risk of damage during procedure?

A- Ovarian Artery
B- Uterine Artery
C- Internal Iliac Artery
D- Femoral Artery
E- Pudendal Artery

Ans: C

Explanation:

- During hystrectomy ureter damag at A>B>C
  - A- cardinal ligament (uterine vessel)
  - B- Behind broad ligament
  - C- At pelvic brim (ovarian artery)
- Ureter damage at pelvic brim – While crossing common iliac vessel
- While removing ovary damage to – Internal iliac artery
- So ovarian artery damage at pelvic brim and internal iliac artery while removing ovary from lateral pelvic wall in this case

CamScanner

9- **Regarding male urogenital system Structure arranged behind the bladder from lateral to medial in which order?**
A- Ureter, Seminal vesicle, Ampulla of vas deference
B- Seminal vesicle ampulla of vas deference, ureter
C- Ureter. Ampulla of vas, seminal vesicle
D- Ampula, Ureter and Seminal
Ans: A (USA Pneumonic)

10- **Bulhourethral gland is present in which of the following?**
A- Superficial perineal pouch
B- Deep perineal pouch
C- Root of pems
D- Sphincter urethra
Ans: B

Explanation:
- Bulbourethral gland is a part of deep perineal pouch
- Greater vestibular gland is the part of superficial perineal pouch
- Bulbar urethra rupture (Below urogenital diaphragm) urine into – Superficial perineal pouch
- Membranous urethra rupture (At urogenital diaphragm) urine into – Deep perineal pouch
- Prostatic urethra rupture (Above urogenital diaphram) urine into – Retropubic space
- Penile Urethra Rupture Urine into – Scrotum> Anterior Abdominal Wall

11- **A patient having below hymen boil on Labia majora, group of lymph nodes involved:**
A- Medial group Horizontal superficial inguinal LN
B- Vertical group of upper middle superficial inguinal LN
C- Vertical group of superficial inguinal LN
D- Deep inguinal LN
E- External iliac LN
Ans: A

12- **A 29-year-old woman is admitted to a hospital because the birth of her child is several days overdue. Tearing of the pelvic diaphragm during childbirth leads to paralysis of which of the following muscles?**
A- Pirifonnis
B- Sphincter urethrae
C- Obturator internus
D- Levator ani
E- Sphincter ani externus
Ans: D

13- **Highest no of alpha receptors are present in:**
A- Trigone
B- Neck of bladder and proximal urethra
C- Penile urethra
D- Membranous urethra
E- External urethra
Ans: B

14- **Parasympathatic supply of rectum and bladder consist of following nerve root value**
A- L2-3
B- S2-S4
C- S1-2
D- S4-5
E- S5
Ans: B

Explanation:
Urinary bladder nerve supply
- Sympathetic - through hypogastric nerve (T11-L2) cause relaxation of detrous muscle – Urine retention
- Parasympathetic- Through pelvic splanchnic nerve (S2-4) Cause contraction of detrous muscle – Micturition

Rectum nerve supply
- Sympathetic(L1-2), Parasympathetic(S2-4) through superior rectal (inferior mesenteric) and Inferior hypogastric plexuses

15- **Hystrectomy is perfomed through transverse suprapubic incision known as:**
A- Mayor incision
B- Maynert incision
C- Linear vertical incision
D- Pfannenstiel inscision
Ans: D

16- **Genital branch of genitofemoral nerve:**
A- Gives branches to anterior
B- Gives branches to posterior scrotal wall
C- Pass through deep inguinal ring
D- Pass through superficial inguinal ring
Ans: C

17- **Distention of rectum is transmitted by which of these**
A- Sympathetic afferent
B- DCML
C- Parasympathetic
D- Lateral Tract
Ans: C (Grey's Anatomy +BD)

Explanation:
- Distension of rectum carried by - Parasympathetic

CamScanner

- Pain of Rectum carried by -Sympathetic and parasympathetic
- Pain Sensation of bladder pass through - Lateral spinothalmic track
- Awareness of bladder distension mediated by – DCML (Posterior Column)
- Pain and filling sensation of bladder by – Sympathetic

18- In an old age patient myomectomy performed in which very large fibroids rectus muscle to be transferred best possible incision:

A- Midline
B- Pfannestiel
C- Transverse
D- Oblique
Ans: A(Prefer Vertical)

19- Superficial boundary of superficial perennial pouch is

A- Perineal membrane
B- Ischial tuberosity
C- Ischial SPine
D- Ischiopubic rami
Ans: A

Explanation:

- **Superiorly** – Perineal membrane
- **Inferiorly** – Membranous layer of Superficial fascia
- **Laterally** – Ischiopubic rami

20- Ureter relation with uterine artery at:

A- Crosses common iliac vessels
B- Broad Ligament
C- Iscbial Spine
D- Inguinal point
E- Aorta
Ans: A

21- Spinal Level of PUJ is

A- L4
B- T11-T12
C- T11-L5
D- L2
E- S2
Ans: D

22- Regarding upper 2/3 of anal canal, which is correct?

A- Drained by inferior rectal artery
B- Sensitive to stretch
C- Sensitive to pain
D- Supplied by pudendal nerve
E- Lined hy stratified columnar epithelium
Ans: B

23- Students was sitting on stool and visualizing slide on microscope professor suddenly asked you are sitting on which bone?

A- Pubis
B- Ischia tuberosity
C- Sacrum
D- Ilium
E- Cocyx
Ans: B

24- A patient Para 8 with UV prolapse and cervix at introitus ligament damage is

A- Uterosacral ligament
B- Transverse cervical ligament
C- Broad ligament
D- Round ligament
E- Perineal body
Ans: A

Explanation:

- 1st Degree – Decent of Cervix within Vagina
- 2nd Degree – Decent of Cervix to Introitus
- 3rd Degree – Decent of Cervix Outside Introitus
- 4th Degree (Procidentia) – Whole Uterus outside Introitus
- In 1st and 2nd Degree – Uterosacral Ligament Damage
- 3rd Degree – Uterosacral > Cardinal Ligament Damage
- 4th Degree – Cardinal ligament damage

25- Micturition is controlled by:

A- Mechanoreceptors in bladder wall
B- Inhibited by a center in pons
C- Stretch of urethral sphincter
D- Condition reflex
E- Processed in cerebral cortex
Ans: A

26- Superficial inguinal lymph node drain into:

A- Lower body of uterus
B- Cervix
C- Vagina above hymen
D- Ureter
E- Vagina below hymen
Ans: E

Explanation:

Vaginal lymph as follow

- Upper1/3rd drain into external and internal iliac node.
- Middle1/3rd drain into the internal iliac node.
- Lower1/3rd into the superficial inguinal node.

CamScanner

27- **Regarding urinary bladder true is:**
A- Motor supply by sympathetic and parasympathetic
B- Posterior surface not covered with peritonium
C- Columnar Epithelium
D- Supplied by L3-4
Ans: A

Explanation:
- Peritonium covers superior and upper part of posterior surface rest all surfaces devoid of peritonium
- Motor supply by both sympathetic and Parasympathetic

28- **A Patient present with painless testicular swelling and diagnosed as tumor Testicular tumor drains into which of following group of lymph nodes?**
A- Iliac lymph node
B- Popliteal lymph nodes
C- Inguinal lymph nodes
D- Lumbar lymph nodes
E- Sacral lymph node
Ans: D

29- **Lymphatic spread of right testicular CA to which of following?**
A- Right internal iliac nodes
B- Right aortocaval nodes
C- Inguinal lymph nodes
D- Inferior mesenteric nodes
E- Deep inguinal nodes
Ans: B

30- **Patient after RTA Sacral region damage with dribbling of urine likely due to:**
A- Bladder injury
B- Parasymoathetic damage
C- Detrous muscle injury
D- None
Ans: B

Explanation:
Injury above Sacral Segment (Sympathetic damage) Cause:
- Spastic Bladder
- Automatic Bladder
- Urge Incontinence

Injury at Sacral Segment (Parasympathetic damage) Cause:
- Atonic Bladder
- Autonomous Bladder
- Overflow Incontinence

Note: Neurogenic is common term for both spastic and Atonic Bladder.

31- **External anal sphincter attached to perennial body:**
A- Posteriorly
B- Anteriorly
C- Laterally
D- Medially
Ans: B

32- **Muscle cut during episiotomy:**
A- Levator ANI
B- Bulbocavernous
C- Bulbosalpingeous
D- Bulbospongiosus and superficial transverse perineal
Ans: D

33- **A patient comes to you with the history of fall from height now presented with the complain of urine incontinence the damage of which section of spinal cord involves:**
A- Lumbar
B- Sacral
C- Lumbosacral
D- Coccygeal
Ans: C

34- **Most common site of ureteric stone lodgement:**
A- Hilum of kidner
B- Proximal ureter
C- Distal ureter
D- Neck of bladder
Ans: C

35- **Structure lateral to lower vagina:**
A- Urogenital diaphragm
B- Ureter
C- Uterine artey
D- Bladder
Ans: A

36- **External urethral sphineter is present in?**
A- Psoas facia
B- Fascia transebersalis
C- Urogenital diaphragm
D- Anorectal facia
Ans: C

37- **Artery remains inside pelvis:**
A- Middle rectal artery
B- Superior rectal artery
C- Inferior rectal artery
D- Superior vesicle artery
Ans: A

CamScanner

38- To anesthetize the during delivery a pudendal nerve block is performed. This nerve block may result in urinary incontinence due to anesthesia of muscle lying in the:
A- Urogenital diaphragm.
B- Superficial perineal pouch.
C- Pelvic diaphragm.
D- Ischiorectal fossa.
E- Trigone of bladder
Ans: A

39- Normal weight of prostate:
A- 10gm
B- 18gm
C- 22gm
D- 15gm
Ans: B

40- Organ lined by stratified squamous epithelium with increase vascularity, elasticity, tubular glands in lamina propria?
A- Vagina
B- Uterus
C- Fallopian tube
D- Cervix
Ans: A

41- Damage to perineal body muscle injured will be:
A- Deep tranverse perineal
B- Bulbospongiosus
C- External sphinter
D- Internal sphinter
Ans: B

42- In pelvic outlet fracture which is not damaged?
A- Pubic symphysis
B- Ischial tuberosity
C- Sarcotuberous ligament
D- Coocyx
E- Acetabulum
Ans: E
Explanation:
- In pelvic outlet Fracture – Acetabulum intact
- In Pelvis Fracture – Ischial tuberosity Intact

43- Lymphatic drainage of clitoris:
A- Superficial inguinal
B- Deep inguinal
C- Internal illiac
Ans: B

44- A 68-year-old woman with uterine carcinoma undergoes surgical resection. This cancer can spread directly to the labia majora in lymphatic that follow which of the following structures?
A- Pubic arcuate ligament
B- Suspensory ligament of the ovary
C- Cardinal (transverse cervical) ligament
D- Suspensory ligament of the clitoris
E- Round ligament of the uterus
Ans: E

45- Ovarian artery branch of:
A- Abdominal aorta
B- Internal illiac
C- External illiac
D- IMA
Ans: A

46- A young man suffers injury to lacerates penile urethra. After where else urine will be leaked:
A- Anterior abdominal wall
B- Rectovesical pouch
C- Deep perineal pouch
D- Pelvis
Ans: A

47- Lateral Fornix of Vagina is related to
A- Ureter
B- Pudendal Artrey
C- Pudendal Nerve
D- Broad Ligament
Ans: A

48- lower boundary of lumbar triangle is formed by
A- illiacCrest
B- Lastismus dorsi
C- External oblique
D- Internal oblique
E- Inguinal ring
Ans: A
Explanation:
- **Anteriorly** – Posterior border of external oblique
- **Posteriorly** – Lattismus dorsi
- **Inferiorly(Base)** – Iliac crest
- **Floor** – Internal oblique

49- Glans of Penis Lymphatic drainage:
A- Para Aortic
B- Superficial Inguinal
C- Deep Inguinal
D- Internal Iliac
Ans: C
Explanation:
- Glans of penis drain into deep inguinal lymph nodes while
- Skin of glans penis drain into superficial inguinal lymph nodes

CamScanner

50- Ureter damaged during hysterectomy at
A- Pelvic Brim
B- Bifurcation of Common Iliac Artery
C- Base of Broad Ligament
D- Suspensory Ligament
Ans: C

Explanation:
- Ureter damaged during hysterectomy follows the following order: Cardinal Ligament > Broad Ligament > Pelvic Brim.

51- A boy on bicycle had an accident and presented with unable to void is due to injury to:
A- Urethra
B- Urinary Bladder
C- Prostate
D- Vas deferens
E- anuria due to hypovolemia
Ans: A

52- The medial wall of ischiorectal fossa is formed by
A- Levator Ani
B- Perineal Membrane
C- Obturator Internus
D- External Anal Sphincter
E- Gluteus Maximus
Ans: A

Explanation:
- Medial wall: Sloping fibres of Levator Ani & Anal Sphincter
- Lateral Wall: Lower part of Obtruator Internus with covering Fascia
- Anterior wall: posterior border of perineal membrane
- Posterior wall: sacrotuberous ligament and gluteus Maximus
- Base : form by skin
- Apex : line of meeting of obturator internus and levator ani

Contents:
- Ischiorectal pad of fat
- Pudental nerve & its branches
- Internal pudental vessels
- Pudental canal with its content

53- Bladder on cystoscopy with lem growth & basement membrane intact:
A- Ca in Situ
B- UTI
C- BPH
D- Bladder Ca
Ans: A

54- Which of the following is dynamic support of uterus?
A- Pelvic diaphragm
B- Broad ligament
C- Urogenital diaphragm
D- Transverse cervical ligament
Ans: A

Explanation:
- Main support of uterus is: Lateral Cervical Ligament.
- Dynamic Support of uterus is: Pelvic Diaphragm.
- Associated support of Uterus is: Uterosacral Ligament

55- Which of the followig lies posterior to urinary bladder
A- Anal canal
B- Prostate
C- Denonvillers fascia
D- Completely covered by peritoneum
E- Covered by peritoneum in lower half only
Ans: C

56- What is the landmark for Pudendal Nerve Block?
A- Sacral promontory
B- Ischial spine
C- Ischial tuberosity
D- Pubic tubertubercle
Ans: B

Explanation:
- Land mark of Pudendal nerve Block - ischial spine
- Weight bearing line passes through- ischial tuberosity

57- Micturition reflex is
A- Self generating
B- Cerebral control
C- Condition reflex
D- None:
Ans: A

Explanation:
- Initiation of Micturition reflex - Stretch receptors in bladder wall
- Micturition centre (stimulatory)- Pons
- Micturition centre (Inhibitory) - Midbrain
- processing of micturition - Cerebral cortex
- micturition reflex / integration - Sacral segments of spinal cord
- Vontarily Inhibition -Activation of Pudendal nerve
- Pain and filling sensations of bladder are carried by -Sympathetic(Guyton)

58- Bilateral S3.4.5 cut what will result in
A- Painless menses
B- Anorgasmia
C- Rectal incontinence
D- Labour with out pain
Ans: C

59- Bulbar urethral rupture blood will extravasate into:
A- Superficial perineal pouch
B- Deep pouch
C- Scrotum
D- anterior abdominal wall
Ans: A

CamScanner

Explanation:

- Bulbar Urethra Rupture(Below Urogenital Diaphragm) urine into-Superficial Perineal pouch
- Membranous Urethra Rupture(At Urogenital Diaphragm) urine into-Deep Perineal Pouch
- prostatic Urethra Rupture(Above Urogenital Diaphragm) urine into Retro pubic Space
- penile Urethra Rupture Urine into-Scrotum> Anterior Abdominal Wall

60- Hypogastric sheath is condensation of:

A- Superior gluteal
B- Inferior gluteal
C- Pelvic fascia
D- Transversialis fascia
Ans: C

61- Regarding symphysis pubis true is:

A- Secondary cartilaginous joint
B- Synarthrosis
C- Gomphosis
D- Sec ossification
E- Primary cartilaginous joint
Ans: A

Explanation:

Primary cartilagenous joint

- 1st Sternocostal joint
- Between epiphysis and Diaphysis of long bone

Secondary cartilagenous joint

- Intervtebral discs
- Symphysis pubis
- Manubriosternal joint

62- Micturition reflex

A- Once start then self-regenerative
B- Control by sacral segments of spinal cord.
C- Control by cerebral cortex
Ans: B

63- Defecation carried out by:

A- Sacral parasympathetic nerves
B- Myentric plexus
C- Mass movements
D- Cerebral cortex
Ans: A

Explanation:

- Defecation is initiated by -- Mass Movement
- Defecation is Carried out by -- Sacral Parasympathetic
- Defecation Reflex- Recto Anal
- Defecation Reflex in Baby- Gastro colic

64- A child fall from 7 feet height, later he develops urinary incontinence and loss of control of bowel. Where islesion?

A- SI, S2, S3
B- Urethra rupture
C- Casuda equina
D- Ureter damage
Ans: B

65- 85 year old female undergoes laparotomy for secondary infertility,artery which can be damaged while removing ovary?

A- Internal iliac artery
B- Uterine
C- Subcostal arteries
D- Superficial circumflex iliac artery
Ans: A

66- Mass in ovarian fossa will damage which of the following structure?

A- Uterine artery
B- Internal iliac artery
C- Internal iliac vein
D- External iliac artery
Ans: B

67- Prostatic lymphatic drainage

A- External illiac
B- Internal illiac
C- Inguinal
D- Parainguinal
Ans: B

68- While Ligating Ureter at Pelvic brim artery damaged is:

A- Uterine artery
B- Internal Illiac artery
C- Ovarian artery
D- External iliac artery
Ans: C

69- During hysterectomy, ovarian artery damaged at:

A- Pelvic brim
B- Iscial spine
C- Ischial tuberosity
D- Pubic symphysis
E- Sacroilliac jomt
Ans: A

70- Which of following muscle is part of levator ani

A- Puborectalis
B- Pubococcygeous
C- Illiorectalis
D- Illiococcygeous
Ans: B> A

CamScanner

71- Patient with the deep knife wound in the buttock and walks with the waddling gait that is characterised by the pelvis falling towards one side at each step which of the following nerve damage?
A- Obturator nerve
B- Illioinguinal nerve
C- Inferior gluteal nerve
D- Superior gluteal nerve
E- Femoral nerve
Ans: D

72- Venous drainage of urinary bladder
A- Internal iliac vein
B- External iliac vein
C- Common iliac vein
D- Internal + external iliac vein
Ans: A

73- What is the nerve supply of internal urethral sphincter?
A- Splanchnic nerve
B- Pudendal nerve
C- Hypogastric nerve
D- Ilioinguinal nerve
Ans: A > C

74- Supply of sphincter urethra (External urethral) comes from:
A- Pelvic splanchnic nerve
B- Pudendal nerve
C- Hypogastric nerve
D- None
Ans: B (BD Churasia)

75- Skin of scrotum drains into:
A- Internal iliac
B- Superficial inguinal
C- Deep inguinal
D- External iliac
Ans: B

76- Patient stood on right leg, pelvis dropped on left side which nerve damage:
A- Left superior gluteal
B- Left inferior gluteal
C- Right superior gluteal
D- Right inferior gluteal
Ans: C

Explanation:
- It is right superior gluteal nerve which supplyabductor muscles (gluteal mmimum and medius) and help to lift up the opposite site of pelvis.

77- A wedge shaped fibromuscular mass that separates urogenital and anal triangle?
A- Perineal membrane
B- Perineal body
C- Uro-rectal septum
D- Urogenital sinus
Ans: B

78- Sciatic nerve passes through:
A- Behind inguiinal ligament
B- Obturator formen
C- Sephenous opening
D- Lesser sciatic foramen
E- Greater sciatic foramen
Ans: E

79- The skin of scrotum blood supply:
A- Perineal arteries
B- Pudendal artery
C- Penile arteries
D- Testicular arteries
Ans: B

Explanation:
- (The exteral pudendal branch offemoral and scrotal branches of internal pudendal supplies the scrotum).

80- Sperm storage site
A- prostate
B- Urethra
C- Ampulla
D- Epididymis
E- Seminal vesicle
Ans: D

81- Patient presented with testicular cancer . it will involve which lymphatics
A- Paraortic
B- Superficial inguinal
C- Deep inguinal
D- Pre aortic
Ans: A

82- Which of following is true about female urethra
A- Resistant to infections
B- Prone to infections
C- Structure below urogenital diaphragm
D- Longer than male urethra
Ans: B

83- Obturator internus muscle nerve supply:
A- Femoral nerve
B- Sacral plexus
C- Pudendal nerve
D- Illiohypogastric nerve
Ans: B

CamScanner

Explanation:
Muscles of pelvic wall supply
- Pirifomis - sacral plexus
- Obturator internus - sacral plexus
- Levator ani - pudendal and 4th sacral nerve
- Coccygeus - 4th and 5th sacral nerve

84- The plane from sacral promontory to the inferior surface of pubic symphysis is an important dimension for normal delivery is referred to be
A- True Conjugate
B- Diagonal Conjugate
C- Obstetric Conjugate
Ans: B

Explanation:
- True Conjugate— Sacral promontory to upper pubic symphysis (11cm)
- Obstetric Conjugate -Sacral promontory to middle or posterior pubic symphysis (10.5cm).
- Diagonal Conjugate -Sacral promontort to lower pubic symphysis (12cm)

85- Lateral relation of upper part of vagina:
A- Ureter
B- Urogenital diaphragm
C- Pelvic diaphragm
D- Levator ANI
Ans: A

Explanation:
- Lateral to upper part: Ureter
- Lateral to middle part: Anterior fibers of levator ANI
- Lateral to lower part: Urogenital diaphragm

86- Anterior half of sphincter urethra covered by:
A- Urogenital diaphragm
B- Perineal body
C- Pelvic diaphragm
Ans: A

87- Superficial inguinal nodes drain directly & follow the tract of:
A- Round ligament of uterus
B- Cervix
C- Uterus
Ans: A

88- In pelvic outlet fracture which bone is not fractured?
A- Pubic crest
B- Ischial tuberosity
C- Sacrotuberous ligament
Ans: A

(In option if acetabulum is present prefer that)

89- Pelvic inlet anterior aperture boundary?
A- Pubic symphysis
B- Ischial tuberosity
C- Sacrotuberous ligament
D- Illiopectinate lines
Ans: A

90- Pelvic outlet bounded anteriorly by:
A- Urogenital diaphram
B- Pelvic diaphram
C- Levator ani
D- Piriformis
Ans: A

91- Main support of pelvic viscera?
A- Levator ani
B- Uterosacral ligament
C- Anal sphincter
D- Pelvic diaphragm
Ans: A

92- Blood supply of middle third of rectum?
A- Superior rectal artery
B- Middle rectal artrey
C- Inferior rectal artery
D- Inferior vesical artrey
Ans: A

93- Which of the following is posterior division of sacral plexus?
A- Nerve to quadratus femoris
B- Iuperior gluteal nerve
C- Inferior gluteal nerve
D- Common peroneal nerve
E- Tibial nerve
Ans: D

94- Blood supply of lower third of rectum:
A- Superior rectal artery
B- Middle rectal artrey
C- Inferior rectal artery
D- Internal pudendal artery
Ans: C

95- Middle rectal artery is branch of:
A- External iliac artery
B- Common iliac artery
C- Inferior vesical artery
D- Internal pudendal artery
E- Inferior mesenteric artery
Ans: B (Prefer Internal Iliac)

Explanation:
- Superior rectal branch of - Inferior mesenteric artery.
- Middle rectal branch of — Internal iliac artery which is branch of common iliac artery.
- Inferior rectal artery branch of -Internal pudendal artery.

CamScanner

96- Part of levator ani that slings around anus forming angle:
A- Cocygeus
B- Puborectalis
C- Puboanal
D- Levator ani
Ans: B

97- Uterine artery passes anterior to:
A- Rectum
B- Ureter
C- Ilium
D- Ovary
Ans: B
Explanation:
- Uterine artery passes anterior to ureter .
- Common illiac artrey passes posterior to ureter

98- The plane from sacral promontory to the inner surface of pubic symphysis is an important dimension for normal delivery it refers to be
A- True conjugate
B- Obstretic Conjugate
C- Diaonal conjugate
D- None
Ans: B

99- Most common type of pelvis in obstructed labour
A- Gynecoid
B- Platepelloid
C- Android
D- Platypelvic
E- Dollichopelic
Ans: C

100- Superior rectal artery is branch of:
A- External iliac artery
B- Common iliac artery
C- Inferior vesical artery
D- Internal pudendal artery
E- Inferior mesenteric artery
Ans: E
Explanation:
- Superior rectal branch of – Inferior mesenteric artery
- Middle rectal branch of -Internal iliac artery which is branch of common iliac artery
- Inferior rectal anery branch of -Internal pudendal artery.

101- Branch of internal iliac which is mostly absent?
A- Illioypogastric
B- Lateral sacral
C- Middle rectal
D- Superior rectal
Ans: C

102- Inferior rectal artery is branch of:
A- External iliac artery
B- Common iliac artery
C- Inferior vesical artery
D- Internal pudendal artery
E- Inferior mesenteric artery
Ans: D

103- Support of female reproductive viscera?
A- Levator ani
B- Uterosacral ligament
C- Broad Ligament
D- dinal ligament
Ans: A
Explanation:
- Pelvic viscera Support— Levator ani
- Uterus support- cardinal > broad >Uterosacral

104- Superficial external pudendal artrey emerges from:
A- Saphenous opening
B- Rectus sheath
C- Femoral sheath
D- Cribriform fascia
E- None
Ans: A
Explanation:
- Superficial external pudendal artrey pierces the femoral sheath and cribriform fossa , then it crosses the spermatic cord (males) or round ligament (females) and emerges from sephnous opening

105- During pregnancy, obliteration of uterine cavity occurs due to fusion of:
A- Amnion & decidua capsularis
B- Decidua Parietalis& decidua capsularis
C- Chorion& amnion
D- Decidua basale& Capsularis
Ans: B

106- A middle-aged man came back from Cairo & developed painless hematuria, what is the likely diagnosis
A- Squamous cell carcinoma of the urinary bladder
B- Transitional cell carcinoma of the urinary bladder
C- Transitional cell carcinoma of the prostate
D- squamous cell carcinoma of prostate
Ans: A (Cairo is the capital of Egypt and is endemic for schistosomiasis which causes SCC of the urinary bladder)

CamScanner

107- Which one forms pelvic diaphragm?
A- Levator ani
B- Deep perennial muscle
C- Sphincter urethra
D- Bulbospongiosus muscle
Ans: A

108- Rupture of membranous urethra, fluid will accumulate in:
A- Superficial perennial pouch
B- Deep perennial pouch
C- Scrotum
D- Anterior a abdominal wall
Ans: B

109- Sensation of distension of rectum
A- Parasympathetic nerve.
B- Sympathetic nerve.
C- Inferior rectal nerve.
D- Middle rectal nerve.
E- Superior rectal nerve
Ans: A

110- Parasympathetic supply of rectum:
A- S 1,2, 3
B- S 2,3, 4
C- S 3,4, 5
D- 12
E- S2
Ans: B

111- Perineal area innervated by
A- S1 s2 s3
B- S2 s3 s4
C- S5 s6 s7
D- S2 s3
Ans: B

112- Sacral plexus anterior division branch is
A- Sciatic
B- Common peroneal
C- Tibial
D- Obturator
Ans: D

113- Which of the following is branch of posterior division of sacral plexus?
A- Pudendal
B- Posterior cutaneous nerve of thigh
C- Common peroneal nerve
D- Nerve to quadratus femoras
E- Perforating cutaneous nerve
Ans: E>C

114- Length of ureter is
A- 5 to 10 cm
B- 10 to 15 cm
C- 20 to 15 cm
D- 25 to 30 cm
E- 30 to 35 cm
Ans: D

115- Coccygeal ligament starts at
A- L1
B- L2
C- S1
D- S2
E- S3
Ans: D
Explanation:
- Coccygeal ligament extension of dura matter start at S2 and ends at coccyx
- Coccygeal segment lies at LI level

116- 17 years old boy suffers a traumatic injury at groin region, the urologist notices tenderness and swelling of boy right testicle that may be produced by thrombosis in which viens
A- IVC
B- Right inferior epigastric vien
C- Right external phdendal vien
D- Right renal vien
E- Rt internal pudendal vien
Ans: A

117- A patient presented with scrotal mass with transillumination test positive , the mass most likely involves which of the following structure?
A- Tunica vaginalis
B- Tunica vasculosa
C- Testis
D- prostate
E- None
Ans: A

118- Deep dorsal vein of penis drains
A- Santorini plexus
B- Batson venous pleaxus
C- Sub sartorial plexus
D- Pampiniform plexus
Ans: A
Explanation:
Deep –Santorini Plecus(Internal iliac or pudendal vein)
Superficial- Great Sephnous vein

119- Prostatic duct opens into:
A- Spongy urethra
B- Prostatic sinus
C- Prostatic utrie
D- Seminal colliculus
Ans: B

120- 29 years old women with ruptured ectopic pregnancy is admitted to hospital for cardiocentesis , a long needle on syringe is most efficiently inserted through which structure.
A- Anterior wall of rectum
B- Posterior fornix of vagina
C- Posterior wall of uterus
D- Anterior wall of uterus
E- Posterior wall of bladder
Ans: B

CamScanner

121- Structure damaged in fracture of sacrum and ischial spine:

A- Coccyx
B- Anus
C- Rectum
D- Illium
Ans: C

122- Type of pelvis in male:

A- Android
B- Gyencoid
C- Anthropoid
D- Platepelloid
Ans: A

123- Post hysterectomy, patient presented with lumbar pain and anuria after 1-day cause is:

A- Urethra injury
B- Kidney injury
C- Ureter ligation
D- Spleen injuiry
Ans: C

124- 23 year old man has gonorrhea infection that bas infiltrated the space btw inferior fascia of urogenital diaphragm and superficial perineal fascia , which of of following structure might be inflamed

A- Root of penis
B- Bulbourethral gland
C- Deep transverse perineal muscles
D- Sphincter urethrae
Ans: A

125- 65 years old man is incapable of penile erection after surgery with prostectomy , the patient most likely has level of lesion of

A- Pelvic splanchnic nerve
B- Perineal nerve
C- Pudendal nerve
D- Hypogastric nerve
Ans: A

126- Site of impaction of ureteric stone:

A- Nearest to kidney
B- Opening of ureter into Bladder
C- At crossing of common iliac vessels
D- Pelvic brim
Ans: B

Explanation:

- Common Site of Lodging of ureteric stones overall/Adults — Vesico ureteric Junction
- Common Site of Lodging of ureteric stones in Child -Pelvico ureteric Junction
- Ureter Narrows at - Vesico ureteric Junction > Where it enters Bladder?

127- Anatomically largest lobe of prostate:

A- Peripheral
B- Central
C- Median
D- Lateral
Ans: D

Explanation:

- Largest zone is peripheral.
- Structurally largest lobe is median.
- Anatomically largest lobe is lateral.

128- 23 years old women visit her obstretician for an annual checkup , during vaginal examination which following structure may be palpable

A- Fundus of uterus
B- Uterine cervix
C- body of clitoris
D- Urinary bladder
Ans: B

129- In removing ovarian surgery ligation of urethra is so common they are related when both passes at?

A- Pelvic Brim
B- Pelvic Diaphragm
C- Ischial tuberosity
D- Pelvic diaphragm
Ans: A

130- 70 years old man comes to physician for annual check up , which of the following structure is most readily palpable during rectal examination

A- Prostate gland
B- Epidydimis
C- Ureter
D- Testis
Ans: A

131- Ca cervix drains which lymph node?

A- Inguinal
B- Internal illiac
C- Internal and External illiac
D- Para aortic
Ans: C

132- 76 years of man has carcinoma of rectum . The carcinoma most likely metastasizes via veins into which of the following structure?

A- Liver
B- Breast
C- Lung
D- Kidney
E- Spleen
Ans: A

CamScanner

133- Examination pregnant lady shows inverted ischial spine and narrow pubic arch , best term use for this type of pelvis Doctor ahle to reach the sacral promontry

A- Anthropoid pelvis
B- contracted pelvis
C- Androiid pevis
D- Platepelloid pelvis
Ans: B

Explanation:
- Able to reach – Contracted
- Unable to reach – Android

134- Prostate carcinoma involves which cells

A- Osteoclasts
B- Osteoblasts
C- Osteocytes
D- Osteoprogeinator cells
Ans: B

135- An old lady defecates without her desire and which nerve is injured?

A- Superior Rectal nerve
B- Inferior rectal nerve
C- External pudendal
D- None
Ans: B

136- Sensory Supply to uterus reaches via which ligament?

A- Round ligament
B- Broad ligament
C- Uterosacral ligament
D- Transverse cervical ligament
Ans: B

137- 70 years old man Infected bulbourethral glands . Which of following structure might be infected by this infection

A- Superficial perineal space
B- Testis
C- Seminal vesicles
D- Production of sperms
E- Sphincter urethrae
Ans: E

138- Women is delivering breech baby , the obstetrician decide that it is best to perform a mediolateral episiotomy. Which of following structure should be avoid incising

A- Levator ani
B- Bulbospongious muscle
C- Perineal membrane
D- Perineal body
E- Superficial transverse perineal muscles
Ans: A

139- 32 year old patient with multiple fractures of pelvis has no cutaneous sensations in urogenital triangle . The function of which of following nerve is most likely spared

A- Illioinguinal nerve
B- Pudendal nerve
C- Genitofetnoral nerve
D- Illiohypogastric nerve
Ans: D

140- Superficial inguinal lymph nodes drain:

A- Lower vagina
B- Fundus of uterus
C- Lower uterus
D- Clitoris
Ans: A

141- After tubal ligation bleeding source:

A- Uterine Artery
B- Ovarian Artery
C- renal artery
D- Superior vesical artrey
Ans: A

Explanation:
- During Hysterectomy & Tubal Ligation the artery damaged is Uterine Artery.
- During oophorectomy the artery damaged is internal iliac artery

142- After hysterectomy patient complains of pain in lumber region due to

A- Ureter Ligation
B- Uterine Artery Ligation
C- Ovarin Artery Ligation
D- Bladder Trauma
Ans: A

143- After pelvic fracture patient went into shock due to:

A- Hemorrhage
B- Air Embolism
C- Pulmonary Embolism
D- Cardiogenic Shock
Ans: A

Explanation:
- Hemorrhage due to femoral artery or iliac artery rupture.
- For Air embolism there will be history procedure like passmg CVP then developed SOB.
- For pulmonary embolism there will be history of stasis like patient with long bones fracture was operated and on 3rd day developed sudden SOB

CamScanner

144- Largest zone of the prostate:
A- Peripheral
B- Central
C- Median
D- Lateral
Ans: A

Explanation:
- Largest zone is peripheral.
- Structurally largest lobe is median.
- Anatomically largest lobe is lateral.

145- Rectum in pelvic region is identified by:
A- Appendices epiplociae
B- Complete muscular coat
C- Posterior to prostate
D- Forms medial wall of ischiorectal fossa
Ans: B

146- History of RTA with pelvic fracture which of the following could be the possible cause for low blood pressure?
A- Excessive blood loss
B- Cardiogenic shock
C- Anaphylactic Shock
D- Toxemic Shock
Ans: A

147- In RTA Pelvis fracture of anterior inferior iliac spine cause avulsion of pelvis due to involvement of which muscle?
A- Sartorius
B- Obturator internus
C- Adductor longus
D- Adductor brevis
E- Rectus femoris
Ans: E

Explanation:
- Anterior inferior iliac spine avulsion - Rectus femoris damage
- Anterior superior iliac spine avulsion - Sartorius damage

148- Bulbar urethra lies in:
A- Deep perineal pouch
B- Superficial perineal pouch
C- Scrotum
D- Bladder
Ans: B

149- Injury below and lateral to pubic tubercle will damage:
A- Obtruator nerve
B- Femoral nerve
C- Ilioinguinal nerve
D- Sciatic nerve
Ans: A

150- Ureter can be damaged at pelvic brim while ligating:
A- Uterine artery
B- Internal iliac artery
C- Ovarian artery
D- Aorta
Ans: C

Explanation:
- The artery at pelvic brim is ovarian artery.

151- Neck of bladder and proximal urethra is supplied by
A- Pudendal nerve
B- Pelvic splanchnic nerve
C- Lesser splanchnic nerve
D- Sympathetic L1 - L2 via hypogastric plexus
Ans: D

152- Post-operative intra-abdominal bleeding following lower segment C-Section. Most likely source of bleeding:
A- Uterine vein
B- Branches of uterine artery
C- Ovarian artery
D- Internal iliac artery
Ans: B

153- Prostate arterial supply is
A- Superior vesical artrey
B- Inferior vesical artery
C- External illiac artrey
D- Internal illiac artrey
E- Common illiac artrey
Ans: B

154- Bilateral S2, S3 and S4 damaged:
A- No delivery pain
B- Fecal incontinence
C- Urinary incontinence
D- Both fecal & urinary incontinence
Ans: D

155- 70 years old patient is suffering from carcinoma of rectum . he develops pain in the posterior aspect of thigh due to involvement of nerve , which nerve supply the posterior aspect of that could be involved in malignancy of rectum
A- Sacral nerves
B- Lumbosacral trunk
C- Obturator nerve
D- Femoral Nerve
E- Superior hypogastric plexus
Ans: A

CamScanner

156- **Which structure act as a conduit between peritoneal cavity and uterus?**
A- Birth canal
B- Cervix
C- Fallopian tube
D- Ovaries
Ans: C

157- **In pelvis ureter lies anterior to which of the following structure**
A- Ureter
B- Uterine artrey
C- common illiac artrey
D- Follapian tube
Ans: C

158- **Cervical lymphatic drainage:**
A- Internal + External Iliac Nodes
B- Internal Iliac nodes
C- External Iliac Nodes
D- Para Aortic Nodes
Ans: A

159- **Internal pudendal artrey enters the through**
A- Greater sciatic foramen
B- lesser sciatic foramen
C- Obturator foramen
D- None
Ans: B

Explanation:
- Internal pudendal artrey leaves the pelvis through greater sciatic foramen and enter the through lesser sciatic foramen

160- **True about trigone of bladder**
A- Ureter open as oblique slit
B- Ureter opens as vertical slits
C- Develop from urogenital diaphragm
D- develop from urogenital sinus
Ans: A

161- **Which of the following forms pelvic inlet boundary?**
A- Pubic Crest
B- Levator Ani muscle
C- Ischial Tuberosity
D- Iliacus
Ans: A

162- **Urethral sphincter present in**
A- Urogenital diaphragm
B- Pelvic diaphragm
C- Below prostate
D- Below diaphragm
Ans: A

163- **50 year old women had hysterectomy for uterine fibroids. She develops right lumbar pain within 48hour of surgery. Which of the following structure is to be ligated?**
A- Cardinal ligament
B- Meso ovarium
C- Round ligament
D- Ureter
E- Uterine artery
Ans: D

164- **In testis the innermost layer is**
A- Visceral layer of tunica vaginalis
B- Tunica albuginea
C- Parietal layer of tunica vaginalis
D- Tunica vasculosa
Ans: B

Explanation:
- Tunica Vaginalis – Parietal layer
- Tunica Vasculosa – Visceral layer
- Tunica Albuginea – Innermost layer

165- **Lymphatic drainage of anus is**
A- Vertical group of superficial inguinal lymph nodes
B- Medial group of superficial inguinal lymph nodes
C- Deep Inguinal Lymph node
D- Horizontal Group of Superficial Inguinal Lymph nodes
Ans: B

166- **Right ovarian vein drain into:**
A- Right Renal Vein
B- Inferior Vena Cava
C- Celiac Trunk
D- Internal Iliac Vein
Ans: B

Explanation:
- Right ovarian/testicular vein is direct tributary of inferior vena cava
- In case of left ovarian/testicular vein choose left renal vein>inferior vena cava
- Right renal, Supra renal, Gonadal and left renal all drain into – IVC
- Left Supra renal and Gonadal vein drain into – Left renal vein.

167- **Uterus blood supply:**
A- Uterine and ovarian artery
B- Uterine and superior vesicle artery
C- Uterine and inferior vesicle artery
D- Renal and Ovarian artery
E- Ureteric and Uterine Artery
Ans: A

CamScanner

168- Person has dysuria , he has enlarged prostate with suspected prostatic cancer.what will be the route of spread to the skull
A- Hematogenous spread
B- lymphatic spread
C- Direct spread
D- Vertebral plexus
Ans: D

169- Descent of ovary out of abdomen is prevented by?
A- Inguinal Ligament
B- Rectus Muscle
C- Narrow Inguinal canal
D- Uterus
E- Bladder
Ans: D

170- Ureter is underneath to which of the following structure?
A- Uterine artrey
B- Common illiac artries
C- Bladder
D- None
Ans: A

171- Primigravida undergoes normal delivery.Which structure is most likely damaged?
A- Ischial spine
B- Sacrotuberous Ligament
C- Perineal Body
D- Ureter
E- Levator Ani
Ans: E

172- Female patient after obstretic spinal block develops urinary incontinence due to damage of
A- Round ligament
B- Broad ligament
C- Urogenital diaphragm
D- Pelvic diaphragm
Ans: C

173- Pudendal nerve supplies all except:
A- Perineum
B- levatorani .
C- Posterior fornix of vagina
D- Anal canal
Ans: C

174- Which of following is not the branch of internal illiac artrey?
A- Superior vesicle
B- inferior vesicle
C- Middle rectal
D- Inferior rectal
E- Superior rectal
Ans: E

175- The accessory obturator artrey is branch of
A- obturator artrey
B- Inferior epigastruc artrey
C- Superior epigastric artrey
D- Internal illiac artrey
Ans: B

176- Loss of cutaneous sensation at urogenital, triangle, nerve loss
A- Illioinguinal
B- Illiohypogastric
C- Pudendal
D- All of the above
Ans: C

177- Superficial external pudendal is branch of:
A- Femoral artrey
B- Superior epigastric
C- Inferior epigastric
D- External illiac artrey
E- Internal illiac artrey
Ans: A

178- Most common site of ureter stone obstruction in male patient
A- Pelvicoureteric junction
B- Urterovesical junction
C- Middle part of ureter
D- Lateral wall of pelvis
Ans: B

179- Patient with bicornuate uterus associated with anomaly of:
A- Git
B- Respiratory
C- renal
D- CNS
Ans: C

180- Most common cause of urine obstruction in newborn
A- Renal stone
B- Anterior urethral valve
C- Posterior urethral valve
D- UTI
Ans: C

181- Right testicular vein drains into:
A- IVC
B- aorta
C- Left renal vien
D- Right renal vien
Ans: A

182- Which ligament can be palpated on pelvic examination?
A- Uterosacral
B- Broad ligament
C- Round ligament
D- all of the above
Ans: A

CamScanner

183- Most constricted part of male urethra is

A- Bulbar urethra
B- Prostatic urethra
C- Memberanous urethra
D- Penile urethra
E- External urethral meatus
Ans: E

184- Subcutaneous part of external anal sphincter Contain smooth muscle presents around anus and attached to:

A- Smooth muscles
B- Present around anus
C- Coccygoanal body
D- Middle rectal nerve
E- Angle with rectum upward
Ans: C

185- Bone marrow biopsy is done by

A- Ventral iliac crest
B- Pubis
C- Ischiooubis
D- Ischial Tuberosities
Ans: A

Explanation:

First – Posterior illiac crest

- Easily accessible

Second – Anterior superior illiac crest

- Specially in obese

Third – Spinous process of lumbar vertebrae

Fourth – Tibia

- Used in Less than 1 year age
- Medial aspect of upper end of tibia

Fifth – Sternum

- Manubrium or first part of body of sternum

186- Female with bard cystic swelling between labia majora and labia minora due to which gland involvement:

A- Greater Vestibular gland
B- Bulbospongious muscle
C- Blulbourethral gland
D- Bartholin cyst
E- Cervical gland
Ans: A

187- Adjacent spinous process of sacrum fuses to form:

A- Median sacral crest
B- Sacral promontary
C- Pectenial line
D- Intertrochenteric line
Ans: A

Explanation:

- Adjacent spinous processes of sacrum fuse to form – Median Sacral.
- Failure of Fusion of S4 & S5 – Sacral Hiatus.

188- Total abdominal hystrectomy done of woman and I L normal saline is used to wash the wound it touches the pelvic brim and goes into

A- Left Paracolic
B- Right paracolic
C- Subphrenic
D- Pelvis
Ans: C

189- After prostectomy a rectourethral fistula is formed so which layer should have been preserved to be on the safe side

A- Bucks fascia
B- Waldr fascia
C- Denonvilliers fascia
D- Weldr fascia
Ans: C

190- Internal anal sphincter supplied by:

A- Pudendal Nerve
B- Hypogastric plexus
C- Sympathetic
D- Perineal nerve
E- Sciatic nerve
Ans: B

191- Levator Ani is innervated by which of the following?

A- Pudendal Nerve
B- Obturator
C- Sciatic
D- Femoral
E- Tibial
Ans: A

192- Muscle which originates from lumbar region and goes into deep pelvis.

A- Illiacus
B- Psoas
C- Quadrates lumborum
D- Erractor spinae
Ans: B

193- Child presents with pain in lumbar region. Stone at pelviureteric junction pain arising from which segment?

A- Tl1 – L1
B- L1 – L4
C- Tl2 – L2
D- L5
E- Tl1-L2
Ans: C

194- Perianal abscess in female infection spread laterally to

A- Ischiorectal fossa
B- Superficial perineal pouch
C- Deep perineal pouch
D- Birth canal
Ans: A

CamScanner

195- During pelvic surgery, internal iliac artery cut at origin. Which will be spared
A- Urinary Bladder
B- Urogenital diaphragm
C- Penis
D- Scrotum
Ans: C

196- Which structure forms pelvic diaphragm?
A- Puborectalis muscle
B- Pubococcygeus muscle
C- Rectococcygeus muscle
D- Anococcygeus muscle
E- Rectopuboralis
Ans: B>A

197- Pain of ovary reffered to medial of thigh by which nerve
A- Femoral nerve
B- Pudendal
C- Perinal
D- Obturator
Ans: D

198- Pain of indirect inguinal hernia is due to compression of which nerve in inguinal canal?
A- Iliohypogastric
B- Ilioinguinal
C- Femoral
D- Obturator
Ans: B

199- Muscle in the greater sciatic foramen:
A- Obturator internus
B- Obturator Externus
C- Piriformis
D- Gemellus superior
E- Gemellus inferior
Ans: C

200- Patient had RTA & fracture of ilium & sacrum. Which structure is likely to get damaged in pelvis?
A- Urethra
B- Rectum
C- Ureter
D- Urinary bladder
E- Prostate
Ans: B (Snell)

201- Referred pain from ureteric colic is felt in the skin of scrotum due to the involvement of the following nerve:
A- Subcostal
B- Iliohypogastric
C- Ilioinguinal
D- Genitofemoral
Ans: D

Explanation:
- Referred pain to groin and Loin by illioHypogastric and illioinguinal Nerve
- Referred pain to Thigh and Testicle by Genitofemoral Nerve

202- Patient after Vaginal delivery developed Fecal incontinence, likely damage to internal anal sphincter, suitable Investigation is
A- MRI
B- Anal manometry
C- Pudendal nerve stimulation test
D- Perineal nerve test
Ans: B

203- After Trauma urine accumulation in Scrotum, anterior abdominal wall, likely due injury to?
A- Ureter
B- Spongy urethra
C- Prostate uretha
D- Urinary bladder
E- Anterior abdominal wall
Ans: B

204- Sacial hiatus is
A- Fusion of S1, S2
B- Unfused S4, S5
C- Fused S4, S5
D- Unfused L4-5
Ans: B

Explanation:
- Adjacent spinous processes of sacrum fuse to form – Median Sacral.
- Failure of Fusion of S4 & S5 – SacralHiatus

205- Cremasteric muscle nerve supply:
A- Genital branch of gentofemoral
B- Illiofemoral
C- Illiohypogastric
D- Obturator
E- Sciatic
Ans: A

206- Sciatic nerve root value is:
A- L2-4
B- L4-S3
C- S2-4
D- L5-S2
Ans: B

207- Iliolumbar is branch of which of the following?
A- Femoral artery
B- Tibial artery
C- Internal iliac artery
D- Abdominal aorta
E- Vesicle artery
Ans: C

CamScanner

208- Content of superficial perineal pouch:
A- Bulbourethral glands
B- Perineal body
C- Internal pudendal vessels
D- None
Ans: B

209- Floor of acetabular fossa formed by:
A- Ilium
B- Ilium and pubis
C- Ischium and pubis
D- Pubis
E- Ilium
Ans: C

210- Branch of anterior division of sacral plexus ?
A- Nerve to piriformis
B- Superior gluteal
C- Inferior gluteal
D- Lateral femoral cutaneous nerve
Ans: A

211- Vulva nerve Supply is :
A- illioinguinal
B- Femoral
C- Pudendal
D- Tibial
E- Popliteal
Ans: C(Gray's anatomy)

Explanation:
- Over all main nerve supply of vulva is pudendal However sensory innervation vary at labium
- Anterior third of labium by illioinguinal
- Posterior 2/3rd of labium by pudendal

212- Urogenital diaphragm attached laterally to
A- Inferior Ramus of pubis and ischial Ramus
B- Ischial spines
C- Ischial tuberosities
D- Obturater internus fascia
E- Tip of coccyx
Ans: A

213- After RTA Patient was on motorcyle fell down Damaged to symphis puhis Structure damaged with this ?
A- Rectum
B- Levator ani
C- Ischiorectal fossa
D- Ischium
E- Urogenital diaphram
Ans: B

214- A man got injury in lumbar spine and develop Pus in groin region above and lateral to inguinal ligament Which muscle leads to pus formation from lumbar region to groin
A- Internal intercosal
B- Rectus abdominis
C- Psoas
D- Quadratum lamborum
E- External oblique
Ans: C

215- Which ligament prevents extensive flexion at hip joint?
A- Ischiofemoral
B- Iliofemoral
C- Pubofemoral
D- Rectofemoral
E- Punorectal
Ans: B

216- A 20-year-old boy presented with scrotal swelling after injury. Contents of swelling extend up to abdomen but not reaching thigh. Most common cause of this swelling is:
A- Injury to bulbar urethra
B- Injury to membranous urethra
C- Injury to neck of urethra
D- Injury to bulbourethral glands
E- Injury to penile urethra
Ans: E

217- Which ligament prevents extension at hip joint?
A- Iliofemoral
B- Ischiofemoral
C- Sacrospinous
D- Pubofemoral
E- Sacro tuberous
Ans: B

218- Infection in superficial perineal pouch will go to:
A- Deep transverse perineal muscle
B- Bulbourethral glands
C- Great vestibular glands
D- Membranous part of urethra
E- Perineal body
Ans: C

219- Athlete playing high jump now presented with pain in gluteal region. On examination he cannot flex hip and extend knee at same time. Damage to which of the following?
A- Avulsion of anterior inferior iliac spine
B- Ischial tuberosity fracture
C- Pubic symphysis fracture
D- Neck of femur fracture
Ans: A

CamScanner

220- Operating on the inguinal hernia, surgeon found that the hernia is immediately medial to inferior epigastric artery. what type of hernia the surgeon was operating?

A- Indirect inguinal hernia
B- Direct inguinal hernia
C- Femoral hernia
D- Umbilical hernia
E- Incisional hernia
Ans: B

Explanation:
- Direct Hernia medial to – Inferior epigastric artery
- Indirect hernia lateral to – Inferior epigastric artery
- Inferior epigastric artery lateral to – Direct hernia
- Inferior epigastric artery medial to – Indirect hernia

221- The superficial inguinal ring is traversed by:

A- Iliofemoral nerve
B- Ilioinguinal nerve
C- Gentifemoral nerve
D- Iliohypogastimric nerve
Ans: B

222- In rupture of Penile urethra urine will leak into:

A- Posterior thigh
B- Superficial perineal pouch
C- Scrotum and anterior abdominal wall
D- Deep Perineum pouch
E- Anterior thigh
Ans: C

223- Child present with a suprapuhic swe lling which get wet mostly and childa lso has epispadias pubic hone defo rmity what is the cause?

A- Extrophy of Bladder
B- Incomplete caudal closure of cloacal membrane
C- Cloca rupture
D- Craniocaudal fold defect
Ans: B

Explanation:
- Cause is incomplete caudal closure of clocal membrane
- Associated condition is Extrophy of bladder with epispadiasis
- Associated condition is inguinal hernia and Cryptorchidism with Hypospadiasis

224- An elderly patient suffering from constipation off and on and as a result of straining what exactly she is doing that helps her to pass the stool:

A- Contraction of external anal sphincter
B- Contraction of internal Sphincter
C- Relaxation of puborectalis
D- Relaxation of pubococcygeus
E- Relaxation of External anal sphinter
Ans: C

Explanation
- Strainining-puborectalis reflex
  cause contraction of puborectalis tha prevent
  fecal discharge thus relaxation of puborectalis
  will allow her to pass

225- Inguinal lymphadenitis affects which of the following?

A- Upper vagina
B- Upper Uterus
C- Lower part of the uterus body
D- Upper cervix
Ans: C

226- Direct inguinal hernia is due to defect in:

A- External intercostal
B- External oblique
C- Fascia transversalis
D- Rectus abdominis
Ans: C

227- Lumbar hernia protrude from:

A- Superior lumber triangle
B- Inferior lumber triangle
C- Medial to intercostal
D- Lateral to intercostal
Ans: B

228- Placenta attached but not penetrating through myometrium?

A- Accreta
B- Percreta
C- Increta
D- Previa
Ans: A

229- When needle is passed to drain fluid from hydrocele which structure is not pierced?

A- Dartos fascia
B- Cremasteric fasica
C- Skin
D- Tunica albuginia
Ans: D

CamScanner

230- A women has no difficulty in walking but Can't stand from sitting position due to weakness of which muscle?
A- Gluteus minimus
B- Gluteas intermediate
C- Gluteus maximus
D- Sartorius
E- Obturator internus
Ans: C

Explanation:
- Difficulty in standing from sitting – Gluteus maximus damage (Inferior gluteal nerve).
- Waddling Gate – Gluteus medius and minimus damage (Superior gluteal nerve)

231- Prostate mainly drains into the:
A- Internal illac and sacral lymph node
B- External and inguinal lymphnode
C- Paraortic lymph node
D- Superficial inguinal lymph node
Ans: A(BD)

Explanation:
- Prostate drain into both internal and external iliac but mainly in internal iliac and some times to sacral nodes

232- Fascia scarpa extends to:
A- Membranous layer of urogenital diaphragm
B- Scarpa Fascia of Abdomen
C- Scarpa Fascia of Thigh
D- Deep Fascia of Abdomen
Ans: A

233- Stage 4 CA cervix drains which lymph node?
A- Inguinal
B- Internal illiac
C- External illiac
D- Common iliac
E- Pudendal
Ans: B

234- During oopborectomy ureter damage while crossing:
A- Internal iliac arterey
B- Uterine artery
C- Ovarian artery
D- External iliac artery
Ans: B

235- On per rectal examination which bone is felt on its anterior surface:
A- Sacrum
B- Coccyx
C- Ischium
D- Pubis
Ans: B

236- Pain in gluteal region, most likely atherselerosis of which vessel
A- Internal iliac
B- Aorta
C- External iliac
D- Femoral
Ans: A

237- Longest nerve Sciatic nerve arises from
A- Lumbar plexus
B- Sacral plexus
C- Lumbosacraplexus
D- Coccygeal plexus
Ans: C

238- Dartos fascia is extension of:
A- Skeletal muscle
B- Smooth muscles
C- Fat
D- Iliohypogastric
Ans: B

239- Female is not fertile went for ultrasonnd sound. Radiologist noticed some structure behind her ovarian fossa . Which of following structure is seen?
A- Ureter
B- Internal iliac
C- External iliac artery
D- External iliac vein
E- Obturator
Ans: A >B (Grey's anatomy)

Explanation:
- **Superior** – External iliac vein and artery
- Anterior-Broad ligament of uterus
- **Posterior**-Ureter and Internal iliac artery and
- vein
- **Inferior** – Obturator nerve artery and vein

240- A lady had obstructed labur for 2 days, LSCS done. folley passed for 14 days, urine started leaking after 10 days, what could be the cause?
A- Vesico vaginal fistula
B- UTI
C- Stress incontinence
D- Urge incontinence
E- Ureter damage
Ans: A

241- Middle rectal artery is branch of which of the following?
A- External iliac artery
B- Internal iliac artery
C- Inferior vesical artery
D- Internal pudendal artery
E- Inferior mesenteric artery
Ans: B

CamScanner

Explanation:
- Superior rectal branch of – Inferior mesenteric artery
- Middle rectal branch of – Internal iliac artery which is branch of common iliac artery
- Inferior rectal artery branch of – Internal pudendal artery

242- Uterine artery passes to uterus while crossing:
A- Urethra
B- Bladder
C- Ureter
D- None
Ans: C

243- Perineum supplied by:
A- Femoral nerve
B- Pudendal nerve
C- Sciatic nerve
D- Tibial nerve
Ans: B

244- External anal sphincter supplied by
A- Pudendal nerve
B- Obturator nerve
C- Superior rectal nerve
D- Inguinal nerve
E- Perennial nerve
Ans: A

Explanation:
- Internal anal sphincter – Sympathetic (L1-2) and Parasympathetic (S2-4) through hypogastric plexus
- Extern anal sphincter – Inferior rectal branch of pudendal nerve (S2-4) and perineal branch of S4
- Internal urethral sphincter – Parasympathetic pelvic splanchnic nerve (S2-4)
- External urethral sphincter (sphincter urethra) – Pudendal nerve (S2-4) cause voluntary control over micturition

245- Ischiorectal fossa abscess drainage will result in damage to which of following?
A- Inferior rectal nerve
B- Inferior rectal artery
C- Internal pudendal artery
D- Perineal nerve
E- Femoral nerve
Ans: A

246- Posterolateral boundary of pelvic wall formed by
A- Coccyx and sacrum
B- Pubic symphysis
C- Ischial tuberosity
D- Levator ani and pubococcygeus
E- Sacrotuberous and piriformis
Ans: E

247- Vessel at the base of Bladder lie in which ligament?
A- Dorsolateral
B- Ventrolateral
C- Ventromedial
D- Dorsomedial
E- Ligament teres
Ans: A (Snell)

248- Main support of uterus is:
A- Transverse cervical ligament
B- Uterosacral Ligament
C- Pelvic diaphragm
D- Urogenital diaphragm
E- Round ligament
Ans: A

Explanation:
- Major support of uterus – Cardinal (transverse cervical) ligament
- Dynamic support – Pelvic diaphragm

249- A 23 Year primigravida presented to obstetric department in 2nd stage of labour, on examination the sacral promontory was not reacheable and the pelvic arch was narrow and prominent ischial spines the most likely pelvis is
A- Gynecoid pelvis
B- Anthropoid pelvis
C- Plattyploid pelvis
D- Android pelvis
Ans: D

Explanation:
- Fingers not Reachable to Sacral Promontory –Android Pelvis
- Fingers Reachable to Sacral Promontory – Contracted Pelvis

250- Lymphatic drainage of skin around anus:
A- Internal iliac
B- Popliteal
C- Medial group of superficial inguinal lymph nodes
D- Vertical group of Superficial inguinal lymph nodes
E- Lateral group of Superficial inguinal lymph nodes
Ans: C

CamScanner

251- Patient underwent Hystrectomy, Surgeon should know relation of ureter where it can he damage during hysterectomy
A- Pelvic brim
B- 2cm from ischial spine
C- When it moves upward and laterally Behind Broad ligament
D- When crosses common iliac artery
E- At bifurcation of iliac vessels
Ans: C

252- A house officer is performing SVD. She needs to block pudendal nerve for pain relief. What is landmark for pudendal nerve block?
A- Ischial tuberosity
B- Ischial Spine
C- Pubic tubercle
D- Acetabulum
Ans: B

253- In median episiotomy perineal body is damaged If perineal body cut which muscle damage?
A- Bulbospongiosis and Superficial transverse perineal
B- Puborectalis
C- Pubococcygeus
D- Anal sphincter
E- Superficial and deep transverse perineal muscle
Ans: A

254- Glans and clitoris lymphatic drainage is into
A- Superficial inguinal
B- Internal iliac
C- Deep inguinal
D- Vertical group of superficial inguinal
E- Internal and external iliac nodes
Ans: C

255- Lympbatic drainage of prostate
A- Internal iliac
B- External iliac
C- Internal and external
D- Superficial inguinal
Ans: C
Explanation:
- Prostate drain into both internal and external iliac but mainly in internal iliac.

256- In Pudendal block which roots are blocked?
A- S2 S3 S4
B- L1 to s2
C- T12 to L2
D- L4-5
Ans: A

257- 60 year old man presented in OPD with complain of hematuria and increase urinary frequency on DRE there is stony hard mass felt that is prostate lymphatic drainage of it:
A- Deep inguinal
B- Internal iliac and Sacral
C- Superficial inguinal
D- Common iliac
E- Para aortic
Ans: B

258- Regarding lesser pelvis?
A- Has a cavity whose post wall is much shorter than anterior
B- Outlet is bounded by sacrotuberous and sacrospinous
C- Has relatively longer anteropsterior diameter at inlet
D- Has a small sub pubic angle
E- Is generally circular in cross section
Ans: B

259- Stage 4 CA cervix drains which lymph node?
A- Inguinal
B- Internal illiac and External iliac
C- Femoral
D- Common iliac
E- Pudendal
Ans: B

260- Damage to illioinguinal nerve will result in
A- Loss of sensation in posterior thigh
B- Loss of sensation in anterior thigh
C- Loss of ankle reflex
D- Loss of sensation in upper medial thigh
Ans: D

261- A Patient present with painless testicular swelling and diagnosed as tumor Testicular tumor drains into which of following group of lymph nodes?
A- Iliac lymph node
B- Popliteal lymph nodes
C- Inguinal lymph nodes
D- Retroperitoneal lymph node
E- Sacral lymph node
Ans: D

262- If perineal body cut which muscle damage?
A- Bulbospongiosis
B- Puborectalis
C- Pubococcygeus
D- Anal sphincter
Ans: A

CamScanner

263 55 year old woman present in opd with prolapse uterus and intact anal canal due to intact
A- Pelvic diaphragm
B- Round ligament
C- External anal sphincter
D- Urogenital Diaphragm
Ans: C

264- Lymph nodes involved in infection of glans penis:
A- Superficial inguinal
B- Para aortic
C- Internal iliac
D- Deep inguinal
Ans: D

265- Favourable female pelvis for normal delivery is:
A- Android
B- Anthropoid
C- Platypelloid
D- Gynecoid
Ans: D

266- Injection intragluteal is given with technique to avoid damage to?
A- Sciatic nerve
B- Superior gluteal nerve
C- Tibial nerve
D- Femoral nerve
Ans: A

267- Which structure has Intra pelvic extra pelvic extension?
A- Round ligament of uterus
B- Round ligament of ovary
C- Cervical ligament
D- Suspensory ligament
E- Cooper ligament
Ans: A

268- After trauma there is injury to illioinguinal nerve there will be
A- Lateral thigh sensation lost
B- Loss of Dorsiflexion
C- Cremasteric reflex and Medial thigh sensation lost
D- Loss of Testicular reflex and lateral thigh sensation
Ans: C

269- What happens to sperm reaching in epididymis
A- Capacitance occurs
B- Acrosomal reaction
C- Alkaline
D- Circular movement
E- Directional movement
Ans: E

270- Which nerve formed from anterior division of sacral plexus?
A- Femoral nerve
B- Obturator nerve
C- Post cutaneous nerve of thigh
D- Superior gluteal
E- Nerve to piriformis
Ans: B

271- Skin of glans penis drained by:
A- Superficial inguinal lymph nodes
B- Deep inguinal lymph nodes
C- Internal iliac lymph nodes
D- External and internal iliac
E- Para aortic
Ans: A

Explanation:
- Glans of Penis & Corpora is drained into Deep Inguinal Lymphatic Nodes while Skin of Glans Penis is drained into superficial inguinal lymphatic nodes.

272- Superficial pudendal nerve passes through:
A- Saphenous opening
B- Deep ring
C- Superficial ring
D- Sciatic
Ans: A

273- Female urethra:
A- Lies below diaphragm
B- Lies below urogenital diaphragm
C- Lies below urogenital triangle
D- Lies above urogenital triangle
E- Above urogenital diaphragm
Ans: E

Explanation:
- Neck of female urethra lies above urogenital diaphragm
- Female urethra more prone to infection

274- Prostate cancer metastasizes to:
A- Lungs
B- Liver
C- Bone
D- Brain
Ans: C

275- Which structure crosses at the pelvic brim?
A- Uterine artery
B- Ovarian artery
C- Internal iliac artery
D- External iliac artery
Ans: B

CamScanner

276- **Distance from sacral promontry to posterior surface of puhic symphysis:**
A- True conjugate
B- Obstetric conjugate
C- Diagonal conjugate
D- False conjugate
Ans: B

Explanation:
- True Conjugate – Sacral promontory to upper pubic symphysis (11cm)
- Obstetric Conjugate Sacral promontory to middle or posterior pubic symphysis (10.5).
- Diagonal Conjugate – Sacral Promontory to lower pubic Symphysis (12cm)

277- **Pudendal nerve root value is:**
A- S2-S4
B- S3-S4
C- S1-S4
D- T1-S2
E- L1-2
Ans: A

278- **Urogenital diaphragm supplied by:**
A- Pudendal nerve
B- Obturator nerve
C- Inferior rectal nerve
D- Inguinal nerve
E- Perineal nerve
Ans: A

279- **Gluteus maximus nerve supply is**
A- Inferior gluetal nerve
B- Superior gluteal nerve
C- Sciatic nerve
D- Femoral nerve
E- Common peroneal nerve
Ans: A

280- **A young boy presented with painless swelling in the scrotum with no other complication, he gave history of hit by ball very hard on scrotal area 4 months back what is possible diagnose:**
A- Hydrocele
B- Hematoma
C- Hemartoma
D- Hematocele
Ans: A

281- **Urethra cut distal to pelvic diaphragm urine goes to?**
A- Medial thigh
B- Ischiorectal fossa
C- Suprapubis space
D- Infrapubis space
Ans: A

282- **Nerve Supply of anal canal and rectum is?**
A- Tibial nerve
B- Femoral nerve
C- Internal pudendal
D- Sciatic
E- Sacral plexus
Ans: C

283- **Nerve damaged in indirect inguinal hernia?**
A- iliohypogastric
B- illioinguinal nevre
C- Femoral nerve
D- Tibial nerve
E- Sciatic nerve
Ans: B

284- **What is the landmark of sacral hiatus triangle base:**
A- Line connecting Posterior superior iliac spine
B- Line connecting Anterior superior iliac spine
C- illiac crest
D- Cocyx
E- Inteetrochenteric line
Ans: A

285- **Pelvis anasthesia is given for delivery case ischial spine is land mark for which nerve?**
A- Sciatic
B- Tibial
C- Pudendal
D- Femoral
Ans: C

286- **Which structure forms a medial boundary of the inguinal triangle?**
A- Lateral border of rectus femoris
B- Medial border of rectus abdominis
C- Internal oblique
D- Lacunar ligament
Ans: A

287- **According to macneal classification of prostate:**
A- CA prostate involve transional zone
B- BPH involve transitional zone
C- Prostate hypertrophy involve Posterior lobe
D- Prostate atrophy involve Anterior lobe
Ans: B

288- **Glans of Penis Lymphatic drainage:**
A- Para Aortic
B- Para pelvic
C- Tibial
D- Internal Iliac
Ans: D(No option of deep inguinal)

CamScanner

289- Which ligament holds uterus in anteverted position and can he palpable on rectal examination?
A- Uterosacral ligament
B- Round ligament
C- Cardinal ligament
D- Suspensory ligament
Ans: B

290- Internal spermatic fascia is derived from:
A- External oblique
B- Internal oblique
C- Fascia transversalis
D- Transversus abdominus
E- Superficial fascia
Ans: C

Explanation:
- External fascia from external oblique
- Internal fascia from fascia transversalis
- Cremasteric from internal oblique

291- Relation of Deep inguinal ring to Inferior epigastric artery is:
A- Medial
B- Lateral
C- Posterior
D- Anterior
E- Inferior
Ans: B

Explanation:
- Relation of Deep inguinal ring to Inferior epigastric artery --Lateral
- Relation of Inferior Epigastric artery to Deep inguinal ring –Medial

292- Faecal incontinence can result after trauma to:
A- External anal sphincter
B- Internal sphincter
C- Mucosal tea in the anus
D- Perianal region
E- Rupture of rectum
Ans: A

293- Direct inguinal hernia is located:
A- Medial to inferior epigastric artrey
B- Lateral to epigastric artrey
C- Medial to inferior phrenic
D- Medial to inferior mesentric
E- Lateral to inferior phrenic
Ans: A

294- Scrotal lymphatic drainage:
A- Superficial inguinal lymph nodes
B- Deep inguinal lymph nodes
C- Internal iliac lymph nodes
D- Aortic lymph nodes
Ans: A

295- Cremasteric reflex carried by which nerve:
A- Sciatic nerve
B- Lateral Femoral Cutaneous Nerve
C- Tibial nerve
D- Genitofemoral nerve
E- Sural nerve
Ans: D

296- Afferent fibres of cremasteric reflex are carried by:
A- Tibial nerve
B- Lateral Femoral Cutaneous Nerve
C- Ilioinguinal nerve
D- Genital branch of genitofemoral nerve
E- Femoral Nerve
Ans: C

Explanation:
Afferent – Femoral Branch of genitofemoral nerve and illioinguinal nerve
Efferent – Genital branch of genitofemoral nerve

297- Major blood supply of perineum is from:
A- External iliac artery
B- Common iliac artery
C- Inferior vesical artery
D- Internal pudendal artery
E- Inferior mesenteric artery
Ans: D

298- Which structure is formed from genital tubercle in female?
A- Labia majora
B- Clitoris
C- Labia minora
D- Epididymis
E- Ductus deference
Ans: B

299- Female with dragging sensation in lower abdomen, on examination, cervix at introitus, which ligament is damaged?
A- Uterosacral ligament
B- Transverse cervical ligament
C- Broad ligament
D- Round ligament
E- Perineal body
Ans: A

300- Multigravida female with 3rd degree prolapse which ligament will be damaged?
A- Uterosacral ligament
B- Transverse cervical ligament
C- Broad ligament
D- Round ligament
E- Perineal body
Ans: A

CamScanner

Explanation:
1 st Degree – Decent of Cervix within Vagina
2 nd Degree – Decent of Cervix to Introitus
3 rd Degree – Decent of Cervix outside Introitus
4 th Degree (Procidentia) – Whole Uterus outside Introitus
In 1st and 2nd Degree – Uterosacral Ligament Damage
3 rd Degree – Uterosacral > Cardinal Ligament Damage
4th Degree – Cardinal ligament damage

301- Bartholin gland present between:
A- Labia major
B- Cervix
C- Labia minor and vaginal hymen
D- Perineal membrane
Ans: C

302- A lady whose C section was done leakage of blood due to damage of:
A- Uterine vein
B- Branches of uterine artery
C- Ovarian artery
D- Internal iliac artery
Ans: B

302- Surgeon did operation to separate rectum and bladder which one separate them
A- Vesicovagina septum
B- Rectovagibal septum
C- Rectovesical septum
D- Rectovesical
Ans: C

303- Pelvis with anterior-posterior shorter than transverse diameter which type?
A- Android
B- Contracted
C- Gynaecoid
D- Anthropoid
Ans: C

304- Horseshoe kidney is associated with which of the following conditions?
A- Pyelonephritis
B- Renal cell carcinoma
C- Polycystic kidney disease
D- Pelviureteric junction (PUJ) obstruction
E- Medullary sponge kidney
Ans: D

305- Lateral attachment of urogenital diaphragm
A- Sarum and coccyx
B- Obturator internus membrane
C- Inferior ramus of the pubis and ischial tuberocity
D- schial tuberosities
E- Ilium and ischium
Ans: C

306- Patient having complain of urgency and dysuria and Normal PSA and diagnosed as a case of Bening Prostatic Hyperplasia.It involves which of the following lobe most commonly:
A- Anterior
B- Posterior
C- Lateral
D- Median
E- Inferior lobe
Ans: D

Explanation:
- Structurally largest lobe – Median
- Anatomically largest lobe – Lateral
- Largest zone – Peripheral
- CA prostate – Peripheral zone and Posterior lobe
- BPH – Transitional zone and median lobe

307- Vesicovaginal fistula is communication between vagina and
A- Ureter
B- Urethra
C- Urinary bladder
D- Kidney
Ans: C

308- Boy with H/o trauma to perineal region, swelling in scrotum and anterior abdominal wall but didnt go to thigh. Which of the Following is Ruptured?
A- Urethra above urogenital diaphragm
B- Urethra below urogenital diaphragm
C- Penile Urethra
D- Membranous Urethra
E- Urethra at urogenital diaphragm
Ans: C

Explanation:
- Bulbar Urethra Rupture(Below Urogenital Diaphragm) urine into Superficial Perineal pouch
- Membranous Urethra Rupture(At Urogenital Diaphragm) urine into-Deep Perineal Pouch
- Prostatic Urethra Rupture (Above Urogenital Diaphragm) urine into Retro pubic Space
- Penile Urethra Rupture Urine into-Scrotum & Abdominal Wall

309- In an old age patient myomectomy performed & Transverse lower segment incision given to dissect rectus muscles. Incision given is best termed as
A- Transverse
B- Pfannestiel
C- Vertical
D- Oblique
Ans: B

CamScanner

310- Deep perineal pouch contains which of the following?
A- Bulbourethral gland
B- Great Vestibular glands
C- Root of penis
D- Perineal body
Ans: A

311- Nerve injured in lateral wall of pelvis during lymph node removal?
A- Obturator
B- Pudendal
C- Femoral
D- Superior gluteal
E- Sciatic
Ans: A

Explanation:
- Obturator nerve runs forward on the lateral wall of pelvis to reach the upper part of obturator foramen.

312- After RTA Patient was on motorcyle fell down Damaged to symphis pubis Structure damaged with this ?
A- Rectum
B- Levator ani
C- Ischiorectal fossa
D- Ischium
E- Urogenital diaphram
Ans: B

313- Inferior to Pelvic Outlet, Which structure covers Anteriorly?
A- Levator Ani
B- Pelvic arcute ligament
C- Urogenital diaphragm
D- Coccygeus
E- Obturator Externus
Ans: C

314- Be Voluntary inhibition of micturition reflex is by activation of
A- Increased firing of Pudendal nerve
B- Increasing tone of Detrusor muscle contraction
C- Increased tone of External Anal Sphincter
D- Sympathetic
E- Parasympathetic
Ans: A

315- Skeleton is dug out of grave.How to know it is female pelvis?
A- Everted Iliac Ala
B- Heart Shaped Pelvis
C- Inverted Ischial tuberosities
D- Fused ischial spines at the Mid
E- Suprapubic angle <90
Ans: A

316- Patient with low back pain, on rectal examination firm enlarged prostate, raised LDH. Metastasis by?
A- Para aortic
B- Deep inguinal
C- Internal iliac
D- External iliac
Ans: C

317- Primary support of uterus:
A- Lateral cervical ligament
B- Round ligament
C- Broad ligament
D- Pelvic diaphragm
E- Uterosacral Ligament
Ans: A

318- Female with hard cystic swelling covering 2/3rd of Area between labia majora and labia minora due to which gland involvement:
A- Greater Vestibular gland
B- Bulbospongious muscle
C- Blulbourethral gland
D- Bartholin cyst
E- Cervical gland
Ans: A

319- Loss of sensory supply to the bladder will result in which of the following?
A- Urge incontinence
B- Automatic bladder
C- Autonomous bladder
D- Urinary retention
Ans: D

320- In Grade 4 cervical CA, Which lymph nodes are enlarged?
A- Common Iliac
B- Internal Iliac
C- External Iliac
D- Inguinal
E- Sacral
Ans: B

321- A patient with a 3-4 year history of urinary retention now presents with dysuria and occasional urinary tract infections. Which condition is most likely causing these symptoms?
A- Benign Prostatic Hyperplasia (BPH)
B- Urethral Stricture
C- Bladder Cancer
D- Prostatitis
E- Neurogenic Bladder
Ans: A

CamScanner

322- A 65-year-old male patient presents with a prostatic nodule found on digital rectal examination (DRE) and his PSA levels are 5ng/ml .Patient diagnosed as prostate carcinoma.. What best treatment advise u will provide to the patient

A- Watchful waiting with regular monitoring of PSA level
B- Medications such as alpha-blockers or 5-alpha reductase inhibitors
C- Prostatectomy
D- Transurethral resection of the prostate (TURP)
E- Radiation therapy
Ans: A

323- 35 years old gravida is in labour at 40th week of gestation vaginal exam reveals cervical dilation 6cm. fetal presntation cephalic at Zero station which of the folowng land mark is taken as a refernce for Zero station?

A- iliopectineal eminence
B- Ischeal spine
C- Ischeal tuberosty
D- Pubc arch
E- Sacral promntry
Ans: B

324- Sensory nerves of bladder gone) Which micturition problem will happen?

A- Retention of urine
B- Urinary Incontinence
C- UN inhibited Neurogenic Bladder
D- Automatic Bladder
E- Autonomic Bladder
Ans: A

325- Main Lymphatic Drainage of Prostate:

A- Internal Iliac & External Iliac
B- Internal iliac
C- External iliac
D- Common iliac
E- Para aortic
Ans: B

326- oy with H/o trauma to perineal region, swelling in scrotum. Which of the Following is Ruptured?

A- Urethra above urogenital diaphragm
B- Urethra below urogenital diaphragm
C- Penile Urethra
D- Membranous Urethra
E- Urethra at urogenital diaphragm
Ans: C

Explanation:

- Bulbar Urethra Rupture(Below Urogenital Diaphragm) urine into Superficial Perineal pouch
- Membranous Urethra Rupture(At Urogenital Diaphragm) urine into Deep Perineal Pouch
- Prostatic Urethra Rupture (Above Urogenital Diaphragm) urine into Retro pubic Space
- Penile Urethra Rupture Urine into-Scrotum & Abdominal Wall

327- Lymphatic Drainage of 4th degree Cervical Carcinoma:

A- Internal Iliac lymph nodes
B- Para Aortic lymph nodes
C- Superficial inguinal lymph nodes
D- Deep Inguinal Lymph nodes
Ans: A

328- A patient presented with Boil on perineal area, Anal glands enlarged. Rupture of Boil eroding the lateral wall will lead to spread of the Pus into?

A- Ischiorectal fossa
B- Deep perineal pouch
C- Rectopubic space
D- RectoVesical space
E- Superficial perineal pouch
Ans: A

329- A 60 year old patient has history of LUTS(Difficulty Urinating & Urinary dribbling) from last 4 Years. His prostate size is increasing progressively. On palpation, It was firm. Investigations reveal serum PSA levels of 3.2ng/ml. What is this?

A- Benign Prostatic Hyperplasia
B- Prostate cancer
C- Acute Prostatitis
D- Chronic Prostatitis
E- Benign Prostatic Hypertrophy
Ans: A

330- A patient presented with painless testicular swelling and diagnosed as tumor. Testicular Carcinoma drains into which of the following group of lymph nodes?

A- Iliac lymph nodes
B- Popliteal lymph nodes
C- Inguinal lymph nodes
D- Para aorto caval lymph nodes
E- Sacral lymph nodes
Ans: D

331- Which of the following lies between Rectum & urinary bladder?

A- Anal canal
B- Prostate
C- Denonvillers fascia
D- Completely covered by peritoneum
E- Covered by peritoneum in lower half only
Ans: C

CamScanner

332- Most of the Alpha receptors in bladder are located in:

A- Trigone
B- External urethral sphincter
C- Baldder wall & Urethra
D- Bladder Neck

Ans: D

Explanation:

Most of the Alpha receptors are predominantly located in the bladder neck, where they play a role in smooth muscle contraction, commonly associated with conditions like benign prostatic hyperplasia (BPH)

333- Patient presented with scrotal mass with transillumination test positive, swelling hard in texture & cough impulse is negative . Doctor can go above the swelling. Diagnosis?

A- Hydrocele
B- Hematocele
C- Cancer
D- Varicocele

Ans: A

334- Urethral rupture below urogenital diaphrahm: Blood will extravasate into:

A- Superficial perineal pouch
B- Deep pouch
C- Scrotum
D- anterior abdominal wall

Ans: A

Explanation:

- Bulbar Urethra Rupture(Below Urogenital Diaphragm) urine into- Superficial Perineal pouch
- Membranous Urethra Rupture(At Urogenital Diaphragm) urine into- Deep Perineal Pouch
- Prostatic Urethra Rupture(Above Urogenital Diaphragm) urine into Retro pubic Space
- Penile Urethra Rupture Urine into- Scrotum> Anterior Abdominal Wall

335- A female patient presents with continuous urinary discharge from the vagina. What is the most likely underlying defect?

A- Vaginal- ureter fistula
B- Vaginal- bladder fistula
C- Vaginal- rectum fistula
D- Vagina- Uterus fistula

Ans: B

336- Old man having repeated UTI due to which of the following?

A- Catheterization
B- Urinay obstruction
C- Diabetes Mellitus
D- Nerological conditions

Ans: B

337- A 55 year old patient presents with difficulty in urination ,weight loss. On examination mild enlargement of prostrate on investigation markedly raise in PSA levels .lobe of prostate involve in this is

A- Median lobe
B- Posterior lobe
C- peripheral lobe
D- lateral lobe
E- Anterior lobe

Ans B

Explanation:

- CA prostate – **Peripheral zone / Posterior lobe + Metastasize to Vertebral column and brain by Anterior Intervertebral venous plexus**
- BPH – **Median lobe / Transitional zone**

338- Trauma to "Superficial perineal pouch" with needle will lead to damage of which of the following Structure?

A- Bulbourethral glands
B- Seminal Vesicle
C- Bladder
D- Ischiocavernosus muscle
E- Prostate Gland

Ans: D(Snell)

Explanation.

Superficial perineal space (pouch) Contents

- Structures forming the root of the penis (bulb and crura)
- Muscles that cover the root structures (bulbospongiosus and Ischiocavernosus)
- Perineal Body
- Superficial transverse perineal muscles
- Branches of the pudendal nerve and internal pudendal vessels
- Deep Perineal Space (pouch) Contents
- Intermediate (membranous) part of the urethra,
- Part of the external urethral sphincter (the sphincter urethrae), Bulbourethral glands,
- Deep transverse perineal muscles,
- Internal pudendal vessels and their branches
- Dorsal nerves of the penis

339- 28 Years old female with a very short history of short menstrual periods and heavy bleeding presents to ER department with sudden Lower abdominal pain. Investigations reveal a CA125 level of 40U/ml(Normal level between 0- 35U/ml).Laparoscopy was performed which shows fluid in rectouterine Pouch. Fluid is Red, tinged & Clotted with blood. Most suitable diagnosis?

A- Ruptured ectopic pregnancy
B- Ruptured Ovarian endometriotic cyst
C- Krukenberg Tumour
D- Pelvic Inflammatory disease

Ans: B

CamScanner

340- **Internal pudendal artery cut at its origin: Which of the following structure will be spared?**

A- Urogenital diaphragm
B- Scrotum
C- Anal canal
D- Penis
E- Bladder
Ans: E

341- **30y old male patient presents in Surgical OPD with mass coming out of anus .earlier mass was reducible but now mass only mannualy reducible and bas turns blackish which of the following is your diagnosis (Medicine Feb 2025)**

A- Hemorrhoids
B- Anal fitula
C- Anal fissure
D- Rectal prolapse
Ans: A

342- **30 year old female patient presented to Gynae OPD following the vaginal delivery complicated by a perineal tear on perineal examination the tear was extended up to the muscles without involvement of external anal sphincter which Degree of perineal tear she has (Medicine Feb 2025)**

A- First degree perineal tear
B- Second degree perineal tear
C- Third degree perineal tear
D- Fourth degree perineal tear
E- Fifth degree perineal tear
Ans: B (Ten Teachers)

Explanation:
Grading of Perineal tears

First degree	Injury to perineal skin only
Second degree	Injury to perineum involving muscles but not anal sphinter
Third degree	Injury to perineum involving the anal sphincter complex(EAS)
IIIa	<50% of EAS torn
IIIb	>50% of EAS torn
IIIc	Both the EAS and IAS(Internal anal sphincter. torn
Fourth degree	It involves the perineal fascia, both EAS and IAS, rectal mucosa

343- **A patient presented to the emergency after a road traffic accident (RTA). While passing a Foley's catheter, the doctor noted that a part of the urethra was the least dilatable.Least dilatable part of the Male urethra is: (Medicine Feb 2025)**

A- Membranous part
B- Prostate part
C- Spongy
D- All are equally dilatable
E- External urethral meatus
Ans: A

Explanation:
- External uretheral meatus – Narrowest part
- Prostatic urethra – widest and most distensible
- Membranous urethra – Shortest and least dilatable urethra

344- **A man presents with an inguinal swelling that worsened after lifting weights. The swelling is now warm, red, tender, and associated with severe pain and vomiting. Why is emergency surgery recommended? (Medicine Feb 2025)**

A- Incarcerated hernia with strangulation
B- Incarcerated hernia without strangulation
C- Hydrocele
D- Intestinal Obstruction
Ans: A

345- **A male patient with a long history of urinary symptoms has a firm, large, palpable median lobe on examination. What is the most likely diagnosis? (Medicine Feb 2025)**

A- Benign prostatic hyperplasia (BPH)
B- Prostate cancer
C- Bladder carcinoma
D- Urethral stricture
Ans: B

346- **Boy rides a bike, doesn't pay attention, and has got sacral injury from which of the following condition boy will suffer (Medicine Feb 2025)**

A- urge Incontinence
B- Small capacity bladder
C- Autonomous bladder
D- Automatic bladder
E- bladder injury
Ans: C

CamScanner

Explanation:
Injury above sacral segment (sympathetic damage)-cause:
- **Spastic Bladder**
- **Automatic Bladder**
- **Urge Incontinence**

Injury at sacral segment (parasympathetic damage-cause:
- **Atonic Bladder**
- **Autonomous Bladder**
- **Overflow Incontinence**

Note: **Neurogenic is common term for both spastic and Atonic Bladder**

347- A house officer applies local anesthesia to block the pudendal nerve for an episiotomy. Which anatomical landmark is used for the nerve block? (Surgery Feb 2025)
A- Perineal body
B- Ischial tuberosity
C- Pubic tubercle
D- Ischial spine
Ans: D

348- Pain of Diseased ovary reffered to medial of thigh by which nerve: (Surgery Feb 2025)
A- Femoral nerve
B- Pudendal
C- Perinal
D- Obturator
Ans: D

349- Lymphatic drainage of CA TESTIS? (Surgery Feb 2025)
A- Superior mesenteric Lymph nodes
B- Retroperitoneal Lymph nodes
C- Superficial Inguinal
D- Deep inguinal lymph nodes
Ans: B

350- A 60-year-old male presents with prostate enlargement and firmness on digital rectal examination (DRE). No tumor markers are provided. Which prostatic zone is most likely involved? (Surgery Feb 2025)
A- Transitional
B- Peripheral
C- Central
D- Anterior
Ans: A

351- Which structure prevents the backflow of contents from the cecum to the ileum?(Surgery Feb 2025)
A- Ileocecal valve
B- Ileocecal sphincter
C- Pyloric sphincter
D- Internal anal sphincter
Ans: A

352- Following is An action of Parasympathetic Nervous system (Gynae & Obs Feb 2025)
A- Erection
B- Vasoconstriction
C- Relaxation of Gall Bladder
D- Obturator nerve
Ans: A

Explanation:
- Over all Ejaculation
- Pudendal nerve > Sympathetic
- Ejaculation two parts
- Emission -Sympathetic
- Ejection - Pudendal
- Erection –Parasympathetic

353- Which types of pelvis are commonly found in males? (Gynae & Obs Feb 2025)
A- Anthropoid and platypelloid
B- Android and gynecoid
C- Android and anthropoid
D- Android and platypelloid
Ans: C

354- Bartholin gland present between: (Gynae & Obs Feb 2025)
A- Labia majora
B- Cervix
C- Labia minora and vaginal hymen
D- Perineal membrane
Ans: C

355- Which of the following cancer spreads to bones (Gynae & Obs Feb 2025)
A- Small cell carcinoma
B- Prostate carcinoma
C- Breast carcinoma
D- Renal cell carcinoma
E- Squamous cell carcinoma of esophagus
Ans: B

356- Which type of pelvis has increased transverse diameter than AP diameter (Radiology Feb 2025)
A- Gynaecoid Pelvis
B- Android Pelvis
C- Anthropoid pelvis
D- Contracted pelvis
Ans: A

Explanation:
Distinctive Features of the Four Types of Pelve

Characteristic	Gynecoid Pelvis	Android Pelvis	Anthropoid Pelvis	Platypelloid Pelvis
Shape Inlet	Rounded	Heart-shaped	Anteroposteriorly oval	Transversely oval

CamScanner

Transverse Diameter (cm)	13.5	<12	12	13.5
Anteroposterior Diameter (cm)	12	11	>12	<11
Sidewalls	Straight and parallel	Convergent	Straight	Straight and wide
Ischial Spines	Not prominent	Prominent	Not prominent	Not prominent
Subpubic Arch	Wide	Narrow (<10°)	Medium	Wide

357- Which of the following lymph nodes receive lymphatic drainage from testes? (Radiology Feb 2025)

A- Internal iliac LN
B- Para aortic LN
C- Superior inguinal LN
D- Deep inguinal LN
Ans. B(RJ Last)

Explanation:

Lymphatics from the testis run back with the testicular artery to para-aortic nodes lying alongside the aorta at the level of origin of the testicular arteries (L2 vertebra), i.e. just above the umbilicus. The testicular lymph there-fore does not drain to inguinal nodes, although the overlying scrotal skin does.

358- In a case of third-degree uterine prolapse with damage to the uterosacral ligament, the ligament primarily attaches the cervix to which structure?(Radiology Feb 2025)

A- Bladder wall
B- Lateral pelvic wall
C- Posterior pelvic wall
D- Sacrum
E- Round Ligament
Ans: D

359- Pus drained from the posterior fornix of the vagina. Which structure is approached? (Anesthesia Feb 2025)

A- Anterior fornix
B- Rectouterine pouch
C- Vesicouterine Pouch
D- Great Vestibular Glands
E- Lateral Fornix
Ans: B(Snell)

Explanation:

- Because the rectouterine pouch is the most inferior part of the entire peritoneal cavity (when the patient is in the standing position), it freuently becomes the site for the accumulation of blood (e.g., from a ruptured ectopic pregnancy) or pus (e.g., from a ruptured pelvic appendicitis or in gonococcal peritonitis).
- Because the pouch lies directly behind the posterior fornix of the vagina, it is easily violated by misguided instruments that pierce the wall of the posterior fornix..
- A needle may be passed into the pouch through the posterior fornix in a culdocentesis

360- In the final stages of labor a caudal anesthetic is sometimes given via a needle inserted into the sacral hiatus. The anesthetic is thus placed around the outside of the sacral spinal nerve roots and into the: (Anesthesia Feb 2025)

A- Line joining greater trochanter
B- Anterior Process of S5
C- Anterior Superior Iliac Spine
D- Posterior Superior Iliac spine
E- Anterior Inferior Iliac Spine
Ans: B

CamScanner

HEAD AND NECK QUICK HINTS

Random

- ✓ Foramen Ovale -- Acessory Meningeal artery pass
- ✓ Foramen Spinosum -- Middle Meningeal artery pass
- ✓ Superior Orbital Fissure -- V1(Opthalmic nerve) pass
- ✓ Foramen Rotandum-- V2(Maxillary Nerve) Pass
- ✓ Foramen Ovale -- V3(Mandibular Nerve) pass
- ✓ Jugular Foramen – CN 9,10,11(Accessory part) & Sigmoid Sinus
- ✓ Hypoglossal Canal – CN 12
- ✓ Foramen Magnum – Brainstem & Spinal Part of CN11
- ✓ Ansa cervicalis root value is - Hypoglossal with C123
- ✓ Narrow point in pediatric airway – Cricoid
- ✓ Most common congenmtal anomaly of head and neck – Cleft palate
- ✓ Key Muscle of Neck – SCM >Scalenus Anterior
- ✓ Muscle of Neck Demarcation - SCM >Scalenus Anterior
- ✓ Stylohyoid nerve supply –Facial nerve
- ✓ Sternohyoid And Sternothyroid nerve supply –Ansa cervicalis C1-3
- ✓ Geniohyoid and Thyrohyoid nerve supply –C1 through Hypoglossal
- ✓ Gustatory swelling is caused by – Superficial parotidectomy
- ✓ Loss of sensation in lower teeth , chin and lower lip involve – Inferior alveolar nerve
- ✓ Larynx sensation above the vocal cord is suplplied by – Internal laryngeal branch of superior laryngeal nerve
- ✓ Larynx sensation below the vocal cord is suplplied by – Reccurrent laryngeal branch
- ✓ Superior thyroid artery related to – ELN
- ✓ Inferior thyroid artery related to – RLN
- ✓ Superior laryngeal artery related to – Internal laryngeal nerve
- ✓ Most common nerve injured during
- ✓ Thyroidectomy – ELN
- ✓ Most common nerve injured duringTracheostomy – RLN
- ✓ Common site for thyroglossal cyst – Infrahyoid
- ✓ Most Common Cause of Bleed During Tracheostomy – Inferior Thyroid Vein
- ✓ Most Common Cause of Heavy Bleed During Tracheostomy – Anterior Jugular Vein
- ✓ In Child during Tracheostomy Risk of damage to - Left Brachiocephalic vein and Right brachiocephalicTrunk (Innominate artery)
- ✓ All pharangeal muscles supplied by vagus nerve except – Stylopharangeus
- ✓ Stylopharangeus is supplied by – Glossopharangeal nerve
- ✓ All palate uscles are supplied by vagus nerve except – Tensor veli platini muscle
- ✓ Tensor veli platini muscle is supplied by – Trigeminal nerve
- ✓ All laryngeal muscles are innervated by innervated by recurrent larangeal nerve except –Cricothyroid
- ✓ Cricothyroid is supplied by – External laryngeal nerve
- ✓ All infrahyoid muscles are innervated by Ansa cervicalis except – Thyrohyoid muscle
- ✓ Thyrohyoid muscle is supplied by C1 through hypoglossal nerve
- ✓ Location of descent of 2nd pharyngeal arch to epicardial ridge in lower neck – Lateral in neck anterior to sternoclastoid muscle
- ✓ Phonation occur due to - Vibration of vocal cords
- ✓ Tumor suppressing the anterior surface of SCM cause engorgement of – EJV
- ✓ Pain between eye and upper lip Nerve carried by - Maxillary nerve
- ✓ Nerve causing lacrimation while eating is - Trochlear
- ✓ Injury at foramen ovale will lead to - Loss of sensation of at lower face
- ✓ GVE – Supply Smooth muscles and Glands
- ✓ SVE – Supply Pharynx
- ✓ Pituitary tumor invade -sphenoid bone
- ✓ Compress cavernous sinus – Laterally
- ✓ Compress sphenoid air sinus – Inferiorly
- ✓ Compress optic chiasm – Superiorly

CamScanner

- ✓ Compress optic nerve – Anteriorly
- ✓ Characteristic lesion of hereditary telengectasia is found on – lips
- ✓ A blow on right eye near to medial nasal bridge fracture of - Orbital plate of frontal
- ✓ Submandibular gland is divided into deep and superficial part by – Mylohyoid
- ✓ Artery palpated between trachea and sternohyoid – Common carotid artery
- ✓ Most superficial structure in parotid – Facial nerve
- ✓ Cheyne-Stokes breathing is commonly seen after stroke & head trauma
- ✓ Kussmaul Breathing pattern is seen DKA & Uremia
- ✓ Parasympathetic supply to submandibular salivary gland is from- Sup salivary nucleus
- ✓ Most common Salivary gland tumor is pleomorphic adenoma of Parotid gland
- ✓ Most common malignant tumor of salivary gland is mucoepidermoid carcinoma.
- ✓ Structure preventing damage from rotatory movement of head - Falx cerebri
- ✓ Branch of external carotid artery which arises from medialside, behind thePosterior belly of diagstric muscle in substance of parotid gland is b- Posterior auricular > Ascending pharangeal
- ✓ Artery arise from ext carotid art ascend forward in the neck deep to the post belly of diagastric and stylohyoid muscle and then passes deep to the submandibular gland - .facialartery
- ✓ Deep to posterior digastric and near palatoglossus structure runs obliquelyUpwards – lingualArtery
- ✓ Vertical artery runs obliquely upwards under submandibular gland is- Facial artery
- ✓ In Arch of aorta aneurysm nerve damage – Reccurent larangeal nerve

Mandibular nerve supply following muscles

- ✓ Muscle of mastications
- ✓ Tensor veli palatani
- ✓ Tensor veli tympani
- ✓ Mylohyoid
- ✓ Anterior belly of digastric

Elevation of Jaw (Close mouth)

- ✓ Masseter
- ✓ Anterior fibers of Temporalis
- ✓ Medial Pterygoid

Depression of Jaw (Open mouth)

- ✓ Lateral Pterygoid
- ✓ Digastric
- ✓ Myelohyoid
- ✓ Geniohyoid

Cranial nerve Palsy

- ✓ **CN V motor lesion** – Jaw deviates **toward** side of lesion
- ✓ **CN X lesion** – Uvula deviates **away** from side of lesion
- ✓ **CN XI lesion** – Weakness turning head to contralateral side of lesion (SCM) Shoulder droop on side of lesion (trapezius)
- ✓ **CN XII lesion** – LMN lesion. Tongue deviates **toward** side of lesion
- ✓ Vertical Diplopia – CN 4 >CN3
- ✓ **4th nerve palsy** – Diplopia on seeingdown (vertical).
- ✓ **3rd nerve palsy** – Diplopia on seeingdown (Vertical) and or right and left(horizontal).
- ✓ **6th Nerve palsy** - Diplopia on seeingright or left (horizontal)

Ganglion

Submandibular Ganglion

- ✓ Submandibular and Sublingual gland
- ✓ Preganglionic - Chorda tympani of Facial nerve and Lingual of trigeminal nerve
- ✓ Postganglionic - Carotid plexus to lingual gland

Otic Ganglion

- ✓ Parotid gland
- ✓ Preganglionic - Lesser petrosal of Cranial nerve 9
- ✓ Postganglionic - Auriculotemporal

CamScanner

Pterygopalatine ganglion

- ✓ Nasal and Lacrimal gland
- ✓ Preganglionic Parasympathetic - Greater petrosal branch of Facial
- ✓ Preganglionic Sympathtic - Deep petrosal nerve of Cardiac Plexus
- ✓ Postganglionic Parasympathetic - Maxillary branch of trigemmal

Parotid vs Submandicular duct

Parotid duct (Stenson's Duct)

- ✓ Arises from anterior portion of gland run over Masseter and then It pierce buccopharyngeal fascia buccinators and Buccal Mucosa opposite Upper 3rd Molar Tooth
- ✓ It run further short distance in buecal space Between Buccinator and oral mucosa and opens in smal papilla opposite to Upper second molar Tooth

Submandhular Duct (Warthin's Duct)

- ✓ Arises from portion of gland that lies between Mylohyoid and Hypoglossal muscle
- ✓ It Further passes between Sublingual Gland and Genioglossus to open in Floor of Mouth on summit of Sublingual Papilla at the side of Frenulum of Tongue
- ✓ Lingual nerve loop under duct and run anteriorly

Facial Nerve

- ✓ **Facial nerve enters temporal region -- Internal acoustic meatus**
- ✓ **Facial Nerve Enter Posterior cranial Fossa -- Stylomastoid foramen**
- ✓ **Facial nerve exits posterior cranial fossa -- Internal acoustic meatus**
- ✓ **Facial Nerve exits Skull -- Stylomastoid foramen**
- ✓ Facial Nerve give chorda tympani which carries anterior 2/3rd Tongue taste
- ✓ Facial Nerve **normally** causes **closing** of eye and **Damage** to Facial nerve result in **Opening** of Eye and Vice versa for 3rd Nerve

Tongue

- ✓ Anterior 2/3rd Tongue Lymph – Submandibular
- ✓ Posterior 1/3rd Tongue Lymph– Jugulo omohyoid.
- ✓ Tip of Tongue Lymph – Submental
- ✓ Anterior 2/3 general sensation – Lingual nerve
- ✓ Anterior 2/3 Taste sensation – Chorda tympani
- ✓ Posterior 1/3rd Taste sensation – Glossopharyngeal nerve
- ✓ Posterior most part Taste sensation – Vagus

Larynx Muscles

- ✓ After thyroidectomy Loose Vocal Cord muscle **involved** is - Vocalis and Thyroarytenoid
- ✓ After thyroidectomy Loose Vocal Cord muscle **damage** is -Cricothyroid
- ✓ After thyroidectomy Tense Vocal Cord muscle **involved** is -Cricothyroid
- ✓ After thyroidectomy Tense Vocal Cord muscle **damage** is -Voealis and Thyroarytcnoid

Note: Difference between Muscle involved and Muscle Damage

Actions	Muscle Involved
Abductor of Vocal cord or open Glottis	Posterior Cricoarytenoid
Adductor of Vocal cord or Close Glottis	Lateral Cricoarytenoids(main) Transverse Arytenoids(main) Thyroarytenoids Cricothyroid
Tense Vocal Cord	Cricothyroid
Relax Vocal Cord	Thyroarytenoid Vocalis
Open Larynx Inlet	Thyroepiglotticus
Close Larynx Inlet	Aryepigloticus Oblique Arytenoid

CamScanner

1) **Pain between eye and upper lip Nerve carrying this pain is**
A- Maxillary nerve
B- Ophthalmic nerve
C- Facial nerve
D- Mandibular nerve
Ans: A

2) **Nerve causing lacrimation while eating is**
A- Trochlear
B- Trigeminal nerve
C- Abducent nerve
D- Vagus
E- Facial
Ans: E (BD)

3) **A patient presents with acute painful swelling in front of his ear, O/E parotid gland is enlarged. which nerve is involved?**
A- Maxillary nerve.
B- Opthalmic nerve
C- Greater auricular nerve
D- Mandibular nerve
E- Facial nerve
Ans: C

4) **Parasympatbetic supply of parotid**
A- 7 Cranial nerve
B- 9 Cranial nerve
C- 5 Cranial nerve
D- 10 Cranial nerve
E- 2 Cranial nerve
Ans: B

Explanation:
- Facial nerve via chorda tympani to – Submandibular gland
- Glosopharyngeal via Greater petrosal to – Parotid gland

5) **Patient has lipoma on posterior aspect of SCM, 5 cm relation to sternoclavicular joint whicb structure ligated leading to profuse bleeding?**
A- External jugalr Vein
B- Internal jugular Vein
C- Common carotid artery
D- Vertebral artery
E- 2nd part of Subclavian
Ans: E

6) **Injury at foramen ovale will lead to**
A- Loss of sensation at lower face
B- Loss of sensation at upper face
C- Loss of sensation of forehead
D- Loss of bitter taste
Ans: A

Explanation:
Mandibular nerve pass through foramen ovale which supply lower face so foramen ovale injury cause loss of sensation of lower face

7) **Lady came in OPD she has hoarsness of voice and left vocal cord sluggishmovement due to which nerve damage?**
A- Left ELN
B- Left ILN
C- Left RLN
D- Vagus nerve
E- Glossopharyngeal nerve
Ans: C

8) **A patient complains of dryness of eyes& itching.O/E there was decreased secretion of lacrimal gland. The nerve carrying Postganglionic Fibers to Lacrimal gland**
A- Ophthalmic Nerve
B- Mandibular Nerve
C- Maxillary Nerve
D- Temoral Nerve
E- Facial Nerve
Ans: C

Explanation:
- Parasympathetic post ganglionic fibersfrom the pterygopalatine ganglioncarried via maxillary branch oftrigeminal to nasal and lacrimal gland.
- Greater Petrosal branch of Facial nerveis pre ganglionic parasympathetic tolacrimal gland.

9) **Facial nerve supply taste to anterior 2/3rd of tongue via chorda tympani Taste fibers are**
A- GVE
B- GSA
C- SVE
D- SVA
Ans: D

10) **Regarding Genral Visceral Efferent (GVE) true is**
A- Supply smoth muscle glands
B- Impulses Away from target organ
C- Toward target organ
D- Supply Pharynx
E- Supply Larynx
Ans: A

Explanation:
- GVE – Supply Smooth muscles and Glands
- SVE – Supply Pharynx

CamScanner

11) Tumor of pituitary gland spreads towhich hony structure?

A- Frontal
B- Maxillary
C- Orbital
D- Sphenoid
E- Temporal
Ans: D

Explanation:
- Pituitary tumor invade -sphenoid bone
- Compress cavernous sinus – Laterally
- Compress sphenoid air sinus – Inferiorly
- Compress optic chiasm – Superiorly
- Compress optic nerve – Anteriorly

12) Incisive foramen contains which ofthe following structure?

A- Maxillary Nerve
B- Mandibular Nerve
C- Nasopalatine Nerve
D- Cilliary Nerve
E- Opthalamic Nerve
Ans: C

Explanation:
- Foramen incisive – NasopalatineNerve
- Foramen Ovale – Accessory Meningeal artery pass
- Foramen Spinosum – Middle Meningeal artery pass

13) The primary function of the bones of the middle ear is to

A- Amplify the sound stimulus
B- Filter high-frequency sounds from the sound stimulus
C- Enable the direction of a sound stimulus to be detected
D- Enhance the ability to distinguish different sound frequencies
E- Protect the ear from damage
Ans: A

14) A patient while turning eyes toward left, has medial nystagmus.Nerve involved is which of the following?

A- Occulomotor
B- Trochlear
C- Abducent
D- Vagus nerve
E- Facial
Ans: C

15) A patient fainted during dental surgery, trendelenberg position was maintained and some irritant solution was Snored in order to stimulate some area in brain, which nerve carries that?

A- 9th CN
B- 11th CN
C- 5th CN
D- 12th CN
E- 6th CN
Ans: C

Explanation:
Irritant Solution Snored will stimulate trigeminal nerve which will increase cerebral blood flow and cause alertness

16) A patient complains of dryness ofeyes. O/E there was decreasedsecretion of lacrimal gland. The mostlikely ganglia involved are:

A- Ciliary ganglion
B- Optic ganglion
C- Pterygo palatine ganglion
D- Submandibular ganglion
E- Superior cervical ganglion
Ans: C

17) Which of following passes through foramen rotendum?

A- Mandibular nerve
B- Maxillary Division of trigeminal
C- Ophthalmic nerve
D- Lingual nerve
E- Accessory meningeal
Ans: B

Explanation:
- Foramen Ovale – Acessory Meningeal artery pass
- Foramen Spinosum – Middle Meningeal artery pass
- Superior Orbital Fissure – V1 (Opthalmic nerve) pass
- Foramen Rotandum – V2 (Maxillary Nerve) Pass
- Foramen Ovale – V3 (Mandibular Nerve) pass
- Jugular Foramen – CN 9, 10, 11 (Accessory part) & Sigmoid Sinus
- Hypoglossal Canal – CN 12
- Foramen Magnum – Brainstem & Spinal Part of CN 11

18) True about stenson's/parotid duct is:

A- Pierces buccinator muscle
B- Opens in oral cavity against upper 2nd premolar
C- Arises from post surface of parotid
D- In duct of submandibular gland
Ans: A

19) Salivary secretion is by which of the following?

A- Lingual nerve
B- Maxillary nerve
C- Facial nerve
D- Mandibular nerve
E- Chorda tympani
Ans: C

CamScanner

20) **Hearing improves in noisyenvironment in which of the followingcondition**
A- Menicre's Disease
B- Otosclerosis
C- Tympanic membrane damage
D- Ossicular damage
E- Cochlear damage
Ans: B

21) **Angular artery is a branch of:**
A- Facial
B- Superficial temporal
C- Great auricular
D- Maxillary
Ans: A

22) **A blow on right eye near to medial nasal bridge leads to fracture of:**
A- Orbital plate of frontal
B- Glabella
C- Frontal process of maxilla
D- Sup cilliary arch
Ans: A

23) **A lady presented with diploipa and suddenly fell down can't reach to phone due to damage to which artery?**
A- Anterior cerebral artery
B- Anterior choroidal artery
C- Middle cerebral artery
D- Posterior cerebral artery
E- Middle meningeal artery
Ans: A

24) **A boy was talking in classroom teacher got irritated and askedhim to lower pitch of voice muscleresponsible is which of following?**
A- Vocalis
B- Cricothyroid
C- Thyroarytenoid
D- Post cricoarytenoid
E- Lateral cricoarytenoid
Ans: C

25) **Internal carotid artery is blocked on color doppler.Blood flowback through which artery to supply scalp?**
A- Supra orbital artery
B- Superficial temporal artery
C- Post Auricular artery
D- Occipital artery
Ans: A

26) **Which nerve passes through petro tympanic fissure?**
A- Greater petrosal
B- Lesser petrosal
C- Chorda tympani
D- Deep petrosal
E- Maxillary artery
Ans: C

27) **Geniohyoid function is:**
A- Depress Hyoid
B- Eleveatc mandible
C- Elevate Hyoid
D- Rotate Hyoid
Ans: C

28) **Patient has broad nose, syndactyly and exophthalmos with cleft palate and Dished in face appearance.What is the diagnosis?**
A- Eisenmenger syndrome
B- Down syndrome
C- Turner syndrome
D- Apert syndrome
E- Digeorge syndrome
Ans: D

29) **Which muscle damage results in vocal cord adducted position?**
A- Vocalis
B- Thyroarytenoid
C- Posterior cricoarytenoid
D- Oblique arytenoid
Ans: C

Explanation:
- Posterior cricoarytenoid is abductor of vocal cord its damage will enhance function of adductors result in adducted position.

30) **Inspiration is vital process for oxygenation of tissues. Forceful inspiration occurs via active contraction of which muscle?**
A- SCM
B- Scalene anterior and pectoralis minor
C- Diaphragm
D- External oblique
E- Abdominal muscles
Ans: B>A

Explanation:
- **Muscle of quite inspiration** – Diaphram and external intercostal
- **Muscle of forced inspiration** – SCM & serratous anterior, scalenus anterior & medius and pect minor.
- **Quite expiration** – Passive and by elastic recoil of lung
- **Muscle of forced expiration** – Internal intercostal
- **Accessory muscle of expiration** – Abdominal muscles (External oblique, rectus abdominis)

31) **The Massetar muscle is supplied by:**
A- Facial nerve
B- Mandibular branch of trigeminal nerve.
C- Maxillary nerve
D- Inferior alveolar nerve
E- Occulomotor nerve
Ans: B

CamScanner

32) **Parathyroid glands are 4 in number. 2 are superior parathyriods glands and 2 are inferior parathyroid gland attach to the posterior part of thyroid gland the blood supply to these 4 glands by?**

A- 2 superior parathyroid gland are supplied by superior thyroid artery and 2 inferior parathyroid gland inferior thyroid arteries
B- All four glands are supplied by superior thyroid artery.
C- All four glands are supplied by inferior thyroid artery.
D- Superior parathyroid glands are supplied by superior thyroid artery and inferior parathyroid gland is supplied Internal laryngeal artery

Ans: C(Grey's and KLM)

Explanation:

- Both Superior and inferior parathyroid glands supplied usually by inferior thyroid arteries. Superior gland may be supplied by Superior thyroid artery but main supply for both is Inferior thyroid arteries

33) **Aggregation of lymphoid tissue covered by stratified squamous epithelium is:**

A- Thymus
B- Spleen
C- Palatine tonsils
D- Lymph node
E- Pharyngeal tonsils

Ans: C

Explanation:

- Lymphoid Tissue and Simple Cuboidal Epithelium – Payer patches Lymphoid Tissue and Stratified Squamous Epithelium – Palatine Tonsil

34) **Parallel light rays focusing infront of retina is called:**

A- Myopia
B- Presbyopia
C- Hypermetropia
D- Cataract
E- Retinal detachment

Ans: A

35) **Contraindication to local anesthesia in eye procedures:**

A- Retinal detachment
B- Penetrating injury to eye
C- Procedures less than 60 minutes
D- Glaucoma

Ans: B

36) **Characteristic lesion of hereditary telengectasia is found on:**

A- Palate
B- Lips
C- Gingiva
D- Nose
E- Tongue

Ans: B

37) **72 year old patient has lost general sensation on the anterior 2/3rd of the tongue due to injury to which nerve?**

A- Facial
B- Glossophgel
C- Maxilry
D- Trigeminal
E- Lingual

Ans: E

Explanation:

- Anterior 2/3 general sensation –Lingual nerve
- Anterior 2/3 Taste sensation – Chordatympani
- Posterior 1/3rd Taste sensation – Glossopharyngeal nerve
- Posterior most part taste sensation –Vagus

38) **A patient after fracture of base of skull presented with loss of taste, nasuea and vomiting due to damage of:**

A- Hypoglossal canal
B- Mastoid
C- Jugular foramen
D- Foramen Magnum

Ans: C

Explanation:

Sign and symptoms of 9-11 nerves which are present in Jugular foramen.

39) **A Patient with abscess in posterior triangle of neck which was operated nowpatient can't comb her hair where is lesion?**

A- Radial nerve
B- Axillary nerve
C- Spinal accessory nerve
D- Median nerve
E- Dorsal thoracic nerve

Ans: C

40) **A patient with temporomandibular dislocation has paralysis of which of following muscle?**

A- Medial pterygoid
B- Lateral Pterygoid
C- Buccinator
D- Masseter
E- Temporalis

Ans: B

41) **A surgeon performs submandibular gland surgery. How the lingual nerve can be saved?**

A- Lifting deep cervical fascia
B- Tracing lingual nerve
C- Lifitng fascia and vessels
D- Lifting Facial nerve

Ans: B

CamScanner

42) Retinoblastoma extra ocular spread is by:
A- Optic nerve
B- Infeiorly into maxillary sinus
C- Medially to ethmoid sinues
D- Erode squamous temporal bone
E- Erode Sphenoid bone
Ans: A

43) Submandibular gland is divided into deep and superficial part by which of the following muscle?
A- Omohyoid
B- Mylohyoid
C- Sternthyroid
D- Anterior and posterior belly of diagastric
E- Genohyoid
Ans: B

44) Which of following is absent in first vertebra?
A- Odontoid process
B- Spinous process
C- Lumen
D- Arch
Ans: B

45) A patient was operated for abscessesin posterior triangle of neck, nowcannot raise her arm overhead, whichnerve is damaged:
A- Vagus Nerve
B- Spinal part of Accessory nerve
C- Cervical plexus
D- Axillary Nerve
E- Dorsal thoracic
Ans: B
Explanation:
- Overhead abduction is caused byTrapezius & Serratus anterior muscles. Here as abscess is drained in posterior triangle of neck that's where spinal part of accessory nerve is at risk of damage

46) A patient has hoarseness of voice and a mass on base of the skull which nerve is involved
A- Auditory
B- Vestibulocochlear
C- Vagus
D- Glosopharyngeal
E- Accessory
Ans: C

47) A patient has inflamed parotid gland with pain in temporal region and left half of face which is due to?
A- Auricotemporal nerve
B- Facial nerve damage
C- Stretch of fibrous capsule
D- Maxillary nerve
E- Greater Auricular nerve
Ans: C
Explanation:
- Pain of parotiditis is due to Tense capsule
- And it is transmitted by Greater auricular nerve (RJ last +Grey's)

48) Vocal cord Glotiss is closed by which of following?
A- Posterior Cricoarytenoid
B- Lateral Cricoarytenoid
C- Cricothyroid
D- Vocalis
E- Oblique arytenoid
Ans: B

Abductor of Vocal cord or open Glottis	Posterior Cricoarytenoid
Adductor of Vocal cord or Close Glottis	Lateral Cricoarytenoids(main) Transverse Arytenoids(main) Thyroarytenoids Cricothyroid
Tense Vocal Cord	Cricothyroid
Relax Vocal Cord	Thyroarytenoid Vocalis
Open Larynx Inlet	Thyroepiglotticus
Close Larynx Inlet	Aryepigloticus Oblique Arytenoid

49) In determining age of individual with the help of mandible, features suggesting old age are:
A- Mental foramen lies near lower border of body of mandible
B- Mental foramen lies near upper border of body of mandible
C- Mental foramen lies near middle part of body of mandible
D- Obtuse angle
Ans: B (Parikh)

50) Suboccipital nerve supplies which of the following muscle?
A- Capitis
B- Latissimus dorsi
C- Rectus Capitis Posterior
D- Trapezius
E- Serratus anterior
Ans: C

CamScanner

51) spiration of vomiting by lady during seizure can be prevented by:
A- Closure of true vocal cord
B- Closure of false vocal cord
C- Larynx moving upward
D- Backward movement of tongue
E- Compressing of epiglottis
Ans: B

52) **Which of the following structures provide maximum stability to the temporomandibular joint and keeps the condyle of mandible in the fossa?**
A- Temporomandibular ligament
B- Sphenomandibular ligament
C- Capsule of the joint
D- Muscles of mastication
Ans: A

53) **Sound is best perceived at which area?**
A- Cochlear nucleus
B- Superior temporal gyrus
C- Spiral ganglion
D- Lateral geniculate body
E- Trapezoid Body
Ans: A

54) **Function of nose at alveolar level:**
A- Humidification and air conditioning
B- Filteration
C- Absorption
D- Mucus production
Ans: A

55) **Patient with anterior 2/3rd tongue carcinoma.What is the lymphatic drainage?**
A- Juguloomohyoid
B- Digastric
C- Submandibular
D- Submental
Ans: C

Explanation:
- Anterior 2/3rd Tongue –Submandibular
- Posterior 1/3rd Tongue – Jugulo omohyoid.
- Tip of Tongue – Submental

56) **A child previously having TB comes to you with the complain of fever and cough along with noisy breathing and difficulty in swallowing, now diagnosed as Retropharyngeal Abcess,which structure it will invade first?**
A- Pre cervical fascia
B- Prevertebral fascia
C- Carotid sheath
D- Buccopharyngeal fascia
Ans: B

57) **Middle cranial fossa is formed from:**
A- Lesser wing of solenoid
B- Greater wing of sphenoid
C- Temporal bone
D- Petrous part of temporal bone
Ans: B

58) **Bells phenomenon:**
A- Downward gaze
B- Upward gaze
C- Eyeball moves Upward and outward when closing eye forcefully
D- Eyeball moved Upward and outward when opening the eyes
Ans: C

59) **Man moving down in elevator.Linear vertical acceleration is detected by:**
A- Semicircular canals
B- Utricle
C- Saccule
D- Cochlea
Ans: C

Explanation:
- Linear – Utricle
- Vertical – Saccule
- Angular- Semicircular Canal

60) **Mechanism of action of sternocleiodomastoid muscle?**
A- Extemsion of head
B- Flexion of head
C- Rotate the head on opposite sides
D- Rotate the neck on same side
Ans: C

61) **The muscle which is use as landmark of CVP?**
A- Trapezius
B- Platysma
C- Stemocleidomastoid
D- Digastric
Ans: C

Explanation:
SCM > serratus anterior

62) **Lateral rectus palsy .Nerve affected is:**
A- Occulomotor Nerve
B- Abducent Nerve
C- Trigeminal Nerve
D- Facial Nerve
Ans: B

Explanation:
- Superior Oblique – 4th Nerve
- Lateral Rectus – 6th Nerve
- Other eye muscles – 3rd Nerve

63) **Infarction of pituitary gland will occur with the involvement of which artery?**
A- Anterior Cerebral Artery
B- Posterior Cerebral Artery
C- Posterior superior cerebellar artery
D- Internal carotid Artery
Ans: D

CamScanner

64) **Person was having difficulty in identifying colors while making an assignment. Doctor told that he has a problem in**
A- Rods
B- Cones
C- Vitreous body
D- None
Ans: B

65) **Biopsy of posterior triangle of neck will damage which of the following?**
A- Long thoracic nerve
B- Spinal accessory nerve
C- Internal Jugular Vein
D- None of the above
Ans: B

66) **Most superficial structure in parotid:**
A- External carotid artery
B- Retromandibular vein
C- Maxillary arter
D- Post auricular artery
E- Facial nerve
Ans: E

67) **Posterolateral relation to thyroid:**
A- Parathyroid gland
B- Carotid sheath
C- Trachea
D- Sternohyoid Muscle
Ans: B
Explanation:
- Anterolateral – Sternohyoid, Sternothyroid and SCM
- Posterolateral – Carotid sheath
- Medially -RLN, Larynx, Pharynx and Trachea
- Posteriorly – Parathyroid Glands

68) **Posterior relation of thyroid:**
A- Parathyroid gland
B- Carotid sheath
C- Trachea
D- Sternohyoid Muscle
Ans: A
Explanation:
- Anterolateral – Sternohyoid, Sternothyroid and SCM
- Posterolateral – Carotid sheath
- Medially – RLN, Larynx, Pharynx and Trachea
- Posteriorly – Parathyroid Glands

69) **Ligament injured in hyperflexion of neck is:.**
A- Posterior longitudinal ligament
B- Anterior longitudinal ligament
C- Ligamentum Nuche
D- Atlantoaxial
Ans: C
Explanation:
- Ligament injured in hyper flexion of Neck – Ligament nuche
- Ligament injured in Hyperextension of Neck – Anterior longitudinal ligament

70) **Mental nerve exits from:**
A- Foramen ovale
B- Foramen rotendum
C- Orbital fissure
D- Mental foramen
Ans: D

71) **Except rods and cones,Blood supply of the retina is:**
A- Long ciliary artery
B- Short ciliary artery
C- Central retinal artery
D- Peripheral rentinal artery
Ans: C
Explanation:
- Rods and cones and outer layers:Choridal artery
- Rest Retina:Central retinal artery

72) **Brachiocephalic vein is formed by**
A- Left subclavian vein
B- Left internal jugular vein
C- Junction of left subclavian and left internal jugular vein
D- Junction of left subclavian and left external jugular vein
Ans: C

73) **Which of the following muscle is supplied by ansa cervicalis?**
A- Geniohyoid
B- Omohyoid
C- Stylohyoid
D- Mylohyoid
Ans: B(Snell)
Explanation:
The following mentioned muscles are supplied by Ansa Cervicalis "Sternohyoid, Sternothyroid & Omohyoid"

74) **Regarding parotid gland,Which of the following is correct:**
A- Duct Pierces Masseter Muscle
B- Duct Opens behind the 2nd lower molar teeth
C- Pure Serous Acini
D- Derived from Mesoderm
Ans: C
Explanation:
Parotid gland is purely serous while mandibular gland is mixed & sublingual gland is purely mucinous.

CamScanner

75) **Posterior Cranial Fossa relation:**
A- Separate Cerebrum from Cerebellum
B- Separate Pons from Medulla
C- Basilar Artery Anterior to Pons
D- Basilar Artery Posterior to Pons
Ans: C

76) **Which of the following nerve damaged bilaterally leads to death?**
A- Trigeminal
B- Facial
C- Vagus
D- Sympathetic Trunk
Ans: C

77) **Immediate relation of IJV after its exit from jugular foramen:**
A- Internal Carotid artery
B- Spinal part of Accessory Nerve
C- Vagus Nerve
D- Facial Nerve
Ans: A

Explanation:
- IJV after Coming out of Jugular foramen relation –ICA
- IJV With in jugular foramen relation – Accessory Nerve

78) **Hyperextension of neck will lead to:**
A- Lower motor neuron lesion of Upper limb
B- Upper motor Neuron lesion of Upper Limb
C- Lower motor neuron lesion of Lower limb
D- Loss of Tactile stimulus lower limb
Ans: A

79) **Melanoma invades orbital cavity through:**
A- Sclera
B- Optic Nerve
C- Emissary Vein
D- Retina
E- Lymphatic
Ans: C

Explanation:
Uveal malignant melanoma is the most Common primary intraocular tumour of adulthood & orbital extension probably occurs through the emissary vein.

80) **Nerve passing through foramen magnum:**
A- Spinal Part of Accessory nerve
B- Occulomotor Nerve
C- Trochlear Nerve
D- Trigeminal Nerve
Ans: A

81) **HSV most commonly affects which of the following nerve?**
A- Facial nerve
B- Abducent nerve
C- Trigeminal nerve
D- Trochlear nerve
Ans: C

Explanation:
Herpes simplex virus (HSV) most commonly effect Trigeminal Nerve& leads to Trigeminal Neuralgia

82) **A child can't close his lips due to damage to:**
A- Orbicularis Oculi
B- Orbicularis Oris
C- Levator Palpebrae
D- Masseter
Ans: B

83) **Slow growing tumour of Parotid:**
A- Warthin's tumour
B- Basal Cell Carcinoma
C- Squamous Cell Carcinoma
D- Pleomorphic Adenoma
Ans: D

84) **In Head trauma,breathing pattern is**
A- Kussmaul Breathing
B- Cheyne-Stokes Breathing
C- Biot's Respiration
D- Periodic Breathing
Ans: B

Explanation:
- Cheyne-Stokes breathing is commonly seen after stroke & head trauma
- Kussmaul Breathing pattern is seen DKA & Uremia

85) **Which of the following is higher in tears as compared to plasma?**
A- Amino Acids
B- Sodium
C- Potassium
D- Bicarbonate
Ans: A

- Tear Compare to plasma Has **Equal Sodium**
- Tear Compare to plasma has **LowGlucose and Urea**
- Tear Compare to plasma has **MoreK, Cl, Ca & Amino acids**

86) **A boxer hit on chin will lead to:**
A- Loss of sensation of upper teeth
B- Loss of sensation of lower teeth
C- Loss of sensation of neck dermatome
D- Loss of function of platysma
Ans: B

CamScanner

87) **Most common tumor is of which of the following Salivary Glands:**

A- Parotid Gland
B- Sublingual Gland
C- Submandibular Gland
D- Mixed
Ans: A

Explanation:

- Most common Salivary gland tumor is pleomorphic adenoma of Parotid gland
- Most common malignant tumor of salivary gland is mucoepidermoid carcinoma.

88) **Medial canthal ligament attachments:**

A- Ethmoid & Frontal bones
B- Lacrimal Bone & Frontal process of Maxilla
C- Sphenoid Bone
D- Mandible
Ans: B

89) **Structure preventing damage from rotatory movement of head:**

A- Falx cerebri
B- Tentorium cerebelli
C- Vessels
D- Sinus
Ans: A

90) **Which of the following movements take place at Atlanto - Axial joint:**

A- Flexion
B- Extension
C- Abduction
D- Adduction
E- Rotation
Ans: E

Explanation:

- Rotation that's "No" takes place at atlanto-axial joint.
- Flexion that's "Yes" takes place at atlanto-occipital joint

91) **Fascial spaces are filled with:**

A- Connective tissues
B- Vessels and nerves
C- Adipose tissues
D- Capillaries
Ans: A

Explanation:

The spaces filled with loose areolar connective tissue may also be called clefts that contains nerves and blood vessels.

92) **Most common location of carcinoma of tongue is:**

A- Dorsum of tongue
B- Ventral surface of tongue
C- Tip of tongue
D- Lateral surface of tongue
Ans: D

93) **A boy presented in ER with history of blow to the orbit, on examination the duty doctor felt pulsations at the floor of the orbital cavity, which of the following could be thr possiblecause of these pulsations:**

A- Cavernous sinus+ internal carotid artery
B- Cavernous sinus + external carotid artery
C- Maxillary artery
D- Facial artery
Ans: A

94) **Sub-dural hemorrhage is caused by the rupture of which of the followings:**

A- Berry aneurysm
B- Middle cerebral vein
C- Superior cerebral vein
D- Middle meningeal artey
Ans: C

Explanation:

- Bridging veins > Superior cerebral vein in case of Subdural hematoma.
- Middle meningeal artery in case of Epi dural hematoma.

95) **Bitemporal Hemianopsia is due to damage to:**

A- Optic Nerve
B- Optic Radiation
C- Optic Chiasma
D- Occipital Cortex
Ans: C

96) **Lesion to Right optic radiation lateral fibers in temporal lobe will lead to**

A- Right Superior quadrantanopia
B- Right Inferior quadrantanopia
C- Left Superior quadrantanopia
D- Left inferior quadrantanopia
Ans: C

Explanation:

- Lesion to Right temporal optic fibers leads to left superior quadrantanopia.
- Lesion to Right parietal optic fibers leads to left inferior quadrantanopia.

97) **Which of the following muscles of mastication helps in deep inspiration during yawning& increase cardiac output?**

A- Lateral pterygoid muscle
B- Medial pterygoid muscle
C- Masseter
D- Buccinator
E- Supinator
Ans: A

98) **The outer most layer of retina consist of:**

A- Rods & Cones bodies
B- Rods & Cones Process
C- Pigmented Epithelial Cells
D- Choroid
Ans: C

CamScanner

Explanation:
The outer most layer of retina consists of Pigmented epithelium followed by photoreceptors layers consisting of Rods & Cones.

99) Damage to glossopharyngeal nerve leads to loss of which of the following taste sensation?
A- Sweet
B- Salt
C- Bitter
D- Sour
Ans: C

Explanation:
Glossopharyngeal nerve takes taste & general sensation from posterior 1/3rd of the tongue that's related with transmission of bitter taste sensation.

100) S2 – S4 at the level of:
A- L1 – 2
B- S1 – 2
C- S3 - 4
D- L4 – 5
Ans: A

101) Which of the following muscle protrudes the mandible?
A- Medial Pterygoid
B- Lateral Pterygoid
C- Masseter
D- Buccinator
Ans: B

102) Maxillary artery supplies which of the following aortic arch?
A- 1st
B- 2nd
C- 3rd
D- 4th
Ans: A

Explanation:
- Maxillary artery is the branch of 1st arch (Mandibular Arch).
- The ventral end of the second develops into the ascending pharyngeal artery & its dorsal end gives origin to stapedial artery.
- The third arch gives raise to the proximal end of internal carotid artery.
- The fourth arch forms the right subclavian artery.
- The fifth arch regresses.
- The sixth arch persists as proximal portion of right pulmonary artery.

103) Which of the following nerve supplies skin over the parotid region?
A- Greater Auricular Nerve
B- Auriculotemporal Nerve
C- Greater Occipital Nerve
D- Lesser Occipital Nerve
Ans: A

Explanation:
The greater auricular nerve supplies the fascia superficial and deep to parotid gland and transmits the pain caused by stretching of the fascial envelope when acute enlargement of the gland occurs as in mumps.

104) Which of the following is muscle of mastication & attached to mid mandible?
A- Masseter
B- Mentalis
C- Temporalis
D- Buccinator
Ans: A

Explanation:
The masseter muscle providespowerful elevation & protrusion of the mandible by originating from the zygomatic arch & inserting along the angle and lateral surface of the mandible.

105) Pneumatic bones mainly found in:
A- Face
B- Skull
C- Neck
D- Upper Limb
Ans: A

106) Middle ear medial and posterior wall supplied by:
A- Vagus nerve
B- Facial nerve
C- Trigeminal nerve
D- Abducent nerve
Ans: B

107) Taste sensation from posterior one third of tongue is carried via:
A- Hypoglossal nerve (CN XII)
B- Glossopharyngeal nerve (CN IX)
C- Facial nerve (CN VII)
D- Vagus nerve (CN X)
Ans: B

Explanation:
- Taste sensation from Anterior 2/3rd is carried via facial nerve
- Taste sensation from posterior 1/3rd is carried via Glossopharyngeal nerve.

108) Which of the following is related to anterior surface of SCM:
A- Internal Jugular Vein
B- External Jugular Vein
C- Brachiocephalic Vein
D- SVC
Ans: B

CamScanner

109) **Mandibular bridge is:**
A- Angle of Mandible
B- Root of Mandible
C- Condyle of mandible
D- Coronoid process of mandible
Ans: A

110) **Sensory supply of Temporal/parietal area of scalp:**
A- Supraorbital nerve
B- Supratrochlearnerve
C- Auriculotemporal nerve
D- Greater Auricular nerve
Ans: C

111) **SCM muscle is supplied by which of the following nerve?**
A- Vagus
B- Accessory
C- Hypoglossal
D- Glossopharyngeal
Ans: B

112) **Prevention of excessive medial and lateral movements at TMJ:**
A- Sphenomandibular ligament
B- Stylomandibular ligament
C- Collateral ligament
D- Anterior ligament
Ans: C

113) **Carcinoma of the tongue most commonly occurs at:**
A- Lateral border of anterior 2/3rd
B- Lateral border of posterior 1/3rd
C- Tip
D- Dorsum
Ans: A

114) **A pulsating eye involves:**
A- External jagular vein
B- Internal carotid artery and cavernous sinus fistula
C- External carotid artery and cavernous sinus fistula
D- Cavernous sinus fistula
Ans: B

115) **A patient with right carotid endartectomy presents with dizziness on vigorous right arm movements and diagnosed as emboli in subclavian, Which artery is involved?**
A- Vertebral
B- Carotid
C- Jagular
D- Middle meningeal
E- Anterior communicating
Ans: A

116) **Nerve supply to the skin below the orbit of the eyes and above mouth:**
A- Mandibular nerve
B- Facial nerve
C- Maxillary nerve
D- Zygomatic nerve
Ans: C

117) **Which of the following structures do the cervical vertebrae lack?**
A- Posterior horn
B- Anterior horn
C- Lateral horn
D- White matter
E- Grey matter
Ans: C

118) **Stab wound to the posterior triangle of the neck most likely causes damage to which muscle?**
A- Scalene
B- Trapezius
C- Serratus posterior inferior
D- Subscapularis
Ans: B

119) **An injury to the foramen ovale in skull would result in:**
A- Paralysis of muscles of mastication
B- Loss of accommodation reflex
C- Loss of sensation over zygoma
D- Loss of forehead sensations
Ans: A

120) **Parasympathetic supply to submandibular salivary gland is from:**
A- Superior salivary nucleus
B- Inferior salivary nucleus
C- Auriculotemporal nerve
D- Lesser petrosal nerve
Ans: A

121) **Which structure is transmitted via foramen cecum?**
A- Ophthalmic vein
B- Ophthalmic artery
C- Emissary Vein
D- Olfactory nerve
Ans: C

122) **A damaged occurred to the foramen ovale and as a result the structures passing through it have suffered lesion too, what will be the presentation of the patient?**
A- Upper face affected
B- Lower third of face affected
C- Face and upper limbs affected
D- Loss of sensation over orbital cavity
Ans: B

CamScanner

123) The salivary secretions from parotid gland are controlled by the following nerve:
A- Facial nerve
B- Auriculotemporal nerve
C- Hypoglossal nerve
D- Glossopharyngeal nerve
Ans: D

124) Which of the following nerve lesion due to DM results in vision problems?
A- Occulomotor
B- Abducens
C- Trochlear
D- Optic
Ans: A

125) A histological slide of a tissue taken from the oral cavity is viewed under the electron microscope and the substance shows connective tissue acini and ducts, which structure is it?
A- Salivary gland
B- Pharyngeal tonsils
C- Palatine tonsils
D- Enamel
Ans: A

126) A patient presented to the emergency room with injury to scalene anterior muscle and 1st cervical rib. The radial pulse is feeble on examination. The damage is to which blood vessel:
A- Aorta
B- IVC
C- SVC
D- Internal Jagular Vein
E- Subclavian
Ans: E

127) Which of the following anatomical structures is present anteriorly to the trachea?
A- Phrenic nerve
B- Recurrent Laryngeal nerve
C- Internal Jagular vein
D- Arch of aorta
E- Vagus nerve
Ans: D

128) Which is the correct relation to Pituitary gland?
A- Anteriorly, sphenoidal (paranasal sinus) is present
B- Abducent nerve is present medially to pituitary gland
C- Laterally, it has relation of cavernous sinus
D- Oculomotor nerve is present anteriorly
Ans: C

129) Which of the following muscles ma the neck?
A- Scalene posterior
B- Serratus Anterior
C- Trapezius
D- Scalene Anterior
Ans: D

130) Taste sensations from the anterior pa of the tongue are carried by:
A- Facial nerve
B- Glossopharyngeal nerve
C- Hypoglossal nerve
D- Lingual nerve
Ans: A

131) Which of the following structures similar in adult and a child?
A- Inner ear
B- Outer ear
C- Nose
D- Mouth
Ans: A

132) A post adrenalectomy patient died days after the surgery, Whatis the mo likely cause:
A- Deficiency of Norepinephrine
B- Deficiency of Aldosterone
C- Deficiency of testosterone
D- Deficiency of ACTH
E- Deficiency of Cortisol
Ans: B

Explanation:
Aldosterone is extremely important for life &it deficiency is the leading cause toward death in pe adrenalectomy patient if not treated.

133) German measles causes whic abnormality:
A- Congential cataract
B- Congential deafness
C- Cardiac abnormality
D- Limb defect
Ans: B

Explanation:
- Rubella in pregnancy complication overa – **Deafness > Cataract**
- Rubella in pregnancy complication Withi **7 weeks – Cataract**
- Rubella in pregnancy complication Afte **7 weeks – Deafness**

134) Lesion near the orbit of the eye.U histopathology, langhans giant cells:
A- Tb Leprae
B- Tuberculosis
C- Staph Aureus
D- Hemophilus
Ans: A

CamScanner

Explanation:
Lesion on skin & that too on face with granulomatous findings is most likely Tb leprac.

135) External Ear blood supply:
A- Anterior Auricular Artery
B- Posterior Auricular Artery
C- Accesory artery
D- Left Opthalmic Artery
Ans: B

136) Which ligament keeps vertebral bodies in place?
A. Ligamentum flavum
B. Transverse ligament
C. Interspinous ligament
D. Anterior and posterior longitudinal ligament
Ans: D

Explanation
- Vertebral Bodies **Limited by – Anterior an posterior Longitudinal Ligament**
- Vertebral Bodies kept in **position** by – **Anterior an posterior Longitudinal Ligament**
- Vertebrae **joined** to Adjacent **Lamina – Ligament Flavum**

137) Patient presented with nausea, vomiting, nystagmus, tinnitus and inability to walk unless he concentrates well on a target object. His cerebeller function is intact, Whatis the diagnosis?
A. Benign positional vertigo
B. Meniere's disease
C. Vestibular neuritis
D. Otosclerosis
Ans: B

138) Lacrimal glands are supplied by which of the following?
A. Trigeminal nerve
B. Facial Nerve
C. Glossopharyngeal
D. Vagus
Ans: B

139) Stenson's duct anatomical location is :
A- Inside buccal membrane
B- Lateral to Ramus of Mandible
C- Between superficial and deep parotid gland
D- Auriclar border
E- Runs below masseter
Ans: A

Explanation:
- Parotid duct or stenson's duct is 5cm long and arises from anterior part of parotid gland,runs over masseter a finger's breadth below the zygomatic arch to pierce the buccinators and open opposite the second upper molar tooth.
- Between superficial and deep parotid gland Facial Nerve is present not Parotid Duct.
- Submandibular Gland=Wharton's Duct – Opens in Floor of Mouth
- Sublingual=Duct of rivinous- Multiple small Ducts.

140) Patient oral surgery done and mandibular nerve damaged.Its place of origin:
A. Under Incisor teeth
B. Under Premolar teeth
C. Under canine teeth a little below
D Upper teeth
Ans: C

141) Child was Playing game and injured eye orbit now he is having vertical diplopia and Proptosis. Which area of orbit has been damage?
A. Carotid cavernous fistula
B. Floor damage
C. Roof damage
D. Retro optic Hemorrhage
Ans. C

Explanation:
- **Proptosis** – Roof Damage
- **Enopthalmos-Floor** Damage due to herniation of Orbital contents into maxillary antrumm

142) Loss of taste sensation of anterior 2/3rd of tongue due to:
A. Chorda tympani nerve
B. Facial nerve
C. Lingual nerve
D. Trigeminal Nerve
Ans: A

Explanation
- SVA - Chorda Tympani
- GSA-Lingual Nerve

143) Posterior triangle divided by:
A. Ant. Belly of digastric
B. Sup. Belly of omohyoid
C. Inf. belly of omohyoid
D. Post. Belly of digastric
E. Ant. Border of sternocleidomastoid
Ans: C

144) Facial muscle nerve supply:
A. Facial
B. Mandibular
C. Facial and mandibular
D. Buccal nerve
Ans: C

CamScanner

145) Petrous part of temporal related to
A. Forms base of middle cranial fossa
B. Medial to Apex
C. Anterior
D. Posterior
E. Known as normal basalis
Ans: A

146) Medial palpebral ligament (Medial canthal ligament) attachment?
A- Anterior & Posterior lacrimal ridges
B- Frontonasal
C- Anterior lacrimal ridge
D- Posterior lacrimal ridge
Ans: A

147) Which structure lies posterior to arch of aorta?
A- Left phrenic nerve
B- Right phrenic nerve
C- SVC
D- Brachiocephalic vein
E- Left recurrent laryngeal nerve
Ans: E

148) Women developed painless gradual protrusion of one eye with normal X-Ray.Cause is?
A- Orbital vessel aneurysm
B- Optic nerve glioma
C- Thyroid ophthalmology
D- Meningioma
Ans: B

149) Regarding Scalenus anterior:
A- Phrenic nerve passes anterior to it.
B- Subclavian vein passes behind it
C- Attached to outer border of 1strib
D- Arises from C3 to C6 vertebral bodies
Ans: A

150) Loss of sensation in lower teeth, chin and lower lip.Nerve involved will be:
A. Inferior Alveolar nerve
B. Madibular nerve
C. Superior alveolar nerve
D. Maxillary nerve
Ans: A

151) Retromandibular vein is formed by junction of Maxillary vein and
A- Facial vein
B- Lingual vein
C- Maxillary vein
D- Superficial temporal vein
E- Transverse Facial
Ans: D

152) Masseteric fascia derived from:
A- Carotid sheath
B- Pretracheal fascia
C- Prevertebral fascia
D- Superficial layer of Deep cervical fascia
E- Buccopharyngeal fascia
Ans: D

153) Most common cause of global blindness:
A- Bacterial infection
B- Viral infection
C- Chlamydial infection
D- Glucoma
Ans: C

Explanation
- Global Blindness – **Cataract Chlymydia > Glucoma**

154). Patient with tic doloreaux (Trigemina neuraglia), analgesia given to bloc trigeminal ganglion at which site?
A- Middle cranial fossa
B- Posterior cranial fossa
C- Anterior cranial fossa
D- Infratemporal fossa
E- Pterygopalatine fossa
Ans: E

155) Regarding skull of child:
A- Anterior fontanelle present between bones
B- Posterior fontanelle closes at 3 months
C- Vault is bigger than the face
D- None
Ans: C

156) infratemporal fossa also known as:
A- Parapharyngeal fossa
B- Tonsillar fossa
C- Suprasternal
D- Submesenteric
Ans: A

157) Tumor with nerve sheet involvement:
A. Carcinoma ex-plemorphic adenoma
B. Mucoepidermoid tumor
C. Hemangiopericytoma
D Basal Cell Carcinoma
Ans: A

158) Ligamentum flavum connects:
A- Lamina
B- Body
C- Spines
D- All of the above
Ans: A

Explanation
- Vertebrae Bodies **Limited** by – **Anterior an posterior Longitudinal Ligament**
- Vertebral Bodies kept in position by – **Anterior an posterior Longitudinal Ligament**
- Vertebrae **joined** to Adjacent **Lamina – Ligament Flavum**

CamScanner

159) **Bifurcation of common carotid artery:**
A- At level of cricoid
B- Superior border of thyroid cartilage
C- Jugular notch
D- Inferior border of thyroid cartilage
Ans: B

160) **Corneal reflex by:**
A- Opthalmic division of trigeminal Nerve
B- Occulomotor Nerve
C- Optic Nerve
D- Trochlear nerve
Ans: A

161) **Which structure arches over aorta?**
A- Left Recurrent Laryngeal Nerve
B- Left bronchus
C- Left phrenic nerve
D- Right reccurent laryngeal nerve
Ans: A

162) **Recurrent laryngeal nerve curves around:**
A- Subclavian vein
B- Ligamentum arteriosum
C- Subclavian artery
D- Arch of Aorta
Ans: B

163) **Structure lateral to Internal carotid artery:**
A- Jugular vein
B- Sternum
C- SCM
D- Axillary nerve
Ans: A

164) **Internal carotid artery in relation to external carotid artery at its origin from common carotid artery lies:**
A- Lateral
B- Anterolateral
C- Medial
D- Anteromedial
E- Posterior
Ans: A

165) **External carotid artery differs from internal carotid artery:**
A- As it gives branches in neck
B- No branches in neck
C- More pulsatile
D- Deep in neck
Ans: A

166) **Injury to face due to some sort of trauma,Parient is unable to close eyes and angle of mouth is deviated.Nerve damaged is:**
A- Facial
B- Trigerminal
C- Occulomotor
D- Lingual
E- Trochlear
Ans: A

167) **Regarding superior para thyroid:**
A- Supplied by superior parathyroid artery
B- Outside pre tracheal fascia
C- Posterior surface at the level of 1st tracheal ring
D- Superior to superior thyroidal artery
Ans: C

168) **Boy got meningitis and neck stiffness, bilateral deafness developed due to:**
A- Involvement of organ of corti
B- Involvement of neural pathways
C- Damage of tympanic membrane
D- Damage of scala media
E- Changes in endo lymph / perilymph
Ans: B

169) **Tympanic reflex:**
A- Frequency of 20-25 db
B- Involves a continuous chain of ossicles
C- Function's for very loud noises.
Ans: C

170) **Superficial temporal artery accompanies:**
A- Auriculotemporal nerve
B- Axillary
C- Median.
D- Median nerve
Ans: A

171) **Spinal part of accessory nerve:**
A- Passes below transverse process of atlas
B- Passes through the substance of sternocleidomastoid
C- Passes through Foramen ovale
D- Passes through Foramen spinosum
E- Passes through Superior orbital fissure
Ans: B

172) **Dorsal ramus of 2nd cervical nerve gives**
A- Greater auriculad
B- Greater occipital
C- Lesser occipital
D- Supraclavicular
E- Transverse cervical
Ans: B

CamScanner

173) Aerohatic vertigo in divers is due to:
A- Baro trauma
B- Perforated tympanic membrane
C- Some ear plugging thing
D- Unequal pressures in middle ear during ascent
Ans: D

174) Internal jugular vein when it passes from jugular foramen its immediate relation with:
A- Sternocleidomastoid
B- Trocher nerve
C- Accessory nerve
D- Intrnal carotid artrey
Ans: C
Explaination
- IJV after Coming out of Jugular foramen relation –ICA
- IJV With m jugular foramen relation – Accessory Nerve

175) What could be damaged in surgery of superficial submandibular gland?
A- Hypogastric nerve
B- Mandibular nerve
C- Trigeminal nerve
D- Marginal Brach of facial nerve
Ans: D

176) Fenestration in chorio capillaries aumerous and large in:
A- Equatorial plate
B- Around optic disc
C- Ora serata
D- Sub macular area
Ans: D

177) Regarding pharyngeal phase of deglutition. Which is appropriate:
A- Vocal cords strongly approximate
B- Larynx moves downward
C- Oesophageal sphincter is contracted
D- Palatopharyngeal fold moves downward
Ans: A

178) Which of the following statements is correct regarding middle meningeal artery:
A- Can be felt at pterion
B- Enters the skull through foramen spinosum
C- Passes through foramen ovale
D- Passes through foramen rotundum
Ans: B

179) Left recurrent laryngeal nerve is related to:
A- Brachiocephalic trunk
B- Arch of Aorta
C- Azygous vein
D- Subclavian
E- Esophagus
Ans: B

180) Nerve that supplies Trapezius muscle:
A- Radial Nerve
B- Cranial part of Accessory nerve
C- Spinal part of Accessory nerve
D- Axillary nerve
Ans: C

181) Hypoglossal i.e. CN XII injury on the right side will cause:
A- Left tongue paralysis with atrophy
B- Left tongue paralysis without atrophy
C- Right tongue paralysis with atrophy
D- Right tongue paralysis without atrophy
Ans: C

182) Afferent of Carotid Sinus:
A- Vagus Nerve
B- Glossopharyngeal Nerve
C- Accessory Nerve
D- Trochlear nerve
Ans: B

183) Trochlear Nerve damage will cause:
A- Loss of upward gaze and adduction
B- Loss of downward gaze and abduction
C- Loss of downward gaze and adduction
D- Loss of lateral gaze
Ans: B

184) Cornea Innervation:
A- Optic Nerve
B- Abducen Nerve
C- Occulmotor Nerve
D- Tochlear Nerve
E- Trigeminal Nerve
Ans: E

185) Patient with problem in posterior tongue taste and in elevation of shoulders, these affected nerves pass through:
A- Foramen rotundum
B- Formenovale
C- Foramen spinosum
D- Jugular Foramen
Ans: D (Acessory nerve is damaged)

186) Cervical branch of facial nerve supplies:
A- Sternocleidomastoid
B- Platysma
C- Genioglossus
D- Tensor veli palatani
Ans: B

187) Which Cells in retina cause self Generation of impulse?
A- Bipolar
B- Amacrine
C- Ganglion
D- Horizontal
Ans: C

CamScanner

188) Which vessel lies in sub occipital triangle:
A- Sub occipital nerve
B- Greater occipital nerve
C- Occipital artery
D- Post auricular artery
E- Vertebral artery
Ans: E

189) Cause of decreased hearing for lower frequencies:
A- Ear wax
B- Conductive deafness
C- Sensory deafness
D- Neural deafness
Ans: B

190) When light is thrown in left eye,pupillary light reflex present but consensual light reflex absent.Lesion is in:
A- Right optic nerve
B- Left optic nerve
C- Right occulomotor nerve
D- Left occulomotor nerve
Ans: C

191) Nerve involved in Bell's palsy:
A- 7
B- 9
C- 10
D- 3
Ans: A

192) Structure passing through the cavernous sinus:
A- CN 3
B- CN6 .
C- CN 4
D. CN 1
Ans: B

193) Fascia deep to parotid gland forms:
A- Stylomandibular ligament
B- Stylohyoid ligament
C- Temporomandibular ligament
D- Falciform ligament
Ans: A

194) Structure pierced during spinal tap:
A- Posterior longitudinal ligament
B- Ligamentum flavum
C- Anterior longitudinal ligament
D- Ligament nuchae
Ans: B

195) Light thrown in Right eye. direct reflex is present but absence of indirect light reflex. Which structure is involved/damaged?
A- Right occulomotor nerve.
B- Left occulomotor nerve
C- Left optic nerve
D- Right optic nerve
Ans: B

196) Regarding Pigment layer of retina:
A. Store solar energy and convert it to heat
B. Takes neurotransmitter from blood and stores
C Contains Double layer of post mitotic cells
D. Increasing light scatter
Ans: B

197) Spinal accessory nerve in substance of SCM:
A. Anterior to sternocleidomastoid
B. Superior to sternocleidomastoid
C. Passes through it
D. Atlas
Ans: C

198) Raphe of pterygopalatine Attaches:
A. Mylohyoid
B. Inf constrictor
C. Middle constrictor
D. Buccinators
Ans: D

199) A 25 year old male has developed cluster of vesicles on lateral side of lips. The causative organism resides in:
A. Trigeminal Ganglion
B. Pterygoid Ganglion
C. Otic Ganglion
D. Geniculate ganglion
Ans: A

200) Lacrimal gland receives parasympathetic from pterygopalatine ganglion that receives preganglionic fibers from:
A. Deep petrosal nerve
B. Lateral petrosal nerve
C. Greater petrosal nerve
D Axillary nerve
Ans: C

201) Child with fever and posterior cervical lymphadenopathy. Which structure is most likely to get damaged?
A. CN11
B. CN IX-X-XII
C. Anca cervicalis
D Cranial nerve 1
Ans: A

CamScanner

202) **In Facial pain, hyperacusis. Ganglion involved is**
A. Trigeminal Ganglion
B. Geniculate Ganglion
C. Ciliary Ganglion
D Pterygopalatine ganglion
Ans: B

203) **Chorda tympani carries**
A. Motor fibers to parotid
B. Supplies posterior 1/3rd of tongue
C. Joins lingual nerve
D. Supplies mucosa of middle ear cavity
Ans: C

204) **Regarding C2 vertebrae which is true:**
A. Contains odontoid process
B. Heart shaped body
C. Contains spine
D Has no transverse process
Ans: A

205) **What joins one lamina to the upper lamina of the vertebra?**
A- Ligamentum flavum
B- Anterior spinous ligament
C- Superior spinous ligament
D- Posterior longitudinal ligament
Ans: A

206) **What joins body of vertebra to neural arch of the vertebra?**
A- Lamina of vertebra
B- Neural plate
C- Pedicle
D- None of the above
Ans: C

207) **What happens when facial nerve is avulsed at mastoid level?**
A- Some muscles paralyzed.
B- All muscles paralyzed on same side
C- Some muscles paralyzed on same side
D- All muscles paralyzed on opposite side
Ans. B

208) **Fibers to ciliary ganglion are from which nerve?**
A- CN III
B- CN IV
C- CN V
D- CN VI
Ans. A

209) **Surgeon is performing operation of adrenal gland. Arterial supply to left Suprarenal gland is from**
A- Inferior mesenteric artery
B- Hepatic artery
C- Superior mesenteric artery
D- Inferior phrenic artery
Ans. D

210) **Patient left eye deviated inward. Where is the lesion?**
A- Left abducent palsy
B- Right abducent palsy
C- Left trochlear palsy
D- Left occulomotor palsy
Ans. A

211) **Danger area of scalp:**
A- Loose areolar tissue
B- Periostium
C- Connective tissue
D- Epicranial Apponeuurosis
Ans. A

212) **Cavernous sinus thrombosis caused by?**
A- Inferior ophthalmic vein
B- Superior ophthalmic vein
C- Supraorbital vein
D- Infraorbital vein
Ans. B

213) **Uvula deviation on the right due to lesion of:**
A- Right vagus
B- Left vagus
C- Left glossopharyngeal
D- Right glossopharyngeal
Ans. B

214) **External jugular vein formed by?**
A- Posterior auricular + reteromandibular
B- Posterior auricular + facial
C- Superficial temporal + posterior auricular
D- Superficial temporal + reteromandibular
Ans. A

215) **Infratemporal fossa connected to middle temporal fossa through?**
A- Greater wing of Sphenoid
B- Lesser wing of Sphenoid
C- Squamous part of temporal bone
D- Parietal bone
Ans. A

216) **Sensory neural deafness was present:**
A- Webber lateralized to normal ear
B- Rinne +ve
C- Absolute bone conduction zero
Ans. B>A

217) **True about Pituitary gland:**
A- Is extradural
B- Lies above diaphragm sella
C- Lateral to cavernous sinus
D- Lies below diaphragm sella
Ans. D

CamScanner

218) Optic nerve passes to skull by opening in:
A- Sphenoid
B- Ethmoid
C- Petrous temporal
D- Maxillary
Ans. A

219) Glossopharyngeal nerve supplies:
A- Stylopharyngeus muscle
B- Hyoglossis
C- Stylhyoid
D- Diagastric
Ans. A

220) Submental and submandibular lymph nodes are involved in which carcino ma?
A- Lower lip
B- Upper lip
C- Tongue
D- Jaw
Ans. A

221) Which divide occipital triangle?
A- Inferior belly of omohyoid
B- Superior belly of omohyoid
C- Splenius capitus superior
D- Splenius capitus inferior
Ans. A

222) Medial palperal ligament attachment:
A- Ligament which is formed from deep part of parotid fascia
B- Stylomandibular ligament
C- Stylobyoid ligament
D- Sphenomandibular
Ans. A

223) Parasympathetic to parotid is supplied by:
A- Facial nerve
B- Glossopharyngeal nerve
C- Vagus nerve
D- Trigeminal nerve
Ans. B

224) Lady hasdificulty in coming down stairs and tilts head to left with Eye Upward while moving dowustairs due to lesion at?
A- Right Superior Oblique
B- Left Inferior Oblique
C- Right Inferior Oblique
D- Left superior oblique
Ans. A

225) Diabetic patient presented withdecreased visual acquity.Doctor performed retinal laser photocoagulation.Lesion at?
A- Fovea
B- Retina
C- Cornea
D- Lens
Ans. B

226) Chorda tympani joins mandibular nerve to supply preganglionic fibers to submandibular gland. Which other muscle does this mandibular nerve supplies on its path?
A- Tensor veli palatine
B- Levator veli palatini
C- Stylohyoid
D- Buccinator
Ans: A

227) What is the nerve supply of levator scapula?
A- C4, C5
B- Accessory nerve
C- Thoracodorsal
D- Posterior rami of spinal nerves
Ans: A (Dorsal scapular was not in option)

228) Between sternocleidomastoid. posterior belly of digastric and superior belly of omohyoid,Which triangle is present?
A- Submental
B- Submandibular
C- Carotid
D- Posterior
Ans: C

229) Internal jugular vein relation to carotid:
A- Medial
B- Anterior
C- Lateral
D- Lower
Ans: C

230) The semicircular canals in cortex of ear are maxinially stimulated by
A- With nodding of head downwards
B- Doing cartwheel
C- Equal rotation along each plane
D- Vertical axis
E- Linear acceleration
Ans: B

231) Ansa cervicalis root value:
A- Hypoglossal with C123
B- Hypiglossal with C34
C- Hypoglossal with C67
D- Hypoglossal
Ans: A

CamScanner

232) **Parotid Duct opens:**
A- Buccal Space
B- Between Masseter and medial Pterygoid
C- Inferior Alveolar Canal of Mandible
D- Mandible
Ans: A

233) **Elevation of Jaw done by**
A- Lateral Pterygoid
B- Mylohyoid
C- Digastric
D- Masseter
Ans: D

Explanation:
Elevation of Jaw(Close mouth)
- Masseter
- Anterior fibers of Temporalis
- Medial Pterygoid

Depression of Jaw(Open mouth)
- Lateral Pterygoid
- Digastric
- Mylohyoid
- Geniohyoid

234) **Anterior border of sternoclenomastiod injured leading to bleeding.Vessel affected will be:**
A- Internal juglar vein
B- External juglar vein
C- 2nd part of subclavian
D- Common carotid
Ans: B

235) **Anterior 2/3rd general sensationcarried by:**
A- Facial nerve
B- Glossopharyngeal nerve
C- Vagus nerve
D- Trigeminal nerve
Ans: D

Explanation:
- Anterior 2/3 general sensation - Lingual nerve
- Anterior 2/3 Taste sensation - Chordatympani branch of Facial
- Posterior 1/3rd Taste sensation - Glossopharyngeal nerve
- Posterior most part taste sensation - Vagus

236) **Furunculosis on tip of nose spread tocavernous sinuses via:**
A- Inferior Opthalmic vein
B- Maxillary vein
C- Emissiory veins
D- Superior opthalamic vein
Ans: D

237) **In temporomandibular joint dislocation,what structure prevents the joint to go back in cavity ?**
A- Tubercles on articular surface of mandible
B- Temporomandibular ligament
C- Lateral pterygoid muscle
D- Medial Pterygoid muscle
E- Masster
Ans: C

238) **Pain from Ear lobule carried by:**
A- Posterior auricular nerve
B- Accessory nerve
C- Vagus nerve
D- Greater Auricular nerve
Ans: D

239) **Hoarseness of voice due to damage of:**
A- Vagus nerve
B- Glossopharyngeal nerve
C- Accessory nerve
D- Maxillary nerve
Ans: A

240) **Retropharyngeal lymph nodes drain?**
A- Pharynx
B- Post 1/3rd tongue
C- Larynx
D- Piriform fossa
Ans: A

Explanation:
- Retropharyngeal lymph nodes drain lymph from pharynx & auditory tube.

241) **Digastrif muscle is a two belly muscle.If ligament is attached to:**
A- Hyoid bod
B- Mastoid bone
C- Angle of mandible
D- Sterna angle
Ans: A

242) **Medial to thyroid gland is which of the following?**
A- Parathyroid
B- Recurrent laryngeal nerve
C- Carotid sheath
D- External laryngeal nerve
E- Sternohyoid
Ans: B

Explanation:
- **Anterolateral** - Sternohyoid Sternothyroid andSCM.
- **Posterolateral** - Carotid sheath
- **Medially** - RLN, Larynx, Pharynx and trachea.
- **Posteriorly** - Parathyroid glands

CamScanner

243) **Suhmandibular gland lies at the mandihular angle.Surgery of this will lead to damage of which structure adjacent to this:**

A- Mandibular nerve
B- Facialncrve
C- Lingual nerve
D- Maxillary nerve
E- Lacrimal nerve

Ans: B

Explanation:

While doing suhmandibular gland surgery, Following nerves damage:

- Margmal mandibular nerve branch offacial.
- Lingual nerve.
- Hypoglossal.
- Mylohyoid nerve.
- Mandibular nerve will not be damagewhich is branch of trigeminal

244) **Highest chance of pneumothoraxoccurs while passing CVP line via?**

A- Right internal jugular vein
B- External jugular
C- Subclavian vein
D- Left External jugular vein

Ans: C

245) **Loss of Overhead Abduction is due to damage of which of these:**

A- Nerve to Deltoid
B- Supraspinatus
C- Pectoralis major
D- Nerve to Serratus anterior
E- SCM

Ans: D

246) **Patent foramen ovale, most likely cause is:**

A- A gap between septum secundum and endocardial cushion
B- A gap in septum primum
C- A gap in septum secundum
D- Patent foramen primum
E- Patent foramen secundum

Ans: E

247) **Patient went to dental surgeon for excision of lower teeth.After that procedure, patient developed numbness of lower lip.which nerve is responsible ?**

A- Buccal nerve
B- Inferior dental nerve
C- Mental nerve
D- Facial nerve
E- Maxillary nerve

Ans: B

248) **Excessive opening of mouth prevented by ?**

A- Capsule of temporomandibular joint
B- Muscles of mastication
C- Temporo mandibular ligament
D- Muscles of face

Ans: C

249). **Which of the following structure liedeep to and parallel with carotidsheath?**

A- Reccurent laryngeal nerve
B- Vagus nerve
C- Sympathetic chain
D- Internal jugular vein
E- External jugular vein

Ans: C

250) **An Ent surgeon operating on mastoid antrum see profuse bleeding from posterior wall of mastoid antrum, Source of bleeding?**

A- Sup petrosal sinus
B- Inferior petrosal sinus
C- Cavernous sinus
D- Jugular Bulb
E- Sigmoid sinus

Ans: E

Explanation:

- Posterior Wall - Sigmoid Sinus
- Anterior Wall - Internal carotid artery
- Floor -Jugular Bulb

251) **Mastectomy of Patient done and a muscle was damaged after that patientcant adduct and lift (extend?) the arm.which muscle is damaged ?**

A- Serrartus anterior
B- Rhymbiod major
C- Pectoralis minor
D- Supraspinatus
E- Latismus dorsi

Ans: A

252) **Thoracic duct drains into:**

A- Right branchiocephalic vein
B- Junction between Left Internal jugular vein and left Subclavian vein
C- Right brachiocephalic vein
D- Internal jugular vein
E- Junction of SVC and Azygous vein

Ans: B

253) **Which muscle results in vocal cord abducted position?**

A- Vocalis
B- Thyroarytenoid
C- Posterior cricoarytenoid
D- Oblique arytenoid

Ans: C

CamScanner

254) Patient with pre auricular swelling. All examination & labs normal,only associated with otorrhea& occasional Lymphadenopathy, diagnosis by?
A- Trucut biopsy
B- Needle biopsy
C- Excisional biopsy
D- Incisional biopsy
Ans: A

255) Muscle from vertebral border of Scapula which attaches it to anterior chest wall by which of following?
A- Quadratus laborum
B- Latismus dorsi
C- Rhomboid major
D- Serratus anterior
Ans: D

256) The cutaneous branches of cervical plexus are;
A- Phrenic and lesser occipital
B- Greater occipital and suprascapular
C- Greater auricular and lesser occipital
D- Ansa cervicalis and Supraclavicular
Ans: C

257) Tumor of eye which spreads to liver:
A- RB
B- Ewing sarcoma
C- BCC
D- Melanoma
Ans: D

258) Patient After thyroidectomy developed hoarseness of voice&loose vocal cords Muscle damaged with supply from middle 3rd of nucleus ambiguous is:
A- Cricothyroid
B- Cricoarytenoid
C- Vocalis
D- Arytenoid
Ans: A

259) Nerve supplying of mylohyoid issame as which of following othermuscle?
A- Anterior belly of digastric
B- Posterior belly
C- Stylohyoid
D- Omohyoid
E- Sternothyroid
Ans: A

260) Nerve Supplying Medial Pterygoid supply which other muscle
A- Levator veli palatini
B- Tensor veli palatini
C- Posterior belly of digastric
D- Omohyoid
Ans: B

Explanation:
Mandibular nerve supply following muscles
- Muscle of mastications
- Tensor veli palatani
- Tensor veli tympani
- Mylohyoid
- Anterior belly of digastric

261) A person fell on ground and his chin to nail. Which of the following mu will likely be damaged?
A- Digastric
B- Platysma
C- Myelohyoid
D- Lateral pterygoid
E- Geniohyoid
Ans: B

262) Fat pad of upper eyelid is anteriorto?
A- Orbital septum
B- Muller muscle
C- Orbicularis
D- Levator aponeurosis
Ans: D

Explanation:
- Anterior to – Levator aponeurosis
- Posterior to – Orbital septum

263) Mental foramen location related tomandible and mental nerve at thelevel of:
A- 1st premolar
B- 2nd lower premolar
C- 1st upper molar
D- 2nd upper molar
E- Canine
Ans: B

264) Injury to greater wing of sphenoid and inferior orbital fissure damages which nerve
A- Occulomotor
B- Trochlear
C- Zygomatic
D- Lacrimal
E- Nasociliary
Ans: C

265) Man standing in bus, bus suddenly moves but man does not fall.How balance ismaintained:
A- Saccule
B- Utricle
C- Oval window
D- Semicircular canal
Ans: B

Explanation:
- Linear Acceleration(Bus): Utricle
- Vertical Acceleration(Lift)- Saccule
- Angular Acceleration- Semicircular canal

CamScanner

266) A 17-year-old boy presented with epistaxis and nasopharyngeal angiofibroma. Surgeon decided to ligate the culprit blood vessel. which vessel is this?
A- Intermaxillary artery
B- External maxillary artery
C- Internal jugular vein
D- Palatine artery
E- Ascending pharyngeal artery
Ans: E

267) During tonsillectomy,increased bleeding may be due to damage to which vessel?
A- Inferior thyroid artery
B- Sphenopalatine artery
C- Brachiocephalic vein
D- Tonsillar artery
Ans: D

268) A child came in opd of the orthodontist, child is not sure about his age. What measures should be done to confirm his age?
A- Measure the height by his age
B- Check his nutritional status
C- Do multiple x-rays of bone
D- Number of permanent teeth developed
Ans: C

269) A young boy presented with boil in nasal vestibule. Its route of spread to Dural sinus is:
A. Nasociliary
B. Emissary vein
C. Superior ophthalmic vein
D. Inferior ophthalmic vein
Ans: C

270) In nail injury to submental triangle, the muscle that would be pierced last will be?
A. Geniohyoid
B. Genioglossus
C. Platysma
D. Masseter
E. Stylohyoid
Ans: B

271) Content of inferior orbital fissure?
A- Lacrimal nerve
B- Frontal nerve
C- Trochlear nerve
D- Zygomatic nerve
E- Occulomotor nerve
Ans: D

272) Patient has pain in throat and has hoarsness of voice.On Xray, large styloid process seen.Structure involved is:
A- Facial nerve
B- Stylopharyngeus muscle
C- Buccinator
D- Platysma
Ans: B

273) A women with the history of trauma to head and neck region having lesion on tongue on protrusion of tongue deviated to the left side the nerve most likely involve is:
A- Left hypoglossal
B- Right hypoglossal
C- Glysopharangeal nerve
D- Vagus nerve
E- PICA
Ans: A(FA)
Explanation:
- **CN V motor lesion** – Jaw deviates toward side of lesion
- **CN X lesion** – Uvula deviates away from side of lesion
- **CN XI lesion** – Weakness turning head to contralateral side of lesion (SCM) Shoulder droop on side of lesion (trapezius)
- **CN XII lesion** – LMN lesion. Tongue deviates toward side of lesion

274) 1 year old boy was brought to doctor with complain of inability to swallow. on exam there was regurgitation of milk with cleft palate , what is the Commonest cause of cleft palate?
A- Maternal age
B- Viral
C- Multifactorial inheritance
D- Anti convulsant
E- Sex of baby
Ans: C

275) Both RLN severed.Which muscle will be spared?
A- Lateral circoarytenoid
B- Oblique arytenoid
C- Transverse arytenoid
D- Cricothyroid
Ans: D

276) Tumor compressing hypoglossal canal will affect which muscle?
A- Stylopharymgeus
B- Myelohyoid
C- Genioglossus
D- Thyroglossus
E- Palatoglossal
Ans: C

CamScanner

277) A Patient has boil on upper eyelid drained by Emissiory vein. It is dangerous emergency and opthalmologist will treat it immediatey because:

A- Can involve whole eye
B- Cause Episcleritis
C- Cause Conjuctivitis
D- Spread to Cavernous sinus

Ans: D

288) A Patient has middle ear infection it is dangerous because it can:

A- Spread to Cavernous sinus
B- Involve other ear
C- Lead to Dizziness
D- Affect cartilage of ear

Ans: A

289) Tumor suppressing the anterior surface of SCM. Vessel engorged will be?

A- IJV
B- EJV
C- Subclavian
D- Vagus nerve
E- Long thoracic nerve

Ans: B

290) Phonation occurs due to:

A- Vibration of vocal cords
B- Vocal cord abduction
C- Occurs only during inspiration
D- Occurs only during expirtion
E- Occurs during inspiration and expiration

Ans: A

291) 52 years old man presented in OPDwith unusual facial expressions, halfside of the face was red and absenceof sweating what could be thepossible cause for this condition:

A- Cervical Sympathetic Chain damage
B- Facial nerve damage
C- Parasympathetic damage
D- Abducent nerve damage
E- Lingual nerve damage

Ans: A

292) In emergency procedure you are performing tracheostomy which vessel can be injured and cause profuse bleeding?

A- Thyroid ima artery
B- Inferior thyroid artery
C- Internal JV
D- External JV
E- Subclavian Vein

Ans: A(Only Suitable)

Explanation:

Prefer

- Most Common Cause of Bleed DuringTracheostomy – Inferior Thyroid Vein
- Most Common Cause of Heavy BleedDuring Tracheostomy – Anterior Jugular Vein
- In Child during Tracheostomy Risk ofdamage to - Left Brachiocephalic vein andRight brachiocephalic Trunk (Innominateartery)

293) Patient presented with facial nerve palsy and hyperacusis. Nerve damaged at:

A- Stylomastoid foramen
B- Middle ear
C- Chorda tympani
D- Nerve to stapedius
E- Foramen spinosum

Ans: D

294) A young girl complains of dryness ofthe nose and the palate. This wouldindicate a lesion of which of thefollowing ganglia?

A- Nodose ganglion
B- Otic ganglion
C- Pterygopalatine ganglion
D- Submandibular ganglion
E- Ciliary ganglion

Ans: C

Explanation:

- Parasympathetic post ganlionic fibresfrom the pterygopalatine ganglioncarried via maxillary branch oftrigeminal to nasal and lacrimal gland.
- Parasympathetic post ganglionic fibersfrom cilliary ganglion to sphinterpapillae result in pupil constriction

295) Location of descent of 2nd pharyngeal arch to epicardiat ridge in lower neck:

A- Anterior aspect of neck
B- Posterior aspect of neck
C- Lateral to SCM muscle
D- Lateral in neck anterior to SCM

Ans: D

296) An unmarried female with parotid swelling and no Lymph node enlargement. Which type of biopsy is used for Parotid swelling in this case?

A- Incisional
B- Trucut
C- Excisional
D- Aspirational

Ans: D

CamScanner

297) **Blow out fracture of orbit with Proptosis and loss of cheek sensation is due to:**

A- Check edema
B- Zygoma
C- Infraorbital nerve damage
D- Infraorbital nerve at its formen
E- Orbital Floor fracture
Ans: C

298) **Women during robbing resists.Multiple stab wounds on right side face.She is brought to emergency after primary care.Dr noticed right facial nerve damage.which muscle will be paralyzed?**

A- Genohyoid
B- Sternothyroid
C- Omohyoid
D- Posterior belly of digastric
E- Anterior belly of diagastric
Ans: D

299) **Newborn oral cavity stone due to**

A- Thyroid arrest
B- Parathyroid atrophy
C- Dehydration
D- Fibrosis
Ans: C

300) **Foramen caecum anteriorly elongates from tongue to the hyoid bone by a diverticulum and Forms Thyroid gland in Adults.That Diverticulum is:**

A- Thyroglossal Duct
B- Thyroglossal Diverticulum
C- Thyroglossal Duct Diverticulum
D- Hypoglossal duct
E- Laryngeal Diverticulum
Ans: A

301) **Arch of aorta aneurysm, which of following is affected?**

A- External laryngeal nerve
B- Internal laryngeal nerve
C- Phrenic nerve
D- Recurrent laryngeal nerve
E- Accessory nerve
Ans: D

302) **Student with pain in neck on one side is aggregated during exam.Transection of which of the following will relieve pain?**

A- C5
B- C3
C- Spinal accessory nerve
D- Phrenic nerve
Ans: B

303) **There is a mass on dorsum of tongue at the junction of anterior 2/3rd and posterior 1/3rd, which of the following is most likely the origin of tumour?**

A- Thyroid
B- Ultimobronchial artery
C- Thymus
D- Parathyroid
Ans: A

304- **Emmetropic patient with presbyopia has**

A- Increase refractive index
B- Decrease Far vision
C- Decrease near vision
D- Inability to see far objects
Ans: C

305- **Minor Salivary gland nerve supply is**

A- Glossopharyngeal nerve
B- Vagusnerve
C- Abducentnerve
D- Facialnerve
Ans: D

306- **A patient with Color blindness can'tdifferentiate between red from greenthis is called**

A- Hemianopia
B- Quadrianopia
C- Protonopia
D- Heteroanopia
Ans: C

Explanation:

- Can't differentiate Between Red andgreen - Protonopia
- Can't differentiate Between Green andred – Deutronopia

307-Nerve loop around arch of aorta?

A- Left Phrenic nerve
B- Right Phrenic nerve
C- SVC
D- Bracheocephalic vein
E- Left recurrent laryngeal nerve
Ans: E

308- **Which one has Dual nerve supply but not reciprocal?**

A- Sweat gland
B- Iris
C- Thyroid
D- Pupil
E- Salivary gland
Ans: E

Explanation:

- Salivary gland has both sympathetic and parasympathetic so dual and this dual increase salivation mean same function so its not reciprocal

CamScanner

309- A Patient has eyelid dropping and Change on one side of face due to which nerve paralysis?

A- Vagus
B- Abducent
C- Facial
D- Trigeminal
Ans: C

310- During pharyngeal phase ofswallowing what is true

A- Vocal cords adducted
B- Vocal cords abducted
C- Larynx moves upward and forward
D- Larynx moves downward
E- Closure of Epiglotis
Ans: A (Guyton)

Explanation:

- During pharyngeal phase of swallowingvocal cord approximation (Adduction) and upward and anterior movement oflaryux occur simultaneously. But A ismore Imp (Guyton).

311- During game boy injured which areaof orbit by ball that now there isvertical diplopia and enophthalmos?

A- Apex
B- Base
C- Roof
D- Floor
Ans: D

Explanation:

- Vertical diplopia + Proptosis – Roofdamage
- Vertical diplopia + Proptosis –Enophthalmos - Floor damage

312- Patient with Posterior 1/3rd of tongueCarcinoma.What is the lymphatic drainage?

A- Juguloomohyoid
B- Digastric
C- Submandibular
D- Submemtal
Ans: A

Explanation:

- Anterior 2/3rd Tongue – Submandibular
- Posterior 1/3rd Tongue – Juguloomohyoid.
- Tip of Tongue – Submental

313-Lateral to Pituitary gland lies:

A- Cavernous sinus
B- Optic tract
C- Optic chiasma
D- Optic nerve
Ans: A

Explanation:

- Cavernous Sinus Laterally(Pituitarymedial to it)
- Sphenoid Air Sinus – Inferiorly
- Optic Chiasm – Superiorly
- Optic nerve – Anteriorly

314- Lymphatic drainage of external nose& anterior part of nasal cavity is:

A- Submandibular lymph nodes
B- Deep cervical lymph nodes
C- Retropharyngeal lymph nodes
D- Occipital lymph nodes
E- Jugulo omohyoid
Ans: A

Explanation:

- External nose & anterior nasal cavity – Submandibular lymph nodes
- Posterior nasal lymph nodes – Retropharyngeal lymph nodes & JDnodes
- Remaining nasal cavity: Upper deepcervical lymph nodes.

315- Patient had internal jugular lymphnode biopsy in neck region.After that-he developed numbness of earlobe.Which of the following nervegot injured?

A- Greater auricular nerve
B- Auriculotemporal nerve
C- Recurrent laryngeal nerve
D- Vagus nerve
E- Lesser auricular nerve
Ans: A

Explanation:

- During leprosy there is hanging of ear lobe why: greater auricular nerve
- Ear lobe is supplied by which nerve: greater auricular nerve
- Ear lobe numbness: greater auricular nerve

316- Eyelid drooping due to head trauma, nerve paralysis likely is:

A- Sympathetic
B- Parasympathetic
C- T6-7
D- Vagus nerve
Ans: A

317- Relation of right vagus nerve with trachea while entering thorax?

A- Direct contact
B- Separated by recurrant laryngeal nerve
C- Azygos vein
D- Separated by phrenic nerve
E- Separated by brachiocephalic vein
Ans: A

CamScanner

318- **Temporalis insertion is on:**
A- Mandible Surface
B- Angle of mandible
C- Coronoid process of mandible
D- Undersurface of jaw
Ans: C

319- **Ligament made by thickening of parotid fascia**
A- Bucco pharyngeal membrane
B- Stylomandibular ligament
C- Sheno mandibular ligament
D- Stylo hyoid ligament
Ans: B

320- **Edema in retina occurs due to:**
A- Myasthenia
B- Thyrotoxicosis
C- DM
D- Atherosclerosis
Ans: C

321- **Jaw reflex mediated by:**
A- CN IV
B- CN V
C- CN X
D- CN IX
Ans: B

322- **During near vision, Whathappens?**
A- Spherical diameter of lense increase
B- Cilliary muscle constriction
C- Vertical diameter increase
D- Lense dislocation
Ans: B

323- **Hyper extension of neck is limited bywhich of following?**
A- Ligament nuche
B- Ligament flavum
C- Anterior longitudinal ligament
D- Posterior longitudinal ligament
E- Lateral ligament
Ans: C

324- **Accomodation of eye is:**
A- Involuntary
B- Voluntary cerebral reflex
C- Involuntary pontine reflex
D- Medullary reflex
Ans: A

325- **Patient with deep wound on scalp, which layer has to be sutured otherwise will cause large gap?**
A- Epicranial aponeurosis
B- Pericranium
C- Loose connective tissue
D- Dense veins
Ans: C

326- **Mucosa of trachea sensory nerve supply is:**
A- SLN
B- RLN
C- Aorta
D- Intercostal
Ans: B

327- **Hoarsness of voice due to damage ofwhich of the following nerve?**
A- SLN
B- RLN
C- Vagus nerve
D- ILN
E- Hypoglossal nerve
Ans: B

328 **-Floor of Posterior Triangle of Neck is formed by**
A- Cervical fascia
B- Prevertebral fascia
C- Splenius capitis
D- Trapezius
Ans: B

329- **Location of superior parathyroidgland**
A- Anterior to RLN caudal to inferiorthyroid artery
B- Posterior to RLN cranial to inferiorthyroid artery
C- Anterior to RLN cranial to inferiorthyroid artery
D- Posterior to RLN caudal to inferiorthyroid artery
Ans: B

330- **Which cranial nerve has both afferent and efferent?**
A- Abducent
B- Hypoglossal
C- Optic
D- Facial
E- Occulomotor
Ans: D

Explanation:
- Vestibular -Afferent
- Hypoglossal - Efferent
- Facial - Affierent and efferent

331- **Rightening reflex in cortex corrects position of :**
A- Legs over head
B- Body over head
C- Head over legs
D- Legs over Legs
Ans: B

CamScanner

Explanation:

- The righting reflex, also known as the labyrinthine righting reflex, is a reflex that corrects the orientation of the body when it is taken out of its normal upright position. It is initiated by the vestibular system, which detects that the body is not erect and causes the head to move back into position as the rest of the body follows.

332- Taste sensation lost after tonsillectomy due to damage of which nerve:

A- Chorda tympani
B- Glossopharyngeal
C- Vagus
D- Trigeminal
E- Accessory
Ans: B

333- Regarding Thyroid gland relation, True is:

A- Pretracheal fascia posterior
B- RLN lateral to gland
C- Sternohyoid lateral to gland
D- Parathyroid anterior to gland
Ans: C

Explanation:

- **Anterolateral** – Stemohyoid, Sternothyroid and SCM.
- **Posterolateral** – Carotid sheath
- **Medially** – RLN, Larynx, Pharynx and trachea.
- **Posteriorly** – Parathyroid glands

334- Centrum and neural arch in vertebare joined by:

A- Lamina
B- Body
C- Pedicle
D- Pedicle and body
Ans: C

335- Which vein moves perpendicularly over Sternocleidomastoid and pierces fascia in neck?

A- IJV
B- EJV
C- Retromandivular vein
D- Intercostal vein
E- Thoracic vein
Ans: B

336- Least representation in motor area is of:

A- Finger
B- Lips
C- Thigh
D- None
Ans: C

337- In hanging, Sudden death occurs to fracture of:

A- Atlas vertebra
B- Odontoid process of axis
C- Transverse process of axis
D- Spinous process of axis
E- Base of skull
Ans: B

338- Location of Brachiocephalic vein

A- Behind Coracoacromial joint
B- Behind Coracoclavicular joint
C- Behind sternal end of clavicle
D- Behind SCM
Ans: C

339- Anterior choroidal artery is a branch of?

A- Anterior cerebral artery
B- Posterior cerebral artery
C- Internal carotid artery
D- Anterior communicating artery
Ans: C

340- Lymph nodes of lower lip are:

A- Deep cervical
B- Sub mental
C- Parotid
D- Sublingual
E- Superficial cervical
Ans: B

341- A Patient presented with epistaxis and Bleeding from lateral wall of nose. Artery involved is:

A- Posterior ethmoidal artery
B- Sphenopalatine artery
C- Inferior labial artery
D- Lesser palatine artery
E- Anterior Ethmoidal artery
Ans: B

342- Which of the following is not affected by some tumour in hypoglossal canal?

A- Genioglossus
B- Styloglossus
C- Hyoglossus
D- Palatoglossus
Ans: D

343- Optic canal contains which of the following?

A- Ophthalmic vein
B- Trigeminal nerve
C- Abducent nerve
D- Trochlear nerve
E- Ophthalmic artery
Ans: E

CamScanner

Explanation:
- Foramen cecum contains emissary veins
- Optic canal contains optic nerve,ophthalmic artery, meningeal sheath andsympathetic nerves.
- Superior orbital fissure contains lacrimal& frontal nerves.

344- Lateral wall of cavernous sinus is related to?
A- CN3,4,6,V1,V2
B- CN3,4,6,V3
C- CN 2,3,4,6
D- CN 2,3,5
Ans: A

345- A patient develops infection of mastoid. The likely complication is spread of the infection to?
A- Cavernous sinus
B- Sigmoid sinus
C- Transverse sinus
D- Petrosal sinus
Ans: A

346- Patient after thyroidectomy developed hoarseness of voice. Examination reveals tense vocal cords. Which of the following is most likely damaged?
A- Cricothyroid
B- Cricoaretynoid
C- Vocalis
D- Arytenoid
Ans: C

Explanation:
- Tense vocal cord mean Cricothyroid which is tensor of vocal cord is normal in function and Vocalis which is normally a relaxor of vocal cord is damaged due to which function of Cricothyroid function is enhancedwhich is tensor of vocal cord.

347- Opening of mouth done by:
A- Medial pterygoid
B- Masseter
C- Anterior fibers of temporalis
D- Lateral pterygoid
Ans: D

Explanation:
Elevation of Jaw (Close mouth)
- Masseter
- Anterior fibers of Temporalis
- Medial Pterygoid

Depression of Jaw (Open mouth)
- Lateral Pterygoid
- Digastric
- Mylohyoid
- Geniohyoid

348- Mother noticed swelling below hyoid bone in child first presented when he was 3 year old since than it is increasing it is
A- Accessory thymic tissue
B- Thyroglossal cyst
C- Hyoid cyst
D- Accessory thyroid tissue
Ans: B

349- Nerve damaged during submandibular gland surgery:
A- Mandibular nerve
B- Hypoglossal nerve
C- Mandibular branch of Facial nerve
D- Glossophyrengeal nerve
E- Inferior alveolar nerve
Ans: C

Explanation:
While doing submandibular gland surgeryfollowing nerves damage
- Marginal mandibular nerve branch offacial.
- Lingual nerve.
- Hypoglossal.
- Mylohyoid nerve.
- Mandibular nerve will not be be damagewhich is branch of trigeminal

350- Abductor of vocal cord is:
A- Posterior Cricoarytenoid
B- Lateral Cricoarytenoid
C- Cricothyroid
D- Vocalis
E- Oblique arytenoid
Ans: A

351- Closing of mouth done by:
A- Lateral Pterygoid
B- Myelohyoid
C- Digastric
D- Masseter
Ans: D

Explanation:
Elevation of Jaw (Close mouth)
Masseter
Anterior fibers of Temporalis
Medial Pterygoid
Depression of Jaw (Open mouth)
Lateral Pterygoid
Digastric
Myelohyoid
Geniohyoid

352- In an albino,visual acuity has reduced due to decrease melanin in?
A- Cornea
B- Iris
C- Sclera
D- Lens
Ans: B (Prefer pigmented epithelial layer of retina)

CamScanner

353- A patient in shock became pulseless.Artery palpated by surgeon between trachea and infrahyoid is:
A- Internal carotid
B- Common carotid
C- Internal jugular vein
D- External Carotid
Ans: B

354- Patient has bleeding problem due to mass on lateral side of sternocleidomastoid muscle which vessel is bleeding?
A- Basilar
B- Subclavian
C- Maxillary
D- Accessory
E- ECA
Ans: B

355- Most common calculi of salivary glands in:
A- Parotid gland calculi
B- Warthin duct of submandibular
C- Small salivary glands in floor of mouth
D- Large salivary gland in roof
Ans: B

356- Nerve compression between C5 and C6 compresses which of following?
A- C4
B- C5
C- C6
D- C7
E- C3
Ans: C

357- In strangulation,Which one will be damaged?
A- Thyroid
B- Arytenoid
C- Epiglotis
D- Hyoid
E- Cricoid
Ans: D

358- Alcoholic mother having 5 year old child with spider Navi on face, hypoplastic nasal bridge and ptosis defect will be in:
A- Cartilage formation
B- Bone formation
C- Chondral ossification
D- Membranous ossification
Ans: B

359- A patient undergoing thyroidectomy at lower lobe develop hoarseness of voice nerve injured in vicinity of inferior thyroid artery ligation:
A- External laryngeal nerve
B- Internal laryngeal nerve
C- Phrenic nerve
D- Recurrent laryngeal nerve
E- Accessory nerve
Ans: D

Explanation:
- Upper Lobe – ELN
- Lower Lobe – RLN
- Superior Thyroid artery Related to –ELN
- Inferior thyroid artery related to – RLN
- Superior laryngeal artery related to – Internal laryngeal nerve
- Most common nerve injured duringthyroidectomy – ELN
  Most common nerve injured duringtracheostomy – RLN

360- If we cut one side of cervical sympathetic chain, what happens on ipsilateral side?
A- Sweating
B- Miosis
C- Mydriasis
D- Vasodilation
Ans: B

361- Thyroglossal cyst common location is?
A- Above sternum
B- Anterior triangle
C- Intralingual
D- Posterior triangle
Ans: B

362- Lymph node biopsy from posterior triangle done which structure will be damaged?
A- EJV
B- IJV
C- Long thoracic nerve
D- Accessory nerve
Ans: D

363- 10 Year old child present with lump on forhead Mass excised from forehead microscope shows anastomosis of vessels and single layer of endothelium it is most likely:
A- Lipoma
B- Hemangioma
C- Sarcoma
D- Fibroma
Ans: B

CamScanner

364- Cancer of lower lip drains into which of the following Lymph node?
A- Submandibular
B- Submental
C- Jugulodigastric
D- Juguloomohyoid
E- Omohyoid
Ans: B

365- A surgeon performing thyroidectomy during upper lobe thyroid surgery nerve likely to be damaged in proximity with Superior thyroid artery accidently is:
A- Recurrent laryngeal
B- Superior laryngeal nerve
C- External laryngeal nerve
D- Internal laryngeal nerve
E- Phrenic nerve
Ans: C

Explanation:
- Upper Lobe – ELN
- Lower Lobe – RLN
- Superior Thyroid artery Related to –ELN
- Inferior thyroid artery related to – RLN
- Superior laryngeal artery related to – Internal laryngeal nerve
- Most common nerve injured during thyroidectomy – ELN
- Most common nerve injured during tracheostomy – RLN
- Hoarseness of voice - RLN >ELN >Vagus

366- Nerve supply to cricothyroid is
A- RLN
B- ELN
C- SLN
D- ILN
Ans: B

367- Patient has loss of taste sensation at anterior 1/3 of tongue. Lesion at?
A- Facial Canal
B- Facial Nucleus
C- Internal acoustic meatus
D- Parotid gland
E- Stylomastoid foramen
Ans: A

368- Lymph nude biopsy from posterior triangle done which structure will be damaged?
A- EJV
B- IJV
C- Long thoracic nerve
D- Accessory nerve
Ans: D

369- A patient was made to taste quinidine the taste sensation carried by:
A- Ventro posterio lateral medial
b- Ventro posterio medial
C- Medial geniculate body
D- Lateral geniculate body
Ans: B

370- A person got hit by car from back Can't move neck at atlantoaxial joint Which ligament of joint is damaged.
A- Anterior
B- Posterior
C- Transverse
D- Capsule
Ans: C

371- After trauma to neck surgeon should compress Transverse process of which cervical rib to stop bleeding from internal carotid artery?
A- 3rd
B- 2nd
C- 4th
D- 6th
E- 7th
Ans: D

372- Superior thyroid artery is the branch of which of the following?
A- External Carotid Artery
B- Thyrocervical trunk
C- Subclavian artery
D- Internal carotid artery
E- Internal cerebral artery
Ans: A

Explanation:
- Superior Thyroid artery branch of – ECA
- Inferior Thyroid artery branch of – Thyrocervical trunk

373- Prime flexor of neck is:
A- Scalene medius
B- Trapezius
C- SCM
D- Serratus anterior
Ans: C

374- Trigeminal nerve causes which reflex?
A- Accomodation
B- Light reflex
C- Corneal reflex
D- Cerebral reflex
Ans: C

375- Gustatory sweating after parotid gland surgery may result from injury to?
A- Facial nerve
B- Glossophrangeal nerve
C- Auriculotemporal nerve
D- Lingual nerve
Ans: C

CamScanner

376- **Vessel which runs obliquely upward in parotid gland?**
A- Facial artery
B- Maxillary artery
C- Lingual artery
D- Occipital artery
Ans: C

377- **In sub mandibular triangle which structure along with lingual nerve?**
A- Sub mandibular duct
B- Maxillary artery
C- Facial nerve
D- Glossopharyngeal nerve
Ans: C

378- **Which one located anterior to masseter?**
A- Temporal artery
B- Maxillary artery
C- Facial artery
D- Lingual artery
Ans: C

379- **A young man came he has difficulty in pharyngeal swallowing, which nerve is damaged?**
A- II, V, VII, IX
B- V, VII, IX, X, XI
C- V, VII, IX, X
D- IX, X, XI, XII
Ans: C

380- **Mass in lung or hilum with left vocal cord palsy hoarsness of voice due to:**
A- RLN due to Mediastinal lymph node involved mass
B- Vagus
C- Phrenic
D- Intercostal
Ans: A

381- **A boxer got blow and Mandibular fracture just before the mandibular foreman will cause?**
A- Loss of taste to ant 2/3 of tongue
B- Mylohoid muscle unable to stabilize mandible
C- Loss of sensation over lower teeth
D- Loss of sensation over upper teeth
Ans: C

382- **Internal auditory canal contains which of these?**
A- Glossopharyngeal nerve
B- Facial and Vestibular nerve
C- Abducent and Trigeminal nerve
D- Vagus and facial
Ans: B

383- **Regarding Central retinal vein:**
A- Painless visual loss
B- Received thrombus from sigmoid sinus
C- Is connected to cavernous sinus
D- Painful visual loss
Ans: A

384- **The frequency of impulse from utricle?**
A- Opposite from opposite ear
B- Same as frequency rate of semi circular canal
C- Varies with head position
D- Increases if person travels at high velocity
Ans: A

385- **A Patient having vesicles on lateral forehead and medial side of eye and ala of nose with severe facial pain and headache, which nerve is involved?**
A- Ophthalmic nerve
B- Maxillary division of trigeminal nerve
C- Facial Nerve
D- Nasocilliary
E- Trochlear
Ans: B

386- **The artery which can be palpated under the mandible near the angle of jaw is:**
A- Facial
B- Lingual
C- Maxillary
D- Ascending pharyngeal
Ans: A

387- **Both sides lateral pterygoid and anterior belly of diagastric contract or pull leads to:**
A- Protrusion of mouth
B- Retraction of mouth
C- Closing of mouth
D- Opening of mouth
E- Side to side movements
Ans: D

388- **Which is true for Tympanic membrane?**
A- It forms medial wall of middle ear
B- It forms lateral wall of middle ear
C- It forms posterior wall of external ear
D- It forms both anterior and lateral wall of internal ear
Ans: B

389- **Aortic arch aneurysm compresses which nerve and causes hoarsness of voice?**
A- ILN
B- SLN
C- RLN
D- Hypoglossal nerve
Ans: C

CamScanner

390- Regarding internal jugular vein:
A- Starts from ear lobule to sternal angle
B- Starts from ear lobule to manubrium sterni
C- Starts from angle of mandible to hyoid bone
D- Starts from ear lobule to sternoclavicular joint
Ans: D

391- 1st cervical nerve supply:
A- Omohyoid
B- Geniohyoid
C- Platysma
D- Serratus anterior
Ans: B

392- Middle branch of ECA is
A- Internaxillary artery
B- External maxillary artery
C- Internal jugular vein
D- Palatine artery
E- Ascending pharyngeal artery
Ans: E

393- Narrowest point in pediatric airway:
A- Cricoid
B- Thyroid
C- Trachea
D- False vocal cord
E- True vocal cords
Ans: A

394- Hyoid bone derived from:
A- 1st pharyngeeal arch
B- 2nd and 3rd pharyngeal arch
C- 3rd pharyngeal pouch
D- 4th pharyngeal pouch
Ans: B

395- Enlarged Jugulodigastric lymph node of deep cervical lymph node drains:
A- Palatine tonsil
B- Pharyngeal tonsil
C- Tubal tonsil
D- None of the above
Ans: A

396- Most common midline abnormality:
A- Cleft nose
B- Cleft ear
C- Median cleft lip
D- Median cleft lip and cleft nose
Ans: C

397- Inferior parathyroid is supplied by:
A- Superior thyroid artery
B- Inferior thyroid artery
C- Internal laryngeal artery
D- Superior laryngeal artery
Ans: B

398- Most medial branch of external carotid artery?
A- Ascending pharyngeal
B- Lingual artery
C- Facial artery
D- Superficial temporal
Ans: A

399- Receptor for sweet taste at:
A- Anterior two third of tongue
B- Tip of tongue
C- Lateral tongue
D- Posterior tongue
Ans: B

400- Relation of right vagus nerve with trachea while entering:
A- Direct contact
B- Separated by recurrant laryngeal nerve
C- Azygos vein
D- Separated by phrenic nerve
Ans: A

401- Mucous membrane lining the eyelid and eye outer surfaces:
A- Iris
B- Cornea
C- Lense
D- Conjunctiva
Ans: D

402- A patient with tip of tongue carcinoma 1st drainage of lymph nodes is:
A- Submental
B- Deep cervical
C- Superficial cervical
D- Juguloomohyoid
E- Jugulo Digastric
Ans: A

403- Superior pole of thyroid is ligated.Artery supplying this originates from:
A- External Carotid Artery
B- Thyrocervical trunk
C- Subclavian artery
D- Internal carotid artery
E- Internal cerebral artery
Ans: A

404- Pituitary adenoma surgery donethrough approach via:
A- Sphenoid
B- Cribriform plate
C- Petrous temporal
D- Zygomatic
Ans: A

CamScanner

405- Source of spread of infection to and fromtip of nose occurs through which of thefollowing:
A- Inferior Ophthalmic vein
B- Maxillary vein
C- Emissiory veins
D- Superior ophthalamic vein
Ans: D

406- In Parotid surgery facial nerve cut Muscle affected will be:
A- Levator ocularis
B- Buccinator
C- Masseter
D- Geniohyoid
Ans: B

407- 3-years-old child was brought into pediatric emergency with bradycardia, his history revealed that he had swallowed coin 6 days ago, now vomiting, which of the following nerve responsible for stimulation of one of the nerves supplying larynx:
A- Internal laryngeal
B- Recurrent laryngeal
C- External laryngeal
D- Superior laryngeal
Ans: B

408- After tonsillectomy patient developed Hoarsness of voice due to damage of:
A- Vagus nerve
B- Glossopharyngeal nerve
C- Accessory nerve
D- Maxillary nerve
Ans: A

409- A patient presented with damage to left cervical chain. Symptom present would be?
A- Left sided Ptosis
B- Right sided Ptosis
C- Cutaneous flushing
D- Mydriasis
E- Diplopia
Ans: A

410- A girl did suicide by gun shot which Fractured and cause Pterion hemorrhage due to involvement of which artery?
A- Middle Meningeal Artery
B- Middle Cerebral Artery
C- Posterior Cerebral Artery
D- Anterior Cerebral Artery
Ans: A

Explanation:
Middle meningeal artery is damaged which is branch of maxillary arter

411- Diabetic patient presented with decrea visual acuity. Doctor performed retina laser photocoagulation, It damages?
A- Ganglion layer
B- Nerve fiber layer
C- Outer Layer of retina
D- Photorecptor Layer
Ans: C

412- Singers vocals related muscle is which of following
A- Posterior Cricoarytenoid
B- Vocalis
C- Cricothyroid
D- Thyroarytenoid
E- Cricoarytenoid
Ans: D

413- Major depressor of mandible & angle of mouth?
A- Geniohyoid
B- Buccinator
C- Platysma
D- Masseter
E- Orbicularis Oris
Ans: A

Explanation:
Elevation of Jaw (Close mouth)
- Masseter
- Anterior fibers of Temporalis
- Medial Pterygoid

Depression of Jaw (Open mouth)
- Lateral Pterygoid
- Digastric
- Myelohyoid
- Geniohyoid

414- Tensor Veli Palatini is supplied by:
A- Facial nerve
B- Mandibular branch of trigeminal nerve.
C- Maxillary nerve
D- Inferior alveolar nerve
E- Occulomotor nerve
Ans: B

415- Accumulation of blood due to damage of middle meningeal artery at:
A- Subdural
B- Dura and Clavaria
C- Subarachnoid and Lia
D- Arachnoid and pia
E- Pia and brain
Ans: B

416- Patient is having vertical diplopia and trouble moving downstairs nerve involved will be
A- CN 6
B- CN 2
C- CN 4
D- CN 8
E- CN 3
Ans: C

CamScanner

Explanation:
- Vertical Diplopia – CN 4 >CN3
- 4th nerve palsy – Diplopia on seeing down (vertical).
- 3rd nerve palsy – Diplopia on seeing down (Vertical) and or right and left (horizontal).
- 6th Nerve palsy - Diplopia on seeing right or left (horizontal).

417- A patient complains of dryness of eyes. O/E there was decreased secretion of lacrimal gland. The most likely ganglia involved are:
A- Ciliary ganglion
B- Optic ganglion
C- Pterygo palatine ganglion
D- Submandibular ganglion
E- Superior cervical ganglion
Ans: C

418- A young boy , hit by a ball on temporal region, swelling at temporal region occurs. On x ray linear fracture of parietal bone is seen What's the cause of swelling?
A- Edema due to venous blockage
B- Rupture of Middle Meningeal Artery
C- Bruising
D- Rupture of Anterior Cerebral artery
Ans: B

419- Eyes of a person can't be rotated from adducted position. Which muscle is damaged
A- Medial Rectus
B- Lateral Rectus
C- Superior Oblique
D- Inferior Oblique
Ans: B

Explanation:
- Lateral rectus normally cause abduction of eye
- Medial rectus normally cause adduction of eye
- Due to damage of lateral rectus muscle , medial rectus muscle is enhanced and eyes are fixed in adducted position

420- Boxers hit on the face, temporomandibular joint damaged , now mouth remains in open position, which muscle keeps it in such a way
A- Lateral Ptyregoid
B- Medial Ptyregoid
C- Masseter
D- Temporalis
Ans: A

Explanation:
Lateral pterygoid cause opening of mouth. It is likely other muscle got damaged and lateral pterygoid muscle function is enhanced which leads to opening of mouth.

421- Afferent fibres to ciliary ganglion come frnm:
A- Short cilliary nerves
B- Long cilliary nerves
C- Lacrimal nerve
D- Frontal nerve
E- Occulumotor nerve
Ans: E

422- Superior laryngeal artery and internal laryngeal nerve passes between
A- Thyroid and cricoid
B- Thyroid and arytenoid
C- Hyoid and epiglots
D- Thyroid and hyoid
Ans: D

423- Structure inside cervical fascia is
A- Common carotid artery
B- External jugular vein
C- Subclavian vein
D- Hypoglossal nerve
E- Pharynx
Ans: A

424- Rotational movements of head by
A- Contralateral SCM
B- B/L SCM
C- SCM and scalene anterior
D- Trapezius
Ans: C

425- Level of accessory nerve in posterior triangle of neck is
A- At Erbs point
B- Below Erbs point
C- Above Erbs point
D- Medial to Erbs point
Ans: C

426- GVA nucleus of vagus nerve
A- Nucleus solitarius
B- Nucleus ambiguous
C- Bulbar nucleus
D- Accessory nucleus
Ans: A

Explanation:
Regarding Vagus nuclei
- GVA - Solitarius
- SVA - Solitarius
- GVE - Dorsal motor nucleus
- SVE - Ambigus
- GSA - Spinal nucleus of trigeminal

CamScanner

427- Status of dehydration in a baby can be assessed by palpation of?
A- Posterior fontanelle
B- Lambda
C- Bregma
D- Sagittal suture
E- Pterion
Ans: C

428- Aboy presented with history of Fever, Sorethroat & Diagnosed as a case of Chronic suppurative otitis media.Pus in his middle ear extends to mastoid antrum. Thrombus can form in which of the following dural venous sinuses?
A- Superior Petrosal sinus
B- Transverse Sinus
C- Cavernous Sinus
D- Jugular Bulb
E- Sigmoid sinus
Ans: E

429- A patient presented with Boil of Dangerous area of face. Which one of the following veins transmit this infection from Face to Cavernous sinus?
A- Inferior ophthalmic vein
B- Superior ophthalmic vein
C- Emissary Vein
D- Facial Vein
E- Maxillary Vein
Ans: B

430- Emissary veins pass through?
A- Foramen Lacerum
B- Foramen Rotundum
C- Foramen Ovale
D- Optic Canal
E- Foramen Cecum
Ans: E

431- Optic Canal Compression causes involvement of which of the following?
A- Ophthalmic artery
B- Ophthalmic vein
C- Central retinal artery
D- Central retinal vein
Ans: A

432- Blood supply of Lower third of oesophagus:
A- Superior thyroid
B- Descending thoracic aorta
C- Inferior thyroid
D- Left gastric
Ans: D

433- Inferior thyroid artery is branch of
A- External carotid
B- Thyrocervical trunk
C- Costo cervical trunk
D- Internal carotid
Ans: B

434- Spread of infection to brain is via
A- Diploic viens
B- Emissary veins
C- Internal jugular vein
D- Petrosal venous sinses
E- Dural venous sinuses
Ans: E

435- Which nerve is related to left pulmonary artery and arch of aorta
A- Azygous
B- Phrenic
C- RLN
D- Vagus
E- Accessory nerve
Ans: C

436- In tonsillectomy which structure should be preserved to prevent hypoparathyroidism
A- Superior thyroid artery
B- Inferior thyroid artery
C- Parathyroid artery
D- Tonsillar artery
Ans: B

437- Noise induce causes damageto
A- Organ of corti
B- Outer hair cells
C- Inner hair cells
D- Vestibular cochlea
Ans: B

438- Loudness is determined by
A- Active hair cells on organ of corti
B- Part of Basilar membrane deflection
C- Inactive hair cells on organ of corti
D- Oval window deflection
Ans: B

439- Scalp layer related to infection /pus
A- Skin
B- Connective tissue
C- Aponeurosis
D- Loose areolar tissue
E- Pericranium
Ans: D

CamScanner

440- Injury to greater wing of sphenoid and inferior orbital fissure damages after that patient experiences sensory disturbances in cheek area which nerve is likely damag
A- Oculomotor
B- Trochlear
C- Zygomatic
D- Lacrimal
E- Nasociliary
Ans: C

441- Facial nerve exit skull via
A- Stylomastoid foramen
B- Stapedius
C- Foramen ovale
D- Foramen spinosum
E- Jugular foramen
Ans: A

442- A patient developed midline neck swelling which was diagnosed as Thyroid nodule. Structure most likely damaged during FNAC of this thyroid nodule?
A- Superior thyroid artery
B- Lingual artery
C- Inferior thyroid artery
D- External carotid artery
E- Sympathetic Trunk
Ans: C

443- GVE of Vagus nerve:
A- Hypoglossal nucleus
B- Dorsal motor nucleus
C- Geniculate ganglion
D- Otic capsule
E- Nucleus ambiguous
Ans: B
Explanation:
Regarding Vagus nuclei
- GVA - Solitarius
- SVA - Solitarius
- GVE - Dorsal motor nucleus
- SVE - Ambigus
- GSA - Spinal nucleus of trigeminal

444- Which of following muscle of mastication helps in Deep inspiration during yawning and increase CO ?
A- Medial pterygoid
B- Lateral pterygoid
C- Masseter
D- Supraspinator
E- Buccinator
Ans: B

445- Doctor checking the pulse of which artery between infra hyoid and SCM?
A- Common carotid artery
B- Internal carotid artery
C- External carotid artery
D- Subclavian Artery
E- Inferior Thyroid artery
Ans: A

446- A patient with lipoma on posterior aspect of Sternocleidomastoid, 4 cm posterior in relation to clavicle. Which structure ligated leading to profuse bleeding?
A- External jugular vien
B- Internal jugular vien
C- Thyrocervical trunk
D- 2nd part of subclavian artery
Ans: D

447- Crista galis is extension of which bone
A- Sphenoid
B- Zygomatic
C- Ethmoid
D- Maxilla
Ans: C

448- Sella turcica part of which bone
A- Sphenoid
B- Zygomatic
C- Ethmoid
D- Nasal
Ans: A

449- Patient with epiphoa negative jonesI jones 2 flourescent test what will be next plan
A- Probing
B- Syringing
C- Schirmer test
D- Tear film breakup time
E- Immunoassay of tears
Ans: A

450- A patient has diplopia, eye is adducted and cannot bring back to normal position, most likely damage is
A- Medial rectus muscle
B- Lateral rectus muscle
C- Superior oblique muscle
D- Inferior oblique muscle
Ans: B

451- A patient comes to you with diplopia and internal strabismus (medial squint) loss of parallel gaze, nerve affected will be
A- Trochlear
B- Abducent
C- Oculomotor
D- Trigeminal
Ans: B

CamScanner

452- Hyper flexion of neck is limited by which of following?
A- Ligamentum nuchae
B- Ligament flavum
C- Anterior longitudinal ligament
D- Posterior longitudinal ligament
E- Lateral ligament
Ans: A

453- In Hyper flexion of neck ligament injured is which of following?
A- Ligamentum nuchae
B- Ligament flavum
C- Anterior longitudinal ligament
D- Posterior longitudinal ligament
E- Lateral ligament
Ans: A

454- Muscle of mastication not supplied by mandibular nerve?
A- Lateral pterygoid
B- Med pterygoid
C- Massetor
D- Digastric
Ans: D

455- Nerve damage during submandibular gland surgery:
A- Mandibular nerve
B- Hypoglossal nerve
C- Lingual nerve
D- Glossophyrengeal nerve
E- Inferior alveolar nerve
Ans: C
Explanation:
While doing submandibular gland surgery following nerves damage
- Marginal mandibular nerve branch of facial.
- Lingual nerve.
- Hypoglossal.
- Mylohyoid nerve.
- Mandibular nerve will not be be damage which is branch of trigeminal

456- A patient with Long history of Headache with increase on tilting forward and yellow nasal discharge due to?
A- Chronic sinusitis
B- Nasal polyp
C- Acute sinusitis
D- Allergic Rhinitis
Ans: A

457- Movement of brain with skull limited by
A- Falx cerebri
B- Tentorium cerebelli
C- Vessels
D- Sinus
Ans: A

458- Stylomastoid Canal contains:
A- Facial Nerve
B- Stylomastoid Artery
C- Glossopharyngeal Nerve
D- Facial Artery
Ans: A>B

459- Patinet can't abduct eye then exce abduction, Palpaberal elevation ridiculous sign of extra ocular muscles:
A- Mizuo sign
B- Marcus Gunn Pupil
C- Kocher sign
D- Von graefe sign
Ans: A

460- Blow out fracture of orbit with Proptos and loss of cheek sensation it's due to:
A- Cheek edema
B- Zygomatic bone fracture
C- Infraorbital nerve damage
D- Infraorbital nerve entrapment at its formen
E- Orbital Floor fracture
Ans: C

461- Crista falciformis is a bony projection that separates:
A- Facial nerve from inferior vestibular nerve
B- Vestibular nerve from cochlear nerve
C- Stapedius muscle from chorda tympani
D- Chorda tympani from cochlear nerve
Ans: A
Explanation:
- Bill bar separate Facial nerve from Superior vestibular nerve
- Crista falciformis seprate Facial nerve and Superior vestibular nerves present above Crista falciformis from Cochlear and inferior vestibular nerve present below Crista falciformis

462- A patient presented with complaint of facial tingling, drooling saliva. Lesion is located at:
A- Cerebellopontine Angle
B- Medulla
C- Primary motor area
D- Jugular foramen
Ans: A

463- Structure passing through Foramen Rotundum
A- Maxillary nerve
B- Mandibular nerve
C- Accessory nerve
D- Ophthahmic nerve
E- Oculomotor nerve
Ans: A

CamScanner

464- Optic nerve Carries signals to Brain which are transmitted by the following Nuclues:

A- Somatic Afferent
B- Somatic visceral Efferent
C- Visceral Somatic Effierent
D- Special Viseral Efferent
E- Special Somatic Afferent
Ans: E

465- Nerve supplying Mylohyoid is same as which of the following other muscle?

A- Anterior belly of digastric
B- Posterior belly of digastric
C- Stylohyoid
D- Omohyoid
E- Stemothyroid
Ans: A

466- A pregnant lady was presented in ER with raised bp. Methyldopa was given. What is the mechanism of action of methyldopa?

A- Blocks Neurotransmitter
B- Block Sympathetic CNS
C- Acts on central alpha 2 receptors
D- Direct relaxation of Arteriolar smooth muscle
E- Stimulation of Adrenergic ending at postganglionic fibers
Ans: C

467- Tumor of pituitary gland spreads to which bony structure?

A- Frontal
B- Maxillary
C- Orbital
D- Sphenoid
E- Temporal
Ans: D

Explanation:

- Pituitary tumor invades-sphenoid bone
- Compress cavernous sinus – Laterally
- Compress sphenoid air sinus – Infieriorly
- Compress optic chiasm – Superiorly
- Compress optic nerve – Anteriorly

468- Hyper extension of neck is limited by which of following?

A- Ligament nuche
B- Ligament flavum
C- Anterior longitudinal ligament
D- Posterior longitudinal ligament
E- Lateral ligament
Ans: C

469- Boxers hit on the face, temporomandibular joint damaged, now mouth remains in open position, which muscle keeps it in such a way

A- Lateral Ptyregoid
B- Medial Ptyregoid
C- Masseter
D- Temporalis
Ans: A

Explanation:

Lateral pterygoid cause opening of mouth. It is likely other muscle got damaged and lateral pterygoid muscle function is enhanced which leads to opening of mouth.

470- Patient has tinnitus, facial muscle Paralysis & Hearing loss.Where is the lesion?

A- Stylomastoid foramen
B- Internal acoustic meatus
C- Near nerve to stapedius
D- Cerebellopontine Angle
Ans: D

471- Sphenoid bone artery:

A- Ophthalmic vein
B- Internal carotid artery
C- Abducent nerve
D- Trochlear nerve
E- Ophthalmic artery
Ans: B

472- Most common function of "TRIGEMINAL NERVE":

A- Light reflex
B- Corneal reflex
C- Gag reflex
D- Accommodative reflex
Ans: B

473- Patient presented with eye swelling and acne on nose also severe headache. Most likely related to?

A- Cavernous sinus
B- 3rd nerve
C- 6th nerve
D- 9th nerve
Ans: A

474- Which of the following structures is supplied by the recurrent laryngeal nerve?

A- Cricothyroid
B- Intrinsic muscles of the larynx
C- Epiglottis
D- Subglottis
E- Thyroid
Ans: B

CamScanner

475- A soldier who was frequently exposed to noisy environments now presents with complaints of deafness. Which structure is most likely damaged due to prolonged noise exposure?
A- Outer hair cells
B- Inner hair cells
C- Organ of Corti
D- Basilar membrane
E- Cochlear nerve
Ans: A

476- A female with a history of being hit by a ball to the lower orbital cavity now presents with numbness in her cheek. Which nerve is most likely injured?
A- Superior orbital nerve
B- Inferior orbital nerve```
C- Zygomatic nerve
D- Infraorbital nerve
E- Mandibular nerve
Ans: D

477- Which of the following muscles is innervated by the first cervical nerve (C1)?
A- Mylohyoid
B- Platysma
C- Masseter
D- Geniohyoid
Ans: D

478- Which of the following is involved in the innervation of the oro- and nasopharynx?
A- Glossopharyngeal and Trigeminal
B- Facial and Trigeminal
C- Vagus and Facial
D- Maxillary and Hypoglossal
E. Glossopharyngeal and Vagus
Ans: E

479- To avoid the bitter taste of quinine, which part of the tongue should be prevented from contacting the substance?
A- Anterior
B- Posterior
C- Tip
D- Lateral
Ans: B

480- Infection of danger area of face spread to which of following?
A- Pons
B- Midbrain
C- Cavernous sinus
D- Ethmoidal sinus
E- Pituitary
Ans: C

481- In the posterior triangle of the neck, where can the accessory nerve be palpated?
A- At Erb's point
B- Below 2 cm from Erb's point
C- Above 2 cm from Erb's point
D- At the midpoint of the sternocleidomastoid muscle
Ans: C

482- Which nerve carries the sensory innervation of the dura mater?
A- Trigeminal
B- Facial
C- Glossopharyngeal
D- Vagus
Ans: A

483- A boxer hit on mouth of a person who is unable to open mouth and do protrusion of jaw which muscle is damage?
A- Masseter
B- Temporalis
C- Medial pterygoid
D- Lateral pterygoid
Ans: D

484- A women with history of tongue bite sensations lost from the area of tongue bite due to damage of:
A. Maxillary nerve
B. Lingual nerve
C. Corda tympani
D. Facial nerve
E. Vagus
Ans: B

Explanation:
- Anterior 2/3 general sensation – Lingual nerve
- Anterior 2/3 Taste sensation – Chorda tympani
- Posterior 1/3rd Taste sensation – Glossopharyngeal nerve
- Posterior most part taste sensation – Vagus

485- Patient during eating, increased lacrimation, which nerve involved?
A. Facial
B. Vagus
C. Glossopharyngeal
D- Accessory nerve
E- Hypoglossal nerve
Ans: A

CamScanner

486- A woman develops gaze disturbance. On looking to the right her right eye remains in the middle and also decrease corneal sensations. She also has hearing loss on the right side. Lesion is at:

A- Rolandic fissure
B- Cerebellopontine angle
C- Medulla
D- Temporal lobe
E- Internal auditory meatus

Ans: B

487- Patient reports loss of sensation from the chin down to the supraclavicular region. Which cervical nerve roots are most likely involved in this sensory loss?

A- C1-2
B- C2-3
C- C3-4
D- C5-6
E- C6-T1

Ans: B

488- A 45 years old pt came with sudden onset of facial weakness on examination her taste sensation is lost and unable to move her eyes laterally where does the lesion lies

A- Pons
B- Medulla
C- Midbrain
D- Spinal cord
E- Cerebellum

Ans: A

489- Palpation of artery at TMJ is

A- Temporal artery
B- Maxillary artery
C- Facial artery
D- Lingual artery

Ans: C

490- Which of following structure pass through foramen ovale?

A- Mandibular nerve
B- Maxillary Division of trigeminal
C- Ophthalmic nerve
D- Lingual nerve
E- Middle meningeal artery

Ans: A

Explanation:

- Foramen Ovale – Acessory Meningeal artery pass
- Foramen Spinosum – Middle Meningeal artery pass
- Superior Orbital Fissure – V1 (Opthalmic nerve) pass
- Foramen Rotandum – V2 (Maxillary Nerve) Pass
- Foramen Ovale – V3 (Mandibular Nerve) pass
- Jugular Foramen – CN 9, 10, 11 (Accessory part) & Sigmoid Sinus
- Hypoglossal Canal – CN 12 Foramen Magnum – Brainstem & Spinal Part of CN11

491- Women during robbing resist multiple stab wound on rt side face brought to emergency after primary care dr notice right facial nerve damage which muscle will be paralyzed

A- Geno hyoid
B- Sterno throid
C- Omo hyoid
D- Posterior belly of digastric
E- Anterior belly of diagastric

Ans: D

492- Furunculosis on tip of nose spread to cavernous sinuses via:

A- Inferior Opthalmic vein
B- Maxillary vein
C- Emissiory veins
D- Mandibular vein
E- Superior opthalmic vein

Ans: E

493- Superfascial sheath of Anterior Surface of Thyroid is derived from:

A- Prevertebral fascia
B- Pretracheal fascia
C- Subcutaneous fat
D- Muscles

Ans: B

494- Loss of general sensation in dura of middle cranial fossa due to lesion of:

A- Facial Nerve
B- Glossopharyngeal Nerve
C- Hypoglossal Nerve
D- Trigeminal Nerve
E- Vagus Nerve

Ans: D

495- Abducent nerve damage will cause:

A- Loss of upward gaze and adduction
B- Loss of downward gaze and abduction
C- Loss of downward gaze and adduction
D- Loss of lateral gaze

Ans: D

496- Sympathetic nerves are located in which part of Spinal Cord?

A- Lateral horn
B- Posterior born
C- White matter
D- Gray matter
E- Anterior horn

Ans: A

CamScanner

497- Foramen which opens into Infratemporal fossa:
A- Foramen Cecum
B- Foramen Lacerum
C- Stylomastoid Foramen
D- Sphenopalatine Foramen
E- Foramen Vesculis
Ans: B

498- Lymphatic drainage of Anterior face and scalp?
A- Submental nodes
B- Parotid nodes
C- Submandibular oodes
D- Occipital Nodes
E- Buccal
Ans: C

499- Which nerve pass through Foramen Ovale:
A- Maxillary
B- Opthalmic
C- Facial
D- Glosopharyngeal
E- Mandibular
Ans: E

Explanation:
- Foramen Ovale - -Accessory Meningeal artery pass
- Foramen Spinosum - - Middle Meningeal artery pass
- Superior Orbital Fissure - - V1(Opthalmic nerve)pass
- Foramen Rotandum- - V2(Maxillary Nerve) Pass
- Foramen Ovale - - V3(Mandibular Nerve) pass

500- A man presents with pain radiating from the nose to the inferior orbit and temporal region. Which nerve is most likely involved?
A- Auricular Nerve
B- Maxillary division of Trigeminal nerve
C- Opbthalmic Nerve
D- Nasociliary Nerve
E- Trochlear Nerve
Ans. B

501- Years old kid, Restless & not being able to sleep has been crying continuously. He is pulling his ear. On otoscopy, bulge seen beyond ear drum. Nerve supply of that bulge?
A- Glossopharyngeal nerve
B- Facial nerve
C- Vestibulocochlear nerve
D- Maxillary
E- Mandibular
Ans: A

502- A patient with History of Recurrent Otitis Media.How will surgeon reach mastoid antrum in this case?
A- External auditory meatus
B- Suprameatal Triangle
C- Maxillary Arch
D- Sigmoid Sinus
E- Superior Petrosal sinus
Ans: D

503- Approach to Ear in chronic otitis media
A- Suprameatal triangle
B- External acoustic meatus
C- Internal acoustic meatus
D- Inframeatal triangle
Ans: A

504- A diabetic patient with decreased vision visited an ophthalmologist and underwent laser photocoagulation to prevent further damage. On examination via ophthalmoscope, which area has been affected?
A- Macula densa
B- Retina
C- Cornea
D- Fovea Centralis
E- Lens
Ans: B

505- Normal Suboccipito-Bregmatic Diameter:
A- 9.5cm
B- 11cm
C- 13cm
D- 11.5cm
E- 14cm
Ans: A

506- Volume of Mucous Flow Rate per minute in nasolacrimal duct:
A- 6ml/min
B- 12ml/min
C- 3ml/min
D- 7ml/min
E- 20ml/min
Ans: C

507- A patient presents with right-sided facial palsy, characterized by mouth deviation to the left, drooling of saliva from the right side, right-sided ear pain, and drooping of the right eyelid. There is no ataxia or motor weakness in the extremities. Where is the lesion located?
A- Supra Nuclear lesion
B- Infra Nuclear lesion
C- Pterygopalatine lesion
D- Geniculate Ganglion
Ans: B

CamScanner

508- An unmarried woman presents with a preauricular parotid swelling without fever, cough, ear infection, or cervical lymphadenopathy. What is the next appropriate step in management?

A- Excisional biopsy
B- Incisional biopsy
C- FNAC (Fine Needle Aspiration Cytology)
D- Aspirational biopsy
E- True cut biopsy
Ans: C

509- Which cranial nerve carries taste sensations (e.g., sugar)from the anterior two- thirds of the tongue?

A- Facial nerve
B- Glossopharyngeal nerve
C- Vagus nerve
D- Trigeminal nerve
Ans: A

Explanation:

- Anterior 2/3 general sensation – Lingual nerve
- Anterior 2/3 Taste sensation – Chorda tympani branch of facial
- Posterior 1/3rd Taste sensation – Glossopharyngeal nerve
- Posterior most part Taste sensation – Vagus

510- A patient presented with deep skull wound, surgeon should be careful in suturing which layer that if properly not sutured leave behind large gap and also involve in granulation tissue formation:

A- Skin
B- Fascia
C- Loose areolar tissue
D- Aponeurosis
E- Periosteum
Ans: D(KLM)

Explanation:

- The tension of the epicranial aponeurosis, produced by the tone of the occipitofrontalis muscles, is important in all deep wounds of the scalp.
- If the aponeurosis has been divided, the wound will gape open. For satisfactory healing to take place, the opening in the aponeurosis must be closed with sutures. REFERENCE:KEITH L. MOORE

511- A child can't close his lips due to damage to:

A- Orbicularis Oculi
B- Orbicularis Oris
C- Levator Palpebrae
D- Masseter
E- Lateral Pterygoid
Ans: B(KLM)

Explanation:

Contraction of the orbicularis oris causes narrowing of the mouth, the lips becoming pursed up into the smallest possible circle (the whistling expression).

512- Skin of face is supplied by

A- 5,7,9,10
B- 4,5,7
C- 5,6,7
D- 3,4,5
E- 3,4,5,6
Ans: A

513- Which unpaired cartilage is affected in laryngeal Carcinoma?

A- Thyroid cartilage
B- Arytenoid Cartilage
C- Cuneiform Cartilage
D- Corniculate Cartilage
Ans: A(Dhingra)

Explanation:

Larynx has three unpaired and three paired cartilages.

- Unpaired: Thyroid, cricoid and epiglottis.
- Paired: Arytenoid, corniculate and cuneiform

514- Clicking sound at TMJ due to which of the following

A- Detached Perforated menicus
B- Meniscal tear
C- Osteophytes
D- Dislocation of TMJ
E- Rheumatoid arthritis
Ans: B

515- A female patient has deliver baby with face presentation which of the following is skull diameter of face presentation

A- Suboccipito-bregmatic
B- submento-bregmatic
C- Mentovertical
D- suboccipito-frontal
E- Occipitio-frontal
Ans: B(Ten teachers)

Skull diameter	Presenting part	measurement
Suboccipito-bregmatic	Vertex occipito-anterior	9.5cm
Submento-bregmatic	face	9.5cm
Occipito-mental	brow	13cm
occipitofrontal	Vertex occipito-posterior	11.5cm
Suboccipito-frontal	Vertex occipito-posterior	10cm

CamScanner

515- Omohyoid is supplied by which of the following
A- C1 cervical
B- Ana cervicalis
C- Hypoglossal nerve
D- Facial nerve
E- Trigeminal nerve
Ans: B

516- Cell bodies of Greater petrosal nerve are present in
A- Superficial cervical ganglion
B- Submandibular ganglion
C- Geniculate ganglion
D- Superior salivary nucleus
Ans: D

517- Lymphatic drainage of the ear pinna and forehead involves which of the following lymph nodes
A- Preauricular and submandicbular lymph nodes
B- Preauricular and postauricular lymph nodes
C- Submandibular and cervical lymph nodes
D- Postauricular and supraclavicular lymph nodes
Ans: B

518- Afferents of cough reflex from trachea carried via
A- Vagus nerve
B- Glossopharyngeal nerve
C- Phrenic nerve
D- Trigeminal nerve
E- Hypoglossal nerve
Ans: A

519- Attachment of meningeal dura can be ruptured due to fracture of
A- Squamous part of frontal bone
B- Frontal crest
C- Orbital plate of frontal bone
D- Crista gallis
E- Cribriform plate of ethmoid
Ans: D

520- Which of the following nerve give the motor supply to the tongue
A- Chorta tympni
B- Lingual nerve
C- Trigeminal nerve
D- Hypoglossal nerve
E- Facial nerve
Ans: D

521- A 17-year-old boy presented with epistaxis and nasopharyngeal angiofibroma. Surgeon decided to ligate the culprit blood vessel, which vessel is this?
A- Anterior ethmoidal artery
B- External maxillary artery
C- Posterior Ethmoidal artery
D- Sphenopalatine artery
E- Ascending pharyngeal artery
Ans: E

522- Two days ago in medical school a boy performed two songs in annual function today he presented with hoarseness of voice.Direct laryngoscopy showed "ON ADDUCTION BOWING OF VOCAL CORDS" which muscle is involved here?
A- Cricothyroid
B- Thyroarytenoid
C- Lateral thyroarterinoid
D- Vocalis
Ans: B

523- Patient is having Left sided Visual field defect in upper lateral area due to damage to?
A- Left temporal Meyer's loop
B- Right temporal Meyer's loop
C- Right dorsal radiation at Parietal lobe
D- Left dorsal radiation at Parietal lobe
Ans: B

Explanation:
Visual Lesions:
- Temporal lobe (Meyer loop) involve Lower retina result in Contralateral superior uadrantanopia
- Parietal lobe involve upper retina result in contralateral inferior uadrantanopia.
- Middle Optic Chiasma Lesion - Bitemporal Heteronymous Hemianopia
- Optic Tract Lesion – Homonymous Hemianopia
- Right Optic Tract Lesion - Left Homonymous Hemianopia
- Pituitary Tumor with Homonymous hemianopia – Optic Track lesion
- Pituitary Tumor with Heteronymous hemianopia – Optic Chiasma Lesion
- Right Optic Track Lesion causes – Right Temporal and Left Nasal Fibers loss
- Right Optic Tract Lesion Causes –Right Nasal and Left Temporal Vision loss
- Right Optic Track is made up of – Right Temporal fibers(which See Nasal Vision) and Left Nasal Fibers(which See Temporal Vision) so Fibers loss and vision loss are Separate things

CamScanner

524- A thyroid false capsule is derived from which of the following
A- Carotid sheath
B- Investing layer of the deep cervical fascia
C- Pretracheal fascia
D- Prevertebral fascia
E- Condensation of connective tissue
Ans: C

Explanation:
Thyroid gland capsules
1) **True capsule**
- This is a peripheral condensation of connective tissue of gland and a dense capillary plexus is present deep to it

2) **False capsule**
- It is derived from pretracheal layer of deep cervical fascia that encloses and suspends the thyroid gland and this is responsible of upward movement of goiter on swallowing

525- A Patient presents in OPD after face injuring during boxing now on examination patient cannot whistle ,unable to close eye ,cannot smile which of the following nerve is injured
A- Facial nerve
B- Vagus nerve
C- Maxillary nerve
D- Mandibular nerve
E- Occulomotor nerve
Ans: A

526- A female gynaecologist was taking the class of students about the position of the pelvis she asked what is the diameter of Submentobregmatic diameter
A- 10.5cm
B- 9.5cm
C- 11.5cm
D- 13.5cm
E- 10cm
Ans: B(Ten Teachers)

Explanation:

Skull diameter	Measurement
Suboccipito-bregmatic	9.5cm
Occipito-frontal	11.5cm
Occipito-mental	13cm
Submento-bregmatic	9.5cm

527- Palatine tonsil drains by:
A- Pharyngeal lymph nodes
B- Reteropharyngeal lymph nodes
C- Juglodigastric lymph nodes
D- Omohyoid lymph nodes
Ans: C

528- A male patient was presented with sudden Diplopia and eye pain on examination eye is abducted and down position Which of the following should be done
A- B scan
B- MRI
C- CT scan
D- Xray
Ans: B

529- A diabetic female patient present with swelling on back of her neck on examination there was multiple pus draining sinuses which of the following is your diagnosis
A- Fruncle
B- Carbuncle
C- Lipoma
D- Fistula
Ans: B

530- A 30 year old male patient present with zygomatic bone fracture now in which direction fractured zygomatic bone will displaced
A- Downward into maxillary bone
B- Horizontal into maxillary bone
C- Medial to nasal cavity
D- Upward into orbital cavity
Ans: A

531- The submandibular gland located in submandibular triangle which of the following correctly describes its boundaries
A- Posterior belly of digastric, anterior belly of diagastric , and midline of the neck
B- Anterior belly of digastric, Posterior belly of digastric and hyoid bone
C- Posterior belly of digastric, Anterior belly of digastric and inferior border of mandible
D- Posterior belly of digastric, sternocleomastoid and mid line of neck
Ans: C

532- A truck driver slept near an open window and later presented with the inability to taste,Loss of Nasolabial fold, Forehead wrinkling an expressionless appearance on half of his face, and was diagnosed with Bell's Palsy. Which Nucleus is most likely damaged?
A- Facial Motor Nucleus
B- Lingual nerve
C- Trigeminal Nerve Nasociliary Nucleus
D- Hypoglossal Nucleus
E- Nucleus Solitarius
Ans: A

CamScanner

533- A patient presents with the following findings: Rinne test is negative in the right ear and positive in the left ear.The Weber test lateralizes to the left ear. What is the most likely diagnosis?
A- Conductive hearing loss left ear
B- Conductive hearing loss right ear
C- Sensorineural hearing loss right
D- Sensorineural hearing loss left ear
Ans: B

534- A man develops sudden-onset diplopia, painful ptosis and his eye is turned downward and outward. What is the most appropriate initial investigation?
A- CT brain and orbit
B- Brain scan
C- MRI brain and orbit
D- X-ray orbit
Ans: A

535- To which bony projection on temporal bone behind the Ear?
A- Mastoid Process
B- Petrous Part
C- Styloid process
D- Tympanic Part
E- Occipital Protuberance
Ans: A(KLM Anatomy)

Explanation:
Superior/Medial Attachment of "Sternocleidomastoid":
Lateral surface of the mastoid process of the temporal bone and lateral half of the superior nuchal line

536- Which of the following structure prevent the condyloid process of the TMJ from going back into its cavity
A- Articular Disc
B- Stylomandibular Ligament
C- Pterygomandibular ligament
D- Capsule of TMJ
E- Lateral part of temporomandibular ligament
Ans: E

537- Trigeminal nerve is damaged which reflex is most probably lost
A- Corneal Reflex
B- Accommodation Reflex
C- Light Reflex
D- knee Reflex
E- Ankle reflex
Ans: A

538- Nerve supply of Sternohyoid Muscle
A- Ansa Cervicalis
B- C2
C- C3
D- Facial Nerve
E- Glossopharyngeal nerve
Ans: A

539- Which structure passes through the mandibular canal
A- Inferior alveolar nerve
B- Maxillary nerve
C- Mandibular nerve
D- Lingual artery
E- Mylohyoid nerve
Ans: A

Explanation:
Mandibular canal is inner structure of the mandible ,it is the small canal that contain inferior alveolar artery,inferior alveolar vein and inferior alveolar nerve

540- The submandibular gland located in submandibular triangle which of the following correctly describes its boundaries
A- Posterior belly of digastric, anterior belly of diagastric , and midline of the neck
B- Anterior belly of digastric, Posterior belly of digastric and hyoid bone
C- Posterior belly of digastric, Anterior belly of digastric and inferior border of mandible
D- Posterior belly of digastric, sternocleomastoid and midline of neck
Ans: C

541- A patient presented with complain of unilateral mouth deviation. O/E, he is unable to fill air in cheeks & Unable to close eyes. Nerve involved in Bell's palsy:
A- 7
B- 9
C- 10
D- 3
Ans: A

542- A 60 years old patient presents with B/L nasal obstruction, blood-streaked nasal discharge, and palpable lymph nodes in the neck. What is the most likely diagnosis?
A- Nasopharyngeal carcinoma
B- Nasopharyngeal angiofibroma
C- Nasal Polyp
D- DNS
Ans A

543- During Diving, The diver suddenly got Deafness due to?
A- Negative Tympanic Pressure leading to hemotympanum
B- Rupture of TM
C- Disruption of Ossicles
D- Enlarge ossicles
Ans: B

CamScanner

544- The inion is the part of which bone
A- Highest part of external occipit
B- Highest part of internal occipit
C- Bregma
D- Parietal bone
E- Temporal bone
Ans: A(Grays Anatomy)

Explanation:
The external occipital protuberance (inion. is a palpable bony protuberance located on the posterior midline of the occipital bone

545- After RTA patient presents with dilated pupil which of the following nerve is injured
A- Opthalmic division of trigeminal nerve
B- Optic nerve
C- Occulomotor nerve
D- Facial nerve
E- Sympathetic nerve
Ans: C

546- Which of the following structures is involved in damage of foramen lacerum
A- Greater wing of sphenoid
B- Lesser wing of sphenoid
C- Body of sphenoid
D- Squamous part of temporal bone
Ans: A

Explanation:
The foramen lacerum is bounded in front by the body and adjoining roots of pterygoid process and greater wing of sphenoid bone,posteriolaterally, by the apex of petrous part of the temporal bone and medially by the basilar part of the occipital bone

547- An infection on the lateral check can spread to middle cranial fossa through
A- Pterygoid venous plexus
B- Middle meningeal vessels
C- Inferior opthalmic vein
D- Emissary vein
E- Superior ophthalmic vein
Ans A(Grays Anatomy)

Explanation:
The pterygoid venous plexus consists of copious large calibre veins surrounding the pterygoid segment of maxillary artery.the plexus connects with the facial vein via deep facial vein,with the cavernous sinus through veins that pass through the sphenoidal emissary foramen(of vasalius),foramen ovale and foramen lacerum and with the orbit via inferior ophthalmic veins

548- General visceral efferent of vagus carried by?
A- Dorsal motor nucleus
B- Nucleus ambiguus
C- Hypoglossal nucleus
D- Geniculate Ganglion
E- Otic capsule
Ans: A

549- Nerve supply of soft palate, palatine tonsils, Uvula and pharynx
A- Glossopharyngeal nerve
B- Vagus nerve
C- Trigeminal nerve
D- Mandibular nerve
Ans: A

550- Pain in 3rd molar teeth, left side of the tongue and carried by?
A- Lingual nerve
B- Buccal nerve
C- Inferior alveolar nerve
D- Facial Nerve
Ans: C

551- A young girl is found to have a fixed, dilated pupil. Which nerve is most likely affected?(Medicine Feb 2025)
A- Sympathetic chain
B- Oculomotor nerve (CN III)
C- Optic nerve (CN II)
D- Trochlear nerve (CN IV)
Ans: B

552- In myopia (nearsightedness), where do the light rays focus?(Medicine Feb 2025)
A- In front of the retina
B- Behind the retina
C- On the retina
D- Scattered throughout the eye
Ans: A

553- Patient presents with uvula deviation to the right and palatal depression on the same side. Which muscle remains functional? (Medicine Feb 2025)
A- Palatoglossus
B- Palatopharyngeus
C- Levator veli palatini
D- Tensor veli palatini
Ans: A

554- A young male presents with recurrent episodes of epistaxis and imaging shows a contrast-enhancing mass with infratemporal fossa extension. What is the most likely diagnosis? (Medicine Feb 2025)
A- Juvenile nasopharyngeal angiofibroma (JNA)
B- Nasopharyngeal carcinoma
C- Sinonasal polyposis
D- Inverted papilloma
Ans: A

CamScanner

555- Which of the following cranial nerve nuclei is involved in the regulation of salivation, and its dysfunction can lead to xerostomia (dry mouth) - (Medicine Feb 2025)
A- Trigeminal nucleus
B- Inferior salivatory nucleus
C- Superior salivatory nucleus
D- Facial nucleus
Ans: C

556- What is the preferred method for securing the airway in a patient with suspected cervical spine injury? (Medicine Feb 2025)
A- Tracheostomy
B- Oral endotracheal intubation with cervical immobilization
C- Nasotracheal intubation
D- Fiberoptic bronchoscopy
Ans: B

557- A patient presents with severe eye pain, blurred vision, headache, and nausea. The intraocular pressure (IOP) is elevated, and the anterior chamber is shallow. What is the most likely diagnosis?(Medicine Feb 2025)
A- Chronic open-angle glaucoma
B- Acute closed-angle glaucoma
C- Normal-tension glaucoma
D- Acute open-angle glaucoma
Ans: B

558- Ceruminous glands in the ear are responsible for producing:(Medicine Feb 2025)
A- Sweat
B- Mucus
C- Wax
D- Sebum
Ans: C

559- A 72-year-old patient presents with hoarseness of voice. Indirect laryngoscopy reveals that the vocal cords are not opening. Which muscle is most likely damaged? (Medicine Feb 2025)
A- Cricothyroid
B- Posterior cricoarytenoid
C- Thyroarytenoid
D- Vocalis
E- Lateral cricoarytenoid
Ans: B

560- The lateral nasal artery is most commonly utilized in which of the following surgical procedures?(Surgery Feb 2025)
A- Rhinoplasty
B- Cleft lip repair
C- Septoplasty
D- Cleft palate repair
Ans: D

561- General sensation of middle cranial fossa LOST nerve involved is(Surgery Feb 2025)
A- Occulomotor nerve
B- Trigeminal nerve
C- Facial nerve
D- Optic nerve
Ans: B

562- Vagus nerve carry the visceral efferents from CNS to viscera(Surgery Feb 2025)
A- Smooth muscle of git
B- Skeletal muscles of git
C- Cardiac muscles
D- Facial muscles
Ans: A

563- A woman develops gaze disturbance. On looking to the right her right eye remains in the middle and also decreased corneal sensations. She also has hearing loss on the right side. Lesion is at:(Surgery Feb 2025)
A- Rolandic fissure
B- Cerebellopontine angle
C- Geniculate body
D- Temporal lobe
E- Internal auditory meatus
Ans: B

564- Which part of the tongue primarily detects sweet taste(Surgery Feb 2025)
A- Dorsal surface
B- Posterior surface
C- Lateral surface
D- Tip of the tongue
E- Ventral surface
Ans: D

565- A female patient after thyroidectomy developed hoarseness of voice. Examination reveals vocal cords are in medial position which of the following is most likely damaged?(Gynae & Obs Feb 2025)
A- Posterior Cricoarytenoid
B- Lateral Cricoaretynoid
C- Vocalis
D- Thyroarytenoid
E- Cricothyroid
Ans: A

CamScanner

566- A patient presents with conductive hearing loss and history of having recurrent otitis media for the past three years what is most likely diagnosis?(Gynae & Obs Feb 2025)

A- Cholesteatoma
B- Otosclerosis
C- Tympanosclerosis
D- Serous Otitis Media

Ans: A

567- Which of the following structures drain into superior meatus of the nose?(Gynae & Obs Feb 2025)

A- Frontal and maxillary sinus
B- Posterior ethmoid and sphenoplatine sinus
C- Posterior ethmoid and maxillary sinuses
D- Anterior and posterior ethmoid sinuses

Ans: B

568- A 12 years old boy presents with nasal bleeding, runny nose, facial swelling, proptosis, and loss of smell. CT imaging reveals a mass which is extended into infratemporal fossa, what is likely diagnosis?(Gynae & Obs Feb 2025)

A- Juvenile nasopharyngeal angiofibroma
B- Adenoid hypertrophy
C- Allergic rhinitis
D- Sinonasal polyposis
E- polyp

Ans: A

569- Drooping of the angle of mandible is most commonly associated with injury of which of the following nerve(Gynae & Obs Feb 2025)

A- Marginal mandibular branch of facial
B- Ansa cervicalis
C- Auriculotemporal nerve
D- Temporal branch of facial nerve
E- Chorda tympani

Ans: A

570- Adductor of vocal cord(Gynae & Obs Feb 2025)

A- Posterior circoarytenoid
B- Lateral cricoarytenoid
C- Thyroid cartilage
D- Vocalis
E- Circothyroid

Ans: B(Dhingra ENT)

571- A patient complain of multiple areas of focus at right angles the most likely diagnosis is(Gynae & Obs Feb 2025)

A- Myopia
B- Hyperopia
C- Astigmastism
D- Cataract
E- Presbyopia

Ans: C

Explanation:
Astigmatism:It is the condition of refraction in which a point of light cannot be made a punctate image upon the retina by any spherical correcting lens

572- A patient complain of difficulty reading a book but can see distant objects clearly the likely cause is: (Radiology Feb 2025)

A- Short eye ball(hypemetropia)
B- Long eye ball(myopia)
C- Astigmatism
D- Presbyopia
E- Cataract

Ans: A

Explanation:
Hypermetropia(Far sight)
It is that dioptric condition of the eye in which with the accommodation at rest the incident parallel rays of light come to a focus posterior to the light sensitive layer of the retina
Axial-There is short length of the eye ball
Symptoms:There is blurring of vision for near work
Myopia(short sight)
It is that dioptric condition of the eye in which with the accommodation at rest the incident parallel rays of light come to a focus anterior to the light sensitive layer of the retina
Axial-Increased anterioposterior diameter of globe is the most common cause
Symptoms:Indistinct distant vision is the most common symptom

573- Normal Suboccipito-Bregmatic Diameter (Radiology Feb 2025)

A- 9.5cm
B- 11cm
C- 13cm
D- 11.5cm
E- 14cm

Ans: A

574- During mandibular gland surgery, how can the facial nerve be preserved? (Radiology Feb 2025)

A- By tracing the nerve as it enters field
B- By identifying the nerve at the posterior border of the mandible
C- By avoiding dissection near the submandibular gland
D- By using intraoperative nerve monitoring
E- Nerve stimulation

Ans: B

CamScanner

575- In anterior mandibular nerve damage, which muscle would escape paralysis? (Radiology Feb 2025)

A- Digastric
B- Myelohyoid
C- Omohyoid
D- Medial Pterygoid

Ans: A

576- A patient presents with difficulty in reading, diplopia, and recurrent automobile accidents (peripheral vision loss). He also has headaches relieved by painkillers. What is the most likely diagnosis?(Anesthesia Feb 2025)

A- Open-angle glaucoma
B- Closed-angle glaucoma
C- Optic chiasm lesion
D- Occipital cortex lesion

Ans: C

577- A female was advised eye drops for eye infection. Two days later she complains of sour taste. The drops from eyes go first into? (Anesthesia Feb 2025)

A- Nasopharynx
B- Oropharynx
C- Mouth
D- Nose

Ans: A

578- A child with a recurrent history of tonsillitis undergoes a tonsillectomy. During surgery, bleeding occurs from the right tonsillar artery. This artery is a branch of which vessel? (Anesthesia Feb 2025)

A- Lingual artery
B- Facial artery
C- Ascending pharyngeal artery
D- Descending palatine artery

Ans: B

CamScanner

BACK AND VERTEBRAL COLUMN

1- Intervertebral herniation between 5th and 6th vertebral disc will damage
A- 4th spinal nerve
B- 5th spinal nerve
C- 6th spinal nerve
D- 7th spinal nerve
Ans: C

2- Best site of lumbar puncture:
A- Above L4
B- Above L2
C- Above L3
D- Below L5
Ans: A

3. Commonest site of lumbar puncture is:
A- L4-L5
B- L2-L3
C- S1-S2
D- L1-L2
Ans: A

4- Regarding vertebra
A- Thoracic has kidney shaped
B- C7 has long spine
C- Lumber vertebra have heart shape body
Ans: B

5- Eight thoracic vertebra does not make synovial joints with which of the following structures
A- Head to eighth rib
B- Tubercle of eighth rib
C- Superior articular process
D- Body of seventh thoracic vertebra
Ans: D

6- The movement at the following joint permits a person to look towards the right or left
A- Atlanto-occipital joint
B- Atlanto-axial joint
C- C2-C3 joint
D- C3-C4 joint
Ans: B

7- The following joint permits do not movement of head
A- Atlanto-occipital joint
B- Atlanto-axial joint
C- C2-C3 joint
D- C3-C4 joint
Ans: B

8. The lumbar region of the vertebral column permits all of the following movements except
A- Flexion
B- Extension
C- Lateral
D- Rotation
Ans: D

9- Regarding lumber puncture which one is correct
A- Between L4 and L5
B- CSF pressure in mm of Hg
C- spine fully extended
D- Angle of needle must be 45 degree
Ans: A

10. True about vertebral columns
A- 31 vertebrae
B- 7 cervical vertebrae
C- 30 pairs of spinal nerves
D- 6 lumber vertebra
Ans: B

11- Following is true regarding cervical spinal nerves
A. All part arises from neural crest cells
B. Emerge through intervertebral foramen
C. Dorsal root ganglion is intraspinal
D. C1 has sensory supply
E. C7 nerve leaves through C7-T1 foramen
Ans: B

12- Which is not punctured during lumbar puncture
A- Dura matter
B- Ligmentum flavum
C- Longitudinal spinal ligament
D- Skin
Ans: C

13- True about vertebral venous plexus
A- Has no communication
B- Lies in epidural space
C- Is formed by two vertebral veins
D- none of above
Ans: B

14- In adults, spinal cord ends at
A- L1
B- L2
C- L3
D- L4
Ans: A

CamScanner

15- In neonates,spinal cord ends at the level of lower border of:
A- L2 vertebra
B- L3 vertebra
C- L4 vertebra
D- L5 vertebra
E- S1 vertebra
Ans: A

16- Needle inserted at paramedian vertebral canal pierces
A- Anterior spinal ligament
B- posterior spinal ligament
C- Supraspinal ligament
D- Interspinal ligament
E- Ligamentum flavum
Ans: E

17- Blood supply of vertebral column
A- Vertebral artery
B- Spinal artery
C- Medullary artery
D- All of above
Ans: B

18- Dorsal rami of the carvical nerves innervate
A- Extension of Trunk
B- Stabilizers of shoulders
C- Abductor pollices
D- Extension of limbs
Ans: A

19- Spinal cord is suspended
A- Alar ligment
B- Filum terminate
C- Denticulate ligament
D- Conusmedullaris
Ans: C

20- In internal carotid artery damage.At what vertebral tubercle you will press to stop bleeding
A- 3rd
B- 4th
C- 5th
D- 6th
E- 7th
Ans: D

21- A typical cervical vertebra can be differenciated from thoracic vertebra by
A- Formen transversarium
B- Triangular vertebral canal
C- Heavy vertebral body
D- Superior facet on upper body
Ans: A

22- Vertebra having no Spinous process:
A- T1
B- C1
C- T3
D- T4
Ans: B

23- Fusion of L5 vertebra with S1 vertebra is called
A- Lordosis
B- Lumbarization
C- Scalarization
D- Scoliosis
E- Pot's disease
Ans: C

24- Accessory cervical rib attaches
A- C7
B- T1
C- T2
D- C6
E- C5
Ans: A

25- Heart shaped vertebrae are
A- Thoracic
B- Cervical
C- Lumbar
D- Sacral
Ans: A

26- In unexplained hypotension which part of vertebra should be examined
A- Upper cervical
B- Lumbar
C- Thoracic
D- Lower cervical
Ans: C

27- The iliac crest is palpable at the level of which of the vertebra
A- 12th thoracic
B- 2nd lumber
C- 4th lumbar
D- 1st sacral
E- 5th dacral
Ans: C

28- The C7 vertebra develops from somite:
A- C6
B- C7
C- C6-C7
D- C7-C8
Ans: D

CamScanner

29- All of the following statements concerning the cervical rib are incorrect except
A- It arises from C7 vertebra
B- It can cause compression of 7th cervical artery
C- It doesn't cause compression of subclavian artey
D- Bony lump in the lower part of neck due to cervical rib is never palpable
Ans: A

30- T2 Articulates with
A- Rib 1 and 2
B- Transverse process of 2nd rib
C- Cervical Ribs
D- Rib 2 and 3
Ans: D

31- Ganglion at C7 vertebrae is
A- CervicoThoracic
B- Pterygopalatine
C- Geniculate
D- Sphenopalatine
Ans: A

32- Which ligament supports odontoid process of axis on
A- Posterior longitudinal ligament
B- Anterior longitudinal ligament
C- Tranverse ligament
D- Ligamentum nuchae
Ans: C

33- What is appropiate about denticulate ligament:
A- Joins dura
B- joins adjacent vertebra
C- Extension of dura
D- Extension of filum terminate
E- Extension of Pia matter
Ans: E

34- Women got a blow to the neck region and afterwards pupil reduced in size and cannot be dilated in dark, most likely lesion is at
A- CN4
B- CN6
C- CN3
D- Cervical sympathetic chain
Ans: D

35- In which of following vertebrae involved but not spinal cord
A- Chordorma
B- Anencephaly
C- Meningomyelocela
D- Spina bifida
Ans: A

36- Most medial fibers of erector spinae
A- Attached to spine of vertebra
B- Attached to ligament nuchae
C- Attached to larminae
D- Attached to Traverse spines
Ans: A

37- Sensory nerve supply of back of head at occiput
A- Greater Occipital nerve
B- Lesser Occipital nerve
C- Temporal nerve
D- Aunicular nerve
Ans: A

38- Suboccipital nerve supply
A- Rectus capitus anterior
B- Rectus capitus posterior
C- latissmus dorsi
D- None of above
Ans: B

39- Which of the following nerve is formed by the first vertical third and fourth nerves.
A- Transverse Cervical
B- Auricotemporal
C- Occipital
D- Maxillary
Ans: A

40- Cervical spinal cord contains:
A- Ventral horn
B- medial horn
C- dorsal horn
D- Ventral & dorsal horn
Ans: D

44- Which of the following is present at the level of cervical vertebral 2
A- Middle cervical ganglion
B- Inferior cervical ganglion
C- Stellate ganglion
D- Vertebral ganglion
E- Superior cervical ganglion
Ans: E

45- Number of cervical somites, vertebrae and nerves
A- 7,7,7
B- 7,8,7
C- 8,8,8
D- 8,7,8
Ans: D

46- Dorsal ramus of 2nd cervial nerve:
A- Greater auricular
B- Greater occipital
C- Lesser occipital
D- Supraciavicular
E- tranverse cervical
Ans: B

CamScanner

47- Which muscles cause vertebral column motility
A- Latismus dorsi
B- Deitoid
C- Intercostal muscles
D- Deep back muscles
Ans: D

48- Connection b/w centrum and neural arch is buy:
A- Lamina
B- Pedicle
C- Pedicle and body
D- None of above
Ans: A

49- The cauda equina is defined as:
A- Collection of blood vessels below L1
B- Collection of spinal nerves below L1
C- Collection meningeal tissue below L1
D- Collection of spinal nerves above L1
Ans: B

50- Ligament pierced at last during Epidural is:
A- Posterior spinal ligament
B- Anterior spinal ligament
C- Supraspioous ligament
D- Interspinal ligament
E- Ligamentum flavum
Ans: E

51- After gunshot injury to spinal cord patent cannot extend the knee at which level injury to spinal cord occur at which level:
A- L2-3
B- L3-4
C- L4-5
D- L5-S1
Ans: B

52- Lymphatic drainage At base of T10 vertebral level:
A- Lumbar
B- Vertebral
C- Anterior Axillary
D- Sternal
Ans: C

53- Which vertebrae is with hifid spinous process:
A- Lumbar
B- Thoracic
C- Cervical
D- Sacral
Ans: C

54- Patient with lower backache and pain radiating to thigh and leg . and shows Disc herniation at L4-L5 , Which nerve root is compressed?
A- L3
B- L4
C- L6
D- L5
E- L1
Ans: D

55- Muscles of back are supplied by
A- Dorsal rami
B- Dorsal rami of Spinal nerve
C- Intercostal nerve
D- Long thoracic nerve
E- Accessory nerve
Ans: B

56- Kyphosis is an accentuated or abnormal curvature of which region of the spine?
A- Cervical
B- Thoracic
C- Lumbar
D- Sacral
E- Coccygeal
Ans: B

57- If one does a laminectomy (removing the laminae of two adjacent vertebrae) to expose the spinal cord, which ligament must be removed?
A- Anterior longitudinal
B- Denticulate
C- Ligamentum flavum
D- Ligamentum nuchae
E- Posterior longitudinal
Ans: C

58- Lumber vertebra provides attachment to vertebral column
A- Anterior Longitudinal ligament
B- Posterior Longitudinal ligament
C- Muscles of thigh
D- Transverse abdominis
Ans: A

59- Woman having lordosis this involves which part of vertebrae?
A- Thoracic
B- Spinal
C- Lumbar
D- None
Ans: C

60- For the formation of sacral angle which vertebrae is involved:
A- L1
B- L2
C- L3
D- L4
E- L5
Ans: E

CamScanner

61- Hyperextension of neck, diagnosed as Hangman fracture in which there is:
A- Fracture of Atlas vertebra
B- Fracture of Odontoid process of axis
C- Fracture of Transverse process of axis
D- Fracture of Spinous process of axis
E- Base of skull
Ans: B

62- After an accident patient broke his neck and died of bony fragment going into spinal cord. The fragment of bone is derived from which bone?
A- Atlas
B- Axis
C- C7
D- C6
E- C3
Ans: B

63- Preganglionic sympathetic fibers pass through:
A- Dorsal Rami of spinal nerves
B- Posterior column
C- Anterior column
D- Ventral Rami of spinal nerves
Ans: D

64- Boy involved in Road traffic accident. Hyperextension of Neck resulted in fracture of Atlas & slip to lateral area in that axis. This is most commonly termed as:
A- Hangman fracture
B- Jefferson fracture
C- Galeazzi fracture
D- Benette fracture
E- Monteggia Fracture
Ans: B

65- Herniated disc causing sensory changes in specific dermatome due to compression of
A- Anterior horn
B- Posterior horn
C- Intermediate horn
D- Dorsal ramus
Ans: B

Explanation:
White matter has –
- Tracts and fasciculi

Gray matter has -
- Dorsal horn (sensory)
- Ventral horn (motor)
- Intermediate zone (autonomic neurons T1 - L2 S2 -S4)
- Clarke's nucleus

66- Boy involved in Road traffic accident. Hyperextension of Neck resulted in fracture of Atlas & slip to lateral area in that axis. This is most commonly termed as: of (Medicine Feb 2025)
A- Hangman fracture
B- Jefferson fracture
C- Galeazzi fracture
D- Benette fracture
E- Monteggia Fracture
Ans B

67- Herniated disc causing sensory changes in specific dermatome due to compression of (Medicine Feb 2025)
A- Anterior horn
B- Posterior horn
C- Intermediate horn
D- Dorsal ramus
Ans: B

Explanation:
- White matter has –
- Tracts and fasciculi

Gray matter has
- Dorsal horn (sensory)
- Ventral horn (motor)
- Intermediate zone (autonomic neurons T1 - L2 S2 -S4)
- Clarke's nucleus

68- Muscles of the back are supplied by: (Surgery Feb 2025)
A- Dorsal rami of spinal nerves
B- Dorsal root of spinal nerves
C- Ventral root of spinal nerves
D- Ventral primary rami
E- Lateral branches of Perforating arteries
Ans: A

69- Lumbar puncture needle after passing through intraluminal space passes which structure: (Gyane & Ohs Feb 2025)
A- Posterior spinal ligament
B- Anterior spinal ligament
C- Supraspinous ligament
D- Interspinal ligament
E- Ligamentum flavum
Ans: E

70- Sensory changes in a specific dermatome by a herniated intervertebral disc is due to compression on the (Radiology Feb 2025)
A- Spinal nerve+Posterior root.
B- Posterior Primary ramus
C- Anterior root
D- Anterior Primary ramus
E- Anterior Grey Horn
Ans: A

71- After piercing posterior longitudinal ligament in LP, Which space is reached? (Anesthesia Feb 2025)
A- Epidural
B- Subdural
C- Subarachnoid
D- Dura
Ans: A

CamScanner

MEDIPEDIA

- For Online Practice of Mcq Use Medipedia Application From Play Store
- You can search any Mcq in this App on Search bar
- Exam Oriented Pattern of MCQs in this App
- You Can Save Quiz and continue from same MCQ
- Practice Mock Tests on this App

NEUROLOGY

CamScanner

Autonomic Nervous system

Sympathetic (Thoracolumbar, T1-T12, L1-3)

- Preganglionic Sympathetic –Acetylcholine).
- Postganglionic Sympathetic – NE (Except sweat gland which Has Acetylcholine).

Parasympathetic (Craniosacral, CN 3, 7, 9, 10 and S2 – 4)

- Preganglionic parasympathetic –Acetylcholine
- Postganglionic Parasympathetic –Acetylcholine

Receptors

Ruffini

- Deep static "Pressure"
- Detect warmth
- Encapsulated
- Large receptive field

Miessner

- Light "Touch"
- Low frequency Vibration
- Upto 40Hz Frequency
- Abundant on Fingertip
- On Hairless Skin
- Encapsulated

Pacinian

- High frequency Vibration
- From 40 to 400 Hz Frequency
- Detect Tuning fork Frequency (128Hz)
- Deep "Touch "
- Encapsulated
- Onion like on Subcutaneous Skin

Merkel Disc

- Deep "Static Touch"
- Non Capsulated

Krause

- Detect Cold

Fibers

A Alpha

- Fastest
- Largest
- Ia(Muscle Spindle afferent)
- Ib(Golgi Tendon)

A Beta

- Detect Touch and Pressure
- II Sensory Fibers

A Delta

- Detect Fast pain , Temperature , Touch and pressure
- Carry Cold Sensation
- III Sensory Fibers

B Fibers

- Preganglionic Autonomic Fibers

C Fibers

- Detect Slow Pain and Temperature(Unmylinated)
- Carry Itch Sensation
- Carry Warmth Sensation
- Postganglionic Autonomic Fibers
- IV Sensory Fibers

CamScanner

Rods vs cons

Rods	Cons
Night Vision	Day Vision
Low Resolution	High Resolution
Black Vision	Color Vision
Found in periphery	Found in centre (Fovea)
Many	Few

Muscles fibers

- ✓ Extracusal fibers innervated by alpha motor nueron
- ✓ Intrafusal fibers innervated by Gema motor neuron

Muscle spindle

- ✓ Sensory information about muscle length is received by group Ia (velocity) and group II (static) afferent fibers.
- ✓ When a muscle is stretched (lengthened), the muscle spindle is also stretched, stimulating group Ia and group II afferent fibers.
- ✓ Stimulation of group Ia afferents stimulates α-motoneurons in the spinal cord. This stimulation in turn causes contraction and shortening of the muscle. Thus, the original stretch is opposed and muscle length is maintained.

Intrafusal fibers in muscle spindle

- ✓ Nuclear bag(Ia) detect dynamic changes
- ✓ Nuclear chain(II) detect static changing

Reflexes

Stretch reflex or Myotatic

- ✓ Monosynaptic
- ✓ Knee jerk
- ✓ Ia fibers Synapse on alpha motor neuron cause muscle contraction of Muscle stretched and shorten the muscle result in orignal length and antagonist muscle inhibited

Inverse stretch or Inverse myotatic reflex

- ✓ Golgi tendon
- ✓ Disynaptic
- ✓ Ib fibers stimulate inhibitor interneuron that inhibit alpha interneuron thus cause relaxation of muscle and also activate antagonist muscle

Withdrawal reflex(Flexor)

- ✓ Multisynaptic or polysnyaptic
- ✓ Results in flexion on the ipsilateral side and extension on the contralateral side.
- ✓ II , III and IV fibers

Type	Erlanger-Gasser Classification	Diameter (μm)	Myelin	Conduction velocity	Associated sensory receptors
Ia	Aα	13-20	Yes	80–120 m/s	Primary receptors of muscle spindle
Ib	Aα	13-20	Yes	80–120 m/s	Golgi tendon organ

CamScanner

II	Aβ	6-12	Yes	33–75 m/s	Secondary receptors of muscle spindle All cutaneous mechanoreceptors
III	Aδ	1-5	Thin	3–30 m/s	Free nerve endings of touch and pressure Nociceptors of neospinothalamic tract Cold thermoreceptors
IV	C	0.2-1.5	No	0.5-2.0 m/s	Nociceptors of paleospinothalamic tract Warmth receptors

Sleep
(Guyton, Ganong & FA)

REM sleep:

- ✓ Occur every 90 min (4-6 period occur in Night)
- ✓ Most Dream Occur **(Can be recalled)**
- ✓ Eye movement , **Loss of Muscular Tone**, pupil constriction and Penile Erection occur
- ✓ Associated with Mark Brain Activity
- ✓ Difficult to arouse from Sleep
- ✓ **80%** in Premature infant, 50% in Mature Neonate and 25 % in old Adult
- ✓ Sleep Centre is Locus Coeruoleus and Neurotransmitter is Acetylcholine
- ✓ Beta waves appear (14-80Hz) -- High Frequency and low Amplitude
- ✓ Also Called **Paradoxical Sleep** because person can still be Asleep despite Marked Brain Activity
- ✓ Also Called **Desynchronized Sleep** Because there is lack of synchrony in firing of Neuron Despite Marked Brain Activity
- ✓ Short term memory involve Synaptic changes
- ✓ Long term memory Involve new protein Synthesis and gene activation or (Structural changes)

NREM:

- ✓ **Also Called Slow Wave Sleep**
- ✓ Divided into 4 Stages and specifically stage 4 is more Slow Wave
- ✓ Sleep Centre is Raphe Nucleus and Neurotransmitter is Serotonin > GABA
- ✓ Dream May occur **(Cannot be Recalled)**
- ✓ **N1:** Light Sleep
- ✓ **N2: Deeper** Sleep ,Bruxism
- ✓ **N3:** Deepest Sleep, Sleep walking(Somnambulism) ,Sleep talking(Somniloquy) Night Terror, Bed Wetting and **loss of Vascular Tone**
- ✓ **N4:** Maximum Slowing occur Here
- ✓ **Sleep talking in N3>N2**

EEG Waveforms:

- ✓ **Awake and Eye Close :** Alpha Wave
- ✓ **Awake and Eye open :** Beta Wave (Wave during algebra arithmetic means solving)
- ✓ **N1:** Theta Wave (4-7Hz)
- ✓ **N2:** Sleep spindles (12-14Hz) and K complexes (High Voltage biphasic waves)
- ✓ **N3&4:** Delta Wave (0.5-4Hz) – Low Frequency and High Voltage Wave
- ✓ Theta wave may occur during Stress, N 2 &3 but Predominantly in N1
- ✓ Delta Wave occur during Deep sleep, Infancy and Organic Brain Disease
- ✓ Spindle may Occur During N1 but Predominantly in N2

CamScanner

CSF

- ✓ CSF **Density** is 1.0005.
- ✓ CSF **Specific Gravity** is 1.005.
- ✓ CSF PH is 7.33.
- ✓ CSF is isotonic with serum.
- ✓ CSF has Equal sodium as compared to plasma.
- ✓ CSF has **High** magnesium and chloride as compared to plasma.
- ✓ CSF has **More** Creatinine as compared to plasma.
- ✓ Rest everything is **Low** in CSF as compared to plasma (Protein more Low than glucose)
- ✓ CSF is produced by – Ependymal cells
- ✓ CSF Provides nutrition to – CNS
- ✓ Arachnoid granulations are seen by naked eye
- ✓ Indicator for CSF **Leak -- Beta 2 Transferrin**
- ✓ CSF Has **Cushion** like effect
- ✓ **Maximum determinant** of CSF composition is Ependymal cells
- ✓ **CSF Pressure – 10-20 cm H2O or 60-150mm H2O or 6-15mmhg**
- ✓ CSF production – **20ml/h**
- ✓ CSF production – **450 -500 ml /day**
- ✓ CSF in Ventricle – **150ml**
- ✓ Lateral ventricle to 3rd via Interventricular Foramina of Monro
- ✓ 3rd to 4th via cerebral aqueduct (blockage can cause hydrocephalus)
- ✓ 4th to Subarachnoid space via Foramen Magendie and Foramen Luschka
- ✓ CSF made by choroid plexus (Ependymal cells) in 4th and lateral ventricle
- ✓ CSF absorbed by arachnoid granulations and then drains into Dural venous sinus

Temperature regulation

- ✓ Posterior Hypothalamus activated Via Cold temp and activate Sympathetic which will increase Heating.
- ✓ Anterior Hypothalamus activated via hot temp and activate parasympathetic and will increase Cooling.
- ✓ Overall Temperature regulation – Preoptic Nucleus >Anterior Hypothalamus

Random

- ✓ Erectile tissue of penis comprises on – Muscarinic cholinergic
- ✓ When lights enter retina , the layer of eye is strikes first and goes out? – Photoreceptor layer
- ✓ Evoked potential of anesthesia can be assessed by – Auditory
- ✓ Under 2 years Babinski sign is normal but it disappear after 2 years due to- Myelination of oligodendrocytes
- ✓ process of long term memory involves - Protein synthesis
- ✓ Oligodendrocytes and Astrocytes are both glial cells.
- ✓ Most Numerous Glial cell overall is Astrocytes
- ✓ Most numerous glial cells in Whitematter is Oligodendrocytes.
- ✓ Most Numerous Astrocyte in white matter is Fibrous Astrocyte
- ✓ Most Numerous Astrocyte in Gray Matter is Protoplasmic Astrocyte
- ✓ Basal nucleus of Meynert(forebrain) contains - Acetylcholine
- ✓ Ventral tegmentum, (midbrain) contains - Dopamine
- ✓ Nucleus accumbens(basal ganglia) contains - GABA
- ✓ Locus ceruleus (pons) contains - Norepinephrine
- ✓ Raphe nuclei(brain stem) contains - Serotonin
- ✓ Sensory neurons are – Bipolar
- ✓ In sekeltal muscles neurons present – Multipolar
- ✓ In spinal ganglia neurons present – Pseudo bipolar
- ✓ In retina and cochlea neurons present – Bipolar
- ✓ In nasal epithieleum neurons present – Bipolar
- ✓ Sense organ developed first in fetus – Touch
- ✓ Neagitive firing fibers in brain – Purkunjie cells

CamScanner

- ✓ Hormone released during intermediate term memory – Scrotinin
- ✓ Non – adaptive receptors – Nocireceptors
- ✓ Neurotransmitter of outflow of basal ganglia – GABA
- ✓ Neurotransmitters of Corticostriatal fibers – Glutamate
- ✓ Neurotransmitters of rodes and cones – Glutamate
- ✓ Major neurotransmitter of substantia nigra – Dopamine
- ✓ neurotransmitter of brain stem striatal fibers – Serotinin
- ✓ Fast pain neurotransmitter – Gltutamate
- ✓ Slow pain neurotransmitter – Substance P
- ✓ Pain inhibitory fibers - Enkephalin

CamScanner

1) Fast conduction in myelinated fibers due to:
A- Saltatory conduction
B- Increase Na-k ATPase
C- Increase myofibrils
D- Low Gap junction
Ans: A

2) EEG of a man with relax mind and eyes closed show which EEG waveform?
A- Alpha waves
B- Beta waves
C- Theta waves
D- Delta waves
E- Gama waves
Ans: A (Guyton + Ganong + BRS)

3) Part of brain involved in intelligence is:
A- Frontal lobe
B- Visual lobe
C- Somatosensory association
D- Occipital lobe
Ans: A

4) Preganglionic sympathetic nervous system supplies:
A- Adrenal medulla
B- Iris
C- Sweet glands
D- Kidney
Ans: A

5) Anterior hypothalamus maintains temp effectively by:
A- Cutaneous vasodilation
B- Shivering
C- Vasoconstriction
D- Increase permeability
Ans: A

6) Deep sleep is characterized by:
A- Delta waves
B- Bruxism
C- Loss of muscular tone
D- Penile erection
E- Pupil constriction
Ans: A

7) Which receptor senses vibration?
A- Ruffini
B- Krause
C- Pacinian
D- C fiber
E- Rayanodine
Ans: C

Explanation:
- High frequency vibration – Panician
- Low frequency vibration – Miessner

8) Decrease core body temperature stimulates:
A- Shivering
B- Anterior Hypothalamus
C- Generalized vasodilation
D- Cutaneous Vasodilation
E- Activate Preoptic Nucleus
Ans: A

9) Theta wave will appear in which of the following stage of sleep?
A- NREM 3
B- NREM 1
C- REM
D- Deep Sleep
E- NREM 4
Ans: B (FA + Guyton + Ganong)

Explanation:
- Awake and eye close: Alpha Wave
- Awake and Eye open: Beta Wave
- N1: Theta Wave (4-7Hz)
- N2: Sleep spindles (12-14Hz) and K complexes (High voltage biphasic waves).
- N3 & 4: Delta Wave (0.5-4Hz) – Low frequency and high voltage wave.
- Theta wave may occur during Stress. N 2 &3 but predominantly in N1.
- Delta wave occurs during deep sleep, infancy and organic brain disease.
- Spindle may occur during N1 but predominantly in N2.

10) Pacinian corpuscle function is to detect:
A- High Frequency Vibration
B- Low Frequency Vibration
C- Pressure
D- Light Touch
E- Crude Touch
Ans: A

11) Neuron from substantial nigra pars compacta to striatum is:
A- GABA
B- Glycine
C- Choline
D- Dopaminergic
E- Glutamate
Ans: D

12) Alpha Rhythm on EEG increase frequency due to:
A- Hypoglycemia
B- Hypothyroidism
C- Exercise
D- Low glucocorticoids
E- Low $PaCO_2$
Ans: E (Ganong)

CamScanner

Explanation:

Decrease Frequency

- Hypoglycaemia
- Hypothermia
- Low Glucocorticoids
- High PaCO2(Hypoventilation)

Increase Frequency

- Hyperglycaemia
- Hyperthermia
- High Glucocorticoids
- Low PaCO2 (Hyperventilation)

Note: Some students recall 5th option as Hyperventilation that's also true so if no Low $PaCO_2$ option prefer hyperventilation then. Hypoventilation will be wrong.

13) Low PCO_2 will cause which of the following effect?

A- Decrease Cerebral blood Flow
B- Increase Cerebral blood flow
C- No change in Cerebral blood flow
D- Hyperventilation
E- Tachycardia
Ans: A

14) Clasp knife reflex is exaggerated response of:

A- Muscle spindle
B- Golgi tendon
C- Free nerve ending
D- Proprioceptor
Ans: B

15) Nucleus of REM sleep is:

A- Raphe Magnus nucleus
B- Substantia nigra
C- Thalamus
D- Hypothalamus
E- Locus ceruleus
Ans: E

Explanation:

- NREM sleep centre is located in – Raphe nucleus
- REM sleep centre is located in – PONS (locus ceruleus)

16) Which of the following mechanism prevents heat loss?

A- Cutaneous Vasodilation
B- Vasoconstriction
C- Activation of anterior hypothalamus
D- Activation of preoptic nucleus
Ans: B

17) Deep sea diver ascends suddenly to surface which oxygen toxicity will occur and cause death?

A- Nausea
B- Vomiting
C- Seizure
D- Headache
E- Backache
Ans: C

18) Man got an accident and had complete transection at T1 level he will have:

A- Permanent loss of tendon reflexes below the level of lesion
B- Temporary loss of stretch reflex below the lesion
C- Permanent loss of consciousness above the lesion
D- Permanent loss of Voluntary control of movements above the lesion
E- Temporary loss of conscious proprioception below the lesion
Ans: B (BRS – MCQ 28 in chapter 2)

Explanation:

Transection of the spinal cord causes "spinal shock" and loss of all reflexes below the level of the lesion. These reflexes, which are local circuits within the spinal cord, will return with time or become hypersensitive. Proprioception is permanently (rather than temporarily) lost because of the interruption of sensory nerve fibers. Fibers above the lesion are intact.

19) In voluntary contraction, descending pathways cause excitation of:

A- Alpha motor neurons discharge
B- Both alpha and gamma motor neuron discharge
C- Presynaptic nerves inhibited
D- Postsynaptic nerve inhibited
Ans: B

20) Steady pressure detected by which of the following?

A- Free nerve endings
B- Golgi tendon organ
C- Mesinner corpuscles
D- Ruffini receptor
E- Krause receptor
Ans: D

21) Dysequilibrium response of Autonomic nervous system shown in which of the following?

A- Meniere's disease
B- Hyperhydrosis
C- Cushing reflux
D- Hydrocephalus
E- Raised ICP
Ans: A

22) Which of the following is slowly adapting receptor?

A- Hair Follicle
B- Pacinian
C- Messiner
D- Ruffini receptor
E- Free nerve ending
Ans: D

CamScanner

23) Forceful stretching of muscle is done. Which of the following prevents muscle tear?
A- Muscle spindle
B- Golgi tendon
C- Ruffini
D- Miessener
E- Free nerve ending
Ans: B

24) The amount of heat loss from body depends upon:
A- Temperature of external environment
B- Conduction, radiation, convection
C- Humidity
D- Evaporation
Ans: A

25) Which of the following is released at the synapse between incoming pain fibers and pain inhibitory fibers in spinal cord?
A- Histamine
B- Glutamate
C- Substance P
D- Enkepbalin
E- Substance C
Ans: D

Explanation:
- Fast pain – Glutamate
- Slow pain – Substance – P
- Pain inhibitory – Enkephalin

26) How anterior hypothalamus regulates temperature:
A- By sweating and vasodilation
B- By shivering
C- By vasoconstriction
D- Pilocrection
Ans: A

27) How does posterior hypothalamus regulates temperature?
A- Shivering
B- Vasodilation
C- Sweating
D- Release cytokine
Ans: A

Explanation:
- Posterior hypothalamus activated via cold temp and activate sympathetic which will increase heating.
- Anterior hypothalamus activated via hot temp and activates parasympathetic and will increase cooling.

28) Neurotransmitter of mood is:
A- Dopamine
B- Serotonin
C- Glycine
D- GABA
E- Choline
Ans: B

Explanation:
- Mood – Serotonin
- Emotions – Dopamine

29) The strongest inhibitory signal in central nervous system comes from which neuron?
A- Substansia nigra
B- Pyramidal cells of cerbral cortex
C- Purkinji cells of cerbral cortex
D- Bipolar cells of Cerebellum
Ans: C

30) Regarding microglial cells true is:
A- Are Spider cells
B- Found in grey matter
C- Found in white matter
D- Start activity in inflammatory response
Ans: D

Explanation:
- They first release inflammatory mediators in response to noxious stimuli and then release anti-inflammatory and stop inflammation.
- It is macrophage of CNS

31) A man while walking accidently lands his foot on a pointed object and immediately removed it. Which of the following is involved in withdrawal reflex?
A- Encapsulated receptor
B- Unencapsulated receptor
C- Monosynaptic receptor
D- Multisynaptic receptor
E- Dont involve neuron
Ans: D

Explanation:
- Stretch reflex – Monosynaptic
- Inverse stretch reflex – Disynaptic
- Withdrawal reflex – Multisynaptic

32) Neurotransmiter of basal ganglia output is:
A- GABA
B- Glutamte
C- Serotonin
D- Acetylcholine
E- Glycine
Ans: A

CamScanner

33) Bipolar neuron has how many dendrites:
A- 1
B- 2
C- 4
D- 3
E- 5
Ans: A

34) About Astrocytes action potential what is true?
A- Action potential is generated in hypernatremia
B- Action potential is generated when intracellular NA is increased
C- Action potential is generated with increase extracellular potassium
D- No action potential
Ans: C (FA)
Explanation:
Astrocytes are extracellular K buffer.

35) Seizure activity result of agent which blocks cerebral synaptic action of?
A- Glycine
B- GABA
C- Acetylcholine
D- Norepinephrine
E- Glutamate
Ans: B

36) Norepinephrine is released by:
A- Preganglionic cell bodies
B- Postganglionic sympathetic nerve fibers
C- Postganglionic parasympathetic nerve fibers
D- Preganglionic sympathetic fibers
E- Postganglionic sympathetic fibers supplying sweat glands
Ans: B
Explanation:
- Pre ganglionic sympathetic fibers release- Ach
- Post ganglionic cholinergic sympathetic fibers release- Ach
- Post ganglionic non adrenergic sympathetic fibers release- non adrenaline
- Preganglionic parasympathetic fibers - Ach
- Post ganglionic parasympathetic fibers - Ach

37) When temp of skin reaches 52 degree which receptors are stimulated?
A- Nociceptors
B- Ruffinis
C- Salt buds
D- Nerve endings
Ans: A

38) About parasympathetic true is:
A- Vasoconstriction
B- Relaxation of gall bladder
C- Decrease intestinal motility
D- Pupil constriction
Ans: D

39) Physiological indirect activity of brain:
A- Pupillary reaction
B- Peripheral blood flow
C- Muscle tension
D- Skin constriction
Ans: A

40) Microglial cells in CNS:
A- Are macrophages of CNS
B- Lie in white matter of brain
C- Lie in grey matter of brain
D- Lie in posterior column
Ans: A

41) Chronic cold adaptation occurs through which one of the following mechanisms?
A- Internal pyogens
B- Chemical thermogenesis
C- Formation of brown fat
D- Peripheral vasodilation
E- Peripheral vasoconstriction
Ans: C

42) Cerebral oxygen metabolic rate:
A- 10-20 ml/min/100g
B- 5-6 ml/min/100g
C- 3-4 ml/min/100g
D- 30-40 ml/min/100g
E- 1-2 ml/min/100g
Ans: C
Explanation:
- Brain consumes 20% of total Body oxygen
- Brain oxygen consumption is 3.5 ml/min/100gm of tissue
- Cerebral blood flow – 50ml /min/100gm of tissue
- Glucose extraction is 5mg /min/100gm of tissue

43) REM sleep is characterized by:
A- Sleepwalking
B- Loss of muscle tone
C- Bed wetting
D- Night terror
Ans: B
Explanation:
- Non REM sleep – Loss of vascular tone
- REM sleep – Loss of muscular tone

CamScanner

44) Sweat gland and pilocrector muscles are:
A- Adrenergic preganglionic sympathetic
B- Cholinergic preganglionic sympathetic
C- Adrenergic postganglionic parasympathetic
D- Cholinergic postganglionic sympathetic
Ans: D

45) Withdrawal reflex carried by:
A- Golgi tendon organs
B- Muscle spindles
C- Free nerve endings
D- Nuclear bag fibres
Ans: C

46) Cushing reflex is initiated by:
A- Decrease ICP
B- Increase ICP
C- Increase BP
D- Decrease BP
Ans: B
Explanation:
Cushing reflex triad – increase ICP, Hypertension, bradycardia.

47) The central temperature regulation occurs in:
A- Pons
B- Anterior hypothalamus
C- Medulla
D- Midbrain
Ans: B
Explanation:
- Posterior Hypothalmus activated Via Cold temp and activate Sympathetic which will increase Heating.
- Anterior Hypothalmus activated via hot temp and activate parasymapthetic and will increase Cooling.
- Overall Temperature regulation – Preoptic Nucleus > Anterior Hypothalmus.

48) Vomiting centre Located in:
A- Medulla
B- Midbrain
C- Pons
D- Cortex
Ans: A

49) Itching is carried by which fibers?
A- A alpha
B- Delta fibers
C- C fibers
D- B fibers
Ans: C
Explanation:
- Itching Fibers – C
- Itching Track – Anterior spinothalmic

50) Which of the following receptors is with no adaptation?
A- Pain receptors
B- Baroreceptors
C- Chemoreceptors
D- Pacinin Receptors
Ans: A

51) If temperature of set point increase then there will be increase in:
A- Sweating
B- Shivering
C- BP
D- Vasoconstriction
Ans: B
Explanation:
- If temperature of set point increase (Hypothermic state) then dec. in sweating and inc. in shivering.
- If temperature of body increase (Hyperthermic state) above set point decrease in shivering and increase in sweating

52) Bipolar cells found in:
A- Nasal epithelium
B- Olfactory neuron
C- Anterior Horns
D- Spinal nerve
Ans: B
Explanation:
- Spinal Ganglia – Pseudo unipolar
- Skeletal Muscle – Multipolar
- Olfactory – Bipolar
- Retina and Cochlea – Bipolar

53) Most abundant cells in white matter of CNS are:
A- Microglia
B- Fibrous astrocytes
C- Oligodendrocytes
D- Protoplasmic astrocytes
Ans: C
Explanation:
- Oligodendrocytes and Astrocytes are both glial cells.
- Most Numerous Glial cell overall is Astrocytes
- Most numerous glial cells in White matter is Oligodendrocytes.
- Most Numerous Astrocyte in white matter is Fibrous Astrocyte
- Most Numerous Astrocyte in Gray matter Is Protoplasmic Astrocyte

54) Sympathetic cholinergic discharge occurs in:
A- Salivary glands
B- Lacrimal glands
C- Sweat glands
D- Parotid Gland
Ans: C

CamScanner

55) Which of the following occurs due to sympathetic stimulation?
A- Ciliary muscle contraction
B- Bronchoconstriction
C- Bradycardia
D- Bronchodilation
Ans: D

56) Taste pathway relay in:
A- Raphe nucleus
B- Hypothalamic nuclei
C- Tractus solitrus
D- Locus ceruleus
Ans: C

57) Hormone which increases in darkness?
A- Melatonin
B- GH
C- Cortisol
D- Insulin
Ans: A

Explanation:
✓ Increase in Darkness – Melatonin
✓ Increase during night in NREM – GH
✓ Increase in Early morning – Cortisol

58) Regarding thermo receptor:
A- Large receptive field
B- Small receptive field
C- Long receptive field
D- None
Ans: C

Explanation:
✓ Large Receptive Field – Ruffini corpuscle
✓ Small receptive Field – DCML
✓ Long Receptive field – Lateral spinothalamic Tract

59) Brain metabolite is:
A- CO_2
B- Adenosine
C- Lactat
D- Potassium
Ans: A

60) Neurohypophysis contains secretory granules stored in:
A- Nerveending
B- Pituicytes
C- Kupfer cells
D- Astrocytes
Ans: A

Explanation:
✓ Secreted by – Nerve endings
✓ Stored in – Nerve ending

61) Absorption of CSF occurs in:
A- Arachnoid Granulations
B- Ependymal cells
C- Epidural space
D- Meninges
Ans: A

Explanation:
- Total quality of CSF about – 150ml
- Formed at the rate of – 500ml/day
- Normal pressure of CSF is 60 to 150mm of water
- Formed by choroid plexus of lateral, third and fourth ventricles
- Absorption of CSF in – Arachnoid villi
- CSF leak marker – Beta 2 transferrin
- In CSF chloride and magnesium are more in plasma
- Na+ is equal in serum and CSF
- K+, Ca+, HCO_3, Glucose in low amount in CSF than serum

62) CSF differs from plasma in decreased:
A- Magnesium
B- Chloride
C- HCO_3
D- Protein
Ans: D

Explanation:
- CSF has equal sodium as compared to plasma.
- CSF has high magnesium and chloride as compared to plasma.
- CSF has more creatinine as compared to plasma.
- Rest everything is low in csf as compared to plasma (protein more low than glucose)

63) Maximum concentration in vitreous humour is of:
A- Glucose
B- Anion
C- Cation
D- Water
Ans: D

64) Common astrocyte cells in gray matter:
A- Oligodendrocyte
B- Schwan CE
C- Protoplasmic astrocytes
D- Fibrous Astrocyte
Ans: C

65) Density of CSF:
A- 1.005 -1.009
B- 1.001-1.005
C- 1.0005
D- 1.009
Ans: C

Explanation:
- CSF Density is 1.0005.
- CSF Specific Gravity is 1.005.
- CSF PH is 7.33.

CamScanner

66) Respiratory centre present in:
A- Pons
B- Medulla
C- Midbrain
D- Hypothalmus
Ans: B

67) Herring beur reflux activated by:
A- Irritant receptors in epithelium
B- Stretch receptors
C- Peripheral receptor
D- Thermoreceptors
Ans: B

68) A patient with hypertonic arm increase sensitivity to muscle spindle Flexor muscles stimulated initial resistance then flexed by mechanism:
A- Polysynaptic
B- Flexor reflex
C- Extensor reflex
D- Muscle Spindle
E- Inverse myotactic
Ans: E (BRS)

69) A person sitting in well ventilated room having sweating tachycardia, most likely due to:
A- Mental Stress
B- Heat exhaution
C- Cerebral concussion
D- Exercise
Ans: A

70) Erection and decreased muscle tone occur at:
A- Stage 1 sleep
B- NREM
C- REM
D- Stage 2 sleeps
Ans: C

71) Which nerve fibres carry touch and pressure sensation?
A- Alpha
B- A-beta
C- A-delta
D- C fibres
Ans: B

72) Part of brain involved in REM sleep:
A- Amygdala
B- Reticular formation
C- Hypothalamus
D- Substania nigra
Ans: B

73) Which type of nerve fibre has fast speed?
A- Alpha-fibre
B- Beta fibre
C- Delta fibre
D- C fibre
Ans: A

74) Connective tissue cells are derived from:
A- Neural crest cells
B- Mesoderm
C- Endoderm
D- Ectoderm
Ans: B

75) Satiety and feeding centre located in?
A- Pituitary gland
B- Hypothalamus
C- Basal ganglia
D- Midbrain
Ans: B

76) What is true about sympathetic nervous system?
A- Preganglionic fibres release acetylcholine
B- Release epinephrine
C- Release atropine
D- Postganglionic fibres release acetylcholine
Ans: A

77) Myelin sheath in the CNS is formed by:
A- Astrocytes
B- Schwan cells
C- Oligodendrocytes
D- Grey matter
Ans: C
Explanation:
Mnemonic – COPS
(Myelin sheath in the peripheral nervous system is formed by Schwan cells and in CNS it is formed by oligodendrocytes).

78) Cause of increase blood flow to brain:
A- Exercise
B- Acidosis
C- Hypoxia
D- CO2
Ans: C

79) Ventricles and central canal lined by:
A- Ependymal cells
B- Schwan Cells
C- Oligodendrocytes
D- Astrocytes
Ans: A

80) Fast pain fibers are:
A- C fiber
B- B Fibers
C- A Alpha
D- A delta
Ans: D

CamScanner

81) 512Hz tuning fork placed over head of patient. Receptors involved?
A- Pacinian
B- Merkels
C- Ruffini
D- Free nerve endings
Ans: A

Explanation:
- High frequency vibration -Pacinian
- Low frequency vibration –Meisner

82) Mylein sheath damage what effect occurs?
A- No effect on action potential
B- Loss of action potential
C- Membrane resistance of nodal and internode
D- Increase Action potential
Ans: C

83) Increase cerebral blood flow in which condition?
A- Hypertension
B- Non REM sleep
C- Rest
D- Mentally active
Ans: D

84) Pre ganglanic sympathetic release:
A- Acetylcholine
B- Dopamine
C- Epinephrine
D- Nor epinephrine
Ans: A

Explanation:
Sympathetic (Thoracolumbar, T1-T12, L1-3)
- Preganglionic Sympathetic – Acetylcholine).
- Postganglionic Sympathetic – NE (Except sweat gland which Has Acetylcholine).

Parasympathetic (Craniosacral, CN 3, 7, 9, 10 and S2–4)
- Preganglionic parasympathetic – Acetylcholine
- Postganglionic Parasympathetic – Acetylcholine

85) Iggo dome receptors is Collection of:
A- Ruffni ending
B- Merkel disc
C- Pacinian Corpuscle
D- Free nerve endings
Ans: B

86) Metabolic fuel of brain is:
A- Glucose
B- Fructose
C- Fatty acid
D- Protein
Ans: A

87) Muscle spindle acts through:
A- Alpha motor neuron
B- Increasing and decreasing length
C- Muscle tension
D- Dorsal root C
Ans: A

88) NMJ Neurotransmitter is:
A- ACH
B- Dopamine
C- Norepinephrine
D- Serotonin
Ans: A

89) Beta 2 adrenergic effect:
A- Miosis
B- Bronchodilation
C- Bronchoconstriction
D- Increase HR
Ans: B

90) Immediate effect in cold:
A- Piloerection
B- Sweating
C- Increased physical activity
D- Vasodilation
Ans: A

91) Cerebral perfusion pressure is equal to MAP when?
A- Normal person
B- Dura is opened
C- While lying
D- When there is no increased ICP
Ans: B

Explanation:
- CPP = MAP – ICP (Intracranial pressure)
- When Dura matter is open ICP equals to Atmospheric pressure so
- CPP = MAP

92) CSF pressure of water:
A- 60mm
B- 10-20 mm
C- 25-30 mm
D- 50- 70 mm
Ans: A

Explanation:
CSF Pressure – 10 – 20cm H_2O or 60 – 150mm H_2O or 6-15mmHg.

93) Nocireceptor located in:
A- Pons
B- Medulla
C- Meninges
D- Hypothalamus
Ans: C

CamScanner

94) CSF composition is:
A- PH comparable to ECF
B- Sodium higher in CSF
C- Protein higher in CSF
D- Glucose lower in CSF
Ans: D

95) CSF specific gravity:
A- 1.005 – 1.009
B- 1.004 – 1.008
C- 1.009 – 2.009
D- 1.003 – 1.007
Ans: A

96) Nerve metabolism is blocked by:
A- Cyanide
B- Transferrin
C- Free Radicals
D- Virus
Ans: A

97) Heat loss is controlled by:
A- Vasoconstriction of Skin vessels
B- Vasodilation of Skin vessels
C- Anterior Hypothalamus
D- Preoptic area
Ans: D (Ganong + Guyton + FA)

98) Athlete maximum heat loss through:
A- Vasoconstriction
B- Sweating
C- Shivering
D- Posterior Hypothalamus
Ans: B

99) Melatonin regulates which one of the following:
A- Pigmentation
B- Taste
C- Vision
D- Visual Acuity
Ans: A
Explanation:
Melatonin controls pigmentation changes by aggregation of melanin into the melanocytes within the skin causing the skin to change colour.

100) Which of the following is the effect of catecholamines after injury:
A- Vasodilation
B- Vasoconstriction
C- Increase Permeability
D- None of the above
Ans: B

101) Which of the following is the parasympathetic effect:
A- Increases HR
B- Decreases HR
C- Increase Contractility
D- Increases TPR
Ans: B

102) Fastest control of blood pressure is achieved by:
A- CNS Ischemiac response
B- Chemoreceptors
C- Baroreceptors
D- RAAS
Ans: C

103) Basic mechanism involved in aqueous humor production:
A- Active sodium secretion
B- Active sodium secretion & ultrafiltration
C- Potassium secretion
D- Vessels permeability
Ans: B

104) Local anaesthetic affects which of the following fibers?
A- A fibers
B- B fibers
C- C fibers
D- A delta
Ans: C
Explanation:
1. Type A>B>C affected by – **Pressure**
2. Type B>A>C affected by – **Hypoxia**
3. Type C >B>A affected by – **Anesthesia**

105) Visual accommodation involves:
A- Increase IOP
B- Relaxation of sphincter muscle of iris
C- Contraction of ciliary muscle
D- Increase tension of lens ligament
Ans: C

106) Heat loss in humid environment is through which of the following?
A- Evaporation
B- Convection
C- Conduction
D- Radiation
Ans: B
Explanation:
- If patient is naked heat loss is through: Radiation.
- If patient is naked & lying (Contact with table) then: Conduction.
- If patient is naked & temperature mentioned: Radiation.
- If humidity mentioned: Convection (Convection requires medium & here Humidity is medium)

107) When looking to near object what will increase?
A- Size of pupil
B- Parasympathetic on ciliary
C- Sympathetic on ciliary
D- Both on ciliary
Ans: B

CamScanner

108) When light strikes the eye what happens?
A- Increase cGMP
B- Increase cAMP
C- Increase neurotransmitter Release
D- Increase conversion of cis retinal to all trans retinal
Ans: D

109) Cochlear action potential is generated by:
A- K^+ efflux from the cells
B- K^+ Influx into cells
C- Na^+ efflux from the cells
D- Na^+ influx into cells
Ans: B

110) Aqueous humor is produced by:
A- Non pigmented ciliary epithelium
B- Pigmented ciliary epithelium
C- Iris and lens
D- Ganglion cell layer of the retina
Ans: A

111) Which of the following statements regarding sympathetic and parasympathetic preganglions is true?
A- They are both cholinergic and adrenergic
B- They are neither cholinergic nor adrenergic
C- They are cholinergic
D- They are adrenergic
Ans: C

112) What will be shown on electroencephalograph of an anaesthetic patient?
A- High waves
B- Low waves
C- Iregular waves
D- Flatline
Ans: B

113) Parasympathetic act on SA node via which neurotransmitters?
A- Nor-epinephrine
B- Adrenaline
C- ACH
D- Epinephrine
Ans: C

114) The core body temperature is decreased what will happen?
A- Sweating
B- Shivering
C- Nothing
D- Increase HR
Ans: B

115) Hypophyseal structure receiving signals from hypothalamus via hypophyseal portal system:
A- Neurohypophysis
B- Adenohypophysis
C- Pericytes
D- Infundibulum
Ans: B

116) Grasp reflex in babies is present up to:
A- By the end of 1st postnatal month
B- By the end of 3rd postnatal month
C- By the end of 6th postnatal month
D- Early in 6th postnatal month
Ans: C
Explanation:
Start at term and ends at 6 month.

117) Receptors Abundant on finger tips:
A- Pacinian corpuscles
B- Meissners corpuscle
C- Krause bulb
D- Raffini receptors
Ans: B

118) Most rapidly adapting receptors:
A- Raffini
B- Krause
C- Meissner
D- Hair end organ
Ans: C
Explanation:
Pacinian > Meissner > Hair end organ > Krause.

119) First & important sign of cholinergic overdose:
A- Bradycardia
B- Tachycardia
C- Volume depletion
D- Increase Urinary output
Ans: A

120) Which is not related to pain transmission?
A- Thalamus
B- Substantia Gelatinosa
C- C fibers
D- B fibers
E- Hypothalamus
Ans: E

121) Decrease sympathetic outflow leads to shock due to:
A- Loss of vasovagal tone
B- Decrease vasomotor tone
C- Acidosis
D- Increase CVP
E- Increase cardiac output
Ans: B

CamScanner

122) 1 degree decrease in body temperature. What %age of CMRO2 decreases?
A- 3%
B- 8%
C- 15%
D- 28%
E- 32%
Ans: B

123) Sensory Preganglionic sympathetic fibers are:
A- Whiterami
B- Gray Rami
C- Dorsal Root
D- Dorsal primary ramus
E- Ventral primary ramus
Ans: A

Explanation:
Sympathetic polyneuronal signals starts from Hypothalamus and Pre ganglionic sympathetic reach in lateral or intromedial horn of spinal cord. Then from here these pre ganglionic sympathetic fibres leaves as white rami (name white rami because these fibers are Myelinated). So Intromedial/Lateral horn>White Rami.

124) Parasympathetic Activation causes:
A- Decrease Heart Rate
B- Increase Secretions from various glands of body
C- Relaxation of GIT sphincters
D- Bronchoconstriction
E- Pupillary Dilatation
Ans: C

125) Parasympathetic loss affects which major component of body?
A- Skeletal
B- GIT
C- Light Reflex
D- Vascular smooth muscles
Ans: B

126) Cardiac muscles have sympathetic and parasympathetic these fibers are?
A- Preganglionic autonomic
B- Post ganglionic
C- Preganglionic somatic
D- None
Ans: B

127) Lady accidently cut radial artery which mechanism detects pressure?
A- A alpha
B- A beta
C- A delta
D- C fibers
Ans: B

128) Loss of water by evaporation a insensible loss from body:
A- Controlled by hypothalamus
B- Thermal gradient
C- Remains constant
D- Depends on core body temperature
Ans: D

129) Golgi Tendon Organ detects tension which of the following?
A- Agonists
B- Antagonist
C- Synergistic
D- Agonist & Antagonist
Ans: A

130) Conduction in nerve fibers is slow down due to?
A- Myelinated
B- Non-myelinated
C- Short fiber
D- Membrane resistance
E- Increase diameter
Ans: B

131) The action potential of a neuron:
A- Is initiated by efflux of Na+
B- Is terminated by efflux of K+
C- Declines in amplitude as it moves along axon
D- Results in a transient reversal of concentration gradient of Na+
Ans: B

132) Cushing reflex triad:
A- Hypertension, bradycardia, increase ICP
B- Hypertension, tachycardia, increase ICP
C- Hypertension, bradycardia, increase ICP
D- Hypotension, bradycardia, decrease ICP
Ans: C

133) When patellar tendon hits, which of following occurs?
A- Quadrataus femoris muscle contracts
B- Muscle spindle afferent sends transmissi
C- Golgi tendon sends transmission
D- None
Ans: B>A

134) Man in marathon in July excess sweating collapses cause:
A- Dehydration
B- Heat stroke
C- Heat exhaustion
D- Sun burn
Ans: C

CamScanner

135) Inhibitory neurotransmitter is:
A- Ach
B- GABA
C- Aspartate
D- Glutamate
Ans: B

136) Increase cerebral blood flow by
A- Isoflurane
B- Sevoflurane
C- NO
D- Halothane
Ans: D

137) Anxiety is decreased by the activation of which receptors:
A- Gaba
B- Glutamate
C- Glucocorticoid
D- Nicotinic cholinergic
E- Dopamine
Ans: A

138) Which of these is not synthesized by post ganglionic sympathetic fibers?
A- Ach
B- Dopamine
C- Nor epinephrine
D- Epinephrine
E- L.Dopa
Ans: A

139) Upper and lower limits of cerebral blood flow autoregulation:
A- 25-150ml/min
B- 50-150ml/min
C- 50-200ml/min
D- 75-200ml/min
Ans: B

140) About Sensation in periphery:
A- All must have to pass through reticular formation
B- Half will pass through reticular formation
C- Never pass through reticular formation
D- Depending on modalities some pass while another bypass
Ans: D

141) Neuron peak of Action potential:
A- Electric gradient tend to send Na into the cell
B- Concentration gradient send Na out of the cell
C- Electric gradient tend to send K out of the cell
D- Concentration gradient send K in of the cell
Ans: C

142) Neurotransmitter released in chemical junction by:
A- Ca influx
B- Ca efflux
C- Na influx
D- Hyperpolarisation
Ans: A

143) Regarding Axons:
A- Carry impulses toward the cell bodies
B- Carry impulses away from the cell bodies
C- Carry pain impulses
D- Are several in numbers for multipolar neurons?
E- Are found primarily in the gray matter
Ans: B

144) Preganglionic autonomic fibres are:
A- B fibres
B- C fibers
C- A beta
D- A delta
Ans: A

Explanation:
- Fastest fibers – A alpha
- Fast pain fibers – A delta
- Slow pain fibers – C fibers
- Preganglionic fibers – Beta fibers (True Autonomic)
- Postganglionic fibers – C fibers (Autonomic)
- Pain from fingertip by – A delta
- Proprioception from fingertip – B fiber

145) Beta endorphins produced by:
A- Hypothalamus
B- Post ganglionic nerve fibers
C- Preganglionic nerve fiber
D- Thalamus
Ans: A

146) Neuronal AP is due to:
A- Rapid Ca influx
B- Influx of K
C- Leakage of K
D- Influx of Na^+
Ans: D

147) Free nerve ending are:
A- Detect only pain
B- Encapsulated receptor
C- Non-encapsulated receptor
D- Detect pressure and deep static touch
Ans: C

148) At motor end plate, acetylcholine:
A- Stored in vesicles
B- Calcium in post synaptic cell to release vesicles
C- Destroyed by choline acetylase
D- Opens the acetylcholine gated ion channels which are linked to voltage gates.
Ans: D

CamScanner

149) Motor Cerebral Metabolic Rate for Consumption of Oxygen is.
A- 10% of the total consumption of Oxygen at rest.
B- 20% of the total consumption of Oxygen at rest.
C- 30% of the total consumption of Oxygen at rest.
D- 40% of the total consumption of Oxygen at rest.
E- 50% of the total consumption of Oxygen at rest.
Ans: B

150) Adrenal medulla is supplied by:
A- Adrenergic fibers
B- No autonomic supply
C- Cholinergic fibers
D- Ganglionic effect
Ans: C

151) Polysynaptic reflex arc present in:
A- Cremesteric reflex
B- Triceps
C- Supinator
D- Knee
Ans: A

152) Hot and burning sensation of heat stroke due to:
A- Above 45 degrees
B- Less than 45 degree
C- At 20 degrees
D- At 43 degrees
Ans: A

155) Neurotransmitter in slow wave sleep is
A- Acetylcholine
B- Dopamine
C- Serotonin
D- Norepinephrine
E- Epinephrine
Ans: C

156) REM sleep related to
A- Adrenergic
B- Serotonin
C- Cholinergic
D- GAB Anergic
Ans: C
Explanation:
- REM sleep – Acetylcholine
- NREM (Slow Wave Sleep) – Serotonin > GABA

157) After compensation of starvation, which substance is used by brain?
A- Glucose
B- Ketone bodies
C- Fatty acid
D- Carbohydrate
E- Proteins
Ans: B

180) Neurotransmitter in nigrostrial pathway
A- Ach
B- Dopamine
C- NE
D- Epinephrine
Ana: B

158) Slow wave sleep is characterized by:
A- Active dreaming
B- Teeth grinding
C- Alpha wave
D- Beta wave
Ans: B

159) A patient came in emergency with hypoglycemic coma.What findings will be there?
A- Hypertension
B- Sweating
C- Dehydration
D- Hypotension
E- Bradycardia
Ans: B

160) Sneeze reflex afferent via:
A- Vagus
B- Trigeminal
C- Abdudent
D- Accessory
Ans: B

161) With exception of sweat glands, parasympathetic system cause what?
A- Dec secretions
B- Promote secretions
C- Increase HR
D- Decrease peristalsis
Ans: B

162) Comparision to CSF with plasma is
A- High protein in CSF than Plasma
B- Less glucose in CSF than plasma
C- Hyperinengnesia
D- More ions than Plasma
Ans: B

163) Tactile two point discrimination is done by
A- Merkel's Disc
B- Meissner's Corpuscles
C- Ruffni Corpuscles
D- Pacinian Corpuscles
Ans: B

164) Semicircular canal is for
A- Linear acceleration
B- Vertical acceleration
C- Angular acceleration
D- Head and neck movements
E- Neck movement only
Ans: C

CamScanner

Explanation:
- Linear Acceleration(Bus): Utricle
- Vertical Acceleration(Lift) – Saccule
- Angular Acceleration – Semicircular canal

165) The fibers transmitting slow pain are:
A- A Beta fibers
B- C Fibers
C- A Alpha fiber
D- A Gamma fibers
E- A Delta fibers
Ans: B

166) Patient can't recognize the things (object) touching body with eyes closed, Lesion is at
A- Anterior spinothalamic track
B- Lateral spinothalamic tiack
C- DCML tract
D- Rubrospinal tract
E- CST
Ans: C

167) Boy walking barefoot a pointed object pinches his plantar surface he withdraws suddenly receptors involved:
A- Pancianain
B- Merkel disc
C- Meissner's
D- Free nerve endings
E- Ruffni
Ans: D

168) Velocity of conduction increased 5-50 fold due to large diameter what will be other reason.
A- Na channel increase permeability
B- Increase Na/K ATPase pump
C- Increase length
D- Increase Ca channel
Ans: A

169) EEG of patient show no A wave because patient is
A- Alert and Conscious
B- Drowsy
C- Sleepy
D- Alert with Eye close
Ans: A

170) Basal ganglia composed of
A- Cortex+ Striatum +Subthalamus + Sunstantia nigra
B- Cortex + Globus pallidus
C- Striatum + Globus pallidus + Subthalamus + Substantia nigra
D- Striatum + Subthalamus + Substantia nigra
Ans: C

171) Knee reflex involves which of the following?
A- Merkel disc
B- Pacinaian
C- Meissner
D- Free nerve ending
E- Muscle spindle
Ans: E

172) Noxious stimulus is carried by
A- Lamina I
B- Lamina 2
C- Lamina 7
D- Lamina 4
Ans: A

Explanation:
- **Lamina 1 – 6** – Dorsal (Posterior) Horn
- **Lamina 8 – 9** – Ventral (Anterior) Horn
- **Lamina 7 & 10** – Intermediate Horn
- **Lamina 1** – High threshold mechanoreceptor, noxious stimulus & A delta pain
- **Lamina 2** – C fiber Pain & Substantia gelatinosa
- **Lamina 3 – 4** – Low Threshold mechanoreceptor
- **Lamina 6** – Deepest Layer, Joint skin Signal
- **Lamina 7** – Largest Area, Dorsal Nucleus of Clarke
- **Lamina 10** – Central Canal

173- Dorsal column medial leminiscus link to thalamus via nucleus
A- Ventral postolateral
B- Ventral postomedial
C- Anterior
D- Lateral
Ans: A

174) Ventral spinothalamic carries which sensations
A- Vibration
B- Pain
C- Tickling
D- Propioception
Ans: C

175) Raphe nucleus bas which pain neurotransmitter
A- Substance p
B- Serotonin
C- Encephalin
D- Acetylcholine
Ans: B

176) Organophosphate poisouing causes which effect?
A- Pupil constriction
B- Pupil dilation
C- Increase HR
D- Arrhythmia
Ans: A

CamScanner

177) During Exercise, Max water loss by:
A- Radiation
B- Conduction
C- Sweating
D- Convection
Ans: C

178) What lies posterior to cerebral aqueduct in midbrain?
A- Substantia nigra
B- Red nucleus
C- Pineal gland
D- Tectum
E- Colliculus
Ans: D

179) Post ganglionic sympathetic release:
A- Acetylcholine
B- Epinephrine
C- Norepinephrine
D- GABA
E- Histamine
Ans: C

180) Left anterior spinothalamic tract lesion because which affect
A- Right vibration lost
B- Right muscle joint paralysis
C- Right loss of touch and pressure
D- Right loss of pain and temperature
Ans: C

181) Alpha adrenergic stimulation causes
A- Cardiac stimulation
B- Bronchodilation
C- Pupillary dilation
D- Vasodilation
E- Increase activity of gut.
Ans: C

Explanation:
Sympathetic
- Cause radial muscle contraction result in mydriasis or dilation of pupil (A1)
- Dilate ciliary muscle (Far vision)

Parasympathetic (M Receptor)
- Act on circular sphincter muscle cause constriction or meiosis of Pupil
- Contract ciliary muscle (Near vision)

182) A woman has loss of 2 points discrimination and fine touch in right leg. Which is defective
A- Fasciculus gracilis
B- Dorsal column
C- Fasciculus cuneatus
D- Spinothalamic
Ans: A

183) In Amyotrophic lateral sclerosis patient disease will affects motor system. Which of following part of spinal cord affected
A- Vental horn
B- Dorsal horn
C- Dorsal root
D- Vental spinocerebellar
E- Lateral horn
Ans: A

184) Male had RTA with injury to occipital region now has homonymous hemianopia which structure is damaged?
A- Optic chiasm
B- Optic tract
C- Visual area
D- Lateral geniculate body
E- Optic radiation
Ans: E

185) Sympathetic cholinergic stimulation causes which effect?
A- Increase GIT motility
B- Relaxation of cilliary muscle
C- Pupillary Constriction
D- Accommodation reflex for near vision
E- Dilate blood vessel in skeletal muscle
Ans: E

186) Somniloquy occurs in which phase of sleep cycle:
A- REM
B- NREM
C- NREM 1
D- NREM 2
Ans: D(Prefer N3)

187) Person was frustrated and disappointed after argument with Boss What waves are seen on EEG?
A- Alpha
B- Beta
C- Theta
D- Delta
Ans: C

Explanation:
- It is stress condition so Theta wave
- Awake and Eye Close : Alpha Wave
- Awake and Eye open : Beta Wave
- N1: Theta Wave (4-7Hz)
- N2: Sleep spindles (12-14Hz) and K complexes (High Voltage biphasic waves)
- N3&4: Delta Wave (0.5-4Hz) — Low Frequency and High Voltage Wave
- Theta wave may occur during Stress, N2 &3 but Predominantly in N1
- Delta Wave occur during Deep sleep Infancy and Organic Brain Disease
- Spindle may Occur During N1 but Predominantly in N2

CamScanner

188) When lights enter the retina which layer of eye is strikes first and goes out:
A- Outer plexiform layer
B- Outer nuclear
C- Inner nuclear
D- Photoreceptor layer
Ans: D

189) Erectile tissue of penis comprises of:
A- Alpha adrenergic
B- Muscuranic cholinergic
C- Nicotinic cholinergic
D- Sympathetic muscuranic
Ans: B

190) Wave during algebra arithmetic means solving which wave appear :
A- Alpha
B- Beta
C- Delta
D- Theta
Ans: B

191) Vomiting center Located in:
A- Basal ganglia
B- Tractus solitarius
C- Nucleus ambigus
D- Cortex
E- Falx cerebri
Ans: B(No medulla option)
Explanation:
- Loosely organized neuron that present in medulla include CTZ Within the area postrema and nucleus tractus solitarii

192) Decrease in which neurotransmitter cause anxiety?
A- Glutamate
B- Serotonin
C- Acetylcholine
D- GABA
E- Glycine
Ans: D

193) Evoked potential of anesthesia can be assessed by?
A- Auditory
B- Visual
C- Noxious Stimuli
D- Olfactory
Ans: A

194) Constant blood flow present in
A- Kidney
B- Liver
C- Gut
D- Brain
Ans: D

195) Infants brain EEG finding will be
A- B waves dyssynchronized
B- Delta waves
C- Alpha
D- Beta waves
Ans: B

196) Basal Ganglia ,Substantia & Substantia Nigra Release what to Stop Seziure
A- Serotonin
B- Glycine
C- GABA
D- Epinephrine
Ans: C

197) In Slow wave sleep which is correct?
A- Loss of muscle tone
B- Longer duration than rem sleep
C- Detailed dreaming
D- Similar to REM
Ans: B

198) Sour taste is carried by which receptors?
A- Glutamate
B- Ach
C- ACTH
D- Glycine
Ans: A

199) Depression of parasympathetic causes:
A- Increase heart rate
B- Increase secretion from various glands of body
C- Bronchoconstriction
D- Relaxation of git sphincter
E- Pupillary Construction
Ans: A

200) EEG synchronization is caused by:
A- Nonspecific thalamic nuclei
B- Locus cerulus
C- Nucleus ambiguous
D- Nucleus raphe
E- Dorsal vagus
Ans: B

201- Negative stretch reflex is by
A- Golgi tendon
B- Nuclear bag
C- Free nerve endings
D- Nuclear ends
Ans: A

202- Blood flow to brain:
A- Remains Unchanged throughout
B- Increase by Decrease PH in ECF
C- Not affected by raised ICP
D- Change always
Ans: A

CamScanner

203- Fiber for pain and pressure is:
A- Alpha
B- A alpha
C- Beta
D- Gamma
Ans: C (No option of A beta)

204- An armed officer is habitual of awaking early in morning Circadian Rythm is controlled by which of following?
A- Nerve fiber
B- Lateral Hypothalmus
C- Medial Hypothalmus
D- Suprachiasmatic nucleus
Ans: D

205- Frontal cortex/cerebral lesion will more effect on
A- Pacinian corpuscles
B- Ruffini corpuscles
C- Meisseners corpuscles
D- Golgi tendon organ
Ans: D

206- Neurotransmitter in slow Type C fiber is
A- Glutamate
B- Enkephalin
C- Substance P
D- Histamine
Ans: C
Explanation:
- Fast pain(A delta) – Glutamate
- Slow pain(Typ C) – Substance – P

207- LP of normal patient done what will be findings of CSF to differentiate from plasma?
A- Low Chloride
B- Low magnesium
C- High Sodium
D- Low glucose
E- High Potassium
Ans: D
Explanation:
- CSF has equal sodium as compared to plasma.
- CSF has high magnesium and chloride as compared to plasma.
- CSF has more creatinine as compared to plasma
- Rest everything is low in CSF as compared to plasma (Protein more low than glucose)

208- Sympathetic cholinergic post gunglionic supply is to which of following?
A- Detrusor muscle
B- Sweat gland
C- Adrenal medulla
D- Adrenal cortex
Ans: B

209- True about alpha motor neuron
A- Myelinated
B- Unmyleinated
C- End at motor end plate
D- Terminate in intrafusal fiber of neuromuscular spindle
Ans: A
Explanation:
- Alpha motor neuron are myelinated and terminate in Extrafusal fibers
- Gamma motor neuron terminate in Intrafusal fibers

210- A neurotransmitter of nigrostriatal pathway to caudate nucleus and putamen is:
A- GABA
B- Glycine
C- Dopamine
D- Serotonin
E- Nor epinephrine
Ans: C

211- Myelination of CNS by
A- Schwan cells
B- Oligodendrocytes
C- Astrocytes
D- Fibroblast
Ans: B

212- Climber at high altitude Experience Hypothermia on returning to base camp adapts to cold weather by heat generation due to which of Following
A- Anterior hypothalamus
B- Posterior hypothalamus
C- Lateral hypothalamus
D- Medial hypothalamus
E- Thalamus
Ans: B
Explanation:
- Posterior Hypothalamus activated Via Cold temp and activate Sympathetic which will increase Heating.
- Anterior Hypothalamus activated via hot temp and activate parasympathetic and will increase Cooling.
- Overall Temperature regulation – Preoptic Nucleus >Anterior Hypothalamus

213- Babinski negative usually seen
A- Sleep
B- Coma
C- Lesion of corticospinal tract
D- After 2 Year
Ans: D

CamScanner

214- Antigravity muscles which stabilize you, when you stand are controlled by ?
A- Cerebral cortex activity
B- Basal ganglia
C- Spinal cord
D- Basal Ganglia
E- Medulla
Ans : C

215- A person while awake with eyes closed which waves will he seen on EEG?
A- Alpha
B- Beta
C- Delta
D- Theta
E- Gamma
Ans: A (Guyton + First Aid + Ganong)

216- A patient is unable to perform rapid movements of the hand/ past pointing/ finger nose test?
A- Dysmetria
B- Dysdiadochokinesia
C- Dyslexia
D- Alexia
E- Agraphia
Ans: B

217- REM sleep wave?
A- Beta wave
B- Delta
C- Alpha
D- Gamma
Ans: A (Guyton + Ganong +BRS)

218- A Patient wants to avoid bitter taste of medicine/Tablets what will you tell him
A- Avoid touching anterior part of tongue
B- Avoid touching central part of tongue
C- Avoid touching posterior most part of tongue
D- Compress anterior part and lateral part of tongue
Ans: C

219- Which one directly controls autonomic reflex system of body?
A- Thalamus
B- Hypothalamus
C- Cerebrum
D- Cerebellum
E- Pons
Ans: B

220- Blood brain barrier is formed by:
A- Continuous basment membrane
B- Pericytes
C- Epineurium
D- Capillary endothelium
Ans: D

221- Young medical student holding three books want to hold 4th book from library upon holding the 4th book she drop all the hooks this is most likely due to:
A- Stretch reflex
B- With drawal reflex
C- Inverse stretch reflex
D- Myotonic reflex
E- Myostatic reflex
Ans: C

Explanation:
Stretch reflex (Myotatic) – Monosynaptic
Inverse stretch reflex (Golgi tendon) – Disynaptic
Flexor withdrawal reflex – Multisynaptic.

222- A patient presented with hydrocephalus with dilated ventricles, what are cells that protect brain cells from the fluid?
A- Ependymal cells
B- Endothelium
C- Perineurium
D- Epithelial cells
Ans: B

223- A patient is having resting tremors at rest, he is diagnosed as Parkinson's disease. The lesion is in?
A- Substantia Nigra
B- Subthalamic Nuclei
C- Globus Pallidus
D- Hypothalamus
E- Cortex
Ans: A

224- What type of Wave will be seen on EEG while solving math problems?
A- Alpha waves
B- Theta waves
C- Beta waves
D- Delta waves
E- Gamma waves
Ans: C (FA + Guyton + Ganong)

Explanation:
- Solving maths mean Awake and open eyes
- Awake and Eye Close: Alpha Wave
- Awake and Eye open: Beta Wave
- N1: Theta Wave (4-7Hz)
- N2: Sleep spindles (12-14Hz) and K complexes (High Voltage biphasic waves)
- N3&4: Delta Wave (0.5-4Hz) – Low Frequency and High Voltage Wave
- Theta wave may occur during Stress, N 2 &3 but Predominantly in N1
- Delta Wave occur during Deep sleep, Infancy and Organic Brain Disease
- Spindle may Occur During N1 but Predominantly in N2

CamScanner

225- Olfactory receptors adaption in first second
A- 10%
B- 30%
C- 40%
D- 50%
E- 100%
Ans: D

226- Cranial and spinal nerve both supply:
A- Sensory supply to muscles
B- Motor supply to muscles
C- Supply organs
D- Supply gut
Ans: B

227- Posture maintenance via anti gravity muscles is a function of:
A- Reticulospinal tract
B- Lateral vestibular nucleus
C- Rubrospinal tract
D- Corticospinal tract
E- Tectospinal tract
Ans: B

Explanation:
- Flexor muscle (Gravity) – Rubrospinal and medulloreticular
- Extensor help in standing (anti-gravity) – Vestubulospinal and Ponto reticular

228- Olfactory sensations via 2nd order neuron relay to?
A- Hypothalmus
B- Thalmus
C- Cerebral cortex
D- Pons
Ans: C

229- On direct light in Right eye, right pupil dilates and left constricts What is that?
A- Left Relative afferent pupillary defect
B- Right corneal defect
C- Right Relative afferent pupillary defect
D- Right retina defect
Ans: C

230- Free nerve ending detects which of the following?
A- Pressure
B- Temp
C- Touch
D- Pain
E- Frequency
Ans: D

231- Low frequency vibration detected by:
A- Pacinian
B- Ruffni
C- Krause
D- Miessner
E- Merkel Disc
Ans: D

Explanation:
Ruffini
- Deep static "Pressure"
- Detect warmth
- Encapsulated
- Large receptive field

Miessner
- Light "Touch"
- Low frequency Vibration
- Upto 40Hz Frequency
- Abundant on Fingertip
- On Hairless Skin
- Encapsulated

Pacinian
- High frequency Vibration
- From 40 to 400 Hz Frequency
- Detect Tuning fork Frequency(128Hz)
- Deep "Touch "
- Encapsulated
- Onion like on Subcutaneous Skin

Merkel Disc
- Deep "Static Touch"
- Non Capsulated

Krause
- Detect Cold

232- CSF in normal condition
A- Has 200 protein
B- 10cm water pressure
C- Specific gravity 1.002
D- <3g albumin
Ans: B

Explanation:
- CSF Pressure – 10-20 cm H2O or 60-150mm H2O or 6-15mmhg
- CSF production – 20ml/h
- CSF production – 450 -500 ml /day
- CSF in Ventricle – 150ml

233- The introduction of cold water into one ear may cause giddiness and nausea. The primary cause of this phenomena:
A- Temporary immobilization of otoliths
B- Decreased movement of ampullar crests
C- Increased discharge rate in vestibular afferents
D- Creation of convection currents in endolymph
Ans: D

234- Posterior nucleus of hypothalamus controls:
A- Pressure
B- Vision
C- Temperature
D- Touch
Ans: C

CamScanner

235- **True regarding Inverse stretch reflex:**
A- Disynaptic
B- Reduce muscle tension
C- Control muscle length
D- Control muscle pressure
Ans: **B**

236- **Posterior hypothalamus will cause:**
A- Shivering
B- Sweating
C- Peripheral Vasodilation
D- Stress
Ans: **A**

237- **Typical spinal nerve is a**
A- Parasympathetic nerve
B- Sympathetic nerve
C- Motor nerve
D- Mixed nerve
Ans: **D**

238- **Which one of the following receptor is phasic type?**
A- Golgi tendon
B- Merkel's disc
C- Nociceptors
D- Pacinian corpuscles
E- Ruffini's end organs
Ans: **D**

239- **What is released from raphe Magnus to pain inhibitory fibers in spinal cord?**
A- Vasopressin
B- Serotonin
C- Angiotensin
D- GABA
E- Oxytoxin
Ans: **B**

240- **Endorphin concentrated in which part of brain:**
A- Thalamus
B- Cortex
C- Hypothalamus
D- Basal Ganglia
Ans: **C**

241- **Thirst is activated hy which of the following?**
A- Intercellular decrease volume
B- Extracellular decrease volume
C- Plasma expansion
D- Increase Interstitial fluid
Ans: **B**

242- **Along with thermo receptors pain receptors are also stimulated for sensation of:**
A- Cold
B- Hot
C- Warmth
D- Freezing cold
E- Crude pressure
Ans: **D**

243- **Olfactory pathway involves:**
A- Mitral cells to olfactory cortex
B- Mitral cells to thalamus to olfactory cortex
C- Ganglion cells to hypothalamus
D- Mitral cells to Hypothalamus then thalamus
Ans: **A**

244- **What is the function of pacinian receptors to detect**
A- Warmth
B- Cold
C- Temp
D- Transient vibration
E- Touch
Ans: **D**

245- **Ligand gated ion channels act on which receptors**
A- GABA-A
B- GABA-B
C- Glutamate
D- Glutamine
Ans: **A**

246- **A lady cut her finger by knife while working in kitchen which fiber detect pressure?**
A- A delta fibers
B- Pre ganglionic alpha fibers
C- Post ganglionic C fibers
D- Alpha fiber
E- A beta fibers
Ans: **E**

247- **Most rapidly adapting receptors?**
A- Touch
B- Pain
C- Pressure
D- Baroreceptors
Ans: **D**

248- **Hypothermic cooling is most tolerated at**
A- <69 Fareheit
B- 70-74
C- 75-79
D- 80-84
E- 85-89
Ans: **E**

249- **A hoy daily go to office and has problem in sleep Melatonin and ACTH are involved in circadian rhythms. Which part is responsible for regulating circadian rhythms and sleep awake cycle?**
A- Supraoptic nucleus
B- Pre optic nucleus
C- Suprachaismatic nucleus
D- Para optic nucleus
Ans: **C**

CamScanner

250- Which one will cause shivering?
A- Anterior hypothalamus
B- Thalamus
C- Posterior pituitary
D- Pons
Ans: C

251- Posture is maintained during moderate exercise through:
A- Increased HR
B- Increased venous return
C- Proprioception
D- Rubrospinal tract
E- Decrease pulse
Ans: C

252- A person saw lion what will happen:
A- Parasympathetic activation
B- Sympathoadrenal activation
C- Bronchoconstriction
D- Increase Gut motility
Ans: B

253- Blood brain barrier is formed by:
A- Continuous basement membrane
B- Pericytes
C- Epineurium
D- Astrocytes foot processes
Ans: D
Explanation:
- Blood-brain barrier—formed by capillary endothelium with tight junctions; astrocyte foot processes contribute.

254- Withdraw reflex is?
A- Synaptic
B- Mono synaptic
C- Prepotent
D- Di synaptic
Ans: C
Explanation:
- Stretch reflex (Myotatic) – Monosynaptic
- Inverse stretch reflex (Golgi tendon) – Disynaptic
- Flexor withdrawal reflex – Multisynaptic or Prepotent

255- A patient has complaint of headache due to high ICF. CSF is example of:
A- ECF
B- Plasma
C- Interstitial fluid
D- Transcellular fluid
E- ICF
Ans: D

256- Spinocerebellar tract – Function is:
A- Equilibrium
B- Vision
C- Initiation and planning of movements
D- Smoothens and co-ordinates movement
Ans: D

257- Muscarinic on effector:
A- Sympathetic post ganglionic
B- Parasympathetic post ganglionic
C- Sympathetic preganglionic
D- Autonomic
Ans: B

258- In increase CSF pressure hypertension is due to which mechanism:
A- Autoregulation
B- CNS ischemic responce
C- Increase cardiac output
D- Cushing reflex
Ans: D

259- Inhibition of a presynaptic neuron is primarily due to which phenomenon in the axon?
A- Hyperpolarization
B- Conduction block
C- Depolarization
D- Repolarization
E- Axonal oscillation
Ans: A

260- Parasympathetic leads to which of the following?
A- Decrease Airway resistance
B- Airway Constriction
C- Decrease Bronchoconstriction
D- Increase Heart rate
Ans: B

261- Patient presented with severe headache on Lp blood in csf found Diagnose is:
A- Blood in epidural space
B- Blood in sub arachnoid space
C- Blood in subdural space
D- Blood in arachnoid granulations
Ans: B

262- REM sleep deprivation is due to:
A- Personality changes.
B- Alzhimer symptoms
C- Anxiety
D- Improvement in depression
Ans: D
Explanation:
- Normally Depression increase total REM sleep thus improvement in Depression will cause decrease REM sleep.
- Alcohol, benzodiazepines, and barbiturates other anti-depressant are associated with decrease REM sleep and delta wave sleep as they improve depression.
- Norepinephrine also decrease REM sleep

CamScanner

263- Lateral to 3rd ventricle CSF flow by?
A- Foramen of monro
B- Aqueduct
C- Foramen Magnum
D- Foramen Magande
Ans: A

264- Student has viva exam what waves are seen on EEG?
A- Alpha
B- Beta
C- Theta
D- Delta
Ans: B

265- A patient has CVA now has zero power in muscles. Which of the sensory receptors are not functioning in this patient?
A- Nociceptors
B- Pacinian receptors
C- Meissner cells
D- Merkel cells
E- Golgi tendons
Ans: A

266- Thick saliva is caused by which receptor which are same as in Adrenal gland:
A- Alpha 1
B- Alpha 1 Beta 1
C- Beta 1
D- Alpha 2
Ans: B

267- Slow writhing movement is called:
A- Chorea
B- Hemiballismus
C- Parkinson
D- Athetosis
Ans: D (FA)

268- Regarding warmth receptors:
A- Large Receptive Field
B- Adopt Quickly To Change in Temperature
C- Delta fibres
D- Short Receptive Field
Ans: A

269- A patient had stroke and now on Doppler he has increased blood flow what is the reason for this increase iu cerebral blood flow?
A- Decreased po2
B- Increased pco2
C- Increase o2
D- Increase N2
Ans: B

270- After dark adaptation what will occur?
A- Improve vision in central part
B- Improve vision in peripheral part
C- Decrease cone sensitivity
D- None
Ans: B

271- Tickle sensation is carried by which fibres:
A- B fibres
B- C fibres
C- A delta
D- Gamma
Ans: B

272- First step in CSF formation by choroid plexus is:
A- Active sodium secretion
B- Active sodium secretion & ultrafiltration
C- Potassium secretion
D- Vessels permeability
Ans: B

273- Peripheral nerve damaged, nerve will regenerate at the rate of:
A- 0.1 mm/day
B- 0.3 mm/ day
C- 10mm/day
D- 0.4 mm/ day
E- 1.2 mm/day
Ans: B

274- Normal person at 104 F room temp and 10% humidity loses beat by:
A- Conduction to air
B- Convection
C- Radiation
D- Conduction to objects
E- Evaporation
Ans: B

275- Cerebral blood flow at rest:
A- 25ml/100mg/min
B- 50ml/100mg/min
C- 75ml/100mg/min
D- 100ml/100mg/min
E- 150ml/100mg/min
Ans: B

276- Exicito toxic neurotransmitte ls:
A- Glycine
B- Ach
C- Glutamate
D- GABA
Ans: C

277- Which receptors are responsible for Erection?
A- Nicotinic
B- Muscarinic
C- Beta adrenergic
D- Alpha adrenergic
E- Dopamine
Ans: B

CamScanner

278- Temperature 106 Degrees farenheit & humidity 10%, Heat loss from the body will be through
A- Evaporation
B- Conduction
C- Convection
D- Radiation
Ans: C

279- Mediator of Deep Sleep?
A- Serotonin
B- Epinephrine
C- Norepinephrine
D- Melatonin
E- GABA
Ans: A

280- Which of the following occurs due to parasympathetic stimulation?
A- Ciliary muscle Relaxation
B- Bronchoconstriction
C- Tachycardia
D- Bronchodilation
Ans: B

281- Which of the following is involved in pain inhibitory pathway in spinal cord in raphe magnus nucleus?
A- Serotonin
B- Glutamate
C- Substance P
D- Enkephalin
E- Substance C
Ans: D

282- Drainage of CSF occurs in:
A- Arachnoid Granulations
B- Ependymal cells
C- Epidural space
D- Meninges
E- Diploic veins
Ans: A

283- A person awake from his sleep and starts walking this is termed
A- Bruxism
B- Somnabulism
C- Nacroplexy
D- Somniloquoy
Ans: B
Explanation:
- Sleep walking- Somnambulism
- Sleep talking-Somniloquy

284- Depletion of Serotonin and Nor adrenaline will cause
A- Increase duration of REM sleep
B- Decrease of REM sleep with normal NREM
C- Absence of sleep (Insomnia)
D- Decrease of NREM sleep with prolonged REM sleep
Ans: A

285- The most characteristic of REM sleep is
A- Sleep walking associated with it
B- Benzodiazepenes decreases interval of it
C- Night mairs only occur in REM sleep
D- Depression decrease REM sleep
Ans: B

286- Initiation of REM sleep is by
A- Raphe nucleus
B- Amygdala
C- Hypothalamus
D- Substantia nigra
E- Reticular formation
Ans: E

287- Adrenal gland releases secretion with the help of which receptor
A- Muscarinic cholinergic
B- Nicotinic cholinergic
C- Adrenergic beta 1
D- Muscuranic adrenergic
E- Adrenergic beta 2
Ans: B

288- Excitatory neurotransmitter at postganglionic sympathetic synapse:
A- Acetylcholine
B- Epinephrine
C- Dopamine
D- Dobutamine
E- Norepinephrine
Ans: E

289- Which of the following is true regarding Cerebral blood flow:
A- Equal in all areas of brain
B- Increases with Hypoxia
C- Increases with Decreased PCo2
D- None of these
Ans: B

290- The fibers transmitting pain and pressure are:
A- A Beta fibers
B- C Fibers
C- A Alpha fiber
D- A Gamma fibers
E- A Delta fibers
Ans: E

291- Sleep walking is termed as:
A- Somnolence
B- Somnambulism
C- Somniloquy
D- Hypnagogism
Ans: B

CamScanner

292- A patient having temperature of 99F, cold clammy skin, sweating profusely, and working on a hot day, brought to the hospital in semiconscious state is most likely due to:

A- Heat Stroke
B- Dehydration
C- Hyponatremia
D- Normal phenomenon
E- Excessive sweating

Ans: B

293- Child awake from Sleep and starts walking it is termed as:

A- Somnolence
B- Somnambulism
C- Somniloquy
D- Hypnagogism

Ans: B

Explanation:

- Sleep walking -Somnambulism
- Sleep talking- Somniloquy

294- A lady cut her finger by knife while working in kitchen which by which mechanism her vasomotor response increases

A- Post ganglionic A delta fibers
B- Pre ganglionic alpha fibers
C- Post ganglionic C fibers
D- A nerve fibers
E- Preganglionic A beta fibers

Ans: C

Explanation:

Post ganglionic C fibers are autonomic fibers that cause vasomotor response to injury

295- Regarding REM sleep true is

A- Bed wetting
B- No active dreaming
C- Beta waves
D- GH increase
E- Night walking

Ans: C

296- Sensory Preganglionic sympathetic fibers travel through

A- Gray ramus
B- White Ramus
C- Dorsal Root
D- Dorsal primary ramus
E- Ventral primary ramus

Ans: B

Explanation:

Sympathetic polyneuronal signals starts from Hypothalamus and Pre ganglionic sympathetic reach in lateral or intromedial horn of spinal cord. Then from here these pre ganglionic sympathetic fibres leaves as white rami (name white rami because these fibers are Myelinated). So Intromedial/ Lateral horn>White Rami

297- Polysynaptic synapses is related to

A- Knee jerk
B- Ankle jerk
C- Bicep jerk
D- Cremastaric reflex
E- Withdrawl reflex

Ans: D

298- When ICP raised, the systemic bp also raised, this help to maintain cerebral blood flow, this response involves???

A- Baroreceptor reflex
B- CNS ischemic response
C- Cushing reflex
D- Chemoreceptors

Ans: C

299- Endorphin concentrated in which part of brain:

A- Thalamus
B- Cortex
C- Hypothalamus
D- Basal Ganglia

Ans: C

300- The type of neuron present in spinal sensory ganglia is ?

A- Golgi type 1
B- Pseudo unipolar
C- Multiple
D- Bipolar
E- Unipolar

Ans: B

Explanation:

- Spinal Ganglia or dorsal root ganglia – Pseudo unipolar
- Skeletal Muscle – Multipolar
- Olfactory – Bipolar
- Retina and Cochlea – Bipolar

301- During exam preparation pupil dilated,eyes stay at one place for long time heart beat fast due to which system

A- Sympathetic
B- Parasympathetic
C- Splanchnic
D- Somatic

Ans: A

302- True regarding Heart muscle:

A- Autonomic supply
B- Striated
C- Get Fatigued Easily
D- Somatic Nerve Supply

Ans: A

CamScanner

303- 21 years old male has been sleeping normally for the last 5 hours. His skeletal muscle tone and stretch reflexes are reduced. His EEG activity shows rapid, low voltage irregular activity. Another EEG finding in him is ponto geniculo occipital spikes. Apart from these which other feature is most likely to be present.

A- Enuresis
B- Night terrors
C- Penile errection
D- Sleep spindles
E- Somnambulism
Ans: C (REM sleep)

304- Different Color perception in cortex due to?

A- Discriminatory center
B- Visual cortex
C- Optic radiation
D- Optic tract
Ans: B

305- Polysynaptic synapses is related to

A- Knee jerk
B- Ankle jerk
C- Bicep jerk
D- Cremastaric reflex
E- Withdrawl reflex
Ans: D

Better

306- In CSF formation, Ist step is:

A- Filtration of Na
B- Filtration of K
C- Filtration of Mg
D- Filtration of Chloride
Ans: A

307- In stroke patient doppler showed increase perfusion, by which metabolite?

A- Decreased O2
B- Capillary vasoconstriction
C- Decreased pCo2
D- Local metabolite
E- Decreased Extracellular potassium
Ans: A

Explanation:

- Decrease O2 leads to increase CO2 which leads to increase perfusion

308- Most numerous glial cells in gray matter of CNS are:

A- Microglial cells
B- Fibrous astrocytes
C- Oligodendrocytes
D- Protoplasmic astrocytes
E- Schwann Cells
Ans: D

Explanation:

- Oligodendrocytes and astrocytes are both glial cells.
- Most numerous glial cell overall is astrocytes
- Most numerous glial cells in white matter is oligodendrocytes.
- Most numerous astrocyte in white matter is fibrous astrocyte
- Most numerous astrocyte in gray matter is protoplasmic astrocyte

309- Surgeon while doing surgery requires skill full coordination of hands and mind. Which of the following is important in this?

A- Premotor Cortex
B- Parietal Cortex
C- Sensory Feeback system
D- Control of Voluntary movement during surgery
E- Basal Ganglia
Ans: C

310- After sleeping, there is pupil constriction, Inc salivation, Inc gastric motility. These changes are due to involvement of :

A- Parasympathetic autonomic system
B- Sympathetic autonomic system
C- Somatic nervous system
D- Enteric Nervous system
Ans: A

311- Receptor detects pressure despite continuous pressure- Which property of nerves help them to detect continuous stimuli?

A- Adaptation
B- Modality
C- Conductivity
D- Receptivity
E- Transduction
Ans: A

312- Ventricles and central canal lined by Which cells which produce Cerebrospinal fluid?

A- Ependymal cells
B- Schwan Cells
C- Oligodendrocytes
D- Astrocytes
Ans: A

313- Ventricles and central canal lined by Which cells which produce Cerebrospinal fluid?

A- Ependymal cells
B- Schwan Cells
C- Oligodendrocytes
D- Astrocytes
Ans: A

better

CamScanner

314- In an infant, when skin of the lateral border of sole of the foot is scratched with a blunt pointed object, there is:
A- Dorsiflexion of the big toe
B- Flexion at the knee
C- No response
D- Planter flexion of all the toes
E- Planter flexion of the big toe
Ans: A

315- A lady cut her finger by knife while working in kitchen which by which mechanism her vasomotor response increases
A- Post ganglionic A delta fibers
B- Pre ganglionic alpha fibers
C- Post ganglionic C fibers
D- A nerve fibers
E- Preganglionic A beta fibers
Ans: C

Explanation:
- Post ganglionic C fibers are autonomic fibers that cause vasomotor response to injury

Better

316- The most characteristic of REM sleep is
A- Sleep walking associated with it
B- Benzodiazepenes decreases interval of it
C- Night terrors only occur in REM Sleep
D- Depression decrease REM sleep
Ans: B

317- The sympathetic nervous system increases blood pressure primarily by which of the following mechanisms?
A- Vasoconstriction of skeletal muscle
B- Decreasing heart rate
C- Dilating coronary arteries
D- Increasing venous return
E- Relaxing smooth muscle in large arteries
Ans: A

318- Which type of receptors are found in the inner ear and are responsible for detecting sound and balance?
A- Photoreceptors
B- Mechanoreceptors
C- Chemoreceptors
D- Nociceptors
E- Thermoreceptors
Ans: B

319- Brain blood flow increased due to
A- Increase PaO2
B- Increase PaCO2
C- Decrease Blood pressure,
D- D ccreasc K
Ans: B

320- A man stand from sitting position which reflex involve
A- Stretch reflex
B- Flexor reflex
C- Vestibular reflex
D- Spinal reflex
Ans: B

321- A neurologist stimulated Locus Cerolcus. Which of the following Neurotransmitter will be secreted from this Nucleus?(Medicine Feb 2025)
A- Glutamate
B- Serotonin
C- Nor Epinephrine
D- Acetylcholine
E- Dopamine
Ans: C(Guyton)

Explanation:
- Basal nucleus of Meynert(forebrain) contains - Acetylcholine
- Ventral tegmentum, (midbrain) contains - Dopamine
- Nucleus accumbens(basal ganglia) contains - GABA
- Locus ceruleus (pons) contains - Norepinephrine
- Raphe nuclei(brain stem) contains - Serotonin

322- A patient is alert but relaxed with eyes closed. Upon giving a stimulus, the patient's eyes open. What is the likely change in EEG waves? Medicine Feb 2025)
A- Theta to Beta
B- Beta to Alpha
C- Alpha to Beta
D- Beta to Theta
Ans: C

Explanation:
When a relaxed person with closed eyes is exposed to a stimulus (e.g., eyes opening), the EEG typically shifts from alpha waves (associated with relaxation) to beta waves (associated with alertness and attention)

323- Sympathetic response to Cold situation? Medicine Feb 2025)
A- Cutaneous vasoconstriction
B- Sweating
C- Increase Respiratory rate
D- Increased Appetite/Hunger
E- Anorexia
Ans: A

CamScanner

324- woman while cooking accidently lands his lland on a burning object and immediately removed it. Which of the following is involved in withdrawal reflex? Medicine Feb 2025)
A- Encapsulated receptor
B- Unencapsulated receptor
C- Monosynaptic receptor
D- Multisynaptic receptor
Ans: D

Explanation:
- Stretch reflex – Monosynaptic
- Inverse stretch reflex – Disynaptic
- Withdrawal reflex – Multisynaptic

325- Cerebral cortex receives afferent from- Medicine Feb 2025)
A- Noxious receptor
B- Thermoreceptor
C- Electro Receptor
D- Nociceptors
Ans: D

326- Decrease in core body temperature results in: (Surgery Feb 2025)
A- Decrease BMR
B- Shivering
C- Sweating
D- Vasodilation
E- Activation of anterior hypothalamus
Ans: B

327- Increased Myelin causes: (Surgery Feb 2025)
A- Decreased space constant
B- Decreased nodular and internode resistance
C- Increased conduction velocity
D- Decreased Cytoplasmic Resistance
Ans: B

328- Myelin loss causes: (Surgery Feb 2025)
A- Increased Intracellular resistance
B- Axon behaves like unmyelinated neuron
C- Decreased Extracellular resistance
D- No change in action potential
E- Increased Extracellular resistance
Ans: A

329- Effects of atropine(Surgery Feb 2025)
A- Inhibition of sweating
B- Constriction of Pupil
C- Blocks autonomic Function
D- Radical muscle contraction
E- decrease heart rate
Ans: A

330- Effect of Parasympathetic stimulation is(Surgery Feb 2025)
A- Inhibition of sweat gland Secretion
B- Blocked by atropine
C- Dec gastric motlity
D- Increase heart rate
E- Mydriasis
Ans: B

331- Flexor reflex response muscle(Surgery Feb 2025)
A- Stretch antagonist muscle contraction
B- Hitting tendon with hammer
C- Nocireceptor
D- Diasynaptic reflex
Ans: C

332- An area in the brain that does not directly receive motor or sensory input but is involved in processing and integrating information is called (Surgery Feb 2025)
A- Association cortex
B- Somatosensory Association Area
C- Agranular cortex
D- Primary Somatosensory Area
E- Secondary Somatosensory Area
Ans: A

333- What is the average rate of peripheral nerve regeneration?(Surgery Feb 2025)
A- 0.1 mm/sec
B- 0.3 mm/sec
C- 1 mm/day
D- 300 mm/sec
Ans: C

334- How will chef differentiate between garlic flavours/taste?(Gynae & Obs Feb 2025)
A- Sensory stimuli
B- Sensory transmission
C- Olfactory perception
D- Gustatory receptors
Ans: A

335- IGGO dome appearance is seen in which of the following(Gynae & Obs Feb 2025)
A- Meisner corpusles
B- Markel disc
C- Pacinian corpuscles
D- krause bulb
E- Ruffini corpuscles
Ans: B(Guyton)

CamScanner

Explanation:
Merkel's discs are often grouped together in a receptor organ called IGGO dome receptor,which project upward against the underside of the epithelium of the skin.this causes the epithelium at the point to protrude outward,thus creating a dome and constituting an extremely sensitive receptor
Better

336- **Role of sympathetic stimulation: (Gynae & Obs Feb 2025)**

A- Loss of sweating
B- Contraction of gallbladder
C- Decreases Heart rate
D- Stimulates telease of glucose from liver
Ans: D

337- **A patient complain of increase sweating in summers you explain the mechanism of sweating in summers as(Gynae & Obs Feb 2025)**

A- Thermotegulation
B- Sympathetic netvous system activation
C- Increased blood circulation to skin
D- Increased evaporation to cool the body
Ans: A

338- **A person picks different flowers and perceives various smells. Which process is responsible for distinguishing these different scents?(Radiology Feb 2025)**

A- Modulation
B- Integration
C- Adaptation
D- Discrimination
Ans: D

339 **A person has been sitting with one leg crossed over the other for an extended period. Upon standing up, he experiences difficulty in walking, particularly with foot dorsiflexion and eversion. What is the most likely cause?(Anesthesia Feb 2025)**

A- A fibers have faster conduction than B fibers
B- A fibers are more sensitive to pressure than C fibers
C- A fibers have slower conduction than C fibers
D- C fibers are more prone to ischemia than A fibers
Ans: B

340- **The vomiting center is located in which of the following areas? (Anesthesia Feb 2025)**

A- Nucleus tractus solitarius (NTS)
B- Midbrain
C- Nucleus ambiguus
D- Cortex
Ans: A

341- **"What is the name of the nucleus responsible for detecting phone vibrations in the pocket?"(Anesthesia Feb 2025)**

A- Nucleus Proprius
B- Nucleus Dorsalis
C- Vestibular Nucleus
D- Mesencephalic Nucleus of the Trigeminal Nerve
Ans: B

CamScanner

CNS PATHOLOGY QUICK HINTS

Subarachnoid hemorrhage

- ✓ Bleeding due to trauma, or rupture of aneurysm (such as a saccular aneurysm) or arteriovenous malformation.
- ✓ Patients complain of "worst headacheof my life or Thunderclap headache"
- ✓ Bloody or yellow (xanthochromic) lumbar puncture
- ✓ Increase risk of developing communicating and/or obstructive hydrocephalus
- ✓ Treat with Nimodipine

Intraparenchymal hemorrhage

- ✓ Most commonly caused by systemic hypertension. Also seen with amyloid angiopathy
- ✓ Hypertensive hemorrhages (Charcot-Bouchard microaneurysm) most often occur in putamen of basal ganglia (lenticulostriate vessels followed by thalamus, pons, and cerebellum

Extradural vs subdural

Extradural hematoma	Subdural hematoma
MMA involved	Bridging vein > Superior cerebral vein involved
Lucid interval	No Lucid interval
Biconvex	Crescent shaped
Not cross Suture lines	Cross Suture lines

Seizure

Partial (focal) seizures

- ✓ Affect single area of the brain. Most commonly originate in medial temporal lobe.
- ✓ Simple partial (consciousness intact)
- ✓ Complex partial (impaired consciousness, automatisms)

Generalized seizures Diffuse.

Types:

Absence (petit mal)—3 Hz spike-and-wave discharges, no postictal confusion.

Myoclonic—quick, repetitive jerks

Tonic-clonic (grand mal)—alternating stiffening and movement, postictal confusion, urinary incontinence, tongue biting

Epilepsy—disorder of recurrent, unprovoked seizures (febrile seizures are not epilepsy).

Status epilepticus---Continuous (≥ 5 min) or recurring seizures that may result in brain injury.

Post Ictal – Period when Seizure stop and patient return to normal state

Aura – It is Sensation that may occur before Seizure or Migraine or before Consciousness impaired.

Headaches

Cluster Headache

- ✓ Unilateral 15min -3h
- ✓ Excruciating periorbital pain (Suicide headache) with lacrimation, rhinorrhea, conjunctival injection
- ✓ May be Associated with Horner syndrome

Migraine

- ✓ Unilateral 4-72
- ✓ Pulsating pain with nausea, photophobia, and/or phonophobia. May have "aura."
- ✓ Due to irritation of CN V

Tension

- ✓ Bilateral 30 min (typically 4–6 hr)
- ✓ Steady, "band-like" pain. No photophobia or phonophobia. No aura.

CamScanner

Parkinson disease

- ✓ Loss of dopaminergic neurons (ie, depigmentation) of substantia nigra(Midbrain) pars compacta or Caudate lesion
- ✓ **Lewy bodies:** composed of α-synuclein (intracellular eosinophilic inclusion

TRAPSS

- ✓ Tremor (pill-rolling tremor at rest)
- ✓ Rigidity (cogwheel)
- ✓ Akinesia (or bradykinesia)
- ✓ Postural instability
- ✓ Shuffling gait
- ✓ Small handwriting (micrographia)

Huntington disease

- ✓ Autosomal dominant trinucleotide (CAG)repeat expansion in the huntingtin (HTT) gene on chromosome 4
- ✓ Symptoms include chorea, athetosis, aggression, depression, dementia
- ✓ Atrophy of caudate and putamen with ex vacuo ventriculomegaly.
- ✓ Increase dopamine, Decrease GABA and ACh in brain

Alzheimer disease

- ✓ Most common cause of dementia in elderly.
- ✓ Down syndrome qssociated with it
- ✓ APP is located on chromosome 21.
- ✓ Decrease ACh.

Associated with the following altered proteins:

- ✓ ApoE-2: Decreaserisk of sporadic form
- ✓ ApoE-4: Increase risk of sporadic form
- ✓ APP, presenilin-1, presenilin-2: familial forms (10%) with earlier onset
- ✓ Senile Plague- Aβ (amyloid-β)
- ✓ **Neurofibrillary tangles** - intracellular hyperphosphorylated tau protein
- ✓ **Hirano bodies**—intracellular eosinophilic proteinaceous rods in hippocampus.

Hydrocephalus

- ✓ Increase CSF volume result in ventricular dilation +/– Increase ICP.

Communicating hydrocephalus

- ✓ Due to arachnoid scarring and post-meningitis

Normal pressure hydrocephalus

- ✓ Affects the elderly, idiopathic, CSF pressure elevated only episodically
- ✓ Triad of urinary incontinence, gait apraxia (magnetic gait), and cognitive dysfunction.

Noncommunicating hydrocephalus

- ✓ Stenosis of aqueduct of Sylvius most common cause at Mesencephlom

Multiple sclerosis

- ✓ Autoimmune inflammation and demyelination of CNS (brain and spinal cord) with subsequent axonal damage.

Can present with

- ✓ Acute optic neuritis
- ✓ Brain stem/cerebellar syndromes (eg, **diplopia**, ataxia, scanning speech, intention tremor)
- ✓ Nystagmus [bilateral > unilateral])
- ✓ Pyramidal tract demyelination (eg, weakness, spasticity)
- ✓ Show Type 4 HS
- ✓ Periventricular plaques
- ✓ Increase IgG level and myelin basic protein in CSF. Oligoclonal bands are diagnostic. MRI is gold standard

Guillain-Barré syndrome

- ✓ Associated with GIT infection and organism Complyobacter jejuni and Zika virus

CamScanner

- ✓ Present with Ascending paralysis , Facial paralysis(B/L) , Respiratory ,Cardiac problem and Sensory problems
- ✓ Can affect peripheral nerve (CN 3-12)
- ✓ Increase CSF protein with normal cell count (albuminocytologic dissociation)

Neurofibromatosis

NF1 – Mutation of NF1 on chromosome 17 it has Pheochromocytoma, Nodules and focal neurological lesion.
NF2 –Mutation in NF2 on chromosome 12 it has B/L Vestibular Schawanoma and cataract.

Brain Tumors

Adult Tumors

Glioblastoma

- ✓ Grade IV astrocytoma
- ✓ Common highly malignant primary brain tumor in adult
- ✓ Found in cerebral hemispheres. Can cross corpus callosum ("butterfly glioma)
- ✓ Astrocyte origin, GFAP ⊕."Pseudopalisading

Oligodendroglioma

- ✓ Involve frontal lobe and calcified
- ✓ Oligodendrocyte origin.
- ✓ "Fried egg" cells—round nuclei with clear cytoplasm
- ✓ "Chicken-wire" capillary pattern

Meningioma

- ✓ Common, typically benign
- ✓ Most often occurs near surfaces of brain and in parasagittal region and Dural attachment
- ✓ May present with seizures or focal neurologic signs.
- ✓ Arachnoid cell origin and whorled pattern of spindle cells
- ✓ Psammoma bodie seem
- ✓ It is radiation induced

Hemangioblastoma

- ✓ Most often cerebellar
- ✓ Associated with VHL
- ✓ Can produce erythropoietin(secondary polycythemia)
- ✓ Blood vessel origin

Pituitary adenoma

- ✓ May be nonfunctioning (silent) mass effect or hyperfunctioning (hormone-producing).
- ✓ Hyperplasia of only one type of endocrine cells found in pituitary.
- ✓ Most commonly from **lactotrophs** (prolactin) - Galactorrhea, amenorrhea
- ✓ **Somatotrophs** (GH) -acromegaly, gigantism; **Corticotrophs** (ACTH)-Cushing disease. **Thyrotrophs** (TSH),Gonadotrophs (FSH, LH).

Schwannoma

- ✓ Classically at the cerebellopontine angle , benign, involving CNs V, VII. and VIII,
- ✓ B/L. Schawannoma associated with NF-2
- ✓ Schwann cell origin, S-100 ⊕.
- ✓ Biphasic, dense Hypercellular area(spindle cells) alternating with hypocellular(Myxoid areas)

Childhood Tumor

Pilocytic astrocytoma

- ✓ Low-grade astrocytoma. Most common primary brain tumor in childhood.
- ✓ Found in posterior fossa (eg cerebellum). May be supratentorial.
- ✓ Benign has good prognosis.
- ✓ Astrocyte origin, GFAP ⊕.
- ✓ Rosenthal fibers

Medullohlastoma

- ✓ Most common malignant brain tumor in childhood.
- ✓ Commonly involves cerebellum
- ✓ Compress 4th ventricle(Non communicating hydrocephlus)

CamScanner

- ✓ Cause truncal ataxia and Drop metastasis
- ✓ Synaptophysin ⊕.
- ✓ Homer-Wright rosettes, small blue cells. Neuroectodermal origin

Ependymoma
- ✓ Most commonly found in 4th ventricle Can cause hydrocephalus.
- ✓ Ependymal cell origin.
- ✓ Rod-shaped blepharoplasts(Cilliary body)

Craniopharyngioma
- ✓ Most common childhood supratentorial tumor.
- ✓ Calcification is common G H.
- ✓ Cholesterol crystals found in "motor oil"-like fluid within tumor.

Pinealoma
- ✓ Tumor of pineal gland.
- ✓ Can cause Parinaud syndrome (compression of tectum result in vertical gaze palsy) , obstructive hydrocephalus and precocious puberty in males (hCG production).

Horner syndrome

- ✓ Sympathetic denervation of face
- ✓ Ptosis (superior tarsal muscle)
- ✓ Anhidrosis (absence of sweating) and
- ✓ flushing of affected side of face
- ✓ Miosis (pupil constriction)

Note
- ✓ Ptosis + Mieosis -- Horner syndrome
- ✓ Ptosis+Mydriasis -- 3 rd Nerve palsy
- ✓ Ptosis + normal pupil -- Myesthenia gravis

Deafness

Conductive hearing loss
- ✓ Negative renin test i.e BC >AC
- ✓ Weber lateralized to poorer ear
- ✓ Low frequency affected more
- ✓ Loss is not more than 60 dB

Sensrineural hearing loss
- ✓ Positive renin test i.e AC >BC
- ✓ Weber lateralized to better ear
- ✓ High frequency affected more
- ✓ Loss is more than 60 dB

Random
- ✓ In alzhimer disease area involved – Entorhinal cortex
- ✓ patient with B/L vision loss and raised prolactin level and homonymous hemianopia due to lesion of – Anterior pituitary
- ✓ Substance causing peripheral neuropathy and degeneration of mylein in CNS is - Lead
- ✓ Patient has slow writhing purposeless movements, lesion in – Globus pallidus
- ✓ Hemiballismus is the result of lesion of – Subthalmus
- ✓ Chorea is characterstic of – Basal ganglia
- ✓ In wilsons disease part of basal ganglia effected – Putamen
- ✓ Pyramidal tract lesion – Clasp knife spasicity
- ✓ Extrapyramidal tract lesion – Lead pipe or cog wheel rigidity

CamScanner

- ✓ Charcoat buochard microanneurysms associated with – HTN
- ✓ In Klever bucy syndrome area involves – Amygdala
- ✓ Wernickie korakoff syndrome involves – Dorso medial nucleus
- ✓ Clinical triad of normal pressure hydrocephalus – Dementia, Ataxia and urinary incontinence
- ✓ Floppy baby at birth- Werding hoffman disease
- ✓ Café-au-lait spots seen in – Neurofibromatosis type 1
- ✓ Port wine birth mark seen in – Sturge weber syndrome
- ✓ Diabetes involves 3rd cranial nerve
- ✓ Brain Herniation involves 3rd cranial nerve
- ✓ Nasopharyngeal carcinoma involves 6th Cranial nerve
- ✓ AIDS involves 7th Cranial nerve
- ✓ Lyme Disease involves 7th Cranial nerve
- ✓ Sarcoidosis involves 7th Cranial nerve
- ✓ Late congenintal syphilis involves 8th cranial nerve
- ✓ Most common primary brain tumor – Glioma
- ✓ Most common benign Brain tumor - Meningeoma
- ✓ Most common type of glial tumor – Astrocytoma
- ✓ Most common brain tumor in adults – Astrocytoma
- ✓ Most common site of brain tumor in neonates- Supratentorial
- ✓ Most common site of brain tumor in childrens – Infratentorial
- ✓ Psammoma bodies – Meningeoma
- ✓ Butterfly tumor – Glioblastoma multiforme
- ✓ Verocay bodies – Schwannoma
- ✓ Enamel like structures – Craniophryngioma
- ✓ Pseudorossets - Neuroblastoma

CamScanner

CNS PATHOLOGY

1. A patient having Neck Swelling with dropping of eyelids to diagnose condition which among these is suitable

A- Antibodies against Acetylcholine receptors
B- Antibodies against calcium receptors
C- Antibodies against both receptors
D- None
Ans: A

2. A patient presented with Bilateral Ptosis with muscle wasting on mastication suitable pathology is

A- Myasthenia Gravis
B- Eaton Lambort Syndrome
C- GBS
D- Polio
Ans: A

3. Patient presented with nasopharyngitis & lymphadenopathy these features are also carried by the organism that causes which of these

A- Burkitt Lymphoma
B- AIDS
C- Bronchogenic Carcinoma
D- BCC
Ans: A

4. Young female presented with atypical lymphoctyosis likely diagnose is

A- Infectious Mononucleosis
B- AIDS
C- HBV
D- CMV
Ans: A

5. Brain tumor most commonly occuring after radiation?

A- Acute leukemia
B- Meningioma
C- AML
D- CML
Ans: B

Explanation:

- Most common after radiation – Leukemia
- Most common brain tumor after radiation – Meningioma

6. Primary CNS tumour is

A- Glial Cell Tumour
B- Mets
C- Meningoma
D- Schwanoma
Ans: A

7. Hydrocephalus most common cause is

A- Aqueductal Stenosis
B- 4th Ventricle Obstruction
C- Lateral Ventricle Obstruction
D- None
Ans: A

8. Commonest brain tumor is

A- Astrocytoma
B- Meningoma
C- Medulloblastoma
D- Pineal gland tumor
Ans: A

Explanation

- Most common primary brain tumor – Glioma
- Most common benign Brain tumor - Meningeoma
- Most common type of glial tumor – Astrocytoma
- Most common brain tumor in adults – Astrocytoma
- Most common site of brain tumor in neonates- Supratentorial
- Most common site of brain tumor in childrens – Infratentorial

9. A 48 year old male presented with complain of severe headache and blurring of vision, doctor performed the LP, he found that the CSF is blood stained, what could be the possible cause of this blood stained CSF?

A- Sub-dural hemorrhage
B- Epi-dural hemorrhage
C- Sub-archinoid hemorrhage
D- Extra-dural hemorrhage
E- Intraparenchymal hemorrhage
Ans: C

10. 40 years old hypertensive man had thalamic hemorrhage, the most prominent finding on the examination of his sensory system will be

A- Abnormal thermal sensation
B- Altered sexual sensations
C- Hyperaesthesia
D- Numbness
E- Reduced kinaesthesia
Ans: C

Explanation:

- Thalamic Pain Syndrome affects the ventral nuclear group. Patients present with burning, aching pain in contralateral limbs or body involvement of the DCML part of VPL increases the sensitivity to pain and presents as contralateral loss of vibratory sense and gait ataxia. Thalamic pain syndrome is resistant to Analgesic medications.

CamScanner

11. Point that distinguish partial transection from spinal complete transaction?
A- Spinal shock
B- Bladder atonia
C- Increase reflexes
D- Diminish reflexes
Ans: A

12. Which of the following relays in substantia gelatinosa?
A- Fine touch
B- Proprioception
C- Pain
D- Vibration
Ans: C

13. Subdural haemorrhage is caused by damage to:
A- Superior cerebral veins
B- Bridging veins
C- Diploic veins
D- Middle cerebral veins
Ans: B

14. Bell's phenomenon is
A- Bell's Palsy
B- Eye globe downwards and drooping of lid
C- Eye globe upwards, drooping of lid
D- Eye globe moves upward when he tries to close his eyes
Ans: D

15. Farmer with OP Poisoning feature:
A- Dilated pupils
B- Bilateral pin point pupils
C- Decrease Salivation
D- Decrease Lacrimation
Ans: B

16. 14yr old boy with fluctuating type of deafness. On examination, Tympanic membrane retracted inward. Rinne test is negative, weber lateralized to affected ear. What is the probable cause?
A- Otitis media
B- Eustachian tube blockage
C- Adenoids
D- SNHL
Ans: B

Explanation:
- As the Rinne test is negative it means it is conductive hearing loss that's confirmed with the weber test that's lateralized toward the affected side, now the probable cause for fluctuating hearing loss at this age is Eustachian tube blockage

17. A Stroke patient with irregular breathing related to
A- Kussmual Breathing
B- Periodic Breathing
C- Normal Breathing
D- Cheyne stokes breathing
Ans: D

Explanation:
- Cheyne-Stokes breathing is common seen after stroke & head trauma
- Kussmaul Breathing pattern is seen DK & Uremia

18. Patient Having Fever, neck rigidity and Slight SOB. CSF report reveals Increase lymphocytes,Glucose 40 and Protein 400 what is likely Diagnose:
A- Viral Meningitis
B- Fungal Meningitis
C- TB meningitis
D- Bacterial Meningitis
Ans: C

Explanation:
- Bacterial – Neutrophil + Low glucose
- TB – Lymphocyte + Low Glucose
- Viral – Lymphocyte + Normal Glucose

19. A patient having temperature of 98, cold clammy skin, sweating profuse and working on a hot day, brought to the hospital in semiconscious state most likely due to:
A- Heat Stroke
B- Heat Exhaustion
C- Excessive Sweating
D- Normal Phenomenon
Ans: B

Explanation:
- Heat exhaustion is characterized by excessive sweating and cold, clammy skin
- Heat Stroke is characterized by Temperature above 100 & absence of sweating with loss of consciousness

20. Patient with Paroxysmal hypertension episodic headache is seen in which of the following condition?
A- Pheocbromocytoma
B- Adrenal tumor
C- Myxoma
D- Renal Cell carcinoma
Ans: A

21. A young boy sitting in a room is sweating & BP of 150/80 which of the following is the most likely cause:
A- Mental Stress
B- Exercise
C- Heat Stroke
D- Dehydration
Ans: A

CamScanner

22. Which of the following translocation is seen in Burkitt's Lymphoma?
A- t (8:14)
B- t (8:21)
C- t (9: 22)
D- t (11:14)
E- t (X:18)
Ans: A

23. Transfer of heat from the core of the body to the surface depends on
A- Core body temperature gradient
B- Remains constant
C- Depends on external environment
D- Controlled by Sub-thalamus
Ans: A

24. A patient presents with nerve deafness in one ear (unilateral). The test will show
A- Normal sound in normal ear
B- High sound in normal ear
C- High sound in affected ear
E- No sound in affected ear
Ans: B (Dhingra)

25. Jet-engineer presents to the ENT physicians and complains that be works in an environment of loud noises. What kind of hearing defect he might be suffering from on an audiogram?
A- Deafness to low frequency sound
B- Deafness to every sound
C- Deafness to high frequency sound
D- No deafness
E- Audiogram would show dip at 2000 Hz
Ans: A

26. Mechanism of action in fever is
A- Cox-II inhibition
B- Thromboxane A2 inhibition
C- Cox-I and Cox-II inhibition
D- Increase prostaglandins synthesis
Ans: D

27. Male presented with head injury present with decrease thirst and decrease plasma osmolarity cause of decrease thirst is
A- Stimulation of lateral hypothalamus
B- SIADH
C- Cushing Reflex
D- Aldosteron
Ans: B

28. The lesion occurred at the caudate and globus pallidus of the brain. There was loss of GABA in Substantia Nigra The condition is:
A- Alzheimer's Disease
B- Parkinsonism
C- Homer Syndrome
D- Retrograde Amnesia
Ans: B

29. Loss of sympathetic supply to eye would result in:
A- Tears
B- Miosis
C- Drooping eyelids
D- Squint
Ans: B

30. Parkinsonism affects which of these?
A- Nucleus Basalis
B- Substantia Nigra
C- Subthalamus
D- Globus Pallidus
Ans: B

31. A patient exhibiting hyperprolactinemia signs with decreased vision loss has a problem in
A- Hypothalamus
B- Thalamic nuclei
C- Pituitary
D- Occulomotor nerve
Ans: C

32. Infectious mononucleosis is diagnosed by:
A- ANA
B- Antimitochondrial antibody
C- Antimicrosomal antibody
D- Heterophile sheep antibody
Ans: D

33. Ebstein barr virus is associated with which of these
A- Cervical carcinoma
B- Erythroplakia
C- Lichen Planus
D- Burkitt lymphoma
Ans: D

34. The amplification of N-myc gene causes:
A- Retinoblastoma
B- Nephroblastoma
C- Hodgkin lymphoma
D- Neuroblastoma
Ans: D

CamScanner

35. The damage in the nucleus of Arcuate would result in
A- Parkinsonism
B- Alzheimer disease
C- Homer Syndrome
D- Kallman Syndrome
Ans: D

36. The stroke due to berry aneurysm involves which artery?
A- Anterior communicating artery
B- Posterior communicating artery
C- MMA
D- ASA
Ans: A

37. The tumor of the posterior cranial fossa is:
A- Medulloblastoma
B- Glioblastoma
C- Astrocytoma
D- Ependymoma
Ans: A

38. What is less in CSF in comparison to plasma?
A- K
B- Na
C- Mg
D- Protein
Ans: D

Explanation
- CSF density is 1.0005
- CSF specific gravity is 1.005.
- CSF PH is 7.33.
- CSF is isotonic with serum.
- CSF has equal sodium as compared to plasma.
- CSF has high magnesium and chloride as compared to plasma.
- CSF has more creatinine as compared to plasma.
- Rest everything is low in CSF as compared to plasma (Protein more low than glucose)

39. Brain tissues are damaged by stroke, cells will be regenerated by
A- Fibroblast
B- Glial cells
C- Astrocytes
D- Schwann Cells
Ans: C

40. Cause of meningitis in newborn is
A- Streptococcus lancefield A
B- Streptococcus lancefield B
C- Streptococcus lacefield C
D- Streptococcus lancefield D
Ans: B

41. A 67 year female presents with balance problem Exam: nystagmus on left lateral gaze, a loss of the left corneal reflex and reduced hearing in the left ear. What is the most likely diagnosis?
A- Meniere's disease
B- Acoustic neuroma
C- Cerebral abscess
D- Pituitary tumor
E- Gentamicin
Ans: B

42. Which ion is raised in malignant hyperthermia?
A- Na
B- K
C- Ca
D- Mg
Ans: C

43. A Security guard got gun-shot injury on lower back.After physiotherapy and rehabilitation he had lost contralateral Pain/temp below the level of lesion and ipsilateral loss of Vibration What is diagnosis?
A- Damaged 1st dosral root
B- Damaged ventral root
C- Brown sequard syndrome
D- Developing tabes dorsalis
E- Syringomyelia
Ans: C

44. A young Man presents with complain of one-sided facial flushing and heating up with no sweating. Where is defect?
A- Sympathetic loss
B- Facial nerve
C- Autonomic outflow Loss
D- Cranial outflow
E- Parasympathetic loss
Ans: A

45. Patient has test come positive for infectious mononucleosis.Which organ will be susceptible to injury?
A- Liver
B- Kidney
C- Spleen
D- Lung
Ans: C

46. Child with disturbed behavior suffering from Fever and Convergent squint. Which of following is most likely diagnosis?
A- Tuberculosis meningitis
B- Viral meningitis
C- Bacterial meningitis
D- Fungal meningitis
E- Brain tumor
Ans: A

CamScanner

47. Mono spot test is diagnostic for which of the following disease?
A- HIV
B- Typhoid
C- Infectious mononucleosis
D- Measles
E- GBS
Ans: C

48. Burkitt lymphoma oncogenes are by EBV:
A- Protooncogene c-myc amplification
B- Protooncogene c-myc translocation
C- Ras proto-oncogene
D- BCL2 proto-oncogene
Ans: B(FA)

49. Patient present with spells of dizziness and diplopia.Now presented with coma. What's the Diagnosis?
A- Subarachnoid hemorrhage
B- Carotid artery obstruction
C- Basilar artery thrombosis
D- Pontine hemorrhage
Ans: C

50. Middle aged man presented with meningitis after having lung abscess cause is?
A- Staph aureus
B- H.influenza
C- Streptococcus pneuminae
D- Klebsiella
Ans: A

51. Damage to first lumbar vertebra will lead to
A- Conus Medullaris Syndrome
B- Damage to spinal Cord
C- Damage to sympathetic system
D- Damage to parasympathetic system
Ans: A

52. Post syphilitic patient can't constrict pupil on light, with intact accommodation most suitable cause is
A- Argyl robertson pupil
B- Masthenia gravis
C- Oculomotor palsy
D- Optic nerve damage
Ans: A

53. A young girl finds it hard to hear at low frequencies of sound which type of conduction?
A- Sensory
B- Due to ear wax
C- Conductive
D- Mixed
Ans: C

54. Dopamine and acetylcholine imbalance in corpus striatum leads to:
A- Chorea
B- Hemiballismus
C- Parkinson
D- Athetosis
Ans: C(FA)

55. Only nerve affected in Multiple Sclerosis is:
A- Optic
B- Trigeminal
C- Olfactory
D- Oculomotor
E- Abducent
Ans: A

56. Person is in prolonged coma which one involved
A- Nucleus cerelus
B- Periaqueductal gray matter
C- Thalamus
D- Subtbalamus
Ans: B

Explanation:
Prolong Coma – Periaqueductal gray matter
Deep Coma – Nucleus Cerelous
Permanent Coma -Thalamus

57. Causative agent of meningitis in newborn
A- S.Agalactae
B- E. coli
C- Neisseria meningitis
D- Klebsiela
Ans: A

58. Hypogonidism and anosmia lesion in
A- Hypothalamus
B- Amygdala
C- Hippocampus
D- Arcuate nucleus
Ans: D

59. Regarding Hodgkin lymphoma:
A- Symptoms are present in mental zone
B- It is associated with CmV infections
C- Contiguous spread
D- Vascular spread
Ans: C(FA)

60. Hyper sexuality, hyper morality & disinhibition Seen in
A- Kallaman syndrome
B- Kluver bucy syndrome
C- Lateral Meduulary Syndrome
D- Medial medullary syndrome
E- Lateral pontine syndrome
Ans: B

CamScanner

61. Which one dec blood supply to brain:
A- Inta ventricular epinephrine
B- Inhalation off 17% CO_2
C- Seizures
D- Hyperbaric O_2
Ans: D

62. Main reason for development of brain abscesses:
A- Hematogenous spread of infection
B- Neurosurgical intervention
C- Penetrating wounds
D- Frontal trauma
E- Infections around cancer in brain
Ans: A

63. 6 months to 2years of age cause of meningitis is
A- S pneumocia
B- Hinfluenza
C- Strep pygenes
D- Labsiella
E- Neisseria
Ans: A(FA 2021)

64. Patient has intractable long history of pain and has taken various painkillers. How do you treat the patient then?
A- Psychological cognitive treatment
B- Steroids and local anesthetics
C- NSAIDS and Benzodiazepine's
D- Narcoleptic analgesics
Ans: A

65. Ocular manifestation in myasthenia gravis is due to?
A- ACH antibodies
B- Decrease post synaptic ACH receptors
C- TSH antibodies
D- Acb antigen
Ans: B

66. A patient presented with stroke in emergency his chest x-ray shows Kerley's B line. What is diagnosis?
A- Sub arachnoid hemorrhage
B- Cerebral embolism
C- Intracranial bleeding
D- Saccular Aneurysm
Ans: C(Neurogenic edema)

67. Infectious mononucleosis shows?
A- Activated T cell
B- Activated B cell
C- Atypical cells
D- Inactivated T cells
Ans: A

68. Infectious mononucleosis diagnosis?
A- Bire beck
B- Cold agglutinins
C- Anti-sheep Ab
D- Lymphadenopathy
E- Mono spot test
Ans: E>B

69. 3rd Cranial nerve involved in?
A- Brain hemiation
B- Lyme disease
C- AIDS
D- Multiple sclerosis
E- Nasopharyngeal carcinoma
Ans: A

Explanation:
3rd cranial nerve
- Diabetes
- Brain Herniation

6th Cranial nerve
- Nasopharyngeal carcinoma

7th Cranial nerve
- AIDS
- Lyme Disease
- Sarcoidosis

8th cranial nerve
- Late congenintal syphilis

70. Verocay bodies present in
A- Schwannoma
B- Astrocytoma
C- Meningioma
D- Oligodendroglioma
E- Medulloblastoma
Ans: A

Explanation:
- **Pseudo rossets** – Neuroblastoma
- **Enamel like structures** – Craniopharyngioma
- **Glial fibrillary proteins** – Astrocytoma
- **Verocay bodies** – Schwannoma
- **Fried Egg appearance** – Oligodendroglioma
- **Psammoma bodies** – Meningioma
- **Butterfly Tumor** – Glioblastoma Multiforme

71. A person presented to you with history of severe headache and vomiting at start of day. There was a tumor suspicion on radiography which was in cerebellar area involving granular layer what it can be?
A- Ependymoma
B- Astrocytoma
C- Medulloblastoma
D- Condroma
Ans: C

CamScanner

Explanation:
- Medulloblnstoma arise from external granular layer of cerebellum and symptoms include vomiting morning head ache stumbling gait and frequent falls.

72. In post epileptic patient, time taken from fits to normal state:
A- Post ictal
B- Aura
C- Clonic
D- Tonic
Ans: A

Explanation:
- **Post Ictal** – Period when Seizure stop and patient return to normal state.
- **Aura** – It is sensation that may occur before seizure or migraine or before consciousness impaired.

73. Interruption of cervical sympathetic chain result in horner syndrome if sympathetic nerves to the Eye are affected which one of the following is the commonest finding?
A- Absence of sweating on affected side
B- Drooping of eyelid on affected side
C- Flushing of face on affected side
D- Occurs in young age group
E- Xerosis and anhydrosis on affected side
Ans: B>A

74. Lady heard his husband saying that the neighbor loves her but do not confess which further proves his secret love. The lady tried contacting the neighbor but he refused which makes her sad. She is pre occupied with this thought. Sometimes get confused:
A- Delusion
B- Depression
C- Unipolar
D- Schizophrenia
E- Schizoaffective Syndrome
Ans: A

75. Colleagues complain about a 30 Year old woman who forges signs on imp documents and search for belongings of others in their absence. Has joined another company and started smoking. He has history of taking some drugs What test would you do for psychiatric evaluation?
A- Urine analysis for drugs
B- Thyroid
C- B-HCG
D- Cortisol
Ans: A

76. A patient after Lesion of caudate, putamen and loss of GABA neuron in substantia nigra and gollibus pallidus patient is suffering from which disease?
A- Parkinsonism
B- Hemiballismus
C- Chorea
D- Athetosis
E- Ballismus
Ans: C(C>D -Huntington Chorea)

Explanation:
- **Caudate Lesion** – Chorea
- **Globus pallidus lesion** -Athetosis
- **Substantia nigra** – Parkinson's disease
- **Sub thalamus** - Hemiballismus

77. **Malignant hyperthermia receptor is**
A- Ryanodine receptors
B- Na/K Pump
C- Ca Sarcoplasm
D- Acetylcholine gated ions
E- Krause Receptor
Ans: A

78. A patient with Color blindness can't differentiate between red from green this is called:
A- Hemianopia
B- Quadrianopia
C- Protanopia
D- Heteroanopia
Ans: C

Explanation:
- Can't differentiate Between Red and green - Protanopia
- Can't differentiate Between Green and red – Deuteranopia

79. Patient after history of stroke develops Brain necrosis and ischemia which type of necrosis will he seen?
A- Coagulative necrosis
B- Fibrinoid Necrosis
C- Liquefective necrosis
D- Fat necrosis
E- Caseous necrosis
Ans: C

80. 26-year-old patient came in ophthalmology OPD with complain of inability to differentiate between different colors where is the pnthology?
A- Rods and cones
B- Cones
C- Parafovea
D- Vitrous body
E- Optic disc
Ans: B

CamScanner

Explanation:

Rods	Cons
Night Vision	Day Vision
Low Resolution	High Resolution
Black Vision	Color Vision
Found in peripher y	Found in centre (Fovea)
Many	Few

81. 45-year-old male with mask like facies, resting tremors, this is due to lesion in
A- Globus pallidus
B- Caudate
C- Lateral thalamic nucleus
D- Nucleus basalis
E- Dentate nucleus
Ans: B

82. A 30 year old guard presented in emergency in semi conscious state, high temperature 104F Chills and altered mental status passing dark colour urine. This is due to?
A- Cerebral haemorrhage
B- Heatstroke
C- Cerebral malaria
D- Heat exhaustion
E- Dehydration
Ans: C

83. A patient presented with sore throat, fever & lymphadenopathy.EBV was detected.He is at risk of which of the following?
A- Burkitt's lymphoma
B- Kaposi Sarcoma
C- Multiple myeloma
D- Wilms Tumor
Ans: A

84. 30 years old male treated for meningitis 1 month ago came with morning headache having B/L papilledema cause is:
A- Blockage of Dural sinus
B- Hydrocepbalus
C- Involvement of cerebra l vessels
D- Involvement of meninges
E- Subdural collection
Ans: B

85. A patient feeling unwell from 3 days, anorexic headache and neck stiffness. Lumbar puncture done which shows 100% lymphocytosis, low protein with glucose 84 what is disease?
A- Cerebral Malaria
B- Syphilis
C- Meningitis
D- Encephalitis
Ans: C

86. A mother delivered a child and brought her 5 days baby with fever, vomiting and neck stiffness, what is the cause?
A- Group A streptococcus
B- Group B streptococcus
C- Nisseria
D- E. coli
E- H. influenza
Ans: B (FA)

87. Suspicion of psuedoseizure in:
A- Absence seizure
B- Partial complex seizure with temporal lobe epilepsy
C- Partial complex seizure with frontal lobe epilepsy
D- Tonic clonic seizure
Ans: A

88. In Alzheimer disease brain finding will be:
A- Loss of Sulci
B- Hyperplasia of brain
C- Hypertrophy of brain
D- Atrophy of brain
Ans: D

89. Petil mal epilepsy shows:
A- Spike and rapid firing
B- Spike and dome appearance
C- Spike and slow appearance
D- Double Spike
Ans: C

90. Regarding pituitary gland true is:
A- Lateral to cavernous sinus
B- Derived from endoderm
C- Lies on diaphragm sella
D- Pituitary tumor causes junctional scotoma
E- Inferior optic chiasma
Ans: D

91. A police man was sent to you because his urine has some opioid and other drugs found.What will be his response?
A- Denial
B- Depression
C- Blaming the doctors
D- Politely acceptance
Ans: A

92. Halothane causes malignant hyperthermia by:
A- Increasing set point of hypothalamus
B- Linterleukin-1
C- Interleukin -6
D- Continous muscle contraction
Ans: D

CamScanner

93. **Myasthenis gravis most initial test is:**
A- EMG
B- Tensilon test
C- NCV test
D- Biopsy
Ans: B

94. **Brain has ischemic stroke, most likely cause:**
A- Hypertension
B- Aneurysm
C- Atherosclerosis (ischemic)
D- Thrombosis
Ans: C

95. **Anterior pituitary removal leads to:**
A- Short stature
B- Absence of menses
C- Short width
D- Excessive menses
Ans: B

96. **A 30 years man with sore throat & cervical lymphadenopathy CBC picture shows presence of atypical lymphocytes the most important test in this setting is:**
A- Monospot test
B- Mantoux test
C- Lymph node biopsy
D- Blood culture
E- X-ray
Ans: A

97. **Patient having 15 years of diabetes have decreased visual acuity. O/E it showed white spots and exudates on retina. Most likely due to:**
A- Central retinal artery occlusion
B- Central retinal vein occlusion
C- Hypertension
D- Lipid storage disease
Ans: B

98. **Myasthenia gravis bilateral ptosis at night what test will help in diagnose?**
A- Acetylcholine number
B- Acetylcholine receptor antibodies
C- Anti calcium channel antibodies
D- Anti Sodium channel antibodies
Ans: B

Explanation:
- Myasthenia gravis – Antibodies' against postsynaptic voltage gated cannels.
- Diagnostic test – ACH receptor antibodies
- Most accurate/confirmatory/gold standard – EMG
- Initial drug for Myasthenia gravis – Neostigmine
- DOC For maintained therapy – Pyridostigmine.
- Physostigmine – Crosses BBB immediately and increase acetylcholine.
- In Lambert eaten Syndrome – Antibodies are directed against Calcium channels.

99. **Stroke and brain tissue are damaged now repair is by:**
A- Neurone
B- Fibroblast
C- Schawn cell
D- Astrocytes
Ans: D

100. **After thoracolumbar outflow cut which one affected?**
A- Skeletal muscle
B- Blood vessel
C- Smooth muscle
D- Respiratory
Ans: B

101. **Sub Dural hemorrhage involves which vessels?**
A- MMA
B- Superior cerebral veins
C- Inferior cerebral veins
D- Cerebral Artery
Ans: B

Explanation:
- Extradural – MMA
- Subdural – Bridging veins >Superior Cerebral vein

102. **Patient having seizures due to decrease presynaptic reuptake of?**
A- Gaba
B- Dopamine
C- Glycine
D- NE
Ans: A

103. **HIV positive patient with fever from 4 to 5 days vomiting from 1 day CSF Glucose 80 BSR 110 CSF Protein 45 with no cell raised cause in HIV patient is:**
A- Tb
B- Streptococci meningitis
C- Bacterial meningitis
D- HSV
Ans: D

104. **Most common cause of Pale brain infarction:**
A- Emboli
B- Atherosclerosis
C- Trauma
D- HTN
Ans: B

CamScanner

105. If basilar artery is blocked it will cause:
A- Contralateral cerebellar symptoms
B- Ipsilateral cerebellar symptoms
C- Quadriplegia
D- Paraplegia
Ans: C

106. Common site of pyogenic brain abscess:
A- Frontal lobe
B- Temporal lobe
C- Parietal lobe
D- Occipital lobe
Ans: A (Dhingra)

107. Meningitis in newborn caused by :
A- Staph aureus
B- Alpha Streptococus pneumoniae
C- E. Coli
D- H. infleunza
Ans: C

Explanation:

Newborn (0-6 months)	Children (6 mo-6yr)	6-60yr	60 yr. +
• Group B Streptococcus • E coli • Listeria	• SPneumonia • N meningitidis • H influenzae type b • Group B streptococcus • Enteroviruses	• Spneumoniae • N meningitidis • Enteroviruses • HSV	• S pneumoniae • N meningitidis • H influenzae type b • Group B Streptococcus • Listeria

108. Gene amplification childhood tumor:
A- Neuroblastoma
B- Nephroblastoma
C- Retinoblastoma
D- Burkit lymphoma
Ans: A

109. Seizures occur as a result of imbalance in the neurotransmitter:
A: Glycine
B: Glutamate
C: GABA
D: Serotonin
Ans: C

110. Most radiosensitive tumor:
A- Meningioma
B- Neuroblastoma
C- Ganglionglioma
D- Brain stem glioma
Ans: D

Explanation:
- Regarding sensitivity to radiotherapy :
- Lymph node tumor > Seminoma > Glioma > Craniopharyngioma

111. Organism responsible for causing meningitis in HIV patient:
A- N. meningitis
B- Strept. Pneumonia
C- Cryptococcus
D- Toxoplasmosis
Ans: C

112. A patient presents with only complain of resting tremors, area of brain involved:
A- Cerebellum
B- Substantia nigra
C- Globus pallidus
D- Caudate nucleus
Ans: B

113. Lesion at Hippocampus result in:
A- Loss of new memory
B- Loss retrograde memory
C- Loss of Feeding
D- Loss of weight
Ans: A

114. Lucid interval present in:
A- Epidural hematoma
B- Subdural hematoma
C- SAH
D- Extradural hematoma
Ans: A

115. Head injury biconvex hemorrhage vessel ruptured is:
A- Bridging vein
B- MCA
C- MMA
D- Superoor cerebral vein
Ans: C (Extradural Hematoma)

116. Brain tumor, immunohistopathology GFAP + tumor of which cells?
A- Dendric cells
B- Astrocytes
C- OligoDendrocytes
D- Schwan cell
Ans: B

117. Patient with Resting tremor, stooped posture, shuffling gate lesion in:
A- Cerebrum
B- Cerebellum
C- Midbrain
D- Medulla
E- Pons
Ans: C (Substansia nigra present in Midbrain)

CamScanner

118. Patient after being operated of brain tumor now presented with excessive appetite, thirst. Which hypothalmic nucleus is damaged?

A- Paraventicular
B- Medial
C- Lateral
D- Anterior
Ans: B

Explanation:

- Medial Nucleus is Satiety centre its damage will result in increased hunger
- Lateral Nucleus is Hunger centre its damage will result in loss of Appetite

Ans: B

119. Prosopagnosia occurs due to lesion in

A- Parietal lobe
B- Prefrontal eye field
C- Parietal and occipital lobe
D- Parieto-occipiti-temporal lobe
Ans: D

120. Lateral hypothalamus injury result in

A- More feeding
B- Inhibition of feeding
C- Obesity
D- Hypotension
Ans: B

121. Blow to Head caused extra dural hematoma due to involvement of which artery?

A- Middle meningeal artery
B- Anterior cerebral artery
C- Posterior cerebral artery
D- Superior Cerebral veins
E- Bridging veins
Ans: A

Explanation:

Extradural hematoma	Subdural hematoma
MMA involved	Bridging vein > Superior cerebral vein involved
Lucid interval	No Lucid interval
Biconvex	Crescent shaped
Not cross Suture lines	Cross Suture lines

122. A person after RTA cannot speak lesion is at which of following area?

A- Wenike area
B- Broca area
C- Angular gyrus
D- Occipital lobe
E- Arcuate Fasciculus
Ans: B (FA +Kaplan)

Explanation:

- **Broca aphasia** – Motor aphasia + Non-fluent + area 44 and 45 + inferior frontal gyrus
- **Wernicke aphasia** – Sensory aphasia + fluent + area 22+ superior temporal gyrus
- **Global aphasia** – Both Wernicke and broca aphasia + arcuate fasciculus
- **Anomic aphasia** – Mild fluent aphasia + failure of word retrieval + angular gyrus

123. A boy after blunt trauma to eye, Present to you with lower orbit fracture, crackling sound on palpation and blood accumulation diagnose is:

A- Orbital edema
B- Surgical emphysema
C- Foreign body
D- Fracture bone pieces
Ans: B

124. If Accomodation to remains intact and Light reflex is absent where will be damage

A- Edinger westphal
B- Optic nerve
C- Optic tract
D- Optic chiasma
E- Pretectal area
Ans: E

Explanation:

- Loss of light Reflex but intact accommodation reflex – PRETECTAL NUCLEUS (MIDBRAIN AT THE LEVEL OF SUPERIOR COLLICULUS)
- Loss of Accomodation reflex -- Cerebral cortex
- Loss of Accomodation -- Cerebral cortex
- Loss of Accomodation + 3rd CN Involvement -- Midbrain (due to Edinger westphal nucleus)

125. Lesion in parietal lobe causes which of following?

A- Illusion
B- Asterognosia
C- Social withdrawal
D- Delirium
E- Delusion
Ans: B

Explanation:

- Prospagnosia lesion in – Temporal Lobe
- Asterognosis lesion in – Parietal Lobe

126. A man during a road side accident suffer injury to cervical sympathetic chain most likely change in eye

A- Ipsilateral Sweating
B- Ipsilateral pupil constriction
C- Mydriasis
D- Isohydrosis
Ans: B

CamScanner

127. A patient has gradual vision loss and laser photocoagulation was done which structure involved
A- Lense
B- Retina
C- Cornea
D- Anterior chamber
Ans: B

128. A patient having intension tremors he is having lesion in:
A- Midbrain
B- Cerebellum
C- Pons
D- Midbrain
E- Cortex
Ans: B
Explanation:
- Intension tremors – Lesion of cerebellum
- Resting tremos – Lesion of substansia nigra (midbrain) causes Parkinson disease

129. Characteristic of Cerebellar lesion is
A- Dysdiadoochokinesia
B- Hypotonia
C- Ataxia
D- Dysarthria
E- Dysemtria
Ans: A

130. A patient has damage to a nerve coming out from dorsal surface of left side of brain stem. What will be the defect in this patient?
A- Left sided loss of intorsion
B- Ptosis of the left eye
C- Loss of corneal reflex on right
D- Loss of corneal reflex on left
Ans: A (Trochlear nerve injury)

131. In internal capsule injury what will be effected
A- Flaccid paralysis of same side
B- Flaccid paralysis of opposite side
C- Spastic paralysis of same side
D- Spastic paralysis of opposite side
Ans: D

132. A known Smoker and Diabetic patient presented with partial ptosis small pupil and miosis Diagnosis is
A- Horner syndrome
B- 3rd nerve palsy
C- Diabetic opthalmopathy
D- 4th nerve palsy
Ans: A

133. A patient went to prosthodontics it did not fit in his mouth so he was reffered to a doctor on examination he has rigidity and tremors. Which nucleus is likely affected
A- Red nucleus
B- Substantia nigra
E- Edinger westpal nucleus
D- Trigeminal
Ans: B

134. A patient presented with paralysis of right limb and right lower face along with homonymous hemianopia lesion present in which of following?
A- Basilar pons
B- Forebrain
C- Midbrain
D- Medulla
E- Thalamus
Ans: B

135. Damage to cerebroparietal area. What will be effected?
A- Sensory
B- Motor
C- Visual
D- Loss of tuning fork sensation
Ans: D

136. A patient has problem of anosmia and hypogonadism, which of following region of the brain will be having lesion on MRI?
A- Basal ganglia
B- Cerebral cortex
C- Hippocampus
D- Hypothalamus
E- Thalamus
Ans: D

137. A patient present to you with both lower limb weakness and gait problem and has peripheral tingling sensation he is most probably having:
A- Asterocytoma
B- Oligocytoma
C- Schwanoma
D- Ependyoma
Ans: C

138. A young lady has Aphasia ,due to lesion of non dominant brocas area lesion it will cause
A- Global aphasia
B- Anomic aphasia
C- Brocas aphasia
D- Wernicke aphasia
Ans: B

CamScanner

139. A patient has injury of head and he has developed prospognosia where is the lesion
A- Temporal lesion
B- Parietal lesion
C- Occipital lesion
D- Temporo parieto occipital lesion
E- Frontal lesion
Ans: A
Explanation:
- For Propagnosia Inferior temporal lobe is mostly related but if an of temporal lobe is not given then Parieto occipito temporal lobe option is also correct
- Prospagnosia lesion in – inferior Temporal Lobe
- Asterognosis lesion in – Parietal Lobe

140. Person who writes from his left hand , he suffered an RTA and head injury . now presented to you problem of he cant differentiate from left from right and difficulty in writing and comprehension and word retrival he has injury of
A- Right temporal
B- Left tempoaral
C- Right parietal
D- Left parietal
Ans: C

141. A patient come with RTA and has spinal cord lesion completely cut what are the findings
A- Flaccid paralysis
B- Spastic paralysis
C- Upgoing planter
D- Bibniski sign positive
E- Absent knee jerk
Ans: B

142. 54 year old male went to doctor with complain of weakness of left half of body O/E He has tremors of left hand at end of movement. Muscular hypotonia of left limb And tendency to fall on left side. All Cranial nerve intact Neurological lesions located in:
A- Left Caudate and Putamen
B- Precentral gyrus
C- Right Cerebellar
D- Red Nucleus
E- Left Cerebellar
Ans: E

143. A patient comes to ophthalmology clinics with complain of gradual loss of vision his accomodation reflex was lost but light reflex was present
A- Presbyopia
B- Encephalitis
C- Hornor syndrome
D- 3rd nerve injury
Ans: A

144. Young patient presented in ward with complain of vomiting and drowsiness what is next step to confirm diagnosis
A- CBC
B- Cerebral examination
C- Endoscopy
D- LFT
Ans: B

145. Stab injury to neck posterolateral muscle is damaged which movement will be affected ?
A- Turing of face(neck)to opposite site
B- Medial movement of scapula
C- Lateral movement of scapula
D- Downward movement of neck
Ans: A

146. Old age patient complains of difficulty in reading near things and accomodation issue what is the cause ?
A- Lens curvature lost(or destroy)
B- Decrease contraction of ciliary muscle
C- Increase contraction of cilary muscle
D- Glaucoma
Ans: A

147. After gunshot injury to lower back, patient has loss of contraleral pain sensation but intact temperature sensation what is the likely diagnosis?
A- Section of dorsal root S1
B- Section of ventral root S1
C- Brown sequard syndrome
D- Early stage of tabes dorsalis
E- Syringomyelia
Ans: A

148. Man with normal hearing but cant recognize the source from which sound is coming
A- Medial geniculate body
B- Primary auditory area
C- Associated auditory area
D- Lateral superior olivary nucleus
E- Medial superior olivary nucleus
Ans: A

149. Bulbar palsy caused by:
A- Huntington Disease
B- Gullien berry
C- Motor neuron disease
D- Synringomeilia
Ans: C

CamScanner

150. A newborn is brought with lumbosacral swelling containing meninges without neural tissue What is most likely diagnosis of this swelling?

A- Spina bifida with Meningocele
B- Meningomyelocele
C- Encephalocele
D- Meningomyeloencephalocele
E- Anencephaly
Ans: A

151. Which of following finding will be found in person having bradycardia and Hypertension

A- Hypotension
B- Tachycardia
C- Malignancy
D- Regular Respiration
E- Raised ICP
Ans: E

Explanation:
- Cushing triad consists of bradycardia, hypertension, increase ICP & irregular respiration.

152. Patient having Paralysis of Right side of body with deviation of angle of mouth to the Left, Dribbling of saliva patient can close both eyes. Injury is at the level of:

A- Supranuclear
B- Pontine nucleus
C- Petrous part of temporal bone
D- Stylomastoid Foramen
E- Medulla
Ans: A (UMN Lesion)

153. A patient having Hemiplegia with same side deviation of angle of mouth and lateral rectus affeted lesion in ?

A- Mid brain
B- Medulla
C- Pons
D- Cortex
E- Internal Capsule
Ans: C

154. Mass in premotor anterioinferior part of periatal lobe affected result in

A- Face affected
B- Leg movement affected
C- Hand movement affected
D- Eye movement affected
Ans: B

155. A female having postpartum hemorrhage during delivery of twins after that she can't lactate her babies even her desire to lactate, she also complain that she remain 6 month lethargic after delivery where is problem that she can't lactate?

A- Pidtuatry adenoma
B- Sheehan syndrome
C- Shemron syndrome
D- Pralacinoma
Ans: B

156. CSF examination necessary to rule out.

A- Retinoblastoma/Melanoma of eye
B- Fever
C- Leukemia
D- Nasuea
Ans: A

157. In Internal capsule hemorrhage following will be present

A- Ipsilateral UMN sign
B- Contralateral UMN signs
C- Flacid paralysis
D- Atrophy
E- Dimnished Reflexes
Ans: B

158. A patient having Sensless speech and cannot remember which is said due to lesion of

A- Frontal lobe with mamilothalamic tract
B- Temporal lobe with mamilothalamic tract
C- Parietal lobe with mamilotahlamic tract
D- Occipital lobe with mamilothalamic tract
Ans: B

159. A patient with B/L vision loss and raised prolactin level and homonymous hemianopia due to lesion of:

A- Hypothalamus
B- Cortex
C- Anterior pituitary
D- Pons
Ans: C

160. 50 Year old man with R sided hemiparesis and carotid bruit + . Which investigation should done?

A- Carotid angiography
B- CT angiogram
C- MRI
D- Carotid artery Doppler
E- Only CT
Ans: D

CamScanner

161. In Alzheimer disease involve area of brain is following:
A- Prefrontal cortex
B- Basal ganglia
C- Hypothalamus
D- Caudate
E- Entorhinal cortex
Ans: E

162. Substance causing peripheral neuropathy and degeneration of myelin in CNS is:
A- Lead
B- Asbestos
C- Silicosis
D- Berilium
E- CO
Ans: A

163. Women developed painless gradual protrusion of one eye with normal X-Ray cause is?
A- Orbital vessel aneurysm
B- Optic nerve glioma
C- Thyroid ophthalmology
D- Meningioma
Ans: B

164. A patient is having bitemporal hemianopia with increase of jaw protrusion due to lesion of:
A- Pituitary adenoma
B- Optic nerve lesion
C- Optic radiation
D- Occipital cortex lesion
E- Optic tract lesion
Ans: A

165. Tourist has lateral gaze diplopia, Ataxia, CBC normal , CSF shows 50 – 120 mm pressure , protein 2.1 g/l , Glucose 50g/l , 90% lymphocytes Diagnose is?
A- Tb meningitis
B- Herpes encephalitis
C- Bacterial meningitis
D- Fungal meningitis
Ans: B

166) Patient after RTA Cant write speak and read most likely suffering from
A- Anomic aphasia
B- Global aphasia
C- Brocas aphasia
D- Wernicke aphasia
Ans: B

167) Regarding CSF exam true is
A- Low Glucose-Viral meningitis
B- High Glucose-Bacterial meningitis
C- Low Glucose-Bacterial meningitis
D- Normal glucose-Tb meningitis
Ans: C

168) A patient came with complain of fever , vomiting and neck rigidity diagnosed as meningitis. Which findings are abnormal in CSF of this patient?
A- Na 136
B- Ph 7.33
C- Glucose 60mg/dl
D- Protein 500
Ans: D

169) A patient know case of hypertension and he has stroke 1 year back with vision loss. Now his stroke and vision is improving. Actively he had complain of left homonymous hemianopia with left hemi spatial neglect which part of brain is affected
A- Right parietal and frontal area
B- Left parietal and frontal area
C- Right parietal cortex
D- Right temporal cortex
E- B/L Temporal cortex
Ans: C

170) If one spin in chair continously and stop suddenly fast phase of nystagmus is in opposite direction of rotation is called as
A- Diplopia
B- Nystagmus
C- Post rotatory nystagmus
D- Ptosis
Ans: C

171) A young boy faced RTA, he was rushed to emergency department he was irritated and restless but was opening eyes and localizing pain, looking towards the stimulus site, and his words were incomprehensible. How will you calculate his Glasgow Comma scale.
A- 6
B- 7
C- 9
D- 4
E- 11
Ans: E

172) In a Patient Jaw jerk absent, nucleus involved-
A- 5th nerve nucleus
B- Facial motor nucleus
C- Hypoglosal nucleus
D- Accessory nucleus
Ans: A

CamScanner

173) 85 year male Patient complain of lower backache doctor during examination noticed a outgrowu with tuft of hairs at LS what is your Diagnosis?

A- Spina bifida occulta
B- Anencephalay
C- Meningiomyocele
D- Meningicele
Ans: A

174) Damage to superior inferior parietal area. What will be affected?

A- Head movement
B- Face movement
C- Visual
D- Leg Movements
Ans: D

175) A patient comes to ophthalmology clinics with complain of gradual loss of vision his accommodation reflex was Present but light reflex was Lost:

A- Presbyopia
B- Encephalitis
C- Homorsyndrome
D- 3rd nerve injury
Ans: B

Explanation:
- Ptosis +Anhydrosis + Miosis –Horner Syndrome
- Light reflex present and Accomodation reflex lost –Presbyopia
- Light reflex Lost and Accomodation reflex Present –Encepbalitis

176) A young boys having Night blindmess, his elder brother also having the same problem during night which investigation wills you perform further to diagnose the cause of night blindness:

A- Electroretinogram
B- Electrooculogram
C- Flouresentangio gram
D- Visual evoked potential
Ans: A

177) A patient presented In ER with GCS E4V3M5 12/15 which part of brain is affected

A- Motor cortex
B- Temporal lobe
C- Visual cortex
D- Assocuated visual cortex
Ans: B

178) Patient eyes looks towards the site of lesion horizontal gaze centre has lesion in:

A- Medial longitudinal fasciculus (MLF)
B- Frontal eye field
C- Occipital cortex
D- Paramedia pontine reticular formation (PPRF)
Ans: B

Explanation:
Lesion of Frontal Eye field
- Eye Looks toward side of lesion

Lesion of PPRF
- Eye look away from side of leison

Lesion of MLF
- Intranuclear opthalmoplegia

179) Radiation entering retina will cause damage by:

A- Electrical
B- Photochemical
C- Chemical
D- Thermal
Ans: B

189) Glial fibrillary Acid protein positive in:

A- Meningioma
B- Astrocytoma
C- Epedymoma
D- Medulloblastoma
Ans: B

190) CNS lymphoma in patient on the lateral side of the brain what are the findings?

A- HIV RNA 8000
B- Positive nucleoside
C- Glucoside 200
D- HIV DNA
Ans: A

191) In stroke patient doppler showed increase perfusion, by which metabolite?

A- Decrease PCO2
B- Decrease N2
C- Decrease PO2
D- Increased PO2
Ans: C

Explanation:
Decrease O2 leads to increase CO2 which leads to increase perfusion

192) Syncope with change in posture due to:

A- Aortic stenosis
B- Subclavian steal syndrome
C- HOCM
D- Dilated cardiotnyopathy
Ans: B

CamScanner

193- Obesity is caused by lesion of which part of hypothalamus?
A- Ventromedial nucleus
B- Lateral hypothalamus
C- Posterior hypothalamus
D- Anterior hypothalamus
E- Inferior hypothalamus
Ans: A

Explanation:
- Lateral Nucleus is Feeding Centre its Damage result in Stop Feeding and make you Lean
- Medial Nucleus is Satiety Centre and its Damage result in Over eating and make you Massive (Obese)

194- Acetylcholine transferase deficiency occurs in?
A- Huntington
B- Alzehmeir
C- Myasthenia
D- Multiple sclerosis
Ans: C

195- Regarding parkinson disease treatment
A- Levodopa start early to decrease prolactin
B- Give anticholinergics before giving levodopa
C- Delay giving Levodopa
D- Carbidopa with Dopamine Bestc Treatment
Ans: A

196- Patient Came in semiconscious condition CSF analysis shows Glucose 20mg , Protein 150mg 75% Neutrophil and 20% Lymphocytes diagnose is
A- Acute Bacterial Meningitis
B- Partially treated Bacterial Meningitis
C- Tuberculosis
D- Encepblitis
Ans: B

Explanation:
- Partially treated Pyogenic meningitis may Have lymphocytes in CSF analysis

197- Pituitary tumor cause most common increase in which of following?
A- Cortisol
B- Prolactin
C- GH
D- Thyroid hormones
E- Glucagon
Ans: B

198- Myc gene associated with
A- Pituitary adenoma
B- Prostate cancer
C- Ewing sarcoma
D- Neurofibroma
E- t(8:14) in Burkit lymphoma
Ans: E

199- A patient with severe headache vomiting and neck stiffness raised ICP on Lumber puncture there was blood stained CSF diagnose is
A- Subdural hemorrhage
B- Cerebral hemorrhage
C- Extradural Hematoma
D- Subarachnoid hemorrhage
E- Intraparenchynal hemorrhage
Ans: D

200- Which disease makes patient resistant to muscle relaxation by succinylcholine?
A- Myasthenia gravis
B- Eaten lambert
C- Multiple sclerosis
D- GBS
Ans: A

201- In Kluver bucy syndrome which part of brain affected?
A- Amygdala
B- Hypothalamus
C- Thalamus
D- Cortex
Ans: A

202- Man got headache anorexia unwell for 3 days .O/E Pale dehydrated wasted Lumber puncture showed lymphocytosis 100/hpf protein 85 glucose 65 diagnosis
A- Malaria
B- Meningitis
C- Intracanial Tumor
D- Leptospira
Ans: B

203- Spike and dome appearance of pattern on eeg what is the cause:
A- Petit mal epilepsy
B- Acksonian epilepsy
C- Grand mal epilepsy
D- Hypoglycemic fits
Ans: A

204- Pineal gland defect result in:
A- Insomnia
B- Early puberty
C- Amonorrhea
D- Anuria
Ans: A

205- Posterior pituitary injury result in:
A- DM
B- Weight gain
C- Polyuria
D- Infection
Ans: C

CamScanner

Explanation:
In posterior pituitary lesion there is No ADH due to which no water reabsorption occur so all water filtered result in polyuria

206- Most common site of metastatic tumour in brain?
A- Cerebellum
B- Cerebral cortex
C- Brainstem
D- Substantia nigra
Ans: B

207- A Patient presented with headache, Neck stiffness and photophobia on LP glucose 40, and Raised Neutrophila. What is the diagnosis?
A- Encephlilis
B- Viral meningitis
C- TB meningitis
D- HSV
E- Pyogenic meningitis
Ans: E

208- Epidural hematoma is in spaee between:
A- Arachnoid and pia
B- Dura and arachnoid
C- Pia and brain
D- Dura and calvaria
E- Two layer of Dura
Ans: D

209- Intensioa tremors and jerky eye movements occur due to:
A- Midbrain lesion
B- Cerebellar chorea
C- Hyperthyroidism
D- Anxiety
E- Cortex lesion
Ans: B

210- 55 years old female taking phenolhiazine was observed to have slow flying movement in an attempt to remove a fly resting on her nose. This is mostly likely due to
A- Parkinsonism
B- Athetosis
C- Ballismus
D- Hemiballismus
Ans: B

211- Optic disc edema occurs in:
A- Retinal detachment
B- Hypertension
C- Hyperlipidemia
D- Hyponatremia
Ans: B

212- Multiple sclerosis is characterized by
A- Lewy bodies
B- Patchy demyelination of neurons
C- Axonal neuropathy
D- Nueronal hyperplasia
Ans: B

213- A patient has hyper reflexia and positive Babinski sign this is due to
A- Hypothalamus lesion
B- Cerebellar lesion
C- Brain infarct/CVA
D- Insomnia
Ans: C

214- A patient presented to emergency with history of fall, he opens eyes on giving painful stimulus, has incomprehensible speech and localizes pain. His GCS is:
A- 7
B- 8
C- 9
D- 10
Ans: C

215- Child having hydrocephalus due to defect in:
A- Meninges
B- Ependymal cells
C- Epidural space
D- Arachnoid Granulations
Ans: D

216- A patient had injury on head. He remained unconscious for a short period of time. CT showed crescent shaped hematoma. Diagnosis?
A- Epidural hematoma
B- Subdural hematoma
C- Subarachnoid hematoma
D- Subarachnoid hemorrhage
Ans: B

217- Most common intracranial tumor is:
A- Meningioma
B- Schwanoma
C- Astrocytoma
D- Glioma multiforme
Ans: C

218- Amyotrophic lateral sclerosis (Lou Gehrigs Disease) caused by degeneration of neurons in:
A- Ventral horns
B- Anterior horn
C- Dorsal horn
D- Cranial horns
Ans: B

219- Patient presented with fever, neck rigidity, kerning sign +ve which investigation should be carried out?
A- CBC
B- CSF analysis
C- Blood culture
D- Bone marrow biopsy
Ans: B

220- Patient presented with peripheral tingling numbness diplopia and visual disturbance diagnosed with demyelination disease what type nervous system cells are affected in this disease
A- Oligodendrocytes
B- Schwan cells
C- Astrocytes
D- Glial cells
Ans: A(Multiple sclerosis)

221- Security guard had history of fall and remain unconscious for 30 sec. His neurological examination is unremarkable. He is having irregular pulse what is cause?
A- Stroke
B- TIA
C- Syncope
D- Infection
Ans: C

222- Which scale can be used to assess the abnormal behaviors in a person?
A- Minnesota Multiphasic scale
B- HAD scale
C- Y-BOCS
D- Advanced mental test score
Ans: D

223- Patient with lesion in brain, present with Resting tremor, stooped posture, shuffling gait, cogwheel rigidity and expressionless face. Lesion in which part of brain:
A- Cerebrum
B- Cerebellum
C- Substantia nigra
D- Pons
E- Medulla
Ans: C

224- Patient suffers eva, he cant understand spoken words but can read words, which area is involved most likely?
A- Secondary auditory area
B- Primary auditory area
C- Visual cortex
D- Corpus callosum
E- Frontal Lobe
Ans: B

225- Hard blow to skull resulting in depressed fracture With no splintering is more specifically called as:
A- Pond fracture
B- Blowout fracture
C- Depth fracture
D- Depression fracture
E- Gutter fiacture
Ans: A

226- In Brain damage after stroke, Which type of cells can be seen initialing the regeneration process?
A- Glial cells
B- Schwann cells
C- Oligodendrocytes
D- Protoplasmic astrocytes
E- Neurons
Ans: D

Explanation:
- Cells seen in damaged brain tissue – Glial cells
- Cell for repair after damaged brain tissue – Astrocytes

227- A patient bas ptosis and pinpoint pupils due to
A- Cervical Sympathetic Chain damage
B- Facial nerve damage
C- Parasympathetic damage
D- Abducent nerve damage
E- Occulomotor nerve damage
Ans: A

Explanation:
- Ptosis + Miosis -- Horner syndrome(Sympathetic damage)
- Ptosis+Mydriasis – 3 rd Nerve palsy
- Ptosis + normal pupil -- Myesthenia gravis

228- Patient unable to understand spoken words but can understand written words damage to which area?
A- Primary auditory cortex
B- Secondary auditory cortex
C- Temporal lobe
D- Inferior frontal lobe
Ans: A(Wernike area damage)

229- Person with hypertension and Raised ICP which one of the following will decrease
A- Blood flow
B- Hean rate
C- Headache
D- Blood pressure
Ans: B

CamScanner

230- A patient bad stroke and now on Doppler he has increased blood flow what is the reason for this increase in cerebral blood flow?
A- Decreased po2
B- Increased pco2
C- Increase o2
D- Increase N2
Ans: B

231- A patient presented with Hyperphagia, Hyperorality & increased Libido. Which part of the Brain is affected?
A- Amygdala
B- Hypothalamus
C- Thalamus
D- Cortex
Ans: A(Kluver Bucy Syndrome)

232- Lou Gehrig's disease is caused by degeneration of neurons in:
A- Posterior horn
B- Anterior horn
C- Lateral horn
D- White matter
E- Grey matter
Ans: B(Amyotrophic Lateral Sclerosis)

233- Patient Having Fever, neck rigidity and Slight SOB. CSF report reveals Increase lymphocytes, Glucose 40 and Proteins . Which of the following test is routinely done for the diagnosis of meningitis?
A- CSF Culture
B- Lumbar puncture
C- Blood Culture
D- Ct Brain
Ans: B

234- A patient presented with paralysis of B/L Lower Limbs & Lower half of face. Power 3/5 in both limbs. Homonymous hemianopia along with Loss plantar reflexes. Lesion present in which of following?
A- Basilar pons
B- Forebrain
C- Midbrain
D- Medulla
E- Tegmentopontine area
Ans: B

235- 21-year-old woman presents with complaints of progressive weakness in her legs, intermittent blurred vision, and tingling sensations in her hands and feet over the past few months. Neurological examination reveals bilateral optic neuritis, weakness in the lower extremities, and exaggerated reflexes. What is the likely Defect?
A- Demylination of CNS neuron
B- Schwann cells
C- Astrocytes
D- Microglia
E- Neurons
Ans: A

236- A patient presented with bilateral ptosis wirh muscle wasting on mastication and decrease voice untill no voice uttered diagnosed as myasthenia gravis . Best test for it
A- Anti calcium antibodies
B- EMG
C- Edrophonium
D- Acb receptors antibodies
E- Tensilon test
Ans: B

237- A man during a road side accident suffer injury to cervical sympathetic chain most likely changeia eye:
A- Ipsilateral sweating
B- Ipsilateral pupil constriction
C- Mydriasis
D- Isohydrosis
E- Increase salivation
Ans: B

238- A patient with dilated ventricles and having defect in CSF absorption due to defect in
A- Meninges
B- Ependymal cells
C- Epidural space
D- Arachnoid Granulations
E- Chroid plexuses
Ans: D

239- A man during road traffic accident got injury to cervical sympathetic chain. Most likely change in eye is:
A- Ipsilateral Drooping of eye lids
B- Ipsilateral mydriasis
C- Flushing of face on opposite site
D- sweating on ipsilateral side
E- cilliay muscle paralysis
Ans: A

240- A patient had injury on head. He remained unconscious for a short period of time. CT showed crescent shaped hematoma. Diagnosis?
A- Epidural hematoma
B- Subdural hematoma
C- Subarachnoid hematoma
D- Subarachnoid hemorrhage
Ans: B

241- Patient presented with dizziness and vertigo after history of fall. On CT scan subdural haemorrhage is suspected. Which of the following vessels is involved?
A- Vertebral arteries
B- Meningeal arteries
C- ACA
D- pCA
E- Cerebral veins
Ans: E

242- A patient with unable to move eye to lateral side and having contralateral hemiparesis due to lesion of
A- Cortex
B- Pons
C- Cerebellum
D- Thalamos
Ans: B

243- A 25 years old female with relapsing remitting course of neurological deficit related to
A- Spectin
B- Myelin
C- Titin
D- Fibrin
Ans: B(Demyelinating disease)

244- After injury to cortex which supporting cell will be present?
A- Oligodendroglial
B- Ependymal
C- NK cells
D- Epithelial cells
Ans: A

245- A young boy busy, Hyperventilating with Sweating, Heart rate 110bpm & BP of 150/80. Which of the following is the most likely cause:
A- Mental Stress
B- Exercise
C- Excitement
D- Dehydration
E- Sympatholytic Drugs
Ans: A

246- 21-year-old woman presents with complaints of progressive weakness in her legs, intermittent blurred vision, and tingling sensations in her hands and feet over the past few months. Neurological examination reveals bilateral optic neuritis, weakness in the lower extremities, and exaggerated reflexes. What is likely Defect?
A- Demylination of CNS neuron
B- Schwann cells
C- Astrocytes
D- Microglia
E- Neurons
Ans: A

247- Patient was operated for small tumor blocking the cerebral aqueduct, after few days presented with disturbance of sleep, which nucleus is damaged?
A- Suprachiasmatic Nucleus
B- Reticular Formation
C- Paraventricular Nucleus
D- VentroMedial Nucleus
Ans: B

248- A Person after RTA is unable to speak and has non fluent Speech but can understaod commands lesion is in which of followiog:
A- Brocas Area
B- Internal Capsule
C- Primary motor area in postcentral gyrus
D- Wernickies Area
E- Medulla
Ans: A

249- A Person after RTA is unable to speak and has non fluent Speech but can understand commands lesion is io which of following:
A- Brocas . Area
B- Internal Capsule
C- Primary motor area in postcentral gyrus
D- Wernickies Area
E- Medulla
Ans: A

250- Neurological examination indicates that a 50 years old woman with hypertension has left homonymous hemianopia but is not aware of her deficit (anosognosia). When asked to copy a drawing of a clock face, she neglect to draw numerals on left side of the clock. Based on this examination lesion would most likely be in the
A- Frontal lobe
B- Insula
C- Right parietal lobe
D- Right temporal lobe
E- Left parietal lobe
Ans: C

CamScanner

251- A man working in factory has neuronal degeneration due to exposure to:
A- Organophosphate poisoning
B- Arsenic poisoning
C- Lead poisoning
D- Aspirin poisoning
Ans: C

252- A 45-year-old man presents with inability of feel heat or cold on the left side of his body. On examination, there is loss of vibration, position sense, deep touch, and motor functions of the right lower limb. What is the most likely diagnosis?
A- Brown Sequard syndrome
B- Tabes dorsalis
C- Syringomyelia
D- Posterior cord syndrome
E- Anterior cordi syndrome
Ans: A

253- Which of the following is feature of UMN lesion
A- Atrophy
B- Flaccid paralysis
C- Diminished reflexes
D- Spasticity
Ans: D

254- A patient presented with damage to cervical chain. Symptoms present would be?
A- Diplopia
B- Pupilary constrictioo
C- Cutaneous flushing
D- Mydriasis
Ans: B

255- A patieat had RTA, he does not know recent events but he remembers his school events where is the lesion?
A- Arcuate
B- Amygdala
C- Hippocampus
D- Frontal lobe
E- Temporal lobe
Ans: C

256- Person with diabetes, now cant speak and walk, tries to reach phone but cannot also having exaggerated hlanter reflex which artery is involved
A- Middle cerebral artery
B- Anterior communicating artery
C- Posterior cerebral artery
D- Vertebral artery
Ans: B

257- A patient presents with right-... asterognosis, which is the inability ... recognize objects by touch. Which of ... following is the most likely cause?
A- Left internal capsule
B- Right internal capsule
C- Occipital lobe
D- Left parietal lobe
Ans: D

258- The Babinski sign is a reflex where ... big toe extends upward and the ... toes fan out when the sole of the foot ... stroked. This reflex is normal in infants ... but disappears as the nervous system ... matures. How does the Babinski sign ... disappear in children?
A- Myelination by oligodendrocytes
B- Myelination by Schwann cells
C- Formation of corticospinal tracts
D- Formation of vestibulospinal tracts
Ans: C

259- A patient having temperature of 39°C, cold clammy skin, sweating profusely, and working on a hot day, brought to the hospital in semiconscious state is most likely due to:
A- Heat Stroke
B- Dehydration
C- Hyponatremia
D- Normal phenomenon
E- Excessive sweating
Ans: B

260- An increase in cerebrospinal fluid circulation due to impaired absorption is most commonly associated with fault in which of the following structures?
A- Arachnoid granulations
B- Pial granulations
C- Oligodendrocytes
D- Venous sinuses
E- Schwann cells
Ans: A

261- A patient with a spinal cord injury at T6 presents with severe hypertension, pounding headaches, and sweating above the level of the lesion. What is the most likely cause of these symptoms?
A- Horner's syndrome
B- Autonomic dysreflexia
C- Neurogenic shock
D- Central cord syndrome
E- Postural hypotension
Ans: B

262- A 45-year-old patient presents with symptoms of excessive heat production and profuse sweating. Imaging reveals a space-occupying lesion in the brain. Which area is most likely to be affected by this lesion?
A- Hypothalamus
B- Thalamus
C- Cortex
D- Medulla
E- Cerebellum
Ans: A

263- Recent memory loss occurs due to lesion in:
A- Hippocampus
B- Amygdala
C- Neocortex
D- Prefrontal cortex
E- Thalamus
Ans: A

264- A patient had RTA 6 months back) He does not know recent events but he remembers Events from his youth. Which one is involved in This case?
A- Temporal Lobe
B- Hippocampus
C- Parietal Lobe
D- Thalamus
E- Amygdala
Ans: B

265- Most common cerebellar tumor in Children?
A- GBM
B- Meningioma
C- Medulloblastoma
D- Ependymoma
E- Pilocytic Astrocytoma
Ans: C

266- Most common cerebellar tumor in Children"?
A- GBM
B- Meningioma
C- Medulloblastoma
D- Ependymoma
E- Pilocytic Astrocytoma
Ans: C

267- Unilateral, severe episodic periorbital headache with tearing and conjuctival erythema? (Medicine Feb 2025)
A- Migraine
B- Cluster headache
C- Tension headache
D- Subarachnoid hemorrhage
Ans: B

268- A male patient experiences recurreot episodes of severe unilateral throbbing headaches, often accompanied by tears from eyes and runny nose. During acute attacks, he becomes agitated and restless. He is having history of these symptoms occuriog weekly from past 3-4 months.What is the most likely diagnosis? (Medicine Feb 2025)
A- Migraine
B- Cluster Headache
C- Tension Headache
D- IgE Type-I HSR
E- Vasculitis
Ans B

269- A patient presents with a throbbing headache, tearing from tbe eyes, and a runny nose occurring every week for the past 3-4 months. What is the most likely diagnosis?(Surgery Feb 2025)
A- Migraine
B- Cluster beadache
C- Tension Headache
D- Giant Cell arteritis
Ans: B

270 A 20-year-old girl, who is a graphic designer, presents with difficulty reading, clumsiness io ber arms while steering her bike, and vision problems. She has been referred to physiotherapy to regain motor control. Blood tests reveal positive autoimmune antibodies, and imaging shows a lesioo in the corpus callosum. What is the most likely diagnosis? diagnosis?(Surgery Feb 2025)
A- Multiple sclerosis
B- Myasthenia Gravis
C- Schwanomma
D- Acoustic Neuroma
E- Lambert Eaton syndrome
Ans: A

271- Calculate GCS with the following responses: Eye opening to verbal stimulation. Localizes to pain, Incomprehensible speech. Most probable diagnosis?(Surgery Feb 2025)
A- 8
B- 9
C- 10
D- 11
Ans: C

Explanation:
The Glasgow Coma Scale (GCS) is calculated as the sum of:
- **Eye Response (E):** 3 (to stimulation)
- **Motor Response (M):** 5 (localizes to pain)
- **Verbal Response (V):** 3 (incomprehensible speech)

Total GCS = 3 + 5 + 2 = 10

CamScanner

272- Disequilibrium response of Autonomic nervous system shown in which of following? diagnosis?(Surgery Feb 2025)
A- Cerebellar Ataxia
B- Hyperhydrosis
C- Cushing reflux
D- Hydrocephalus
E- Raised ICP
Ans: C

273- A patient presented to emergency with history of fall, he opens eyes on giving painful stimulus, has incomprehensible speech and localizes paia. His GCS is: diagnosis?(Surgery Feb 2025)
A- 7
B- 8
C- 9
D. 10
Aus: C

Explanation:
The Glasgow Coma Scale (GCS) is a clinical tool ased to assess a patient's level of consciousness. particularly in cases of traumatic brain injury. It evaluates three components:
Components and Scoring:
1. Eye Opening (E)
- 4: Spontaneous
- 3: To verbal command
- 2: To pain
- 1: No response
2. Verbal Response (V):
- 5: Oriented (e.g., knows name, location. time)
- 4: Confused conversation
- 3: Inappropriate words
- 2: Incomprehensible sounds
- 1: No response
3. Motor Response (M):
- 6: Obeys commands
- 5: Localizes pain
- 4: Withdraws from pain
- 3: Abnormal flexion (decorticate posture)
- 2: Abnormal extension (decerebrate posture)
- 1: No response

Total GCS Score:
- Range: 3 (deep coma to 15 (fully awake and alert)
- Interpretation:
- 13–15: Mild injury
- 9–12: Moderate injury
- 3–8: Severe injury (coma)

274- A patient presents with raised blood pressure and laboratory findings sbowing bicarbonate levels of 35 mmol/L. Imaging reveals dilated ventricles in the posteror fiosa. What Is the most likely diagnosis? (Surgery Feb 2025)
A- Dandy Walker Malformation
B- Friedrich ataxia
C- Aqueduct stenosis
D- Cerebellar ataxia
Ans: A

275- A patient presented with trauma got flaccidity which later progress Upper motor neuron lesion limb and lower motor neuron le ulper limb. No sensory abnormal parasympathetic involvement Bladder function & perinatal is intact. Most suitable diagnosis (Gynae Feb 2025)
A- Cauda equina syndrome
B- Coims medullaris syndrome
C- Brown-Scquard syndrome
D- Spinal shock
E- Complete cord paralysis
Ans: D

276- Patient presents with chorea, retardation. depression and lapse Neurotransmitter Decreased this condition? (Radiology Feb 2025)
A- Dopamine
B- GABA
C- Serotonin
D- Acetyl Choline
Ans: B(Kumar anıl Clarke medicine)

Explanation:
Changes in Neurotransmitters in Parkinson's and Huntington's Diseases

Parkinson's Disease	Huntington's Disease
Site: Putamen	Site: Corpus striatum
- Dopamine ↓ 90%	- Acetylcholine ↓
- Norepinephrine (noradrenaline) ↓ 60%	- GABA ↓
- 5-HT ↓ 60%	- Dopamine normal
Site: Substantia nigra	- GAD + GABA ↓↓
- Dopamine ↓ 90%	
- GAD + GABA ↓↓	
Site: Cerebral cortex	
- GAD+ GABA ↓↓	

277- A patient presents with beadache confusion but shows no signs meningeal irritation. What is investigation of choice? (Radiology Feb 2025)
A- Lumbar Puncture
B- Culture and Sensitivity (C/S)
C- CBC
D- CT Scan bram
Ans: D

278- Strychnine Causes convulsions by (Radiology Feb 2025)
A- Gaba
B- Glycine
C- Dopamme
D- Acetylcholine
Ans: B

279- Patient diagnosed a Case of meningitis. Which function of CSF was disrupted due to meningitis?(Radiology Feb 2025)
A- Absorption of CSF
B- Less nutrition to Brain Tissue
C- Regulation of ICP
D- Protection of Brain tissue by CSF
E- Excretion of CSF
Ans: A

280- aircraft engineer presented in ent department with progressive decrease in hearing. His audiogram shows(Radiology Feb 2025)
A- Decrease hearing of htgh frequency sounds.
B- Decrease hearing of low frequency sounds.
C- A dip at 2000 hz
D- Difference of sounds at 40 db.
Ans: A

Explanation:
- Aircraft engineers are commonly exposed to chronic noise at high frequencies, which leads to noise-induced hearing loss (NIHL). This condition primarily affects the high-frequency sounds in the range of 3000–6000 Hz, as these frequencies are most vulnerable to prolonged noise exposure.
- **Low-frequency sounds:** More commonly associated with conditions like Meniere's disease.
- **Dip at 2000 Hz:** Indicates Carhart's notch, which is specific to otosclerosis.
- **Difference of sounds at 40 dB:** Not a standard diagnostic feature of NIHL

281- Drooping of eyelid seen if damage to? (Radiology Feb 2025)
A. Sympathetic
B. Parasympathetic
C. Facial Nerve
D. Trigeminal Nerve
E. Optic nerve
Ans: A

282- Spike and slow wave pattern on eeg what is the cause? (Anesthesiu Feb 2025)
A. Petit mal epilepsy
B. Acksonian epilepsy
C. Grand mal epilepsy
D. Hypoglycemic fits
Ans: A

283- Which is characteristics lesion in cerebellar disease(Anesthesiu Feb 2025)
A. Nystagmus
B. Hypotonia
C. Ataxia
D. Dysmetria
E. Resting tremors
Ans: D

284- In meningitis which CSF lab value is most likely abnormal(Anesthesia Feb 2025)
A- PH 7.3
B- Sodium 144mg/dl
C- Protein 400-500mg/dl
D- Chloride 120mg/dl
E- Glucose 60mg/dl
Ans: C

285- In decrebrate animal what happens(Anesthesia Feb 2025)
A- Extention of arm and flexion of knee
B- Flexton of arm and extention of knee
C- Extention of arm and extention of knee
D- Flexion of arm and flexion of knee
Ans: C(first aid)

Explanation:
- **Decorticate (flexor)** posturing- lesion above red nucleus,presents with flexion of upper extremities and extension of lower extremities
- **Decerebrate(extensor)** posturing –lesion at or below the red nucleus,presents with extention of upper and lower extremities

CamScanner

NEUROANATOMY QUICK HINTS

Ventricle

- ✓ Choroid plexus—contains choroid epithelial cells and is in the lateral, third, and fourth ventricles. Secretes CSF. Tight junctions form blood-CSF barrier
- ✓ Blood-brain barrier—formed by capillary endothelium with tight junctions; astrocyte foot processes contribute.
- ✓ About 70% CSF secreted by Choroid plexus and 30% represent metabolic water

CSF

- ✓ CSF Density is 1.0005
- ✓ CSF Specific Gravity is 1.005.
- ✓ CSF PH is 7.33.
- ✓ CSF is isotonic with serum.
- ✓ CSF has Equal sodium as compared to plasma
- ✓ CSF has High magnesium and chloride as compared to plasma
- ✓ CSF has More Creatinine as compared to plasma
- ✓ Rest every thing is Low in CSF as compared to plasma (Protein more Low than glucose)
- ✓ CSF is produced by—Ependymal cells
- ✓ CSF Provides nutrition to—CNS
- ✓ Arachnoid granulations are seen by naked eye
- ✓ Indicator for CSF Leak — Beta 2 Transferin
- ✓ CSF Has Cushion like effect
- ✓ Maximum determinant of CSF composition is Ependymal cells
- ✓ CSF Pressure – 10-20 cm H2O or 60-150mm H2O or 6-15mmhg
- ✓ CSF production – 20ml/h
- ✓ CSF production – 450-500 ml /day
- ✓ CSF in Ventricle and Subarachnoid space – 150ml
- ✓ Lateral ventricle to 3rd via Interventricular Foramina of Monro
- ✓ 3rd to 4th via cerebral aqueduct (blockage can cause hydrocephalus)
- ✓ 4th to Subarachnoid space via Foramen Magendie and Foramen Luschka
- ✓ CSF made by choroid plexus (Ependymal cells) in 4th and lateral ventricle
- ✓ CSF absorbed by arachnoid granulations and then drains into Dural venous sinus

Spinal cord

- ✓ Conus medullaris Caudal end of the spinal cord (S3–S5). In adult, ends at the L2 vertebra
- ✓ Cauda equina Nerve roots of the lumbar, sacral, and coccygeal spinal nerves
- ✓ Filum terminale Slender pial extension that tethers the spinal cord to the bottom of the vertebral column
- ✓ Cervical enlargement (C5–T1) → brachial plexus → upper limbs
- ✓ Lumbar enlargement (L2–S3) → lumbar and sacral plexuses → lower limbs
- ✓ White matter has -Tracts and fasciculi
- ✓ Gray matter has
  - Dorsal horn (sensory)
  - Ventral horn (motor)
  - Intermediate zone (autonomic neurons T1 -L2 S2 -S4)
  - Clarke's nucleus
- ✓ Polio involve anterior horn and Damage LMN
- ✓ Syringomyelia may present with hydrocephalus and Arnold Chiari I malformation
- ✓ Syringomyelia results in a "belt- like" or "cape-like" loss of pain and temperature bilateral
- ✓ Loss of Contralateral Temperature and Intact Pain sensation lesion of - Dorsal root S1

Motor Pathway (Descending)

Corticospinal Tract

- ✓ The cell bodies of upper motoneu- rons are found in the brain stem and cerebral cortex
- ✓ The primary motor cortex, located in the precentral gyros of the frontal lobe
- ✓ 80-90% Fibers decussate at pyramid of medulla

Lesion

- ✓ If lesions of the corticospinal tract occur above the pyramidal decussation, a weakness is seen in muscles on the contralateral side of the body.
- ✓ Lesions occur below this level, an ipsilateral muscle weakness is seen.

Sensory Pathway (Ascending)

- ✓ Sensory Cortex located in Postcentral gyros of anterior parietal Lobe

Dorsal column–medial lemniscal system (Posterior Column)

- ✓ Carries proprioception, vibration sense and fine touch and Two point Descrimination
- ✓ Fasciculus Gracilis Located in all spinal level Related to Lower limb
- ✓ The fasciculus cuneatus, found only at upper thoracic and cervical spinal cord levels Related to Upper limb
- ✓ Class II or A-beta dorsal root fibers

Lesions

- ✓ Lesions of the dorsal columns result in a loss of joint position sensation, vibratory and pressure sensations, and 2-point discrimination.
- ✓ There is loss of the ability to identify the characteristics of an object, called **astereognosis** (e.g., size, consistency, form, shape), using only the sense of touch.
- ✓ Evaluated by testing vibratory sense using a 128-Hz tuning fork.
- ✓ Asking the patients to place their feet together if the patient sways with the eyes closed, this is a **positive Romberg sign indicate DCML lesion vs Fall with Open eye indicate Cerebellar lesion**
- ✓ Also Astereognosis due to lesion in - Somesthetic association area > Primary somatosensory area

Anterolateral (spinothalamic tract) system

- ✓ The anterior tract carry Crud touch
- ✓ Lateral tract carry Pain and Temperature
- ✓ Trigemmothalamic Tract carry Pain and Temperature from Face
- ✓ Lesion of Lateral tract cause loss of contralateral pain and temp 1 or 2 segment belowlevel of lesion
- ✓ A-delta and C or class III and class IV dorsal root fibers.

Pathway	First Order	Second Order	Third Order
Anterolateral	Posterior Root Ganglion	Substantia gelatinosa	VPL Thalamus
DCML	Posterior Root Ganglion	Nuclei gracilis & Cuneatus	VPL Thalamus

Spinocerebellar Pathway

- ✓ Dorsal spinocerebellar tract—carries input from the lowerextremities and lowertrunk
- ✓ Cuneocerebellar tract—carries input from the upper extremities and upper trunk
- ✓ External posterior arcuate form- Cuneocerebellar
- ✓ External Anterior arcuate form - Pontocerebellar
- ✓ Internal arcuate form - Dorsal medial lemniscus
- ✓ Friedreich ataxia may affect these tract and Ataxic gait common symptom

Brown Squard Syndrome

Hemisection of spinal cord findings

- ✓ Ipsilateral loss of all sensation at level of lesion
- ✓ Ipsilateral LMN signs (eg, flaccid paralysis) at level of lesion
- ✓ Ipsilateral UMN signs below level of lesion (due to corticospinal tract damage)
- ✓ Ipsilateral loss of proprioception, vibration, light (2-point discrimination) touch, and tactile sense below level of lesion (due to dorsal column damage)

CamScanner

✓ Contralateral loss of pain, temperature, and crude (non-discriminative) touch below level of lesion (due to spinothalamic tract damage)

Bladder injury

Injury above sacral segment (sympathetic damage) cause:

✓ Spastic Bladder
✓ Automatic Bladder
✓ Urge Incontinence

Injury at sacral segment (parasympathetic damage) cause:

✓ Atonic Bladder
✓ Autonomous Bladder
✓ Overflow Incontinence

Note: Neurogenic is common term for both spastic and Atonic Bladder.

Brainstem

Cranial nerves

✓ Cranial nerve 3 4 arise from - Midbrain
✓ Cranial nerve 5-8 arise from -Pons
✓ Cranial nerve 9,10 and 12 arise from- Medulla
✓ Fibers of the accessory nerve arise from the cervical spinal cord.
✓ Pure Sensory CN 1, 2, 8
✓ Pure motor CN 3, 4, 6, 11, 12
✓ Mixed CN 5, 7, 9, 10
✓ Parasympathetic CN 3,7,9,10
✓ Abducent – Lateral Rectus(LR6)
✓ Trochlear – Superior oblique(SO4)
✓ Occulomotor – Rest extraocular muscles
✓ Vertical Diplopia – CN 4 >CN3
✓ 4th nerve palsy – Diplopia on seeing down (vertical).
✓ 3rd nerve palsy – Diplopia on seeing down (Vertical) and or right and left (horizontal).
✓ 6th Nerve palsy - Diplopia on seeing right or left (horizontal).
✓ CN V motor lesion – Jaw deviates toward side of lesion
✓ CN X lesion – Uvula deviates away from side of lesion
✓ CN XI lesion – Weakness turning head to contralateral side of lesion (SCM) Shoulder droop on side of lesion (trapezius)
✓ CN XII lesion – LMN lesion Tongue deviates toward side of lesion

Random

✓ The pons is located between the medulla (caudally) and the midbrain (rostrally)
✓ The midbrain (mesencephalon) is located between the pons and diencephalon.
✓ Cerebellum connected to mid brain – Superior cerebellar peduncle
✓ Cerebellum connected to medulla – Inferior cerebellar peduncle
✓ A section of horizontal fibers in caudal pons – Middle cerebellar peduncle.
✓ Superior colliculus – Vision
✓ Inferior colliculus – Auditory
✓ Spinal cord Blood supply by Spinal branches of Vertebral artery
✓ Anterior two third of spinal cord by - one Anterior spinal artery
✓ Posterior one third of spinal cord by - two Posterior spinal artery

Auditory system

✓ Linear Acceleration(Bus): Utricle
✓ Vertical Acceleration(Lift)- Saccule
✓ Angular Acceleration- Semicircular canal
✓ A lesion of the vestibular nuclei or nerve produces a vestibular nystagmus with a slow deviation of the eyes toward the lesion and a fast correction back to the right.
✓ Cold water irrigation of ear → nystagmus to opposite side
✓ Warm water irrigation of ear → nystagmus to same side

Conductive Hearing loss

✓ Negative Rinne test ie BC >AC
✓ Weber lateralised to poorer ear
✓ Low frequency affected more
✓ Loss is not more than 60 dB

Sensorineural Hearing loss

✓ Positive Rinne test ie AC >BC
✓ Weber lateralised to Better ear
✓ High frequency affected more
✓ Loss is more than 60 dB

Lesion of Frontal Eye field

✓ Eye Looks toward side of leison

Lesion of PPRF

✓ Eye look away from side of leison

Lesion of MLF

✓ Intranuclear opthalmoplegia

Medullary Syndrome

Medial Medullary Syndrome

✓ Anterior Spinal Artery
✓ Pyramid: contralateral spastic paresis
✓ Medial lemniscus: contralateral loss of tactile, vibration, conscious proprioception
✓ XII nucleus/fibers: ipsilateral flaccid paralysis of tongue with tongue deviation on protrusion to lesion side.

Lateral Medullary Syndrome

✓ **PICA, Wallenberg Syndrome**
✓ **Inferior cerebellar peduncle:** ipsilateral limb ataxia
✓ **Vestibular nuclei:** vertigo, nausea/vomiting, nystagmus (away from lesion)
✓ **Nucleus ambiguus (CN IX, X):** ipsilateral paralysis of larynx, pharynx, palate → dysarthria, dysphagia, loss of gag reflex
✓ **Spinal V:** ipsilateral pain/temperature loss (face)
✓ **Spinothalamic tract:** Contralateral pain/temperature loss (body)
✓ **Descending hypothalamics:** ipsilateral Horner syndrome

Pontine Syndrome

Medial Pontine Syndrome

✓ Paramedian Branches of Basilar Artery
✓ Corticospinal tract: contralateral spastic hemiparesis
✓ Medial lemniscus: contralateral loss of tactile/position/vibration sensation
✓ Fibers of VI: medial strabismus

Lateral Pontine Syndrome

✓ AICA
✓ Middle cerebellar peduncle: ipsilateral ataxia
✓ Vestibular nuclei: vertigo, nausea and vomiting, nystagmus
✓ Facial nucleus and fibers: ipsilateral facial paralysis; ipsilateral loss of taste (anterior two-thirds of tongue), lacrimation, salivation, and corneal reflex; hyperacusis
✓ Spinal trigeminal nucleus/tract: ipsilateral pain/temperature loss (face)
✓ Spinothalamic tract: contralateral pain/temperature loss (body)
✓ Cochlear nucleus/VIII fibers: ipsilateral hearing loss
✓ Descending hypothalamics: ipsilateral Horner syndrome

Midbrain syndrome

Medial Midbrain (Weber) Syndrome

✓ Branches of PCA
✓ Fibers of III: ipsilateral oculomotor palsy (lateral strabismus, dilated pupil, ptosis)
✓ Corticospinal tract: contralateral spastic hemiparesis

CamScanner

✓ Corticobulbar tract: contralateral hemiparesis of lower face

Hemiplegia

Uncrossed Hemiplegia:

✓ Same sided hemiplegia and same sided face involve (Angle deviate to opposite) lesion in – Internal capsule (forbrain) or cortex or supranuclear.

Crossed hemiplegia:

✓ One sided hemiplegia and other side face involve – Brainstem (Pons/Midbrain)

Cerebellum

✓ Most afferent reach via ICP and MCP

✓ Most Efferent leave via SCP

3 layers

✓ The molecular layer is the outer layer and is made up of basket and stellate cells as well as parallel fibers, which are the axons of the granule cells

✓ The Purkinje layer is the middle and most important layer and Form only outflow tract

✓ The granule cell layer is the innermost layer of cerebellar cortex and contains Golgi cells, granule cells, and glomeruli

Cells

✓ Granule cells release Glutamate excite Purkinji cell

✓ Basket and Satellate cell release GABA inhibit purkinji cell

✓ Golgi cell release GABA inhibit Granule cells

✓ **Purkinji cell release GABA inhibit Deep cerebellar nuclei**

Afferent

✓ Mossy fibers - Vestibulocerebellar, Spinocerebellar and Pontocerebellar exert extitatory terminals on Granule cells

✓ Climbing fibers - Olivocerebellar exert extitatory terminals on purkinji cells

Nuclei

✓ Lateral to medial – Dentate, interposed (globose and emboliform), fastigial

Lesion

Vermis lesion

✓ Anterior vermis lesions are usually the result of degeneration from alcohol abuse and are present with gait ataxia.

✓ Posterior vermis lesions result from medulloblastomas or ependymomas and present with truncal ataxia (Drunken Sailor gait)

Hemisphere lesion

✓ Intension tremors

✓ Dysdiadochokinesia

✓ Dysmetria (past pointing)

✓ Scanning dysarthria

✓ Nystagmus

✓ Hypotonia

✓ Will not lead to muscle paralysis

Basal ganglia

✓ **Neostriatum** – Caudate +Putamen

✓ **Corpus striatum** – Caudate +Lantiform

✓ **Paleo striatum** – Globus pallidus

✓ **Lantiform nucleus** – Globus pallidus + Putamen

✓ Dopamine drive direct pathway

✓ Acetylcholine drive indirect pathway decrease cortical excitation

✓ Dopamine excite direct pathway via D1 and inhibit indirect pathway via D2

✓ Both basal ganglia pathways utilize 2 GABA neurons in series, and a "disinhibition."

✓ All basal ganglia connections are with ipsilateral cortex

Lesion

✓ Caudate lesion - Chorea

✓ Globus pallidus lesion -Athetosis

✓ Subthalamus lesion - Hemiballismus

✓ At Mid collicular = Decerebrate rigidity >> Inc. Extensors tone in all four limbs.

✓ Below Superior colliculus = Decorticate rigidity >> Inc. flexor tone in upper limbs

Visual pathway

Accommodation:

Parasympathetic fibers contract the ciliary muscle, which relaxes suspensory ligaments, allowing the lens to increase its convexity (become more round). This increases the refractive index of the lens, thereby focusing a nearby object on the retina.

Convergence:

Both medial rectus muscles contract, adducting both eyes.

Pupillary constriction

Parasympathetic fibers contract the pupillary sphincter muscle result in miosis.

Lesions

✓ **Argyll Robertson pupil (pupillary light-near dissociation)** -No direct or consensual light reflex; accommodation-convergence intact Seen in neurosyphilis, diabetes

✓ **Adie pupil** - Dilated pupil that reacts sluggishly to light, but better to accommodation, often seen in women and often associated with loss of knee jerks. Ciliary ganglion lesion

✓ Loss of Accommodation reflex – Cerebral cortex

✓ Loss of Accommodation – Cerebral cortex

✓ Loss of Accommodation + 3rd CN Involvement – Midbrain (due to Edinger westphal nucleus)

✓ Temporal lobe (Meyer loop) involve Lower retina result in Contralateral superior quadrantanopia

✓ Parietal lobe involve upper retina result in contralateral inferior quadrantanopia

Visual Lesion

✓ **Middle Optic Chiasma Lesion – Bitemporal Heteronymous Hemianopia**

✓ **Optic Track Lesion – Homonymous Hemianopia**

✓ **Right Optic Track Lesion -- Left Homonymous Hemianopia**

✓ **Pituitary Tumor with Homonymous hemianopia – Optic Track lesion**

✓ **Pituitary Tumor with Heteronymous hemianopia – Optic Chiasma Lesion**

✓ Right Optic Track Lesion causes – Right Temporal and Left Nasal Fibers loss

✓ Right Optic Track Lesion Causes – Right Nasal and Left Temporal **Vision loss**

✓ **Right Optic Track is made up of – Right Temporal fibers(which See Nasal Vision) and Left Nasal** Fibers(which See Temporal Vision) so Fibers loss and vision loss are Separate things

✓ Pauem is Blind on testing but have no Insight of Vision loss – **Cortical Blindness**

✓ Cortical Blindness due to Blockage in -- PCA

Diencephalon

✓ Consist of Thalamus, Hypothalamus, Subthalamus and Epithalamus

Hypothalamus nuclei

✓ **Lateral nucleus** is feeding centre its damage result in stop feeding and make you Lean

✓ **Medial nucleus** is satiety centre and its damage result in over eating and make you Massive

✓ **Suprachiasmatic** – Regulates circadian rhythms, receives direct retinal input

✓ **Supraoptic and paraventricular** -Synthesizes ADH and oxytocin; regulates water balance Lesion leads to diabetes insipidus, characterized by polydipsia and polyuria.

✓ Mamillary body Input from hippocampus; damaged in Wernicke encephalopathy

✓ **Arcuate** -Has neurons that produce dopamine (prolactin-inhibiting factor)

✓ Dorsomedial Stimulation - savage behavior

✓ **Posterior Hypothalamus(Nucleus)**- activated Via Cold temp and activate Sympathetic which will increase Heating. Lesion result in Poikilothermia

✓ **Anterior Hypothalamus(Nucleus)** - activated via hot temp and activate parasympathetic and will increase Cooling. Lesion result in Hyperthermia

✓ Overall Temperature regulation – Preoptic Nucleus > Anterior Hypothalamus

CamScanner

Epithalamus
- ✓ Consists of pineal body and habenular nuclei. The pineal body secretes melatonin with a circadian rhythm.
- ✓ In young males, pineal lesions may cause precocious puberty.
- ✓ Pineal tumors may cause obstruction of CSF flow and increased intracranial pressure. Compression of the upper midbrain and pretectal area by a pineal tumor results in Parinaud syndrome

Thalamus
Nuclei
- ✓ Anterior nuclear group (part of the Papez circuit of limbic system)
- ✓ Medial nuclear group (part of limbic system). Most important is dorsomedial nucleus

Ventral nuclear group
Motor Nuclei
- ✓ Ventral anterior
- ✓ Ventral lateral

Sensory
- ✓ Ventral posterolateral
- ✓ Ventral posteromedial - Input from trigeminal and taste pathway
- ✓ Medial geniculate body(nucleus) - Auditory
- ✓ Lateral geniculate body(nucleus)- Vision

Midline and Intralaminar Nuclei - These nuclei appear to be important in mediating desynchronization of the EEG during behavioral arousal

Thalamic pain syndrome
- ✓ Affects the ventral nuclear group. Involvement of the dorsal column- medial lemniscal part of VPL increases the sensitivity to pain and presents as contralateral loss of vibratory sense and gait ataxia

Cerebral cortex

The middle cerebral artery (MCA) supplies:
- ✓ The lateral lower surface of the frontal, parietal, and upper temporal lobes
- ✓ The posterior limb and genu of the internal capsule
- ✓ Most of the basal ganglia
- ✓ Proximal Visual radiations(Mayer loop)

Occlusion
- ✓ Occlusion result in spastic paresis and Anasthesia of the contralateral lower face and upper limb
- ✓ Anaphasia(e.g., Broca, Wernicke, or conduction) usually due to block Left MCA
- ✓ Left Hemineglect due to Right MCA to Right parietal lobe block
- ✓ Contralateral superior quadrantanopsia due to damage of branches of MCA to Mayer loop(Temporal lobe)

The anterior cerebral artery (ACA) supplies
- ✓ Medial surface superior inch of frontal and parietal lobes and upper temporal lobe
- ✓ Anterior 4/5 of corpus callosum
- ✓ Anterior limb of internal capsule

Occlusion
- ✓ Occlusion results in spastic paresis and anasthesia of the contralateral lower limb
- ✓ Urinary incontinence(In B/L damage)
- ✓ Transcortical apraxia of the left limbs(Can understand Command but cannot execute command) Due to involved anterior portion of the corpus callosum
- ✓ Anterior communicating artery most common site of aneurysm
- ✓ Posterior communicating artery second common site of aneurysm

The posterior cerebral artery supplies
- ✓ The occipital and temporal cortex on the inferior and lateral surfaces of the hemisphere
- ✓ The occipital lobe and posterior 2/3 of the temporal lobe on the medial surface of the hemisphere
- ✓ Thalamus and subthalamic nucleus.

Occlusion
- ✓ Homonymous hemianopia of contralateral side with macular sparing
- ✓ Alexia without agraphia
- ✓

Brain Lobe Lesion

Frontal Lobe
It Result in
- ✓ Expressive (Broca) Non-fluent Aphasia
- ✓ Release of Sucking and Grasp Reflex
- ✓ Frontal Lobe Syndrome(Poor Social behave and lack of concentration)

Parietal Lobe
It result in
Gerstmann Syndrome which Include
- ✓ Right and left Confusion
- ✓ Finger Agnosia
- ✓ Dysgraphia and Dylexia
- ✓ Dyscalculia
- ✓ Alexia(Unable to understand written language) with Agraphia(Unable to write)

Other findings
- ✓ Dressing Apraxia
- ✓ Construction Apraxia
- ✓ Asterogonosis
- ✓ Contralateral Inferior Quadrantanopia(Upper Retina Involved)

Temporal Lobe
It result in
- ✓ Receptive(Wernicke) Fluent Aphasia
- ✓ Contralateral Superior Quadrantanopia(Lower Retina Involved-Meyer Loop)
- ✓ Olfactory and Gustatory Hallucination
- ✓ Ipsilateral Anosmia
- ✓ Klaver Bucy Syndrome
- ✓ Prosopagnosia

Occipital Lobe
It Result in
- ✓ Bilateral Lesion causes Cortical Blindness
- ✓ Unilateral Lesion causes Contralateral Quadrantanopia
- ✓ Macular sparing hemianopia
- ✓ Alexia without agraphia(Vs Alexia with agraphia in parietal lobe lesion)

Aphasia

Motor Aphasia
- ✓ Lesion of Broca Area(Dommant) 44 and 45
- ✓ Lesion of Inferior Frontal Lobe
- ✓ Expressive or Non Fluent Aphasia
- ✓ Cannot Speak or Write
- ✓ Comprehension Intact

Sensory Aphasia
- ✓ Lesion of Wernike area 22
- ✓ Lesion of Superior temporal Lobe
- ✓ Receptive or Fluent Aphasia
- ✓ Can Speak but make No sense

CamScanner

Anomic Aphasia
- ✓ Lesion of Angular Gyrus area 39
- ✓ Lesion of Non Dominant Broca Area
- ✓ Lesion of Arcuate Fasciculus
- ✓ Mild Fluent Aphasia
- ✓ Cannot express the words they want to use

Global Aphasia
- ✓ Lesion of Broca and wernike area

Vertebrobasilar (posterior circulation)
Vertebral artery branches
- ✓ ASA
- ✓ PICA

Basilar artery branches
- ✓ Pontine arteries
- ✓ AICA
- ✓ Superior cerebellar artery
- ✓ Labyrinthine artery (sometimes arises from AICA)

Internal carotid (anterior circulation)
- ✓ Opthalamic artery
- ✓ ACA
- ✓ MCA
- ✓ Anterior Communicating artery
- ✓ Posterior Communicating artery

Limbic System

Papez Circuit
- ✓ Axons of hippocampal pyramidal cells converge to form the fimbria and, finally, the fornix. The fornix projects mainly to the mammillary bodies in hypothalamus. The mammillary bodies project to the anterior nucleus of the thalamus (mammillothalamic tract). The anterior nuclei project to the cingulate gyrus, and the cingulate gyrus projects to the entorhinal cortex (via the cingulum). The entorhinal cortex projects to the hippocampus (via the perforant pathway).

Anterograde Amnesia
- ✓ Bilateral damage to the medial temporal lobes including the hippocampus results in a profound loss of the ability to acquire new information

Korsakoff syndrome
- ✓ It is seen mainly in alcoholics who have a thiamine deficiency and often follows an acute presentation of Wernicke encephalopathy(ocular palsies, confusion, and gait ataxia , Nystygmus and Opthalomoplegia)
- ✓ Korsakoff patients also present with Anterograde >retrograde amnesia. These patients confabulate, making up stories to replace past memories they can no longer retrieve.

Klüver-Bucy Syndrome
- ✓ Klüver-Bucy syndrome results from bilateral lesions of the amygdala and hippocampus.

These lesions result in:
- ✓ Placidity- There is marked decrease in aggressive behavior
- ✓ Psychic blindness—objects in the visual field are treated inappropriately
- ✓ Hypermetamorphosis - Visual stimuli (even old ones) are repeatedly approached as though they were completely new.
- ✓ Increased oral exploratory behavious(Put every thing in mouth)
- ✓ Hypersexuality and loss of sexual preference
- ✓ Anterograde amnesia

Alzheimer Disease
- ✓ Alzheimer disease accounts for 60% of all cases of dementia

- ✓ Lesions involve the neocortex, hippocampus, Temporal lobe and subcortical nuclei, including forebrain cholinergic nuclei (i.e., basal nucleus of Meynert
- ✓ Five to 10% of Alzheimer cases are hereditary, early onset, and trans- mitted as an autosomal dominant trait.

Random

- ✓ CNS-- **Oligodendrocytes**
- ✓ PNS -- **Schwann cells**
- ✓ Repairing cells -- **Astrocytes**
- ✓ Greymatter -- **Protoplasmic astrocytes (overall abundant)**
- ✓ White matter -- **Fibrous astrocytes (abundant astrocytes)**
- ✓ Adult spinal cord -- **Lower border of L1 or upper border of L2**
- ✓ Neonates spinal cord -- **Upper border of L3**
- ✓ **Endoneurium --- Individual** nerve fiber
- ✓ **perineurium ---- Bundle** of nerve fibers
- ✓ **Epineurium --- Entire Nerve**
- ✓ Fasciculus Gracilis -- **Lower limb Sensations**
- ✓ Fasciculus Cuneatus -- **Upper limb Sensations**
- ✓ Loss of light Reflex but intact accommodation reflex – **Pretectal Nucleus** (Midbrain at the level of superior colliculus)
- ✓ Loss of Accommodation reflex – **Cerebral cortex**
- ✓ Loss of Accommodation -- **Cerebral cortex**
- ✓ Loss of Accommodation + 3rd CN involvement -- **Midbrain** (Due to Edinger westphal nucleus)
- ✓ Corneal reflex lost -- **Pons**
- ✓ **Heating + Sympathetic effect – Post Hypothalmus**
- ✓ **Cooling + Parasympathetic – Ant Hypothalmus**
- ✓ Overall temperature regulation -- **Ant Hypothalmus (Preoptic Nucleus)**
- ✓ **FOLIA– Cerebellum Fold**
- ✓ HYPERACUSIS -- **Geniculate ganglion** (medial wall of middle Ear)
- ✓ **Broca aphasia** – Motor aphasia + Non-fluent + area 44 and 45 + inferior frontal gyrus
- ✓ **Wernicke aphasia** -- Sensory aphasia + fluent + area 22+ superior temporal gyrus
- ✓ **Global aphasia** -- Both Wernicke and broca aphasia + arcuate fasciculus
- ✓ **Anomic aphasia** -- Mild fluent aphasia + failure of word retrieval + angular gyrus
- ✓ **Lesion in DCML (Post White Column)** -- Sensory Ataxia> Asterognosia
- ✓ Loss of Proprioception lesion in – **Posterior Column (DCML)**
- ✓ Loss of Proprioception mechanism is – **Lateral Inhibition (Guyton)**
- ✓ Reduced motivation and depression -- **Frontal Lobe**
- ✓ Characteristic of cerebellum lesion -- **Dysdiadochokinesia > Dysarthria**
- ✓ **Resting Tremor-- Substansia Nigra**
- ✓ **Intentional tremors – Cerebellum**
- ✓ **IJV after Coming out of Jugular foramen relation –ICA**
- ✓ **IJV With in jugular foramen relation – Accessory Nerve**
- ✓ Neostriatum -- **Caudate + Putamen**
- ✓ Corpus Striatum – **Caudate + Lentiform**
- ✓ **Lentiform – Putamen + Globus Pallidus**
- ✓ Olfactory Cortex location – **Posterior inferior Temporal Lobe + Uncus**
- ✓ Olfactory Area location – **Anterior Perforating Substance**
- ✓ **Fastest fibers -- A alpha**
- ✓ **Fast pain fibers -- A delta**
- ✓ **Slow pain fibers -- C fibers**
- ✓ **Preganglionic fibers -- Beta fibers (True Autonomic)**
- ✓ **Postganglionic fibers -- C fibers (Autonomic)**

CamScanner

- ✓ **Pain** From fingertip by – **A delta**
- ✓ **Proprioception** from fingertip – **A Beta fiber**
- ✓ Type A>B>C affected by -- **Pressure**
- ✓ Type B>A>C affected by – **Hypoxia**
- ✓ Type C >B>A affected by – **Anesthesia**
- ✓ Itching -- Slow C fibers
- ✓ **Itching Track** – **Anterior Spinothalmic Track**
- ✓ Sleep Centre – **Preoptic nucleus**
- ✓ Circadian Rhythm – **Suprachiasmatic nucleus**
- ✓ Chorea (Jerky+ quick movements) -- **caudate nucleus**
- ✓ Athetosis (slow + writhing) – **Globus pallidus**
- ✓ Hemi-ballismus – **Sub-thalamic nuleus lesion**
- ✓ Fusiform gyrus (Temporal Lobe) – **Face Recognization** (Unable to recognize face called propopgnosia)
- ✓ Amygdala &Cingulate gyrus (Limbic System) -- **Emotions**
- ✓ Sexual centre – **Nucleus Acumbens**
- ✓ Hippocampus – Short term memory + recollection in long term memory (long term memory formed by new Protein synthesis)
- ✓ Structure close to crus cerebri – **Substantia nigra**
- ✓ Medial leminiscus formed by decussation of -- **Internal arcuate fibers**
- ✓ In UMN lesion fibers decussate at the level of -- **Pyramid**
- ✓ Cerebellum connected to Midbrain by – **Superior cerebellar peduncle**
- ✓ Bleeding from mastoid antum -- **Sigmoid sinus**
- ✓ Climbing Purkinje fibers originate from -- **Inferior olivary nucleus**
- ✓ **Spinal nerves** – Mixed nerves (both sensory and motor fibers) + formed in intervertebral Foramen - exit intervertebral Foramina
- ✓ Spinal ganglia – **Pseudounipolar neurons**
- ✓ Skeletal muscle – **Multipolar**
- ✓ Olfactory – **Bipolar**
- ✓ **Dorsal column** – fine touch + pressure + vibrations + proprioception
- ✓ **Fine movements of hand** – **Controlled** by cerebellum and **carried** by Corticospinal tracts
- ✓ Centre for direct autonomic reflexes -- **Hypothalamus**
- ✓ MCA (upper limbs + Aphsia) Supplies – Insula and Opercula
- ✓ ACA (lower limbs + aphasia) Supplies – Secondary Somasthetic Area
- ✓ TABES DORSALIS – **Atonic bladder**
- ✓ Proximal muscle **Flexion** – **Rubrospinal tracts**
- ✓ Proximal muscle **Extension** – **Vestibulospinal tracts**
- ✓ Inhibitory output in CNS -- **Purkinje cells**
- ✓ Ptosis + Miosis -- **Horner syndrome**
- ✓ Ptosis+Mydriasis – **3rd Nerve palsy**
- ✓ Ptosisis + normal pupil – **Myesthenia gravis**
- ✓ Site of fusion of binocular vision – **Visual cortex**
- ✓ Day vision+ color Vision – **Cones**
- ✓ Night vision + increased sensitivity to low light -- **Rods**
- ✓ Anterior layer of retina contains – **Retinal pigment epithelium**

Lamina

- ✓ **Lamina 1-6** – Dorsal (Posterior) Horn
- ✓ **Lamina 8-9** – Ventral (Anterior) Horn
- ✓ **Lamina 7 &10** – Intermediate Horn
- ✓ **Lamina 1** – High Threshold mechanoreceptor, Noxious stimulus & A delta pain

- ✓ Lamina 2 – C fiber Pain & Substantia gelatinosa
- ✓ Lamina 3–4 – Low Threshold mechanoreceptor
- ✓ Lamina 6 – Deepest Layer, Joint skin Signal
- ✓ Lamina 7 – Largest Area, Dorsal Nucleus of Clarke
- ✓ Lamina 10 – Central Canal

Medulla

Upper Medulla:
- Vestibular cochlear
- Inferior olivary
- Spinal trigeminal

Middle Medulla:
- Nucleus ambiguas
- Hypoglosal Nucleus
- Dorsal motor Nucleus Vagus
- Spinal Trigeminal

Lower Medulla:
- Hypoglosal Nucleus
- Dorsal Motor Nucleus Vagus
- Spinal Trigeminal

CamScanner

NEUROANATOMY

1- Ia hydrocephalas which structure is most commonly blocked?
A- Aqueduct of sylvius
B- Lateral ventricles
C- Foramen of Monroe
D- Foramen of megendi
E- 4th ventricle obstruction
Ans: A

2- CSF absorbed by which of the following?
A- Arachnoid Villi
B- Choroid plexus
C- Ventricles
D- Spinal arteries
E- Sinusoid
Ans: A

3- Corticospinal tract myelination completed at?
A- 28 Weeks
B- 36 Weeks
C- 40 Weeks
D- After Birth
Ans: D
Explanation:
- Start during 36 weeks and completed after birth at 2year.

4- A patient unable to recognize faces (prosopagnosia) area injured is:
A- Parietal
B- Parieto occipito temporal lobe
C- Somesthetic area
D- Frontal lobe
E- Occipital lobe
Ans: B
Explanation:
- For propagnosia inferior temporal lobe is mostly related but if option of temporal lobe is not given then
- parieto occipito temporal lobe option is also correct
- Prosopagnosia lesion in – Inferior temporal lobe
- Asterognosis lesion in – Parietal lobe.

5- After gunshot injury to spinal cord, Lesion at C7, following will happen:
A- UMN
B- LMN
C- Contralcral Loss of pain and temperature below level of lesion
D- Ipsilateral loss of pain and temperature at site
E- Ipsilateral hypereflexia
Ans: C

6- Unmyelinated nociceptive Primary afferent fibers synapse directly at which neuron of spinal cord?
A- Spinothalamic neuron of lamina 1
B- Flexor motor neuron
C- Ventral spinocerebellar track neuron
D- Preganglionic sympathetic neuron
E- Dorsal spinocerebellar track neuron
Ans: A

7- 54 year old male went to doctor with complain of weakness of left half of body. O/E He has tremors of left hand at the end of movement, Muscular hypotonia of left limb & tendency to fall on left side. All Cranial nerves intact. Neurological lesions located in:
A- Left Caudate and Putamen
B- Precentral gyrus
C- Right Cerebellar
D- Red Nucleus
E- Left Cerebellar
Ans: E

8- A patient had RTA, he does not know recent events but he remembers his school events. Where is the tesion?
A- Arcuate
B- Amygdala
C- Hippocampus
D- Frontal lobe
E- Temporal lobe
Ans: C

9- Post synaptic ganglionic fibers are present in:
A- Thoracic spinal nerves
B- Lumbar spinal nerves
C- Cervical spinal nerves
D- All spinal nerves
E- Sacral spinal nerves
Ans: D
Explanation:
- Preganglionic present in –Thoracolumbar
- Postganglionic present in - All spinal nerves

10- Skilled and fine movement of distal limbs is controlled by:
A- Midbrain
B- Cerebellum
C- Basal ganglia
D- Pons
E- Rubrospinal tract
Ans: B

11- Patient has excruciating right leg pain. Anterolateral right leg chordotomy was performed. Which tract was involved?
A- Right lateral spinothalmic tract
B- Left anterior spinothalmic tract
C- Dorsal column
D- Left lateral spinothalmic tract
E- Left Rubrospinal tract
Ans: D

12- Patient after RTA having Sacral region of Spinal cord damaged. This will lead to:
A- Bladder injury
B- Spastic Bladder
C- Detrous muscle injury
D- Autonomous bladder
E- Bladder Hypertrophy
Ans: D
Explanation:
Injury above sacral segment (sympathetic damage) cause:
- Spasuc Bladder
- Automatic Bladder
- Urge Incontmence

Injury at sacral segment (parasympathetic damage) cause:
- Atonic Bladder
- Autonomous Bladder
- Overflow Incontinence

Note. Neurogenic is common term for both spastic and Atonic Bladder.

13- The sensation of rectal and bladder fullness reach higher centers via:
A- Spinocereballer tract
B- Rubrospinal tract
C- Corticospinal tract
D- Dorsal column medial lemniscus pathway
E- Lateral Ttact
Ans: D (Grey's + BD)
Explanation
- Pain Sensauon of bladder pass through - lateral spinothalmic track
- Awareness of Bladder distentsion mediated by – DCML (Posterior Column)
- Pain and filling sensauon of bladder by – Sympathetic
- Distension of rectum carried by – Parasympathetic
- Pain of rectum carried by – Sympathetic and parasympathetic

14- Proxintal muscles' tone depends upon which tract?
A- Vestibulospinal tract
B- Reticulospinal tract
C- Pyramidal tract
D- Rubrospinal tract
E- Tecto spinal tract
Ans: D
Explanation:
- Flexor muscle (Gravity) – Rubrospinal and medullotecticular
- Extensor help in standing (anti-gravity) – Vestubulospinal and Ponto reticular

15- Medial leminuscus is formed by:
A- Nucleus gracillus
B- Dorsal root ganglions
C- Nucleus gracillus and cuneatus
D- Nucleus cuneatus
E- Pontine nuclei
Ans: C

16- After severe trauma to spinal cord, Patient having loss of all sensations hilaterally due to:
A- Brown sequard syndrome
B- Syringomelia
C- Complete cord transection
D- Dorsal root cut
E- DCML lesion
Ans: C

17- A patient presented with paralysis of right limb and right lower face along with homonymous hemianopia. Lesion present in which of following?
A- Basilar pons
B- Forebrain
C- Midbrain
D- Medulla
E- Thalamus
Ans: B

18- Tabes dorsalis causes which of the following?
A- Atonic bladder
B- Neurogenic bladder
C- Loss of vibration
D- Autonomic bladder
E- Tumbling gait
Ans: A (Kaplan)

19- Patient presented with inability to write, read and understaod most likely lesion is in:
A- Broca Area
B- Frontal lobe
C- Arcuate fasciculus
D- Angular gyrus
E- Wernikearea
Ans: E (Neurosnell and Textbook)

20- A female is carrier of which of the following and transmits to male:
A- ITP
B- Marfan Syndrome
C- Down Syndrome
D- Hemophilia
Ans: D

CamScanner

21- There was hemisection of vertebra what will be lost contralaterally?
A- Vibration
B- Pressure
C- Kinesthetic
D- Warmth
E- Light touch
Ans: D

22- Nucleus pulposus will be seen herniating at which segmeat?
A- S2-S3
B- L2-L3
C- L3-L4
D- T10-T12
Ans: D

23- Patient after post thyroidectomy developed hoarseness of voice. Examination reveals Sluggish movement of vocal cords.Nerve damage related to which area?
A- Hypoglossal nucleus
B- Accessory nucleus
C- Middle Medulla
D- Lower Pons
Ans: C

Explanation:
- It contain CN 9,10 and 11 nuclei. Dorsal vagus nerve supply larynx

24- A female with sign and symptoms of hyper prolactinoma was diagnosed with pituitary adenoma. The growth of this tumor anteriorly will compress which structure?
A- Cavernous sinus
B- Opticnerve
C- Optic chiasma
D- Optic tract
E- Trochlear nerve
Ans: B

Explanation:
- Cavernous Sinus – Laterally
- Sphenoid Air Sinus – Inferiorly
- Optic Chiasm – Superiorly
- Optic nerve - Anteriorly

25- Hemisection of spinal cord at cervical level causes?
A- Loss of pain and sensation on same side
B- Loss of pain and temperature on opposite side below lesion
C- Loss of pain on same side and sensation on opposite
D- Loss of pain above lesion
E- Loss of Pain at level of lesion
Ans: B

26- A Patient came to ER with injury in anterio inferior part of temporal region and period of unconsciousness for 3mints and vision problem.Most likely vessel damaged is?
A- ACA
B- Anterior division of MMA
C- Posterior division of MMA
D- MCA
E- Bridging veins remove 62
Ans: B

27- Cephalohematoma occurs commonly at which of following location?
A- Loose areolar tissue
B- Connective tissue
C- Under skin
D- Between Skull and Periosteum
Ans: D

Explanation:
- Cephalohematoma bleed occur under periostium
- Cephalohematom bleed most common site is over parietal bones

28- After gunshot injury to lower back patient has loss of contralerat pain sensation but intact temperature sensation what is the likely diagnosis?
A- Section of dorsal root S1
B- Section of ventral root S1
C- Brown sequard syndrome
D- Early stage of tabes dorsalis
E- Syringomyclia
Ans: A

29- Post rotatory nystagmus is caused by:
A- Endolymph in semicircular canals
B- Aqous flow on cilliary body
C- Brain trauma
D- Increased ICP
E- Blockage of Eustachian tube
Ans: A

30- A patient with B/L vision loss and raised prolactin level and homonymous hemianopia due to lesion of:
A- Hypothalamus
B- Cortex
C- Anterior pituitary
D- Pons
Ans: C

31- Cat is denervated at mid collicular level what will happen?
A- Decerebrate posture
B- Decorticate posture
C- Increased flexor tone of muscle spindle
D- Increase reflexes
Ans: A (Ganong)

Explanation:
- At Mid collicular = Decerebrate rigidity >> Inc. Extensors tone m all four limbs.
- Below Superior colliculus = Decorticate rigidity >> Inc. flexor tone in upper limbs

32- Climbing fibers to purkinji arise from:
A- Nucleus ambiguou
B- Dorsal nucleus
C- Inferior olivatory nucleus
D- Superior olivatory nucleus
Ans: C

33- Male had RTA with injury to occipital region now has homonymous hemianopia.Which structure is damaged?
A- Optic chiasm
B- Optic tract
C- Visual area
D- Lateral geniculate body
E- Optic radiation
Ans: E

34- Patient has lost fine touch, vibration and proprioception.Where is the lesion?
A- DCML
B- Nucleus gracilis
C- Anterateral coulmn
D- Anterior spinothalamic
E- Nucleus cuneatus
Ans: A (Kaplan + Neurosnell)

Explanation
- Fine touch pressure vibration and proprioception carried by – Dorsal Column (Posterior white column).
- Gracilis – For lower limb
- Cuneatus – For upper limb
- Anterior spinothalmic – Cmd touch and Pressure
- Lateral spinothalmic – Pain and Temperature.

35- Ligament pierced at last during epidural is :
A- Posterior spinal ligament
B- Anterior spinal ligament
C- Supraspmous ligament
D- Interspinal ligament
E- Ligamentum flavum
Ans: E

36- Loss of two point discrimination, fine touch and vibration in the left lower limb. The region of brain affected would be:
A-
B- Fasciculus gracilis
C- Fasciculus Cuneatus
D- Globus Pallidus
E- Substantia Nigra
Ans: Thalamus
A

37- On histology,Flask shaped cells, multiple dendritic synapses in:
A- Substantia nigra
B- Cerebral cortex
C- Geniculate ganglion
D- Cerebellar cortex
Ans: D

38- What will happen due to UMNL?
A- Flaccidity
B- Babinski sign dimimshed
C- Planters upward
D- Exaggerated reflexes
E- Atrophy
Ans: D

39- Patient head is turned to see nearby object, which part of brain is involved in this function?
A- Superior colliculus
B- Inferior colliculus
C- Primary visual cortex
D- Premotor cortex
E- Superior olivary nucleus
Ans: A

Explanation:
- Superior colliculus – Vision
- Inferior colliculus – Auditory

40- Structure connecting hippocampus and hypothalamus is:
A- Fornix
B- Amygdala
C- Thalamus
D- Infundibulum
Ans: A

41- 2nd order neurons of anterior spinothalamic tract lie in?
A- Hypothalamus
B- Accessory nucleus
C- Substantia gelatinosa
D- Thalamus
E- Cortex
Ans: C

Explanation:
- 2nd order lies in Substansia gelatinos and end in thalamus

42- A patient presented with paralysis of Right limb & right lower face along with homonymous Hemianopia.Lesion is present in which of the following?
A- Basilar pons
B- Internal capsule
C- Midbrain
D- Medulla
E- Thalamus
Ans: B

CamScanner

43- Critical tactile Sensation carried by:
A- Ventral horn
B- Dorsal horn
C- Posterior white colmn
D- Anterior white column
E- Lateral column
Ans: C

Explanation:
- Critical touch – DCML (posterior column)
- Crude touch – Anterior column

44- Patient presented with weakness of sternocleidomastoid and trapezius, unable to close his eye and shrug his shoulder with weakened palate elevation and absent gag reflex and hoarseness of voice, lesion is located in:
A- Cerebellopontine angle
B- Medulla
C- Primary motor area
D- Jugular foramen
Ans: D

Explanation:
- Signs and symptoms of 9-11 nerve lesion present which passes through jugular foramen.

45- Patient with Right sided hemiplegia, left sided pain and temp lost below t8 while right side proprioception and touch sensations l[illegible] below t8. What is the cause?
A- Complete transection at T8
B- Hemi section at T8
C- Hemi section below T11
D- Cauda Equina
E- Syringyelia
Ans: B

Explanation:
Hemisection of spinal cord findings
- Ipsilateral loss of all sensation at level of lesion
- Contralateral LMN signs (eg, flaccid [illegible] of lesion
- Ipsilateral UMN signs below level of lesion (due to corticospinal tract damage)
- Ipsilateral loss of proprioception, vibration, light (2-point discrimination) touch, and tactile sense below level of lesion (due to dorsal column damage)
- Contralateral loss of pain, temperature, and crude (non-discriminative) touch below level of lesion (due to spinothalamic tract damage)

46- Pain, temperature & crude touch from face is carried by which of the following tract?
A- DCML
B- Anterolateral Spinothalamic tract
C- Trigeminothalamic tract
D- Lateral tract
E- Rubrospinal tract
Ans: C

47- Corpus striatum contains:
A- Caudate+putamen
B- Caudate+lentiform
C- Caudate+globus pallidus externa
D- Caudate+globus pallidus intern
E- Globus pallidus externa+lentiform
Ans: B

Explanation:
- Neostriatum – Caudate +Putamen
- Corpus striatum – Caudate +Lantiform
- Paleostriatum – Globus pallidus
- Lantiform nucleus – Globus pallidus + Putamen

48- Higher intellectual function of brain by which part:
A- Broca Area
B- Wernicke's area
C- Premotor Area
D- Parietal area
Ans: B (Guyton)

49- Cingulate gyrus is supplied by which of the following?
A- Middle cerebr artery
B- Anterior cerebral artery
C- Posterior coroidal artery
D- Posterior cerebral artery
E- Middle menungeal artery
Ans: B

50- Corpus callosum contains which fibers?
A- Association fibers
B- Projection fibers
C- Commissural fibers
D- Arcuate fibers
E- Circular fibers
Ans: C

Explanation:
- Corpus callosum – Commissural fibers
- Internal capsule – Projection fibers

51- What is the primary function of basal ganglia?
A- Memory
B- Neuroendocrine control
C- Planning voluntary control
D- Sleep
Ans: C

52- A patient with enlarge hands and feet with associated joint. On MRI was found compressing optic chiasma What can occur in this patient?
A- Hitemporal hemianopia
B- Bludness
C- Binasal hemianopia
D- Upper quadrantanopia
Ans: A

Explanation:
- Middle optic chiasma lesion – Bitemporal heteronymous hemianopia.
- Optic track lesion – Homonymous hemianopia
- Right optic track lesion – Left homonymous hemianopia
- Pituitary tumor with homonymous hemianopia – Optic track lesion
- Pituitary tumor with heteronymous hemianopia – Optic chiasma lesion
- Right optic track lesion causes – Right temporal and left nasal fibers loss
- Right optic track lesion causes –Right nasal and left temporal vision loss
- Right optic track is made up of – Right temporal fibers (which see nasal vision) and left nasal fibers (which see temporal vision) so fibers loss and vision loss are separate things.
- Patient is blind on testing but have no insight of vision loss – Cortical blindness
- Cortical blindness due to blockage in – PCA

53- Lateral to medial arrangement of cerebellar nuclei is:
A- Fastigial, Dentate and Interposed
B- Interposed, Fastigial and Dentate
C- Dentate, Globose, Emboliform and Fastigial
D- Fastigial, Interposed and Dentate
Ans: C

Explanation:
- **Lateral to medial** – Dentate, interposed (globose and emboliform), fastigial

54- Lower limb proprioception carried by gracilis in spinal it is located:
A- Lateral
B- Medial
C- Superior
D- Inferior
E- Anterolateral
Ans: B

Explanation:
- Lower limb - Medial
- Upper limb – Lateral
- Lower limb related to upper limb at spinal cord – Medial to lateral
- Lower limb – Cuneatus (Medial)
- Upper limb – Gracilis (Lateral)

55- Connection of amygdala and Hippocampus is:
A- Mammilothalamic body
B- Mammillotrigeminal tract
C- Hypophyseal tract
D- Hypothalamic tract
Ans: A

56- During sympathetomy, Which Lumbar gangolion is spared?
A- L5
B- L3
C- L2
D- L1
E- L4
Ans: D

57- Patient in depression, lack of motivation due to lesion in:
A- Frontal lobe
B- Occipital lobe
C- Temporal lobe
D- Parietal lobe
E- Angular gyrus
Ans: A

58- A patient blindfoldedly asks to identify the structure in hand. Which area assessment is being done?
A- Primary somesthetic area
B- Secondary somesthetic area
C- Somesthetic association area
D- DCL Association area
E- Primary motor area
Ans: C (>A)

59- A patient presented with right side hemiplegia without sensory loss. Lesion is at which site ?
A- Left internal capsule
B- Pons
C- Medulla
D- Midbrain
E- Brainstem
Ans: A

Explanation:
- Lesion of one side of internal capsule cause pure motor stroke of other side.

60- Posterior external arcuate fibers Related to which of following
A- Anterior spinocerebellar
B- Posterior spinocerebellar
C- Spinothalamic tract
D- Cuneocerebellar tract
E- Posterior Dorsal Tract
Ans: D

Explanation:
- External posterior arcuate – Cunocerebellar
- External Anterior arcuate – Pontocerebellar
- Internal arcuate – Dorsal medial leminuscus

CamScanner

61- A patient has damage to a nerve coming out from dorsal surface of left side of brain stem. What will be the defect in thispatient?
A- Left sided loss of intorsion
B- Ptosis of the left eye
C- Loss of corneal reflex on right
D- Loss of corneal reflex on left
Ans: A (Trochlear nerve injury)

62- A 65 year male develops right sided hemiplegia aad slight devlation of angle of mouth to left while talking he is ahle to close his eyes on command.What other fiadiag can be present?
A- Lead pipe rigidity
B- Clasp knife Spasticity
C- Muscle fasciculation
D- Atrophy
E- Low Tone
Ans: B (UMN type lesion)

63- Which is associated with parietal lobe lesion?
A- Vision
B- Asterognosis
C- Hearing
D- Taste
E- Prosopanosia
Ans: B

Explanation:
Asterognosis result from lesion in:
- Parietal Lobe
- Somesthetic association area > primary somatosensory

Propagnosia result from lesion in
- Inferior Temporal Lobe

64- Fluent, non-sense speech is due to damage of which area
A- Parietal lobe
B- Broca area
C- Angular gyrus
D- Wernike area
E- Frontal lobe
Ans: D

Explanation:
- Broca aphasia – Motor aphasia + Non-fluent + area 44 and 45 + inferior frontal gyrus
- Wernicke aphasia – Sensory aphasia + fluent Non sense speech + area 22+ superior temporalbgyrus
- Global aphasia – Both Wernicke and broca aphasia + arcuate fasciculus
- Anomic aphasia – Mild fluent aphasia + failure of word retrieval + angular gyrus

65- Fine skilled discrete movement of hands by which of these?
A- Rubrospinal tract
B- Cerebral cortex
C- Corticospinal tract
D- Midbrain
E- Pons
Ans: C

66- A patient having paralysis of right side of body with deviation of angle of mouth to the left and drooling of saliva but the patient can close both eyes.Injury is at the level of:
A- Supranuclear
B- Pontine nucleus
C- Petrous part of temporal bone
D- Stylomastoid foramen
Ans: A

Explanation:
Uncrossed Hemiplegia
- Same Sided Hemiplegia and Same sided Face involve (Angle Deviate to opposite) lesion in – Internal Capsule (Forbrain)or Cortex or Supranuclear

Crossed Hemiplegia
- One sided Hemiplegia and Other Side Face involve – Brainstem (Pons/Midbrain)

67- Lesion of geniculocalcarine tract causes which defect?
A- Blindness
B- Heteronymous Hemianopia
C- Homonymous Hemianopia
D- Homonymous Hemianopia with Macular Sparing
Ans: D

68- Lesion at right optic tract results in?
A- Blindness
B- Left homonymous hemianopia
C- Right homonymous hemianopia
D- Heteronymous hemianopia
Ans: B

69- Point by point discrete movement of painter carried out by which tract?
A- DCML
B- Corticospinal Tract
C- Olivospinal
D- Rubrospinal
E- Spinothalamic Tract
Ans: B

70- Sign of wernicke's area damage:
A- Fast speech that makes no sense
B- Slow speech
C- Not recognizing faces
D- Uncomprehending words
Ans: A

Explanation:
- Broca aphasia – Motor aphasia + Non-fluent + area 44 and 45 + inferior frontal gyrus
- Wernicke aphasia – Sensory aphasia + fluent Non sense speech + area 22+ superior temporal gyrus
- Global aphasia – Both Wernicke and broca aphasia + arcuate fasciculus
- Anomic aphasia – Mild fluent aphasia + failure of word retrieval + angular gyrus

71- Right frontal lobe optic tract compression leads to:
A- Left homonymous hemianopia
B- Right homonymous hemianopia
C- Heteronymous hemianopia
D- Complete blindness on left
Ans: A

72- After RTA patient suffered change of behavior and decreased motivation due to lesion in which of these?
A- Mid brain
B- Frontal Lobe
C- Parietal Lobe
D- Occipital Lobe
E- Pons
Ans: B

73- Patient after RTA,Sacral region of Spinal cord damage has which effect?
A- Bladder injury
B- Spastic Bladder
C- Detrous muscle injury
D- Automatic Bladder
E- Neurogenic Bladder
Ans: E

Explanation
Injury above Sacral Segment (Sympathetic damage) Cause:
- Spastic Bladder
- Automatic Bladder
- Urge Incontinence

Injury at Sacral Segment (Parasympathetic damage) Cause:
- Atonic Bladder
- Autonomous Bladder
- Overflow Incontinence

Note: Neurogenic is common term for both spastic and Atonic Bladder

74- A patient having tremors while doing some work.He is having lesion in:
A- Midbrain
B- Cerebellum
C- Pons
D- Midbrain
E- Cortex
Ans: B

Explanation:
- Intension tremors – Lesion of cerebellum
- Resting tremos – Lesion of substansia nigra (midbrain) causes parkinson disease.

75- A patient after RTA having Left Precentral gyrus lesion.Effect will be:
A- Exaggerated knee jerk on left
B- Right hemiplegia
C- Loss of Reflexes
D- Normal plantaris on right
E- Right side sensory los
Ans: B

76- Injury to pyramids.Function lost will be:
A- Propioceptioo
B- Motor loss
C- Sensory Loss
D- Temperature loss
E- Taste Loss
Ans: B

77- A Patient having Atrophy of the calf muscles and loss of reflexes with weakness of legs, the lesion in:
A- UMN lesion
B- LMN lesion
C- Sensory lesion
D- Mixed lesion
E- Internal Capsule
Ans: B

78- 68year old man presented with right sided leg and and arm weakness, and angle of mouth deviated towards left. Lesion in which side of the brain?
A- Pons
B- Midbrain
C- Internal capsule
D- Medulla
E- Cerebellum
Ans: C

Explanation:
- Uncrossed hemiplegia (Internal capsule) - Same side Limb weakness and same sided face involve (Mouth angle deviate to opposite site). In this case right sided limb weakness and Right sided face involve (Angle deviate to Left) so internal capsule.
- Crossed Hemiplegia (Pons/Midbrain) - one side limb weakness and other sided face involve

79- Which of the following lines the ventricles of brain and central canal of spinal cord?
A- Oligodendrocyte
B- Astrocyte
C- Ependymal Cells
D- Fibrous Astrocyte
E- Schwan Cells
Ans: C

CamScanner

80- Acute Memory loss due to damage to whichares?
A- Broca Ate
B- Wernike area
C- Limbic association Cortex
D- Prefrontal cortex
E- Cortical association area
Ans: C

81- A patient after Rta having weakness, incoordinatioa,pendular knee jerk and hypotenia.Site of lesion?
A- Internal Capsule
B- Pons
C- Midbrain
D- Cerebellum
E- Cortex
Ans: D

82- Acoustic area location is:
A- Inferior temporal gyrus
B- Superior temporal
C- Middle temporal
D- Inferior frontal
Ans: B

83- A Patient can't perform rapid movement after Lesion of cerebellum.This is called:
A- Dysdiadochokinesia
B- Hypotonia
C- Ataxia
D- Dysarthria
E- Dysmetria
Ans: A

84- Patient has ataxia when asked to walk, with close eyes, sways back and forth, where is the lesion present:
A- Dorsal column
B- Cerebellum
C- Basal ganglia
D- Cerebrum
E- Cortex
Ans: A
Explanation:
- Fall on close eye – Dorsal column
- Fall on open eye – Cerebellum

85- Lesion in parietal lobe causes which of the following?
A- Illusion
B- Astereognosia
C- Social withdrawal
D- Delirium
E- Delusion
Ans: B
Explanation:
- Prospagnosia lesion in – Temporal Lobe
- Asterognosis lesion in – Parietal Lobe

86- Broadmann area 3, 2, 1:
A- Located only on medial side of cortex
B- Receive all special sensations
C- Receive all somatosensory sensations
D- Receive all motor sensations
Ans: C

87- A patient has left sided lesion in brain, when examined he was falling on the left side where is the lesion?
A- Cerebrum
B- Cerebellum
C- Pons
D- Medulla
E- Midbrain
Ans: B

88- Structure hurried in lateral sulcus of cerebrum is
A- Sebiculum
B- Insula
C- Dorsal root
D- Splenium
E- Pars triangularis
Ans: B

89- A patient presented with neck rigidity Fever and Alter state For lumbar puncture which of the following is ideal site?
A- Above the spinous process of L4
B- Below the spinous process of L5
C- Conus medullaris
D- Below Spinous process of L2
Ans: A
Explanation:
Prefer
- Below – L4
- Above– L5
- Between – L4-5

90- Why Association of nausea and Vomiting with vertigo?
A- Close interaction of vestibular and vagal nuclei
B- Vestibular and glossopharyngeal nuclei
C- Glossopharyngeal and vagus nuclei
D- Accessory nerve and Vagus nerve
Ans: A

91- Only afferent nerve that carries information to the brain?
A- Optic
B- Hypoglossal
C- Glossopharyngeal
D- Occulomotor
E- Trochlear
Ans: A

92- Characteristic of cerebellar neoplasm?
A- Ataxia
B- Hyperlonia
C- Nystyglmus
D- Diplopia
E- Static Tremors
Ans: A

93- Babinski sign is due to damage in which of the following area?
A- Basal ganglia
B- Brain stem
C- Pyramids
D- Spinal cord
E- Cerebellum
Ans: C

94- In lesion distal to optic chiasma on left side, the visual defects will?
A- Bitemporal hemianopia
B- Binasal hemianopia
C- Right homonyous hemianopia
D- Left hommous hemianopia
E- Bilateral complete vision loss
Ans: C

95- Which type of loss occurs due to lesion at post central gyrus?
A- Motor area
B- Sensory area
C- Taste
D- Visual
E- Hearing
Ans: B
Explanation
- Precentral – Motor
- Postcentral – Sensory

96- Person after RTA is unable to speak and has non fluent Speech but can understand commands.Lesion is in which of the following
A- Brocas Area
B- Internal Capsule
C- Primary motor area in posteentral gyrus
D- Wernickes Area
E- Medulla
Ans: A(FA + Kaplan)
Explanation:
- Broca aphasia – Motor aphasia + Non-fluent and unable to speak + area 44 and 45 + inferior frontal gyrus
- Wernicke aphasia – Sensory aphasia + fluent and Senseless speech + area 22 + superior temporal gyrus
- Global aphasia – Both Wernicke and broca aphasia + arcuate fasciculus
- Anomic aphasia – Mild fluent aphasia + failure of word retrieval + angular gyrus

97- Subarachnoid space:
A- Between arachnoid and pia mater
B- Between dura and pia mater
C- Between pia mater and Skull
D- Above clavaria
Ans: A

98- Feeding centre located in which of the following?
A- Trigeminal nerve
B- Anterior hypothalamus
C- Medial nucleus of Hypothalamus
D- Lateral nucleus of Hypothalamus
E- Upper medulla
Ans: D
Explanation:
- Lateral nucleus is feeding centre its damage result in stop feeding and make you Lean
- Medial nucleus is satiety centre and its damage result in over eating and make you Massive.

99- Which Structure lies closest to crus cerebri?
A- Caudate
B- Globus Pallidus
C- Substantia Nigra
D- Pons
E- Colliculus
Ans: C

100- Nucleus tractus solitarius contains which of the following?
A- First order neuron of taste pathway
B- Body of 2nd order neuron of taste pathway
C- 2nd order neuron of auditory pathway
D- 3rd order neuron of taste pathway
E- 2nd order neuron of visual pathway
Ans: B

101- Perception of disgust by which area?
A- Frontal Lobe
B- Left insular cortex
C- Thalamus
D- Right insular cortex
E- Cerebral cortex
Ans: B

102- Which sensation is carried through the dorsomedial nucleus of thalamus?
A- Fear and anxiety
B- Modulation of Olfactory nerve
C- Pungent smell
D- Inhibitory signals to smell
E- Food smell
Ans: A

CamScanner

103- Patient with right sided hemiplegia and facial palsy of left half of the face.Lesion in which of the following?
A- Cortex
B- Pons
C- Internal capsule
D- Medulla
E- Cerebellum
Ans: B
Explanation:
- Uncrossed Hemiplegia (Internal Capsule) – Same side Limb weakness and same sided face involve (Mouth angle deviate to opposite site). In this case right sided limb weakness and Right sided face involve (Angle deviate to Left) so internal capsule.
- Crossed Hemiplegia (Pons,Midbrain) – Dae side limb weakness and other sided face involve.

104- Asterognosis is cause by the lesion of which area of brain?
A- Occipital
B- Anterior part of frontal
C- Right internal capsule
D- Left internal capsule
E- Parietal lobe
Ans: E

105- 59 yrs old male hypertensive presented in the emergency in comma with left side hemiplegia and bilateral pin point pupils leisons seen in:
A- Frontal lobe
B- Internal capsule
C- Pons
D- Midbrain
Ans: C

106- A patient sustained injury to posterior head and occipital lobe resulting in vision loss.Artery involved is:
A- Posterior Cerebral Artery
B- MCA
C- ACA
D- Spinal artery
E- Posterior communicating artery
Ans: A

107- Accomodation reflex is coordinated in:
A- Cerebrum
B- Cerebellum
C- Midbrain
D- Pons
Ans: A

108- Myelination in the peripheral nervous system is done by:
A- Oligodendrocytes
B- Schwan cells
C- Astrocytes
D- Dentritic cells
Ans: B

109- Climbing fibres to purkinje arise from:
A- Superior Olivary nucleus
B- Inferior Olivary nucleus
C- Superior cerebellar peduncle
D- Inferior cerebellar peduncle
Ans: B

110- Before voluntary movement, the image is formed in which area of brain?
A- Anteriorpart of premotor area
B- Posterior part of pre motor area
C- Primary motor area
D- Sensory Area
Ans: A

111- Person with pituitary adenoma having Bitemporal Heteronymous hemianopth lesion lies at:
A- Optic Tract
B- Optic Chiasma
C- Optic Nerve
D- LGD
Ans: B

112- Wernicke area located in:
A- Inferior frontal lobe
B- Superior frontal lobe
C- Superior temporal gyrus
D- Inferior frontal gyrus
Ans: C
Explanation:
- Broca aphasia – Motor aphasia + Non-fluent + area 44 and 45 + inferior frontal gyrus
- Wernicke aphasia – Sensory aphasia + fluent + area 22+ superior temporal gyrus
- Global aphasia – Both Wernicke and broca aphasia + arcuate fasciculus
- Anomic aphasia – Mild fluent aphasia + failure of word retrieval + angular gyrus

113- Basal ganglia composed of:
A- Cortex+ Striatum +Subthalamus +Substantia nigra
B- Cortex +Globus pallidus
C- Striatum +Globus pallidus + Subthalamus + Substantia nigra
D- Striatum + Subthalamus + Substantia nigra
Ans: C

114- LMN lesion shows:
A- Increase Power
B- Decrease Power
C- Increase Muscle tone
D- Decrease Muscle tone
E- Fasciculation
Ans: C

115- A patient with loss of accomodation and 3rd Nerve palsy.Where is the lesion?
A- Cerebral Cortex
B- Cerebellum
C- Midbrain
D- Pons
Ans: C
Explanation:
- Loss of accomodation lesion in Cerebral Cortex
- Loss of accomodation reflex lesion in - Cerebral Cortex
- Loss of accomodation with 3rd nerve palsy lesion in- Midbrain

116- Characteristic feature of cerebellar disease:
A- Resting Tremor
B- Loss of accomodation
C- Dysdiadochokinesia
D- Nystygmus
Ans: C

117- Pathway to recognize object on hand or foot without visual stimulns:
A- Dorsal Column medial lemniscus
B- Spinithalmic
C- Rubrospinal
D- None
Ans: A

118- Aphasia center is:
A- Parietal Lobe
B- Temporal lobe
C- Occipital lobe
D- None
Ans: B

119- Vagus nerve location is:
A- Mibram
B- Pons
C- Medulla
D- Cortex
Ans: C
Explanation:
- Cranial nerve 3+4 – Midbrain
- Cranial nerve 5-8 – Pons
- Cranial nerve 9-11 – Medulla

120- Anomic aphasia is caused due to lesion of:
A- Dominant Brocas area
B- Wernickes area
C- Non dominant hemisphere brocas area
D- Occipital region
Ans: C
Explanation:
- Lesion of non-dominant hemisphere brocas area leads to Anomic Aphasia
- Broca aphasia – Motor aphasia + Non-fluent + area 44 and 45 + inferior frontal gyrus
- Wernicke aphasia – Sensory aphasia + fluent + area 22+ superior temporal gyrus
- Global aphasia – Both Wernicke and broca aphasia + arcuate fasciculus
- Anomic aphasia – Mild fluent aphasia + failure of word retrieval + angular gyrus

121- A person after having RTA complains of Leg weakness and Difficulty to walk. Which artery of Brain is likely involved?
A- MCA
B- MMA
C- ACA
D- PCA
Ans: C

122- What is normal CSF pressure?
A- 10 to 25 cm of water
B- 200 to 250 cm of water
C- 1 to 10 mm of water
D- 20 to 40 mm of water
Ans: A

123- Projecting fibers are found in:
A- Internal Capsule
B- Corpus callosum
C- MGB
D- LGB
Ans: A

124- A patient after RTA having left sided weakness and fall on left side lesion in:
A- Internal Capsule
B- Pons
C- Midbrain
D- Left Cerebellum
Ans: D

125- Person having tremors which usually aggravate by activity.Which of the following nucleus involved?
A- Cochlear Nucleus
B- Fastigial Nucleus
C- Substansia Nigr
D- Caudate Nucleus
Ans: B (Cerebellar Nucleus)

CamScanner

126- Cranial nerve 3 Nuclei located in:
A- Pons
B- Midbrain
C- Medulla
D- Thalamus
Ans: B

Explanation:
- Midbrain – CN 3 & 4
- Pons- CN 5 – 8
- Medulla – CN 9, 10 and 11

127- Loss of accommodation due to lesion in:
A- Cerebral Cortex
B- Midbrain
C- Pons
D- Cerebellum
Ans: A

Explanation:
- Loss of Accommodation reflex – Cerebral cortex
- Loss of Accommodation – Cerebral cortex
- Loss of Accommodation + 3rd CN involvement – Midbrain (Due to Edinger westphal nucleus)

128- Patient presents with increase rigidity, resting tremor. Lesion could be in:
A. Subthalamus
B. Caudate nucleus
C. Lentiform nucleus
D. Substantia nigra
Ans: D

129- Weakness on right for 2days and diplopia on seeing left?
A. Midbrain
B. Left internal capsule
C. Right internal capsule
D. Cerebral cortex
Ans: A

Explanation:
- Horizontal Diplopia – Cranial nerve 6>3
- Horizontal Diplopia – Pons (6 nerve) >Midbrain(3rd nerve)
- Cranial nerve 3 lesion cause – Vertical +Horizontal diplopia
- Cranial nerve 4 lesion cause – Vertical diplopia
- Cranial nerve 6 lesion cause – Horizontal diplopia

130- Proprioception is carried by:
A- Anterior spinothalamic
B- Lateral spinothalmic
C- DCML
D. Rubrospinal
Ans: C

131- Continues capillaries present in?
A- Brain
B- Kidney
C- Spleen
D- Liver
Ans: A

132- After RTA patient suffering from hitemporal heteronymous hemianopia lesion in?
A- Optic tract
B- Middle part of optic chiasma
C- Optic nerve
D- Occipital lobe
Ans: B

133- Regarding max determinant of CSF composition:.
A- Ependymal cells
B- Archanoid granulation
C- Choroid cells
Ans: A

134- Antigravity muscles is maintained by:
A- Corticospinal and corticobulbral tract
B- Cerebellum
C- Basal ganglia
D- Vestibulospinal
Ans: D

Explanation:
- Flexor muscle (Gravity) – Rubrospinal and medullo reticular
- Extensor help in standing (anti-gravity) - Vestubulospinal and Ponto reticular

135- Site of lumbar puncture:
A- Below L4
B- Above L4
C- L2 – L3
D- Above L6
Ans: A

Explanation:
- Below L4
- Above L5
- Between L4 – 5

136- A Patient having cerebral trauma after that decreased appetite and thirst cause is damage of:
A- Lateral hypothalamus
B- Medial hypothalamus
C- ADH
D- Aldosterone
Ans: A

137- Increase neuronal activity before skilled voluntary movement:
A- Spinal motor neuron
B- Cortical association area
C- Basal gangli
D- Cerebellum
Ans: B

138- Right sided upper and lower limb paralysis and tongue deviated artery involved:
A- ACA
B- ASA
C- PCA
D-
Ans: B

139- The nucleus of tractus solitarius contains
A- Ist order neurons
B- 2nd order neurons
C- 3rd order neurons
D- None
Ans: B

140- A patient with left sided brain lesion has hemiplegia on right side and the loss of pain and temperature on Right side, which tract is affected?
A- Right sided spinothalamic tract
B- Left sided spinothalamic tract
C- Rubrospinal tract
D- DCML
Ans: B

141- Interlaminar space is used for delivery of injection into:
A- Epidural
B- Subdual
C- Sub arachnoid
D- Pia matter
Ans: A

142. Cerebellum is connected to the midbrain through:
A- Vermis
B- Arcuate fibers
C- Superior cerebellar peduncle
D- Inferior cerebellar peduncle
Ans: C

143. Fibers of upper motor neurons are decussated in:
A. Internal capsule
B. Medulla
C. Pons
D. Cerebellum
Ans: B

144. Cerebral aqueduct of sylvius present in:
A- Within the brain stem
B- Ant to brain stem
C- Post to brain stem
D- In central canal of spinal cord
Ans: A

145- Herniation between L4 and L5 affects which spinal segment?
A- Coccygeal
B- Lumbar
C- Thoracic
D- Cervical
Ans: B (Affect L5SI)

146- After road traffic accident patient talking but makes no sense and aot understanding anything due to damage to which area?
A- Brocasarea
B- Wernicke's area
C- Somatosensory cortex
D- All
Ans: B

147- Middle cerebellar peduncle contains which tract?
A- Dorsal spinocerebellar
B- Ventral spinothalmic
C- Pontocerebellar
D- Olivocerebellar
Ans: C

148- Hippocampal injury causes:
A- Increase Sexual desir
B- Improve memory
C- No new memory
D- Inhibit Old memory
Ans: C

149- Proximal flexor muscles controlled by:
A- Rubrospinal
B- Corticospinal
C- Vesnbular
D- Cochlear
Ans: A

Explanation:
- Gravity or proximal muscle by - Rubrospinal or Red nucleus
- Antigravity muscle -Vesnbular nucleus

150- The structure most likely pierced by the needle during lumbar puncture is :
A- Conus medullaris
B- Filum terminale
C- Ligamentum flavum
D- Pia mater
E- Posterior longitudinal ligament
Ans: C

151- Pain Inhibitory system in brain & spinal cord located in which of the following?
A- Reticular formation
B- Raphe magnus nucleus
C- Nucleus cerelus
D- Anteriod horn grey matter
Ans: B

CamScanner

152- Left pons connection with:
A- Right cereum and right cerebrum
B- Left cerebellum and left cerebrum
C- Right cerebellum left cerebrum
D- Left cerebllum and right cerebrum
Ans: C

153- A female with sign and symptoms of hyperprolactinemia was diagnosed with pituitary adenoma. if this tumor grows anteriorly; it will compress which of the following structures?
A- Cavernous sinus
B- Optic nerve
C- Optic chiasma
D- Optic Tract
Ans: B

154- Corticospinal tract decussate at:
A- Pyramid
B- Medulla
C- Midbrain
D- Pons
Ans: A

155- Damage to dersal column tract causes:
A- Sensory ataxia
B- Loss of crude touch
C- Loss of pain
D- Loss of temperature
Ans: A

156- Subarachnoid space in adules ends at:
A- S2
B- S1
C- L1 lower border
D- Coccyx
Ans: A
Explanation:
In the Adult:
- Spinal cord ends at the level of lower border of the body of the L1 vertebra
- Subarachnoid space ends at the lower border of the body of S2 Vertebra

In the Child:
- Spinal cord ends at - L3 Vertebra

157- Tractus solitarius is formed by cell bodies of:
A- Taste receptors
B- First order neurons
C- Second order neurons of taste fibers
D- 3rd order neurons
Ans: C

158- Left Temporal gyrus/lobe lesion results in:
A- Right Superior quadrantanopia
B- Left Superior quadrantanopia
C- Right Inferior Quadrantanopia
D- Left Inferior Quadrantanopia
Ans: A

Explanation:
- Temporal lobe(Meyer loop) involve Lower retina result in Contralateral Superior Quadrantanopia
- Parietal lobe involve Upper retina result in Contralateral Inferior Quadrantanopia

159- L5 displaced forward on S1 in which disease?
A- Spondylolisthesis
B- Kyphosis
C- Scoliosis
Ans: A

160- Adjacent spinous processes of sacrum fuse to form:
A- Median sacral crest
B- Sacral Hiatus
C- Lateral sacral crest
Ans: A (RJ Last)
Explanation:
- Ajacent spinous processes of sacrum fuse to form – Median Sacral.
- Failure of Fusion of S4 & S5 – Sacral Hiatus.

161- Part of temporal lobe visible on medial surface of hemisphere:
A- Superior Temporal lobe
B- Inferior Temporal lobe
C- Para hippocampus area
D- Cigulate gyrus
E- Middle temporal lobe
Ans: B

162- Slow writhing movements are called athetosis due to defect in which of the following?
A- Globus pallidus
B- Caudate
C- Subthalamus
D- Thalamus
E- Cerebellum
Ans: A

163- Right optic tract lesion cause vision loss:
A- Left temporal and right nasal
B- Bitemporal hemianopia with macular sparing
C- Right Nasal and left Temporal
D- Right temporal and nasal
Ans: C
Explanation:
- Right Optic Track Lesion causes – Right Temporal and Left Nasal Fibers loss
- Right Optic Track Lesion Causes – Right Nasal and Left Temporal Vision loss
- Right Optic Track is made up of – Right Temporal fibers (which See Nasal Visual) and Left Nasal Fibers (which See Temporal Vision) so Fibers loss and vision loss are Separate things

164- Thalamus blood supply is by:
A- MCA
B- PCA
C- ACA
D- PICA
Ans: B

165- Right sided paralysis and loss of vibrations tongue deviated to left lesion in:
A- Internal capsule
B- Pons
C- Middle Medulla
D- Cerebellum
E- Cerebrum
Ans: C (Medial medullary syndrome)

166- Right side hemiplegia and right side facial palsy (Angle deviate to opposite) Lesion most likely in:
A- Medulla
B- Cortex
C- Pons
D- Cerebellum
E- Midbrain
Ans: B

167- Patient with right hemiplegia double vision on seeing left side Lesion of:
A- Pons
B- Midbrain
C- Cerebrum
D- Medulla
Ans: A>B
Explanation:
Uncrossed Hemiplegia
- Same Sided Hemiplegia and Same sided Face involve (Angle Deviate to opposite) lesion in – Internal Capsule (Forbrain)or Cortex

Crossed Hemiplegia
- One sided Hemiplegia and Other Side Face involve – Brainstem (Pons/Mtdbrain)
- Horizontal Diplopia – CN6 Lesion (Pons)
- Vertical Diplopia – CN4 Lesion (Midbrain)
- Vertical + Horizontal Diplopia – CN3 Lesion (Midbrain)
- So for Horizontal Diplopia (as in question) Pons(CN 6) > Midbrain (CN3)

168- A person after RTA with damage to temporal bone which artery is involved?
A- Cerebral artery
B- Bridging vein
C- Superior cerebral vein
D- Anterior branch of middle meningeal artery
Ans: D

169- CT of patient shows dilatation of right lateral ventricle. Most likely blockade:
A- Foramen of monro
B- Aqueduct
C- Foramen Magnum
D- Foramen Magande
Ans: A

170- Reticular formation location:
A- Floor of Sulvyian Aqueduct
B- Roof of Sulvyian Aqueduct
C- Lateral Ventricle
D- Fourth Ventricle
Ans: A

171- Woman presented with bitemporal hemianopsia & increase Prolactin level. Which organ is damaged:
A- Hypothalamus
B- Thyroid Gland
C- Ovary
D- Pituitary Gland
Ans: D

172- Slow component of nystagmus is controlled by:
A- Vestibular Apparatus
B- Brainstem
C- Cortex
D- Medulla
Ans: A
Explanation:
- Endolymph flow stimulates hair cells that's vestibular ganglion & vestibular nuclei while fast components by cortex.

173- Broca's Aphasia due to blockage of:
A- MCA
B- ACA
C- PCA
D- Basilar Artery
Ans: A

174- Olfactory nerve cells repair or change in every 2 weeks:
A- Basal cells
B- Supporting cells
C- Bipolar cells
D- None of the above
Ans: A

175- Pt. came with dysphagia, polyuria & sleeping disorders lesion in:
A- Hypothalamus
B- Subthallamus
C- Pituitary
D- Adrenal
Ans: A

CamScanner

176- Retired officer came with c/o tremors while doing small work! Gait abnormality and past pointing, when asked to touch nose, Lesion in:
A- Basal ganglia
B- Cerebellum
C- Cerebrum
D- Pons
Ans: B

177- A man presented with stroke, ACA is affected; it will affect which area of brain:
A- Somatosensory Area
B- Brocas Area
C- Occipital Area
D- Primary Motor area
Ans: A

178- Most of the optic fibers end at:
A- Lateral Geniculate body
B- Medial Geniculate body
C- Optic chiasma
D- Pretectum
Ans: A
Explanation:
- Optic fibers that's visual pathway ends at LGB
- Auditory fibers ends at MGB
- L for Light that's vision
- M for Music that's hearing

179- A lesion in the basal ganglia results in which of the followings:
A- Dysdydokinesia
B- Intention tremers
C- Cog-wheel rigidity
D- Involuntary movements
Ans: D

180- Regarding weber syndrome:
A- Contralateral paralysis with ipsilateral ptosis and lateral deviation of eye
B- Ipsilateral paralysis with ipsilateral ptosis
C- Ipsilateral Paralysis & cootralateral ptosis
D- Contralateral ptosis & ipsilateral weakness
Ans: A
Explanation: Weber's Syndrome, also known as superior alternating hemiplegia, a form of stroke that affects the medial portion of midbrain. It's characterized by the presence of ipsilateral occulomotor nerve palsy & contalateral hemiparesis or hemiplegia.

181- Clark Nucleus level:
A- C8-S3
B- T1-L2
C- T1-T4
D- C1-C4
Ans: B

182- Nucleus Ambigunus Contains:
A- CN 8,9,10
B- CN3,4,5
C- CN 9,10,11
D- CN 12
Ans: C

183- Patient is suffering from dysphagia, dysarthria, analgesia and thermoanesthesia on ipsilateral side of the face and ipsilateral horner's syndrome. Occlusion of which of the following artery will produce these sign & symptoms:
A- Posterior inferior cerebellar artery
B- Superior cerebellar artery
C- Anterior inferior cerebellar artery
D- Anterior spinal artery
E- Posterior spinal artery
Ans: A
Explanation: This is the case of Lateral Medullary (Wallenberg) Syndrome that's caused by occlusion of PICA (Posterior inferior Cerebellar Artery) & leads to Vomiting, vertigo, nystagmus, Decrease Pain and temperature sensation from ipsilateral face and contralateral body, dysphagia, hoarseness, decrease gag reflex, ipsilateral horner syndrome, ataxia and dysmetria

184- Dorsomedial nucleus of thalamus rebild with:
A- Sweet taste
B- Loud Noise
C- Itching
D- Memory
Ans: D
Explanation:
- Insula is associated with Tactile sensation
- Insula is present in Temporal lobe.
- Sense of disgust is by left insula.
- Olfactory cortex associated with Uncus.
- Memory related with Dorsomedial nucleus of thalamus.

185- Which of the following is trigeminal reflex?
A- Pupillary Reflex
B- Corneal Reflex
C- Accomodation
D- Cardiac Reflex
Ans: B

186- Prosopagnosia means:
A- Inability to read
B- Inability to walk
C- Inability to recognize faces
D- Inability to move
Ans: C

187- Medial part of frontal & parietal lobe blood supply:
A- MCA
B- ACA
C- PCA
D- Spinal Artery
Ans: B

188- Nucleus pulposus derived from:
A- Dermatome
B- Sclerotome
C- Notochord
D- Dytome
Ans: C
Explanation:
- The only adult anatomy derived from the notochord is the nucleus pulposus of the intervertebral disc.

189- Loss of pain & temperature sensation but intact touch sensation in which of the following:
A- Tabes Dorsalis
B- DM
C- Syringomyelia
D- SCD of Spinal cord
Ans: C

190- Cranial neuropore closure defect with absent brain calvarium:
A- Hydrocephalus
B- Anencephaly
C- Microcephaly
D- Myeloschiasis
Ans: B

191- Patient with upper motor neuron lesion exhibits signs of right side hypertonia with exaggerated reflexes & positive babinski's sign.Which of the following area is affected:
A- Left Broadman Area 4
B- Left Internal Capsule
C- Left Pyramids
D- RubroSpinal
Ans: A

192- Highest presentation on the motor homunculus:
A- Hand
B- Lips
C- Face
D- Thigh
Ans: A
Explanation:
- Highest sensory area: Lips.
- Highest Motor area: Thumb > Hand.
- Smallest motor area: Thigh.

193- Injury at foramen ovale will lead to:
A- Loss of sensation of at lower face
B- Loss of sensation at upper face
C- Loss of sensation of forehead
D- Loss of bitter taste
Ans: A
Explaoation:
- Mandibular nerve is passing through formaen ovale & due to damage to this foramen and nerve sensation of lower face will be affected.

194- Which of the following is nerve supply of SCM?
A- Accessorynerve
B- Vagus nerve
C- Trigeminal nerve
D- Abducent nerve
Ans: A

195- Xerostomia, dry eyes & otitis media, where is the nuclei located?
A- Cerebral cortex
B- Pons
C- Midbrain
D- Medulla
Ans: B

196- Circle of willis is formed by:
A- One anterior cerebral arteries
B- Three posterior cerebral arteries
C- Two Posterior Communicating arteries
D- Two anterior communicating arteries
Ans: C
Explanation:
- Circle of willis is formed by two anterior cerebral arteries, two posterior cerebral arteries, two posterior communicating arteries & one anterior communicating artery.

197- Face sensation lost along with hearing loss, which of the following is the site of lesion?
A- Pons
B- Medulla
C- Internal Ataditory Meatus
D- Cortex
Ans: C

198- Spinal nerve comprises of which of the following?
A- Motorcomponent
B- Sensory Component
C- Motor & Sensory Component
D- None of the above
Ans: C

CamScanner

199- Which of the following is the nucleus of central medulla?
A- Vagus Nucleus
B- Nucleus Ambigous
C- Dorsal Nucleus
D- Inferior Olivary Nucleus
Ans: B

Explanation:
Upper Medulla:
- Vestibular cochlear
- Inferior olivary
- Spinal trigeminal

Middle Medulla:
- Nucleus ambiguas
- Hypoglosal Nucleus
- Dorsal motor Nucleus Vagus
- Spinal Trigeminal

Lower Medulla:
- Hypoglosal Nucleus
- Dorsal Motor Nucleus Vagus
- Spinal Trigeminal

200- Which of the following is correct route of CSF?
A- Fourth ventricles to Third ventricles
B- Lateral venticles to fourth ventricles
C- Foramen Magendi to subarachnoid space
D- Foramen Lushka to magendi
Ans: C

201- Vagus nerve cut & central part stimulated will lead to:
A- Tachycardia
B- Tachypnea
C- Increase Respiration
D- Apnea
Ans: D

202- True about ependymal cells:
A- Line the ventricles and spinal canal
B- Covers neurons
C- Function in phagocytosis
D- Help in defense
Ans: A

Explanation: Ependymal cell, type of neuronal support cell (Neuroglia) that forms the epithelial lining of ventricles in the brain & the central canal of spinal cord.

203- Specific Gravity of CSF:
A- 1.005 – 1.009
B- 1.004 – 1.008
C- 1.009 – 2.009
D- 1.003 – 1.007
Ans: A

204- A patient has Ataxic gait & Ipsilateral face sensation lost. Where is the site of lesion:
A- Cerebro Pontine Angle
B- Cerebellopontine Angle
C- Midbrain
D- Pons
Ans: B

205- Accommodation reflex intact but light reflex is lost due to lesion in:
A- Cerebral cortex
B- Midbrain
C- Pretectum
D- Pons
Ans: C

Explanation:
- If accommodation or accommodation reflex lost without 3rd cranial nerve involvement: Cerebral cortex
- With 3rd Cranial nerve involvement Midbrain
- Accommodation reflex intact but light reflex lost in lesion of: Pretectum

206- Lesion involving the parietal lobe of the brain will result in:
A- Athetosis
B- Astercognosis
C- Prosopagnosia
D- Astigmatism
Ans: B

207- A patient presents with stroke, which has resulted in Left sided hemiplegia and he is unable to talk (aphasia), this lesion is as a result of which affected artery?
A- PICA
B- AICA
C- MCA
D- ACA
E- PCA
Ans: C

208- A patient presents with unique choreiform movements due to the lesion to:
A- Substantia Nigra
B- Caudate
C- Mid brain
D- Amygdala
E- Hippocampus
Ans: B

209- The process of long term memory involves?
A- Protein synthesis
B- Long chain fatty acids
C- Carbohydrates breakdown
D- Protein and carbohydrates lysis
Ans: A

210- A section of caudal pons consists of horizontal fibers. Theses fibers most likely consist of:
A- Superior cerebellar peduncle
B- Middle cerebellar peduncle
C- Inferior cerebellar peduncle
D- Sub thalamus
Ans: B

Explanation

Cerebellum connected to mid brain via	Superior peduncle	cerebellar
Cerebellum connected to medulla via	Inferior peduncle	cerebellar
A section of horizontal fibers in caudal pons	Middle peduncle	cerebellar

211- The part of the brain responsible for anxiety, emotions and rage:
A- Amygdala
B- Lateral Thalamic nuclei
C- Hippocampus
D- Medial Thalamic nuclei
Ans: A

212- Nerve supply of the adrenal medulla is:
A- Lesser splanchnic nerve
B- Greater splanchnic nerve
C- Pudendal nerve
D- Iliobypogastric nerve
Ans: B

213- Pituitary adenoma invades which bone?
A- Occipital
B- Parietal
C- Temporal
D- Sphenoid
Ans: D

214- Sensory supply to the eyes is lost and the jaw movements are intact. Which of the following has undergone lesion?
A- Sensory nucleus of trigeminal nerve
B- Optic nerve nucleus
C- Occulomotor nerve
D- Trochlear nerve
Ans: A

215- Damage to the Crunial nerve IX (9), the taste lost would be?
A- Sweet
B- Sour
C- Salty
D- Bitter
Ans: D

Remember:

Sour + salty + Sweet	Facial nerve CN-vii
Bitter	Glossopharyngeal nerve CN-ix

216- The brain structure embedded in lateral hemisphere:
A- Splenium
B- Operculum
C- Insula
D- Cnis
Ans: C

217- The calcarian sulcus is involved in which sensations?
A- Visual
B- Olfactory
C- Motor tone
D- Coordination
Ans: A

218- A person who had a huge blow to the temporal portion of the head and as a result blood got accumulated in the epidural space, the vessel ruptured would be:
A- ASA
B- MMA
C- PCA
D- ACA
Ans: B

219- A patient with low level of thyroid hormones. TSH level is also low but increases when TRH is administered to the patient. The structure most likely damaged:
A- Thyroid gland
B- Pituitary
C- Hypothalamus
D- Adrenal gland
Aos: C

220- Decussation of motor fibers occur at:
A- Pons
B- Mid Brain
C- Medulla
D- Cerebellum
Ans: C

221- A patient with loss of touch seasation on face while pain and temperature being intact, which nucleus lesion is involved?
A- Primary sensory nucleus
B- Spinal nucleus
C- Mesencephalic nucleus
D- Thalamic nuclei
Ans: A

222- Blood supply of the thalamus is by:
A- ACA
B- PCA
C- ASA
D- MCA
Ans: B

223- A patient with vertigo and sensation of nausea and vomiting, the site responsible would be:
A- Juxtapose dorsal vagal and vestibulocochlear nucleus
B- Dorsal nucleus
C- Ventral Nucleus
D- Caudate
Ans: A

CamScanner

224- The nerve palsy of 6th and 7th nerves would involve:
A- Medulla
B- Mid Brain
C- Forebrain
D- Pons
Ans: D

225- Splaal cord is supplied by which of the following?
A- Spinal artery
B- Vertebral artery
C- Basilar artery
D- Internal thoracic artery
Ans: A

226- Vertebral bodies limited by:
A- Ligamentum flavum
B- Anterior & posterior longitudinal ligaments
C- Lagamentum nuchae
D- Interspinous ligament
Ans: B
Explanation
- Vertebral Bodies Limited by – Anterior an posterior Longitudjaal Ligament
- Vertebral Bodies kept in position by – Anterior an posterior Longitudinal Ligameat
- Vertebrae joined to Adjacent Lamina – Ligament Flavum
- Hyperenteasion of neck Ligament Injured – Anterior Longitudinal Ligament
- Hyper flexion of neck Ligament Injured – Ligament Nuche

227- Regarding Corpus callosum true is
A- Connected to fornix by septum pellucidum
B- Most fibers interconnect symmetrical areas of cerebral cortex
C- Related superiorly to falx cerebri
D- Fibers of genu curve into frontal lobe as forcep minor
E- Rostrum connects genu to lamina terminlais
Ans: B(B>A)

228- True about motor cortex, only present In:
A- Frontal Lobe
B- Temporal Lobe
C- Parietal Lobe
D- Occipital Lobe
Ans: A
Explanation:
- Precentral gyrus that's motor cortex is present in frontal lobe while sensory cortex is present in parietal lobe.

229- Cortical area with maximum representation:
A- Lips
B- Nose
C- Little Finger
D- Knee
Ans: A
Explanation:
- Maximum sensory cortical area is Lips
- Maximum motor cortical area is Thumbs Hand.

230- Spinal Anesthesia is given in:
A- Subarachnoid Space
B- Epidural Space
C- Extra Dural Space
D- None
Ans: A

231- Which space is assessed after piercing the inter laminar ligament during LP?
A- Subdural Space.
B- Subarachnoid Space.
C- Pia
D- Epidural Space
E- Intracranial space.
(Inter laminar ligament =Ligamentum flavum)
Ans: D

232- Premotor area is supplied by:
A- Anterior and middle cerebral artery
B- Posterior cerebral
C- PICA
D- Middle n posterior cerebral art
E- Anterior n posterior cerebral art
Ans: A

233- A Young man presented with recurrent episodes of Syncope. These syncope episodes are related to reduce cerebral perfusion when the arm ipsilateral to the subclavian stenosis is exercised. subclavian steal phenomenon (SSP) occurs when there is stenosis or occlusion of the subclavian artery. In SSP which artery is stealing blood and shunting this to arms?
A- External carotid
B- Internal carotid
C- Thyrocervical trunk
D- Vertebral artery
E- Cerebral artery
Ans: D

234- Septum pellucidum is bounded superiorly by?
A- Body of carpus callosum
B- Rostrum of carpus callosum
C- Fornix
D- Genu
Ans: A(Neurosnell)

235- 26 years old man had gunshot wound to the spine after which he lost sensations to lower limbs loss of power but increased tone and up going plantar with central clonus lesion at?
A- Corticospinal
B- Lateral spinothalamic
C- Both corticospinal and lateral spinothalamic
D- Cerebellum
E- Corticobulbar
Ans: C

237- What is age of closure of Anterior fontanelle?
A- 24 month
B- 12 month to18months
C- 9 month
D- 36 month
Ans: A
Explanation:
- After 18 month range is 18-24months(KLM+BD)

238- Cephalohematoma most common site is:
A- Loose areolar tissue
B- Connective tissue
C- Under the skin
D- Under periostium
Ans: D

239- Superolateral relation of floor of 4th ventricle:
A- Superior cerebellar peduncle
B- Middle cerebellar peduncle
C- Inferior cerebellar peduncle
D- Lower pons and pyramidal tracts
Ans: A

240- In which of the following area, the vomiting center is located:
A- Thalamus
B- Hypothalamus
C- Medulla oblongata
D- Pons
Ans: C

241- Person has problem with reading writing and speaking. Lesion in:
A- Left frontal and temporal
B- Right frontal and temporal
C- Right parietal
D- Left parietal
Ans: A

242- Lucid interval after injury, then again loss of consciousness:
A- Epidural hemntoma
B- SAH
C- Subdural hemorrhage
D- Intracerebral hemorrhage
Ans: A

243- Sacral hiatus:
A- Fused S4 and S5
B- Unfused S4 and S5
C- Between S1 and S2
D- Between S2 and S3
Ans: B

244- Microglial cells
A- Are known as spider cells
B- Found in grey matter of CNS
C- Found in white matter of CNS
D- Macrophages of CNS
Ans: D

245- Labyrinthine artery is a branch of:
A- Internal carotid
B- Anterior cerebral
C- PICA
D- AICA
Ans: D

246- Fibers after decussating in medulla are called:
A- Pyramid
B- Lemniscus
C- Callosum
D- Splenium
Ans: A

247- Medial geniculate body, a thalamic nucleus?
A- Lies on the mid brain
B- Is attached to the main mass of thalamus
C- Receive fibers from oculomotor nerve
D- Relays fibers to frontal lobe
E- Relays fibers to visual cortex
Ans: A

248- Lesion at right precentral gyrus cause
A- Exaggerated knee jerk on left
B- Right hemiplegia
C- Loss of voluntary control on left
D- Normal plantars on right
E- Right side sensory los
Ans: C

249- If thalamus gets damaged,which is not affected:
A- Sense of olfaction
B- Vibration
C- Touch
D- Pain
Ans:

250- Dorsal nucleus of vagus nerve is present:
A- Upper part of pons
B- Lower part of pons
C- Medulla
D- Midbrain
Ans: C

CamScanner

251- Posterior communicating artery:
A- Passes above the oculomotor nerve and connects ICA and PCA
B- Passes above oculomotor nerve and connects ICA to MCA
C- Connects ICA to posterior cerebellar artery
Ans: A

252- Injury to lateral hypothalamus will cause:
A- Increases appetite
B- No effect on hunger
C- Decrease hunger
D- Increases hunger for carbohydrates
Ans: C

253- Internal carotid artery:
A- Ophthalmic branch enters thru superior otbital fissure
B- It enters through squamous paart of temporal bone
C- At bifurcation its lateral to external carotid artery then turns medially and posteriorly
D- Pierces diaphragma sella medial to optic nerve
Ans: C

254- Primary Brain Vesicle:
A- Diencephalon
B- Mesencephalon
C- Metencephalon
D- Prosencephalon
E- Myelencephalon
Ans: B

255- Extra-Ocular nucles of eyes are coatrolled by which Loop:
A- Association loop
B- Orbital loop
C- Occulomotor loop
D- Sacculartoop
Ans: C

256- Intracranial and extracranial veins are joined by
A- Emissary Veins
B- Cavernous sinus
C- Dipolic veins
D- Facial veins
Ans: A

257- PICA damage, blood supply of which part will be affected?
A- Dorslateral of medulla
B- Pons
C- Midbram
D- Cerebellum
Ans: A

258- Regarding Brainstem reticular formation:
A- Unusual sumulus causes arousal
B- Imtiates Rem sleep
C- Inhibition of neural systems causing wakefulness
D- Does not communicate with upper part of CNS
Ans: A

259- How many white ramus communicn are there in our body:
A- 13
B- 14
C- 15
D- 16
Ans: B

260- Basal ganglia send excitatory signals to:
A- Thalamus
B- Pontine reticular formation
C- Medullary reticular formation
D- Olvary nucleus
Ans: A

261- In CSF:
A- Arachnoid vallii can be seen with naked eye
B- Glucose 120 mg/di
C- Proteins 20-40 mg/di
D- Drain into caversous sinus
Ans: C

262- Spinal cord supplied by:
A- Vertebral artrey
B- Intercostal arteries
C- Basilar artery
D- PICA
E- AICA
Ans: A

263- Spinal cord supported by:
A- Denticulate ligament
B- Transverse ligament
C- Ligamentum flavum
D- ligamentum nuchae
Ans: A

264- Brain veins are tributaries of?
A- Diploic veins
B- Emissary veins
C- Inferior jugular vein
D- Petrosal venous smuscs
E- Dural venous sinuses
Ans: E

265- Sub Arachnoid space ends at:
A- L2
B- L4,5
C- S1.2
D- S3,4
Ans: C

266- Optic chiasma damage with also hypothalamus damage will result in:
Diabetes Instpidus
A- Hyperphagia
B- Hypertension.
C-
Ans: B

267- Ventral corticospinal end at:
Mid thoracic
A- Upper thoracic
B- All spinal cord
C- Lower thoracic
D-
Ans: A

268- About cerebellum true is
Lies below tentorum cerebelli
A- Middle cerebellar connect with medulla or spinal was given
B- Only supply by basilar artery
C- Lesion Cause resting tremors
D-
Ans: A

269- Which part of brain receives major excitatory input to from cerebral cortex butit itself doesn't send axons to cortex?
A- Substantia Nigra
B- Globes Pallidus
C- Caudate
D- VI Thalamus
E- Va Thalamus
Ans: A

270- Posteroxuperior relation of pituitary:
A- Sphenoid air cells
B- Ethmoid air cells
C- Maxillary sinus
D- Mastoid air cells
Ans: A

271- Coccygeal segment of spinal cord lie at the level of:
A- LI
B- C1
C- S2
D- C2
Ans: A

272- Thoracolumbar outflow composed of:
A- ANS
B- CNS
C- Parasympathetic
D- PNS
E- Sympathetic
Ans: E

273- Basic electrical rhythm of brain is located in:
A- Reticular formation
B- Thalamus
C- Cerebellum
D- Medulla oblaganta
Ans: A

274- Resed lamina 3, 4 presents io:
A- Lateral Gray horn
B- Posterior Gray horn
C- Anterior Gray born
D- Gray commissure of spinal cord
Ans: B

275- Most abundant sphingolipids In Gray matter of the brain:
A- Sphingomyclin
B- Cerebroside
C- Globoside
D- Glycide
Ans: A

276- Parasympathetic flow to beart via:
A- Vagus nerve
B- Superficial cardiac plexus
C- Deep cardiac plexus
D- TI - T5
E- T1 - T4
Ans. A

277- Ventraf spioothalmic tract carry:
A- Itch and tickle
B- Pain
C- Temperature
D- Vibration
E- Proprioception
Ans: A

278- Parasympathetic origin in spinal cord:
A- S2 S3 S4
B- SJ S2 S3
C- S3 S4 S5
D- LI-L2
Ans: A

279- The strongest inbibitory signals in central nervous system come from which neurons?
A- Substantia nigra
B- Pyramidal cells of cerebral cortex
C- Purkinje cells of cerebellar cortex
D- Thalamus
Ans: C

280- Athetosis is:
A- Due to defect in chromosome 4
B- Slow continuous writhing movements
C- Jerky movements
D- Resting tremors
Ans: B

281- Left half of pons is related to:
A- Left olivary nucleus
B- Left cerebellar hemisphere & right basal ganglia
C- Right cerebellar hemisphere & left basel ganglia
D- Anterior vestibular nuclei
E- Right cortical tract & left olivary nucleus
Ans: C

CamScanner

282- Anterior & posterior spinal arteries are the branches of:
A- Vertebral arteries and PICA respectively
B- Aica & vertebral arteries respectively
C- Ica & vertebral artenes respectively
D- Vertebral & posterior cerebral arteries respectively
Ans: A (RJ Last)

283- When a person encounters an obnoxious stimulus, he reflexively withdraws his limbs & body away from the stimulus. Most appropriate statement regarding this reflex is:
A- Is monosynaptic
B- Is absent in lower animals
C- Remains for many months after complete cord transection
D- Weak stimulus prolongs it
E- Is a superficial reflex
Ans: C

284- Dosral Coulmn fibers of lower body related to upper body at cervical level:
A- Medjal to lateral
B- Lateral to media
C- Dosral to ventral
D- Rsotral to caudal
Ans: A

285- Death is caused by bilateral damage to which nerve?
a. Vagus
b. Hypoglossal
c. Trigeminal
d. Facial
Ans: A

286- What is not present at L4:
A- Lateralhorn
B- Ventral horn
C- Dorsal horn
D- None
Ans: A

287- Synapses absent in:
A- Ventral column
B- Dorsalcolumn
C- Lateral column
D- Sympathetic chain
E- Dorsal root ganglion
Ans: E

288- Basal gaoglia damage will cause all except:
A- Involuntary movements
B- Postural disturbance
C- Intention tremors
D- Rigidity in limbs
Ans: C(cerebellum function)

289- Inferiorly the floor of fourth ventricle has which structure medially:
A- Pons
B- Hippocampus
C- Caudate
D- Amygdala
Ans: A

290- In some (hospt. or lab), a research by Functional MRI of thalamus is being done to detect neurological activity of thalamus on different sensory stimuli .Which of these stimuli will produce minimal neurologic activity in thalamus:
A- Visual
B- Auditory
C- Gustatory
D- Vibration/proprioception
E- Olfactory
Ans: E (olfactory sensations bypass thalamus)

291- Two kids bet on eye blinking, the one kid lost as he blinked 1st, this blinking was due to:
A- Thoracic segment of spinal cord
B- Cervical segment of spinal cord (superior cervical ganglion)
C- Mid brain
D- Medulla
Ans: B

292- Medial leminiscus formed by decussation of:
A- Pyramidal tract
B- Anterior spinothalmic tract
C- Internalarcuate fibers
D- External arcuate fibers
Ans: C

293- Superior colliculus is compressed. It will affect eye muscles and cause what?
A- Nystagmus
B- Convergence
C- Contralateral saccades
D- Ipsilateral saccades
Ans: C

294- All central primary somatosensory nucleus were damaged. Which one of these are primary sensory?
A- Dorsal grey of spinal cord + dorsal white column + trigeminal nucleus
B- Dorsal grey + dorsal white + abducens nucleus
C- Dorsal grey and trigeminal complex
Ans: A

295- Which nerve is Motor and Sensory?
A- Facial
B- Optic
C- Olfactory
D- Hypoglossus
Ans: A

296- In RTA, loss of phonation and can't speak which area damaged?
A- Sub frontal
B- Posterolateral part of inferior frontal gyrus
C- Perital lobe
D- Inf part of temporal lobe
E- Occipital lobe
Ans. B

297- Patient of Meningitis was given treatment, after few weeks presented with morning headache and papilledema:
A- Hydrocephalus
B- Recurrent meningitis
C- Involvement of meninges
D- Dural sinus blockage
E- Involvement of cerebral vessels
Ans. A

298- Visual fibers after crossing chiasma passe:
A- Lateral geniculate body to optical radiation
B- MGB to optical radiation
C- Occipital lobe
D- Frontal lobe
Ans. A

299- Optic nerve is?
A- GVE
B- GVA
C- GVS
D- SSA
Ans. D

300- After gunshot injury at L1 a man presented to you with loss of pain and temperature on right side. Where is the lesion?
A- Left lateral spinothalmic tract
B- Right lateral spinothalamic tract
C- Left anterior spinothalamic tract
D- Right anterior spinothalamic tract
Ans. A

301- Ideal site for LP:
A- L2 – 3
B- L4 – S1
C- L4 – 5
D- L5 – S2
Ans: C

Explanation:
- Ideal Site – L4 5
- Below – L4
- Above – L5

302- Major Blood vessels in brain are present in:
A- Sub arachnoid space
B- Sub dural space
C- Extradural space
D- Calvaria
Ans: A

303- Part of brain involved in intelligence:
A- Frontal lobe
B- Visual lobe
C- Somatosensory association
D- Occipital lobe
Ans: A

304- Which one Directly control autonomic reflex system of body
A- Thalamus
B- Hypothalamus
C- Cerebrum
D- Cerebellum
E- Pons
Ans: B

305- Neuroepithelium of nose is
A- Unipilar
B- Biopolar
C- Pseudounipolar
D- Multipolar
Ans: B

306- Blow to temporal region cause involvement of which artery?
A- Middle meningeal artery
B- Anterior cerebral artery
C- Posterior cerebral artery
D- Suprior Cerebral veins
E- Bridging veins
Ans: A

307- True about pia matter is
A- Exteods into sulci aod fissures of brain tissue
B- Extends into posterior median sulcus of spinal cord
C- Has openings at the medial / lateral ends of ventricles
D- Extends into ventricles
E- Continues along with dura up to S2 level.
Ans: A
Explanation:
- Dura & arachnoid mater extends up to S2.
- Pia matter extends up to tip of coccyx

CamScanner

308- Final common motor pathway is
A- Descending fibers of Corticospinal tract
B- Alpha motor neurons
C- Upper motor neuron
D- Cerebral cortex
E- Fibers ending in sensory cortex
Ans: B

309- A man unable to hold a mug of coffee an image draw of shoulder and hand movement on which part of brain?
A- Premotor
B- Primary motor
C- Somatosensory
D- Cerebellum
Ans: A

310- Agranular cerebral cortex is present is:
A- Auditory area
B- Gustatory area
C- Primary motor area
D- Secondary visual area
E- Somatic sensory area
Ans: C

311- Neo striatum contains:
A- Caudate+putamen
B- Caudate+lentiform
C- Caudate+globus pallidus externa
D- Caudate+globus pallidus intern
E- Globus pallidus externa+lentiform
Ans: A
Explanation:
- Neostriatum – Caudate +Putamen
- Corpus striatum – Caudate +Lantiform
- Paleo striatum – Globus pallidus
- Lantiform nucleus – Globus pallidus

312- Hyphemia is
A- Blood in posterior chamber
B- Blood in Anterior chamber
C- Blood in eye aponeurosis
D- Blood in lense
Ans: B

313- Anterior pituitary tumor compressing central optic chiasma visnal field defect will be
A- B/L nasal field
B- B/L temporal field
C- Right nasal
D- Left temporal
Ans: B

314- Sensory supply of Temporal/parietal area of scalp by which of following nerve:
A- Supraorbital
B- Supratrochlear
C- Auriculotemporal
D- Greater Auricular
E- Accessory
Ans: C

315- Child presented with Scaphocephaly which sulure closed prematurely?
A- Saggital
B- Coronal
C- Frontal
D- Parietal
Ans: A

316- ASA and PSA are branches of
A- Vertebral artery and Posterior inferior cerebellar artery Respectively
B- Vertebral artery and Anterior inferior Cerebellar artery Respectively
C- Basilary artery
D- Basilar artery and Anterior inferior Cerebellar artery Respectively
E- Vertebral artery and Basilar artery Respectively
Ans: A

317- Patient is having Ataxia which part of cerebellum is affected
A- Flucoborular lobe
B- Fastigial nucleus
C- Red Nucleus
D- Vermis
E- Anterior lobe
Ans: D (Kaplan)
Explanation:
Vermis lesion
- Anterior vermis lesions are usually the result of degeneration from alcohol abuse and are present with gait ataxia.
- Posterior vermis lesions result from medulloblastomas or ependymomas and present with truncal ataxia(Drunken Sailor gate)

318- Right homonymous hemianopia occur due to lesion of
A- Left Occipital lobe
B- Right temporal lobe
C- Optic chiasma
D- Optic radiations
E- Right Occipital lobe
Ans: D
Explanation:
- Homonymous hemianopia lesion of - Optic radiations
- Heteronymous hemianopia lesion of - Optic chiasma

319- A patient presented in OPD with loss of touch, max two point discrimination distance can be checked between:
A- Lips
B- InterScapular region
C- Hands
D- Back
E- Legs
Ans: B

Explanation:
- Maximum 2 point Discrimination on – Lips
- Minimum 2 point Discrimination on – Scapula
- Maximum 2 point Discrimination Distance on – Scapula
- Minimum 2 point Discrimination Distance on – Lips

320- A woman has stroke and lost sensation. On CT in lateral side of parietal area damage. Lesion in
A- Secondary Somatosensory area
B- Broca
C- Visual cortex
D- Temporal
Ans: A

321- A patient cannot recognize opposite side of his face/body, lesion is in:
A- Neocortex
B- Primary somaesthetic area
C- Secondary somaesthetic area
D- Frontal cortex
E- Somaesthetic association area
Ans: E

322- A woman had an episode of stroke and lost sensations. On Ct scan lateral side of parietal area is damaged, lesion is in?
A- Broca's area
B- Visual cortex
C- Somaesthetic association area
D- Primary somatosensory area
Ans: C

323- In astercognosis on right side brain area involved is:
A- Left internal capsule
B- Right internal capsule
C- Pons
D- Cerebral cortex
E- Parietal lobe
Ans: E

324- Sinus present at junction of Saggital sinus and tentorium cerebelli is:
A- Maxillary sunus
B- Opthalmic sinus
C- Inferior petrosal sinus
D- Superior sinus
Ans: C

325- A girl presented with non resting tremors, lesion present in?
A- Cerebellum
B- Cerebrum
C- Substantia nigra
D- Pons
Ans: A
Explanation:
- Resting tremor lesion in -Substantia nigra
- Non resting tremor(Intentional) lesion in – Cerebellum

326- Afferent fibres from pontocerebellar carry impulse from:
A- Floconodular lobe
B- All parts of cerebellum except floconodular lobe
C- Cerebral cortex
E- Substansia nigra
Ans: C

327- Patient present with argyl Robertson pupil lesion in
A- Cilliary ganglion
B- Visual cortex
C- Superior colliculus
D- Inferior colliculus
E- Pretectal nucleus
Ans: E

328- Spread of infection to Cavernous sinus caused by?
A- Inferior ophthalmic vein
B- Superior ophthalmic vein
C- Supraorbital vein
D- Infraorbital vein
Ans: B

329- Patient has cavernous sinus thrombosis first sign will be:
A- Ptosis
B- Loss of upward and medial rotation of eye ball
C- Loss of abduction
D- Loss of Adduction
E- Loss of downward and medial rotation
Ans: C
Explanation:
- Cavernous sinus infection: SOV
- Cavernous sinus thrombosis - SOV
- Cevnous sinus affect abducent nerve so abduction of eye will be affected

330- Child with frontal and occipital bossing due to premature closure of which suture?
A- Sagittal
B- Parietal
C- Coronal
D- Occipital
E- Lambdoid
Ans: A

331- Saccades controlled by:
A- Cerebellum
B- Brain stem
C- Basal ganglia
D- Cerebral cortex
E- Deep nuclei
Ans: A

CamScanner

332- Acute and severe damage of spinal cord cause:
A- Spastic paralysis
B- Flacid pamlysis
C- Atrophy
D- Rigidity
Ans: A

333- Truck driver having vesicles at L4 and L5 presented with complain of loss of left sided fine touch temp and pain ialacl most likely defect of?
A- Left ventrolateral pathway
B- Right anterolateral
C- LeftDCML
D- Right Lateral tract
Ans: C

334- Patient has tinnitus, fascial muscle paralysis. Where is the lesion?
A- (internal) acoustic meatus
B- Cerebellopontine angle
C- Fanalcanal
D- None
Ans: B

335- 3rd cranial nerve arises from:
A- Pons
B- Medulla
C- Cortex
D- Midbrain
E- Cerebellum
Ans: D
Explanation:
- Midbrain - Cranial nerve 3 &4
- Pons - Cranial nerve 5-8
- Medulla - Cranial nerve 9-11

336- A patient in RTA has damage posterior cranial fossa and jugular foramen which clinical finding will you find in it:
A- Corneal reflex lost
B- Can't shrug trapezius
C- Absent gag reflex
D- Ptosis
Ans: B

337- Superior cerebral puduncle is connected to:
A- Dorsal midbrain
B- Rosttal midbrain
C- Dorsal to cerebellum
D- Rostral cerebellum
Ans: B

338- A young man came with damage to posterior cranial fossa during RTA he has difficulty in pharyngeal swallowing, which nerve is damaged?
A- II,V, VII,IX
B- V, VII, IX, X, XI
C- VII, IX, X
D- IX,X,XI,XII
Ans: C

339- A young boy fell from motor bike and has head injury on examination his jugular foramen was damaged what findings will you see?
A- Loss of tongue movement
B- Loss of taste
C- Loss of gag reflex
D- Loss of Voluntry movement
Ans: C

340- Pituitary gland lies
A- Lateral to cavernous sinus
B- Medial to cavernous sinus
C- Posterior to optic chiasma
D- In front of optic nerve
E- Inferior to optic nerve
Ans: B
Explanation:
- Cavernous Sinus – Laterally(Pituitary gland medial to it)
- Sphenoid Air Sinus - Inferiorly
- Optic Chiasm - Superiorly
- Optic nerve -Anteriorly

341- Second order neuron of Anterior spinothalamic tract lie in:
Q- Thalamus
B- Hypothalamus
C- Substantia gelatinosa
D- Accessory nucleus
E- Cortex
Ans: C
Explanation:
- Lie in Substantia gelatinosa
- End in Thalamu

342- A patient presented with Left superior quadrantanopia which tract is involved:
A- Optic radiation
B- Optic tract
C- Right meyer loop damage
D- Left meyer loop damage
Ans: C
Explanation
- Temporal lobe (Meyer loop) involve Lower retina result in Contralateral superior quadrantanopia
- Parietal lobe involve upper retina result in contralateral inferior quadrantanopia

343- Before voluntary movement, the image is formed in which area of brain:
A- Premotor area
B- Cerebellum
C- Primary motor area
D- Sensory Area
Ans: A (Only suitable option)

344- If light through in left eye absent light reflex in both eye, when light through in Right eye light reflex is present in both eye, injury occur at??
A- Left oculumotor nerve
B- Right oculomotr nerve
C- Visual cortex
D- Right Edinger westphal nucleus
E- Pretectum
Ans: E

345- A patient presented with unilateral corneal reflex lost due to an RTA where is the lesion
A- Inferior orbital fissure
B- Optic canal
C- Superior orbital fissure
D- Foramen spinousum
E- Foraman rotundum
Ans: C
Explanation:
- VI branch of trigeminal pass through Superior orbital fissure which carry afferent of trigeminal reflex

346- A blow on lateral side of nose which leads to bluish discoloration around eye due to fracture of:
A- Ethmoid
B- Glabella
C- Maxilla
D- Frontal part of orbital bone
Ans: A

347- Pregnant lady with raised AFp but her BHCG is awaited ,Possibility of?
A- Anencephaly
B- Fetal Renal agenesis
C- Down syndrome
D- Edward syndrome
Ans A

348- Antomatic bladder is caused by injury:
A- Below Sacral segment
B- At Sacral segment
C- Above Sacral segment
D- Parasympathetic
Ans: C

349- Which nerve passes through Foramen Ovale:
A- Maxillary
B- Opthalmic
C- Facial
D- Glosopharyngeal
E- Mandibular
Ans: E
Explanation:
- Foramen Ovale – Accessory Meningeal artery pass
- Foramen Spinosum – Middle Meningeal artery pass
- Superior Orbital Fissure – VI (Opthalmic nerve) pass
- Foramen Rotandum– V2(Maxillary Nerve) Pass
- Foramen Ovale – V3(Mandibular Nerve) pass

350- Which part of brain does pain perception:
A- Ventral horn of substantia gelatinosa
B- Dorsal horn substantia gelatinosa
C- Anterior tract
D- DCML
Ans: B

351- Circle of willis formed by:
A- Internal carotid and Vertebral
B- Internal carotid and basilar
C- Vertebral and basilar
D- Basilar
Ans: B

352- Under 2 years Babinski sign is normal but it disappears after 2 years due to:
A- Myelination by Oligodendrocytes
B- Myelination by Schwan cells
C- Myelination of Veins
D- Anterior horn atrophy
Ans: A

353- Epidural space is at which level of Vertebral canal
A- Foramen Magnum to S1
B- C7
C- T12
D- L2
E- L3
Ans: A

354- Posterior external arcute libers are other name for which of the following?
A- Anterior spinocerebelar
B- Posterior spinocerebelar
C- Spinothalamic tract
D- Dorsal Cornu
E- Cuneo cerebellar tract
Ans: E

CamScanner

Explanation:
- External posterior arcuate – Cunocerebellar
- External anterior arcuate – Pontocerebellar
- Internal arcuate – Dorsal medial leminuscus

355- In Long term memory, area involved will be
A- Amygdala
B- Prefrontal Cortex
C- Temporal cortex
D- Cingulate gyrus
E- Limbic System
Ans: E

356- Anterior choroidal artery is branch of:
A- ASA
B- Vertebral artery
C- Internal carotid artery
D- Basilar artery
Aas: C

357- Man had trauma and gradual vision loss start. Acute vision loss preserved due to collateral supply from:
A- Anterior cerebral artery
B- Middle cerebral artery
C- Posterior communicating artery
D- Posterior cerebral artery
Ans: C

358- A known case of diabetes presented with dilated pupil.non reactive to light.which artery aneurysm causes this condition?
A- Anterior communicating
B- Posterior communicating
C- ACA
D- MCA
Ans: B

Explanation:
A Com – Compression of bitemporal hemianopia (compression of optic chiasm); visual acuity deficits; rupture Z ischemia in ACA distribution Z contralateral lower extremity hemiparesis, sensory deficits.
MCA – Rupture and ischemia to MCA distribution Z contralateral upper extremity and lower facial hemiparesis, sensory deficits.
PCom – Compression ipsilateral CN III palsy mydriasis (blown pupil) may also see ptosis, down and out eye.

359- Patient having xerostomia, likely nucleus involved is:
A- Superior Colliculus
B- Inferior Colliculus
C- Superior Salivatory nucleus
D- Inferior Salivatory nucleus
Ans: C

360 In DCML lesion, What will he seem?
A- Anasthesia
B- Asterognosis
C- Aphasia
D- Ataxia
Ans: B

361- Afferent taste pathways from tongue relay at:
A- Lingual nerve joins trigeminal Nerve
B- Nerve goes to inferior cerebral puduncle to cun ecerbellar tract
C- Sensation travels through the peripheral axon to tractus solitarius
D- Glossophyamgeal nerve carries to spinal nucleus of trigeminal
Ans: C

362- Nucleus tractus Solitarius and Associated tracts recieve GVA and SVA by which nerves?
A- CN 7,9,10
B- CN 7,12,9
C- CN7,9,11
D- CN 6,7,8
Ans: A

363- In Alzheimer disease.involved area of brain is following:
A- Prefrontal cortex
B- Basal ganglia
C- Hypothalamus
D- Caudate
E- Entorhinal cortex
Ans: E

364- Blood supply of taste area is:
A- ACA
B- PCA
C- MCA
D- ICA
Ans: C

365- Content of inferior orbital fissure:
A- Lacrimal nerve
B- Frontal nerve
C- Trochlear nerve
D- Zygomatic nerve
E- Oeculomotor nerve
Ans: D

366- Two vertebral arteries join to form basilar artery this is called:
A- Homocladic
B- Heterocladic
C- End to end anastomosis
D- Convergent
E- Divergent
Ans: D

367- Regarding internal auditory meatus, true is:
A- Length 2.5cm
B- One end or fundus closed
C- Passes through facial,vestibular & cochlear nerve
D- Starts from cerebellopontine angle
Ans: C

368- Posterior one third of tongue taste pathway involves:
A- Tractus solitarious
B- Thalmic neuclei
C- Superior olivary nucleus
D- Inferior olivary nucleus
Ans: A

369- Broadman area 43 function is:
A- Hearing
B- Speech
C- Olfaction
D- Taste
Ans: D

370- Melanin is found in:
A- Cilliary body
B- Iris
C- Lung
D- Conjuctiva
Ans: B

371- Patient during RTA sustained Sacral injury. He presented with overflow incontinence . Where is the lesion
A- Sensory nerves
B- Parasympathetic
C- Sympathetic
D- Detrous muscle
Ans: B

Explanation:
Injury above sacral segment (Sympathetic damage) Cause:
- Spastic Bladder
- Automatic Bladder
- Urge Incontinence

Injury at sacral segment (Parasympathetic damage) Cause:
- Atonic Bladder
- Autonomous Bladder
- Overflow Incontinence

Note: Neurogenic is common term for both spastic and atonic bladder.

372- A patient went to prosthodontics it did not fit in his mouth so he was reffered to a doctor. On examination, he has rigidity and tremors. Which nucleus is likely affected?
A- Red nucleus
B- Substantia nigra
E- Edinger westpal nucleus
D- Trigeminal
Ans: B

373- Broca's area of speech is located in which of the following?
A- Superior temporal gyrus
B- Parietal lobe
C- Inferior gyrus of frontal lobe
D- Superior gyrus of frontal lobe
E- Inferior occipital lobe
Ans: C

374- Pendular knee jerk is characteristic of:
A- UMNL
B- LMNL
C- Cerebellar disease
D- Pons lesion
E- Cortex Atrophy
Ans: C>A

375- Patient having right sided weakness and loss of vibration sense and tongue deviated to left side. Lesion is located in
A- Anterior spinal artery
B- Internal carotid artery
C- Basilar Artery
D- PICA
E- Vertebral artery
Ans: A (Kaplan)

Explanation:
Medial medullary syndrome
- Contralateral paralysis – Upper and lower limbs
- Decrease contralateral proprioception
- Ipsilateral hypoglossal dysfunction (Tongue deviate to Ipsilaterally)

376- Major artery entering skull and supplying whole brain?
A- Vertebral
B- Basilar
C- Spinal
D- Carotid
Ans: B

377- Loss of Crude touch and pressure is due to lesion of which tract?
A- DCML
B- Anterior Spinothalamic Tract
C- Olivocerebellum Tract
D- Corticospinal Tract
E- Rubrospinal Tract
Ans: B

CamScanner

Explanation:

- The posterior or dorsal column medial laminscal pathway carries proprioception, vibration sense and fine touch and Two point discrimination.
- Anterior spinothalamic carries crude touch
- Lateral spinothalamic carries pain & temperature sense

378- Which lesion will cause complete blindness?

A- Optic chiasma
B- Optic nerve
C- Optic tract
D- Temporal lobe

Ans: B

379- Regarding a typical spinal nerve

A- All recieve white rami Communicans
B- Anterior horn contains sensory neurons
C- Divide into large dorsal a smallerventral rami
D- Is formed in intervertebral foramen
E- Dorsal root ganglion contains Second order neurons

Ans: D

380- Minimum air blood barrier formed by

A- Type 2 pneumocyte
B- Alveolar macrophages
C- Pores of kohn
D- None

Ans: C

381- B/L All sensations lost due to:

A- Lesion in B/L dorsal
B- Total spinal cord hemisection
C- Total corticospinal lesion
D- Occipital love lesion

Ans: B

382- Hemiballismus occurs due to damage in:

A- Substantia Nigra
B- Subthalamic Nuclei
C- Globus Pallidus
D- Hypothalamus
E- Cortex

Ans: B

Explanation:

- Subthalamic lesion - Hemiballismus
- Substantia nigra lesion - Parkinson
- Globus pallidus lesion - Athetosis

383- Function of Cerebellum includes

A- [illegible]
B- [illegible]
C- [illegible]
D- [illegible]

Ans: C

384- Intension tremors and jerky eye movement occur due to:

A- Midbrain lesion
B- Cerebellar chorea
C- Hyperthyroidism
D- Anxiety
E- Cortex lesion

Ans: B

385- Brainstem parts include:

A- Medulla
B- Cortex, Medulla &pons
C- Pons , Medulla and midbrain
D- Cerebellum & Pons

Ans: C

386- A young lady has aphasia, due to lesion of non-dominant brocas area.It will cause:

A- Global aphasia
B- Anomic aphasia
C- Brocas aphasia
D- Wernicke aphasia

Ans: B

Explanation:

- **Broca aphasia** – Motor aphasia + Non fluent + area 44 and 45 + inferior frontal gyrus
- **Wernicke aphasia** – Sensory aphasia + fluent Non sense speech + area 22+ superior temporal gyrus. In wernike aphasia Patient has Difficulty in comprehending spoken words and Unable to Read(Alexia) Or Write in understandable language(Agraphia)
- **Global aphasia** – Both Wernicke and broca aphasia + arcuate fasciculus
- **Anomic aphasia** – Mild fluent aphasia + failure of word retrieval + angular gyrus

387- Raised prolactin and B/L temporal vision loss due to defect in:

A- Superior optic chiasma
B- Lateral optic chiasma
C- Middle optic chiasma
D- Optic tract

Ans: C

388- A Patient having hyperreflexia due to:

A- UMN lesion
B- LMN lesion
C- Sensory lesion
D- Mixed lesion
E- Internal Capsule

Ans: A

389- The roof of anterior horn of lateral ventricle formed by:

A- Genu of corpus callosum
B- Head of corpus callosum
C- Rostrum of corpus callosum
D- Body of corpus callosum

Ans: D

390- Arachnoid pia dura merge to form coccygeal ligament at which level?

A- L1
B- S2
C- S3
D- L2

Ans: B

Explanation:

- Coccygeal Segment – L1
- Coccygeal Ligament – S2 – Cocyx 1

391- The artery of Adam Kiewicz:

A- Extends between T9-T10
B- Extends between T5-T6
C- Extends between T7-T8
D- Extends between T9-T11

Ans: D

392- Memory centre is located in

A- Frontal lobe
B- Occipital lobe
C- Parietal lobe
D- Temporal lobe
E- Parieto occipital lobe

Ans: D

393- Epidural space is

A- From Foramen Magnum to L5.
B- From Foramen Magnum to S2.
C- From Foramen Magnum to L1.
D- From Foramen Magnum to L4

Ans: B

394- A patient presented in Semi- conscious condition with subclavian steal syndrome, Blood supply to which artery is causing this condition?

A- Intercostal artery
B- Vertebral artery
C- Internal carotid artery
D- Facial artery

Ans: B

395- Lateral ventricles are separated by

A- Falx cerebri
B- Septum pellucidum
C- Hippocampus
D- Amygdala

Ans: B

396- After RTA, patient presents with loss of light touch and pressure on left side. No other sensory or motor loss. Surgeon orders mri because he is suspecting damage of?

A- Right sided ventral spino thalamic tract
B- Left sided ventral spinothalamic
C- Right lateral spinothalamic
D- Left lateral spinothalamic
E- Nucleus gracilis

Ans: A

397- The direction of nystagmus is vertical when:

A- With the head tipped sideway
B- After warm water put into one ear
C- After cold water is put in both ears
D- After section of one vestibular nerve

Ans: A

Explanation:

- Head is tipped side ways leaning on shoulder - Vertical Nystagmus
- Head is upright- Horizontal Nystagmus
- Head is tipped flexed forward - Rotatory Nystagmus

398- Blood supply to internal capsule and basal ganglia?

A- Anterior cerebral artery
B- Anterior choroidal artery
C- Middle cerebral artery
D- Posterior communicating artery
E- Posterior vertebral artery

Ans: C

399- Most abundant cells in gray matter of CNS are:

A- Microglia
B- Fibrous astrocytes
C- Oligodendrocytes
D- Protoplasmic astrocytes

Ans: D

Explanation:

- Oligodendrocytes and astrocytes are both glial cells.
- Most numerous glial cell overall is astrocytes
- Most numerous glial cells in white matter isoligodendrocytes.
- Most numerous astrocyte in white matter is fibrous astrocyte
- Most numerous astrocyte in gray matter is protoplasmic astrocyte

400- Blood supply of pituitary gland?

A- ACA
B- MCA
C- Internal carotid artery
D- PCA
E- PCom artery

Ans: C

401- Patient came in ER after RTA (trauma) to spinal cord which one of these is seen?

A- Spastic Paralysis
B- Flaccid paralysis
C- Hyperreflexia
D- Atrophy

Ans: A

402- Lower Quadraotnopia is due to lesion in
A- Optic radiation (parietal portioo)
B- Optic radiation(temporal portion)
C- Primary visual cortex
D- Occupital cortex
Ans: A

Explanation:
- Temporal lobe (meyer loop) involve lower retina result in contralateral superior quadrantanopia.
- Parietal lobe involve upper retina result in contralateral inferior quadrantanopia

403- Diminished jaw jerk due to lesion of?
A- Mesencephalic nucleus of V nerve
B- Facial motor nucleus
C- Glossopharyngeal injury
D- Vagus injury
Ans: A

404- Boy fell from flight stairs got skull fracture and went unconsious blood was in nape of neck due to Damage of
A- Middle cranial fossa
B- Anterior cranial fossa
C- Posterior cranial fossa
D- Occipital
Ans: C

Explanation:
Anterior Cranial Fossa Fracture
- Bleed from nose
- Bleed under eye(Raccoo eyes or Panda sign)

Middle Cranial Fossa Fracture
- Bleed from ear
- Bruise over ear(Battle Sign)

Posterior Cranial Fossa Fracture
- Bleed in Nape of neck

405- A patient has Right sided hemiplegia, left sided deviation of angle of mouth and dribbling. What will be present:
A- Wasting of muscle with fasciculatioo
B- Clasp-knife rigidity
C- Lead-pipe rigidity
D- Cogbwheel rigidity
Ans: B

406- A boy after injury to head present with the complain of Decrease appetite and lesion on which nucleus of hypothalamus?
A- Medial
B- Lateral
C- Ventral
D- Posterior
E- Inferior
Ans: B

Explanation:
- Lateral Nucleus is Feeding Centre its Damage result in Stop Feeding and make you Lean.
- Medial Nucleus is satiety centre and its damage result in over eating and make you Massive.

407- Medial surface of frontal and Parietal lobe supplied by:
A- PCA
B- MCA
C- ACA
D- Internal carotid artery
Ans: C

408- Sudden Right sided hemiplegia, bleeding from internal capsule and basal ganglia. Which artery is damaged?
A- ACA
B- PCA
C- MCA
D- AICA
E- PICA
Ans: C

409- Regarding visual tract true is
A- All optic tract end in lateral geniculate body
B- Right fibers decussate at optic chiasma
C- Visual field receive fibers only from lateral geniculate
D- Visual field reaches occipital lobe
Ans: A

410- Difficulty in swallowing after stroke is due to lesion of
A- Nucleus solitatius
B- Nucleus ambiguus
C- Dentate nucleus
D- Red nucleus
Ans: B

411- Astereognosis is caused by the lesion of which area of brain?
A- Frontal lobe
B- Anterior part of frontal
C- Right internal capsule
D- Left internal capsule
E- Occipital lobe
Ans: E

Explanation:
- Prospagnosia lesion in – Temporal Lobe
- Asterognosis lesion in – Parieto occipito temporal lobe

412- Cavernous sinus infection because palsy of lateral rectus nerve injured will be:
A- Trigemmal nerve
B- Ophtbalmic nerve
C- Abducent nerve
D- Facial nerve
E- Trochlear nerve
Ans: C

413- Which of the following structure lies deep to and parallel with carotid sheet?
A- Recurrent latyngeal nerve
B- Vagus nerve
C- Sympathetic chain
D- Internal jugular vein
E- External jugular vein
Ans: C

414- A patient having tremors while Starting some movements and discordination he is having lesion in:
A- Midbiain
B- Cerebellum
C- Pons
D- Midbrain
E- Corex
Ans: B

415- Injury to greater wing of sphenoid and inferior orbital fissure damages which nerve?
A- Occulomotor
B- Trochlear
C- Zygomatic
D- Lacrimal
E- Nasociliary
Ans: C

416- A patient cannot utter words due to damage of
A- Parietal lobe
B- Broca area
C- Angular gyrus
D- Wernike area
E- Frontal lobe
Ans: B

417- Cranial and spinal nerve both supply:
A- Sensory supply to muscles
B- Motor supply to muscles
C- Supply organs
D- Supply gut
Ans: B

418- Pregnant female has diet lacking green leafy vegetables possible pathology of fetus
A- Low birth weight
B- Megaloblastic anemia
C- Congenital heart disease
D- Anencephaly
Ans: D

419- Which tumor involves extension to nerve sheath?
A- Myxoma
B- Adenoma
C- Hemangiopericytoma
D- Carcinoma expleomorphic adenoma
Ans: D

420- Parasympathetic supply of parotid gland is supplied by branches of:
A- Facial nerve
B- Glossopharyngeal nerve
C- Vagus nerve
D- Chorda tympani nerve
Ans: B

421- Function of 4th cranial nerve on eye movement is
A- Superionmedial
B- Superolateral
C- Inferiorolateral
D- Adduction
Ans: C

422- A newborn is brought with lumbosacral swelling containing meninges without neural tissue. What is most likely diagnosis of this swelling?
A- Spina bifida with Meningocele
B- Meningomyelocele
C- Encephalocele
D- Meningomyelocncephalocele
E- Anencephaly
Ans: A

423- 85 year male Patient complain of lower backache doctor during examination noticed a outgrowo with tuft of hairs at L5 what is your Diagnosis?
A- Spina bifida occulta
B- Anencephalay
C- Meningiomyocele
D- Menmgicele
Ans: A

424- Person with pituitary adenoma having bitemporal heteroonymous hemiaoopia lesion lies at:
A- Optic Tract
B- Central Optic Chiasma
C- Optic Nerve
D- LGD
E- Visual cortex
Ans: B

425- Female present with weakness in legs, upon MRI Bilateral infarct in Frontal lobes, tract involved will be
A- Rubrospinal tract
B- Corticospinal tract
C- Spioothalamic tract
D- Lateral vestibular tract
E- Olivicerebellar
Ans: B

CamScanner

426- Pain, temperature and crude touch is carried by which of following tract?

A- DCML
B- Anterolateral Spinothalamic tract
C- Trigeminothalamic tract
D- Lateral tract
E- Robrospinal tract
Ans: B

Explanation:

- The posterior or dorsal column medial leminscal pathway carries proprioception, vibration sense and fine touch and two point discrimination.
- Anterior spinothalamic Carries Crude Touch
- Lateral spinothalamic carries pain & temperature sense Trigeminothalamic tract carries pain and temp from face

427- Interruption of cervical sympathetic chain result in Horner syndrome if sympathetic nerves to the EYE are affected which one of the following is the commonest finding?

A- Absence of sweating on affected side
B- Drooping of eyelid on affected side
C- Flushing of face on affected side
D- Occurs in young age group
E- Xerosis and anhydrosis on affected side
Ans: B>A

428- A patient present with Ataxia on both closing eyes and open eyes. patient sways with open eyes and eyes closed lesion in:

A- Cerebellum
B- Cerebellar peduncle
C- Dcml tract
D- Left internal capsule
E- Cortex
Ans: A

Explanation:

Patient fall on Close eye only(Positive Romberg) – DCML lesion

Patient fall on open and close eye – Cerebellum lesion

429- Fracture of Pterion which artery damage

A- Middle Meningeal Artery
B- Middle Cerebral Artery
C- Posterior Cerebral Artery
D- Anterior Cerebral Artery
Ans: A

Explanation:

Pterion is related with Middle Meningeal Artery & that"s what will be damaged at this site trauma

430- The functional cortical area electrically stimulated movement of eyes especially opposite side and control movement of eye is

A- Cortical eye field
B- Frontal eye field
C- Medulla
D- Midbrain
Ans: B

431- A 35-year-old male presented with fluent, expressive, motor aphasia dorminant hemisphere. Which area brain is involved?

A- Wernicke's area
B- Temporal lobe
C- Angular gyrus
D- Broca's area
E- Parietal lobe
Ans: D

432- Satiety centre is located in:

A- Medulla
B- Midbrain
C- Pons
D- Thalamus
E- Hypothalamus
Ans: E

433- Secondary somesthetic area supplied by

A- MCA
B- ACA
C- Middle meningeal artery
D- PCA
E- Occipital artery
Ans: B

434- Blood supply of Thalmus, Sub thalamus and hypothalamus by branch of which artery:

A- MCA
B- ACA
C- Posterior communicating
D- Anterior choroidal
E- Internal carotid artery
Ans: E

435- A young man presented with absent stretch reflex, atrophy of calf muscles loss of pain and temperature on the lateral aspect of leg and foot. The most likely lesion is:

A- Upper motor neuron lesion
B- Lower motor neuron lesion with anterior horn damage
C- Lower motor neuron lesion
D- Lower + upper motor neuron lesion
Ans: B

436- A patient has loss of vibration, proprioception and two point discrimination lesion of which of following tract?

A- Anterior spinothalamic
B- Lateral Spinothalamic
C- DCML
D- Rubrosoibal tract
Ans: C

437- Which of the following tract carries sensation of crude touch?

A- DCML
B- Anterior Spinothalamic Tract
C- Olivocerebellum Tract
D- Corticospinal Tract
E- Rubrospinal Tract
Ans: B

Explanation:

- The posterior or dorsal column medial leminscal pathway carries proprioception, vibration sense and fine touch and Two point discrimination.
- Anterior spinothalamic carries crude touch.
- Lateral spinothalamic carries pain & temperature sense.

438- Congenital hydrocephalous is due to blockage in Cerebral aqueduct at:

A- Telencephlan
B- Mesencephlan
C- Diencephlan
D- Prosencephlan
Ans: B

439- Lateral wall of cavernous sinus coutains:

A- VI nerve
B- VII
C- VIIand VI
D- VI,V2 CN 3 and CN4
Ans: D

440- Blow to Head caused extra durnl hematoma due to involvement of which artery?

A- Middle meningeal artery
B- Anterior cerebral artery
C- Posterior cerebral artery
D- Superior Cerebral veins
E- Bridging veins
Ans: A

441- After head injury patient having difficulty in writing and reading language comprehension assessed by hospital staff area damage is:

A- Broca aphasia
B- Somesthetic association area
C- Wernicke area
D- Frontal
E- Parietal lobe
Ans: C

442- Complete transection of brainstem above pons would

A- Result in cessation of all breathing movements
B- Prevent any voluntary holding of breath
C- Prevent control of central chemoreceptors from exerting any control over breathing
D- Prevent peripheral chemoreceptors from exerting any control over ventilation
E- Abolish Hering Breuer reflex
Ans: B

443- A microscopic slide stained with cajal method shows cells in gray matter which had long branches processes, occupied most of inter neuroanal spaces and perivascular feet spaces. What type of cell is this:

A- Ependymal cells
B- Olidodendrocytes
C- Fibrous astrocytes
D- Microglial
E- Protoplasmic astrocytes
Ans: E

444- A patient presented with hemisection of spinal cord, what changes could be seen in the patient?

A- Contralateral loss of pain & temperature below the lesion site
B- Ipsilateral loss of pain & Temperature
C- Contralateral loss of Proprioception
D- Spastic paralysis on both sides
E- Complete paralysis
Ans: A

445- If sympathetic supply is completely cut off what will be level of section

A- Sacral
B- All thoracic
C- Thoracic + Lumbar
D- Lumbar
Ans: B

446- Which Structure is relay centre for all sensation except olfaction:

A- Basal ganglia
B- Cortex
C- Thalamus
D- Midbrain
E- Medulla
Ans: C

447- The lateral ventricle communicates with the 3rd ventricle through:

A- Aqueduct of Sylvius.
B- Foramen of Magendie.
C- Foramen of Monro.
D- Foramen of Luschka.
E- Central canal
Ans: C

CamScanner

448- Which nuclear group in the brain stem is responsible for the reticular activating system norepinephrine input to cerebral structures?
A- Raphae nuclei
B- Locus coeruleus
C- Lateral reticular formation
D- Nucleus gracilis
Ans: B

449- Spinal cord in child ends at:
A- L1
B- Upper border of L2
C- Lower border of L3
D- Upper border of L3
E- L4
Ans: D

450- A patient having resting Tremors, shifting gait and cog wheel which area affected?
A- Globus palidus
B- Caudate and putamen
C- Lentiform nucleus
D- Lentiform + Putamen
Ans: B

451- Pregnant with neural tube defect which will be increased in blood?
A- HCG
B- Alpha feto protein
C- LDH
D- Aflatoxin
Ans: B

452- Loss of Accomodation reflex, lesion in which area:
A- Cerebellum
B- Mid brain
C- Pons
D- Cerebrum
E- Medulla
Ans: D
Explanation:
- Loss of Accommodation reflex – Cerebral cortex
- Loss of Accommodation – Cerebral cortex
- Loss of Accommodation + 3rd CN involvement – Midbrain (due to Edinger westphal nucleus)

453- In A patient loss of proprioception occur after RTA what is underlying mechanism?
A- Lateral Column lesion
B- Lateral Inhibition
C- Posterior inhibition
D- Field Blockage
E- Anterior Inhibition
Ans: B
Explanation:
- Loss of proprioception lesion in – Posterior column (DCML)
- Loss of proprioception mechanism is – Lateral inhibition (Guyton)

454- Which of following is sign of cerebellar lesion?
A- Resting Tumor
B- Synergism
C- Dysarthria
D- Hypertonia
E- Increase reflexes
Ans: C

455- Substance causing peripheral neuropathy and degeneration of myelin in CNS:
A- Lead
B- Asbestos
C- Silicosis
D- Beryllium
E- Co
Ans: A

456- 30 years old female with fever headache ptosis mydriasis and isochoric bilateral horizontal diplopia nerve involved:
A- Abducent nerve palsy
B- Trochlear nerve
C- Oculomotor nerve
D- Trigeminal nerve
Ans: C

457- A patient has loss of abduction of eye nerve injured will be:
A- Trigemmal nerve
B- Ophthalmic nerve
C- Abducent nerve
D- Facial nerve
E- Trochlear nerve
Ans: C

458- Left Asterognosis is cause by the lesion of which area of brain?
A- Occipital
B- Anterior part of frontal
C- Right internal capsule
D- Left internal capsule
E- Frontal lobe
Ans: C(No option of parietal lobe)
Explanation:
- For propagnosia inferior temporal lobes mostly related but if option of temporal lobe is not given then parietooccipital temporal lobe option is also correct.
- Prospagnosia lesion in – Inferior temporal lobe.
- Asterognosis lesion in – Parietal lobe

459- A person with uncoordinated and inaccurate movements of hand and motor ataxia Lesion is in:
A- Premotor cortex
B- Somatosensory
C- Primary motor
D- Dorsal nucleus
Ans: A

460- Pleasure, Reward center, Fear, Addiction control by:
A- Nucleus accumbens and septal nucleus
B- Locus ceruleus
C- Basal nucleus of Meynet
D- Raphe Nucleus
Ans: A

461- Fear centre located in?
A- Hypothalamous
B- Amygadala
C- Thalamous
D- Left insular cortex
Ans: B

462- Neuroendocrine respoose involves which part?
A- Thalamus
B- Hypothalamus
C- Spinal cord
D- Temporal lobe
Ans: B

463- Cerebellar signs are due to:
A- Hypocalcemia
B- Hypokalemia
C- Hyponatremia
D- Hypercalecemia
E- Uremia
Ans: B

464- Superior cerebellar peduncle contains which tract:
A- Dorsal spinocerebellar
B- Ventral spinocerebellar
C- Pontocerebellar
D- Olivocerebellar
Ans: B
Explanation:
- Superior cerebellar peduncle - Central spinocerebellar
- Middle cerebellar peduncle - Pontocerebellar

465- Which hemianopia occurs due to lesion of optic chiasm?
A- Binasal
B- Bitemporal
C- Right nasal
D- Left Temporal
Ans: B

466- Swear gland and pilloerector muscle are supplied by:
A- postganglionic sympathetic cholinergic
B- Preganglionic Sympathetic cholinergic
C- Adrenal medulla
D- Preganglionic adrengeric
Ans: A

467- A patient has Left lower limb weakness artery involved is:
A- ACA
B- MCA
C- PCA
D- PICA
Ans: A

468- Fibers of corticospinal tract and corticobalbar pass through:
A- Hypothalamus
B- Anterior of Cerebelli
C- Middle third of crus cerebri
D- First half of Thalamus
Ans: C

469- Tumor in Middle cranial fossa involves which of the following:
A- Lesser wing of sphenoid
B- Greater wing of sphenoid
C- Temporal bone
D- Petrous part of temporal bone
Ans: B

470- Long receptive field sensation carried by:
A- Dorsal column
B- Lateral spinothalamic tract
C- Anterior spinothalamic tract
D- Merkle disc
Ans: B
Explanation:
- Large Receptive Field – Ruffini corpuscle
- Small receptive Field – DCML
- Long Receptive field – Lateral spinothalamic Tract

471- Feature of cerebellar lesion is?
A- Inability to maintain posture
B- Difficulty initiating movement
C- Resting tremors
D- Hypertonia
Ans: A
Explanation:
- Initiation of movement by basal ganglia
- Resting tremor in Parkinson disease

In cerebellar disease following occur
- Dysdiadochokinesia
- Intension tremors
- Ataxia
- Dysarthria
- Hypotonia
- Posture instability

472- Elder patient has head injury due to fall there loss of memory due to damage of:
A- Parietal lobe
B- Temporal lobe
C- Occipital lobe
D- Frontal lobe
Ans: B

473- Patient presents in OPD with loss of vibration and proprioception due to:
A- Lateral spinothalamic tract
B- Anterior spinothalamic tract
C- Interruption of posterior column
D- Spinocerebellar tract
Ans: C
Explanation:
DCML is also called posterior column

474- Persuit movement of eye controlled by:
A- Cerebellum
B- Basal ganglia
C- Brainstem
D- Cerebrum
Ans: A

475- Which Cells in retina cause self Generation of impulse?
A- Bipolar
B- Amacrine
C- Ganglion
D- Horizontal
Ans: C

476- Excessive overgrowth of neuroglia with cavity formation in the gray mater around the central canal of spinal cord resulting into dissociated anesthesia occurs in:
A- Poliomyelitis
B- Syringobulbia
C- Syringomyelia
D- Tabes dorsalis
E- Upper motor neurone lesion
Ans: C

477- Anterior fontanelle is called:
A- Asterion
B- Bregma
C- Pterion
D- Lambda
Ans: B

478- Accumulation of blood due to damage of middle meningeal artery at:
A- Subdural
B- Epidural
C- Subarachnoid
D- Arachnoid and pia
E- Pia and brain
Ans: B

479 Lateral to Pituitary gland lies:
A- Cavernous sinus
B- Optic tract
C- Optic chiasma
D- Optic nerve
Ans: A
Explanation:
- Cavernous Sinus – Laterally (Pituitary medial to it)
- Sphenoid Air Sinus – Inferiorly
- Optic Chiasm – Superiorly
- Optic nerve – Anteriorly

480 What structure is notably absent in the cervical spinal cord when compared to the thoracic and lumbar spinal cord?
A- Gray matter
B- White matter
C- Anterior horns
D- Dorsal root ganglia
E- Lateral horn
Ans: E

481- Lesion of upper eyelid mostly drained by:
A- Superior Sagittal Sinus
B- Emissary Veins
C- Cavernous Sinus
D- Inferior Sagittal Sinus
Ans: C

482- Boy elevated on giving pride on speech which nucleus of thalamus involved:
A- Medial
B- Lateral
C- Dorso medial
D- Dorso posterior
Ans: C

483- Early in morning Circadian Rhythm is controlled by which of following:
A- Nerve fiber
B- Lateral Hypothalmus
C- Medial Hypothalmus
D- Suprachiastamic nucleus
Ans: D

484- A patient has increased prolactin and Bitemporal hemianopia problem will be in:
A- Thalamus
B- Hypothalamus
C- Pituitary gland
D- Cortex
Ans: C

485- Limbic system works with which for behaviour and motivation:
A- Hypothalamus
B- Thalamus
C- Internal capsule
D- Prefrontal cortex
Ans: D

486- Corneal Reflex due to cotton place in the side, is carried via:
A- Ophthalmic branch of trigeminal Nerve
B- Optic Nerve
C- Oculomotor Nerve
D- Facial Nerve
E- Maxillary branch of trigeminal nerve
Ans: A

487- Vision loss in the peripheral zone of the visual field with central sparing is often associated with the involvement of which artery in the brain?
A- Anterior cerebral artery
B- Middle cerebral artery
C- Posterior cerebral artery
D- Vertebral artery
Ans: C

488- Which fiber tract carries sensory information from the brain to the spinal cord, conveying sensations such as touch, pressure, and proprioception?
A- Mammalothalamic tract
B- Dorsal Lemniscus
C- Ventral corticospinal tract
D- Spinothalamic tract
Ans: B

489- A patient know case of hypertension and he has stroke 1 year back with vision Loss. Now his stroke and vision is Improving. Actively he had complain of Left homonymous hemianopia with left Hemi spatial neglect which part of brain is affected:
A- Right parietal and frontal area
B- Left parietal and frontal area
C- Right parietal cortex
D- Right temporal cortex
E- B/L Temporal cortex
Ans: C

490- Right Asterognosis is cause by the lesion of which area of brain?
A- Thalamus
B- Anterior part of frontal
C- Right internal capsule
D- Left internal capsule
Ans: D(No parietal in the options)

491- Chorea is caused due to lesion of:
A- Globus pallidus
B- Caudate
C- Lateral thalamic nucleus
D- Nucleus basalis
E- Dentate nucleus
Ans: B

492- A patient with Ptosis and mydriasis likely due to damage:
A- Occulomotor nerve
B- Trochlear nerve
C- Abducent nerve
D- Facial nerve
E- Maxillary nerve
Ans: A
Explanation:
- Ptosis + mydriasis – Occulomotor nerve palsy
- Ptosis + miosis – Horner syndrome.
- Ptosis + Normal Pupil – Myasthenia Gravis.

493- Patient having stiffness of neck went unconscious due to Subdural hemotoma it involves which of these?
A- Superior cerebral vein
B- Inferior cerebral vein
C- Middle cerebral vein
D- Middle meningeal artery
E- Posterior cerebral artery
Ans: A

494- Limbic system associated with:
A- Pons
B- Medulla
C- Basal ganglia
D- Whole cortex
Ans: C

495- Tremors before skilled movements is initially present on which area:
A- Thalamus
B- Midbrain
C- Hypothalamus
D- Prefrontal cortex
Ans: D

496- Which of the following is the site of fusion of binocular vision?
A- Optic chiasma
B- Lateral geniculate bodies
C- Retina
D- Visual cortex
E- Optic nerve
Ans: D

497- Patient has Loss of thirst, hunger and sexual desire, due to lesion in:
A- Basal ganglia
B- Hypothalamus
C- Cerebral cortex
D- Medulla
Ans: B

CamScanner

498- Patient has CNS symptoms and ameoorrhea. She is diagnosed as case of Prolactinoma. She has Bitemporal hemianopia which occur due to lesion of:
A- Optic chiasma
B- Optic disc
C- Lateral part of chiasma
D- Right optic nerve
E- Optic radiations
Ans: A

499- Pyramidal tract in voluntary muscle action will activate:
A- Descending fibers of corticospinal tract
B- Alpha motor neurons
C- Lower motor neuron
D- Cerebral cortex
E- Fibers ending in sensory cortex
Ans: B

500- Tractus solitarius receives afferent from?
A- VIII nerve
B- VII nerve
C- IX nerve
D- X nerve
Ans: B

501- Patient has aphasia and homonymous hemianopia. Thrombus involves which artery?
A- ACA
B- MCA
C- PCA
D- Posterior communicating artery
Ans: B

502- Motor apraxia due to lesion in:
A- Prefrontal cortex
B- Occipital lobe
C- Cerebellum
D- DCML
Ans: A

503- Flexor muscles tone is maintained by:
A- Spinothalamic tract
B- Red nucleus
C- Basal ganglia
D- DCML
Ans: B

504- Middle meningeal artery is a branch of:
A- Cerebral artery
B- Mandibular artery
C- Occipital artery
D- Temporal artery
E- Maxillary artery
Ans: E

505- Kyphosis involves which part of spinal cord?
A- Lumber
B- Thoracic
C- Cervical
D- Sacral
Ans: B

506- Man with hearing problem and was tested he can't recognize the source from which sound is coming due to defect in:
A- Superior colliculus
B- Primary auditory area
C- Associated auditory area
D- Lateral Superior olivary nucleus
E- Medial superior apex auditory area
Ans: D

507- Relay and integration of all senses in:
A- Basal ganglia
B- DCML
C- Cerebellum
D- Thalamus
Ans: D

508- A 20 Years old skateboarder hit his head on the left side. Initially alert but then became unconscious CT brain showed a crescent shaped bleed on parietal area of side what artery/vein involved?
A- Bridging vein
B- Great vein of galen.
C- Medial meningial artery
D- Basilary artery
Ans: A

509- Male had malignancy of brain 1 year back having sagging face, dropping eyelid what part of skull/cranium/ Fossa is affected?
A- Base
B- Petrosal part
C- Anterior part
D- Posterior part
Ans: B

510- A feminle presented with Weakness on right side. CT scan shows Posterior frontal parietal and Medial temporal lobe affected which artery is involved:
A- Posterior cerebral artery
B- Anterior cerebral artery
C- Middle cerebral artery
D- Posterior communicating artery
Ans: C

511- Right lower limb paralysis is caused by:
A- Left MCA
B- ACA
C- PCA
D- Communicating artery
Ans: B

512- A 35 yeu male usually goes to Dnhai and has H/O immornl sexual activities and doesn't use any protection.He has problem in walking in dark and loses balance, absent light reflex, no pain sensation, most likely diagnosis.
A- UMNL
B- Tabes dorsalis
C- LMNL
D- Syringomyclia
E- Lesion in visual cortex
Ans: B

513- Patient after RTA having urge incontinence, which region of Spinal cord is damaged:
A- Above Sacral
B- Sympathetic
C- Sacral segment
D- None
Ans: A

514- Regarding UMN lesion of facial nerve all true except:
A- Forehead spare
B- Deviation of mouth angle towaid side of lesion
C- One eye spared
D- None
Ans: C

515- Optic radiations and internal capsule are ?
A- Commisural divers
B- Projecting fibers
C- Dissociative fibers
D- Terminal fibers
Ans: B
Explanation:
Corpus callosum – Commissural fibers
Internal capsule – Projection fibers

516- A 70 ye ohl with accomodation modulation refractive error will be:
A- 2 diopter
B- 30 diopter
C- 50 diopter
D- 20 diopter
E- 59 diopter
Ans: E

517- Lesion at left optic tract resulting:
A- Blindness
B- Right homonymous hemianopia
C- Left homonymous hemianopia
D- Heteronymous hemianopia
Ans: B

518- Nerve passing through petrous part of temporal bone?
A- Abducnt
B- Occulomotr
C- Trochlear
D- Opthalmic
E- Facial
Ans: E

519- Past pointing test done tn see lesion in which of following?
A- LMN
B- Pons
C- Basal ganglia
D- Cerebellum
E- UMN
Ans: D

520- Spinal cord compression due to:
A- Osteopbytes
B- Osteoclast
C- Osteoblast
D- Osteocytes
Ans: A

521- Accessory meningeal artery passes through:
A- Foramen magnum
B- Foramen rotendum
C- Foramen ovale
D- Jugular foramen
E- Orbital fissure
Ans: C

522- Patient has lower limb paralysis and unable to recogoize objects due to damage of:
A- Left MCA
B- ACA
C- PCA
D- Communicating artery
Ans: B

523- Posrerior cerebral artery when damage causes:
A- Partial blindness.
B- Macular damage.
C- Weakness of eye muscles.
D- Homonymous hemianopia with macular sparing
Ans: D

524- A boy was playing cricket and ball bit his head after MRI of brain Flocolondular part of brain was found damaged which function will be test:
A- Memory
B- Equilibrum
C- Accomodation
D- Tone of muscles
Ans: B

CamScanner

525- A patient has uncontrollable rapid movements of hands even he can damage his hand nucleus involved is:
A- Subthalamic nucleus
B- Globus pallidus
C- Peri equiductal nucleus
D- Midbrain
Ans: A

526- Child was playing game and injured eye orbit now he is having vertical diplopia and Proptosis. Which area of orbit has beendamage?
A- Carotid cavernous fistula
B- Floor damage
C- Roof damage
D- Retro optic Hemorrhage
Ans. C

527- Corneal Reflex afferent is carried by:
A- Trigeminal
B- OpticNerve
C- OculomotorNerve
D- Facial Nerve
E- Maxillary branch of trigeminal nerve
Ans: A

528- Left arm blood supply by:
A- ACA
B- Right MCA
C- LeftMCA
D- PCA
Ans: B

529- After trauma patient has rustling sound and proptosis of eye with episcerel vessel dilation cause is?
A- Carotid cavernous fistula
B- Floor damage
C- Roof damage
D- Both roof and floor damage
Ans: A
Explanation:
- Proptosis - Roof Damage Proptosis +
- Enophthalmos- Floor Damage due to herniation of Orbital contents into maxillary antrumo
- Proptosis + Rustling sound -Carotid cavernous fistula

530- After accident change in behaviour, aggression, lost job due to damage of:
A- Thalamus
B- Midbrain
C- Prefrontal cortex
D- Medulla
Ans: C

531- Right sided spinal cord hemisection causes following defect:
A- Left sided at the level of lesion
B- Ipsilateral UMN signs
C- Same sided above level of lesion
D- Ipsilateral LMN signs below level of lesion
Ans: B
Explanation:
Hemisection of spinal cord findings
- Ipsilateral loss of all sensation at level of lesion
- Ipsilateral LMN signs (eg, flaccid paralysis) at level of lesion
- Ipsilateral UMN signs below level of lesion (due to corticospinal tract damage)
- Ipsilateral loss of proprioception vibration, light (2-point discrimination) touch, and tactile sense below level of lesion (due to dorsal column damage)
- Contralateral loss of pain, temperature, and crude (non- discriminative) touch below level of lesion (due to spinothalamic tract damage)

532- Auditory visual loss pathway involved will be:
A- DCML
B- Anterior Spinothalamic Tract
C- Olivocerebellum Tract
D- Corticospinal Tract
E- Rubrospinal Tract
Ans: C

533- Taste sensation pathway goes into thalamus then last central gyrus stop with:
A- Temp
B- Pain
C- Propioception
D- Touch
Ans: D

534- Nucleus of muscle elevating jaw:
A- Vagus nucleus
B- Trigeminal motor nucleus
C- Facial nucleus
D- Accessory nucleus
Ans: B

535- Left optic tract lesion cause vision loss of which of following?
A- Right tempral and left nasal
B- Bitemporal hemianopia with macular sparing
C- Left Nasal and right Temporal
D- Right temporal and nasal
E- Blindness
Ans: C

536- A patient after stroke develope Obesity it is caused by lesion of which part of hypothalamus?
Ventromedial nucleus
A- Lateral hypothalamus
B- Posterior hypothalamus
C- Anterior hypothalamus
D- Inferior hypothalamus
E-
Ans: A
Explanation:
- Lateral Nucleus is Feeding Centre its Damage result in Stop Feeding and makeyou Lean
- Medial Nucleus is Satiety Centre and its Damage result in Over eating and make you Massive (Obese)

537- Nerve causing gustatory lacrimation while eating is:
A- Trochlear
B- Trigeminal nerve
C- Abducent nerve
D- Vagus
E- Facial
Ans: E (BD)

538- Which of following structure passes through foramen ovale?
A- Mandibular nerve
B- Maxillary Division of trigeminal
C- Ophthalmic nerve
D- Lingual nerve
E- Accessory meningeal
Ans: E
Explanation:
- Foramen Ovale – Acessory Meningeal artery pass
- Foramen Spinosum – Middle Meningeal artery pass
- Superior Orbital Fissure – V1 (Opthalmic nerve) pass
- Foramen Rotandum – V2 (Maxillary Nerve) Pass
- Foramen Ovale – V3 (Mandibular Nerve) pass
- Jugular Foramen – CN 9, 10, 11 (Accessory part) & Sigmoid Sinus
- Hypoglossal Canal – CN 12 Foramen Magnum – Brainstem & Spinal Part of CN11

539- Regarding pituitary gland relation true is:
A- Cavernous sinus laterally
B- Optic tract laterally
C- Optic chiasma posteriorly
D- Optic nerve inferiorly
Ans: A
Explanation:
Cavernous Sinus – Laterally (Pituitary medial to it)
Sphenoid Air Sinus – Inferiorly
Optic Chiasm – Superiorly
Optic nerve – Anteriorly

540- Pars distalis is supplied by:
A- Superior hypophyseal artery
B- Inferior hypophyseal artery
C- Both
D- Internal carotid artery
Ans: A

541- Pigment in substantia nigra:
A- Melatonin
B- Neuromelanin
C- Melanocytes
D- Hemosiderin
Ans: B

542- Patient was operated for small tumor blocking the cerebral aqueduct, after ten days presented with disturbance of sleep, which nucleos is damaged:
A- Paraventricular
B- Medial thalamic
C- Suprachiasmatic
D- Ventricular
Ans: C

543- Nystygmus is causedby lesionof:
A- Flocculonodular lobe of cerebelum
B- Anterior vermis
C- Posterior vermis
D- Dentate nucleus
Ans: A

544- Cells present in damaged brain tissue after cerebrovascular accident?
A- Glial cells
B- Astrocytes
C- Oligodendrocytes
D- Ependymal cells
Ans: A

545- A few days old new born presented with abdominal distention and vomiting was diagnosed as a case Hirschsprung disease in which there is complete absence of parasympathetic ganglia. These ganglia receive preganglionic innervation from which segment of cord?
A- S1,2,3
B- S2, 3, 4
C- L2-4
D- L55-S1
Ans: B

CamScanner

546- Posterior tongue Taste sensation lost after tonsillectomy due to damage of which nerve:
A- Chorda tympani
B- Glossopharyngeal
C- Vagus
D- Trigeminal
E- Accessory
Ans: B

547- Furunculosis on tip of nose spread to cavernous sinuses via:
A- Facial veins
B- Maxillary vein
C- Emissiory veins
D- Opthalamic vein
Ans: D

548- A businessman came back after multiple trips his circadian rhythm is disturbed circadian rhythm is maintained by:
A- Nerve fiber
B- Lateral Hypothalmus
C- Medial Hypothalmus
D- Suprachiasmatic nucleus
Ans: D

549- Somatosensory fibers moving from somatosensory to parietal cortex then to frontal cortex?
A- Tocoordinate movement of hands eye and face
B- Memory of touching objects
C- Pain and temperature regulation
D- To maintain balance
Ans: A

550- Most common side of choroid plexus papilloma in children?
A- Anterior part of lateral ventricle
B- Posterior part of lateral ventricle
C- Trigone of lateral ventricle
D- 3rd ventricle
Ans: C

551- Paleospinothalamic tract carried pain By?
A- Lamina VII
B- Lamina III
C- Lamina IV
D- Lamina II, III(Substantia gelatinosa)
Ans: D

552- Patient is having restricted movement in left lateral gaze inability to close left eyes and loss of hearing of left side site of lesion?
A- Cerebro Pontine Angle
B- Cerebellopontine Angle
C- Midbrain
D- Pons
Ans: B

553- A patient presented in ER with GCS E4V3M5 12/15 which part of brain is Affected?
A- Motor cortex
B- Temporal lobe
C- Visual cortex
D- Associated visual cortex
Ans: B

554- Which tract when decebrated cause Spasticity?
A- Rubrospinal
B- Corticospinal
C- Spinothalamic
D- Olivocerebellar
Ans: B

555- Motor cerebral cortex function is
A- Voluntory control
B- Direct movement
C- Balance
D- Eyesight
Ans: B

556- A patient presented with complain of unannounced voiding. He had beta earthquake and crush injury of spinal cord. His lower limbs were parahyzed. What is your diagnosis?
A- Automatic bladder
B- Autonomous bladder
C- External sphincter damage
D- Neurogenic bladder
E- Internal sphincter damage
Ans: D

557- Rigidity is a feature of damage to?
A- Substansia nigra
B- Basal ganglia
C- Caudate
D- Putamen
E- Subthalamus
Ans: A

558- Bitemporal vision loss due to involvement of which organ?
A- Pineal gland
B- Pituitary tumor
C- Thyroid
D- Adrenal
Ans: B

559- Cranial nerve 9, 10 and 12 arise from:
A- Medulla
B- Basilar pons
C- Midbrain
D- Tegmentun
Ans: A

560- A patient presented with paralysis of B/L Lower Limbs & Lower half of face. Power 3/5 in both limbs. Homonymous hemianopia along with Lost plantar reflexes. Lesion present in which of following?
A- Basilar pons
B- Forebram
C- Midbrain
D- Medulla
E- Tegmentopontine area
Ans: B

561- Patient Lawyer is Less aggressive. Can't recall things in argument which can easily be recollected. Area of lesion?
A- Thalamus
B- Prefrontal Cortex
C- Somesthetic association area
D- Amygdala
Ans: B

562- Complete transection of spinal cord at T1 causes:
A- Permanent loss of consciousness above lesion
B- Temporary loss of conscious propioception below lesion
C- Temporary loss of voluntary movement above lesion
D- Permanent loss of voluntary movement above lesion
E- Temporary loss of stretch receptor below lesion
Ans: E

563- Patient has aphasia and upper arm weakness Thrombus involves which artery?
A- ACA
B- MCA
C- PCA
D- Posterior communicating artery
Ans: B

564- Ipsilateral occulomotor nerve palsy and contralateral corticospinal tract affected it is seen in
A- Lateral pontine syndrome
B- Medial pontine syndrome
C- Lateral medullary syndrome
D- Weber syndrome
Ans: D

565- In which brain part neural activity increases before a skilles movement
A- Precentral Cortex
B- Cerebellar cortex
C- Medulla
D- Midbrain
E- Cortical association area
Ans: B

566- Patient develop bulla on tip of nose it will spread to cavernous sinus through
A- Facial vein
B- Maxillary vein
C- Emissiory veins
D- Opthalamic vein
Ans: D

567- A person is unable to Lower his eyes. Lesion in ?
A- Pons
B- Medulla
C- Midbrain
D- Cerebellum
Ans: C

568- A man preents with parietal lobe atrophy. what will be seen
A- Contralateral Hemianesthesia
B- Loss of memory
C- Right Left Disorientation
D- Anosmia
Ans: C

569- A piano player, presents with Right or left Hemisphere lesion , which of the following will be problematic in him
A- Recent memory
B- Lost his way to home
C- Fine movements of hands
D- Difficulty in facing the crowd
Ans: C

570- A patient presented with hydrocephalus with dilated ventricles due to CSF blockage. Blood CSF barrier formed by
A- Ependymal cells
B- Endothelium
C- Glial cells
D- Astrocytes
E- Perineurium
Ans: B

571- Folia is feature of
A- Brainstem
B- Thalamus
C- Cortex
D- Cerebellum
Ans: D

572- Patient presented with dizziness and vertigo after history of fall. On CT scan subdural haemorrhage is suspected. Which of the following vessels is involved?
A- Vertebral arteries
B- Meningeal arteries
C- ACA
D- PCA
E- Cerebral veins
Ans: E

CamScanner

573- GVE of Vagas nerve:
A- Hypoglossal nucleus
B- Dorsal motor nucleus
C- Geniculate ganglion
D- Otic capsule
E- Nucleus ambiguous
Aas: B

Explanation:
Regarding Vagus nuclei
- GVA - Solitarius
- SVA - Solitarius
- GVE - Dorsal motor nucleus
- SVE - Ambigus
- GSA - Spinal nucleus of trigeminal

574- The type of neuron present in spinal sensory ganglia is ?
A- Golgi type I
B- Pseudo unipolar
C- Multipolar
D- Bipolar
E- Unipolar
Ans: B

Explanation
- Spinal Ganglia or dorsal root ganglia – Pseudo unipolar
- Skeletal Muscle – Multipolar
- Olfactory – Bipolar
- Retina and Cochlea – Bipolar

575- A patient with unable to move eye to lateral side and having contralateral hemiparesis due to lesion of
A- Cortex
B- Pons
C- Cerebellum
D- Thalamus
Ans: B

576- A newborn after 6 h of hematomatous swelling over parietal bone. What is common site for such swelling?
A- Loose areolar tissue
B- Connective tissue
C- Under skin
D- Between Skull and Periosteum
Ans: D

Explanation:
- Cephalohematoma bleed occur under periosteum
- Cephalohematom bleed most common site is over parietal bones

577- Bulb of posterior horn of lateral ventricle formed by:
A- Head of internal capsule
B- Optic radiation
C- Forceps major
D- Forceps minor
E- Pretectum
Ans: C

578- A patient present to you with both lower limb weakness and gait problem. Most commonly artery involved will be:
A- Middle cerebral artery
B- Anterior spinal artery
C- Anterior cerebral artery
D- Posterior Spinal artery
E- Posterior cerebral artery
Ans: C

579- A patient presented with swaying continuous forward & backward movement of his right arm. Which one of the following area is defected?
A- Left subthalamic
B- Right subthalamic
C- Left internal capsule
D- Left cortex
E- Caudate nucleus
Ans: A

580- Blood supply of Medulla?
A- Vertebral artery
B- Anterior Spinal artery
C- Medullary artery
D- Posterior spinal artery
Ans: B

581- Nucleus ambiguus present in
A- Pons
B- Midbrain
C- Medulla oblangata
D- Cerebellum
Ans: C

582- In an infant, when skin of the lateral border of sole of the foot is scratched with a blunt pointed object, there is:
A- Dorsiflexion of the big toe
B- Flexion at the knee
C- No response
D- Planter flexion of all the toes
E- Planter flexion of the big toe
Ans: A

583- Broca's area and wernicke area connected by
A- Pyramidal tract
B- Arcuate fasciculus
C- Midbrain
D- Angular gyrus
Ans: B

584- Patient has aphasia and upper arm weakness thrombosis involve which of following artery
A- Anterior cerebral artery
B- Posterior cerebral artery
C- Middle cerebral artery
D- Posterior communicating artery
E- Anterior communicating artery
Ans: C

585- In which brain part neural activity increases before a skills movement
A- Precentral Cortex
B- Cerebellar cortex
C- Medulla
D- Midbrain
E- Cortical association area
Ans: B

586- A patient developed sudden weakness in right upper and lower limbs and mouth deviated to left which artery is involved
A- ACA
B- MCA
C- PCA
D- Circle of Willis
Ans: B

587- Movement of brain with skull limited by
A- Falx cerebri
B- Tentorum cerebelli
C- Vessels
D- Sinus
Ans: A

588- A patient went to dental clinic for dental procedure. He was known case of MI and suddenly collapsed. CT scan brain done thrombosis involved which artery
A- Middle cerebral artery
B- Anterior communicating artery
C- Posterior cerebral artery
D- Anterior cerebral artery
E- Branches of basillar artery
Ans: A

589- Bilateral damage to hibhocampus results in
A- Disappearance of recent memories
B- Loss of working memory
C- Loss of ability to encode events of recent past in long term memory
D- Loss of all memories
Ans: C

590- A patient having resting Tremors, shuffling gait , stooped posture which area affected?
A- Globus palidus
B- Caudate and putamen
C- Lentiform nucleus
D- Lentiform + Putamen
Ans: B

591- A female presented with weakness on the right side. CT scan shows posterior frontal, parietal and medial temporal lobe affected. Which artery is involved?
A- Posterior cerebral artery
B- Middle cerebral artery
C- Anterior cerebral artery
D- Middle meningeal artery
E- Internal Carotid Artery
Ans: B
(Better statement but repeated)

592- Patient sways back and forth is having Ataxia and drunken gate where does neuron synapses in cerebellum and affected
A- Flucoborular lobe
B- Fastigial nucleus
C- Red Nucleus
D- Cerebellar vermis
Ans: D

Explanation:
Vermis lesion
- Anterior vermis lesions are usually the result of degeneration from alcohol abuse and are present with gait ataxia.
- Posterior vermis lesions result from medulloblastomas or ependymomas and present with truncal ataxia (Drunken Sailor gate)

593- Before voluntary movement, the image is formed in which area of brain?
A- Anterior part of premotor area
B- Posterior part of pre motor area
C- Primary motor area
D- Somatosensory Area
E- Prefrontal Cortex
Ans: A

Better statement

594- Tract actively & functionally associated with Lateral spinothalamic tract is:
A- Corticospinal Tract
B- Rubrospinal Tract
C- Cuneocerebellar Tract
D- Vestibulospinal Tract
E- Spinothalamic Tract
Ans: B

595- Bitemporal hemianopia is caused by lesion of:
A- Lower optic chiasma
B- Middle optic chiasma
C- Upper optic chiasma
D- Optic nerve
E- Optic tract
Ans: B

CamScanner

596- Folia is feature of
A- Brainstem
B- Thalamus
C- Cortex
D- Cerebellum
Ans: D

597- Autonomic nervous system is controlled by:
A- Thalamus
B- Hypothalamus
C- Internal capsule
D- Pituitary gland
Ans: B

598- Loss of two point discrimination after RTA due to:
A- Lateral Column
B- Lateral Inhibition
C- Posterior inhibition
D- Field Blockage
E- PostSynaptic Inhibition
Ans: B

599- 55 years old female taking phenithiazine was observed to have slow flying movement in an attempt to remove a fly resting on her nose. This is mostly likely due to
A- Parkinsonism
B- Athetosis
C- Ballismus
D- Hemiballismus
Ans: B

600- A patient has loss of fine touch, pressure, proprioception with intact pain temperature sensation in lower limbs related to
A- Fasciculus gracilus
B- Fasciculus cuneatus
C- Anterior spinothalamic
D- Lateral Spinothalamic
Ans: A

601- Female present with weakness in legs. upon CT Bilateral lesions in Forebrain, tract involved will be:
A- Rubrospinal tract
B- Corticospinal tract
C- Spinothalamic tract
D- Lateral vestibular tract
Ans: B

602- CSF drainage takes place via:
A- Diploic Veins
B- Dural Venous Sinuses
C- Emissary Veins
D- Cavernous Sinus
E- Petrosal Venous sinus
Ans: B

603- A patient present with wittle gait, dysdiadochokinesia Ataxia on both closing eyes and open eyes, patient sway with open eyes and eyes closed lesion in:
A- Cerebellum
B- Cerebellar peduncle
C- Demi tract
D- Left internal capsule
E- Cortex
Ans: A
Explanation:
- Patient fall on Close eye only(Positive Romberg) – DCML lesion
- Patient fall on open and close eye – Cerebellum lesion

604- Patient has a tumor which causes Amnesia but he remembers Youth time memories. Brain region likely involved:
A- Hippocampus
B- Amygdala
C- Hypothalamus
D- Basal ganglia
Ans: A

605- Processes visual information and sends signals to the muscles controlling eye movements, enabling:
A- Oculomotor loop
B- Association loop
C- Limbic loop
D- Papez circuit
Ans: A

606 A patient has hyperphagia & Obesity due to lesion of which part of hypothalamus?
A- Ventromedial nucleus
B- Lateral hypothalamus
C- Posterior hypothalamus
D- Anterior hypothalamus
E- Inferior hypothalamus
Ans: A
Explanation:
- Lateral Nucleus is Feeding Centre its Damage result in Stop Feeding and make you Lean
- Medial Nucleus is Satiety Centre and its Damage result in Over eating and make you Massive (Obese)

607- Nystagmus is due to lesion in:
A- Vennis
B- Cerebellar peduncle
C- Cerebellum
D- Substania nigra
Ans: B

608- Patient with TB after 15ml of spinal tap develops headache. Cause is
A- Stretch of dura artery
B- Stretch of falx cerebri
C- Stretch of tentorium cerebelli
D- Stretch of sinuses
Ans: B

609- Which of the following arteries is primarily involved in supplying the thalamus, epithalamus, subthalamus, and hypothalamus?
A- Anterior Communicating Artery
B- Posterior Communicating Artery
C- Medial Striate Artery
D- Middle Cerebral Artery
E- Internal carotid artery
Ans: B

610- A patient presented with wide gait, dysdiadochokinesia, ataxia on both closing eyes and open eyes, patient sway with open eyes and eyes closed, lesion:
A- Cerebellum
B- Cerebellar peduncle
C- Demi tract
D- Left internal capsule
E- Cortex
Ans: A

611- To anesthetize a limb, which part of the spinal cord is typically targeted for drug injection?
A- Ventral substantia gelatinosa
B- Dorsal substantia gelatinosa
C- Ventral horn
D- Lateral column
Ans: B

612- Which of the following statements is true about the primary motor cortex?
A- It is found only in the frontal lobe
B- It receives sensory input
C- It is involved in sensory processing
D- It is found only in the parietal lobe
Ans: A

613- A dancer moves smoothly and rhythmically in sync with the music. Which function of the motor cortex is primarily responsible for this performance?
A- Integration of sensory information
B- Planning and execution of movement
C- Coordination of balance
D- Maintenance of muscle tone
E- Regulation of reflexes
Ans: B

614- Major input to motor cortex:
A- Ventromedial nucleus of thalamus
B- Ventrolateral nucleus of thalamus
C- Caudate
D- Globuspalidus
E- Substantia nigra
Ans: B

615- A dancer moves smoothly and rhythmically in sync with the music. Which function of the motor cortex is primarily responsible for this performance?
A- Integration of sensory information
B- Planning and execution of movement
C- Coordination of balance
D- Maintenance of muscle tone
E- Regulation of reflexes
Ans: B

616- True Regarding "Primary motor cortex":
A- Doesnot receive sensory input
B- Receives sensory input and gives motor response accordingly
C- Is present only in Frontal lobe
D- Doesnot Control Fine Motor movements
E- Is involved in coordination of the Motor response for smoother Response
Ans: B

617- A Pain had Pain on doing Excessive movement of His right arm) Doctor Diagnosed him as a case of "SUBCLAVIAN STEAL SYNDROME". Which of the following Arteries' Blood supply is probably stolen in this syndrome?
A- External carotid
B- Internal carotid
C- Thyrocervical trunk
D- Vertebral artery
E- Cerebral artery
Ans: D

618- Structure immediately above subarachnoid space during Lumbar puncture:
A- Epidural
B- Arachnoid
C- Dural
D- Subarachnoid
E- Skin
Ans: B

CamScanner

619- A patient presented with Expressionless face & Ataxia Examination reveals rigidity Damage to:
A- Caudate & Putamen
B- Globus Pallidus Externa
C- Globus Palludus Interna
D- Subtbalamus
Ans: A

620- In Right astereognosis involved brain area is:
A- Left internal capsule
B- Right internal capsule
C- Pons
D- Posterior occipital Lobe
F- Cerebral cortex
Ans: A

621- After Rta patient presents with loss of light touch and pressure in Lower Leg) No other sensory or motor loss) Surgeon orders mri because he is suspecting damage of?
A- Anterior spino thalmic tract
B- Lateral spinothalamic Tract
C- Fasciculus Cuneatus
D- Fasciculus Gracilis
Ans: A

622- A Lady who is always crying & sometimes have Uncontrolled laugh She is socialy isolated, Depressed & has recurrent Mood changes.Defect lies in:
A- Left Frontal Cortex
B- Right Frontal Cortex
C- Cingulate gyrus
D- Amygdala
E- Papez Circuit
Ans: E

623- Which of them is a higher Intellectual sensory area?
A- Wernicke's area
B- Broca's area
C- Somatosensory association area
D- Angular Gyrus
Ans: A

624- A patient blind foldedly asks to identify the structure in hand. Which area assessment is being done?(better)
A- Superior parietal lobe
B- Inferior parietal lobe
C- Temporal lobe
D- Pre-central cortex
E- Frontal Lobe
Ans: A (Snell Neuroanatomy)

Explanatinn:
- Lesions of the "superior parietal lobule" interfiere with the patient's ability to combine touch, pressure, and proprioceptive impulses, so he or she is unable to appreciate texture, size, and form. This loss of integration of sensory impulses is called astereognosis. For example, with the eyes closed, the individual would be unable to recognize a key placed in the hand

625- A Lady who is always crying & sometimes have Uncontrolled laugh She is socially isolated. Depressed & has recurrent Mood changes. Defect lies in:
A- Left Frontal Cortex
B- Right Frontal Cortex
C- Cingulate gyrus
D- Amygdala
E- PapezCircuit
Ans: E

626- Which thalamic nucleus receives relay sensation of taste and facial sensation?
A- Ventro Postero Lateral Nucleus (VPLN)
B- Ventro posterior medial Nucleus(VPMN)
C- Ventro Lateral Nucleus
D- Ventro Medial Nucleus
E- Lateral geniculate Nucleus
Ans: B

627- Patient hypertensive hyperlipidemic bent to pick up something that fell down. His vision got blurred along with diplopia. There is no history of Unconsciousness or Focal neurological deficit. He got recovered after sometime. Which artery is involved?
A- Posterior Cerebral Artery
B- Anterior Cerebral Artery
C- Middle Cerebral Artery
D- Anterior choroidal Artery
Ans: A

628- A patient presents with right sided hemiparesis & Tongue deviated Ipsilaterally. There is ipsilateral loss of proprioception as well. Which artery is most likely affected?
A- Posterior Inferior Cerebellar Artery(PICA)
B- Vertebral Artery
C- Basilar Artery
D- Superior cerebellar
Ans: B(Medial Medullary Syndrome)

629- A patient presented with History of Unable To walk & lift objects. CT scan reveals areas of infarct in posterior aspect of parietal, frontal and Temporal lobes. Which vessel is compromised in this case?
A- Anterior Cerebral Artery
B- Middle Cerebral Artery
C- Posterior Cerebral Artery
D- Posterior communicating artery
E- Anterior Communicating Artery
Ans: B

630- Patient has difficulty in unable to comprehend language and intelligence. Where is the lesion?
A- Primary Prefrontal cortex
B- Broca
C- Wernicke
D- Premotor Area
Ans: C

631- Hemisection of Spinal Cord. What will be lost contralaterally below the level of Lesion?
A- Pain
B- Fine Touch
C- Vibration
D- Proprioception
E- Ptessure
Ans: A

Explanation:
Hemisection of spinal cord findings
- Ipsilateral loss of all sensation at level of lesion
- Ipsilateral LMN signs (eg, flaccid paralysis) at level of lesion
- Ipsilateral UMN signs below level of lesion (due to corticospinal tract damage)
- Ipsilateral loss of proprioception, vibration, light (2-point discrimination) touch, and
- tactile sense below level of lesion (due to dorsal column damage)
- Contralateral loss of pain, temperature, and crude (non-discriminative) touch below level of lesion (due to spinothalamic tract damage)
- A lesion(hemesection) of spinal cord, what is lost below the level of lesion on contralateral side

632- A set of muscles innervated by corticospinal tract. Cerebral cortex gets feedback from:
A- Muscle spindle of antagonist
B- Red Nucleus
C- Golgi tendon organ
D- Fastigial Nucleus
E- Tactile Response from free nerve endings on fingers holding the object
Ans: E

633- Patient can't raise eyelid perhaps, nerve lesion arisiug front
A- Midbrain
B- Pons
C- Medulla
D- Cerebellum
E- Cerebrum
Ans: A

634- A patient present in Emergency department On examination there was loss of pain and temperature on left side and loss of touch and vibration sensarion on right side which of the following is ur diagnosis
A- Hemisectioo of right side of spinal card
B- Hemisection of left spinal card
C- Compelete card sectioo
D- Brown sequard syndrome
E- Syrinomyelia
Ans: A

Explanation:
Hemisection of spinal cord findings
Ipsilateral loss of all sensation at level of lesion
- Ipsilateral LMN signs (eg, flaccid paralysis) at level of lesion
- Ipsilateral UMN signs below level of lesion (due to corticospinal tract damage)
- Ipsilateral loss of proprioception, vibration, light (2-point discrimination. touch, and tactile sense below level of lesion (due to dorsal column damage)
- Contralateral loss of pain, temperature, and crude (non-discriminative) touch below level of lesion (due to spinothalamic tract damage)

635- Patient present with hypertbermia On CT scan there was space occupyiog lesion with compressing the
A- Hypothalamus
B- Thalamus
C- Amygdala
D- Hippocampus
Ans: A

636- Patient presented with dysartbria, dysmetria, dysphagia & Left tbermoanesthesia of the Face. O/E: Ptosis & Weakness in Right Upper & Lower Limb. Most suitable diagnosis?
A- Wallenberg syndrome of Left Side
B- Right Sided Lateral Medullary Syndrome
C- Weber Syndrome
D- Section of Ventral root
Ans: B(Snell Neuroanatomy

CamScanner

Explanation:
Lateral Medullary Syndrome of Walleoberg:

- The lateral part of the medulla oblongata is supplied by the posterior inferior cerebellar artery, which is usually a branch of the vertebral artery.
- Thrombosis of either of these arteries produces the following signs and symptoms.
- Dysphagia and dysarthria due to paralysis of the ipsilateral palatal and laryngeal muscles (innervated by the nucleus ambiguus);
- Analgesia & thermoanesthesia on the ipsilateral side of the face (nucleus and spinal tract of the trigeminal nerve);
- Vertigo, nausea, vomiting, and nystagmus (vestibular nuclei);
- Ipsilateral Horner syndrome (descending sympathetic fibers);
- Ipsilateral Cerebellar Signs. gait and limb ataxia (cerebellum or inferior cerebellar peduncle)
- contralateral loss of sensations of pain and temperature (spinothalamic tract)

637- Anterior attachment of falx cerebri is interrupted by:
A- Crista galli
B- Ethmoid part of frontal bone
C- Temporal part of sphenoid
D- Tentorium cerebelli.
Ans: A(Snell)

Explanation:
- The falx cerebri is a large, sickle- shaped fold of dura mater that lies in the midline between the two cerebral hemispheres
- Its narrow anterior end attaches to the internal frontal crest and the crista galli.
- Its broad posterior part blends in the midline with the upper surface of the tentorium cerebelli.

638. Cavernous Sinus thrombosis will lead to involvement of which nerves?
A- Oculomotor, Trochlear & Abducent Nerve
B- Oculomotor, Ophthalmic & Abducent Nerve
C- Trochlear, Abducent & Optic nerve
D- Oculomotor, Facial & Optic Nerve
Ans: A(KLM +Snell)

Explanation:
The contents of the cavernous sinus include:
- The internal carotid artery and the abducens nerve (cranial nerve VI) which travel through it
- In the lateral wall, cranial nerves III and IV and the ophthalmic and maxillary divisions of cranial nerve V.
- The pituitary gland, which lies medially in the sella turcica.
- The veins of the face, which are connected with the cavernous sinus via the facial vein and superior ophthalmic vein, are an important route for the spread of infection from the face
- The superior and inferior petrosal sinuses

639- A patient known case of Hypertension presents with a stroke and, upon examination, exhibits spastic paralysis in the lower limb with a positive Babinski sign. Where do the nerve fibers of the involved tract decussate?
A- Medulla
B- Midbrain
C- Pons
D- Cerebal Cortex
E- Spinal Cord
Ans: A

640- Man after stroke has issues with phonation and unable to repeat words. Lesion in:
A- Motor cortex
B- Temporal area
C- Wernicke's area
D- Transcortical area
Ans: C

641- What is the function of the pyramidal cells of the medulla?
A- Control of voluntary movements
B- Balancing
C- Sense of taste and smell
D- Respiratory Function
Ans: A

642- Boxer got jaw-jacked,now he can't close his jaw and on examination gag reflex is absent. Which of the following is nerve is involved
A- Mesancephalic nucleus of Trigeminal Nerve
B- Hypoglossal Nerve
C- Facial Nerve
D- Glossopharyngeal Nerve
E- Occulomotor nerve
Ans: A
Better

643- Which one of the following has large receptive field
A- Dorsal Column
B- Spinothalamic Tract
C- Medial Lemniscus
D- Nucleus gracillus
E- Posterior medial nucleus of thalamus
Ans: B

644- ACA supplies
A- Secondary somesthetic area
B- Motor Area
C- Premotor Cortex
D- Temporal Cortex
E- Somesthetic Association cortex
Ans: A

645- Which of the following is the nucleus of upper medulla?
A- Vesubulocochlear nucleus
B- Nucleus Ambigous
C- Dorsal Nucleus of vagus
D- Inferior Olivary Nucleus
Ans: A

Explanation:
Upper Medulla:
- Vestibular cochlear
- Inferior olivary
- Spinal trigeminal

Middle Medulla:
- Nucleus ambiguas
- Hypoglosal Nucleus
- Dorsal motor Nucleus Vagus
- Spinal Trigeminal

Lower Medulla:
- Hypoglosal Nucleus
- Dorsal Motor Nucleus Vagus
- Spinal Trigeminal

646- Area supplied by ACA:
A- Broca's Area
B- Premotor Area
C- Primary Visual Area
D- Insular cortex
Ans: B

647- A man with presented stroke. ACA is affected; ACA supply which of the following areas of brain
A- Somatosensory Area
B- Brocas Area
C- Occipital Area
D- Premotor area
E- Angular gyrus
Ans: A

648- A group of men faced some blizzard, in cold temp on returning to base camp Adapt to cold weather by heat generation due to which of Following
A- Anterior hypothalamus
B- Posterior hypothalamus
C- Lateral hypothalamus
D- Medial hypothalamus
E- Thalamus
Ans: B

Explanation:
- Posterior Hypothalamus activated Via Cold temp and activate Sympathetic which will increase Heating.
- Anterior Hypothalamus activated via hot temp and activate parasympathetic and will increase Cooling.
- Overall Temperature regulation – Preoptic Nucleus >Anterior Hypothalamus

649- Taste fibers from the tongue are transmitted to the cortex via which structure?(Medicine Feb 2025)
A- CI cervical spinal nerve
B- VPM nucleus of Thalamus
C- Internal capsule
D- Hippocampus
Ans: B

650- Patient is unable to retain long term memory due to damage in which area of brain (Medicine Feb 2025)
A- Arcuate
B- Amygdala
C- Hipocampus
D- Frontal lobe
E- Temporal lobe
Ans: C

651- Patient has aphasia and upper arm weakness thrombosis involve which of following artery (Medicine Feb 2025)
A- Anterior cerebral artery
B- Posterior cerebral artery
C- Middle cerebral artery
D- Posterior communicating artery
E- Anterior communicating artery
Ans: C

652- A 65 year old male presents to the ER department with sudden onset dizziness, difficulty swallowing, hoarseness of voice and right sided facial numbness, he reports that these symptoms started after waking up in the morning he also reports of double vision. Most probable diagnosis: (Medicine Feb 2025)
A- Right lateral medullary syndrome
B- Left lateral medullary syndrome
C- Right medial medullary syndrome
D- Left medial medullary syndrome
Ans: A

Explanation:
- This is the case of Lateral Medullary (Wallenberg) Syndrome that's caused by occlusion of PICA (Posterior inferior Cerebellar Artery) & leads to Vomiting, vertigo, nystagmus, Decrease Pain and temperature sensation from ipsilateral face and contralateral body, dysphagia, hoarseness, decrease gag reflex, ipsilateral horner syndrome, ataxia and dysmetria

CamScanner

653- A known case of diabetes patient presented with Ptosis,dilated pupil and non-reartive to light which artery aneurysm cause this condition? Medicine Feb 2025)

A- Anterior communicating
B- Posterior communicating
C- ACA
D. MCA
Ans: B

Explanation:

- ACom --- Compression of bitemporal hemianopia (compression of optic chiasm); visual acuity deficits; rupture Z ischemia in ACA distribution Z contralateral lower extremity hemiparesis, sensory deficits.
- MCA – Rupture and ischemia in MCA distribution Z contralateral upper extremity and lower facial hemiparesis, sensory deficits.
- PCom – Compression ipsilaterel CN III palsy mydriasis (blown pupil. may also see ptosis, down and out eye

654- A Dubai businessman daily go to office in morning and sleep early at night Melatonin and ACTH are involved in circadian rhythms. Which part is responsible for regulating circadian rhythms and sleep awake cycle? (Surgery Feb 2025)

A- Supraoptic nucleus
B- Pie optic nucleus
C- Suprachaismatic nucleus
D- Para optic nucleus
Ans: C

655- In decrebrate animal which of the following is effected(Surgery Feb 2025)

A- Red nucleus
B- Cortex
C- Thalamus
D- Basal gangiia
Ans: A

656- Injury to to Bilateral hippocampus causes:

A- Loss of taste
B- Homonymous hemianopia
C- Loss of smell
D- Amnesia
E- Aphasia
Ans: D

657- Right sided Loss of touch but pain and temperature intact. Lesion of which tract? (Surgery Feb 2025)

A- Left DCML
B- Left anterolateral
C- Right anterolateral
D- Right DCML
Ans: A

Explanation:

Ascending Pathways and Sensations

Ascending pathways	Sensation
Lateral spinothalamic tract	Pain and temperature
Anterior spinothalamic tract	Slight touch and pressure
Gracile and cuneate fasciculi medial lemniscus	Discriminatory touch, vibratory sensitivity, conscious sensation of muscles and joints
Anterior and posterior spinocerebellar tract	Musculo-articular unconscious sensation

658- A patient presents with nystagmus on rightward gaze, and a left eye does not move inward on right gaze. Where is the lesion? (Gynae & Obs Feb 2025)

A- Right MLF
B- Left MLF
C- Right oculomotor nerve
D- Frontal eye field lesion
Ans: B

659- Which neural tract conveys proprioceptive information from the upper limb to the cerebellum?(Radiology Feb 2025)

A- Cuneocerebellar tract
B- Dorsal spinocerebellar tract
C- Ventral spinocerebellar tract
D- Spinothalamic tract
E- Corticospinal tract
Ans: A

660- A left-handed person presents with an inability to write, understand words, and difficulty identifying the left side. Which brain region is most likely affected?(Radiology Feb 2025)

A- Left frontal lobe
B- Right parietal lobe
C- Left temporal lobe
D- Right temporal lobe
E- Left parietal lobe
Ans: E

661- Vomiting centre located in:(Anesthesia Feb 2025)

A- Pons
B- Midbrain & Hypothalamus
C- Midbrain
D- Cerebellum
Ans: B

662- A patient presented with analgesia and thermoanesthesia of right side of face and weakness of left side of body, where is the disease? (Anesthesia Feb 2025)

A- Wallenberg syndrome of left side
B- Lateral medullary syndrome of right side
C- Medial medullary syndrome
D- Pontine Lesion
Ans: A

663- A Security guard got gun-shot injury on lower back. After physiotherapy and rehabilitation he had lost contralateral Pain temp below the level of lesion and ipsilateral Paralysis. What is the diagnosis?(Medicine Feb 2025)

A- Damaged 1stdosral root
B- Damaged ventral root
C- Brown sequard syndrome
D- Spinal Shock
E- Syringomyelia
Ans: C

Explanation:

Hemisection of spinal cord Findings:

- **Ipsilateral** loss of all sensation at the level of the lesion.
- **Ipsilateral LMN signs** (e.g., flaccid paralysis) at the level of the lesion.
- **Ipsilateral UMN signs** below the level of the lesion (due to corticospinal tract damage).
- **Ipsilateral loss of proprioception, vibration, and fine (2-point discrimination) touch** below the level of the lesion (due to dorsal column damage).
- **Contralateral loss of pain, temperature, and crude (non-discriminative) touch** below the level of the lesion (due to spinothalamic tract damage).
- If the lesion occurs above T1, the patient may present with **ipsilateral Horner syndrome** due to damage of the oculosympathetic pathway.

664- Elder patient has head injury due to fall. He cant recall past memory due to damage of: (Medicine Feb 2025)

A- Parietal lobe
B- Temporal lobe
C- Occipital lobe
D- Frontal lobe
Ans: B

665- A patient presents with an inability to close the eyelid, ptosis with constricted pupils, deviation of the mouth to the right side, and difficulty drinking water, with water leaking from the mouth. Where is the lesion most likely located? (Medicine Feb 2025)

A- Midbrain
B- Pons
C- CN III damage
D- Edinger-Westphal nucleus
Ans: B

666- A patient presents with right-sided hemiplegia, astereognosis, and loss of vibration and proprioception. Which part of the nervous system is most likely affected? (Medicine Feb 2025)

A- Right internal capsule
B- Left internal capsule
C- Anterior frontal
D- Left occipital
E- Pons
Ans: B (No option of parietal lobe)

667- A patient presented with history of Trauma to ER. Blood accumulated between Dura & Skull. Bleeding artery is a branch of(Medicine Feb 2025)

A- Maxillary artery
B- Ophthalmic artery
C- Mandibular Artery
D- Facial Artery
Ans: A

668- Partial nasal hemianopia is caused by damage to which structure?(Medicine Feb 2025)

A- Optic nerve
B- Lateral optic chiasm
C- Optic tract
D- Lateral Geniculate Body
Ans: B

669- Damage to the anterior spinal artery typically affects multiple spinal cord tracts. Which tract is spared? (Medicine Feb 2025)

A- Corticospinal tract
B- Spinothalamic tract
C- Dorsal column (Posterior column)
D- Spinocerebellar tract
Ans: D

670- A 30-year-old male is involved in a high-speed road traffic accident (RTA) and is rushed to the hospital. Despite the absence of external signs of head injury, including no lacerations or fractures, the patient remains unconscious and is later diagnosed to be in a vegetative state. What is the most likely cause of the patient's condition?(Medicine Feb 2025)

A- Diffuse axonal injury
B- Epidural hematoma
C- Cerebral contusion
D- Subarachnoid hemorrhage
Ans: A

CamScanner

671- A patient presents with blurring of vision and a history of repeated accidents, stating that they are unable to see vehicles approaching from the left side of the road. Which of the following is the most likely site of the lesion? (Medicine Feb 2025)
A- Opticradiations
B- Opticnerve
C- Visual cortex
D- Lateral geniculate body
E- Optic chiasma
Ans: A

672- A child is born 2 days ago, her mother took her due to the complaint of unconsolable cry since birth. On examination child has developed papiloedema , patient has developed acutely (Gynae Feb 2025)
A- Hydrocephalus
B- Kernicterus
C- Meningitis
D- Dual sinus blockage
E- Involvemeeto of cerebral vessels
Ans: A

673- A patient is having decreased sensations & weakness in Left Lower leg and foot. Artery involved? (Gynae Feb 2025)
A- AnteriorCerebral Artery
B- Posterior Cerebral Artery
C- Internal carotid Artery
D- Middle Cerebral Artery
E- Anterior Choroidal Artery
Ans: A

674- If the aqueduct of sylvius is blocked, which of the following would be dilated first (Gynae Feb 2025)
A- Lateral ventricles
B- 3rd ventricle
C- 4rth ventricle
D- Subarchnoid space
E- Dual venous sinuses
Ans: B

675- A 2 year old child presents with jerking movemeats of right upper and lower limbs. which of the following neurodevelopmental disorder most likely he has?(Gynae & Obs Feb 2025)
A- Neuronal degeneration
B- Neural crest cells defect
C- Neural tube defect
D- Corticospinal tract defect
Ans: D

676- A 30-year-old man presents with enlarged jerky writhing movements. Ataxic gait and spasms. His father died at age 50 from the same disease. Where is the lesion most likely located? (Gynae Feb 2025)
A- Cortex
B- Substantia nigra
C- Corpus Striatum
D- Caudate+Lenuform Nucleus
E- Caudate+Putamen
Ans: D

677- Man cannot string words together but can understand canse is (Gynae Feb 2025)
A- Broca's aphasia
B- Wernicke's aphasia
C- Conduction aphasia
D- Anomic Aphasia
Ans: A

678- A patient presents with blindness on laboratory findings prolactin levels were increased which of the following is likely etiology of his condition (Gynae Feb 2025)
A- Pituitary adenoma
B- Hypothalmic lesion
C- Glucoma
D- Cairact
E- chlamydial infection
Ans: A

679- A pntient present with headache. On examination there is an hepatospeenomegaly ,an lymphadenopathy on brain MRI lesion present just left to midline diagoosis of Large b cell lymphoma is made what else will be present in laboratory findings(Radiology Feb 2025)
A- Absolute lymphocytosis
B- HIV RNA undetected
C- HIV RNA 8000 copies
D- Diffuse lymphoma resistant to teryarate
Ans: C

680- Patient with lesion in brain, presented with Resting tremor, stooped posture, shuffling gait, cogwheel rigidity and expressionless face, Lesion in which part of brain: (Radiolngy Fch 2025)
A- Cerebrum
B- Cerebellum
C- Substamia nigra
D- Pons
E- Medulla
Ans: C(Parkinsonism)
Better

681- Patient can utter wurds but no complete sentences, not obeying commands and understands. lesium in? (Radiology Feb 2025)
A- Broca's
B- Wernicke's
C- Conduction aphasia
D- Global aphasia
Ans: B

682- A 50 years old patient presented with morning headache, nnusea, tumor arising from external granular layer of cerebellar cortex is?(Anesthesia Feb 2025)
A- Ependymoma
B- Medulloblastoma
C- Glioma
D- Can't remember
Ans: B

683- Left sided facial paralysis and right sided body paralysis lesion location in(Anesthesia Feb 2025)
A- Brainstem
B- Cerebral cortex
C- Basal ganglia
D- Internal capsule
Ans: A

Explanation:
Uncrossed hemiplegia
- h refers to contralateral hemiplegia + contralateral cramal nerve palsy (facial nerve)
- It resuhs from lesion above the brainstem like cerebral cortex or inrcmal capsule

Crossed hemiplegia
- h refers to contralateral hemiplegia + ipsilateral cranial nerve palsy(facial nerve)
- h resuhs from the lesions of the brain stemlike midbrain, pons, medulla

684- A patient presented with seizures ,tongue movements ,smacking of lips,headaches and muscle movements. His grandfather also had the same disease, where is the lesion? (Anesthesia Feb 2025)
A- Caudate
B- Substania nigra
C- Cerebellum
D- Frontal Lobe
Ans: A

685- What forms the roof of anterior part of lateral ventricles? (Anesthesia Feb 2025)
A- upper surface of thalamus
B- genu of corpus callosum
C- Body of corpus callosum
D- Cerebral Cortex
Ans: B

686- A patient presents with difficulty in phonation. Which brain area is most likely involved?"(Anesthesia Feb 2025)
A- Motor cortex
B- Posterior lateral prefrontal cortex
C- Inferior temporal gyrus
D- Subfrontal region
Ans: A

687- The internal capsule is composed of which of the following?"(Anesthesia Feb 2025)
A- Gray matter
B- Whitematter
C- Astrocytes
D- Oligodendrocytes
E- Ependymal cells
Ans: B

CamScanner

MICROBIOLOGY

Microbiology Quick Hints

Bacteriology

- ✓ Gram positive differ from negative by periplasmic space and cell wall composition
- ✓ Gram negative bacteria such as shigella have endotoxin in their- outer layer of cell wall
- ✓ Nisseria attaches to Endothelial cells by– Pillus
- ✓ Nisseri a cause Symtoms by – Endotoxin
- ✓ Pseudomonas commonly produce – Exotoxin
- ✓ Pseudomonas Cause fever and Hypotension – Endotoxin
- ✓ Pseudomonas cause fever by Cytokine – TNF >IL1
- ✓ Over All Fever – IL 1>TNF
- ✓ Group A streptococal pyogen cause Scarlet fever
- ✓ Group B is Streptococcus agalactiae
- ✓ C Tetani -Produce tetanospasmin A cause tetanus + Spastic paralysis. Tetanus toxin is Exotoxin> neurotoxin
- ✓ C Botulinum -Floppy baby , Flacid paralysis dysarthria and dyspbagia +Death due to food poisning
- ✓ C perfringes -Gas gangreen
- ✓ Clostridioides difficile -Produces toxins A and B, which damage enterocytes. Both toxins lead to watery diarrhea -pseudomembranous colitis
- ✓ Cornybacterium diptheria has lethal effect on Heart
- ✓ Actinomyces diagnosed by Granuloma and abscess and produce yellow sulphur granules
- ✓ Nocardia cause pulmonary infection and brain abscesses
- ✓ Leprosy diagnosed by nasal scraping
- ✓ Vibrio cholera cause diarrhea by Increase Cl secretion and Act by CAMP +Dearb due to diarrhea
- ✓ Rickettsia and mycoplasma differ by Giemsa stain
- ✓ Q fever by Coxiella burnetti
- ✓ STD by– Chlymydia > Gonorrhea > Syphlis
- ✓ Tubuovarian mass – Gonorrhea
- ✓ Honeymoon Cystitis – E. coli
- ✓ B cereus is due to Reheated rice
- ✓ C perfringens due to Reheated meat
- ✓ E coli O157:H7 due to Undercooked meat
- ✓ Proteus mirabilis Motility causes "swarming" on agar; associated with struvite stones. Produces urease

Syphlis

- ✓ Primary syphilis -Painless chancre (Treponema pallidum)
- ✓ Secondary syphilis - Fever, lymphadenopathy, skin rashes, condylomata lata + it can also has Painless ulcer in 15% cases
- ✓ Tertiary syphilis- Gummas, tabes dorsalis, general paresis, aortitis, Argyll Robertson pupil

Chlymydia

Types A-C

- ✓ Chronic infection and blindness

Types D–K

- ✓ Urethritis/PID
- ✓ Ectopic pregnancy,
- ✓ Neonatal pneumonia (staccato cough) with eosinophilia
- ✓ Neonatal conjunctivitis (1-2 weeks after birth)

Tybe L1-L3

- ✓ Lymphogranuloma venercum

E coli

Enterohemorrhagic E. coli

- Invade intestinal mucosa (Necrosis and Inflammation)

CamScanner

- Produce Heat Labile and Heat Stable Enterotoxin (No inflammation or invasion)
- Cause Travelor's Diarrhea

Entero Hemorrhagic E coli

- O157:H7 is most common form
- Cause dysentry (Inflammation and necrosis)
- Shiga like toxin cause HUS(Anemia + Thrombocytopenia +AKI)
- Cause mechanical hemolysis (Schisocytes on peripheral smear)
- Do not ferment sorbitol (Other E coli Do)

Entero Pathogenic E. coli

- Attach to apical surface filanen villi impair absorption
- Cause diarrhea in pediatric

Mycology

Mucor and Rhizopus

- Diabetic (DKA) and Neutropenic (Leukemia)
- Rhinosinusitis
- Non septate hyphae branch at wide angle
- Invade blood vessel

Aspergillus

- Nondiabetic
- Immuno compromised and neutrophilic dysfunction (CGD)
- Rhinosinusitis
- Septate hyphae branch at acute angle

Candida

- Diamorphic
- Pseudohyphae

Cryptococcus

- Not Diamorphic
- 5-10 um narrow budding
- Brain meningitis and Encephalitis(Soap bubble lesion) in immunocompromised

Histoplasmosis

- Reticulocndothelial System involve

Parasitology

- ✓ Giardia lamlia cause fatty diarrhea
- ✓ Entamoeba cause Liver abscess and Anchovy paste exudate
- ✓ Cryptosporidium cause diarrhea in AIDS
- ✓ Cryptococus neoformis cause Meningitis in AIDS
- ✓ Naegleria fowleri Rapidly fatal meningoencephalitis(Brain eating parasite)
- ✓ Congenital toxoplasmosis: classic triad of chorioretinitis, hydrocephalus, and intracranial calcifications Mononucleosis like symptoms with -ve Heterophil antibody test
- ✓ Trypanosoma brucei -African sleeping sickness(Tsetse fly)
- ✓ Trypanosoma cruzi -Chagas disease---dilated cardiomyopathy with apical atrophy, megacolon, megaesophagus(kissing bug)
- ✓ Visceral leishmaniasis (kala-azar)--spiking fevers, hepatosplenomegaly, pancytopenia
- ✓ Cutaneous leishmaniasis—skin ulcers
- ✓ Trichomonas vaginalis -Vaginitis—foul-smelling, greenish discharg
- ✓ Rectal Prolapse – Trichuris Trichura
- ✓ Muscle(Myalgia) – Trichinella Spiralis
- ✓ Respiratory Symptoms – Ascaris
- ✓ Fisherman With Anemia + Echymosis -- Vitamic C deficiency
- ✓ Fisherman With Anemia + Raised MCV – B12 Deficiency – Diphyllobothrium
- ✓ Microcytic Anemia – Ankylostoma
- ✓ Conjuctival Swelling – Loa Loa
- ✓ Portal HTN – Schistosoma Mansoni + Japonicum (Lateral Spine)

- ✓ Hydatid Cyst – Echinococus
- ✓ Neurocysticercosis (Bram Cyst) – Tenia Solium
- ✓ Cysticercosis caused by -Ingestion of ova of tenia solium
- ✓ Pinworm infection in its life cycle in human by - Ingestion of eggs

Malaria

- ✓ Plasmodium malarie can lead to – Nephrotic syndrome (Membranous GN)
- ✓ Plasmodium Vivax and ovale has – Hypnozoite stage (means sleep)
- ✓ Primaquine is DOC to kill – Hypnozoites.
- ✓ Shortest pre-erythrocytic phase is seen in – Plasmodium Falciparum.
- ✓ Longest pre-erythrocytic phase is in – Plasmodium malariae.
- ✓ Species that cause relapse are – Vivax and ovale.
- ✓ Most common non falciparum malaria is – Plasmodium vivax.
- ✓ DOC for non-falciparum malaria is – Chloroquine.
- ✓ Malignant tertian malaria is caused by– Plasmodium falciparum
- ✓ Benign tertian malaria (48 hours) is caused by – Ovale/vivax
- ✓ Quartan malaria (72 hours) caused by – Plasmodium malariae.
- ✓ Quotidian malaria caused by – plasmodium Knowlesi > Falciparum
- ✓ Anemia in malaria is – Normocytic normochromic.
- ✓ Dormant phase of malaria – Hypnozoire
- ✓ Malaria enter into human body as –Sporozoite
- ✓ Sporozoite divide in liver as – Merozoite
- ✓ New species of malaria is – Knowlesi

Virology

DNA viruses

- ✓ These Are HHAPPPPy viruses
- ✓ Hepadna(Hep B) , Herpes, Adeno, Pox, Parvo, Papilloma, Polyoma
- ✓ All Are double stranded Except parvo (single stranded).
- ✓ Have linear genomes Except papilloma and polyoma (circular, supercoiled) and hepadna (circular, incomplete)
- ✓ All Are icosahedral Except pox (complex).
- ✓ All Replicate in the nucleus Except pox (carries own DNA-dependent RNA polymerase)

RNA viruses

- ✓ All replicate in the cytoplasm (except retrovirus and influenza virus).
- ✓ All are Single stranded except Reo virus
- ✓ Flavi virus cause Yellow fever
- ✓ Bunya viruses cause California encephalitis
- ✓ Zika Virus can cause Conjuctivitis + Miscarriage
- ✓ Segmented viruses -Bunyaviruses (3 segments), Orthomyxoviruses (influenza viruses) (8 segments), Arenaviruses (2 segments), and Reoviruses (10-12 segments)
- ✓ Paramyxo Viruses -Measles ,Parainfluenza Mumps and RSV
- ✓ Orthomyxo Virus -Influenza Virus
- ✓ Measles cause 3 C's of measles- Cough ,Coryza ,Conjunctivitis "K(C)"oplik spots +Lymphadenitis with Warthin-Finkeldey giant cells (fused lymphocytes) +Subacute sclerosing panencephalitis (SSPE)
- ✓ Rubella in pregnancy complication overall – Deafness > Cataract
- ✓ Rubella in pregnancy complication Within 7 weeks –Cataract
- ✓ Rubella in pregnancy complication After 7 weeks – Deafness

Aids/HIV

- ✓ Initial Test - ELISA
- ✓ Confirmatory Test - Western Blot
- ✓ In children Confirmatory - PCR
- ✓ Hall mark of HIV - Proliferation of Virus in TCell
- ✓ Hall mark of AIDS - Progressive Immunodeficiency (Decrease CD4 Count)

CamScanner

✓ Progression from asymptomatic to Symptomatic stage can be assessed by - PCR

Meningitis

0-6 months	6months-6 years	6Year-60Year	Above 60 Year
GroupB streptococci EColi Listeria	S Pneumoniae N Meningitidis H Influenzae type b Group BStreptococcus Enterovirus	S Pneumoniae N Meningitidis Enterovirses HSV	S Pneumoniae N Meningitidis H Influenzae type b Group BStreptococcus Listeria

Sterilization

- ✓ In HIV Patient after surgery to clean Floor use – 1% Hypochlorite
- ✓ In HIV Patient after surgery to clean Instruments use – 2% Glutradehyde
- ✓ Heat Labile instruments sterilized by –Ethylene oxide gas
- ✓ Face Mask Sterilization done by – Ethylene oxide gas
- ✓ Face Mask Cleaning done by – Lukewarm water
- ✓ Dry Heat at 160 C for 2 h used for – Killing Spores of surgical instruments
- ✓ Autoclaving is heating objects at 121 C at 15 Psi for 15-30 min
- ✓ Tyndalization is Heating in steam at 100 C for 20 min on 3 Consecutive days
- ✓ Dry Heat Kill bacteria by Oxidation
- ✓ Moist Heat Kill bacteria by Coagulation of Proteins
- ✓ Syringes Needles sterilized by –Gamma Radiations
- ✓ Use Extensive Hand Washing to prevent Infection in ICU

Prevention

- ✓ Primary – Prevent disease before it occur i.e. HPV vaccination.
- ✓ Secondary - Early diagnose and treatment i.e. Pap smear.
- ✓ Tertiary – Treatment to reduce complication i.e Chemotherapy.
- ✓ Quaternary – Avoid unnecessary intervention to minimize incidental harm.

BACTERIOLOGY

1. 80yrs old male bed ridden since 1 years presented with the complain of fever and cough with sputum yellowish in colour, his lower lobe of lung was filled with pus which turn into consolidations after his most commonly involve organism?
   - A- Staph Aureus
   - B- Streptococcus pneumonia
   - C- Hemophilus influenza
   - D- Morexella catarahhalis

   Ans: A

2. 46 years old male presented with complain of fever with chills and thick yellow tinaceous sputum since 4 days organism involves?
   - A- Staph aureus
   - B- Pseudomonas
   - C- Proteus
   - D- Klebsella

   Ans: A

3. A child with profuse diarrhea 20 episodes per day and shooting star motility of organism is seen, what will be the growth of organism in specific media?
   - A- E.coli
   - B- Vibrio cholera
   - C- Shigella
   - D- Klebsella

   Ans: B

4. Acute bacterial meningitis case with typical picture of increased proteins and neutrophils more than lymphocytes. He was having rash around ankles and signs of meningeal irritation. On the basis of Gram stain, doctor started IV ceftriaxone, what are the results on gram stain?
   - A- Gram positive diplococci
   - B- Gram negative diplococci
   - C- Gram negative rods
   - D- Gram positive rods

   Ans: B

5. Patient in ICU with CVP passed, developed rash aronnd it. Cultures showed Catalase +ve and coagulase -ve organism, What is the way by which the orgauism causes intravascular symptoms?
   - A- TSST-1
   - B- Exo polysaccharide
   - C- Protein A
   - D- Capsule

   Ans: B

Explanation:

- TSST 1 belongs to staph aureus which is coagulase Postive and Exopolysaccbride produce by staph epidermitis which is Coagulase negative and Catalase Positive so B suitable ans here.

6. A person got a prick (or cut) and the finger was tender, painful and red. Later pus developed at that site. Culture showed staph aureus, how it escaped the phagocytosis?
   - A- Coagulase
   - B- Secrete Efb
   - C- Secrete C3b
   - D- Secrete endotoxin

   Ans: B

Explanation:

- Staph aureus secrete Efb (Extracellular fibrinogen binding protien) bound to C3b Via C terminal. By using N terminal attract Fg that gives protection And prevent binding of phagocytic receptor to bind C3b and IgG.

7. Greenish Vaginal discharge by which organism?
   - A- Candida
   - B- Chlymydia
   - C- Pseudomonas
   - D- Gonorrhea

   Ans: C

8. Common cause of otitis media in children?
   - A- Step pneumonia
   - B- H influenza
   - C- Beta hemolytic streptococii
   - D- Staph aureus

   Ans: A

9. Virulence factor Staphaureus is
   - A- Coagulase
   - B- Protein A
   - C- Capsule
   - D- Protien M

   Ans: B(FA)

10. Sulphur granules containing
    - A- Staph Aureus
    - B- Streptococus
    - C- Actinomycets
    - D- Listeria

    Ans: C

CamScanner

11- Triad of sinus bradycardia absolute neutropenia hepatosplenomegaly Diagnose is:
A- Malaria
B- Typhoid
C- Dengue
D- Yellow fever
Ans: B

12- Which one can be normal flora of respiratory tract?
A- H influenza
B- C Diptheria
C- S Epidermitis
D- None
Ans: A

13- Diptheria growing media:
A- Loffler
B- LJ media
C- Basal media
D- Blood agar
Ans: A

Explanation
- H lafuenzae – Chocolate agar
- Nüsseria – Thayer martin medium
- B pertussis – Bordet Gengou agar
- C diptheriae – Loffler medium
- MTB – LJ medium
- Ecoli – EMB agar
- M paeumoniae – Eaton agar
- Brucella, Francisella, Legionella, Pasteurella - Charcoal yeast extract agar buffered with cysteine and iron
- Fungi - Sabouraud agar

14- Rocky mountain spotted fever is Caused by:
A- Rickettsia Rickettsii
B- Rickettsia Prowazaki
C- Rickettsia Typhus
D- Coxiella Burnetii
Ans: A

15- Staphlococus aureus differentiated from other by staining positive for:
A- Catalase
B- Coagulase
C- Lactase
D- Urease
Ans: B

Explanation:
- Staining – Coagulase positive
- Virulence by – Protein A

16- Pyogenic Peritonitis caused by:
A- Bacteroids
B- E.coli
C- Streptococus
D- Staphlococus
Ans: A

Explanation:
- Ascetic Tap – E-coli
- Peritonitis – E-coli
- Pyogenic Peritonitis – Bacteroids
- Peurperal Sepsis – Group B streptococcus > E coli > ides

17- A neutropenic hypntensive patient admitted in oncology ward with Hx of dysuria & high grade fever. His blood culture yielded growth of P. aeruginosa. These findings suggest that the disease is a result of the excessive release of the following bacterial product in the blood:
A- Endotoxin
B- Erythrogenic toxin
C- Toxic shock syndrome
D- Leucocidin
E- Proteases
Ans: A

Explanation:
- Pseudomonas commonly produce – Exotoxin
- Pseudomonas Cause fever and Hypotension – Endotoxin
- Pseudomonas cause fever by Cytokine – TNF>IL1
- OverAll Fever – IL 1>TNF

18- 30 year old male with a history of sexual exposure comes with an indurated painless ulcer over the penis with everted margins diagnose is:
A- Syphillis
B- Chancroid
C- Gonorrhea
D- HSV
Ans: A

Explanation:
- Painless ulcer – Primary Syphlis
- Painless ulcer + Lymphadenopathy – Secondary ulcer
- Painful Ulcer – Chancroid caused by Haemophilus Ducreyi

19- Spore forming bacteria is
A- Corny bacterium
B- Clostridium
C- E. coli
D- Shigella
Ans: B

20- A patient after eating from restaurant in dinner then at mid night present with diarrhea due to:
A- Clostridium
B- Staph aureus
C- Ent amoeba
D- Salmonella
Ans: B

21- Post influenza infection thick yellow sputum present due to:
A- Staph aureus
B- Klebisln pneumonia
C- Streplococus
D- Legionella
Ans: A

Explanation:
- Post Influenza Most Common Organism – Strep Pneumona
- Post Influenza Brown Rusty Sputum – Strep Pneumonae
- Post Influenza Yellow thick Sputum – Staph Aureus
- Post Influenza Current jelly Sputum – Klebsiella Pneumonae

22- Patient in oncology ward diagnosed with case of Pseudomonas auregnosa. Which one of the following cause infection
A- Erythrogenic toxin
B- Endotoxin
C- TSSTI
D- Exotoxin
Ans: D

23- Pus that accumulates in boils or abscess is mainly composed of:
A- Neutrophils
B- Dead bacteria lymph
C- Monocytes
D- Mucus
Ans: A

24- Person had molar tooth extraction developed mandibular swelling with yellow discharge grape like cluster colonies organism:
A- Staph aureus
B- Actinomyces
C- Strep pyogens
D- Klebsiella
Ans: A

25- Actinomycosis jaw draining abscess the finding:
A- Gmnuloma with abscess
B- Abscess
C- Non caseating granuloma
D- Cascating granuloma
Ans: A

26- 67 years old man presented with history of cough for the last 7 days and its also associated with thick mucoid sputum, the organism respunsible is:
A- Strep pneumonin
B- Staph aureus
C- Klebsella
D- Legionella
Ans: C

Explanation:
- Slaph Aureus – Thick Yellow Sputum
- Streptococus – Brown Rusly Sputum
- Klebsiella – Current jelly mucoid Sputum

27- Most common organism responsible for causing infections in post splenectomy patient in a 4 years old child:
A- Staphaureus
B- Streppneumonia
C- E.coli
D- N meningitides
Ans: B

Explanation
- Streptococus pneumonae >H influenza >Nisseria meningitis

28- 2 weeks after sore throat child presents with hematuria, hypertension and mild proteinuria, likely organism for causing infection:
A- Group A streptococci
B- Group B streptococci
C- Staph aureus
D- Strep saprophylicus
Ans: A

29- Most common cause of hospital acquired infections:
A- Strep pneumonia
B- Staph aureus
C- Hemophillus influenza
D- E. Coli
Ans: B

30- Cause of urease positive UTI:
A- E.coli
B- Shistosmia hematobius
C- Klebsella
D- Proteus
Ans: D

31- Urease Negative organism:
A- Ecoli
B- Proteus
C- H pylori
D- Nocardia
E- Klebsiella
Ans: A

Explanation:
Urease positive organisms
- Proteus
- Clyptococcus
- H pylori
- Ureaplasma
- Nocardia
- Klebsiella
- S epidermidis
- S saprophyticus

CamScanner

32- Gram negative is differ from gram positive because of
A- Cell wall
B- Peptidglycan
C- Flagella
D- Periplasmic space
Ans: D

33- Which part of the bacteria increases its toxicity?
A- Periplasmic Space
B- Capsule
C- Flagella
D- Cell membranes
Ans: B

34- A bird catcher comes to you with the complain of cough, Flu like illness and fever which since 1 week x-ray chest showing features of pneumonia & infiltrates, most commonly organism involved is:
A- Streptococcus pneumonia
B- Staphaureus
C- Chlymydia psittaci
D- Hemophilus influenza
Ans: C

35- 8 years old child comes to you with the complain of fever, throat pain, on examination there are enlarged tonsils with the greyish membrane over tonsils, most common involved micro-organism:
A- E. coli
B- Morexella catarrhalis
C- Compylobecter
D- Corynebacterium
Ans: D

36- Patient had eaten fried rice 6 hours ago now presented with nausea vomiting and diarrhea cause is:
A- Staph aureus
B- Salmonella
C- Bacillus cereus
D- Vibrio cholera
Ans: C

37- Bacillus anthrax grows in which medium:
A- Sudan black
B- Loffiers medium
C- MacConkeys agar
D- Blood agar
Ans: D
Explanation:
- Bacillus is gram positive rods and forming non Hemolytic colonies on blood agar

38- In case of corynebacterium diphtheria what type of growth pattern is seen
A- Palisade pattern
B- Cluster pattern
C- Long chain branching
D- Lettuce pattern
E- Haphazardous
Ans: A
Explanation:
- It is a gram positive rod, club shaped and arranged in pallisade pattern V or L shaped

39- Patient with abdominal pain and persistent vomiting cause is:
A- Endo +Exotoxin
B- Enterotoxin
C- Endotoxin
D- Erythrogenic
Ans: B

40- Anthrax main differentiating feature:
A- Spore
B- Gram stain
C- Capsule
D- Motility
Ans: A

41- Chlamydial infection causing chlamydia psittacosis is:
A- Obligate intracellular
B- DNA derived from host
C- Contain RNA
D- Extracellular
Ans: A

42- Cause of meningitis in a 3 year with ear pain and gram negative cocobacilli:
A- E.coli
B- H influenza
C- Listeria
D- Streptococcus
Ans: B
Explanation
- H influenza is gram negitive cocobacilli

43- The most commonest hospital acquired organism for UTI:
A- E.Coli
B- Paurigmosa
C- S-aureus
D- Citrobacter species
Ans: A

44- Patient having Fever Cough with Sputum infiltrate on x-ray chest gram positive, catalase negative organism isolated on culture likely:
A- Streptococcus pneumonia
B- Staphylococcus aureus
C- Klebsella
D- Streptococcus pyogens
Ans: A

45- A mother brings her 5 years old daughter to the emergency room and relates a 4 day history of sour throat, and a painless but persistent serosanguinous discharge from the child's vagina. Pelvic examination confirms history and the saline/potassium chloride preparations are negative. The most likely etiology is:
A- Candida
B- Foreign Body
C- Neisseria gonorrhea
D- Streptococcus
E- Trichomonas
Ans: D
Explanation:
- Streptococcus induced valvovaginitis result in serosanguinous discharge.

46- 70 years old Alcoholic man presents with thick mucoid sputum, organism likely involved is:
A- Klebsiella
B- Streph pneumonia
C- Staph Aureus
D- Legionella
Ans: A
Explanation:
- Klebsiella – Alcoholic + Current jelly sputum
- Strep Pneumonae – Brown Rusty Sputum
- Staph Aureus – Thick Yellow Sputum

47- 29 years sexually active male, presents with urinary discharge, the most common organism involved is:
A- Chlamydia
B- E.coli
C- Proteus
D- Saprophyticus
Ans: A

48- Abscesses in both lungs is caused by:
A- Nocardia
B- TB
C- Mycobacterium avium
D- Staph aureus
Ans: D

49- Cause of preterm labour is
A- Bacterial vaginosis
B- Trichomonas vaginalis
C- Endometriosis
D- Strep pneumoniae
Ans: A

50- Bacterial spore resistant to oxidation & heat why?
A- Capsule with diplomic acid
B- Diplomic acid in cell membrane
C- Diplomic acid with phospholipids
D- Low water content & dipicolinic acid
Ans: D
Explanation:
- These resistance factors include the outer layers of the spore, such as the thick proteinaceous coat that detoxifies reactive chemicals; the relatively impermeable inner spore membrane that restricts access of toxic chemicals to the spore core containing the spore's DNA and most enzymes; the low water content and high level of dipicolinic acid in the spore core that protect core macromolecules from the effects of heat and oxidation.

51- Respiratory paralysis by which organism?
A- Salmonella
B- Corynebacterium
C- Botulinism
D- Bacillus
E- Shigella
Ans: C

52- Donovan bodies found in infection:
A- HSV
B- HPV
C- Granuloma inguinale
D- Chalymydia
E- TB
Ans: C
Explanation
- Donovan bodies – Granuloma inguinale
- Henderson petresco bodies – molluscum contangiosum
- Michaelis guttman body – Malakoplakia

53- Septic meningitis commonly in old age caused by:
A- E. Coli
B- Streptococcus
C- Listeria
D- Influenza
Ans: B

54- Patient with Non ulcerative Lesion discharge cause is
A- Nissena Gonorrhea
B- Chalamydia
C- HSV
D- Syphlis
Ans: A

CamScanner

55. Gram ve diplococci organism most commonly involve which route?
A- Urinarytract
B- Ureter
C- Respiratory tract
D- Kidney
Ans: A

56- Boy had ice cream then he developed sore throat investigationshow Inc. neutrophils and lymphocyte normal:
A- Fungal
B- Bacterial
C- Viral
D- Parasite
Ans: B

57- Shooting star motility organism produce:
A- Clear conies on mcconkey agar
B- Pink colonies
C- Red colonies on XLD agar
D- Yellow Colonies on TCBS
Ans: D
Explanation:
- This is vibrio cholera which has motility and Show darting (Shooting Star) and produce Yellow Colonies on TCBS (Thiosulfate Citrate Bile salt sucrose) agar.
- Campylobacter can also show darting which usually produces creamy Gray or white colonies

58- Causative organism of pneumonia in alcoholic patients?
A- Mycoplasma
B- Pneumocystis carinii
C- Klebsella
D- Pseudomonas
Ans: C
Explanation
- Pneumonia in diabetics and alcoholic patients – klebsiella
- Ventilator associated pneumonia - P aeraginose
- Pneumonia in COPD – H influenza and Moraxella
- Pneumonia in Bronchiectasis – P Aeruginosa
- Nosocomial pneumonia – staph aureus
- Pneumonia in cystic fibrosis – staph aureus
- Community acquired pneumonia – Strep pneumoniae
- Most common cause of lobar pneumonia – S pneumoniae (most commou), Legionella, Klebsiella
- Cause of bronchopneumonia – S pneumoniae, S aureus, H influenzae, Klebsiella
- Pneumonia after viral infection – staph aureus
- Pneumonia with rusty sputum – strep pneumoniae
- Pneumonia with current jelly sputum – Klebsiella
- Pneumonia in AIDS Patient – pneumocystis jirovecii/carinii
- Atypical pneumonia – Mycoplasma
- Walking pneumoniae – Mycoplasma
- Air condition related pneumonia – Legionella
- Pneumonia with hyponatremia – Legionella

59- Portal of entry of Meningococcal meningitis:
A- Feco oral
B- Respiratory droplets
C- Airborn
D- Blood
Ans: B

60- Fumigation is done in case of:
A- In wards where a patient of plague was admitted
B- 5 confirmed cases of dengue
C- Cardiac surgery O.T where increased incidents of post Op infections reponed
D- H1N1
Ans: D

61- Most common cause of puerperal Sepsis is:
A- DES
B- E.coli
C- Trichomonas
D- Group B Streptococcus
Ans: D
Explanation:
- Group B Streptococus > E coli > Bacteroids.
- Ascetic Tap – E-coli
- Peritonitis – E-coli
- Pyogenic Peritonitis – ides
- Peurperal Sepsis – Group B streptococcus > E coli > ides

62- Inactivated toxoid used as vaccine is
A- Typhoid
B- Tetanus
C- Rubella
D- Rabies
Ans: B

63- A child was having fever cough and upper lobe consolidation. he developed respiratory distress. cll cannot be passed as he had laryngotracheobronchitis, what is the most likely cause of this notorious condition ?
A- Hemophilus influenza
B- Moraxella catarrhalis
C- Staph aureus
D- Streptococus
Ans: A(No para influenza option)

64- pseudomembranous colitis is caused by which organism
A- Staph Aureus
B- Streptococus
C- Clostridium Perfringes
D- Klebsiella
E- Clostridum Difficile
Ans: E

65- Diagnosis of gonococcus is easily made by which of following
A- Eosin
B- Basophilic dye
C- Gram stain
D- Fermentation
E- Giemsa Stain
Ans: C

66- Most commou cause of pyogenic lung abscess:
A- Staph Aureus
B- E.Coli
C- Streptococcus Pneumoniae
D- Klebsiella
E- H influenza
Ans: A

67- A 25 year female newly married presents to ER with fever and burning micturition and suprapubic pain with increased WBC count. The organism involved most likely is:
A- E.coli
B- Neisseria gonorrhea
C- Chlamydia trochimatis
D- Pseudomonas
E- Proteus
Ans: A

68- The best diagnostic lab test for the infection by streptococcus beta haemolyticus is:
A- ASO titre
B- Blood culture
C- Inuunoassay
D- Leukocytes culture
E- Urine for bile pigment
Ans: B
Explanation:
- Initial – ASO
- Best Diagnostic – Throat culture > Blood culture

69- Which bacteria have no cell wall?
A- Chlamydia
B- Mycoplasma
C- Klebsiella
D- E.coli
E- Shigella
Ans: B(FA)
Explanation:
- Mycoplasma and ureaplasma has no cell wall

70- Person infected with rat fleas present with multiple lymphadenopathy, fever and chills and eventually dies in epidemic organism identified was gram negative rod. What is the causative organism?
A- Francisella
B- Yersinia pestis
C- Actinomycets
D- Salmonella
E- Shigella
Ans: B

71- Staining shows gram positive cocci in chain. Many attempts made but cannot be cultured. What other technique can be used to apart from it?
A- PCR and rRNA amplification
B- SDS polyacrylamide gel electrophoresis
C- Enzyme electrophoresis
D- Serology
Ans: D

72- Virulence of staph aureus strain Measuredby
A- Ability to hemolyze
B- Coagulase positivity
C- IgA protease
D- Fragility positivity
E- Drug Sensitivity positivity
Ans: B (No protein A option)

73- A patient presented with prolonged diarrhea and undergoes esophagogastroduodenoscopy biopsy of small intestine demonstrates crescent shape protozoa adjacent to epithelial brush border which of the following organisms is the most likely pathogen?
A- Entamoeba histolytica
B- E.coli
C- Giardia lamblia
D- Naegleria fowleri
E- Trichomonas vaginalis
Ans: C

CamScanner

74- Female patient present with increased frequency and urgency was diagnosed as UTI case microscopy shows gram negative motile rods urease positive lactose non fermenting on macconkey agar likely urganism involved is:

A- Pseudomonas
B- Compylobacter
C- Proteus metabilis
D- Klebsiella
E- E.coli
Ans: C (FA)

Explanation:

Lactose fermentor

- Fast – (KNEE) E coli. Klebsiella artd Enterobacter
- Slow – Citrobacter and Serratia

Lactose non fermenters (SPYS)

- Salmonella , proteus , Yersinis . Shigella

75- A patient having thin discharge foul smelling, pear shaped trophozoites on per speculum examination erythematous vagina a reddish punctuation of cervix:

A- Gonorrhea
B- Chlymydia
C- Trichomonas
D- Bacterial vaginosis
E- Candida
Ans: C

76- Cells responsible for innate immunity are activated most commonly by:

A- Carbohydrate sequence in bacterial Cell wall
B- Cytoplasmic protein of bacteria
C- Pollen
D- Eosinophils
Ans: A

77- In 1918 If influenza pandemic was the worst pandemic and killed many people why was it so lethal?

A- It was resistant to antibiotics
B- There was mutation in DNA of H influenza
C- Reassortment
D- Phenotype mixing
E- Antigenic shift due to animal proteins
Ans: E

78- A patient having Deep neck infection, Most likely microorganism:

A- Gram positive plus gram negative
B- Gram positive aerobe
C- Gram negative aerobe
D- Mixed anaerobes
E- Mixed aerobes
Ans: E

79- 12 years old Afghan boy came with fever night sweats on right side neck discharging sinus and cervical lymphathnopathy. No growth revealed on blood culture which next confirmatory test should be done?

A- ZN staiin
B- Lymph node Biopsy
C- Mycobacterium culture
D- Mycobacterium antibody
E- Blood culture
Ans: B

80- In Trichomonas infection, which investigation is required to Diagnose:

A- Blood sample
B- Genital sores
C- Wet smear of vaginal secretion
D- Urine sample
Ans: C

81- Which chlamydial specie causes blindness?

A- Chlamydia A-C
B- Chlamydia D-K
C- Chlamydia Psittaci
D- Chlamydia G
E- Chlamydia L1-3
Ans: A (FA)

Explanation:

Types A-C

- Chronic infection and blindness

Types D-K

- Urethritis/PID
- Ectopic pregnancy,
- Neonatal pneumonia (staccato cough) with eosinophilia
- Neonatal conjunctivitis (1–2 weeks after birth)

Types L1-L

- Lymphogranuloma venereum

82- A Patient presented with Fever Headache, Muscle ache and Rash. All symptoms suggesting Rickettsia infection. The target tissue in rickettsial infection is which of following?

A- Endothelium
B- Epidermis
C- Lymph node
D- Nerve fibres
E- Neural tissue
Ans: A

Explanation:

- Rickettsia primarily attack endothelial cells of vessel. They enter, grow and replicate within cytoplasm of endothelial cells.

83- Child present with abdominal pain with dysentery, stool contains pus and RBCs causative agent is:

A- Campylobacter
B- Enterotoxigenic E coli
C- Enterohemorrhagic E coli
D- Enteropathogenic E coli
E- Salmonella
Ans: C (FA)

Explanation:

EnteroInvasive E. coli

- Invade intestinal mucosa (Necrosis and Inflammation)
- Cause dysentry similar to Shigella

EnteroToxigenic E. coli

- Produce heat labile and heat stable enterotoxin (no inflammation or invasion)
- Cause Travelor's diarrhea

EnteroHemorrhagic E. coli

- O157:H7 is most common form
- Cause dysentery (Inflammation and necrosis)
- Shiga like toxin cause HUS (Anemia + Thrombocytopenia + AKI)
- Cause mechanical hemolysis (Schisocytes on peripheral Smear)
- Do nor ferment sorbitol (Other E. coli Do)

Entero-Pathogenic E. coli

- Artach to Apical surface Flatten Villi impair absorption
- Cause Diarrhea in Pediatrics

84- After bacterial infection which cells will be seen?

A- Lymphocytic Leukocytosis
B- Monocytosis
C- Neutrophilic Leukocytosis
D- Basophilic Leukocytosis
E- Macrophages
Ans: C

85- Most common cause of community acquired pneumonia is:

A- H. influenza
B- Strep Pneumoniae
C- Staph Aureus
D- Klebsiella
E- Mycoplasma
Ans: B

86- Which of the following organism causes meningitis in age of 5 year?

A- Streptococcus pneumonia
B- Staph Aureus
C- E. coli
D- Group B streptococcus
E- H influenza
Ans: A (FA 2021)

87- Patient having HIV sero positive and not yet developed AIDS. suffer acute suppurative otitis media the likely organism responsible for it:

A- Pseudomonas areginosa
B- Candida albican
C- Mycobacterium avium
D- Staphylococcus aures
E- Streptococcus pneumonia
Ans: E

88- A patient in an ICU is on a CVP line. His blood culture shows growth of grain positive cocci which are catalase positive and coagulase negative. The most likely etiological agent is?

A- Staphylococcus aureus
B- Staphylococcus epidermidis
C- Streptococcus pyogenes
D- Enterococcus faecalis
E- Stephlococcus Saprophyticus
Ans: B

89- After appendectomy patient developed chronic wound abscess and draining sinus containing yellow granules the organism is:

A- Nocardia
B- Actinomyces
C- H.pylori
D- E.coli
E- Proteus
Ans: B

Explanation

- Yellow Granules – Actinomyces
- Yellow Colonies – Staph Aureus

90- 24 year old mechanic presents with dysuria urethritis most likely organism is:

A- Ureaplasma urealiryticus
B- Chlamydia trachomatis
C- Gonorrhea
D- HPV
E- HSV
Ans: B

91- Diphtheria affects which type of cell

A- B Cell
B- CD 8 Cells
C- NK Cell
D- Plasma Cell
E- Neutrophil
Ans: B

92- Painful genital ulcers occur in which of following?

A- Chlamydia
B- Treponema
C- Haemophilus ducreyi
D- Nisser a
E- Klebsiella
Ans: C

CamScanner

Explauation:
Painful Genital ulcer
- Bachet disease
- Genital herpes(HSV 2)
- Chanchroid(Haemophilus Ducreyi)

Painless Genital ulcer
- Syphlis(Chamce)
- Lymphogranulom Venerum(Chlamydia)
- Granuloma inguinale(Klebsiella)
- Painless ulcer +Painful Lymphnode - LymphogranulomaVenerum(Chlamydia
- Painful ulcer +Painful lymphnode -HSV
- Painless ulcer + Painless lymphnode - Syphilis

93- A young boy with complains of facial asymmetry drooling of saliva from mouth and inability to close his eyes the history prevails chronic nasopharyngeal siousitis what is the most likely cause?
A- E.coli
B- Corynebacteria diptheria
C- Herpes Simplex Virus
D- Campylobacter
E- H.influenae
Ans: B

Explanation:
- Facial palsy and drooling of saliva suggesting comybacteria diphtheria.

94- Capsule of B Anthrax is stained With
A- Albert stain
B- Neisser'sstain
C- Sudan stain
D- Loeffler stain
E- M'Faayen stain
Ans: E

95- Male with urethral discharge, gram staining showed gram negative diplococci:
A- N.Gononbea
B- N.Meningitidies
C- Pseudomonas
D- Staph Aureus
Ans: A

96- Gummatous Necrosis is a feature of:
A- Syphilis
B- AIDS
C- IM
D- Hepatitis
Ans: A

97- 40 years old male drink water from a stream developed mild diarrhea & other symptoms along with two children who developed same symptoms too:
A- E. Coli
B- Giardia
C- Vibrio Cholera
D- Staph Aureus
Ans: C

98- Atypical pneumonia feature is by:
A- Staph Aureus
B- S.Pnumoniae
C- Mycoplasma
D- TB
Ans: C

99- School Children presented with bloody diarrhea containing mucus is most likely caused by which of the following:
A- Shigella
B- Vibrio Cholera
C- Salmonella
D- Streptococcus
Ans: A

100- Shigella causes dysentery by mechanism of:
A- Mucosal Invasion
B- Cell Wall
C- Proteogiycan
D- Phospholipid
Ans: A

101- Which of the following is characteristic of bacteroids infection?
A- Can't cause abscess
B- Foul smelling discharge
C- Not part of nonnal flora
D- Fruity smell
Ans B

102- A pregnant woman presented with the complain of severe diarrhea on microscopy there is tumbling movement of the organism, what could be the possible cause of diarrhea in this woman:
A- Enterococus
B- Listeria
C- Staph Aureus
D- Shigella
E- Salmonella
Ans: B

103- A patient presented with headache, nausea vomiting., he was diagnosed as a case of brain eating amoeba, which of the followings is causative organism:
Proteus
A- Naegleria flowcri
B- Aspergillus
C- Hemophillus
D-
Ans: B

104- Butchers are at highest risk of getting infected with which of the following disease?
Brucellosis
A- HIV
B- IM
C- Dengue Fever
D-
Ans: A

Explanation:
- Butchers & slaughterhouse workers are at highest risk of contracting zoonotic diseases.

105- Which of the following test to be done for typhoid fever during the first week?
A- Urine culture
B- Blood Culture
C- Antibody Test
D- Stool Culture
Ans: B

Explanation:
BAST
- Blood Culture = 1st week
- Agglutination Test (Widal Test) = 2nd week
- Stool culture = 3rd week
- Urine culture = 4th week

106- A child presented with Sickle cell anemia with cordman triangle Osteomyelitis most likely due to which of the following:
A- Salmonella
B- E. Coli
C- Staph Aureus
D- Streptococcus
Ans: A

Explanation:
- The commonest cause of Ostcomyelitis is Staph Aureus
- While, in Sickle cell anemia it's Salmonella

107- A female with sore throat & diagnosed with water house friedrichsen syndrome most likely caused by:
A- Neisserin Meningitides
B- Gonorrhea
C- Staph Aureus
D- Streptococcus Pneumonia
Ans: A

Explanation
- The commonest cause of Water house friedrichsen syndrome is N. Meningitides and symptoms of sore throat is seen at initial stages.

108- Which of the following is air borne preventable disease?
A- HIV
B- IM
C- Tuberculosis
D- Sarcoidosis
Ans: C

109- Typhoid Diagnostic test:
A- Widal Test
B- Immunoassay
C- Western blot Test
D- CD4Count
Ans: A

110- Which of the following causes food poisoning by release of exotoxia:
A- Shigella
B- E coli
C- P.Jirovecii
D- Staph Aureus
Ans: D

111- Patient known HIV sufferingfrom severe headache, photophobia & sign of meningeal irritation. On microscopy organism has halo around it. The organism is:
A- Toxoplasmosis
B- Histoplasmosis
C- Cryptococcus
D- Candida
E- CMV
Ans: C

Explanation:
- Brain Abscess: Toxoplasma Gondii
- Halo: Cryptococcus (Silver Stain)

112- Which of the following organism is responsible for rheumatic fever?
A- Group A Streptococcus
B- Group B Streptococcus
C- Group C Streptococcus
D- Staph Aureus
Ans: A

Explanation:
- Group A streptococcus (Streptococcus Pyogenes) is responsible for Rhumatic Fever.

CamScanner

113- A male with history of travel to Bangkok, presented with painless penile ulcer with localized lymphadenopathy that were found to be rubbery & painless upon examination. additionally he had rash on his palms & soles due to
A- Primary Syphilis
B- Secondary Syphilis
C- Tertiary Syphilis
D- Latent Syphilis
Ans: B

Explanation:
- Primary Syphilis: Formation of non-itchy and painless chancre
- Secondary Syphilis: Rashes
- Tertiary Syphilis: Asymptomatic
- Late Syphilis: Neurological disorders Cardiac Disorder

114- Which of the following organism causes meningitis in age group 06 months to 02 years old?
A- Streptococcus pneumonia
B- Staph Aureus
C- E. coli
D- Group B streptococcus
Ans: A

115- Cause of pneumonia in elders
A- Group B Streptococcus
B- Strep pneumonia
C- E.coli
D- RSV
E- Mycoplasma
Ans: B

Explanation:
- In neonates (< 4 weeks) – group B streptococcus, E coli
- In childrens - Viruses RSV, Mycoplasma, C pneumonia, C trachomatis
- Adults - Mycoplasma, C pneumonia, S pneumoniae, influenza virus, Anaerobes
- Elders– Strep pneumonia, influenza virus, anerobes, H influenza and gram -ve rods

116- Vibrio causes diarrhea due to which of the following ?
A- Increase in Chloride ion secretion
B- CAMP Activation
C- CGMP Activation
D- Increase in Sodium ion secretion
Ans: A

117- Streptococal toxic shock syndrome is due to:
A- Pyrogenic Exoroxin
B- Streptolysin S
C- Streptolysin O
D- Pyogenic Exotoxin
Ans: A

Explanation:
- Pyrogenic exotoxin due to Streptococcus
- Pyogenic exotoxin due to Staph Aureus

118- Endotoxin causes:
A- IL1 activation
B- IL6 activation
C- Complement activation
D- TNF activation
Ans: D > A

119- Woman married now presented with RIF pain & suprapubic pain, which of the following organism is involved?
A- Chlamydia
B- Gonorrhea
C- E. coli
D- Diptheria
Ans: A

Explanation:
- This is a case of PID & the commonest organism causing PID is Chlamydia followed by Gonorrhea

120- Which of the following is the virulence of Tb?
A- Exotoxin
B- Endotoxin
C- Cell Wall composition
D- Nucleus composition
Ans: C

121- Mother has infection of toxoplasmosis in 1st trimester, & was treated. Now her baby is born, to check acute infection in baby on ELISA method which antibody will be there:
A- IgA
B- IgM
C- IgG1
D- IgE
E- IgG2
Ans: B

122- Chlamydia causes which of the following:
A- Syphilis
B- Granuloma Inguinale
C- Lymphogranuloma Venereum
D- AIDS
Ans: C

Explanation:
- Syphilis is caused by: T-Pallidum
- Granuloma Inguinale is caused by Klebsiella granulomatis
- Lymphogranuloma Venererum is caused by: Chlamdia
- AIDS is caused by: HIV

123- Lyme disease is caused by which of the following?
A- Chlamydin
B- Gonorrhea
C- Spirochete
D- Viral
Ans: C

Explanation:
- Lyme disease is caused by Borrelia Burgdorferi is a bacterial species of the spirochetes class of the genus borrelia.

124- Condyloma latum is present in which stage of syphilis?
A- Primary
B- Secondary
C- Tertiary
D- None of the above
Ans: B

125- A patient present with pelvic discharge and having hutchinson teeth and gummas, cause is
A- Primary Syphilis
B- Secondary Syphilis
C- Tertiary syphilis
D- Congenital syphilis
Ans: D

126- Droplet infection spread by:
A- 1 – 3 feet
B- 1 – 3 Meter
C- 3 – 6 feet
D- 1 – 6 feet
Ans: A

Explanation:
- Droplet infection : 1 – 3 feet
- Airborne infection: 3 – 6 feet

127- Atypical Lymphocytosis is seen in which of the following?
A- SLE
B- AIDS
C- Infectious Mononucleosis
D- RA
Ans: C

128- Gram +ve Diplococci bacteria is:
A- Enterococcus
B- Streptococcus
C- Hemophilus
D- Klebsiella
Ans: A

129- Alcoholic patient presents with an episode of flu, the color of sputum is yellow and there are atypical pneumonia symptoms. X-ray showed bilateral diffuse infiltrates. What is the causative agent?
A- Klebsiella
B- Mycoplasma
C- Pseudomonas
D- Staph Aureus
E- Strep Pneumonia
Ans: B

130- An 85-year-old patient presents to the clinic with pneumonia. He had done splenectomy 20 years back. The causative agent of pneumonia in him is:
A- Klebsiella
B- Mycoplasma
C- Pseudomonas
D- Staph Aureus
E- Strep Pneumonia
Ans: E

131- A patient was started on therapy of clindamycin and now develops diarrhea. The causative agent is:
A- Clostridium difficile
B- Staph Aeureus
C- Staph Epidermidis
D- E.Coli
Ans: A

132- Most common opportunistic infection in AIDS?
A- Pseudomonas
B- Histoplasma
C- Pneumocystis carni
D- M.Bovis
E- S. aureus
Ans: C

133- Pink frothy vaginal discharge with vulval pruritus is caused by:
A- HSV
B- HPV
C- Gonorrhea
D- Chlamydia
E- Trichomonas Vaginalis
Ans: E

Explanation:
Trichomonas vagiualis
- pear shaped, foul smelling greenish discharge, pturitis, strawberry cervix
- Lab findings - Motile pear-shaped trichomonads, pH > 4.5
- DOC: Metronidazole or Clindamycin, treat both partners

CamScanner

Bacterial vaginosis
- No inflammation Thin, white discharge with fishy odour
- Lb findings - Clue cells pH> 4.5. ⊕ KOH , whiff test
- DOC – Metronidazole

Candida vulvovaginitis
- Inflammation Thick, white, "cottage cheese" discharge
- Lab findings - Pseudo hyphae pH normal (4.0–4.5)
- DOC: Azoles

134- Post hysterectomy infection caused By which of these
A- Bacteroids
B- StaphAureus
C- E.coli
D- Chlamydia
Ans: A

Explanation:
- Post hystetectomy infection is caused by bacteroids.
- Pyogenic peritonitis is caused by bacteroids.
- Only peritonitis caused by E. coli
- Peuperal sepsis caused by: Group B strep > Bacteroids.

135- Disease caused by mosquito bite:
A- Leishmaniasis
B- Yellow fever
C- Q fevet.
D- African sleeping sickness.
Ans: B

136- Intestinal flora that causes lobar pneumonia in alcoblics and diabetics having dark red "currant jelly" sputum:
A- E.coli
B- Pseudomonas
C- Klebsiella
D- S. aureus
Ans: C

137- Most common infectious cause of blindness:
A- Cataract
B- Trachoma
C- Vitamin A deficiency
D- Glaucoma
E- Nectalopia
Ans: B

138- A patient is having Mitral Valve disease now present with Fever, Malaise and Petechia. On examination he was also having Splinter hemorrhages and splenomegaly. What is the causative agent of such Illness?
A- Staphylococcus Aureus
B- Streptococcus Viridian
C- Streptococcus Pneumonia
D- Streptococcus Epidermidis
Ans: B

139- Young patient with burning micturition and cloudy urine, No fever, No pelvic tenderness. Lactose fermenting rods on MacConkey agar. The Causative organism is:
A- Proteus
B- Mycobacteria
C- Staph Aureus
D- E. coli
E- Shigella
Ans: D

140- A patient is having Post abortion sepsis. What is causative organism?
A- Group B Streptococcus
B- Staphylococcus
C- E.coli
D- Syphilis
E- Proteus
Ans: A > C > E

141- A 13 years old boy presented with Rose spots on Chest with fever, Headache Nausea and vomiting. On examination his abdomen was Doughy. What confirmatory Test is needed to diagnose this disease?
A- VDRL
B- Sputum AFB
C- Widal Test
D- Stool Culture
E- Bone marrow Biopsy
Ans: C

Explanation
- Rose spots are diagnostic for enteric fevercausative agent is salmonella typhi

142- 65-year-old man is suffering from pneumonia and unable to recognize faces and died. Which of following Bug is responsible?
A- Staphylococcus aureus
B- Hemophelius
C- Streptococcus P
D- Klebseila
E- Pseudomooas
Ans: C

143- In an ICU patient with CVP line in subclavian vein for the past 10 days is on parenteral nutrition. He developed fever, blood culture showed clusters of gram positive cocci the infection is most likely caused by:
A- Staph Aureus
B- Streptococcus
C- Psudomonas
D- Enterococci Fecalis
Ans: A

144- Mycobacterium does not produce endo/exoloxins then what features makes it so virulent?
A- Tuberculin
B- Tubuloproteins
C- Cell wall glycoproteins
D- Resides in macrophages
Ans: C

145- Patient comes with tender right hypochondrium, stool with occult blood on colonoscopy, ascending colon was involved, showing ulcers while other parts of colon were spared on histology / microscopy , what will be seen?
A- Necrotizing vasculitis
B- Crypt abscess
C- Entamoeba histolytica
D- Carcinoma
Ans: C (Robbins and Harsh Mohan)

146- Which toxin is responsible for scarlet fever?
A- Exotoxin
B- Erythrogenic
C- Endotoxin
D- Enterotoxin
Ans: B

147- Diphtheria toxin severely affect
A- Heart
B- Brain
C- Kidney
D- Lungs
E- Spleen
Ans: A

148- Regarding pertussis most likely:
A- Infants are susceptible from the time of birth
B- DPT has no protective value
C- Nasal and bronchial secretions are highly infectious
D- None
Ans: C

149- Definitive diagnosis of Tb by
A- AFB
B- Caseous granuloma
C- Epithelioid cell
D- Sputum culture
Ans: D

Explanation
- Initial - Chest X ray
- Definitive - Sputum Culture (Harrison)
- Diagnostic – PCR > AFB
- Microscopic - Caseous necrosis
- Histological - Epithelioid Cells with Caseating granuloma
- Type of Hyper Sensitivity - Delayed Type 4 T Cell Mediated
- Margins - Undermined
- Antibodies-Cell Bound

150- 22 year old sexually active, reported to have been in contact with syphilis positive, how would his physician know about him having contacted the disease:
A- Chancre on penis
B- Gumma on testicular biopsy
C- Condylomata accuminatum
D- Discharge
Ans: A

151- 90 % of anthrax infections are associated with:
A- Cutaneous lesions
B- Cardiac problems
C- Kidney problem
D- Lung problems
Ans: A

152 About Corynebacterium Diphtheriae select correct One:
A- Spore forming
B- Produce Exotoxin
C- Penicillin Resistant
D- Produce endotoxin
Ans: B

153 Criteria for diagnosis of sepsis:
A- HR > 100
B- HR > 120
C- Positive culture
D- WBC < 2000 and > 15000
Ans: C

154- Most characteristic feature of actinomyces:
A- Talcum granules
B- Restictive anaerobe
C- Cause infection in immunodeficient
D- Spore producing
Aos: A

CamScanner

155- Patient with hypotension and fever, on examination there were splinter hemorrhages, something palpable in splenic region, and needle track sign in cubital region, what is the diagnosis'?
A- Cholesterol > 300 g/dl
B- Urea is 114 mmol/l
C- Pseudomonas aeruginosa
D- H influenza
Ans: C

156- Child have non-fever diarrhea for many days, on microscopy comma shaped curved and gram-negative bacteria:
A- Vibrio
B- Ecoli
C- Giardia
D- Staph aureus
Ans: A

157- Initial investigation of leprosy:
A- Nasal scraping
B- Culture
C- Biopsy
D- PCR
Ans: A

158- ICU infections prevented by:
A- Multiple hand washing
B- Using face mask
C- Sterilising the reusable instruments
D- By keeping ICU temperature at 20
Ans: A

159- Prophylaxis against tetanus to population:
A- Toxoid
B- Antitoxin
C- Use of antibiotic prophylactically
D- Immunization with gamma globulin
Ans: A

160- Boat shaped organism in case of pneumonia is
A- Pneumocystitis jervoci
B- CMV
C- Vibrio cholera
D- HIV
E- Cryptosporidium
Ans: A

161- A male complains of pain at penis, urine culture negative for N.gonorrhea but leukocytes are positive in urine D/R which organism can cause this infection:
A- EColi
B- Chlamydia
C- HPV
D- HIV
Ans: B

162- Multinucleated giant cells least likely present in:
A- Blastomycosis
B- Cat scratch disease
C- Sarcoidosis
D- Leprosy
E- Strep pneumonia
Ans: E

163- Q fever is caused by which
A- Rickettsia
B- Rick
C- Virus
D- Parasite
Ans: A

164- A neonate was brought to the emergency with history of fever, neck rigidity. Organism likely to be the causative agent:
A- Hemophilus influenza
B- Streptococcus Pyogenes
C- E. coli
D- Staph aureus
E- Streptococcus pneumonae
Ans: C

165- Which vaccine shall be given to the patient who has undergone splenectomy?
A- H. influenzae
B- Hepatitis B
C- Streptococcal
D- Pneumococcal
Ans: D

166- Weil felix test is done for the identification of:
A- Klebsiella
B- Rickettsia
C- Pseudomonas
D Staph aureus
Ans: B

167- A young boy has complaint of diarrhea & abdominal bloating. Stool examination shows rod shaped bacteria that are slightly curved. Organism involved is:
A- Salmonella
B- Shigella
C- E. coli
D- Campylobacter jejuni
Ans: D

168- Pathogenesis of Diphtheriu is
A- Exotoxin
B- Enterotoxin
C- Endotoxemia
D- Alpha toxin
Ans: A

169- A 32-y ear-old patient with fever 100 fh. dry cough, joint pain WBCs 7.5 with 70% neutrophils. cause:
A- Strep. Pneumoniae
B- Stap. Aureus
C- Mycoplasma Pneumoniae
D- Vibrio cholera
Ans: C > A

170- Airborne transmission except:
A- Diphtheria
B- Typhoid
C- Anthrax
D- SARS
E- Meningitis
Ans: B

171- Regarding atypical mycobacteria:
A- They have cell wall of muramic acid
B- They can be cultured on loffler media
C- Resistant to anti tuberculosis typical drugs
D- Cause quartan fever
Ans: C

172- A drug which blocks adenylyl cyclase and inhibits cAMP can be used in the treatment of:
A- Corynebacterium Diphtheria
B- Pseudomonas Aeruginosa
C- Vibrio Cholera
D- Clostridium tetani
Ans: C

173- Which of the following is an opportunistic bacteria?
A- Staph aureus
B- Strep pyogenes
C- Histoplasma
D- Corynebacterium
Ans: A

174- MOA of gangrene caused by clostridium perfringens:
A- Local hypoxia
B- Release of phospholipase
C- Decreased ATP
D- Release of ACH
Ans: B

175- Regarding Vibro cholera:
A- Resistant to Alkaline medium
B- Resistant to acidic medium
C- Grow in acidic medium
D- Grow in basic medium
Ans: A

176- Tetanus toxin is:
A- Endotoxin
B- Neurotoxin
C- Erythrogenintoxin
D- Toxoid
Ans: B

177- Differentiate b/w rickettsia and mycoplasma by which of following?
A- Zeihl Nelsen stain
B- Gram stain
C- Sudan black
D- Geiosa stain
Ans: D

178- Gamma radiation sterilization use to sterilize which instrument?
A- Syringes needles
B- Brochoscope
C- Cystoscope
D- Laryngoscope
Ans: A

179- A patient presented with flattening of nasal bridge. Initial scrapping taken which organism is most likely
A- M leprae
B- M tuberculosis
C- Hinfluenza
D- C diptheria
E- L monocytogen
Ans: A

180- Fever and Hypotension in gram -ve organism due to
A- Pillus
B- Exotoxin
C- Endotoxin
D- Fimbriae
Ans: C

181- 27 years old man presents with headache, fever, positive kernigs sign, CSF analysis shows increased lymphocytes, sugar = Normal proteins = 60mg/dl, likely diagnosis:
A- Bacterial meningitis
B- Viral meningitis
C- Tuberculous meningitis
D- Fungal infection
Ans: B

182- In HIV patient surgery done then which antiseptic to use after surgery to clean floor?
A- 1% hypochlorite
B- 4% hypochlorite
C- Glutaraldehyde
D- Soap & water
E- Water
Ans: A

CamScanner

Explanation:
- Floor – 1% Hypochlorite
- Instruments – 2% Glutradchyde

183- Immune system produce memory to which component of bacteria?
A- Nucleus
B- Carbohydrate composition in bacterial cell wall
C- Cytoplasmic proteins
D- Cytoplasmic RNA
Ans: B

184- Drug of choice in actinobaeter bounei
A- Imipenem
B- Tetracycline
C- Aminiglycoside
D- Macrolide
Ans: A

185- A Patient presented with headache. Neck stiffness and photophobia on LP glucuse 40, Protein 150 and lymphocytes 20% and Neutrophils 80% what is diagoose?
A- Bacterial meningitis
B- Viral meniogitis
C- TB meningitis
D- HSV
E- Encephlitis
Ans: A

186- Cholera Mode of action is by decrease
A. Electrogenic Na absorption in small intestine
B. Electrogenic Na absorptionm Colon
C. Neutral Nael absorption
D. Na/K pump
E. Na/Glucose absorption in small intestine
Ans: C

187- Farmer present with red granules + draining abcess from foot organism responsible is
A- Chylmyda
B- Staphylococcus aureus
C- Gonorrhea
D- Actinomadura
E- Streptococus
Ans: D

188- Female having UTI Gynecologist adviced urine R/E shows pus cells organism is gram +ve catalase +ve coagulase -ve which organism is involved?
A- Staphylococcus aureus
B- Staphylococcus epidrmitis
C- Staphylococcus saprophyticus
D- Streptococcus pyogens
Ans: C

189- Horse rider fall and scratches same day ago presented with lock jaw and spasm due to :
A- Tetanus toxin Decrease GABA
B- Toxin Release Acetyl choline
C- Hypokchina with toxin
D- Toxin cause hyperkalemia
Ans: A

190- For diagnose of Chlamydia following test is used
A- Enzyme immunoassay
B- Dark field microscopy
C- Cytology
D- Culture
Ans: D

191- Meningitis in 20 year old organism is:
A- N meningitis
B- Ecoli
C- Listrteria
D- Streptococcus pneumoniae
Ans: D

192- Regarding Pseudomonas true is:
A- Normal flora of throat
B- Normal flora of skin
C- Sensitive tetracycline
D- Resistant to fluoroquinolones
Ans: D

193- Young male addict 25 y/o arrived s/s heart failure with needle track marks in arm. What next investigation will reveal?
A- Culture for pseudomonas
B- Ana Raised >2
C- CK-MB 8% and CK level 800
D- LDH 1000
Ans: A

194- A mother comes to you with her 4 month old baby. The baby has muscle weakness, no head hold. Failure to thrive. She says she gives the baby formula milk mixed with honey what is cause:
A- C. Botulinum
B- C.tetam
C- Diphtheria
D- Staph aureus
E- Bacillus
Ans: A

195- TSSY gene carried by 10-15 % by the following bacteria:
A- Staphlococus epidrmidis
B- Staph Aureus
C- Streptococus pneumomae
D- Comybactcrium
Ans: B

196- A 03 year child presented to opd has developed meningitis on culture gram negative coccobacillus was present the organism is:
Listeria
A- Niesseria meningitides
B- H. influenza
C- strep pneuminae
D- C
Ans:

197- After an automobile accident splenectomy done. After two months patient presents to Emergency with septic shock and fever. Causative organism for this overwhelming infection is:
A- Klebsiella
B- Mycoplasma
C- Pseudomonas
D- Staph Aureus
E- Strep Pneumonia
Ans: E

198- A person was walking on grass accidently a thorn pick his foot and it was painful and got swollen likely cause is:
A- E coli
B- Klebsiella
C- Stretococcus
D- Staph aureus
E- Candida
Ans: D

199- Female came from rural area with severe diarrhea with 15-16 episodes in 24 hours this is due to ingesion of :
A- Ascariasis
B- Trichuris
C- Comylobacter
D- Vibrio cholera
Ans: D

200- Cystoscope and endoscope sterilization is done with which of the following
A- Flush the channel with 70-90% ethyl alcohol or isopropyl alcohol
B- Tyndilization
C- Autoclaving
D- Pasteurization
Ans: B

201- A lady was using tampons, she bad TSST syndrome, what's the most important feature in toxic shock syndrome?
A- Skin desquamation,
B- Bacteraemia
C- Cellulitis
D- Anemia
E- Thrombosis
Ans: A

202- In Primary syphilis best specimen for diagnosis
A- Blood
B- Genital sore
C- Lymph node
D- Bone biopsy
Ans: B

203- Brodie's abscess seen in:
A- Pyogenic osteomyelitis
B- Pyogenic arthritis
C- Tuberculous osteomyelitis
D- Tuberculous arthritis
E- Gout
Ans: A

204- CT brain of patient shows cyst with multiple daughter cysts, which of the following is responsible?
A- Loa Loa
B- Taenia solium
C- Trichuris
D- Ankylostoma
E- Ascariasis
Ans: B. Nu option of Echinococus if present prefer it)

Explanation:
- Cyst with daughter cyst in brain by – Tenia Echinococcus
- Neurocysticercosis caused by – Tenia solium

205- Organism in boil of nose:
A- Staphlococcus
B- Streptococcus
C- Pseudomonas
D- Candida
E- Klebsiella
Ans: A

206- For sterilization by Ethylene glycol, time needed
A- 2 to 4 hr
B- 3 to 5 hr
C- 5 to 6 hr
D- 7 to 8 hr
E- 1 to 2 hr
Ans: A

CamScanner

207- A 67-year-old woman with congenital bicuspid aortic valve is admitted to the hospital because of a 2-day history of fever and chills. Current medication is lisinopril. Temperature is 38.0°C (100.4°F), pulse is 90/min, respirations are 20/min, and blood pressure is 110/70 mm Hg. Cardiac examination shows a grade 3/6 systolic murmur that is best heard over the second right intercostal space. Blood culture grows viridans streptococci susceptible to penicillin. In addition to penicillin, an antibiotic synergistic to penicillin is administered that may help shorten the duration of this patient's drug treatment. Which of the following is the most likely mechanism of action of this additional antibiotic on bacteria?

A- Binding to DNA-dependent RNA polymerase
B- Binding to the 30S ribosomal protein
C- Competition with p-aminobenzoic acid
D- Inhibition of dihydrofolate reductase
E- Inhibition of DNA gyrase
Ans: B

Explanation:
Additional antibiotic is Gentamycin which act on 30S ribosomal unit

208- Homosexual male HIV positive has fever, dry cough for week's atypical mycobacteria shown cause is:

A- Mycobacteria tuberculosis
B- S.Aureus
C- M. Scrofulceum
D- M avium intracellulare
Ans: D

209- Antibiotic for bacteriods fragilis is:

A- Cefixime
B- Azithromycin
C- Clindamycin
D- Chloramphenicol
Ans: C

210- Weil disease is caused by

A- Syphlis
B- Chalamydia
C- Gonorrhea
D- Leptospira
Ans: D

211- Chlamydia is the etiological agent for

A- Asbcess
B- Bacterial inclusion conjunctivitis
C- Chancroid
D- Coodyloma latum
E- Lymphogranuloma inguinale
Ans: B

212-Gas gangrene in limb caused by

A- Clostridium biregrengi
B- Clostridium welchii
C- Clostridium defficile
D- Clostridium tetani
Ans: B

213-Rat bite cause fever by toxin

A- Neurolysin
B- Streptobacillus moniliformis
C- Staphloacidus
D- Moniolysin bacillus
Ans: B

214-Function of lactoferrin is

A- Bacterial cell wall syntgesis Inhibitor
B- Inhibit bacterial enzyme
C- Prevent iron utilization by bacteria
D- Prevent glucose utilization
Ans: C

Explanation:
- Prevent iron utilization by bacteria-Lactoferin
- Inhibit bacterial enzyme by-Lactoperoxidase

215- A diabetic patient presented in OPD with oozing greenish discharge from wound. Which of following is causative agent?

A- Bacteriods
B- E.coli
C- Listeria
D- Pseudomonas
E- Klebseila
Ans: D

216- 12 Years old child presented with blood diarrhea. Colonoscopy shows red descending and sigmoid colon. What is the likely cause:

A- Entamoeba
B- C jejuni
C- Vibno cholera
D- Infleunza
Ans: B

217- A patient whose biopsy taken from macular area showing Langerhan cells and multiple necrotic area cause is

A- Histoplasmosis
B- Toxoplasmosis
C- Leprosy
D- Ashestosis
Ans: C

218- Formalin is used in pathology lab for samples because
A- It cause coagulation of protems
B- It cause oxidation of proteins
C- prevent autolysis
D- It cause autolysis
Ans: C

219- Patient presented with UTI culture shows gram -ve orgianism with swarming motility which is the responsible organism?

A- Pseudomonas
B- E.Coli
C- Proteus
D- Klebsiella
E- Staph Aureus
Ans: C

220- Cell wall of gram positive cause septic shock which component of cell wall cause shock?

A- Peptidoglycan
B- Techoic acid
C- Endotoxin
D- Phospholipid A
E- Capsule protein
Ans: A

Explanation:
- Gram Positive cause Shock via Exotoxin and Peptidoglycan
- Gram Negative cause Shock via Endotodxin(LPS)

221- Infectivity of Streptococcus pneumoniae is due to

A- Coagulase
B- Streptolysin
C- Elastase
D- O antigen
Ans: B

222- A procedure which most organism but not spores. Which organism spores are most resistant

A- Staph aureus
B- Comybacterium
C- Clostridium
D- Nisseria
E- Syphlis
Ans: C

223- A girl during menstruation develops high grade fever because she was using tampons, organism responsible is?

A- Staph aureus
B- Staph epidenudis
C- Actinomyces
D- Nisseria
E- Gonorrhea
Ans: A

224- A boy present with sign and symptoms of meningitis. On Examination Organism found is diplococci and Alpha hemolysis seen it is caused by

A- Staph aureus
B- Listeria
C- Ecoli
D- Strep pneumoniae
Ans: D

225- Method of face mask cleaning for prevention against organism is:

A- Steam sterilization
B- Glutaraldehyde
C- Phenol
D- Distal water
E- Lukewarm water
Ans: E

226- Most common organism for pyogenic liver abscess:

A- E.coli
B- Pseudomonas
C- Streptococus
D- Staph aureus
Ans: A

227- A patient develop abdominal tenderness, guarding after fever what is likely cause:

A- Malaria
B- Obstruction
C- Typhoid with intestinal perforation
D- Liver CA
Ans: C

228- A patient having earache . Fever and discharge from ear. Organism that produce fluorescent pigment and resistant to antibiotics and antiseptics disinfectants is

A- Pseudomonas
B- Mycobacterium
C- Treponema
D- Staph aureus
Ans: A

Explanation
- Actinomyces israelii--yellow "sulfur" granules, which are composed of filaments of bacteria
- S aureus--golden yellow pigment
- P aeruginosa--blue-green pigment (pyocyanin and pyoverdine
- Serratia marcescens--red pigment

229- What is the most appropriate way to perform urine culture?

A- CLED agar with 1 ml urine
B- Bacterial dipstick
C- 1ml
D- 10ml
Ans: A

230- Granulomatous lesion in bladder, after few years progressed to carcinoma this is caused by:
A- Tuberculosis
B- Schistosomiasis
C- Acute Cystitis
D- Syphilis
Ans: B (Robins)
Explanation:
• Though both TB and schistosomiasis can cause granulomatous lesion schistosomiasis notorious for SCC of bladder.

231- A young boy with complains of mild fever and pharyngitis, examination shows white membrane that bleeds on removal. Methylene blue stain was positive. What is the most likely cause?
A- E. coli
B- Corynebacterium diptheria
C- Herpes simplex virus
D- Camphylobacter
E- H. influenza
Ans: B

232- Botulinum toxin A and B inhibit release of acetylcholine via
A- SNAP25
B- Inhibiting Ca channel
C- Motor end plate
D- Synaptobrevin
E- Syntaxin
Ans: A

233- Schistosoma causes which of the following?
A- Urinary bladder infection
B- Cardiac issues
C- Liver CA
D- Stomach Cancer
Ans: A
Explanation:
• If asked Schistosoma complication then Splenomegaly.

234- Cold agglutination Pneumonia caused by
A- Legionella
B- Mycoplasma
C- Chalaymydia
D- Gonorhea
E- Staph aureus
Ans: B

235- A patient presented to you with history of high grade fever gram positive diplococci lancet shaped bacterin on gram staining found in his blood most probable cause will be:
A- Strepviridans
B- Listeria
C- Strep pneumoniae
D- E. coli
Ans: C

236- Strep Pneumoniae appears as:
A- Diplococci (Heart Shaped)
B- Cocci in Chain
C- Bacilococci
D- Diplococci (Lancet Shaped)
Ans: D

237- A 46 year old farmer with history of discharge sinus on foot smear show red granules and filaments 1-3 microns. Which is most appropriate?
A- Leptospitosis
B- Coryoea bacterium
C- Medurnla myectoma
D- Actinomyces pelletieri
E- Tuberculosis
Ans: D

238- Common organism for STD is:
A- Ureaplasma urealitycus
B- Chlamydia trachomatis
C- Gonorrhea
D- HPV
E- HSV
Ans: B

239- 12 year old child having fever, Sore throat body ache, cause is:
A- Staph aureus
B- Strep pyogens
C- Strep pneumonia
D- Bacteroides
Ans: B

240- Gas gangrene causes death due to:
A- Fat embolism
B- Fibrinoid nerosis
C- Septicemia
D- Tissuenecrosis
E- Hemorrhage
Ans: C

241- TSST is produced by 15 to 30% strain of?
A- Staph aureus
B- Streptococcus pneumoniae
C- Streptococcus epidemidis
D- Group b streptococcus
Ans: A

242- In Syphilis VDRL diagnosed after:
A- 6 and 12 month
B- 4 month
C- 24 month
D- 36 month
Ans: A

243- Patient presented with fever, neck rigidity, kerning sign +ve, CSF finding reveal decrease glucose, increase protcins and leukocytes 450 mainly lymphocytes diagnose is:
A- Acute pyogenic
B- Viral meningitis
C- TB meningitis
D- Fungal meningitis
Ans: C

244- 19 Year old student comes to you with fever Sore throat and Enlarged tonsils lymphadenopathy from last one week this is
A- Myeloma
B- Malaria
C- Strep pharyngitis
D- Yellow fever
E- TB
Ans: C

245- The most common characteristic sign and symptoms of food poisoning due to clostridium botulinum is:
A- Diarrhea and vomiting
B- Dysentery
C- Fever
D- Projectile vomiting
E- Flaccid paralysis of respiratory muscles
Ans: E

246- A mother has child of 10 year diagnosed with meningitis and now she ask that aoother 2 child 4 and 6 year old are at risk of the meningitis. Tell her the route of spread of infection:
A- Airborn
B- Oral
C- Respiratory droplet
D- Pelvic infection
E- Lung infection
Ans: C

247- Chronic diarrhea not responding to antibiotics crescent shape organism is seen diagnosis:
A- Entamoeba
B- E coli
C- Giardia
D- Botulinium
Ans: C

248- Target tissue of Rickettsia is
A- Bloodcells
B- Muscles cells
C- Nervous tissue
D- Macrophages
E- Skin
Ans: E

249- Fumigation is done in case of:
A- In wards where a patient of plague was admitted
B- 5 confirmed cases of dengue
C- Cardiac surgery O.T where increased incidence of post Op infections reported
D- Measles
Ans: C

250- 85 year old man presented with fever neck stiffness and diagnosed as meningitis which organism is responsible:
A- H influenza
B- Group B streptococcus
C- E.coli
D- Streptococcus pneumoniae
E- Listeria
Ans: D(FA)

251- A Female patient with UTI. Cloudy urine. gram negative rod, having swarming urease positive organism is:
A- E Coli
B- Proteus mirabilus
C- Staph aures
D- Strep saprophyticus
E- Pseudomonas
Ans: B

252- About vibrio cholera true is:
A- Treated by oral antibiotics
B- Treated by parenteral antibiotics
C- Due to drinking of water and food
D- Inflammatory mechanism
Ans: C

253- Diphtheria confirmed by haematologist as early by Morphology in new stain is:
A- Gram Stain
B- Giemsa Stain
C- Bacilli counting
D- Albert's Stain
E- Sudan Stain
Ans: D

CamScanner

254- Most urgent /immediate test for finding bacteria type is:
A- Staining
B- Culture
C- Serum
D- Histopathology
E- CBC
Ans: A

255- Diphtheria toxin causes which of these
A- Affect carbohydrate synthesis
B- Decrease protein synthesis
C- Stimulate TNF synthesis
D- Affect capsule
Ans: B

256- Cell wall of gram negative cause septic shock which component of cell wall cause shock?
A- Peptidoglycan
B- Techoic acid
C- Endotoxin
D- Phospholipid A
E- Capsule protein
Ans: C
Explanation:
- Gram Positive cause Shock via Exotoxin and Peptidoglycan
- Gram Negative cause Shock via Endotoxin(LPS)

257- Sterilization of endoscopic instruments by:
A- Chlorhexidine
B- Autoclaving
C- Glyceraldehyde 2%
D- Pasteurization
Ans: C

258- Method of face mask sterilization for prevention against organism is:
A- Steam sterilization
B- Ethylene oxide gas
C- Phenol
D- Distal water
E- Lukewarm water
Ans: B

259- Which ulcer is caused by infection by microaerophilic non-hemolytic streptococci and aerobic haemolytic staphylococci?
A- Martonel's ulcer
B- Bazin's disease
C- Meleney's ulcer
D- Stress ulcer
Ans: C

260- Woman came with fever, and BP 80/60mmHg. Gram negative rods were identified she goes into shock what is the mechanism of shock in UTI?
A- Neurogenic
B- Septic shock
C- Anaphylactic
D- Hypotensive shock
Ans: B

261- Patient presented with abdominal and pelvic pain upon taking hx IUCD was implanted what causative organism has caused this complication?
A- Actinomycetes
B- Candida
C- Chlamydia
D- Enterococcus faecalis
E- Staph aureus
Ans: A

262- A patient with chronic diarrhoea not responding to gluten free diet .Crescent shaped organisms are seen near brush border. Diagnosis is:
A- Giardiasis
B- Entamoeba Histolytica
C- E. Coli
D- Shigella
Ans: A

263- Eosinophilia with IgE seen in infection of:
A- Staph aureus
B- Aspergillus
C- Mucor
D- Streptococcus
Ans: B

264- Brutons agammaglobulinemia increase the risk of infection of:
A- Fungal
B- Viral
C- Pyogenic
D- None
Ans: C

265- A patient has history contact with multiple sexual partner and develop chancre. He diagnosed as syphilis. How syphilis follow up on?
A- FTA
B- TPR at 4 month
C- VDRL at 6 and 12 month
D- PCR
E- VDRL at 6 month
Ans: C

266- Gram negative bacteria such as shigella have endotoxin in their:
A- Capsule
B- Outer membrane of cell wall
C- Cell wall
D- Cytoplasm
Ans: B

267- Streptococcal diagnosis by other than gram staining by which technique?
A- Serology
B- CBC
C- Electrophoresis
D- Bone marrow biopsy
Ans: A

268- A patient is suffering from ostcomyelitis the most likely organism?
A- Staphylococcus aureus
B- Streptococcus
C- Salmonella
D- E.coli
Ans: A

269- 30 yr. old mate who was treated for meningitis one month back has complaint of morning headache- What is the likely route of spread of meningitis?
A- Blood borne transmission
B- Faecal-oral transmission
C- Vector-borne transmission
D- Airborne transmission
E- Sexual transmission
Ans: D

270- Which is non bleeding ulcer related to streptococcus?
A- Marjolin ulcer
B- Buruli ulcer
C- Arterial ulcer
D- Venous ulcer
E- Meleney ulcer
Ans: E

271- A person presented with pus discharge from surgical site after knee surgery, likely cause is:
A- E. coli
B- Klebsiella
C- Streptococcus
D- Staph aureus
E- Candida
Ans: D

272- Patient has respiratory illness, treated by Erythromycin, organism likely:
A- Staph aureus
B- Streptococcus
C- Mycoplasma
D- Listeria
Ans: C

273- Urethritis, arthritis and conjunctivitis is seen in:
A- Reiter syndrome
B- Pot syndrome
C- Crest syndrome
D- Sjogren syndrome
Ans: A

274- Acute maxillary sinusitis caused by which bacteria?
A- H.influenza
B- Streptococcus pneumoniae
C- Mycoplasma
D- Ureaplasma
Ans: B

275- Conjunctivitis in baby, mother will have?
A- Chlamydia
B- HIV
C- Rubella
D- Mumps
Ans: A

276- In abdominal and gynaecological surgeries which of the following orgaoism causing infection which are penicillin resistant and beta lactamase producing:
A- E coli
B- Streptococcus
C- Bacteroids
D- SA ureus
Ans: C

277- Death due to food poisoning by which organism?
A- Salmonella
B- Corynebacterium
C- Botulism
D- Bacillus
E- Shigella
Ans: C
Explanation:
- Death due to food poisoning - C botulism
- Death due to diarrhoea - Vibrio cholera

278- A patient of Tonsillitis with crypt abscesses Organism will be:
A- Strep pneumonia
B- Staph aureus
C- Pseudomonas
D- H. Influenza
Ans: A

CamScanner

279- Person in infected with staph aurens. What is role of lymphatics in immune resporse?
A- Lymph spreads staph aureus
B- Transport of neutrophils
C- Return of fluid baek to circulation
D- Transport lymphocytes
Ans: C

280- Most common cnuse of bacterial conjunetivitis?
A- N gonorrhoea
B- N meningitis
C- S aureus
D- S pneumonia
E- H influenza
Ans: C

281- Which one is Gram negative but catalase positive?
A- Clostridium
B- Hemophilus influenza
C- Listeria
D- Corynebacterium
Ans: B

282- 6 year old patient having joint pain redness, swelling and fever likely cause is:
A- Ecoli
B- Actinomycetes
C- Staph aureus
D- Streptococcus
Ans: C

283- Organisms which produced Fluoroscent pigment resistant to beta lactam:
A- Pseudomonas
B- Staph aureus
C- Streptococcus
D- Mycobacterium
E- Treponema palladium
Ans: A

284- Spores are resistant due to:
A- Monopicolinic
B- Dipicolinic and capsule thickness
C- Thin Capsule
D- Thin capsule and Tripicolioic
Ans: B

285- Antiseptic for skin surgical gowns:
A- Glutaraldehyde
B- Benzene
C- Chlorhexidine
D- Chloroform
Ans: C

286- A 57 years old patient presented with cough and thick sputum. Causative organism is
A- Pseudomonas aregmosa
B- Candida albican
C- Mycobacterium avium
D- Staphylococcus aures
E- Stieptococcus pneumonia
Ans: E

287- A patient has fever, Neck pain and rash organism responsible for meningitis
A- Neisseria Meningitides
B- Gonorrhoea
C- Staph Aureus
D- Streptococcus Pneumonia
Ans: A

288- The character which distinguishes anthrax **bacillus from other organism is:**
A- Aerobic/Anaerobic growth atmosphere
B- Capsule formation
C- Gram staining
D- Motility
E- Position of spore
Ans: A

289- Organism mostly present in surgery of abdomen and urogenital tract surgery
A- Bacteriodes fragilis
B- Actinobacter
C- Pseudomonas
D- Klebsiella
Ans: A

290- Patient develop diarrhea after autlbiotics use cause is
A- Clostridium bireyrengi
B- Clostridium ngeri
C- Clostridium difficile
D- Clostridium tetani
Ans: C

291- Talcum granules produced by:
A- Staph Aureus
B- Streptococcus
C- Actinomyces
D- Listeria
Ans: C

292- A Female presented with fever, Suprapubic pain & Pus in urine which is treated for 2 Weeks. On Culture, Urease positive organism found growing on chotomagar. Most likely culprit is:
A- Proteus
B- E-Coli
C- Pseudomonas
D- H.Intluenzae
Ans: A

293- A Newborn presented with post pneumonia infection. Sputum with greenish tinge is seen Causative agent is
Pseudomonas
A- E.Coli
B- H.influenzae
C- Streptococcus Pneumoniae
D-
Ans: B

294- When Botulinum, a toxin is used for Blapherospasm and orofascial dyskinesis what's the mechanism of Botulinum ?
Decreases release of Ach from presynaptic
A- NMJ
Increases release of Ach
B- Increase release of serotonin
C- Decrease release of dopamine
D-
Ans: A

295- A sexually active female came with dysuria , urine dipstick and culture shows increased leukocytes , positive nitrates and gram positive organism
A- Candid albicans
B- Staphlococcus Saprophyticus
C- Enterooccus fecalis
D- Compylobacter
Ans: B

296- What is the characteristic of Mycobacteria leprae
A- Opacities
B- Photophibia
C- Acid fast intracellular bacteria
D- Acid fast extracellular bacteria
E- Non acid fast intracellular bacteria
Ans: C

297- Characteristic feature of acid fast Mycobacterium tuberculosis Bacteria
A- Thick wall Mycolic acids
B- Cell wall made of peptidoglycan
C- Capsule
D- Periplasmic space
Ans: A

298- Sterilization is done which kills all except shores , which of the following organisms can still produce infection ?
A- Staph aureus
B- Strep pneumonae
C- Clostridium Tetani
D- Yersinia
E- Compylobacter
Ans: C

299- A child with osteomyelitis. Which is correct regarding osteomyelitis?
A- Most common caused by staph aureus
B- Occurs in children due to h influenza
C- Involves single joint
D- Involved bone degeneration
Ans: A

300- Which one is the microaerophilic organism?
A- Mycoplasma
B- C jejuni
C- Listeria
D- Complylobacter
Ans: D

301- Meningitis in newborn of 48h caused by:
A- Staph aureus
B- Alpha Streptococcus pneumoniae
C- E. Coli
D- H. influenza
Ans: C
Explanation
- Group B streptolysin>Ecoli>Listeria

302- Group A streptococcus related to
A- Streptolysin O
B- Streptolysin S
C- M-Protein
D- S- Protein
Ans: C

303- A mother bring her child who is reluctant to drink water and has muscles spasms. She gave history of nail puncture to his toes what is likely cause
A- Endotoxin
B- Neurotoxin
C- Enterotoxin
D- Pale toxin
Ans: B

304- A 29 Years Old Sexually active female Presented with Complain of Urinary Urgency & Flank Pain. Investigation was carried out & Urine R/E shows Increased Leucocytes & Pus. Which of the following Organism is responsible?
A- S.Saprophyticus
B- S.Aureus
C- Chlymydia
D- Ecoli
Ans: D
Explanation
- E coli is common overall and also in sexually active

CamScanner

305- Gram negative bacteria cause shock via endutuxin present in their:
A- Outer layer of cell wall
B- Ouer layer of Cell membrane
C- Peptidoglycan
D- Cytoplasm
E- Capsule
Ans: A

306- A boy had fever, palpitatiuns, hulitosis nd sore throat O/E there is edematous tonsil with yellow colored uhscess .most likely organism insnlved is?
A- Gtp B streptococus
B- Staph aueus
C- H influenza
D- Pseudomonas
Ans: B

307- Patient is 12 hours postpartum, Having foul smelling lochia & fever. Casuative organism is
A- Bacteroids
B- Group B streptococcus
C- E.coli
D- S.aureus
E- Chlamydia
Ans: B

308- Which of the following is true regarding toxie shock syndrome?
A- Its a misnomer because there is no fever in it
B- Presentation includes skin rashes
C- Caused by pseudomonas
D- Caused by exotoxin
Ans: B

309- Female sexually active having dysuria fever most likely involved organism is gram positive It is
A- Salmonella
B- Gonorrhea
C- Staph aureus
D- S Saprophyticus
E- Pseudomonas
Ans: D
Explanation:
- Most commoo organism for UTI - E coli
- Sexually active and most common organism for UTI - E coli
- Sexually active and Gram negative organism for UTI - E coli
- Sexually active and Gram positive organism for UTI - S saprophytieus

310- Tuetun granules produce by
A- Staph Aureus
B- Streptococcus
C- Actinomyces
D- Listeria
E- Pseudomonas
Ans: C

311- A patient has fever. Neck pain and lower limh rash organism responsible for meningitis is
A- Neisseria Meningitides
B- Gonorrhoea
C- Staph Aureus
D- Streptococcus Pneumonia
Ans: A

312- A person wants to identify Acid fast bacilli .Which feature is unique to acid fast bacilli and helps identify them?
A- Cell wall made of peptidoglycan
B- Capsule
C- Mycolic acids
D- Periplasmic space
Ans: C
better

313- A diabetic patient presented to doctor with abscess on his foot. Pus was drained & was senr to lab for culture & sensitivity. It revealed Gram +ve. Catalase +ve & Coagulase +ve Organism.Growing in Yellow clusters which develops its immunogenicity and protects itself from antibacterial action by:
A- Avoidance of Opsonizarion By protein A
B- Degradation of Complement By protein A
C- Coagulase Positivity
D- IgA protease
E- Outer Capsule
Ans: A

314- Which of the following organism causes meningitis in age of 5 year?
A- Streptococcus pneumonia
B- Staph Aureus
C- E. coli
D- Group B streptococcus
E- H.influenza
Ans: A (FA 2021)

315- A child with osteomyelitis. Which is correct regarding osteomyelitis?
A- Most common caused by staph aureus
B- Occurs in children due to h influenza
C- Involves single Joint
D- Involved bone degeneration
Ans: A

316- Sulphur granules containing organism is:
A- Staph aureus
B- Streptococcus
C- Acunomyces
D- Listeria
E- Nocardia
Ans: C
Better

317- Patient presents with dysuria and burning mieturation. organism is gram positive ,urease hasitive.
A- E.Coli
B- Proteus mirabilis
C- Streptococcus
D- Staphylococcus
E- S. Saprophyticus
Ans: E

318- Best Method used to inoculate Urine For Culture?
A- Iul Uiine drop
B- 2uL Urine drops
C- 20ul Urine drops
D- 100uL urine drops
E- 1 Drop of urine
Ans: C

320- Most common cause of pyogenic lung abscess with yellow sputum is
A- Staph Aureus
B- E.Coli
C- Streptococcus Pneumoniae
D- Klebsiella
E- H influenza
Ans: A
repeated bacterio and resp patho

321- A 5 year old child caught sore throat with a grey white membrane covering the throat. Few days back a child in neighborhood died of same complains. Diphtheria antitoxin given as a treatment option. What is mechanism of actiou of toxin?
A- Macrophage to produce TNF
B- Inhibit protein synthesis
C- Stimulate complement system
D- Transcription
Ans: B

322- A patieut has multiple visits to Far East indulges in sexual activities came to OPD with conjunctivitis gram negative diplococcie was cultured organism is:
A- Strep pneumoniae
B- Nisseria gonnorhoea
C- Staph aureus
D- Chlymydia
Ans: B

323- 30 years G3 iv drug abuser presented with chest pain.O/E, Auscultation reveals dull percussion souads. She is not responding to TB Medications. which organism is responsible?
A- Mycobacterium Tuberculosis
B- Pneumocystis Jiroveci
C- Klebsiella Pneumoniae
D- Atypical mycobacterium
Ans: D

324- A child presented with sorethroat and pseudomembrane oa tonsils. Diphtheria antitoxin given as a treatment option. Which of the followieg represents the mechanism of actioa of diphtheria toxin?
A- Inhibits transcription
B- Inhibits DNA replication
C- Inhibit protein synthesis by Inhibiting E factor 2 that is needed for syothesis
D- Causes cytolysis
E- Inhibits translatioa
Ans: C

325- Diabetic patient with a wound on foot, greenish discharge and fruity smell. taking amoxicillin-clavunatE- But wound does not heal. What organism is not responding to above antibiotics:
A- Pseudomonas
B- S.Aureus
C- S.Pneumoniae
D- Neisseria
E- Klebsiella
Ans: A

326- A 4 Years old child presented with severe profuse watery diarrhea 20 episodes per day & effordess Vomiting from 12 hours. Whar will be the growth of organism in specific media?
A- E-coli
B- Vibrio cholera
C- Celiac disease
D- Giardia Lamia
E- Food poisoning
Ans: B

327- A 70 year old female sitting in wheel chair doing nothing just roaming in home got pneumonia with Copious yellowish sptum died 4 days after getting infection. On autopsy there were neturophils in the alveolai what is eaustive agent
A- Staph aureus
B- Streptococus penumonica
C- Legionella
D- Mycoplasma
Ans: A

CamScanner

328- Female patient present with increased frequency and urgency was diagnosed as UTI case microscopy shows gram negative motile rods urcase positive lactose non fermenting on macconkey agar likely organism involved is:
A- Pseudomonas
B- Compylobacter
C- Proteus merabilis
D- Klebsiella
E- E.coli
Ans: C (F. A)

329- Sbigella causes diarrhea due tu which toxin?
A- Exotoxin
B- Neurotoxin
C- Endotoxia
D- Enterotoxin
E- Verotoxin
Ans: D

330- Female has history of visit to Foreign.Now presented with complain of diarrhea. bruises & rashes on hands & limbs. Cause?
A- Endotoxin
B- Neurotoxin
C- Erythrogenio toxin
D- Toxoid
Ans: C

331- Friedlander pneumonia is primarily caused hy which of the following pathogens?
A- Streptococcus pneumoniae
B- Staphylococcus aureus
C- Klebsiella pneumoniae
D- Haemophilus influenzae
E- Mycobacterium tuberculosis
Ans: C

332- Sexually active young female baving UTI Gynecologist advised urine R/E shows pus cells organism is gram +ve catalase +ve coagulase -ve which organism is involved?
A- Staphylococcus aureus
B- Staphylococcus epidermidis
C- Staphylococcus saprophyticus
D- Streptococcus pyogens
Ans: C

333- Which stain is specifically used to visualize anthrax bacilli and their capsules?
A- Gramstain
B- Ziehl-Neelsen stain
C- M'Fayen stain
D- Wright-Giemsa stain
E- H&E (Hematoxylin and Eosm) stain
Ans: C

334- Toxio produced in scarlet fever:
A Erythrogenic toxin
B Exotoxm
C. Endotoxin
D Invasive
E- TSST
Ans: A

335- A patient presents with a mass in the mandihular region and facial deterioration. Vhich of the following viruses is most commonly associated with these symptoms?
A- Epstein-Barr Virus
B- Adenovirus
C- Herpes Simplex Virus
D- Cytomegalovirus
E- Human Papillomavirus
Ans: A

336 For prevention of trachoma what should be done:
A- Vitamin A supplementation and diet
B- Prophylactic topical antibiotics
C- Sunlight pcevention
D- Washing o f hand and mouth
Ans: D

337- A person came with abcess formation on foot-Staphylococcus aureus was preserved in the tissue. Tissue kept under observation for 24 hour to see the role of lymphatics. Which role lymphatics will play
A- Presentation by antigen-presenting cells (APCs)
B- Site of neutrophil emigration
C- Clearance of edematous fluid
D- Production of antibodies
E- Clearance of debris around vascular tissue
Ans: A

338- A child is diagnosed with Neisseria meningitis, and the parents are concerned about how the infection might spread, as other siblings have also been affected. What is the primary mode of transmission for Neisseria meningitis?
A- Respiratory droplets
B- Fecal-oral route
C- Contaminated food or water
D- Direct skin contact
E- Insect bites
Ans: A

339- Which of the following cerebrospinal fluid (CSF) findings is typically seen in bacterial meningitis?
A- Increased protein
B- Increased glucose
C- Decreased white blood cells
D- Decreased protein
E- Normal glucose
Ans: A

340- Which of the following represents the mechanism of action of diphtheria toxin?
A- Inhibits transcription
B- Inhibits DNA ceplication
C- Inhibit pcotein synthesis by Inhibiting E factor 2 that is needed for synthesis
D- Causes cytolysis
E- Inhibits translation
Ans: C

341- A person is having "ATHLETE'S FOOT") He presents with red,hot & tender foot with red lines Extending up) Organsim involved is:
A- Streptococcus Pyogenes
B- Tinea Pedis
C- Staph Aureus
D- Staph Epidermidis
E- Clostridium Perfiringes
Ans: A

342- Acute bacterial meningitis case with typical picture of increased proteins and neutrophils more than lymphocytes. He was having rash around ankles and signs of meningeal irritation. On the basis of Gram stain, doctor started IV ceftriaxone. what are the results on gram stain?
A- Gram positive diplococci
B. Gram negative diplococci
C- Gram negative rods
D- Gram positive rods
Ans: B(Neisseria Menmgitides)
Explanation:
- Gram ⊖ diplococci.
- The two most important manifestations of disease are meningococcemia and meningitis.
- Meningococcemia typically presents as septic shock, namely, high fever, hypotension, and a petechial or purpuric rash.
- Reference. First Aid & Levinson Microbiology

343- Sterilization involves different kind of techniques. Heating kills all most all of the bacteria present in the medium other than the bacteria that also havespores la their transmission?
A- Clostridium Perfirenges
B- Clostridium Welchi
C- Clostridium Tetani
D- Shigella
Ans: C

344- A patient presents with a painless pealle ulcer with everted margins. If left untreated, the condition may progress to involve the central nervous system. What is the most likely diagnosis?
A- Chancroid
B- Syphilis
C- HPV
O- Kaposi Sarcoma
Ans. B

345- Patient presented with Splinter hemorrhages & painful red nodes on His thumb & index finger. His blood culture is positive & the patient is a known case of I/V drug abuse. Most common cause of infective endocarditis in IV drug abusers with tcieuspid valve involvement is:
A- Strep viridians
B- Staph Aureus
C- Strep epidermis
D- Strep Hemolyticus
Ans: B

346- A 6-month-old infant presents with poor feeding, reduced suck, lethargy, and symmetric muscle weakness after being fed locally sourced hooey a few weeks ago. The infaot is afebrile. Mechanism of action of The organism responsible for these symptoms?
A- Inhibition of Ach
B- Inhibition of GABA
C- Inhibition of Norepinephrine
D- Potentiation of Ach
E- Potentiation of GABA
Ans: A

347- In a patient of Lower limb ulcer, previous history of Diabetic foot. Most common cause
A- Clostridium Perfringes
B- Clostridium tetani
C- Clostridium Botulism
D- Wucheria
Ans: A

CamScanner

348- A patient in the ICU develops diarrhea followlog aotihiotic use. What is the most appropriate diagnostic test for pseudomcmbranous colitis?

A- Stool culture
B- Stool toxin test
C- Blood culture
D- Urine Culture
Ans: B(Lippincott microbiology)

Explanation:

- The enterotoxin can be detected in stool samples using the ELISA test for exotoxins A and B.
- The presence of a pseudomembrane in the colon can be detected by endoscopy

349- A patient presents with History of Epigastric pain along with black tarry stools. On endoscopy, a biopsy reveals a urease- positive organism. What is the most likely cause?

A- H. pylori
B- Proteus
C- Klebsiella
D- Ecoli
Ans: A

350- Sterilisation is the process of killing all bacteria. Spores are not destroyed by simple sterilisation methods. Which one of the following can cause disease through spores?

A- Staph aureus
B- Corynebacterium
C- Clostridium
D- Nisseria
E- Streptococcus pyogenes
Ans: C

351- A new born Present with fever and stiff neck diagnose as a case of meoingiris the organism most likely responsible is

A- H. Influenae
B- Strep Pneumonia
C- Ecoli
D- Listeria monocytogene
E- Nisseria gonorrhea
Ans. C(F.A)

Explanation:
Common causes of meningitis
NEWBORN(0-6M)
Ecoli
Group B Streptococcus
Listeria
Group B streptococcus>Ecoli>listena
CHILDREN(6M-6YR)
S. Pneumonia
N.Meningitidis
Influenza type B
Group B Streptococcus
Enter virus
6-60YR
Streptococcus pneumoniae
Nisseria Meningitidis
Enteroviruses
HSV
60YR+
S.Pneumoniae
N.Menmgitidis
H.Influenza type B
Group B Streptococcus
Enteroviruses

352- TSST is produced by 15 to 20% strains of?

A- Staph aureus
B- Streptococcus pneumoniae
C- Streptococcus epidermidis
D- Group b streptococcus
Ans: A(Levinson microbiology)

Explanation:

- Toxic shock syndrome toxin (TSST) causes toxic shock, especially in tamponusing menstruating women or in individuals with wound infections.
- Toxic shock also occurs in patients with nasal packing used to stop bleeding fromthe nose
- TSST is produced locally by S. aureus inthe vagina, nose, or other infected site. The toxin enters the bloodstream, causing a toxemia. Blood cultures typically do not grow S. aureus.
- Approximately 5% to 25% of isolatesofS aureus carry the gene for TSST

353- A patient presented at 20 weeks of gestation with passage ofgrape like masses, clots and vesicles. What lab finding will be present?

A- Increased AFP
B- Increased CEA
C- Increased Beta HCG >20000
D- Low Beta HCG
E- Inc CA 19.9
Ans: C

Better

354- Diphtheria toxoid most important toxic effect.

A- Myocarditis
B- Larynx
C- Tonsils
D- Larynx
Ans: A

355- An intravenous (IV) drug abuser presents with fever, joint and muscle aches. On examination, Heberden nodes, Bouchard nodes, Osler nodes, and splinter hemorrhages are noted. What is the most common cause of infective endocarditis in such patients, accounting for 50% of cases in IV drug abusers?

A- Strep Viridian
B- Staph Aureus
C- Rheumatoid arthritis
D- Strep hemolyticus
Ans: B

356- Child presents with high grade fever for the past 4 days, swollen, tender and inflamed knees, cytology done which of the following is causative organism

A- Staphylococcus aureus
B- Neisseria gonorrhoea
C- Haemophilus influenzae
D- Streptococcus pyogenes
E- Nisseria mengitidis
Ans: A

357- Young lady went to a fancy restaurant for a dinner. Later in the night, she woke up and has bouts of projectile vomiting and watery diarrhea, what might be the cause of her condition

A- Salamonella paratyphii
B- E Coli
C- Staphylococcus Aureus
D- Clostridium Perfringens
E- Giardiasis
Ans: C

358- A patient with history of Mitral valve transplant 2 months back had Now developed infective endocarditis. Organism responsible?

A- Staph epidermidis
B- S.Viridans
C- S. Aureus
D- S. Bovis
Ans: A

359- Following splenectotny which organism least likely to cause severe septicemia?

A- Meningococcus
B- Neiseria
C- E.Coli
D- Pneumococcus
E- Haemophilus
Ans: C

Explanation:
The order of infection after splenectomy is S.Pneumoniae >> H.Influenza >> N. Meningitidis >> Beta hemolytic Streptococcus >> Staphylococcus Aureus >> Escherichia Coli >> Pseudomonas sp

360- 29 year old lady with expanding ring like rash on forearm, which subsides after 3 days and patient develop facial palsy and neck stiffness.

A- Cocaine abuse
B- Intake of Cephalosporin
C- Deer tic bite
D- SLE
Ans: C(Lippincott microbiology)

Explanation:

- The first stage of Lyme disease begins 3 to 32 days after a tick bite,when a characteristic red, circular lesion with a clear center (erythema chronicum migrans) appears at the site of the bite .Flulike symptoms often accompany the erythema.
- The organism spreads via the lymph or blood to musculoskeletal sites, skin, CNS, heart, and other tissues and organs.
- Weeks to months after the onset, the second stage of the disease begins, with symptoms such as arthritis, arthralgia, cardiac complications, and neurologic complications such as meningitis.
- Months to years later, the third stage begins with the appearance of chronic arthritis and, in a small number of patients, progressive CNS disease

361- In an ICU patient with CVP line in subclavian vein for the past 10 days is on parenteral nutrition. He developed fever, blood culture showed clusters of gram positive cocci the infection is most likely caused by: (Medicine Feb 2025)

A- Coagulase -ve Staph epidermitis
B- Coagulase +ve Streptococcus
C- Pseudomonas
D- Enterococci Fecalis
Ans: A

362- A patient presents with lower respiratory tract infection (LRTI). Gram-negative rods are identified. Which antibiotic should be given? (Medicine Feb 2025)

A- Ciprofloxacin
B- Levofloxacin
C- Amoxicillin
D- Azithromycin
Ans: A

CamScanner

363- A 35 year old male patient with HIV presents with 2 week history of fever, non productive cough and shortness of breath .he is cachectic and reports night sweats and weight loss.his CD4 cell count is <200 and chest x-ray Reveals bilateral diffuse infiltrates what is most likely causative organism for this patient(Medicine Feb 2025)

A- Streptococcus pneumoniae
B- Mycobacterium tuberculosis
C- Pneumocystis jetoveci
D. Staphylococcus aureus
E- Cryptococcus

Ans: C

Explanation:

CD4 count and risk of common HIV-associated diseases

<500cells/mm3	<200cells/mm3	<100cells/mm3
Tuberculosis	Pneumocystis jirovecii pneumonia	Cerebral toxoplasmosis
Bacterial pneumonia	Chronic herpes simplex ulcers	Cryptococcal meningitis
Herpes zoster	Oesophageal candidiasis	Cryptosporidiosis and microsporidiosis
Oropharyngeal candidiasis	Cystoisospora belli diarrhoea	Primary CNS lymphoma
Non-typhoid salmonellosis	HIV wasting syndrome	CMV
Kaposi's sarcoma	HIV-associated dementia	Disseminated mycobacterium avium complex
Non-hodgkin lymphoma	Peripheral neuropathy	Progressive multifocal leucoencephalopathy
HIV-associated idiopathic thrombocytopenic purpura	Endemic mycoses	

364- A Patient presents with constipation and mouth taste change, blood picture shows microcytic hypochromic anemia: (Surgery Feb 2025)

A- Diphyllobothrium lattum
B- Ancylostoma duodenale
C- Entameoba histolytica
D- E.coli
E- Trichuris

Ans: B(Levfoson microbiology)

365- During a medical procedure, a syringe becomes contaminated. What is the appropriate course of action?(Surgery Feb 2025)

A- Sterilize the syringe using an autoclave
B- Clean the syringe with soap and water
C- Replace the syringe with a new, sterile one
D- Use the contaminated syringe to minimize waste

Ans: C

366- A patient with a history of sarcoidosis presents with lung cavitations. Acid-fast staining is negative with HCl (Zenker's solution) but positive with 1% H_2SO_4 (sulfuric acid). Which of the following is the most likely causative organism?(Gynae & Obs Feb 2025)

A- Nocardia asteroides
B- Cryptococcus neoformans
C- Mycobacterium tuberculosis
D- Mycobacterium avium
E- Actinomyces israelii

Ans: E

368- A patient with a Staphylococcus aureus infection is treated with cloxacillin, but the treatment is not effective. What is the most likely reason for the treatment failure? (Gynae & Obs Feb 2025)

A- The bacteria produce beta-lactamase enzyme
B- The bacteria have altered penicillin-binding proteins (PBPs)
C- The patient is not compliant with the treatment regimen
D- The bacteria have no penicillin-binding site in the cell wall
E- The bacteria are resistant to cloxacillin due to genetic mutation

Ans: B

369- Which of the following statements is true regarding Methicillin-resistant Staphylococcus aureus (MRSA)? (Gynae & Obs Feb 2025)

A- MRSA is resistant to all antibiotics
B- MRSA is susceptible to Ciprofloxacin
C- MRSA is susceptible to Vancomycin
D- MRSA is susceptible to all beta-lactam antibiotics
E- MRSA is resistant to Linezolid

Aus: C

370- Female has burning pain during urination. She is diagnosed with having uti. The organism on culture is identified oxidase posilive non lactose fermenting greenish in color and fruity smell.. Drug ugulist this organism?(Radiology Feb 2025)

A- Ciprofloxicin
B- Ceftazidime
C- Ceftriaxone
D- Azithromycin

Ans: B(Pseudomonas)

371- Instruments and packaging materials which cannot be steam sterilized are disinfected using which? (Radiology Feb 2025)

A- Chlorine
B- Phenol
C- Cytylperidinium Chloride
D- Ethylene gas

Ans:

372- Glutaraldehyde is commonly used as a high-level disinfectant in medical settings. At what concentration (%) does it exhibit bactericidal activity?(Anesthesia Feb 2025)

A- 0.5%
B- 1%
C- 2%
D. 1.5%

Ans: C

373- A patient presents with diarrhea caused by Campylobacter jejuni. Which antibiotic is the most appropriate treatment for this infection? (Anesthesia Feb 2025)

A- Penicillin
B- Ciprofloxacin
C- Azithromycin
D- Bismuth

Ans: C

374- A hospitalized patient developed redness and swelling around the IV line. The organism isolated was Catalase-positive and Coagulase-negative. Which toxin or antigen is most relevant? (Anesthesia Feb 2025)

A- Enterotoxin
B- Polysaccharide
C- TSST-1
D- Protein A

Ans: B

375- A patient has a urinary tract infection (UTI) and thickened mucosa of the urinary bladder. What is the primary protective mechanism of the bladder against infections?(Anesthesia & Medicine Feb 2025)

A- Glycocalyx
B- Thickened mucosa
C- Thickened submucosa
D- Urothelial tight junctions

Ans: A

CamScanner

VIROLOGY

1- Nasopharyngeal Carcinoma caused by which organism?
A- HPV
B- CMV
C- EBV
D- HSV
E- Hep. B
Ans: C
Explanation:
- Nasopharyngeal CA – EBV
- Oropharyngeal CA – HPV
- Lung CA - CMV

2- If patient is HIV seropositive what is the best approach?
A- Repeat tests with other methods
B- Correlate with history
C- Isolatehim
D- Declare AIDS
Ans: A

3- Child has papules, rash starting from behind ear and spread to whole body most likely diagnoseis?
A- Mumps
B- HSV
C- HPV
D- Measles
E- Polio
Ans: D

4- A Patient with large B cell lymphoma you will look for antibodies against:
A- CMV
B- EBV
C- HIV
D- HSV
E- HPV
Ans: C

5- Confirmatory test for AIDS in child born to HIV infected mother is
A- PCR
B- Western blot
C- ELISA
D- CD4 cells
E- CD8 cells
Ans: A
Explanation:
- Initial Test- ELISA
- Confirmatory Test -Western Blot
- In children Confirmatory- PCR
- Hall mark of HIV- Proliferation of Virus in T Cell
- Hall mark of AIDS- Progressive Immunodeficiency(Decrease CD4 Count)
- Most common opportunistic infection in- HIV is TB
- Most common opportunistic infection in- AIDS Pneumocystic Jirovoci
- Follow up is done by -CD4 Count
- Progression from asymptomatic to Symptomatic stage can be assessed by PCR

6- Typical Feature of a virus is:
A- Self replicative
B- It has his own DNA and RNA
C- Enveloped coated
D- Has DNA
Ans: A

7- A Patient presented with Cough, coryza, conjunctivitis and koplik spots. Most like orgauisms responsible for this clinical presentation is which among these?
A- Paramyxo Virus
B- Picarna
C- Polyoma virus
D- Orthomyovirus
E- Adeno
Ans: A (Measles)
Explnation:
Parayxo Viruses
- Measles
- Parainfluenza
- Mumpss
- RSV

Orthomyxo Virus
- Influenza Virus

8- Which viral agent causes bronchiectasis in child?
A- EBV
B- CMV
C- Adeno virus
D- RSV
E- HSV
Ans: D

9- A boy whose circumcision had not done presented with glans laceration and rash skin is lixed which Organism is responsible?
A- HPV
B- HSV
C- EBV
D- CMV
Ans: A

10- A women undergoes abdominal surgery 10 years ago now she is diagnose with HCC thought to cause by Hep B. It is said that DNA and RNA viruses are oncogenes which one of the following is caused by RNA virus:
A- EBV
B- HPV
C- HSV
D- T cell leukaemia causing virus
E- Hep E
Ans: D

11- Child at 6 years of age. Bowing of legs was noticed and history of diarrhoea few weeks back. Now the paralysis of right leg Parents give history of incomplete vaccination in the childhood previously:
A- Polio
B- H. influenza
C- Clostridium
D- Nisseria
Ans: A

12- Adult presented with fever, sore throat, posterior cervical node lymadenopathy on peripheral blood smear atypical lymphocytes seen. Which of the following virus is likely being responsible?
A- CMV
B- EBV
C- RSV
D- HSV
E- VZV
Ans: B (Infectious mononucleosis)

13- A female traveled from cold area to juddah having buccal mucosal eruption organsim involved:
A- HSV type 1
B- HHV type 8
C- CMV
D- EBV
E- HPV
Ans: A
Explanation
- HSV - 1 : herpes labialis , keratoconjuctivitis
- HSV - 2 : herpes genitalis

14- Hodgkin's lymphoma with mixed cellularity association with which virus?
A- Parvo virus
B- Adeni virus
C- EBV
D- HPV
Ans: C (FA)

15- Slapped cheek syndrome caused by:
A- Single stranded RNA virus
B- Single stranded DNA virus
C- Ribovirus
D- None
Ans: B (Parvo)
Explanation
- Caused by parvo virus which is DNA Virus

16- A rourist after six weeks of returning from tour came with fever, generalized lymphadenopathy and raised atypical lymphocytes. What is the probable diagnosis?
A- Typhoid
B- HIV seroconversion
C- Dengue
D- Plasmodium falciparum malaria
Ans: B

17- A patient with HIV the confirmatory test:
A- Western blot
B- Elisa
C- Cd4 count
D- PCR
Ans: A

18- A patient presented to doctor with shooting pain on chin doctor prescribe carbamizpine 200 for 3 time daily butt pain is not off after 5 days use of medicine he presented again to doctor with eruption at the site of chin which one of the following is the cause of this condition?
A- HZV
B- Osteomyelitis
C- Trigeminal neuroglia
D- HPV
Ans: A

19- A young girl presented with generalized lymphadenopathy due to which of these
A- AIDS
B- Sarcoidosis
C- Leukemia
D- Asbestosis
Ans: A

20- Most common complication of rubella in 5th week pregnant ladys
A. Cataract
B- Deafness
C- PDA
D- Microcephaly
Ans: A

CamScanner

Explanation:
- Rubella in pregnancy complication overall - Deafness > Cataract
- Rubella in pregnancy complication within 7 weeks – Cataract
- Rubella in pregnancy complication After 7 weeks – Deafness

21- Post splenectomy patient presented with fever, chills, lethargy for the last 5 days. he has returned recently from south Africa. likely diagnosis:
A- Infectious mononucleosis
B- Malaria
C- Typhoid
D- Leishmania
Ans: B

22- A 28- year old woman goes to her physician for a routine examination. the cytopathology report of pap smear indicates the presence of severely dysplastic cells (high grade squamous intraepithelial lesion, or HSIL) A biopsy of the cervix is performed. and on microscopic examination shows cervical intraepithelial neoplasia III (CIN III). Infection with which of the following organisms is most likely to cause her disease?
A- Candida albicans
B- Epstein – Barr virus
C- Gardnerella vaginalis
D- Human papilloma virus
E- Trichomonas vaginalis
Ans: D

23- Which among the following is RNA virus?
A: Mumps
B: HPV
C: Herpes
D: EBV
Ans: A

Explanation:
RNA VIRUSES
- Naked - polio , coxsackie , entero , rhino , hepatitis A virus , astro virus , HEV , norwalk , Rota , Reo
- Enveloped - Rubella , RCV , HGV , Yellow fever, Dengue fever , Lassa fever virus , Corona virus , Hiv 1,2 , HTLV- 1,2 , Influenza. hanta virus , sandyfly fever virus , borna virus , rabies , Ebola virus , Parainfluenza , Mumps , RSV , Rubeola

24- EBV associated with which of following?
A- Bronchogenic Cancer
B- Oropharyngeal Cancer
C- Lymphoma
D- Multiple myeloma
Ans: C

Explanation:
EBV cause
- Lymphoma in AIDS
- Burkitt lymphoma
- Non - hodgkin lymphoma
- Hairy tongue
- Infectious mononucleosis
- Nasopharyngeal carcinoma

25- Pregnant lady fetus develops congenital cataract most likely due to:
A- Rubella
B- CMV
C- EBV
D- HSV
Ans: A

26- Pap smear done for patient most commonly Virus associated with Cervical CA:
A- HPV 16 & 18
B- HPV 8
C- HPV 6
D- HSV
Ans: A

27- DNA virus acting on respiratory system includes:
A- Adenovirus
B- Rhinovirus
C- Resp syncytial virus
D- Influenza virus
Ans: A

Explanation:
- Naked - parvo virus B19 , adeno virus , Papilloma virus, Polyoma virus , BK virus , JC virus
- Enveloped - Hep B virus , VZV , CMV , EBV , HSV 1,2

28- Corona virus was recently named
A- Navel Corona
B- SARS-CoV-2
C- SARS-CoV-1
D- SARS -3
Ans: B

29- Post-transplant patient prone to infection:
A- CMV
B- HBV
C- HIV
D- HAV
Ans: A

Explanation:
- Post-transplant: CMV
- Post transfusion commonest: CMV >HBV
- >HCV

30- Which of the following is Virus related cancer?
A- T Cell Leukemia
B- Renal cell carcinoma
C- Squamous cell carcinoma
D- Diffuse cell carcinoma
Ans: A

31- In viral disease what will Increase
A- Neutrophils
B- Esinophils
C- Lymphocytes
D- Macrophages
Ans: C

Explanation:
- In viral diseases Lymphocytes increases
- In parasitic infecion eosinophils increases
- In bacterial infection neutrophils inreases

32- A child suffering from infection sent his blood for histopathology. There were Warthin Finkeldey giant cells present in slide. The condition is:
A- Rubella
B- Chicken Pox
C- Toxoplasmosis
D- Small Pox
E- Measles
Ans: E

Explanation:
Measles causes
- Warthin - finkeldey giant cells
- Subacute sclerosing panencephalitis

33- In OT procedure alcohol was used for cleansing purpose but the organism was resistant. Which of the following organisms is it?
A- HIV
B- E.Coli
C- Staph Aureus
D- Cryptococcus
Ans: A

34- Condyloma Accuminatum occurs due to
A- HSV
B- HPV
C- Chlamydia Trachomatis
D- Gonococcus
Ans: B

Explanation:
- Intraepithelial lesion on vulva: Paget disease
- Ulcer on Vulva: Condyloma & is caused by HPV

35- EBV is associated with Burkett lymphoma because?
A- It causes defect in DNA repair
B- African with Burkitt lymphoma has Ebv genome 3
C- EBV has toxins
D- Mitochondrial damage
Ans: B

36- Vesicles on vulva are due to:
A- HPV 18
B- Herpes 1
C- Herpes 2
D- Varicella
E- Chlamydia
Ans: C

37- 38 years old HIV positive patient is complaining of headache. On examination neck stiffness is positive fungal meningitis is suspected to be the cause. Which of the following is thought to be the number one cause in HIV/AIDS patient?
A- Aspergillus fumigates
B- Blastomycosis dermatitis's
C- Cryptococcus neoformans
D- Histoplasma capsultum
E- Malassezia furfur
Ans: C

38- Acute laryngotracheobronchitis (Croup) is caused by which of following?
A- Parainfluenza virus type 1
B- Respiratory Syncytial virus
C- Hemophelius
D- Legionella
Ans: A

39- Measles in pregnant lady doctor worried about:
A- TOF
B- Peripheral neuropathy
C- Cataract
D- Anencephaly
E- Cleft plate
Ans: C

40- Measels will cause:
A. Subacute sclerosing pan encephalitis
B. Progressive multifocal leukoencephalopathy
C. Aseptic meningitis
D. Roseola infantum
Ans: A

CamScanner

41- Regarding Poliomyelitis true is
A- Affects anterior horn cells
B- Reaches cns through nerves
C- Affects posterior horn cells
D- Cause common cold
Ans: A

42- Hallmark of HIV disease:
A- Proliferation of virus in T-Cells.
B- Progressive immune deficiency
C- Proliferation of virus inside the B cells
D- None
Ans: A
Explanation:
- HIV - proliferation of virus in T cells
- AIDS - Progressive immune deficiency

43- Regarding HPV:
A. Serotype 16,18, 31 associated with dysplasia and cervical carcinoma
B. Serotype 11 associated with Ca cervix
C. More than 100 genotypes
D. Vaccination effective only after infection
E. Vaccination at 20-23 years age is recommended
Ans: A

44- Reinfection with what causes Fever and Hemorrhagic manifestations:
A- CMV
B- Measals
C- Dengue
D- Mumps
Ans: C

45- School teacher who after death was diagnosed as a case of endocarditis and lymphocytic infiltration of cardiac tissues Cause may be:
A- Bovine endocarditis
B- Viridians
C- Coxsackie virus
D- CMV
Ans: C

46- Watery diarrhea resolve spontaneously witbin one week cause is
A- Giardiasis
B- Vibrio
C- Entamoeba
D- Rotavirus
Ans: D

47- Which is the longest phase of HIV without ANY symptoms
A- Incubation period
B- Acute phase
C- When overt aids converts in active
D- Latent phase
Ans: D

48- Patient known case of Lumbago came with bilateral lung infiltrations. Low neutrophils and Recovered spontaneously after 2 weeks due to
A- TB
B- Streptococcus Pneumonia
C- Influenza A
D- Histoplasmosis
E- Apergillosis
Ans, C

49- Chorio retinitis in AIDS is caused by which of these
A- EBV
B- CMV
C- HepB
D- Gonorrhea
E- Clamydia
Ans. B
Explanation:
CMV causes
- Chorioretinitis in AIDS
- infection in post transplant patients

50- Meningioencephelitis caused by
A- Coxsakie virus
B- Rhino virus
C- Reo virus
D- Rota virus
E- Echovirus
Ans. E

51- Hand foot and mouth disease caused by
A- Coxsackie virus
B- Echo virus
C- Rhino virus
D- Measles virus
E- Parvo virus
Ans A

52- Coxsackie virus causes:
A- Aseptic menmgitis
B- Herpangia
C- Hand foot and mouth disease
D- Myocarditis
E- Pericaarditis
Ans C

53- Which of the following most probably has animal reservoirs?
A- influenza
B- Small pox
C- Measles
D- Mumps
Ans: A

54- Aedes musquitu transmit all except:
A- Yellow fever
B- Dengue haemorrhagic fever
C- Rift valley fever
D- Japanese's virus
Ans: D

55- Least transmitted by blood transfusion
A- Cytomegalovirus
B- EBV
C- HTLV1
D- Parvo virus
E- Hepatitis A
Ans: B

56- HBV not present in
A- Milk
B- Sweat
C- Stool
D- Tears
E- Lymph
Ans: C

57- Kaposi sarcoma Caused by
A- HHV8
B- HHV6
C- HHV 7
D- B19
E- HHV 5
Ans: A
Explanation:
- HHV 8 - Kaposi sarcoma
- HHV 6, HHV 7 - Roseola infantum
- B 19 - Parvo virus
- HHV 5 virus – cytomegalovirus

58- Which is the common hosts of all genetic diseases?
A- RNA
B- tRNA
C- mRNA
D- DNA
E- Nucleotides and Nucleosides
Ans: E

59- Virus increase virulence by
A- Mutating DNA
B- Increase adhesion
C- Resistance to drugs
D- Mutating Cell wall
Ans: A

60- Most common skin cancer in HIV/AIDS patients is:
A- Kaposi sarcoma
B- Hodgkin Lymphoma
C- Basal cell carcinoma
D- Squamous cell carcinoma
E- Multiple Myeloma
Ans: A

61- A warty lesion on vulva in a female due to viral infection is due to?
A- Condylomata
B- Squamous papilloma
C- Paget's disease
D- Lipoma
E- Painless chancre
Ans: A

62- Warty lesion caused by HPV is
A- SCC
B- Squmous papilloma
C- Fibroepithelial polyp
D- Condyloma acuminatum
Ans: D

63- A 22-year-old primigravida has noted no fetal movement at 18 weeks gestation. Fetal ultrasound examination shows marked hydrops fetalis and organomegaly. There is extensive cerebral necrosis and periventricular calcification. Infection with which of the following organisms is most likely to produce these findings?
A- Herpes simplex virus
B- Cytomegalovirus
C- Human immunodeficiency virus
D- Epstein-Barr virus
E- Rubeola
Ans: B

64- A patient presented with fever, Vesicle containing clear fluid how to confirm your diagnose?
A- PCR for iron load
B- Culture
C- Tzank Smear
D. Varicella zoster antigen in Fluid
Ans: C

65- Most common complications of rubella in 7th week pregnant lady:
A- Cataract
B- Deafness
C- PDA
D- Microcephaly
Ans: A
Explanation:
- Rubella in pregnancy complication overall – Deafness > Cataract
- Rubella in pregnancy complication within 7 weeks – Cataract
- Rubella in pregnancy complication After 7 weeks – Deafness

66- Which one is used in HIV?
A- Acyclovir
B- Amantadine
C- Foscarnet
D- Zidovudine
Ans: D

CamScanner

67- Increase Lymphocytes with eosinophilia seen in
A- Bacterial disease
B- Fungal disease
C- Parasitic disease
D- TB
E- Viral Disease
Ans: E

68- HIV infected patient with 300cm3 cd4 cells With respiratory symptoms cause is
A- Pneumocystis
B- Strep pneumonia
C- Mycoplasma
D- Influenza
Ans: A

69- A patient after traasplant develop visual problem and diarrhea on examination cells with basophilic inclusion seem this is due to which of following?
A- HSV
B- HPV
C- EBV
D- CMV
E- Adenovirus
Ans: D

70- HIV positive patient with fever from 4 to 5 days vomiting from 1 day CSF Glucose 80 BSR 110 CSF Protein 45 with no cell raised cause in HIV patient is
A- Tb
B- Streptococci meningitis
C- Bacterial meningitis
D- Herpes Encephlitis
Ans: D

71- COVID 19 recently shows a specie transfer which is named as
A- SARS COVID 1
B- SARSCOV1D2
C- Novel Corona
D- NovelSARS
Ans; B

72- A female presented with caulf flower like lesion in perineum and diagnose of Condyloma Acuminatum made it is caused by
A- HSV1
B- HSV2
C- HPV
D- Gonorrhea
E- Syphlis
Ans: C
Explanation:
- Condyloma Acuminatum - HPV
- Condyloma Latum - Syphilis

73- In viral infection there Is increase.
A- Plasma cells
B- Monocytes
C- Lymphocytes
D- Macrophages
E- Mast cell
Ans: C

74- Which one cause lymphoma with C myc translocation?
A- HSV
B- HPV
C- EBV
D- Adeno virus
Ans: C

75- Burkitt lymphoma cuused by:
A- HSV
B- HPV
C- EBV
D- Adeno virus
Ans: C

76- In HIV patient surgery done then which antiseptic to use after surgery to clean instrument?
A- 2% Glutraldehyde
B- 4% hypochlorite
C- Glutaraldehyde
D- Soap & water
E- Water
Ans: A
Explanation:
Floor – 1% Hypochlorite
Instruments – 2% Glutraldehyde

77- 8 month old bny is brought for assessment.he was born to an HIV Infected mother.the most reliable investigation to conform HIV infection in this infant??
A- HIV P24 antigen test
B- HIV RNA detection by PCR
C- IIIV culture of blood lymphocytes
D- Western blot
E- ELISA
Ans: B

78- A couple who is married from 10 year have no child. Husband had history of Parotid swelling. Which one of following is responsible for this?
A- HSV
B- Measles
C- Mumps
D- HPV
E- Adeno virus
Ans: C

79- Hodgkin lymphoma virus involved:
A- HSV
B- CMV
C- Herpes virus
D- EBV
E- HPV
Ans: D

80- A patient has complain of night blindness and diarrhea there is corneal ulcer Koplik and bitot spots due to deficiency of?
Vitamin E
A- Vitamin B
B- Vitamin C
C- Vitamin D
D- Vitamin A
E
Ans: E

81- Para ventricular calcification (Brain Ventricle), Cardinc defect and Vision defect In child. Mother had suffered from which disease during pregnancy
A- Measles
B- HSV
C- Rubella
D- Chalamydia
Ans: C

82- Best dose for hepatitis b vaccine in nursing staff is:
A- 6, 12 month IV
B- 0, 1 , 6 month IM
C- 8,6. 12 month IM
D- 12, 4 month IM
Ans: B

83- Young boy has Bilateral parotid enlargemeut due to:
A- Bacterial parotitis
B- Mumps
C- Infectious mononucleosis
D- Measles
Ans: B

84- Fumigation after influenza done due to:
A- Increase infection
B- Decrease spread of infection
C- Lack of instruments
D- As it is endemic
Ans: B

85- A patient of HIV having decrease CD4 cell count follow up in this patient is done by:
A- PCR
B- Western blot
C- ELISA
D- CD4 cells
E- CD8 cells
Ans: D

Explanation:
- Initial Test- ELISA
- Confirmatory Test -Western Blot
- In children Confirmatory- PCR
- Hall mark ofHIV- Proliferation of Virus in TCell
- Hall mark of AIDS- Progressive Immunodeficiency(Decrease CD4 Count)
- Most common opportunistic infection in-HIV is TB
- Most common opportunistic infection in-AIDS Pneumocystis jiroveci
- Follow up is done by -CD4 Count
- Progression from asymptomatic to Symptomatic stage can be assessed by PCR

86- Most lethal after liver transplant is
A- CMV
B- HBV
C- HIV
D- HAV
Ans: A

87- Farmer has core antibody positive, surface antigen negative aad surface antibody positive this is:
A- Acute resolving
B- Chronic resolving
C- Recent immunity due to prior infection
D- Vaccinated against Hep B
E- Incubation period
Ans: C

88- What does Hiv do after entering into cell?
A- Leave the cell immediately
B- Copies Its RNA to DNA
C- Remain dominant for some time
D- Activates T cell
Ans: B

89- Pain in mumps transmitted by which nerve:
A- Auriculotemporal nerve
B- Greater auricular
C- Opthalmic nerve
D- Maxillary nerve
Ans: B

90- Patient diagnosed with early Aids What effect be seen in a biopsy of lymph node of patient:
A- Mantle zone proliferation
B- Follicular Hyperplasia
C- Follicular atrophy
D- Hyalinization of germinal centres
Ans: B

CamScanner

91- A lady had pet in a house and had exposure which organism likely to cause symptoms in this lady:
A- E coli
B- Toxoplasmosis
C- Staphaureus
D- Loaloa
Ans: B

92- Painful genital ulcers occur in which of following?
A- Chlamydia
B- Treponema
C- HSV2
D- Nisseria
E- Klebsiella
Aas: C

Explanation:
Painful Genital ulcer
- Bachet disease
- Genital herpes(HSV 2)
- Chanchroid(Haemophilus Ducreyi)

Painless Genital ulcer
- Syphilis(Chancre)
- Lymphogranuloma Venerum(Chlamydia)
- Granuloma inguinale(Klebsiella)
- Painless ulcer +Painful Lymph node – Lymphogranuloma Venerum (Chlamydia)
- Painful ulcer +Painful lymph node -HSV
- Painless ulcer + Painless lymph node – Syphilis

93- HSV virus is transmitted by:
A- Blood
B- Lymph
C- Aerosolized drop or secretion
D- Stool
Ans: C

94- Erythema multiforme is associated with which of the following virus?
A- HSV
B- HPV
C- HIV
D- Adeno virus
Ans: A

95- 1st FDA approved therapy virus is:
A- Adeno virus
B- Picorna virus
C- Paramyxo virus
D- Herpes simplex
Ans: A

96- 64 years old male became disabled and confined to wheel chair then got fever and bilaterally inspiratory rales organism involved?
A- Influenza virus
B- Staph aureus
C- Pseudomonas
D- Proteus
Ans: A

97- In HIV patient lymphoma caused by which organism:
A- HPV
B- CMV
C- EBV
D- HSV
E- Hep. B
Ans: C

98- HIV patient has ulcers in colon cause by:
A- HSV
B- Syphilis
C- CMV
D- EBV
E- Chlamydia
Ans: C

99- HSV 2 causes which of following?
A- CA Cervix
B- CA Endometrium
C- CA Ovary
D- CA Breast
Ans: A

Explanation:
HSV 1 – Herpes labialis, Keratitis and Encephalitis
HSV 2 – Herpes Genitalis and CA Cervix

100- EBV cause which tumor:
A- Infectious mononucleosis
B- Burkitt lymphoma
C- HCC
D- Typhoid
Ans: B

101- Which is type of Hodgkin lymphoma with EBV:
A- Lymphocyte rich
B- Lymohcyte depleted
C- Nodular hodgkin lymphoma
D- None
Ans: C

102- A baby has jaw lesion it is caused by:
A- CMV
B- Adeno virus
C- EBV
D- Polio
Ans: C

103- Adult genital lesion under microscope show squamous papilloma causative organism is:
Herpes simplex
A- Herpes zoster
B- Human papilloma virus
C- CMV
D- Adeno virus
E-
Ans: C

104- A woman with 5 weeks of pregnancy contracted German measles. She consulted her obstetrician worrying about the baby which is the most likely complication the baby might develop?
A- Aortopulmonary septal defect
B- Congenital cataract
C- Deafness
D- Spina bifida
E- Mental retardation
Ans: B

Explanation:
- Rubella in pregnancy complication overall – Deafness > Cataract
- Rubella in pregnancy complication within 5- 6 weeks – Heart defect
- Rubella in pregnancy complication within 7 weeks – Cataract
- Rubella in pregnancy complication after 7 weeks – Deafness

105- Patient developed cirrbosis few years after abdominal surgery, keeping in view viral etiology, what is the feature?
A- Non enveloped, single stranded RNA virus with reverse transcriptase
B- Enveloped, single stranded RNA virus with reverse transcriptase
C- Enveloped, Double stranded RNA virus with reverse transcriptase
D- Double stranded RNA virus
Ans: B

106- Burkitt lymphoma is caused by EBV due to:
A- Interfere DNA repair
B- Produce toxin against DNA
C- Produce mitochondrial toxins
D- Antibody to viral capsid
E- Common in African
Ans: E

107- CMV spreads through?
A- Sexual contact
B- Blood transfusion
C- Mother to child
D- Saliva
E- Trans placental
Ans: D

108- A man who is taxi driver in UAE for 3 years, has now returned to Pakistan working and presented with C/O fever, weight loss, anorexia, diarrhoea, splenomegaly. He is emaciated, has jaundice and Generalized Lymphadenopathy. What is the diagnosis:
A- AIDS
B- Leishmaniasis
C- Yellow fever
D- Dengue Fever
Ans: A

Explanation:
- The symptoms & the abroad history with findings are suggestive of AIDs

109- Most common skin cancer in homosexual male partners is:
A- Kaposi sarcoma
B- Hodgkin Lymphoma
C- Basal cell carcinoma
D- Squamous cell carcinoma
E- Multiple Myeloma
Ans: A

110- HIV affects which of following cells?
A- Helper T cell
B- Cytotoxic T cell
C- NK cells
D- Cd8 cells
E- Eosinophil
Ans: A

111- 2 days baby developed rash over her extremities, mother has contracted infection during pregnancy. Which organism is transmitted vaginally?
A- HPV
B- Influenza
C- HSV
D- Adeno virus
Ans: C

112- Pregnant lady develop initial infection with fever and rash then develop hemorrhagic signs this is:
A- Dengue Fever
B- HSV infection
C- Ebola infection
D- Malaria
Ans: A

CamScanner

113- Baby has rash and slapped cheeks caused by virus having structure:
A- Enveloped RNA virus
B- Double stranded DNA virus
C- Single stranded enveloped virus
D- Single stranded negative DNA virus
E- Single stranded positive DNA
Ans: D (Parvo virus)

114- In pathogenesis of HIV AIDS what is is affected
A- Decrease NK cells
B- Decrease CD 4 + Helper T cells
C- Decrease CD 8 + Cytotoxic cells
D- Decrease macrophages
Ans: B

115- Patient having Vesicular rash on palms soles With Blistering lesions on Tongue & Gums. Which of the following is true about virus causing this disease?
A- Enveloped Positive Sense RNA with reverse transcriptase
B- Naked Positive Sense RNA
C- Enveloped Single stranded DNA
D- Enveloped Positive Sense RNA
Ans: B(Coxsackie virus)

116- A sexually active person develop Oropharyngeal carcinoma . Most likely virus related is
A- HIV
B- EBV
C- HPV
D- Adeno
E- HSV
Ans: C
Explanation:
- Nasopharyngeal CA – EBV
- Oropharyngeal CA – HPV
- Lung CA – CMV

117- EBV can be best detected by
A- Activated T lymphocytes
B- Activated B lymphocytes
C- Ebv in infected cells
D- Infected T lymphocytes
Ans: A
Explanation:
- Infected cells- B cells
- Activated atypical cells- T cells

118- A patient of HIV presented with some purple rash on forearm cause is
A- HPV
B- HSV
C- EBV
D- HHV8
E- HHV2
Ans: D

119- HPV is non enveloped DNA virus which has different serotypes. Which serotype is responsible for cervical cancer?
A- HPV 16,18
B- HPV 6,8
C- HPV 3,4
D- HPV 5, 6
Ans: A

120- Newborn presents with bilateral cataract and low birth weight. Which of the following causes these symptoms:
A- Rubella
B- CMV
C- Toxoplasma Gondii
D- Syphilis
E- Neisseria Gonorrhea
Ans: A

121- Patient having Vesicular rash on palms soles With Blistering lesions on Tongue & Gums. Which of the following is true about virus causing this disease?
A- Enveloped Positive Sense RNA with reverse transcriptase
B- Naked Positive Sense RNA
C- Enveloped Single stranded DNA
D- Enveloped Positive Sense RNA
Ans: B(Coxsackie virus)

121- Baby has rash and slapped cheeks caused by virus having structure
A- Enveloped RNA virus
B- Double stranded DNA virus
C- Single stranded enveloped virus
D- Single stranded negative DNA virus
E- Single stranded positive DNA
Ans: D (Parvo virus)

122- A 22-year-old primigravida has noted no fetal movement at 18 weeks Gestation. Fetal ultrasound examination shows marked hydrops fetalis and organomegaly. There is extensive cerebral necrosis and periventricular calcification. Infection with which of the following organisms is most likely to produce these findings?
A- Herpes simplex virus
B- Cytomegalo virus
C- Human immunodeficiency virus
D- Epstein-Barr virus
E- Rubeola
Ans: B

123- A sexually active person develop Oropharyngeal carcinoma. Most likely virus related is
A- HIV
B- EBV
C- HPV
D- Adeno
E- HSV
Ans: C
Explanation:
- Nasopharyngeal CA – EBV
- Oropharyngeal CA – HPV
- Lung CA – CMV
-

124- EBV can be best detected by
A- Activated T lymphocytes
B- Activated B lymphocytes
C- Ebv in infected cells
D- Infected T lymphocytes
Ans: A
Explanation:
- Infected cells- B cells
- Activated atypical cells- T cells

125- A patient presented with sore throat, submental swelling and testicular involvement. Other 2 boys had same history what could be the cause
A- HSV
B- Influenza
C- Mumps
D- Chlymydia
Ans: C

126- 8 year Old girl presented with facial pain and mass in mandible which organism related to this most likely?
A- HTLI
B- HIV
C- HHV8
D- EBV
Ans: D

127- A patient came with complaint of red raised painless lesion on forearm which increased in size within 3 months, he has diarrhea for few days and lymphadenopathy and oral thrush. Which virus causes these skin lesions?
A- HIV
B- Candida
C- HHV-8
D- CMV
E- Rubella
Ans: C

128- A patient came with complaint of red raised painless lesion on forearm which increased in size within 3 months, he has diarrhea for few days and lymphadenopathy and oral thrush. Which virus causes these skin lesions?
A- HIV
B- Candida
C- HHV-8
D- CMV
E- Rubella
Ans: C

129- What does HIV does after entry into cell?
A- Forms a provirus
B- Double RNA
C- Converts RNA to DNA
D- Remain latent
Ans: C

130- Which of the following organisms is commonly associated with erythema multiforme?
A- Herpes Simplex Virus
B- Human Papilloma virus
C- Varicella-Zoster Virus
D- Cytomegalovirus (CMV)
E- HIV
Ans: A

131- Patient Immunocompromised Received a transplant. Which of the following is most lethal for causing infections post transplant?
A- CMV causing Pneumonia & death
B- Kaposi Sarcoma
C- Streptococcal Pneumoniae
D- Burkitt Lymphoma
Ans: A

132- A mother brings her son to the clinic with complaints of a barking cough. What is the most likely area affected?
A- Upper trachea
B- Larynx
C- Carina of the trachea
D- Bronchi
Ans: B

CamScanner

133- A newborn has history of Acquired Coagenital Infection from mother. He has presented with Jaundice & Microcephaly. Torch screening positive. Periventricular infections along with cerebral necrosis noted on CT scan. Infection with which of the following organism is most likely to produce these findings?
A- Herpes simplex virus
B- Cytomegalo virus
C- Human immunodeficiency virus
D- Syphilis
E- Rubella
Ans: B

134- A child presents with a history of a rash that started on the trunk and has a "dew drop on a rose petal" appearance. What is the most likely diagnosis?
A- Varicella Zoster Virus (VZV)
B- HHV6
C- Measles
D- HHV8
Ans: A

135- In infectious mononucleosis, which organ is most prone to rupture after minor trauma?
A- Spleen
B- Liver
C- Kidney
D- Stomach
Ans: A
Explanation:
- Infectious mononucleosis, caused by Epstein- Barr Virus (EBV), leads to splenomegaly (enlargement of the spleen) in many patients.
- The spleen becomes fragile and is at increased risk of rupture, even with minor trauma, due to its vascular nature and thin capsule

136- Patient presented with watery discharge from Eye. On slit lamp examination Dendritic nicer present in Eye. Most likely diagnosis?
A- Viral Keratitis
B- Bacterial Keratitis
C- Fungal Keratitis
D- Amoebic Keratitis
Ans: A
Explanation:
- The presence of a dendritic ulcer in the eye is a hallmark feature of viral keratitis, specifically herpes simplex virus (HSV) keratitis.
- HSV typically causes dendritic ulcers, which are branching lesions seen on fluorescein staining during slit-lamp examination.
- Symptoms include watery discharge, photophobia, and pain.

137- 40 year old male patient present to OPD with Multiple painless lesions on the penis.the lesions were small, raised and papilloma-like which of the following is the causative organism
A- HPV
B- HSV1
C- Cytomegalovirus
D- Syphylis
E- Chlamydia
Ans: A

138- Patient with fever, cervical lymphadenopathy and lymphocytosis. Investigation of Choice:
A- EBV titre
B- Blood Culture
C- Throat Culture
D- Urine Culture
Ans: A

139- Virus transmitted by mosquito?
A- Dengue
B- Congo
C- Ascariasis
D- Schistosomiasis
E- Malaria
Ans: A

140- Reye's syndrome is most commonly associated with which virus?(Medicine Feb 2025)
A- Influenza virus
B- Hepatitis B virus
C- HIV
D- Cytomegalovirus (CMV)
Ans: A

141- Drug effective in HIV is:(Medicine Feb 2025)
A- Abacavir
B- Lamivudine
C- Zidovudine
D- Amantadine
Ans: C

142- Hepatitis B virus (HBV) primarily leads to liver damage through which of the following mechanisms?(Surgery Feb 2025)
A- Apoptosis
B- Direct cytopathic effect
C- Oxidative stress
D- Immune-mediated membrane damage
Ans: D

143- A male patient present in OPD with complain of infertility gives a history of swelling at the jaw and testicular infection the most likely cause is(Surgery Feb 2025)
A- Measles
B- Mumps
C- Rubella
D- Chicken pox
E- EBV
Ans: B

144- A patient of HIV presented with some purple rash on forearm cause is (Surgery Feb 2025)
A- HPV
B- HSV
C- EBV
D- HHV 8
E- HHV 2
Ans: D

145- Lymphoma in AIDS patient is caused by which virus(Surgery Feb 2025)
A- CMV
B- EBV
C- HSV
D- HHV 8
E- HPV
Ans: B

146- Which of the following organisms contain either DNA or RNA, but never both?(Anesthesia Feb 2025)
A- Viruses
B- Bacteria
C- Fungi
D- Molds
E- Yeast
Ans: A

147- Patient with AIDs presented with respiratory symptoms. Drug given what does the drug inhibits?(Anesthesia Feb 2025)
A- Protein synthesis
B- Cell wall synthesis
C- DNA synthesis
D- RNA synthesis
Ans: C

CamScanner

MYCOLOGY

1. Most common opportunistic infection in patient with HIV?
A- Cryptococcus neoformis
B- CMV
C- Candida
D- HSV
E- Haemophilus
Ans: C

2. Chronic fungal infection with rhinosinusitis causing medial erosion and granulomas is by
A- Cryptococcus
B- Mucormycosis
C- Rhinopjycomycosis
D- Hiatoplasmosis
E- Aspergillus
Ans: E

3- Child prone to systemic candidiasis:
A- Antibiotic Use
B- Hospilalization
C- Immunosuppressant
D- Viral infection
Ans: C

4- This AIDS opportunist mostly causes diarrhea is
A- Coccidioides immitis
B- Cryptococcus
C- Cryptosporidia
D- Histolasma
E- Toxoplasma
Ans: C

5- During 3rd trimester of pregnancy,vaginal infection usually occurs with following organism:
A- E. coli
B- Chlamydia
C- Candida albicans
D- Trichomonas
Ans: C

6- One of the following fungus acts by involvement of the Reticuloendothelial system:
A- Histoplasma
B- Blastomycosis
C- Cryptococcus
D- Candida
Ans: A

7- A farmer with SOB came to clinic. On CXR, physician found coin lesion. What could be the cause?
A- Thypoid
B- Klebsella
C- Aspergillus
D- Viridans
Ans. C

8- A female of 34 years old came with complain of high blood sugar level, shortness of breath and fruity odor smell. Diabetic ketoacidosis is associated with which of the following infection?
A- Aspergillosis
B- Mucor
C- S. Aureus
D- H. influenza
Ans. B

9- The serology test for aspergillus?
A- Galactosidace.
B- Galactomann
C- Galactoprotein
D- Phospholipid
Ans: B

10- HIV patient presented with fever neck rigidity and meningeal irritation, Bolo seen around the organism involving the brain tissue What is likely cause
A- Cryptococcus Neoformans
B- Candida Albicans
C- Staph Aureus
D- Chlamydia
E- Gonorrhea
Ans: A(FA)

11- Patient is having rhinoinusitis and nasal polyp with the fungus invading lamina papyracea, excessive endothelial damage and having non septate hyphae organism involved is:
A- Candida
B- Histoplasmosis
C- Aspergillus
D- Mucor
E- Rhizopus
Ans: D (FA)

12- Person with difficulty in swallowing, there was some white growth inside esophagus with psuedohyphae likely reason is:
A- Candidiasis
B- Aspergillosis
C- Histoplasmosis
D- Mucor
E- Rhizopus
Ans: A (FA)

Explanation:
Mucor and Rhizopus
- Diabetic (DKA) and Neutropenic (Leukemia)
- Rhinosinusitis
- Non septate hyphae branch at wide angle
- Invade blood vessel

Aspergillus
- Non diabetic
- Immuno compromised and neutrophilic dysfunction (CGD)
- Rhinosinusitis
- Septate hyphae branch at acute angle

Candida
- Diamorphic
- Pseudohyphae

Cryptococus
- Not Diamorphic
- 5-10 um narrow budding
- Brain meningitis and Encephlitis(Soap bubble lesion) in immunocompromised

Histoplasmosis
- Reticuloendothelial Syste

13- Granuloma with suppuration caused by
A- Nocardia fungus
B- Aspergillus
C- Amoeba
D- Virus
Ans: A

14- A young male with h/o athlete's foot (right side) presents now with right foot and leg red, hot to touch and painful. He is febrile and has inguinal lympadenopnthy. Indurated lines that are spreading up cause is:
A- Stap epidennidis
B- Strep pyogens
C- Tenia pedis
D- Staph aureus
E- C. Perfringes
Ans: B

15- 70 years old man with renal transplant 2 years back, now presented with complicated pneumonia not responding to antibiotics. Bronchoalvealar lavage shows boat shaped cyst. The organism causing the condition is:
A- Pneumocystic jiroveci
B- Candida albicans
C- Mycoplasma tuberculosis
D- Treponema pallidum
Ans: A

16- Organism involved in oral tiarush:
A- Chlamydia
B- Aspergillus
C- Rhizopus
D- Candida
Ans: D

17: Cryptococcus neoformans can be visualized by:
A- Giemsastain
B- Periodic Acid Schiff
C- Ziehl Neelsen stain
D- Indian ink stain
E- Silver stain
Ans: D

18- A patient having 15 cm mass fixed compact granuloma without necrosis cause is
A- Tb
B- Sarcoidosis
C- Mesothelioma
D- Aspergillosis
Ans: D

19- Most common fungal infection in HIV AIDS is
A- Chlamydia
B- Candida
C- Rubella
D- Bacterial vaginosis
Ans: B

20- The yeast species that are resistant to echinocandins are?
A- Candida albicans
B- Candida krusi
C- Candida auris
D- Aspergillus
Ans: C

CamScanner

21- Whitish Discharge from Vagina caused by:
A- Trichomonas
B- Candida
C- Gonorrhea
D- Syphilis
E- Pseudomonas
Ans: B

22- A non-diabetic female having chronic rhinosinusitis develop fungal infection that shows septate hyphae at acute angle and producing respiratory symptoms most likely fungus is:
A- Candida
B- Histoplasmosis
C- Aspergillus
D- Mucor
E- Rhizopus
Ans: C(FA)

23- 9 years old boy admitted for surgery complain of dry mouth, examination shows white patches on mouth, difficult to eat and swallow what should be treatment?
A- Griseofulvin
B- Nystatin
C- Miconazole
D- Doxycycline
Ans: C

24- The yeast species that are resistaot to echinocandins are?(Medicine & Gynae Feb 2025)
A- Candida albicans
B- Candida kruzi
C- Mucormycosis
D- Aspergillus
Ans: B

25- A patient with Hodgkin lymphoma develops a fungal infection on lumbar puncture (LP). Which fungal pathogen is most likely?(Surgery Feb 2025)
A- Candida
B- Cryptococcus
C- Mucor
D- Aspergillus
Ans: B

26- Germ tube test posilive by which fungal species(Radiology Feb 2025)
A- Candida albicans
B- Candida auris
C- Candida glabrata
D- Candida tropicalis
Ans: A

PARASITOLOGY

1- Patient presented with paroxysmal fever, chills and time duration for symptoms appearing was 36 to 48 hours ring and crescent shaped organism involved likely is
A- P.Vivax
B- P. knowlesi
C- P.Falciparum
D- P.Malaria
E- Dengue
Ans: C

Explanation
Crescent shaped organism – plasmodium falciparum

2- 5 years old child presents with rectal prolapse, organism responsible is:
A- Ascaris
B- Ancylostoma duodenale
C- Trichuris trichura
D- Giardia lambdia
E- Entamoeba
Ans: C(FA)

Explanation:
- Rectal Prolapse – Trichuris Tricbura
- Muscle(Myalgia) – Trichinella Spiralis
- Respiratory Symptoms – Ascaris
- Fisberman With Anemia + Echymosis – Vitamic C deficiency
- Fisherman With Anemia – B12 Deficiency – Diphyllobothrium
- Microcytic Anemia – Ankylostoma
- Conjuctival Swelling – Loa Loa

3- A patient with abdominal pain, sudden headache, fever and chills. He is also having splenomegalay and hepatomegalay organism responsible for this is geimsa stuin positive. Which organism is most likely?
A- Kala Azar
B- Schistosomiosis
C- Plasmodium Falciparum
D- Cryptococcus
E- Entameba
Ans: C

4- Squamous cell CA diagnosed in a person who came from Dubai and presented with painless hematuria likely organisms associated with disease is:
A- E. coli
B- Schistosoma hemobatium
C- S aunues
D- Nessieria
E- Streptococus
Ans: B

5- Fisher man preseuls with complain of weakness and early fatigue. He use to have only fish and rice in his diet. His baselines show Hb 7.8gm, MCV 105. What could be the likely cause?
A- Diphyllobothrium latum
B- Ancylostoma duodenale
C- Entameoba histolytica
D- E.coli
E- Trieburis
Ans: A

Explanation:
- Fisherman with aoemia + Ecbymosis – Vitamin C deficiency
- Fisberman with Anemia +Raised MCV – B12 Deficiency – Diphyllobothrium.

6- Patient was having altered taste e microcytic hypocbromic anemia, stool test showed eggs wbich organism is responsible?
A- Entamoeba histolytica
B- Ancylostoma duodenale
C- Trichurius trichuria
D- LoaLoa
E- Trichinella
Ans: B(FA)

7- An is the intermediate host for which of the following?
A- Hook worm
B- Beep tape worm
C- Hydatid cyst disease
D- Filariasis
E- Trichomoniasis
Ans: C

8- 20 years young boy presented with fever, headache vomiting. He is having neck stiffness and Alter mental status with hallucination which among following is brain eating ?
A- Naglelia fowleri
B- Entamoeba histolytica
C- Falciform malaria
D- Histoplasmosis
E- Mucormycosis
Aos: A

9- In Hookworm infection, the microscopic feature present on peripheral blood slides will be?
A- Eosinophilic chemotactic factor
B- Spectacle shaped bilobed nuclei
C- LTB chemoreceptors factor IgE in membrane
D- Pink cytoplasmic granules
E- Basophilia
Ans: B

CamScanner

10- Pinworm is caused by:
A- Ingestion of larva
B- Ingestion of egg of larva
C- Ingestion of worm
D- None
Ans: B

11- Which of the followings spread by mosquito bite:
A- Leishmeniasis
B- Filariasis
C- Ascariasis
D- Schistosomiasis
Ans: B

12- Which of the following cells are found in parasitic infection?
A- Basophils
B- Eosinophils
C- Neutrophils
D- MastCells
Ans: B

Explanation:
- Parasitic – Esinophils
- Bacterial – Neutrophills
- Viral - Lymphocytes

13- A soldier presented with 3 months history of fever, bilateral lymphadenopathy, epatosplenomegaly, anemia, fatigue & H/O of sleeping on floor and bitten by some fly, diagnosis:
A- Kala Azar
B- Malaria
C- CML
D- Filariasis
Ans: A

14- Cola color urine is seen in which of the following:
A- P.Vivax
B- P.Malaria
C- P.Faciparum
D- P.Ovale
Ans: C

15- Which of the followiog drugs is recommended for the treatment of severe, multidrug resistant falciparum malaria?
A- Artemisinin
B- Chloroquine
C- Quinine
D- Sodium stiboglucoonate
E- Primaquine
Ans: A

16- A farmer presented with migrating linear lesion on foot:
A- Cutanea larva migrans
B- Discoid lupus
C- Lichen planus
D- Melanoma
Ans: A

17- Pregnant lady having cat as a pet is at risk of:
A- Toxoplasmosis
B- Syphilis
C- Gonorrhea
D- Chlamydia
Ans: A

18- A patient with yellowish vaginal discharge & motile trophozite:
A- Gonorrhea
B- Trichomonas Vaginalis
C- HPV
D- HSV
Ans: B

19- Toxoplasmosis is?
A- Parasite
B- Helmintb
C- Virus
D- Bacteria
Ans: A

20- Plasmodium falciparum is:
A- Unicellular Amoeba
B- Cyst
C- Schizoid
D- Ciliate
E- Flagellum
Ans: A

21- Dormant stage of malaria:
A- Egg
B- Cyst
C- Sporozyte
D- Hypnozoite
Ans: D

Explanation:
- Dormant phase of malaria -- Hypnozoite
- Malaria enter into human body as – Sporozoite
- Sporozoite divide in liver as – Merozoite

22- Most sensitive test for amuebic Abscess is
A- CT scan
B- Stool test
C- Serology (hemagglutinin)
D- Urine examination
Ans: C

Explanation:
- Amoebic abscess – serology
- pyogenic liver abscess – US abdomen , raise alkaline phosphate
- Hydatid liver disease – indirect agglutination test (most accurate) , Ct scan (investigation of choice)

23- Malignant tertian malaria cause
A- P. falciparum
B- P. vivax
C- P. ovale
D- P. malariae
Ans: A

24- P falciparum features:
A- Black water fever
B- Jaundice
C- Fever
D- Nausea
Ans: A

25- 29 year old went remote area develop mild watery diarrhoea for 1 wk.no occult blood are resolved after 2 weeks courses:
A- Amoeba
B- Vibrio
C- Rota
D- Shigella
E- Giardia
Ans: C

26- Malaria is associated with?
A- Lymphocytosis
B- Hemolytic anemia
C- Thrombocytosis
D- Rheumatic fever
Ans: B

27- 2-year Boy from AZAD kashmir with failure to thrive for 6 month comes with Hepatosplenomegaly and pallur, plus pancytopenia and ESR 80, dx:
A- Visceral Lesihmaniasis
B- Gaucher disease
C- ALL
D- Liver abscess
Ans: A

28- Infant diagnosed to have worm infestation physician done CBC which of the following will confirm the diagnosis?
A- Eosinophilm
B- Iron deficiency anemia
C- Increase WBC coun
D- Neutrophillia
Ans: A

29- Brucellosis is transmitted by:
A- Mantoman
B- Raw milk
C- Raw fish
D- Fleas
Ans: B

30- Rectal biopsy done. How to diagnose amoeba infection?
A- Electron microscopy
B- PAS
C- Antibodies
D- Gram staining
Ans. B

31- A patient with dyspnea fatigue dysphagia and stool contains egg and labs shows HB on 6mg/dl what is the cause?
A- Hook worm
B- Amoeba
C- Pinworm
D- Trichins tichiurea
Ans. A

32- Pear shaped eggs and causing diarrhea belong to
A- Giardia
B- Amoeba
C- Malaria
D- Aspergillus
Ans. A

33- Longest pro erythrocytic phase is:
A- P. falciparum
B- P. Malaria
C- P. Ovale
D- P. vivax
Ans: B

Explanation:
- Shortest pre-erythrocytic phase is seen in – Plasmodium Falciparum.
- Longest pre-erythrocytic phase is in – Plasmodium Malariae

34- Patient after ingesting some eggs of worms now presents with respiratory symptoms, organism most likely is:
A- Ascaris
B- Ancylostoma Duodenale
C- Diphyllobothrium latum
D- Taenia solium
Ans: A

35- A lady has ring like lesions, rashes on forearm. Which one of the following is responsible?
A- Deeruck
B- Dogbite
C- Mosquito
D- SLE
E- Sjogren
Ans: A

CamScanner

36- Which of following spreads by eating raw and uncooked meat?
A- Tapeworm
B- Enterococcus granulosus
C- Amoeba
D- Ascarias
E- Trichuris
Ans: A (FA)

37- Parasite rate in blood is calculated in which age
A- Neonates
B- Below 5 years
C- 4 to 15 years
D- 2 years
E- 6months
Ans: B

38- Asian Cholangiohepatitis is caused by which of the following?
A- Clonorchis Sinensis
B- E. Coli
C- Hematobium
D- HIV
E- HSV
Ans: A

39- A patient presented with high grade fever, with rigor and chills for 2days, 105 Pulse. Bp 110/ 80, dark color urine likely cause is
A- Cerebral Malaria
B- Typhoid
C- Polio
D- Leishmaniasis
E- Kala azar
Ans: A

40-A middle-aged man living nearby river gets blind due to:
A- Chlamydia trachomatis
B- Wuchereria bancrofti
C- Onchocerca volvulus
D- Loa loa
E- scaris lumbricoides
Ans: C(FA)

41- Treatment of Plasmodium vivax is:
A- Mefloquinone
B- Chlorquinine
C- Azithromycin
D- Praziquental
Ans: B

42- CT brain of patient shows cyst with multiple daughter cysts, which of the followiog is responsible:
A- Taenia echinococcus
B- Taenia solium
C- Trichuris
D- Ankylostoma
E- Ascariasis
Ans: A

Explanation:
- Cyst with daughter cyst in brain by - Taenia Echinococcus
- Neurocysticercosis caused by - Taenia solium

43- Parasites live in which of the following system:
A- Urinary
B- GIT
C- Renal
D- Lymphatics
E- Venous
Ans: D

44- DOC of tapeworm:
A- Albendazol
B- Mebendazol
C- Niclosamide
D- Metronidazole
Ans: C

45- A young group of boys living in daycare service, all of them are having ataxia and weakness and restlessness during night, thy cant properly sleep due to perianal itching. What is the cause of their symptoms?
A- Tapeworm
B- Ascaries
C- Enterobious vermicularis
D- Amoebiasis
E- Trichuris
Ans: C

Explanation:
- Rectal prolaspe - Trichuris trichura
- Anal itching - Enterobious vermicularis

46- A 7-year-old boy who lives in Keotucky is brought to the office by his mother because of a 2-week history of cramping abdominal pain and diarrhea. Three hours ago, the patient thought he had accidentally defecated in his pants. The mother says that she looked in his underpants and saw something move, which she captured. She says that it looked like an earthworm. The patient has had no fever, cough, or blood-tinged sputum. He has not traveled recently. Physical examination, including rectal examination, shows no abnormalities. This patient most likely acquired the causal infectious agent via which of the following modes of transmission?
A- Black fly bite
B- Contact wnh infected puppies
C- Ingestion of soil
D- Mosquito bite
E- Tick bite
Ans: C

47- Shistomiasis has which one of following complication?
A- Urinary abnormalities
B- Splenomegaly
C- Gastric ulcer
D- PUD
Ans: B

48- Malaria enter into human body as
A- Sporozoite
B- Merozoite
C- Hypnozoite
D- Epizoit
Ans: A

Explanation:
- Dormant phase of malaria – Hypnozoite
- Malaria enter into human body as – Sporozoite
- Sporozoite divide in liver as – Merozoite

49-Malignant Quartan malaria is caused by
A- Falciparum
B- Vivax
C- Ovale
D- Malarie
Ans: D

Explanation:
- Malignant tertian malaria is caused by – Plasmodium falciparum
- Benign tertian malaria (48 hours) is caused by – Ovale/vivax
- Quartan malaria (72 hours) caused by – Plasmodium malariae.
- Quotidian malaria caused by – plasmodium Knowlesi > Falciparum

50-Myasis of nose caused by
A- Bacteria
B- Viral disease
C- Larva fly
D- Fungus
Ans: C

51- A young girl uses contact lenses, present to opd with redness and itchy eye her cornea is inflamed, her contact lens water sent for culture which organism is the causes of her infection?
A- Staph aureus
B- Acanthameoba
C- Paramecium
D- Shigella
Ans: B

52- A woman present with high grade fever with chills and Cola color urine O/E splenomegaly and stool test revealed crescent shape gametocyte in blood cause is:
A- Leishmaniasis
B- Plasmodium falciparum
C- Giardiasis
D- Hyatid cyst
E- Kala Azar
Ans: B

53- A man swimming in fresh water pool died after 5 days. What is likely cause
A- Nagleria fowleri
B- Entamoeba histolytica
SC- Falciparum malaria
D- Histoplasmosis
E- Mucormycosis
Ans: A

54- A lady with pallor and weakness, o/c low MCV taste changes and eggs in stool, Diagnosis?
A- Ascaris
B- Ancylostoma duodenale
C- Enterobius vermicularis
D- Trichuris
Ans: B

55- A female came back from Thailand with fever , chills and body ache and postural hypotension. Labs shows deranged RFTs and low bb WBC and Platelets. What is most suitable cause
A- Dengue
B- Syphilis
C- Malaria
D- Chagas disease
E- Typhoid
Ans: C

56- A person went to Thailand and on return presented with diarrhea which is watery and large in amount, in stool sample donut shaped cysts and Halo around organism were found. Cause is:
A- Cryptosporidiosis
B- Giardiasis
C- Amoeba
D- Gnsporiasis
E- Blastocystosis
Ans: A

57- A patient eating Daily from Street vaodor hospitalized for 2 weeks and Ameobic infection reaches lungs via?
A- Direct extension from liver
B- By aspiration of ova of entamoeba histolitica
C- By aspiration of trophozoites of entamoeba histolitica
D- Via portal vein
Ans: A

58- Female with multiple sexual partners developed vaginal irritation and pus, organisms found with jerky movements having yellow vagiual discharge cause is:
A- Candida
B- Pseudomonas
C- Trichomonas vaginalis
D- Syphilis
Ans: C

CamScanner

59- Urinary abnormality associated with:
A- Schistosomiasis
B- T-solium
C- Ecoli
D- Trauma
E- Infection
Ans: A

60- A patient has presented with history of unconsciousness, fits, high grade fever and dark coloured urine for one day CSFexam is unremarkable, diagnosis is:
A- TBM
B- Cerebral malaria
C- Typhoid
D- Leishmanias
E- Kalaazar
Ans: B

61- A lady visited Thailand and now came back to Pakistan presented with fever, rigors, chills; body aches confusion and postural hypotension. What is most probable diagnosis?
A- Malaria
B- Dengue
C- Chagas disease
D- Dengue
Ans: A
Explanation:
- Thailand is geographically more related to malaria & the findings are suggestive for malaria too those are Fever, rigors & specially chills.

62- HIV patient who Immunocompromised patient with profuse diarrhoea ZN Stain shows oocyts 4-6 cm cause is:
A- Cryptosporidium parvum
B- Isospora
C- Giardia lamblia
D- Influenza
Ans: A

63- An eight years old boy used to eat mud vomited and has respiratory symptoms & passed a 6 inch long worm through his nose. What is the organism?
A- Pin-worm
B- Ascaris
C- Tenia
D- Echinococcus granulosus
Ans: B

64- Squamous cell CA diagnosed in a person who came from Dubai and presented with painless hematuria likely organisms associated with disease is:
A- E.coli
B- Schistosoma hematobium
C- S aurues
D- Schistosoma japonicum
E- Schistosoma mansoni
Ans: B

65- African lady with eye layer infect what could be the possible cause.
A- Loa loa
B- Trichomonas
C- Wucheria
D- Trichutis
Ans: A

66- Urinary abnormality associated with:
A- Schistosoma mansom
B- T-solium
C- E.coli
D- Schistosoma hematobium
E- Clomichis sineses
Ans: D

67- Toxoplasmosis is caused by parasite which is epidemic disease 90% in France, 50% in USA and Latent toxoplasmosis with latent AIDS now mostly presents with which condition
A- Penumonia
B- Encephlitis
C- Diffuse lymphadenopathy
D- Genital ulcers
Ans: B

68- Eating raw or undercooked meat can cause infection by:
A- Hookworm
B- Roundworm
C- Tapeworm
D- Echinococcu
E- Liver fluke
Ans: C

69- Toxoplasma Gondii is a?
A- Parasite
B- Helminth
C- Virus
D- Bacteria
Ans: A

70- A patient with abdominal pain, sudden headache, fever and chills. He is also having splenomegaly and hepatomegaly. Organism responsible for this is gemsa stain positive & known to cause increased degradation of RBCS. Which organism is most likely?
A- Kala Azar
B- Schistosomiosis
C- Plasmodium Falciparum
D- Cryptococcus
E- Entameba
Ans: C

71- Pregnant lady presented with Fever, rigors, chills & headache. Investigations reveal an Hb level of 6.0g/dL. Likely cause:
A- P.Falciparum
B- P.Ovale
C- Dengue Fever
D- Enteric Fever
Ans: A

72- Infant diagnosed to have worm infestation physician done CBC which of the following will confirm the diagnosis?
A- Eosinophilia
B- Iron deficiency anemia
C- Increase WBC count
D- Neutrophillia
Ans: A

73- A patient visiting Pakistan develops fever, hypotension, coma, headache- Renal parameters deranged- Platelets 90,000.Retic count increased- Diagnosis:
A- Dengue fever
B- Falciparum Malaria
C- Encephalitis
D- Infectious Mononucleosis
E- Enteric Fever
Ans: B

74- A Patient presented with paroxysmal fever, chills and time duration for symptoms appearing was 72 hours cause is:
A- P.Vivax
B- P. knowlesi
C- P.Falciparum
D- P.Malariae
Ans: D
Explanation:
- Malignant tertian malaria is caused by – Plasmodium falciparum
- Benign tertian malaria (48 hours) is caused by – Ovale/vivax
- Quartan malaria (72 hours) caused by – Plasmodium Malariae
- Quotidian malaria caused by – plasmodium Knowlesi > Falciparum

75- Ascending cholangio hepatitis is caused by
A- Clonorchos sinensis
B- Leishmania donovani
C- Schistosoma Japomcum
D- Schistosoma Mansom
E- Toxoplasmosis Gondii
Ans: A

76- A boy presenter with history of Fever on & off, Recurrent jaundice & Cola coloured urine) O/E, Splenomegaly found) Investigations reveal Decreased Hb) Possible Diagnosis:
A- Immune Hemolytic Anemia
B- G6PD
C- Falciparum Malaria
D- Anemia of chronic disease
Ans: C

77- A patient presents with a history of diarrhea and flask-shaped ulcers in the cecum. How can this infection be distinguished from an amoebic abscess?
A- Trophozoites with ingested RBCs
B- Trophozoites inside RBCs
C- Both trophozoites and cysts in stool
D- Ova in stool
Ans: A

78- Plasmodium enters the mosqnito in which form?
A- Sporozoite
B- Merozoite
C- Schizont
D- Hypoozoite
Ans: A

79- 7 years old child came in bospital with blood in diarrhea,surgeon examined the child and diagnosed as a case of rectal prolapse which organism embeds its hook in themucosa of GIT
A- Ascaris
B- Aocylostoma duodenale
C- Trichuris nicbura
D- Giardia lambdia
E- Entamoeba histolytica
Ans: C(FA)
Explanation:
- Rectal Prolapse – Trichuris Trichura
- Muscle(Myalgia) – Trichinella Spiralis
- Respiratory Symptoms – Ascaris
- Fisherman With Anemia + Echymosis – Vitamic C deficiency
- Fisherman With Anemia – B12 Deficiency – Diphyllobothrium
- Microcytic Anemia – Ankylostoma Conjuctival Swelling – Loa Loa

CamScanner

80- A child from azad Kashmir presented with 3 months history of fever, rashes on legs, failure to thrive and feature of hemolysis, accompanied by massive splenomagely. Laboratory finding revealed low hb levels ,while the total TLC and platelets count were within normal limits which of the following is your diagnosis: (Medicine Feb 2025)

A- Leukemia
B- Visceral leishmenia
C- Malaria
D- CLL
E- Myloproliferative disease

Ans: B

81- Mosquito ingests which stage of malarial parasite(Medicine Feb 2025):

A- Gametocyte
B- Merozoite
C- Hypnozoite
D- Schizont

Ans: A(Levinson microbiology)

EXPLANATION:

Medically Important Stages in Life Cycle of Plasmodium

- Organism: Plasmodium
- Insect Vector: Female mosquito (Anopheles)

Stages:

1. Stage that Infects Human:
- Sporozoite (in mosquito saliva).
2. Stage in Humans Associated with Disease:
- Trophozoites and merozoites (in red blood cells).
3. Important Stage Outside Human
- Mosquito ingests gametocytes.
- Gametocytes fuse to form a zygote →ookinete → sporozoites

82- A patient comes to you with complain of fatigue and weakness. You made a diagnosis of a parasitic infestation. Which of the following is causative organism may lavolve the lungs: (Medicine Feb 2025)

A- Pin-worm
B- Taenia solium
C- Echinococcus granulosa
D- Ascariasis
E- Roundworm

Ans: D

Explanation:

- Respiratoty Symptoms – Ascaris
- Fisherman with anemia + Echymosis , Vitamin C deficiency
- Fisherman with anemia – B12 Deficiency- Diphyllobothrium
- Microcytic anemia – Ankylostoma
- Conjuctival swelling – Loa Loa
- Rectal prolapse – Trichuris Trichura
- Muscle (MyalgiA- – Trichinella Spiralis

83- Female with past History of fever & chills. Now presented with pain Abdomen. O/E, splenomegaly and hepatomegaly. Investigations reveal increased IgE levels. Most probable diagnosis?(Surgery Feb 2025)

A- Cirrhotic liver
B- CML
C- Malaria
D- Brucellosis
E- Leishmaniasis

Ans: E

84- Difference between the Taenia solium and taenia saginata(Gynae & Obs Feb 2025)

A- Saginata acid fast bacteria
B- Solium is AFM
C- Saginata eggs are round
D- Saginata eggs are 30-40 micrometer size
E- Saginata eggs have striation

Ans: C

85- A child is present with anal itching and worms in stool which of the following laboratory finding is significant(Gynae & Obs Feb 2025)

A- Eosinophilia
B- Increased macrophages
C- Basophilia
D- Lymphocytosis
E- Neutrophilia

Ans: A

MEDIPEDIA

- For Online Practice of Mcq Use Medipedia Application From Play Store
- You can search any Mcq in this App on Search bar
- Exam Oriented Pattern of MCQs in this App
- You Can Save Quiz and continue from same MCQ
- Practice Mock Tests on this App

MINORS

CamScanner

BIOCHEMISTRY QUICK HINTS

Nutrition

Vitamins

- ✓ Vitamin C deficiency Scurvy—swollen gum petechiae, hemarthrosis, anemia, poor wound healing, perifollicular and subperiosteal hemorrhages, "corkscrew" hair.
- ✓ Vitamin C excess - Nausea, vomiting, calcium oxalate nephrolithiasis
- ✓ Vitamin D -D3 (cholecalciferol) and D2 (ergocalciferol) Both converted to 25-OH D3 (storage form) in liver and to the active form 1,25-(OH)2 D3 (calciltiol) in kidney
- ✓ Vitamin D deficiency - Rickets(Children) and Osteomalacia(Adults)
- ✓ Vitamin D excess - Hypercalcemia , Hypercalciuria , Loss of appetitie and Stupor
- ✓ Vitamin E deficiency - Hemolytic anemia, acanthocytosis, muscle weakness, demyelination of posterior columns
- ✓ Vitamin E is anti aging and anti oxidant and has similar neurological feature as Vitamin B12 deficiency but without megaloblastic anemia
- ✓ Vitamin E Excess - Risk of enterocolitis in infants.
- ✓ B1 Deficiency– Dry beri beri, Wet beri beri, wernicke korsakoff measured by transketolase activity
- ✓ B2 deficiency – Corneal vascularization
- ✓ B3 deficiency – Pellagra (diarrhea, dementia, dermatitis)
- ✓ B5 required – Co factor for Co enzyme A
- ✓ B2 required – cofactor in redox reactions
- ✓ B5 deficiency – Adrenal insufficiency
- ✓ B7 (Biotin) – Bind avidin in egg and carrier of one carbon
- ✓ B7 – Role in liver metabolism
- ✓ B9 (Folic acid) – One carbon transfer
- ✓ B7 recquired – Cofactor for Carboxylation reactions
- ✓ B9 deficiency – NTD
- ✓ B12 deficiency – Megaloblastic anemia
- ✓ Optic Neuritis deficiency of – B12 > B6
- ✓ Peripheral Neuritis deficiency of -- B1 >B6 > B12
- ✓ Carbohydrate Metabolism need – **Thiamine**
- ✓ Protien Metabolism need – **Riboflavin**
- ✓ Lipid Metabolism need – **Biotin**
- ✓

Amino Acids

- ✓ **K**etogenic – Leucine and Lysine
- ✓ Essential amiaoacids- Phenylalanine, Valine, Tryptophan, Threonine, Isoleucine, Methionine, Histidine, Leucine, Lysine.
- ✓ Non – Essential aminoacids – Alanine , Asparginine , Glutamate , Glycine , Cysteine , Aspirate , Proline , Glutamine , Serine , Tyrosine
- ✓ Ketogenic – Leucine and Lysine
- ✓ Glucogenic – Histidine , Arginine , Valine , Methionine
- ✓ Postive charge – HAL (Histidine, Arginine & Lysine)
- ✓ Negtive Charge – Aspartate and Glutamate
- ✓ DNA has – Histidine
- ✓ Amino Acid deficiency causes cell injury -- Glycine
- ✓ Amino acid cause injury to cell -- Choline
- ✓ Amino Acid causing renal stones – Lysine (COLA)
- ✓ Amino acid in abnormal metabolism – Tryptophan

- ✓ Threonine dosenot contains Sulpha group
- ✓ Sulphur containing Aminoacids – Methionie and Cysteine
- ✓ Histones have Arginine and Lysine
- ✓ Alpha amino group of non – essential aminoacids derived from – Glutamate
- ✓ Imidazole group – Histidine
- ✓ Precursor of heme - Glycine

Collagen Disorders

Osteogenesis imperfecta

- ✓ Genetic bone disorder (brittle bone disease) caused by a variety of gene defects (most commonly COL1A1 and COL1A2).
- ✓ Decrease production of otherwise type I collagen

Patients can't BITE:

- ✓ Bones = multiple fractures
- ✓ I (eye) = blue sclerae
- ✓ Teeth = dental imperfections
- ✓ Ear = hearing loss

Ehlers-Danlos syndrome

- ✓ Faulty collagen synthesis causing hyperextensible skin , hypermobile joints and tendency to bleed (easy bruising).
- ✓ Associated with joint dislocation, berry and aortic aneurysms, organ rupture.

Hypermobility type (joint instability): most common type.
Classical type (joint and skin symptoms): caused by a mutation in type V collagen (eg, COL5A1, COL5A2).
Vascular type (fragile tissues including vessels [eg, aorta], muscles, and organs that are prone to rupture [eg, gravid uterus]): mutations in type III procollagen (eg, COL3A1).

Marfan syndrome

- ✓ Autosomal dominant
- ✓ Defective fibrillin-1 (ch 15)
- ✓ Findings: tall with long extremities ,pectus carinatum [pigeon chest] or pectus excavatum hypermobile joints arachnodactyly ,cystic medial necrosis of aorta; aortic root aneurysm rupture or dissection (most common cause of death) mitral valve prolapse
- ✓ Increase risk of spontaneous pneumothorax
- ✓ Lense dislocate upward and Out (Vs Down and In of Homocystinuria)

Glycogen Storage diseases

Von Gierke disease (type I)

- ✓ Deficiency of Glucose 6 phosphatase
- ✓ Carbohydrate like Glucose and Glucose polymer given in high amount to prevent Hypoglycemia
- ✓ Carbohydrate like Galactose and Fructose avoided because they break into glycolytic intermediate like Lactate and further aggravate already raised Lactate in Von Gierke disease
- ✓ So in Von Gierke Specific Carbohydrate(Glucose) Rich diet and Specific Carbohydrate(Fructose and Galactose) Restricted diet is Used

Pompe disease (type II)

- ✓ Deficiency of Lysosomal acid α-1,4- glucosidase (acid maltase) with α-1,6-glucosidase activity.
- ✓ Cardiomegaly

Cori disease (type III)

- ✓ Deficiency of Debranching enzymes (α-1,6-glucosidase and 4-α-d-glucanotransferase

Andersen disease (type IV)

- ✓ Deficiency of Branching enzyme.

CamScanner

- ✓ Hepatosplenomegaly

McArdle disease (type V)

- ✓ Deficiency of Skeletal muscle glycogen phosphorylase (myophosphorylase).
- ✓ Muscle cramp and myoglobinuria

Cell Cycle

- ✓ **INTERPHASE** .... Chromosomes REPLICATE
- ✓ **INTERPHASE** .... DNA REPLICATE
- ✓ **INTERPHASE**....Barr Bodies are studied
- ✓ **INTERPHASE is divided into**...
- ✓ **1.G1**
- ✓ **2.S (SYNTHESIS Phase)**
- ✓ **3.G2**
- ✓ 4.Mitosis (also called M phase & cytokinesis is a part of it)
- ✓ G1...Primary Growth, Proteins, Organelles, mRNA Synthesis)
- ✓ G1...Also Called growth phase
- ✓ G1... Longest phase (8 to 10 Hours)
- ✓ G1 Check point...To check if DNA is damaged
- ✓ S .... DNA Replicate
- ✓ S....Cytotoxic & cancer drugs act here to destroy DNA
- ✓ S.....5 to 6 hours
- ✓ G2...Secondary growth (between S phase & Mitosis)
- ✓ G2...Short (3 to 4 hours)
- ✓ G2 Check point... To check if DNA has replicated properly
- ✓ **MITOSIS / M Phase**
- ✓ M...Shortest (2 hours)
- ✓ M... To see spindle assembly and alignment
- ✓ M...Nuclear content divide
- ✓ M...genetic material is Chromosome (Genetic material is chromatid when NOT in M phase)
- ✓ M... Divided into Prophase, prometaphase, Metaphase, Anaphase, Telophase, Cytokinesis
- ✓ **Prophase**....Spindle fibers appear Chromosome Condensation
- ✓ Prophase...Centriole start moving to the oposite end & chromosomes first appear
- ✓ **Prometaphase**....Spindle fibers attach to chromosome & chromosome movement
- ✓ **Prometaphase**....Nuclear membrane dissolve marking the begining of prometaphase
- ✓ **Metaphase**...Chromosome Allignment at Equatorial Plate
- ✓ **Metaphase**.....Chromosome thickest
- ✓ **Metaphase**.....Chromosome begin to divide
- ✓ **Metaphase**...Karyotyping
- ✓ **Anaphase**.... Division of chromatids & sister chromatids move to opposite side
- ✓ **Anaphase**....NON Disjunction
- ✓ **Telophase**... Spindle fibers disappear & Decondensation of Chromosomes
- ✓ **Telophase**...Complete divison
- ✓ **Telophase**....Nuclear membrane formation
- ✓ **Cytokinesis**....Cytoplasm divide
- ✓ **Barr Bodies**....Heterochromatin
- ✓ **Barr Bodies**....Have X chromosome
- ✓ **Barr Bodies**....Seen under light microscope
- ✓ **Barr Bodies**....Absent in Turner
- ✓ **Barr Bodies**....Scanty in Turner
- ✓ **Barr Bodies**....Diagnostic for Turner

One Barr body in Klinfelter:

- ✓ No. of Barr bodies in **OX** ....**No Barr Bodies**
- ✓ No. of Barr bodies in **XX**... **1 Barr Body**
- ✓ No. of Barr bodies in **XXX**....**2 Barr bodies**
- ✓ **Best Test for chromosomal abnormalities is Karyotyping**
- ✓ **Cell to Cell – Cadherin**
- ✓ **ECM TO ICM – Intermediate Filament**
- ✓ **ECM to Cytoskeleton – Integrin**
- ✓ **Leukocyte Adhesion to Endothelium – ICAM (CD18 Subunit)**

Random

- ✓ **FISH** used for – Localization of genes and its abnormality such as Microdeletion and Translocation
- ✓ **Microarray** used for – Gene expression
- ✓ Detoxification of drugs – SER
- ✓ Detoxification of Alcohol in Toxic Dose – SER
- ✓ Detoxification of Alcohol in Nomml Dose – Peroxisomes (Oxidase and H2O2)
- ✓ Lysosomes Contain – Hydrolytic enzyme
- ✓ Peroxisome Originate from -SER
- ✓ Lysosome Originate from – Golgi Body
- ✓ Continue with Nuclear membrane – RER
- ✓ Nissle Substance in –RER
- ✓ Lydeg Cell Has – SER
- ✓ Mitochondria – Power house + self-replicating + Short chains Fatty acids Metabolism
- ✓ Double membrane bounded organelles – Nucleus and Mitochondria
- ✓ Golgi bodies – Packaging of cells
- ✓ Production of proteins – Ribosomes > RER
- ✓ Centrioles make – Basal body (basal body makes cilia and flagella)
- ✓ Desmin: Maintain structural and functional integrity
- ✓ Vimentin: Attachments, cell migration, cell signaling
- ✓ Cytokeratin: Resist mechanical stress
- ✓ Microtubulin: Cell division
- ✓ Microfilaments -Muscle contraction, cytokinesis e.g Actin, microvilli.
- ✓ Microtubules - Movement, cell division e.g Cilia, flagella, mitotic spindle, centrioles.
- ✓ Common Step in Glycolysis and Gluconeogenesis - Fructose 1,6 biphosphate to fructose 6 phosphate
- ✓ 1 molecule of Glucose Completely break into water and CO2 give Total ATP – 38
- ✓ Aerobic metabolism of 1 Glucose molecule via malate aspartate shuttle (Heart and Liver) produce -Net 32 ATP
- ✓ Aerobic metabolism of 1 Glucose molecule via Glycerol 3Phosphate Shuttle(Skeletal Muscle) produce -Net 30 ATP
- ✓ Anaerobic Glycolysis of Glucose produce -Net 2 ATP
- ✓ Arsenic poisoning cause Glycolysis to give -Zero Net ATP
- ✓ Tyrosine derivatives does not contains prolactin
- ✓ Thiamine level monitored by Transkelotase level in RBC
- ✓ End product of prine metabolism is uric acid
- ✓ Urine test for ketones doesnot effect Beta hydroxyl butyrate
- ✓ Most common lysosomal storage disease is Gauchers disease
- ✓ Lysosomal disease with neurodegeneration – Niemman pick disease
- ✓ Lysosomal storage disease without Hepatosplnomegaly – Tay sach disease
- ✓ Mechanism of apoptosis in autoimmune disease is Molecular mimicry
- ✓ Spectrophotometer obeys Beer Lambert law
- ✓ Point mutation is a qualitative change in gene expression
- ✓ Highest energy source – Fats

CamScanner

- ✓ 1gm protein and carbohydrates gives 4 calories per gram
- ✓ 1 gram fat gives 9 calories per gram
- ✓ Fat composition of daily diet – 25- 30%
- ✓ Protein composition of daily diet – 15- 20%
- ✓ Daily requirement of protein in healthy adult – 1gm/kg
- ✓ Total body iron – 4gm
- ✓ Total iron content of adult female – 2gm
- ✓ Total iron content of adult male – 6gm
- ✓ Iron requirement in pregnancy – 800mg
- ✓ Calcium requirement in pregnancy – 1200gm

Collagen

- ✓ Type 1 Collagen - Fibrocartilage + bone + tendons + fascia + Skin
- ✓ Type 2 – Elastic and Hyaline cartilage + vitreous body
- ✓ Type 3 – Blood vessels + Uterus + Reticulin + Skin
- ✓ Type 4 – Basement membrane + Lens
- ✓ Early wound healing + Granulation tissue – Type 3 collagen
- ✓ Late wound healing + Wound strength – Type 1 collagen

Type I Chylomicronemia

- ✓ AR
- ✓ Lipoprotein lipase defect
- ✓ Increase Cholestrol, Chylomicron and TG
- ✓ Pruritic xanthomas

Type II Hypercholestrolenemia

- ✓ AD
- ✓ Defective or absent LDL receptor
- ✓ Increase Cholestrol
- ✓ Achilis xanthomas

Type III Dysbeta- lipoproteinemia

- ✓ AR
- ✓ Apo E defective
- ✓ Increase chylomicron and TG
- ✓ Palmar xanthomas

Type IV Hyper-triglyceridemia

- ✓ AD
- ✓ Hepatic overproduction of VLDL
- ✓ Increase VLDL and TG
- ✓ Pancreatitis and insulin resistance

Mutations

- **Missense mutation** (type of point mutation) Examples: sickle cell disease (substitution of glutamic acid with valine).
- **Nonsense mutation** Results in early stop codon (UGA, UAA, UAG). Usually generates nonfunctional protein. Stop the nonsense!
- **Frameshift mutation** - Examples: Duchenne muscular dystrophy, Tay-Sachs disease.
- **Splice site mutation**- of β-thalassemia, Gaucher disease, Marfan syndrome.

Lipoproteins

- Chylomicrons- intestine
- VLDL and LDL – liver
- HDL – liver and intestine
- **Highest triglyceride** – chylomicrons > VLDL > LDL > HDL
- **Highest cholesterol** – LDL > VLDL > HDL > Chylomicrons
- **Highest Proteins** – HDL > LDL > VLDL > Chylomicrons
- **Highest Phospholipds** – HDL > LDL > VLDL > Chylomicrons

Endproducts of Aminoacids metabolism

- **Tryptophan**- serotonin , melatonin, niacin
- **Glutamic acid** - GABA , gluathione
- **Phenylalanine and tyrosine** - T3, T4, Melanin , DOPA , dopamine , tyramine , epinephrine and non-epinephrine
- **Arginine** - urea, creatinine
- **Methionine and cysteine** - pyruvate formation, CoA taurine and glutathione
- **Glycine** - serine, cysteine, choline, glutathione formation, bile salts

CamScanner

BIOCHEMISTRY

1. A child presented with dark colour nappy, (Dark urine), and homogenistate oxidase deficiency whats likely cause
A- Alkaptonuria
B- Phenylketouria
C- Mapple disease
D- Niekman disease
E- Galactosemia
Ans: A

2. Cell arrested in diplotene which is phase of
A- Metaphase
B- Telophade
C- Anaphase
D- Prophase
E- Interphase
Ans: D

3. Final wound strengthening by which type of collagen?
A- Collagen 3
B- Collagen 2
C- Collagen 1
D- Collagen 4
E- Collagen 5
Ans: C
Explanation:
- Early wound healing + granulation tissue – Type 3 collagen
- Late wound healing + wound strength – Type 1 collagen

4. A Patient wisbed to take supplements or vit. For rejuvenation, came across the info on internet that this vit. deficiency is similar to that of B12 except for anemia and in patients with liver and hiliary tract diseases its deficiency occurs what's the vitamin?
A- Vitamin A
B- Vitamin D
C- Vitamin E
D- Vitamin C
E- Vitamin K
Ans: C(FA)
Explanation:
- Vitamin E is anti aging and anti oxidant and has similar neurological feature as Vitamin B12 deficiency but without megaloblastic anemia

5. Vitamin for good memory is
A- B1
B- B12
C- B6
D- B3
E- B2
Ans A

6. Cheliosis and corneal vascularization is due to deficiency of which of the following vitamin?
A- Thiamine
B- Biotin
C- Riboflavin
D- Folate
E- Vitamin C
Ans: C(FA)
Explanation:
- B1 Deficiency – Dry Beri beri, Wet Beri beri, Wernicke korsakoff
- Measured by Transketolase activity
- B2 Deficiency – Corneal Vascularization
- B3 Deficiency – Pellagra (Diarrhea, Dementia, Dermatitis)
- B5 Required – Co factor for Co enzyme A
- B5 Deficiency – Adrenal Insufficiency
- B7(Biotin) – Bind Avidin in egg and Carrier of One carbon
- B7 -- Role in liver Metabolism
- B9(Folic acid) – One Carbon Transfer
- B9 Deficiency – NTD
- B12 Deficiency – Megaloblastic Anemia

7. Vitamin C deficiency will affect?
A- Hydroxylation of Proline and lysine
B- Hydroxylation of Proline and leucine
C- Hydroxylation of Proline and cysteine
D- Hydroxylation of Lysine and Cysteine
E- Hydroxylation of leucine and lysine
Ans: A

8. 1 molecule of Glucose Completely break into water and CO2 give how much total nu of ATP:
A- 32
B- 34
C- 30
D- 38
E- 42
Ans: D (FA+Guyton)
Explanation:
- Total ATP – 38
- Aerobic metabolism of 1 Glucose molecule via malate aspartate shuttle (Heart and Liver) produce -Net 32 ATP
- Aerobic metabolism of 1 Glucose molecule via Glycerol 3Phosphate Shuttle(Skeletal Muscle) produce -Net 30 ATP
- Anaerobic Glycolysis of Glucose produce -Net 2 ATP
- Arsenic poisoning cause Glycolysis to give -Zero Net ATP

9. Lipoprotein with highest protein:
A- HDL
B- LDL
C- VLDL
D- IDL
Ans: A
Explanation:
- **Lipoprotein with highest triglyceride:**
- Chylomicron > VLDL > Chylomicron remnants > LDL
- **Lipoprotein with Highest Cholesterol:**
- LDL > VLDL > HDL > Chylomicron
- **Lipoprotein with Highest Protein:**
- HDL > LDL > VLDL > Chylomicron

10. Highest calorie value is of which of the following?
A- Carbohydrate
B- Protein
C- Fats
D- Alcohol
E- Water
Ans: C
Explanation:
- Carbs/Protein Give – 4kcal
- Fats Give – 9kcal
- Alcohol Give – 7kcal

11. Plasma protein synthesized by which of the following?
A- Spleen
B- Liver
C- Kidney
D- Pancreas
Ans: B

12. Patient came for weight monitoring best advice for it:
A- Personal monitoring
B- Self reward
C- Self punishment
D- Low protein
Ans: A

13. Female taking supplements for dietary deficiency. After some time, duration she developed dry mouth, bone hyperosteosis, papilledema nausea and vomiting due to increase in which of these?
A- Calcium
B- Fluoride
C- Vitamin A
D- Vitamin C
E- Iron
Ans: C

14. In metaplasia if chromosome divide transversely rather than longitudinally. What will happen?
A- Trisomy
B- Monosomy
C- Isochromosome
D- Heterochromosome
Ans: C

15. A malnourished child with multiples extracted teeth he had on radiography scans were not suggestive of his age calculation how will u access
A- Height and Weight ratio
B- Length of femur
C- Head circumference
D- Length and body surface
Ans: A

16. DOC for treatment of diabetic neuropathy
A- NSAIDS
B- Cobalamin
C- TCA
D- VitaminD
E- Niacin
Ans: B

17. A patient presents with anemia wrist drop constipation and peripheral neuropathy it is caused by:
A- Organophosphate poisoning
B- Arsenic poisoning
C- Lead poisoning
D- Aspirin poisoning
Ans: C

18. If 5m of cholesterol reduced from diet the how much chance of IHD reduced:
A- 1
B- 5
C- 25
D- 50
E- 80
Ans: C

19. A patient with Uroporphyria I in uriae diagnosed with congenital erythropeitic porphyria enzyme deficient is:
A- ALA Dehydratase
B- Uroporphynogen III Syothase
C- Ferrochelatase
D- Uroporphyrinogen II Synthase
E- Uroporphyrin
Ans: B(FA)

20. Carbonic anhydrase is present in:
A- Cytoplasm of neutrophil
B- Cytoplasm of basophil
C- Cell membrane of RBC
D- Cytoplasm of RBC
E- Cell membrane of neutrophil
Ans: D

CamScanner

21. Glucose level between meals is maintained by
A- Glycolysis
B- Hepatic glycogenolysis
C- Adipose tissue release FFA
D- Vital protein degradation
E- Hepatic gluconeogenesis
Ans: B

Explanation:
- After Meal – Glycolysis occur (FA)
- Between Meal – Glycogenolysis > Gluconeogenesis (FA)

22. Fat rich meal, it's absorption and digestion increase due:
A- Gastrin
B- Cholecystokinin
C- Secretin
D- VIP
E- No
Ans: B

23. Lens metabolism require which of these?
A- Glucose
B- Amino acid
C- Sodium
D- Water
E- Fanyacid
Ans: A

24. A 2 Year baby brought by mother she said there is transient decrease of blood sugar and hepatomegaly then diagnosed as von gierke disease the doctor will advice
A- Low intake of protein
B- Low intake of Vitamins
C- Increase intake of carbohydrate
D- Increase intake of fats
Ans: C (Lipincot + FA)

Explanation:
- Carbohydrate like Glucose and Glucose polymer given in high amount to prevent Hypoglycemia
- Carbohydrate like Galactose and Fructose avoided because they break into glycolytic intermediate like Lactate and fuither aggravate already raised Lactate in Von Gierke disease
- So, in Von Gierke Specific Carbohydrate (Glucose) Rich diet and Specific Carbohydrate (Fructose and Galactose) Restricted diet is Used

25. Healthy skin is made up of the best collagen type are:
A- Type 3 and 5
B- Type 1 and 3
C- Type 2 and 4
D- Type 5 and 4
E- Type 3 and 4
Aos: B

Explanation:
- Type 1 Collagen - Fibrocartilage + bone + tendons + fascia + Skin
- Type 2 Collagen -- Elastic and Hyaline cartilage + vitreous body
- Type 3 Collagen -- Blood vessels + Uterus + Reticulin + Skin
- Type 4 Collagen -- Basement membrane + Lens
- Early wound healing + Granulation tissue. - Type 3 collagen
- Late wound healing + Wound strength - Type 1 collagen

26. Presence of genetically distinct cell lines in the same individual, this genetic phenomenon is called as:
A- Variable expressively
B- Zygote acromegaly
C- Mosaicism
D- Genomic imprinting
E- Zygote anomaly
Ans: C (FA)

27. After myocardial injury what ical changes will be seen in hypoxia:
A- Aerobic Glycolysis
B- Oxidative Phosphorylation
C- Anaerobic Glycol ysis
D- Gluconeogenesis
Ans: C

28. Basal metabolic rate depends most closely on
A- Protein
B- Body mass index
C- Obesity
D- Body surface area
Ans: B>D

29. Hb accepts proton from which amino acid, so that Hb can act as a buffer:
A- Histidine
B- Aspartate
C- Alanine
D- Threonine
E- Cystein
Ans: A

Explanation:
- Ketogenic – Leucine and Lysine
- Postive charge – HAL (Histidine, Arginine & Lysine)
- Negtive Charge – Asparate and Gluramate
- DNA bas – Histidine

30. Obesity calculated as:
A- More than 25% weight is of fats in women
B- Less than 20% weight is of fats in man
C- Low metabolic rate
D- BMI less than 20 in women
E- BMI less than 18 in men
Ans: A

31. Which will be the same substrate for the glycolysis glycogenesis and HMP shunt?
A- UDP glucose
B- Glucose 1 phosphate
C- Fructose 1 phosphate
D- Fructose 6 phosphate
E- Phosho isomerase
Ans: D

32. Which one same in glycolysis and gluconeogenesis:
A- Fructose 6 phosphate
B- Glucose 6 phosphate
C- Fructose 1,6 bisphosphate
D- Phosphofructokinase
Ans: C

33. Glycolytic enzyme present in RBC:
A- Cytoplasm
B- Mitochondria
C- Nucleus
D- Cell
Ans: A

34. Crigler najar type 2 which enzyme deficiency will occur
A- Glucose 6 phosphatase
B- UDP glucoronosyltransferase
C- Glycogen phosphorylase
D- UDP glurono synthaase
Ans: B

35. Type-I lipoproteinemia cause is:
A- Deficiecy of lipoproteins lipase
B- Apolipprotein deficiennccy
C- Alcohol consumption
D- Obesity
Ans: A

36. Which of the following vitamin deficiency causes night blindness?
A- Vitamin C
B- Vitamin B-12
C- Vitamin A
D- Vitamin K
Ans: C

Explanation:
Vitamin A deficiency causes
- Bitot spots
- night blindness
- Corneal squamous metaplasia
- Corneal degeneration
- Night blindness
- teratogenic in excess (cleft palate, cardiac abnormalities)

37. Choline is component of
A- Sphingomylein
B- Phosphotidichokine
C- Glycerol
D- Glutamic acid
Ans: A

38. Nucleolus is the collection of?
A- Small amount of RNA
B- Small amount of DNA
C- Large amount of RNA
D- Large amount of DNA
Ans: C

39. A chronic smoker male presented with the cough o/e he is cyanosed reason?
A- HBS
B- HBC
C- Increase level of oxyhemoglobin
D- Increase level of deoxyhemoglobin
Ans: D

40. Mcardle disease enzyme deficient is:
A- Protease
B- Carbonic anhydrase
C- Muscle phosphorhylase
D- Creatinine kinase
Ans: C

Explanation:
- Von gierke disease - glucose 6 phosphatases
- Pompe disease - lusosomal acid alpha 1, 4 glucosidases (acid maltase) with alpha 1,6 glucosidase activity
- Cori disease - debranching enzyme (alpha - 1,6 glucosidase and 4 - alpha - D glucanotransferase
- M cardle disease - muscle glycogen phosphorylase (Myophosphorylase)

41. Hypercholesterolemia type I will have increased level of:
A- Chylomicron+TG+cholesterol
B- Cholestrol
C- TG
D- Chylomicron
Ans: A (First Aid)

42. Apoprotein A is component of
A- HDL
B- LDL
C- VLDL
D- Chylomicrons
Ans: A

Explanation:
- Apo A I and 2 - HDL
- Apo B100 - LDL, VLDL
- Apo B48 - chylomicrons
- Apo C1 - chylomicrons and VLDL
- ApoE - chylomicrons, VLDL, LDL

43. Which type of Ehler Danlos syndrome inherited by autosomal recessive?
A- Atypical EDS
B- Vascular EDS
C- Kyphoscoliotic EDS
D- Arthrochalasia EDS
Aos: C

CamScanner

44. Most common cause of mental retardation:
A- Edward syndrome
B- Fragile X
C- Cri du chats
D- Turner Syndrome
E- Kilnfilter syndrome
Ans: B

Explanation:
- Most Common cause of Genetic intellectual disability -Down Syndrom
- Most common cause of inherited Intellectual disability -Fragile X syndrome
- Over all- Down >Fragile

45. Cell wall lipids are soluble in?
A- Sulphuric acid
B- Alcohol
C- Acetic acid
D- Soap water
E- Normal Saline
Ans: B

46. Most abundant TG's are present in
A- Chylomicrons
B- VLDL
C- LDL
D- HDL
Ans: A

47. Which one of the following delivers hepatic cholesterol to the peripheral tissues?
A- Chylomicrons
B- VLDL
C- IDL
D- LDL
E- HDL
Ans: B

Explanation:
- Chylomicrons - delivers dietary TG's to peripheral tissues
- VLDL - delivers hepatic TG's to peripheral tissue
- IDL - delivers TG's and cholesterol to liver
- LDL - deliver hepatic cholesterol to peripheral tissues
- HDL - reverse cholesterol transport from periphery to liver

48. Mode of inheritance of defective genes involved in DNA repair:
A- X linkedDominant
B- Autosomal recessive
C- Autosomal dominant
D- X – link tecessive
Ans: B

49. For carbohydrate metabolism which vitamin necessary?
A- Riboflavin
B- Thiamine
C- Biotin
D- Pantothenic
Ans: B

Explanation:
- For Carbohydrate – Thiamine
- For Prouen – Riboflavin
- For Lipid – Biotin

50. Which diet should be given for Meniere disease?
A- Low Protien
B- Low Carbohydrate
C- Increase Carbohydrate
D- Low lipids
Ans: B

Explanation:
- High Protein and Low Carbohydrates

51. Redgreen blindness is:
A- Autosomal dominant
B- Autosomal recessive
C- X linked recessive
D- X linked dominant
Ans: C

52. X chromosome in male is:
A- Monozygous
B- Hemizygous
C- Homozygous
D- Heterozygous
Ans: B

53. Mother Milk preffered over cow milk due to:
A- Calcium
B- Iron
C- Immunoglobulin
D- Phosphorous
Ans: C

54. Patient with fragile blood vessel with gums inflamed and bleeding likely diagnose:
A- Inflammation
B- Scurvy
C- Vitamin A toxicity
D- Anemia
Ans: B

55. Glycolysis occurs in
A- Cytosol
B- Mitochondria
C- Nucleus
D- Lysosomes
E- Golgi apparatus
Ans: A

Explanation:
- Glycolysis , fatty acid synthesis , HMP shunt and protein synthesis occurs in cytosol

56. Turner syndrome:
A- Complete Monosomy
B- Incomplete monosomy
C- Trinucleotide repeat
D- Cause mental retardation
Ans: A

57. Rich source of Vitamin K:
A- Meat
B- Green Vegetables
C- Wheat
D- Orange
Ans: B

58. Chronic hypervitaminosis A leads to:
A- Hepatosplenomegaly
B- Mental retardation
C- Osteoma
D- Hypogonadism
Ans: A

Explanation:
- Acute toxicity - nausea, vomiting, vertigo, blurred vision
- Chronic toxicity - alopecia, dry skin, hepatic toxicity and enlargement, arthralgias and idiopathic intracranial hypertension

59. RER is responsible for synthesis of:
A- Fatty acids
B- Glucogen
C- Proteins
D- Glucose
Ans: C

60. Which of the following is responsible for uncoupling of oxidulive phosphotylation?
A- Epinephrine
B- Glucagon
C- Cortisol
D- Thyroxin
Ans: D

Explanation
- NE >Thyroxin >Epinephrine

61. Congenital erythropoitic porphyria. What is finding in urine?
A- Increase urine uroporphyrin I
B- Stool porphyrin increase
C- Decrease urine porphyrin
D- Increase blood porphyrin
Ans: A

62. Beri Beri associated with:
A- Low riboflavin
B- Low biotion
C- Low thiamine
D- Low vitamin E
Ans: C

Explanation:
Thiamine deficiency causes
- Wernicke korakoff syndrome (confusion, ophthalmoplegia, ataxia)
- Dry beri beri (polyneuritis, symmetrical muscle wasting)
- Wet beri beri (high cardiac output failure)

63. Two siblings with osteogenesis imperfecta, but their parents are normal, mode of inheritance is
A- New mutation
B- Germ line mosaicism
C- Genimic imprinting
D- Anticipation
Ans: B

64. Enzyme whose activity increases in cancer cells:
A- Elastase
B- Telomerase
C- Caspase
D- Lipase
Ans: B

65. Vitamin B1 deficiency causes increased cardiac output this is due to:
A- Decrease HR
B- Beri beri
C- Decrease Stroke volume
D- Cheilosis
Ans: B

66. Thiamine deficiency causes:
A- Myocarditis
B- Wernicke encephalopathy
C- Pellagra
D- Keratitis
Ans: B

67. Basement membrane will repel by which negative charge due to??
A- Laminin
B- Fibronectin
C- Type 4 collagen
D- Heparin sulfate
Ans: D

68. Cytokeratin is an intermediate filament found in cells but is most commonly used for detection of:
A- Neoplasia
B- Degree of metaplasia or dysplasia
C- To check rate of proliferation
D- For staging of disease
Ans: A

CamScanner

69. Alcoholic man presented with hypoglycemia, initial treatment is
A- Ivdextrose
B- Thiaroine
C- Oral glucose
D- Normal saline
Ans B

70. An 11 month baby brought by mother with complains that the baby is semi-conscious and listless. O/E no response to vocal stimulation, weight 60% of age and a small purple contusion is found on his thigh. What is the diagnosis?
A- Marasmus
B- Kwashiorkor
C- Physical abuse
D- Nutritional deficiency
Ans: C

Explanation:
- Contusion and no response to vocal is indicating physical abuse.

71. Albumin does not pass basement membrane due to:
A- Negative charge
B- Large size
C- Positive charge
D- Water Solubility
Ans: A

72. Fat digestion done by:
A- Emulsification of Fats by Bile salts
B- Bile salt
C- Lipase
D- HCO3
Ans: A

73. Deficiency of niacin causes:
A- Beriberi
B- Peripheral neuropathy
C- Pellagra
D- Seborrhea dermatitis
Ans: C

Explanation:
Vitamin B3 (niacin) deficiency causes
- Hartnup disease
- Pellagra 4D's: diarrhea, dementia, dermatitis (collarrash like necklace) and death

74. Deficiency of insulin is associated with increased production of:
A- Fatty acids
B- Carboxylic acid
C- Acetoacetic acid
D- Acetic acid
Ans: C

75. Wadding gait like difficulty in [illegible] from squatting position [illegible] involved?
A- Tyrosine kinase
B- Creatinine phosphokinase
C- Glucose 6 phosphatase
D- None
Ans: B

76. Chylomicrons are secreted in:
A- Stomach
B- Small intestine
C- Large intestine
D- Liver
Ans: B

Explanation:
- (Chylomicrons are lipid transporting proteins secreated from brush borders of intestine and enters into lacteals)

77. Patient developed gum swelling and bleeding due to deficiency of:
A- Retinal
B- Ascorbic acid
C- Citric acid
D- Retinoic acid
Ans: B

78. Fats enter the lymph in the form of:
A- Free fany acids
B- Triacylglycende
C- Glycerol
D- Chylomicrons
Ans: D

79. The major lipoproteins source of the cholesterol used in the cells is:
A- Chylomicrons
B- Intermediate density lipoproteins
C- LDL
D- Albumin bound free fatty acids
E- HDL
Ans: C

80. Urine color turns black on exposure to air enzyme deficiecy:
A- Catalase
B- Deaminase
C- Homogenisate oxidase
D- Carboxylase
Ans: C

81. Patient present to you having tall height now complaining of chest pain and having lens dislocation due to
A- Fragile x syndrome
B- Marfan sundrome
C- Digorge syndrome
D- Neurofibromatosis
Ans: B

82. Decrease prothrombin level is due to deficiency of which vitamin?
A- Vitamin A
B- Vitamin D
C- Vitamin C
D- Vitamin K
Ans: D

83. Transferred by multifactorial inheritance:
A- Sickle cell anemia
B- Phenylaketonturia
C- Cystic fibrosis
D- Omphalocele
Ans: D

84. Severe deficiency of which vitamin leads to malignant carcinoid syndrome?
A- Niacin
B- Thiamine
C- Riboflavin
D- Pantothenic acid
Ans: A

85. Factor related to coronary artery disease and inhibits fibrinolysis?
A- HDL - C
B- LDL - C
C- Chylomicrons
D- VLDL
E- IDL
Ans: B

86. Which part of intermediate filaments involve in cell repair?
A- Desmin
B- Vimentin
C- Cytokeratin
D- Microtubulin
Ans: C

Explanation:
- Desmin: Maintain structural and functional integrity
- Vimentin: Attachments, cell migration, cell signaling
- Cytokeratin: Resist mechanical stress
- Microtubulin: Cell division

87. Rate limiting enzyme in glycolysis
A- Phosphofructokinase
B- Tyrosine hydroxylase
C- 7 alpha hydroxylase
D- HMG COA synthetase
E- Isocitrate dehydrogenase
Ans: A

Explanation:
Rate limiting enzymes
- Cholesterol synthesis- HMG COA reductase
- Krebs cycle - isocitrate dehydrogenase
- Ketone body synthesis- HMG COA synthetase
- Fatty acid synthesis- acetyl COA carboxylase
- Bile acid synthesis - 7 alpha hydroxylase
- Gluconeogenesis- pyruvate carboxylase
- Glycolysis - phosphofructokinase
- Cetacholamine synthesis - tyrosine hydroxylase
- Glycogenolysis - glycogen phosphorylase
- HMP shunt - glucose 6 phosphate dehydrogenase
- Urea cycle - carbomyl phosphate synthetase I
- Pyrimidine synthesis - carbomyl phosphate synthetase 2
- Purine synthesis - glutamine phosphoribosylpyropjosphate amidotransferase
- Fatty acid oxidation - carnitineacyl tranaferase

88. Lymph vessels involved in:
A- Patau syndrome
B- Down Syndrome
C- Cystic hygroma
D- Infection
Ans: C

89. B12 carrier factor:
A- TC-I
B- TC-II
C- TC-III
D- Intrinsic factor
Ans: B

Explanation:
- Vitamin B12 and Bile Salts Absorption – Terminal ileum
- For B12 Absorption Needed – Intrinsic Factor
- For B12 Transport Needed – Transcobalamin 2

90. Most common cause of sex chromosome abnormality:
A- Hermaphrodite
B- Klinefelter syndrome
C- Down syndrome
D- Multi X female
Ans: B

CamScanner

91. Magoeta tongue due to deficiency of
A- Vitamin B1
B- Vitamin B2
C- Vitamin B5
D- Vitamin B12
E- Vitamin B3
Ans: B

Explanation:
- B2 deficiency - magneta tongue
- B12 deficiency - red beefy tongue

92. Daily requirement of protein according to FDA:
A- 3gm/kg
B- 1gm/kg
C- 5gm
D- 15gm
Ans: B

93. Uncoupling oxidative phosphorylation
A- Thyroxin
B- Epinephrine
C- Dopamine
D- N.epinephrine
E- Serotinine
Ans: D

Explanation:
- Uncoupling Oxidative Phosphorylation – NE> Thyroxin > Epinephrine.

94. Homocysteine in blood comes from which amino acid?
A- Cysteine
B- Lysine
C- Phenylalanine
D- Tyrosine
E- Methionine
Ans: E

95. What happens in S1 phase?
A: Duplication of DNA
B: Duplication of chromosome
C: Duplication of chromatids
D: Duplication of nucleolus
Ans: A

96. Optic neuritis is caused due to deficiency of vitamin:
A- B1
B- B6
C- B12
D- B5
E- B3
Ans: C

Expalanation:
- Optic neuritis – B12 >B6
- Peripheral neuritis – B 1 >B6 >B12

97. Alkaptouria patient will have:
A- Decrease Homogentisic acid in Urine
B- Decrease Homogentisic acid in Body
C- Increase homogentisic acid in urine
D- None
Ans: C

98. In classic galactosemia defect is:
A- Glucokinase
B- Glucose 6 phosphatase
C- Galactose 1phosphate uridyl transferase
D- Hexokinase
Ans: C (First aid)

99. CoA enzyme required:
A- Vit. B1
B- Vit. B5
C- Vit. C
D- Vit. A
Ans: B

Explanation:
- Vitamin B5 (pantothenic acid) component of coenzyme A
- Vitamin B7 (biotin)- cofactor b carboxylation reactions

100. 1 carbon carrier is:
A- Folate
B- Pantothenic acid
C- Thiamine
D- Biotin
Ans: D

Explanation:
- One Carbon Carrier – Biotin
- Add One Carbon – Biotin
- One Carbon Transfer – Folate

101. No LDL receptor in which disease?
A- Type 1 Hyperlipidemia
B- Type 2 Hyperlipidemia
C- Type 3 Hyperlipidemia
D- Type 4 Hyper lipidemia
Ans: B (FA)

Explanation:
- Type 1 - Lipoprotein lipase & apolipoprotien C - 2 deficiency
- Type 2 - absent or defective LDL receptor or defective Apo B 100
- Type 3 - defective Apo E
- Type 4 - hepatic overproduction of VLDL

102. Raised LDL in blood is seen in:
A- Type 1 Dyslipidemia
B- Type 2 Dyslipidemia
C- Type 3 Dyslipidemia
D- Type 4 Dyslipidemia
Ans: B (FA)

103. Student examining a slide, visualize a tumor of muscle of GIT, a protein which connect cells together is missing. Protein is?
Titin
A- Collagen
B- Fibronectin
C- Actinin
D- C
Ans:

104. Maple syrup urine disease caused by decrease:
Alpha ketoacid dehydrogenase
A- Phenylalanine hydroxylase
B- Homogametic acid synthase
C- None
D-
Ans: A

105. Boy with Palmar xanthomas and high cholesterol:
Hypercholestronemia 1
A- Hypercholesterolemia2 a
B- Hypercholesterolemia2b
C- Hypecholesterolemia3
D-
Ans: D

Explanation:
- Prurutic Xanthomas – Type 1
- Achlis Xanthomas – Type 2
- Palmar Xanthosmas – Type 3
- Type 4 associated with DM , Heart disease and obesity

106. Most abundant substance in protoplasm after water:
A- Lipids
B- Electrolytes
C- Proteins
D- Minerals
Ans: C

Explanation:
- Water >Protien Carb>Lipid

107. Child with hepatosplenomegaly streaks on hair and face abdomen protruded cause:
A- Kawashiorkor
B- Marasmus
C- Physical abuse
D- CLD
Ans: A

108. Peripheral neuritis is caused due to deficiency of vitamin:
A- B1
B- B6
C- B12
D- B3
Ans: A

Explanation:
- Optic Neuritis – B12 > B6
- Peripheral Neuritis – B1 >B6 >B12

109. A patient with chronic renal failure has low serum calcium and high phospbate following will explain these ical changes:
A- Decreaaw calcium absorption in gut
B- Decrease level of 1, 25 dihydro chalceferol
C- Decrease levels of phosphate
D- Increase calcium loss in urine
E- Increase osteo clastic activity
Ans: B

110. Liver maintains serum glucose levels between meals by which of the followings:
A- Glycogenesis
B- Glycolysis
C- Gluconeogenesis
D- Lactogenisis
Ans: C

Explanation:
- Between Meals Glycogenolysis >Gluconeogenesis (FA)

111. A 56 years old executive officer after eating burger with fries, gets his lipid profile done. After centrifuge his plasma appears milky white, this is due to:
A- LD
B- VLDL
C- HDL
D- IDL
E- Chylomicrons
Ans: E

112. Which of the following is the product of carbohydrate digestion?
A- Galactose
B- Glucose
C- Sucrose
D- Maltose
Ans: B

113. Gut bacteria helps in synthesis of which of the following vitamin?
A- Vitamin A
B- Vitamin B
C- Vitamin C
D- Vitamin K
Ans: D

114. Person presented who complaints of can't see in dark due to deficiency of:
A- Retinol
B- Niacin
C- Pyridoxine
D- Ascorbic Acid
Ans: A

CamScanner

115. Which intermediate filament present in mesenchyme:
A- Desmin
B- Lamin
C- Vimentin
D- Vesmin
Ans: C

Explanation:
- In mesenchyme: Vimentio
- In Muscles: Desmin
- In Epithelial Cells: Keratin

116. Largest Molecular weight protein:
A- Albumin
B- Globulin
C- Titin
D- Myosin
E- Actin
Ans: C

Explanation:
- Titin, is definitely the latgest protein in the body, with a molecular weight of 3 million Dalton and composed of 27000 amino acids.
- Largest no. Of exons - titin gene
- Largest coding sequence - titin
- Largest primary transcript - dystrophin gene

117. Regarding Cell cycle G2 Phase is between:
A- G1 – S
B- S – M
C- G1 – G2
D- S-G2
Ans: B

Explaoation:
- G2 phase lies between S – M Phase
- Gl Phase lies between M – S phase

118. Lipids after metaholism absorbed in the form of:
A- LDL
B- VLDL
C- Chylomicrons
D- HDL
Ans: C

119. Which of the following vitamin is deficient post pacreatectomy?
A- Thiamine
B- Niacin
C- Vitamin D
D- Vitamin A
Ans: C

120. Cytoskeleron connected to ECM by:
A- Intermediate filament
B- Integrin
C- Proteoglycan
D- Cadehrin
Ans: B

Explanation:
- Cell to cell - Cadherin
- Cytoskeleton connected to ECM by Integrin.
- ECM connected to ICM by Intermediate filament.

121. Triple pattern of microtubules are present in:
A- Kinetochore
B- Centrioles
C- Centrosomes
D- Centromer
E- Mitotic apparatus
Ans: B

122. A mother has given folic acid, which of the following other condition can lead to Neural tube defect:
A- Vitamin A toxicity
B- Vitamin B12 Overdose
C- Niacin Deficiency
D- Biotin
Ans: A

123. Pellegra occurs due to deficiency of which of the following?
A- Niacin
B- Thiamin
C- Folate
D- Riboflavin
Ans: A

Explanation:
- Niacin deficiency leads to Pellegra (Diarrhea, Dementia & Death).

124. Which of the following is sulfur containing amino acid?
A- Cysteine
B- Phenylalanine
C- Lysine
D- Arginine
Ans: A

Explanation:
- Methionine, Cysteine, Homocysteine and Taurine are the four common sulfur containing amino acids.

125. A man presented in E/R with shortness of breath. CXR shows enlurged heart and hasal lung pulmonary edema. FLC normal which vitamin deficiency will beassociated with this condition?
A- Vitamin K
B- Vitamin C
C- Vitamin B1
D- Vitamin B2
Ans: C

126. Lipoprotein with highest phospholipids:
A- HDL
B- LDL
C- VLDL
D- Chylomicrons
Ans: A

127. In red blood cells Cytoskeleton is associated with which of the following protein:
A- Actin
B- Myosin
C- Spectrin
D- Protein 3
Ans: C

128. Percentage of Fats in adult male:
A- 10%
B- 15%
C- 30%
D- 40%
Ans: B

Explanation:
- Percentage of Fat in male: 15%
- Percentage of fat in female: 30 – 35%

129. Rickets is caused by deficiency of which of the following vitamin?
A- Vitamin A
B- Vitamin B
C- Vitamin C
D- Vitamin D
Ans: D

130. Scurvy is due to deficiency of:
A- Calcium
B- Niacin
C- Ascorbic acid
D- Vitamin D
Ans: C

131. Which of the following properties best define Vitamin – E (Tocopherol) in executing its function?
A- Anticoagulant
B- Antioxidant
C- Antilipidemic
D- Co-enzyme
E- Co-factor
Ans: B

132. Which of the following suits the Eucromatins?
A- Comains densely packed chromatins
B- Long chained
C- Silent DNA
D- Stains densely with basophilic dye
Ans: D

Explanation:
- Eucromatins are active in protein synthesis, light stained and have prominent nucleolus. They stain densely with basophilic dye since they have abundant RNA (active in protein synthesis) and RNA is basophilic.

133. Beri Beri is caused by which of the following vitamin deficiency?
A- B2
B- B1
C- B6
D- B7
Ans: B

134. The differentiating feature of kwasblorkor from marasmus:
A- Fat loss
B- Pitting edema
C- Muscle wasting is not present
D- None of them
Ans: B

Explanation:

Kwashiorkor	Marasmus
Deficient Proteins	Deficient Proteins and Calories
Hair changes present	Hair changes not present
Fatty liver common	No fatty liver
Edema present	Edema not present
Subcutaneous fat present	Subcutaneous fat not present
Poor appetite	Good appetite
No muscle wasting	Severe muscle wasting

135. A mother brings her child with a complaint that her child has visual problems at night, what is responsible?
A- Riboflavin
B- Niacin
C- Retinol
D- Vitamin – K
Ans: C

136. Lioporoteins are taken by cells in the form of:
A- LDL
B- HD
C- Albumin bound
D- Free fatty acids
E- Chylomicrons
Ans: E

137. Muscles have the following intermediate filament:
A- Desmin
B- Vementin
C- Keratin
D- Laminio
Ans: A

Explanation:
- Muscle - desmin
- Connective tissue- vimentin
- Tumor - cytokeratin

138. A pregnant lady in her third trimester uses only iron supplements, what would she be deficient in?
A- Vitamin B12
B- Calcium
C- Folic Acid
D- Magnesium
Ans: B

139. A patient merely eats vegetables, he will be deficient in:
A- Folic Acid
B- Vitamin B12
C- Calcium
D- Iron
Ans: B

Explanation:
- Vegetables contain folic acid
- Animals contains vitamin B12

140. The metabolic fuel for liver in the post absorptive phase is:
A- Ketone bodies
B- Lactate
C- Fatty acids
D- Glucose
Ans: D

141. Which of the following protein is mainly deficient in Kwashiorkor disease?
A- Globulin
B- Keratin
C- Albumin
D- Cysteine
Ans: C

142. Non-essential amino acids take alpha group from:
A- Pyruate dehydrogenase
B- Oxaloacetate
C- Glutamate
D- None
Ans: C

196- Thyroxine derived from:
A- Tyrosine
B- Thyroglobulin
C- Tryptophan
D- Niacin
Ans: A

143. Vitamin A is maximally found in:
A- Carrots
B- Oranges
C- Apples
D- Banana
Ans: A

144. Melatonin is derivative of:
A- Epinephrine
B- Nor epinephrine
C- Prolactin
D- Thyroxin
E- Tryptophan
Ans: E

Explanation:
Endproducts of Aminoacids metabolism
- **Tryptophan-** serotonin, melatonin, niacin
- **Glutamic acid** - GABA, glutathione
- **Phenylalanine and tyrosine** - Melanin, DOPA, dopamine, tyramine, epinephrine and non-epinephrine
- **Arginine** - urea, creatinine
- **Methionine and cysteine** - formation, CoA taurine and glutathione
- **Glycine** - serine, cysteine, glutathione formation, bile salts

145. Benedict test is for:
A- Glucose
B- Diabetes
C- Blood flow
D- Reducing substances of urine
Ans: D

146. A patient presents with hypoglycemia and Hepatomegaly. A glycogen storage disease known as von gierke disease is diagnosed. Which enzyme is deficient in this patient?
A- Alpha 1,4 Glucosidase
B- Glucose 6 Phosphatase
C- Myophosphorylase
D- Alpha 1,6 Glucosidase
Ans: B

147. The Glucose molecule present in Glycogen side chain is metabolized by which enzyme?
A- ATP
B- ADP
C- Glucose 1 phosphorylase
D- Kinase
E- Reductase
Ans: C

148. girl presented with persistent cough with thick mucus, wheezing and Repeated lung infections. She is also having petechia all over body and have bleeding tendency. She is diagnosed with cystic fibrosis. Which Vit is deficient in this case?
A- Vitamin A
B- Vitamin k
C- Vitamin D
D- Vitamin C
Ans: B

149. Collagen type in healthy skin:
A- Type 2and 3
B- Type 3 and 5
C- Type 1and 3
D- Type 1 and 2
Ans: C

150. Scurvy also causes:
A- Pericardial effusion
B- Chyothorax
C- Hemopericardium
D- Pleural effusion (transudative)
Ans: C

151. Arrangement of chromosomes on equatorial plate in
A- Prophase
B- Metaphase
C- Prometaphase
D- Telophase
Ans: B

152. What should be given to increase vitamin in diet?
A- Nuts
B- Yogurt
C- Egg
D- Green vegetables
E- Margarine
Ans: D

153. The end product of carbohydrate metabolism:
A- Fructose
B- Glucose
C- Galactose
D- Starch
E- Pyruvate
Ans: E

154. Patient having petechiae with increase bleeding time what's deficient:
A- Vitamin K
B- Vitamin C
C- Vitamin D
D- Vitamin A
Ans: A

155. Which of the following is associated with complete gastric resection?
A- IDA
B- Vitamin B12 deficiency
C- Folic acid deficiency
D- Sideroblastic anemia
Ans: B

156. Most immediate precursor of epinephrine is:
A- Tyrosine
B- Phenylalanine
C- Dopamine
D- Nor – Epinephrine
Ans: D

157. Least amount of minerals are found in:
A- Roots
B- Tubers
C- Cereal
D- Pulses
E- Veg (leaves)
Ans: B

158. What is glycocalyx?
A- Structural protein
B- Carbohydrate moiety
C- Receptor
D- Vitamin
Ans: B

159. Purine metabolism end product:
A- Uric acid
B- Amino acid
C- Fatty acid
D- Urea
Aas: A

160. Regarding Melatonin true is
A- Melatonin is produced from tyrosine
B- It accelerates / promotes puberty in humans
C- It is not metabolized by liver
D- It is secreted during day time
E- It inhibits pituitary gonadotropins
Ans: E

161. Child with loose skin with easy bruisability and Patient with defective procollagen 3. What can be the most striking complication in this case
A- Hypersensitive skin
B- Hypermobile joints
C- Problem in articular cartilage.
D- Rupture of large vessels
Ans: D

162. True about Nucleus:
A- Euchromatin is transcriptively active and formDNA
B- Hemotoxylin is blue dye which stain nucleus
C- Heterochromatin is active
D- DNA is single stranded
E- Euchromatin is inactive
Ans: A

163. Point mutation causes:
A- Sickle cell Anemia
B- Alpha thalasemia
C- Huntington disease
D- Beta thalasemia
Ans: A

CamScanner

Explanation:

- Missense mutation (type of point mutation) Examples: sickle cell disease (substitution of glutamic acid with valine).
- Nonsense mutation Results in early stop codon (UGA, UAA, UAG). Usually generates nonfunctional protein. Stop the nonsense!
- Frameshift mutation - Examples: Duchenne muscular dystrophy, Tay-Sachs disease.
- Splice site mutation - of β-thalassemia, Gaucher disease, Marfan syndrome.

164. Which Cells have telomerase:
A- Germ cells
B- Endothelial cells
C- Neutrophils
D- RBCs
E- Neurons
Ans: A

165. During conversion of fibrinogen to fibtin , what will be detected in blood
A- Fibtinopeptidase
B- TXA2
C- Transpeptidase
D- Plasmin
Ans: A

166. Which one is Essential amino acid
A- Phenylalanine
B- Glycine
C- Cysteine
D- Proline
Ans: A

Explanation:
Essential amino acids
PVT TIM HALL

- Phenylalanine
- Valine
- Threonine
- Tryptophan
- Isoleucine
- Methionine
- Histidine
- Arginine
- Leucine
- Isoleucine

Non-essential Amino acids : Rest of the 10 amino acids

- Alanine
- Asparginie
- Glycine
- Glutamate
- Cysteine
- Aspartate
- Glutamine
- Proline
- Serine
- Tyrosine

167. Findings in glycogen storage diseases:
A- Hepatomegaly and hypoglycemia
B- Hepatomegaly and hyperglycemia
C- Hepatomegaly and hypokalemia
D- Hepatomegaly and hyperkalemia
Ans: A

168. Hydrolysis of DNA release:
A- Ribose
B- Sugar
C- Phosporic acid
D- salt
Ans: C

169. Stage in which spindle fibers attach centromeres and divide:
A- Telophase
B- Metaphase
C- Anaphase
D- Prophase
Ans: C

170. Glycogen store more in which organ:
A- Liver
B- Skeletal muscle
C- Smoth muscle
D- bone
Ans: A

171. In which phase of cell division chromosomes are arrange in chromatic
A- Prophase
B- Metaphase
C- Anaphase
D- Telophase
Ans: A

172. Collagen atrophy leads to
A- Increase bleeding by minor trauma
B- Increased amount of soluble form in old age
C- Does not affect bones
D- Not involve in Ra
Ans: A

173. RBCS are:
A- Bio convex
B- Nonfragile
C- Have nucleus
D- Have glycolytic enzyme activity
Ans: D

174. An enzyme which combine two and make a single compound
A- Synthetase
B- Isomerase
C- Transferase
D- Telomeres
Ans: A

175. Alcohol causes deficiency of which vitamin:
A- Vitamin B1
B- Vitamin A
C- Vitamin D
D- Vitamin K
Ans: A

176. Essential fatty acid:
A- Linolenic acid
B- Lithocholic
C- Cholic acid
D- methionine
Ans: A

Which one is essential amino acid?
A- Serine
B- Tyrosine
C- Threonine
D- Proline
Ans: C

178. Which vitamin take part in the formation of clotting factors?
A- Vit A
B- VIT K
C- Vit E
D- Vit C
Ans: B

179. A child with recurrent respiratory tract infection and also having kartagner syndrome defect in
A- Dyncin arm
B- Actin
C- Mysoain
D- Cell microtube
Ans: A

180. A boy while playing was hit to right elbow. He developed swelling and bruise. What is the cause of swelling?
A- Carbohydrates
B- Proteins
C- Fats
D- LDL
E- Water and electrolytes
Ans: B

181. Regarding Glycolysis which one is correct?
A- Reversible
B- Hexose phosphate converted to lactate and pyruvate
C- Same as Hexose monophosphate shunt
D- Includes hexose sugars to pyruvate
Ans: D

182. Avidin binds with:
A- Biotin
B- Vit B12
C- Vit C
D- Vit D
E- Riboflavin
Ans: A

183. High magnesium stores are present in
A- Bone
B- Soft tissue
C- Cartilage
D- Ligaments
Ans: A

184. Which Amino acids is not synthesized in body
A- Methionine
B- Glutamate
C- Alanine
D- Glycine
Ans: A

185. Difference between malignant and normal cells such that malignant cells repair the shortening of chromosome so that they can continue dividing. Enzyme responsible?
A- Telomerase
B- Reverse transcriptase
C- Isomerase
D- Lipase
Ans: A

186. Vitamin required for the dietary fatty acids to undergo beta oxidation in cells:
A- Thiamine
B- Biotin
C- riboflavin
D- Niacin
Ans: B

187. Which of the following enzymes is involved in the transfer of radicals from one compound to another?
A- Isomerases
B- Oxidoreductases
C- Transfemses
D- Telomeres
Ans: C

188. From which metabolism most effective gluconeogenesis is resulted
A- Fatty acids
B- Protiens
C- Cholesterol
D- Glycogen
E- Lipid
Ans: B

189. Prolonged use of paraffin leads to deficiency of
A- Vitamin A
B- Vitamin B
C- Vitamin C
D- Vitamin D
E- Vitamin E
Ans: A

190. Which of the following amino acids is not formed in the body & has to be taken in diet?
A- Phenylalanine
B- Alanine
C- Tyrosine
D- Glycine
Ans: A

CamScanner

191. The protien rich in basic Aminoacids which functions in the packaging of DNA in chromosomes is
A- Histone
B- Colagen
C- Hyaluronic acid binding protien
D- Fibrinogen
Ans: A

192. Carbohydrate source in diabetic patientsis
A- Wheat chapatti
B- Bread
C- Cakes n bibiscuit
D- Apple
Ans: A

193. Richestsourceof Vitamin – D:
A- Cod liver oil
B- Milk
C- Liver
D- Margrine
Ans: A

194. Most common type of hyperlipidemia
A- Type 1
B- Type5
C- Type 3
D- Type4
Ans: D
Explanation:
- Type 2 more common in children
- Type 4 more common in adults

195. Collagea arraaged in which layer:
A- Reticular layer
B- Dermis
C- Epidermis
D- Stratum corneum
Ans: A

196. For nutritional assessment of patient we assess aatrition from his weight loss by
A- Traces elements
B- Mineral and vitamins
C- Albumin and TIBC
D- Carbohydrates
Ans: C

197. Patient on steroid now abscess is formed on upper outer half of arm after drainage itealtag process is very slow though a month has been passed reason:
A- Decrease collagen formation
B- Decrease neutrophil migration
C- Infection
D- Decrease body cells
Ans: A

198. The unwanted effects of hyperbaric oxygen administration can be avoided by administering:
A- Vit D
B- Vit A
C- VitE
D- VitD
Ans: C

199. Sickle cell disease due to
A- Point mutation
B- Mismatch repair failure
C- Missense mutation
D- Splice mutation
Ans: C>A

200. Weight gain in the body is regulated weekly by:
A- Food
B- Work output
C- Mark body image
D- Na bicarbonate regulation
Ans: B

201. In the presence of oxygen, end product of glycolysis is:
A- Lactic acid
B- 1 molecule of Pyruvic acid
C- 2 mol of Pyruvic acid
D- 3 molecules of pyruvic acid
Ans: C

202. Which is not sign of malnutrition:
A- Dry pigmented skin
B- Leucopenia
C- Pittingedema
D- Cheilosis
E- Stomatitis
Ans: B

203. A man working in a factory has developed decreased sensation in legs. Exposure to which of the following is responsible for this?
A- Copper
B- Lead
C- Mercury
D- Iron
Ans: B

204. Source of nitrogen in urea cycle
A- Aspartate and ammonia
B- Glutamate and ammonia
C- Arginine and aminonia
D- Uric acid
Ans A

205. Chromosome replication occurs in which stage:
A- Interphase
B- Metaphase
C- Anaphase
D- Prophase
Ans: A

206. Which amino acid deficiency causes cell injury?
Leucine
A- Lycine
B- Glycine
C- Choline
D-
Ans: C

207. In uren cycle one amino group is given by glutomate other one by:
Aspartate
A- Lysine
B- Alanine
C- NH4CL
D-
Ans: A

208. Dry heat kills bacteria by
A- Coagulotion of proteins
B- Cell lysis
C- Free radical formation
D- Oxidation
Ans: D
Explanation:
- Dry heat - oxidation
- Moist heat by coagulation of proteins

209. In PKU phenylalanine is not converted to:
A- Tyrosine
B- Homogemstic acid
C- Leucine
D- Isolcucine
E- Serotonin
Ans: A

210. Which protein is associated with obesity?
A- Fibrin
B- Leptin
C- Lecithin
D- Taurine
Ans: B

211. Structure of carbohydrates can be well elaborated as complex branched structure
A- Have 1,6 linkage in chain and 1,4 in branches
B- Have 1, 4 linkage in chain and 1, 6 in branches
C- Have 2,6 linkage in chain and 1,4 in branches
D- Have 1, 6 linkage in chain and 2, 4 in branches
Ans: B

212. Tyrosine derivative:
A- Norepinephrine
B- Prolactin
C- Glutathione
D- urea
E- glutathione
Ans: A

213. Longitudinal striations on light microscopy are in:
A- Collagen
B- Reticular
C- Elastic
D- Dermis
Ans: B

214. Egg contains protein avidin . Eating raw eggs will leads to its deficiency which causes
A- Increase transamination
B- Decease phosphorylation
C- Decrease carboxylation
D- Decrease COA formation
Ans: C

215. TAGS are produced from which cells?
A- Myocytes
B- Cardiocytes
C- Hepatocytes
D- Adipocytes
Ans: D

216. Why we check lecithin sphingomyelin ratio in amniotic fluid?
A- To check neural tube defect
B- To check lung maturity
C- To check chromosomal abnormality
D- to check heart maturity
Ans: B

217. Avidin is present in
A- Cow's milk
B- Raw egg white
C- Green leafy vegetables
D- Carrots
E- Orange
Ans: B

218. Humaas can easily tolerate a lack of which nutrient?
A- Proteins
B- Lipids
C- Carbohydrate
D- Calcium
E- Iodine
Ans: C

219. Chromatids are parallel in?
A- Prophase
B- Metaphase
C- Anaphase
D- Telophase
Ans: A
Explanation:
- Parallel in prophase
- Align equatorial plate - metaphase
- Doubling in - telophase

220. Homocystenemia caused by?
A- Vitamin E
B- Vitamin B5
C- Vitamin B12 deficiency
D- Vitamin B9 deficiency
Ans: C

221- Free radicals removed by?
A- Transferrin
B- Superoxide
C- Catalase
D- H2O2
Ans: A

222- During active protein synthesis:
A- Prominent nucleolus
B- Prominent RER
C- Prominent sSER
D- Prominent Golgi bodies
Ans: A

223- RER function
A- DNA synthesis
B- Protein synthesis
C- Microbicidal activity
D- lipids synthesis
Ans: B

224- Phenylalanine can't be converted to tyrosine in which of the following?
A- Phenylketonuria
B- Galactosemia
C- MSUD
D- Hemaluria
Ans: A

225- Vitamin E deficiency manifests as:
A- Bowed legs
B- Shiny skin
C- Silky hairs
D- Hyperkeratosis
E- Muscular dystrophy
Ans: E

226- FAT gives how much percentage calories?
A- 40-45%
B- 30-35%
C- 30-50%
D- 15-20%
Ans: B
Explanation:
- Carbs Required- 50-60%
- Fats Required- 25-35%
- Proteins Required- 10-20%

227- High energy compound:
A- ATP
B- ADP
C- AMP
D- Starch
Ans: A
Explanation:
- Highest energy compound -ATP
- Highest energy molecule – ATP
- Highest energy content -Starch

228- Glucogenic Aminoacid:
A- Histidine
B- Leucine
C- Lysine
D- Isoleucine
E- Threonine
Ans: A
Explanation:
Glucogenic Aminoacids
- Histidine
- Arginine
- Valine
- Methionine

Ketogenic Aminoacids
- Leucine
- Lysine

229- Amino acid having negative charge:
A- Aspartate
B- Arginine
C- Lysine
D- Histidine
Ans: A
Explanation:
- Postive charge – HAL(Histidine, Arginine & Lysine)
- Neagtive Charge – Aspartate and Glutamate

230- A female patient underwent C Section 3 months back. Her wound is not healing properly. She is taking diet rich in proteins and carbohydrates but deficient in fruits and vegetables. What vitamin Deficiency cause poor wound healing?
A- Decrease Tensile Strength of Wound
B- Decrease Vitamin C
C- Decrease Vitamin K
D- Decrease Synthesis of Type II Collagen
E- Decrease Vitamin B
Ans: B

231- A patient has increased hepatic glycogen with normal structure of liver no increase in serum glucose occurs after giving fructose which enzyme will be deficient?
A- Fructokinase
B- Glucose 6 Phosphatase
C- Hexokinase
D- Glucokinase
E- Fructose 6 Phosphatase
Ans: B

232- The highest content of triglyceride present in Chylomicron
A- HDL
B- IDL
C- LDL
D- VLDL
E-
Ans: A

233- Factor needed for co enzyme A is which of following?
A- Biotin
B- Pantothenic acid
C- Biotin
D- Folic acid
E- B2
Ans: B
Explanation:
- Vitamin B5 (pantothenic acid) - component of coenzyme A
- Vitamin B7 (biotin)- cofactor for carboxylation reactions

234- High output cardiac failure and cardiomyopathy occurs in:
A- Vitamin C deficiency
B- Scurvy
C- Beriberi
D- Vitamin B3 deficiency
E- Hemophilia
Ans: C

235- Normal healthy individual is?
A- Who eats sleeps & exercises regularly & leads a disciplined life
B- Economically Occupationally socially acceptable Free of discomfort
C- Who is famous in his society
D- Who sleeps only
Ans: A

236- A patient having phenyl alanine in urine due to
A- Alkaptonuria
B- Phenylketonuria
C- Galactosemmia
D- Fructosuria
Ans: B

237- Most potent antioxidant:
A- VitammE
B- Vitamin A
C- Glutathione
D- Vitamin C
Ans: C
Explanation
- Glutathione > Transferrin > Vitamin E > Vitamin C > Vitamin A.

238- Kidney stone due to oxalic glycoxalic which aminoacid defective
A- Glycine
B- Isolucine
C- Leucine
D- Lycine
E- Tryptophan
Ans: D

239- Energy production by complete oxidation of 1 gram of fat:
A- 4kcal
B- 5kcal
C- 6kcal
D- 9kcal
E- 11kcal
Ans: D
Explanation:
- Carbs/Protein Give- 4kcal
- Fats Give- 9kcal
- Alcohol Give- 7kcal
  - Carbs Required – 50-60%
  - Fats Required – 25-35%
  - Proteins Required – 10-20%

240- Pregnant female taking iron supplements She will have deficiency of?
A- Vitamin A
B- Vitamin B
C- Vitamin D
D- Magnesium
E- Folic Acid
Ans: E (Prefer Calcium if present)

241- Dark black urine in which disease ?
A- Alkaptonuria
B- Phenylketonuria
C- Maple syrup urine disease
D- Porphyria
Ans: A

242- Which of the following vitamin is deficient after acute pancreatitis?
A- B12
B- B7
C- VitaminD
D- Vitamin C
E- Thiamine
Ans: C

243- Thiamine deficiency results in:
A- Increase Pyruvate
B- Decrease pyruvate and increase lactic acid
C- Decrease lactate
D- Decrease formation of Proteins
Ans: B

CamScanner

244- Niacin deficiency causes which of the following effects?
A- PNS defects
B- CNS defects
C- Epithelial defects
D- Limb defects
E- Enzyme defect
Ans: B

245-. Iron is readily absorbed in which form:
A- Ferrous form
B- Ferric form
C- Boundform
D- With oxalate in diet
E- With phosphate in diet
Ans: A

246. The tumour suppressor gene p53 induces cell arrest at:
A. Mphase
B. G1-S pbase
C. $G_o$pbase
D. S-G2 phase
Ans: B

247. Which of the following enzymes is involved in carbohydrate metabolism?
A- Enterokinase
B- Lactase
C- Amylase
D- Trypsin
E- Chymotrypsin
Ans: B

248. Hexosaminase A deficiency occurs in:
A- Tay sach disease
B- Neurofuromatosis 1
C- Neurofiromatosis 2
D- Von Gierke disease
Ans: A

249. In basal metabolism heart derives 60%energy form:
A- Fat
B- Carbohydrate
C- Protein
D- Vegetables
Ans: A

250. Norepinephrine synthesis require which enzyme:
A- Methyl transferase
B- Dopamine hydroxylase
C- Dopa decarboxylase
D- Isomerase
E- Synthetase
Ans: B(FA)

251. A 6 year old child with apathy, [illegible] edenin and enlarged liver. Her investigations are as follows: Hb2 $12\times10^{\wedge}9$, platelets: 150×10^{9}, albumin: 28 (lower than the normal range), vitamin D: 30, calcium: 35 diagnosis
A- Kwashiorkor
B- Rickets
C- Beri beri
D- Marasmus
Ans: A

252. Catecholamines synthesis occurs from which amino acid:
A- Serotonin
B- Tryptophan
C- Melatonin
D- Tyrosine
E- Epinephrine
Ans: D(FA)

253. A women deliver a baby with cleft palate and congenital birth defects she gave history of taking drug for acne the likely risk factor is:
A- Retinoic acid
B- Ascorbic acid
C- Iron deficiency
D- Cobalamine
E- Calciutn
Ans: A

254. What of the following is the full source of thiamine:
A- Tubers
B- Minerals
C- Vegetables
D- Wheat
E- Fruits
Aos: D

255 25 cholecalciferol conversion occur in:
A- Liver
B- Intestine
C- Kidney
D- Bone
E- Spleen
Ans: C
Explanation:
- 7 dehydrocholesirol into Vitamin D3 by sun rays in Skin
- Vitamin D3 into 25(OH)Vitamin D by 25 hydroxylase in Liver
- 25(OH)D3 into 1,25(OH)2 Vitamin D by 1 alpha hydroxylase in kidney

256. In Phenylalanine which amino acids diet is restricted:
A- Sulfur containing
B- Aromatic ammo acids
C- Lysine
D- Methionine
Ans: B
Explanation:
- Aromatic ammo acids like Tyrosine , Phenylalanine and tryplophan should not be given

257. Child during day time difficulty in seeing, loss of pigment in hair, skin and enzymes, which enzyme is deficient in this?
Lipase
A- Amylase
B- Maltase
C- Tyrosinase
D- Trypsin
E- D
Ans: D

258. Enzyme increase the rate of reaction by:
A- Increasing the activation energy
B- Decreasing the activation energy
C- Making more free energy
D- Changing the equilibrium constant
Ans: B

259. Major Source of energy for brain in compensatory stage during 24 hr:
A- Fatty acids
B- Carbohydrates
C- Protein
D- Aminoacids
E- Ketone bodies
Ans: E

260. Morphine metabolized by:
A- Glucoronidarion
B- Acetylation
C- Oxidation
D- Deamination
Ans: A

261. Smell of burnt urine is present in:
A- Phenylketonuria
B- Alkaptonuria
C- Maple Syrup urine disease
D- Mcardle disease
Ans: C

262. In a healthy man protein digestion starts from:
A- Mouth
B- Stomach
C- Duodenum
D- ilium
E- Intestine
Ans: A

263. Palient on total parenteral nutrition develop alopecia and Scaly dermatitis likely due to deficiency of
A- Vitamin A
B- Zinc
C- Vitamin C
D- Potassium
E- Vitamin D
Ans: B

264- A 12-year-old girl is brought to the physician because of a 2-month history of intermittent yellowing of the eyes and skin. Physical examination shows no abnormalities except for jaundice. Her serum total bilirubin concentration is 3 mg/dL, with a direct component of 1 mg/dL. Serum studies show a haptoglobin concentration and AST and ALT activities that are within the reference ranges. There is no evidence of injury or exposore to toxins. Which of the following additioual findings is most likely in this patient?
A- Decreased activity of UDP glocuronosyl transferase
B- Gallstones
C- Increased hemolysis
D- Increased serum alkaline phosphatase activity
E- Ineffective erythropoiesis
Ans: A

265- Maximum energy derived from:
A- Carbohydrates
B- Ketones
C- Proteins
D- Lipids
Ans: D

266- Which of the following causes secretory diarrhea when reaches colon in large quantities?
A- Sucrose
B- Lactose
C- Chenodeoxycholic
D- Dipeptides
Ans: B

267- Anti-aging is by which?
A- Decrease calorie diet
B- Decrease cellular Replication
C- Damage to cellular protein
D- Decrease Cellular protein
Ans: A

268- An important function of vitamin A is?
A- To maintain the integrity of epithelial tissue
B- To help in collagen formation
C- Form germinal epithelium
D- Form fibroblast
Ans: A

269- Most common element in lipid is:
A Na
B- Phosphorus
C- Magnesium
D- Carbon
Ans: D

CamScanner

270- Which Vitamin Deficiency cause creatinuria?
A- Vitamin A
B- Vitamin B
C- Vitamin C
D- Vitamin E
Ans: D

271- Mother milk is deficient in:
A- Vitamin C
B- Vitamin A
C- Casein
D- Lactalbumin
E- Pantothenic acid
Ans: A (Chatterjea biochemistry)

272- Most potent antioxidant is:
A- Vit. E
B- Vitamin K
C- Vit.C
D- Vit A
Ans: A

273- G6PD associated with
A- Chronic intra hemolysis
B- Chronic extra vascular hemolysis
C- Acute intravascular hemolysis
D- Favisim
Ans: D

274- Vitamin A in retina is
A- Rhodopsin
B- Retinol
C- Opsonin
D- Retinal
Ans: D

275- True regarding Triple X syndrome
A- Abnormal phenotype
B- More intelligent
C- Sex chromatin positive
D- More hair
Ans: B

276- Coogenital erythropoietic porphyria which eazyme will be deficient
A- Uroporphyrinogen 3
B- Uroporphyro 2
C- Transminase
D- Urinasealpha
Ans: A

277 Chromosomal maneuring doesnot occur in
A- Asexual reproduction
B- Cleavage
C- Meiosis I
D- Meiosis 2
E- Mitosis
Ans: A

278- Chenodeoxycholic acid decrease turnover in
A- Cholestyramine
B- Lipase
C- Ileal resection
D- Colostomy
Ans: C

279- Pregnant female not taking supplements during pregnancy She will have deficiency of
A- Vitamin A
B- Vitamin B
C- Vitamin D
D- Iron
E- Folic Acid
Ans: E

280- Removal of some of carbohydrate bound to serum protein resultin
A- Aggregation and precipitation
B- Rapid uptake and destruction by liver
C- Rapid excretion by kidney
D- Rapid absorption by liver
Ans: A

281- Porphyrins attached to whith in plasma?
A- Iron
B- Albumin
C- Gemma Globulin
D- Transferrin
Ans: B

282- Riboflavin combine with phosphate to form
A- NAD
B- NADPH
C- FAD and FMN
D- Glutathion
Ans: C

283- Progesterone is precursor of:
A- Aldosterone.cortisol.corticosterone
B- Aldossterone.deoxycholic acid, pregnolone
C- Cholesterol.cortisone.cholic acid
D- Corticosterone.testosterone.cholesteryl sulphate
E- Hydrocortisone.pregnolone &esriol
Ans: A

284- Pyruvate is intermediate between
A- Glucose and acetyl-coA
B- Acetoacetic acid and acetyl-coA
C- Carbohydrate and protein
D- Glucagon and fructose
Ans: A

285- Vit C function is
A- Hydroxylation of glycine and proline residues
B- Hydroxylation of proline and lysine residues
C- Reducing agent
D- Anti inflammatoly
Ans: B

286- Patient bad history of recurrent bleeding. Easy bruising and hemolytic anemia most likely pathology is:
A- B1 Deficiency
B- Cobalamine Deficiency
C- Ascorbic acid Deficiency
D- Hydroquinne Deficiency
Ans: C

287- For utilisation in energy production , fatty acids from adipose tissue are transporteil to liver , kidney and muscle as:
A- Camitine acyl esters
B- VLDL
C- Free fatty acid bound to albumin
D- LDL
E- Triglycerides bound to albumin
Ans: C

288- Cyanide poisoning will affect which complex of electron transport chain?
A- Complex 3
B- Complex 1
C- Complex 2
D- Complex 4
Ans: D (FA)
Explanation:
- Complex 1 inhibits by – Rotenone
- Complex 3 mhibited by – Antimycin A
- Complex 4 mhibited by – Cyanide, CO and Azide
- Complex 5 mhibited by – Oligomycio

289- First inauifestation of vitamin A deficiency is:
A- Xerophthalmia
B- Bitot spot
C- Keratomalacia
D- Night blindness
E- Vascularization
Ans: D

290- A patient with history of resection of terminal ileum during surgical exploration in laparotomy which vitamin will be deficient?
A- Vitamm B 1
B- Vitamm B12
C- Niacin
D- Folate
E- Vitamin B6
Ans: B

291- Patient was diagnosed to have gout, which of the following enzymes could be targeted by allopurinol for the treatment of this patient?
A- Guanase
B- Hypoxanthine guanine phosphpribosyl transferase
C- Nuleotidase
D- Phospboribosylpyrophosphate synthase
E- Xanthine oxidase
Ans: E

292- First sign of hypervitaminosis A is:
A- Anemia
B- Jaundice
C- Night blindness
D- Peripheral neuritis
Ans: B

293- What will be incresed in vitamin D deficiency
A- ALP
B- Metabolize Ca from bones
C- Phosphorus
D- LDH
E- AST
Ans: A

294- Trypsin acts on which amino acid?
A- Terminal carboxylic group amino acid
B- Glycine
C- Lysine
D- Tryptophan
E- Tyrosine
Ans: A

295- Free radical formation inhibited by:
A- Nadph Oxidase
B- Hydrogen peroxide
C- Hydrolase
D- Chloride
Ans: A

296- Child diagnosed with genetic cause of hypercholesterolemia father has also some problem defect will be in
A- LDL receptor
B- Chylomicron
C- Cholesterol
D- VLDL receptor
E- HDL receptor
Ans: A

297- Diet In Patient with Type I hyperlipidemia:
A- Decrease intake of cholesterol and saturated fats
B- Decrease fat intake with weight reduction
C- Decrease vegetables
D- Increase Fat intake and low Vegetables
Ans: A

CamScanner

298- In kawashiorkor there is:
A- Calorie deficit
B- Protein Energy malnutrition
C- Lipid deficit
D- Protein Excess
Ans: B

299- Major site of gluconeogenesis is
A- Liver
B- Spleen
C- Thyroid
D- Pancreas
Ans: A

300- Ketogenic amino acids
A- Lysine + Lucine
B- Glycine + isoleucine
C- Tyrosine
D- Tryptophan
Ans: A
Explanation:
- Ketogenic – Leucine and Lysine
- Posive charge – HAL (Histidine, Arginine & Lysine)
- Negtive Charge – Aspartate and Glutamate
- DNA has – Histidine

301- A 16 year boy presented to OPD with 104 fever for last 4 days and prescribed antimalarial for fever. After 12 h he presented with cola colored urine. What is the cause?
A- G6PD
B- Black Water fever
C- Drug induced jaundice
D- Paroxysmal nocturnal hemoglobinuria
E- Hemaolytic uremic syndrome
Ans: A

302- Bile Acids are conjugated with which amino arid to form bile salts .
A- Glycine and Taurine
B- Bilirubin glucoronyltransferase
C- Arginine
D- Glutamine
Ans: A

303- Increase free bile acids present in:
A- Cholestrolemia
B- Hyper lipidemia
C- CLD
D- CKD
Ans: B

304- Pellagra is associated with deficiency of:
A- Cobalamine
B- Riboflavin
C- Thiamine
D- Folate
E- Niacin
Ans: E

305- Maple syrup urine diseases is an error of metabolism
A- Sulphur containing amino acid
B- Aromatic ammo acid
C- Branched chain ammo acid
D- Dicarboxylic ammo acid
Ans: C

306- G2 phase between
A- S and M
B- G1 and G2
C- Prophase
D- Diplotene
Ans: A

307- Glucose transport in skeletal muscle by
A- GLUT 1
B- GLUT4
C- GLUT2
D- GLUT-3
E- GLUT-6
Ans: B

308- Intrinsic factor required for which of following:
A- Cobalamin Transport
B- Cobalamin absorption
C- IV B12
D- Cofactor
Ans: B
Explanation:
- For B12 Absorption Needed – Intrinsic Factor
- For B12 Transport Needed – Transcobalamin 2

309- In Gaucher disease there is deficiency of:
A- Hexosaminadase-A
B- Glucocerebrosidase
C- Fructokinase
D- Hexokinase
E- Glucokmase
Ans: B

310- More cell division Enzyme involved in shortening of DNA is:
A- Helicase
B- R topoisomerase
C- Telomerase
D- Topomerase
Ans: C

311- G1 phase following occur:
A- Doubling of chromosome
B- Doubbling of DNA
C- Duplicauon of centrosome
D- Nucleolus duplication
Ans: C

312- G6pd characteristic is:
A- Reticulocytocts
B- Bite cells
C- Increase indirect hyperbilirubinemia
D- Raised ESR
Ans: B

313- What is the recommended daily protein requirement for an average adult, expressed as a percentage of daily caloric intake?
A- 5%
B- 10-15%
C- 25%
D- 50%
Ans: B
Explanation:
- Carbs/Protien Give – 4kcal
- Fats Give – 9kcal
- Alcohol Give – 7kcal
- Carbs Required – 50 – 60%
- Fats Required – 25 – 35%
- Protiens Required – 10 – 20%

314- Fats absorbed from intestine as:
A- LDL
B- Chylomicroo remnants
C- Mixed Micelles
D- Chylomicrons
Ans: C
Explanation:
- Absorbed as Mixed micelles and transported as Chylomicrons

315- What is the term for the density of a substance compared to the density of water at a specified temperature and pressure"?
A- Specific volume
B- Relative density
C- Specific gravity
D- Mass density
Ans: C

316- What is the term for the density of a substance compared to the density of CSF?
A- Specific volume
B- Relative density
C- Specific gravity
D- Mass density
E- Baricity
Ans: E

317- Which gas law states that the "The total pressure exerted by a mixture of non-reacting gases is equal to the sum of the partial pressures of individual gases"?
A- Henry's law.
B- Dalton's law
C- Boyle's law
D- Fick's law
Ans: B

318- The capillaries can withstand high internal pressures without bursting is explained using:
A- Bernoulli's principle
B- Laplace's law
C- Poiseuille Hagen law
D- Fahraeus-Lindquist effect
Ans: B

319- Time constant:
A- Half life is time constant
B- It is time to reduce drug to half concentration
C- 95 % is till 3 halflife
D- 33% is till 2 halflife
E- Area under curve
Ans: E

320- Plasma protein drugs related:
A- Temporarily inactive
B- Inactive until activated by liver
C- Only act in blood
D- Excreted in or max in GFR
Ans: B

321- A woman wants to decrease her weight what will be most effective step for her management:
A- Increase caloric intake
B- Low Fiber diet
C- Self monitoring
D- Lipolysis
Ans: C

322- Par boiling of pads preserves which vitamin?
A- B1
B- B2
C- B3
D- B4
E- B6
Ans: A

323- RBCs synthesize ATP from glucose Glycolysis enzyme present in:
A- Nucleus
B- Cytoplasm of RBC
C- Mitochondria
D- Cell membrane
Ans: B

324- Intramitochondrial protein synthesis by:
A- ATPase
B- Cytochrome
C- Nuclei gene
D- Golgi apparatus
Ans: C

CamScanner

325- Plasma proteins filtered in minute amount from kidney because filtration is opposed by membrane due to:
A- Negative charge of proteoglycan on basement membrane
B- Large size
C- Positive charge
D- Medium size
Ans: A

326- Glutamate aminotransferase and Alanine aminotransferase formation use which Vitamin:
A- B12
B- B6
C- B2
D- Biotin
E- Thiamine
Ans: B

327- Steatorrhea is caused by:
A- Lipase deficiency
B- Inactivation of pancreatic lipase
C- Activation of pancreatic lipase
D- Amylase deficiency
Ans: B

328- When phenylalanine enzyme is deficient then what will accumulate in body:
A- Serotonin
B- Melanin
C- Dopamine
D- Tyrosine
E- Melatonin
Ans: D

329- In low sbhorkor there is:
A- Protein excess
B- Obesity
C- Protein deficiency
D- Lipid excess
Ans: C

330- G1 to next phase requires:
A- DNA
B- Microtubule
C- RNA
D- Ribosomes
Ans: A

331- Final processing of carbohydrate in glycoprotein occurs in?
A- Mitochondria
B- Golgi bodies
C- Nucleus
D- Lysosomes
E- SER
Ans: B

332- Triglycerides in lipoprotein hydrolysed by which enzyme?
A- Amylase
B- Lipoprotein Lipase
C- Linguae
D- Hormone sensitive lipase
Ans: B

333-Vitamin given with isonlazid is
A- Cobalamine
B- Folic acid
C- B6
D- B1
E- B9
Ans: C

334- A child develop night blindness presented to paediatrician which he should be given to patient
A- Rhodopsin
B- Retinol
C- Opsonin
D- Retinaldehyde
Ans: D

335-PT, APTT replenishes after antibiotic by giving
A- Vitamin A
B- Vitamin C
C- Vitamin K
D- Vitamin D
Ans: C

336- Dietary source of serotonin is
A- Epinephrine
B- Nor epinephrine
C- Prolactin
D- Thyroxin
E- Tryptophan
Ans: E

337- Correct sequence of protein synthesis?
A- Nucleotide , mRNA , tRNA and ribosome
B- Ribosomes , Nucleoude ,mRNA
C- mRNA, cytoplasm, ribosome, tRNA amino acid
D- Ammo acids ,cytoplasm, nucleonde
Ans: C

338- A child with blue sclera and multiple fractures his uncle suffer from same condition diagnose is:
A- Rickets
B- Scurvy
C- Osteogenesis imperfecta
D- Achondroplasia
Ans: C

339- A Fatty person has history of hyperlipidemia which type is dangerous for heart leading to MI?
VLDL
A- LDL
B- HDL
C- Chylomicron
D-
Ans: B

340- Iron present in ferrous form in
Ferritin
A- Ferrous
B- Ferric
C- Hemosiderin
D-
Ans: A
Explanation:
- Iron Transport form – Transferrin
- Iron excess storage form – Hemosiderin
- Iron normal storage form – Ferritin

341- A patient presents with hypoglycemia and Hepatomegaly having recurrent episodes of fainting, improved conscious on feeding. He is having increased lactate level and ketones. A glycogen storage disease known as von gierke disease is diagnosed. Which enzyme is deficient in this patient?
A- Alpha 1,4 Glucosidase
B- Glucose 6 Phosphatase
C- Myophosphorylase
D- Alpha 1,6 Glucosidase
Ans: B

342- Cytokeratin is an intermediate filament found in cells but is most commonly used for detection of:
A- Degree of metaplasia or dysplasia
B- To check rate of proliferation
C- For staging of disease
D- For growth
F- Identification of Neoplasia confirm to be carcinoma
Ans: E>A

343- Child with multiple fractures blue sclera family history of similar disease .Defects in which
A- Fibrillin
B- Collagen
C- Elastin
D- Protein
E- Amyloids
Ans: B

Explanation:
This is the case of osteogenesis imperfecta

344- A 6 year old child with apathy, peripheral edema and enlarged fatty liver. Her lab investigations are as follows: Hb:8, tlc: 12×10^9, platelets: 150×10^9, serum albumin: 28 (lower than the normal range) . What can be the cause of fatty liver in this child?
A- Protein deficiency leading to decreased lipoprotein
B- Protein deficiency leading to increased lipoprotein
C- Low calorie diet
D- Low Carbohydrate diet
E- Low fat diet
Ans: A

345- Carbohydrates/Polished rice is regularly consumed by a lady. Dr prescribed her to eat brown bread of Wheat. What does it contain?
A- Riboflavin
B- Thiamine
C- Biotin
D- Pantothenic
Ans: B
Explanation:
- For Carbohydrate – Thiamine
- For Protien – Riboflavin
- For Lipid – Biotin

346- A patient presented with scaly skin, Loss of memory & frequent episodes of diarrhea. This is caused by deficiency of which of the following vitamin?
A- Thiamine
B- Riboflavin
C- Niacin
D- Folate
Ans: C

347- 28 year old woman presented with easy bruisability, Inc tendency to bleed & Loose teeth. Cause of this
A- increased hydroxylation of proline & lysine residues
B- Deficiency of lysyl oxidase
C- Decreased Formation of unstable Triple Helix collagen
D- Increased collagen fibroblast
Ans: B

CamScanner

348- Fats transport from intestine as:
A- LDL
B- Chylomicron remnants
C- Mixed Micelles
D- Chylomicrons
Ans: D

Explanation:
- Absorbed as Mixed micelles and transported as Chylomicrons

349- Which food contains highest amount of Vitamin K?
A- Tubers
B- Fruits
C- Green vegetables
D- Meat
E- Wheat
Ans: C

350- Glucose is transported in cells of muscles & adipose tissue by which of the following?
A- GLUT 1
B- GLUT2
C- GLUT4
D- Facilitated Diffusion
E- Active transport
Ans: C

351- Carbonic anhydrase is very useful as it catalyses the conversion of Co2 into bicarbonate and is readily available as it is located in:
A- Cytoplasm of neutrophil
B- Cytoplasm of basophil
C- Cell membrane of RBC
D- Cytoplasm of RBC
E- Cell membrane of neutrophil
Ans: D

352- Total ATP Productioo after Aerobic glycolysis & Kreb's cycle?
A- 34
B- 38
C- 36
D- 2
E- 4
Ans: B

Explanation:
Net=36ATP
Gross=38ATP

353- If urine sample darkens on standing: the most likely condition is:
A- Phenylketonuria
B- Alkaptonuria
C- Maple syrup disease
D- Tyrosinemia
Ans: B

354- People consuming polished rice as staple food are prone to deficiency of
A- Riboflavin
B- Niacin
C- Thiamine
D- Folate
Ans: C

355- Wadding gait like difficulty in standing from squatting position enzyme involved?
A- Tyrosine kinase
B- Creatinine phosphokinase
C- Glucose 6 phosphatase
D- None
Ans: B

356- A patient with ability of perception of red color of apple as red but differentiate from green is called
A- Hemianopia
B- Quadrianopia
C- Protonopia
D- Heteroanopia
Ans: C

Explanation:
- Can't differentiate Between Red and green -Protonopia
- Can't differentiate Between Green and red -Deutronopia

357- Homocycystinemia is associated with deficiency of which vitamin:
A- B12
B- B1
C- Vitamin A
D- B6
E- B3
Ans: A

358- Patient has complaint of loose stools, scaly itching and memory problems. Findings are suggestive of which vitamin deficiency:
A- Vitamin B3
B- Vitamin B1
C- Vitamin B6
D- Vitamin B2
E- Vitamin B12
Ans: A

Explanation:
- B1 Deficiency – Dry Beri beri, Wet Beri beri,Wernicke korsakoff Measured by Transketolase activity
- B2 Deficiency – Corneal Vascularization
- B3 Deficiency – Pellagra (Diarrhea, Dementia, Dermatitis)
- B5 Required – Co factor for Co enzyme A
- B5 Deficiency – Adrenal Insufficiency
- B7(Biotin) – Bind Avidin in egg and
- Carrier of One carbon
- B7 – Role in liver Metabolism
- B9(Folic acid) – One Carbon Transfer
- B9 Deficiency – NTD
- B12 Deficiency – Megaloblastic Anemia

359- Increase Homocysteine due to deficiency of:
A- Vitamin E
B- Vitamin B5
C- Vitamin B12
D- Vitamin B9
E- Vitamin B6
Ans: C

360- Proteins give how much percentage calories?
A- 40-45%
B- 30-35%
C- 30-50%
D- 15-20%
Ans: D

Explanation:
- Carbs Required- 50-60%
- Fats Required-25-35%
- Proteins Required 10-20%

361- Resting percentage of Respiratory energy:
A- 5%
B- 20%
C- 100%
D- 80%
Ans: A

362- Boyle's law is:
A- Pressure directly proportional to volume
B- Pressure directly proportional to temperature
C- Pressure inversely proportional to volume
D- Applied to all gases
Ans: C

363- 4 months old child present with 70% of body weight. Fatty liver, abdominal edema, depigmentation. Diagnosis is:
A- Addison disease
B- Kwashiorkor
C- Marasmus
D- Hypothyroidism
Ans: B

364- 2 litres of 2 different gases of different molecular weight contains:
A- Equal number of molecules
B- Equal number of atoms
C- Equal mass of each gas
D- Equal density of each gas
E- Equal volume of each gas
Ans: A

365- What is the recommended percentage range of fat intake in a balanced diet?
A- 10-15%
B- 25-30%
C- 40-55%
D- 60-75%
Ans: B

366- Which structure is located below the temporal fossa?
A- Nasolcavity
B- Infratemporal fossa
C- Maxillary sinus
D- Pterygopalatine fossa
Ans: B

367- In a patient with Alkaptonuria, which substance is expected to be elevated in the urine?
A- Homogentisic acid
B- Phenylalanine
C- Tyrosine
D- Homocysteine
Ans: A

368- A patient presented with megaloblastic anemia.on investigation there is orotic acid in urineleads to an increase in the synthesis of which of the following?
A- Purine
B- Pyrimidine
C- Sphingomyelin
D- Cholesterol
E- Glycogen
Ans: B

369- A 7-year-old child is apathic & Lathargic. On examination, having coarse hairs, Hepatosplenomegaly & edema. Investigations show low albumin and low ca and vit D levels) What is the diagnosis?
A- Kwashiorkor
B- CeliacDisease
C- Marasmus
D- Rickets
E) Scurvy
Ans: A

CamScanner

370- Percentage of Fat needed in diet:
A- 25% to 30%
B- 30%to40%
C- 10to 15%
D- 50-60%
Ans: A

Explanation:
- Carbs/Proteins GivE- 4kcal
- Fats GivE- 9kcal
- Alcohol GivE- 7kcal
- Carbs Required – 50 - 60%
- Fats Required – 25 - 35%
- Protiens Required – 10 - 20%

371- A patient presented with Cardiac, Facial & Corneal defects along with hypotonia & failure to thrive diagnosed as Zellweger syndrome in which there is accumulation of long- chain fatty acids caused by?
A- Peroxisomes
B- Mitochondria
C- Lysosomes
D- Golgi body
Ans: A(Chatterjee biochemistry)

Explanation:
Zellweger syndrome
- Autosomal recessive disorder of peroxisome biogenesis due to mutated PEX genes (accumulation of pipecolic acid in peroxisomes) Hypotonia, seizures, jaundice, craniofacial dysmorphia, hepatomegaly, early death
- High levels of very long chain polyenoic acids have been found in the brains of patients with Zellweger's syndrome. There is inherited absence of peroxisomes in all tissues and peroxisomal oxidation of unsaturated FA does not take place.

372- Cereal give how many calories per 100g?
A- 400–450 mg
B- 450–500 mg
C- 350–370 mg
D- 350–490 mg
E- 250-290mg
Ans: C(Chatterjea biochemistry)

Explanation:
Rice and wheat are the commonly consumed cereals in our country. Cereals consitute the major bulk of the diet, satisfy hunger, and are the main suppliers of calories (350 Cal/100 gm). In a good balanced diet, cereals contribute about 50 percent

372 A patient presents with flexible joints and velvety skin. Which protein abnormality is most likely associated with this condition?
A- Fibrillin
B- Collagen
C- Fibronectin
D- Elastin
Ans: B

373- A 12 Years Old Child presents in OPD with complain of Photosensitivity on Exposure to Sunlight. Upon investigation, Increased Uroporphyrin in Urine, Feces & RBCs.
A- Congenital Erythropoeitc porphyria
B- Acute Intermittent Porphyria
C- Alkaptonuria
D- Protoporphyria
Ans: A

374- A patient presented to OPD with primary complain of Night blindness. On examination, No other sign is present. No Bitot spot, keratomalacia or corneal opacity seen. Which vitamin is deficient in this patient?
A- Vitamin A
B- Vitamin K
C- Vitamin C
D- Vitamin D
Ans: A

375- Type I hyperlipidemia with increased VLDL & TG is due to:
A- Deficiency of Lipoprotein lipase
B- Apo C1 mutation
C- Apo E deficiency
D- LDL receptor deficiency
E- Deficiency of Apo B
Ans: A

376- 10 years old child with lipid accumulation in skin. There is also family history. Mutation in gene of protein which causes cholesterol transport and metabolism
A- LDL receptor
B- Chylomicron
C- Cholesterol
D- VLDL receptor
E- HDL receptor
Ans: A

377- Most common form of lipoprotein used by cells as source of cholesterol is
A- VLDL
B- LDL
C- IIDL
D- Chylomicron
E- IDL
Ans: B

378- A young child presents with skin desquamation, depigmentation, eczema, abdominal distension, and weight loss. What is the most likely cause?
A- Niacin deficiency
B- Marasmus
C- Kwashiorkor
D- Scurvy
Ans: C

379- Macrophages resembling crumpled tissue paper are found in deficiency of which enzyme?
A- Glucocerebrocidase
B- Hexosaminadase
C- Fructokinase
D- Hexokinase
E- Glucokinase
Ans: A(Gaucher Disease)

Explanation:
Gaucher disease results from lack of the lysosomal enzyme glucocerebrosidase and accumulation of glucocerebroside in mononuclear phagocytic cells. In the most common type I variant, affected phagocytes become enlarged (Gaucher cells) and accumulate in liver, spleen, and bone marrow, causing hepatosplenomegaly and bone erosion. These phagocytes—the Gaucher cells—become enlarged acquire a pathognomonic cytoplasmic appearance characterized as "wrinkled tissue paper"

380- A patient presented with complains of Abdominal Pain & Xanthomas. Patient will have increased:
A- VLDL, Cholesterol & Triglycerides
B- Cholesterol & Triglycerides
C- Chylomicrons & TAGS
D- Chylomicrons & VLDL
E- Triglycerides & VLDL
Ans: A

381- Patient having cough and basal crackles on examination doctor finds Enlarged shadow on X- Ray. Echo shows Ejection fraction to be 40%. Which one of them is responsible for his enlarged heart?
A- Vitamin A
B- Vitamin B1
C- Vitamin B3
D- Vitamin B4
E- Vitamin B12
Ans: B

382- A Premature Infant born at 33 weeks he is exclusively on formula milk. He is not thriving and looks weak. His labs show an HB of 6mg/dl and his RBCs are micocytic, haematocrit is 25% diagnose as a case of iron deficiency anemia What should be the treatment
A- 2% Iron Containing Formula milk
B- High caloric formula milk
C- B12 containnig formula milk
D- Increase fruits and vegetable diet
E- Repeat same formula milk
Ans: A

383- A Female has problem seeing at night. She also complains of gastric problems. Most likely cause?
A- Vitamin D Deficiency
B- Vitamin A Deficiency
C- Vitamin K Deficiency
D- Vitamin C Deficiency
Ans: B

384- Bone regeneration is a function of?
A- Vitamin C
B- VitaminE
C- VitaminD
D- Vitamin A
Ans: A

385- Man with recurrent bleeding gums. Overall malnourished and underweight, cause is?
A- Vitamin C deficiency
B- Vitamin D deficiency
C- Vitamin B6 deficiency
D- Vitamin B12 deficiency
Ans: A

386- Most likely Complication of SCURVY? (Medicine & Surgery Feb 2025)
A- Chylopericardium
B- Hemopericardium
C- Fibrinous Pericardial Effusion
D- Exudative Pericardial Effusion
Ans: B

Explanation:
Hemoparicardium
Traumatic Rupture
Rupture aortic aneurysm(Type A)
Scurvy
Neoplasm and Leukemia
Chyloperieardium
Obstruction of thoracic duct
Obstruction of SVC
Pericardial effusion
Heart failure
Viral Myopericarditis
Metastatic malignancy
Renal failure

387- A child presents with hepatosplenomegaly and pancytopenia. Histopathology reveals "crumbled tissue paper appearance". It is due to accumulation of: (Medicine & Gynae Feb 2025)
A- Glucocerebroside
B- Sphingomyelinase
C- Ganglioside
D- Galactocerebroside
E- Alpha 1_4 amylase
Ans: A

388- A patient's urine has a musty odor. Which condition is most likely? (Medicine Feb 2025)
A- Phenylketonuria
B- Alkaptonuria
C- Maple syrup urine disease
D- Tyrosinemia
Ans: A

389- Glucose phosphorylase deficiency primarily affects which tissue? (Medicine Feb 2025)
A- Skeletal muscle
B- Liver
C- Brain
D- Adipose tissue
Ans: A

390- A woman presents with proximal muscle weakness, vacuoles on muscle biopsy, and borderline glucose levels. What is the most likely diagnosis? (Medicine Feb 2025)
A- Carnitine deficiency
B- Tay Sachs disease
C- Pompe disease
D- McArdle disease
Ans: A

391- A child presented with abdominal pain, Joint pains & Hepatosplenomegaly .Cherry red spot seen on macula. Most likely cause? (Medicine Feb 2025)
A- Hereditary Spherocytosis
B- Niemann Pick
C- HbS
D- Hemolytic Anemia
E- Tay Sach's disease
Ans: B(FA)

Explanation:
Niemann Pick Disease
- Progressive neurodegeneration,
- hepatosplenomegaly,
- foam cells
- Sphingomyelinase, Sphingomyelin.
- (lipid-laden macrophages),
- "cherry-red" spot on macula

392- Glucose is transported in cells of muscles & adipose tissue by which of the following? (Surgery Feb 2025)
A- GLUT 1
B- GLUT2
C- GLUT 4
D- Facilitated Diffusion
F- Active transport
Ans: C

393- Lactate dehydrogenase (LDH) is an enzyme responsible for catalyzing which biochemical conversion? (Surgery Feb 2025)
A) Glucose to glycogen
B) Glycogen to glucose
C) Lactate to pyruvate
D) Pyruvate to lactate
Ans: D

394- What is the primary role of carnitine in cellular metabolism? (Surgery Feb 2025)
A) Transport of fatty acids into mitochondria for beta-oxidation
B) Transport of amino acids into mitochondria for protein synthesis
C) Transport of glucose into mitochondria for glycolysis
D) Transport of cholesterol into mitochondria for steroid synthesis
Ans: A

395- What is the mechanism of action of Antimycin A? (Surgery Feb2025)
A) Inhibits ATP synthase
B) Inhibits cytochrome c oxidase
C) Inhibits electron transport chain complex III
D) Inhibits electron transport chain complex I
Ans: C

396- A patient is diagnosed with Type I hyperlipidemia. Which of the following dietary restrictions is most appropriate for managing this condition? (Surgery Feb 2025)
A) Low-carbohydrate diet
B) Restriction of dietary fat, particularly long-chain triglycerides
C) Low-cholesterol diet
D) Low-fat diet
Ans: B

397- A chronic alcoholic presents with severe memory loss and marked confabulation. Deficiency of which vitamin is most likely responsible? (Surgery Feb 2025)
A- Folic acid
B- Niacin
C- Riboflavin
D- Thiamine
E- Vitamin B12
Ans: D

398- In ETC (electron transport chain) Antimycin A inhibits which enzyme: (Gynae & Obs Feb 2025)
A- Coenzyme q
B- Cytochrome C Oxidase
C- Cytochrome bc1 complex
D- NADH Dehydrogenase
Ans: C

400- Which amino acid contains a urea group? (Gynae & Obs Feb 2025)
A- Lysine
B- Tryptophan
C- Proline
D- Arginine
Ans: D

401- When phenylalanine enzyme is deficient then what will accumulate in body (Gynae & Obs Feb 2025)
A- Serotonin
B- Melanin
C- Tryptophan
D- Tyrosine
E- Melatonin
Ans: D

402- Garlic consumption is known to cause phosphorylation of HMG-CoA reductase, an enzyme involved in cholesterol synthesis. Excessive intake of garlic is most likely to result in inhibition of: (Radiology Feb 2025)
A) Acetyl-CoA carboxylase
B) HMG-CoA reductase
C) Lipoprotein lipase
D) HMG-CoA synthase
Ans: B

403- After starting a statin, which parameter should be measured within a few days to assess the initial response for the health promotion in this patient ? (Radiology Feb 2025)
A- Raised LDL cholesterol
B- Raised Chylomicrons
C- Raised HDL cholesterol
D- Decreased HDL cholesterol
Ans: C

404- 6 year old boy presented with self mutilation, involuntary movements, speech problems and painful joints and urine shows excess uric acid what is the deficient enzyme? (Anesthesia Feb 2025)
A- xanthine oxidase
B- HGPRT
C- Urate Oxidase
D- Adenine Phosphoribosyl transferase
Ans: B

405- A 6 years old boy presented with self mutilation, involuntary movements, speech problems and painful joints and urine shows excess uric acid what is the disease? (Anesthesia Feb 2025)
A- Chronic Lead Toxicity
B- Fragile-X syndrome
C- Gout
D- Huntington disease
E- Lesch-Nyhan syndrome
Ans: E

406- A patient visits the clinic and is otherwise healthy. His father died at 60 and his uncle at 49 from cardiovascular disease (CVD). Lab values show: LDL = 148/185, HDL = 35. Along with lifestyle modifications and statin therapy, what else should be assessed for health promotion? (Anesthesia Feb 2025)
A) HDL
B) LDL
C) Chylomicrons
D) VLDL
Ans: D

407- 113. Amino acids that are strictly ketogenic: (Anesthesia Feb 2025)
A. Leucine and lysine
B. Leucine and isoleucine
C. Lysine and valine
D) Phenylalanine and tyrosine
E) Isoleucine and tryptophan
Ans: A

CamScanner

EMBRYOLOGY QUICK HINTS

Ectodermal Derivative's Mnemonic: 7 E

- Epidermis
- Epithelial linings of external orifices
- Ear, eye, and nose – sensory part like olfactory epithelium, retina, etc.
- Enamel of teeth
- Exocrine glands
- Encephalon (CNS)
- Eye lens

Endoderm derivatives

- Lining of tube from nose, mouth and ear to anus and urethra and vagina except those that can be touched with your fingers. (internal organs) E.g. gut tube , lung, liver ,spleen, pancreas, thyroid, bladder epithelium

Mesoderm derivatives Mnemonic: GONADS

- Genitourinary and Renal
- Others – Muscle, bone, connective tissue, serous lining of body cavities, cardiovascular system, parenchyma
- Notochord – Nucleus pulposus
- Adrenal cortex
- Duramater
- Spleen

Pharyngeal cleft derivatives

Pharyngeal cleft 1

- develops into the external auditory meatus (the corresponding 1st pharyngeal pouch develops into the auditory (or Eustachian) tube, and the intervening membrane develops into the tympanic membrane)

Pharyngeal clefts 2, 3, and 4

- overgrown by expansion of the 2nd pharyngeal arch and usually obliterated
- Remnants of pharyngeal clefts 2-4 can appear in the form of cervical cysts or fistulas found along the anterior border of the sternocleidomastoid muscle.

Pharyngeal pouches derivative

1st pouch derivative:

- Middle Ear cavity
- Mastoid air cell
- Eustachian tube

2nd pouch derivative:

- Palatine tonsile epithelial lining

3rd Pouch derivate:

- Ventral Wing – Thymus
- Dorsal Wing – Inferior Parathyroid

4th pouch derivative:

- Ventral Wing – Ultimopharyngeal body, Parafollicular C cells of thyroid
- Dorsal Wing – Superior Parathyroid

Tongue development

- 1st pharyngeal arch forms anterior 2/3 of tongue (sensation via CN V3 , taste via CN VII).
- 3rd and 4th pharyngeal arches form posterior 1/3 of tongue (sensation and taste mainly via CN IX, extreme posterior via CN X).
- Motor innervation is via CN XII to hyoglossus (retracts and depresses tongue), genioglossus (protrudes tongue), and styloglossus (draws sides of tongue upward to create a trough for swallowing).

- Motor innervation is via CN X to palatoglossus (elevates posterior tongue during swallowing)
- Muscles of tongue from Occipital myotome
- Safety muscle of tongue - Genioglossus
- Anterior 2/3rd Tongue drains to – Submandibular
- posterior 1/3rd Tongue drains to – Juguloomohyoid.
- Tip of Tongue drains to – Submental
- Pain of cancer of tongue referred to ear through – Glossopharyngeal nerve

Pharyngeal arches derivatives

Nerve derivatives

- 1st arch – V3
- 2nd arch – VII
- 3rd arch – IX
- 4th arch – X (superior laryngeal nerve)
- 6th arch – X (Recurrent laryngeal nerve)

Arterial derivatives

- 1st arch - Part of maxillary artery (branch of external carotid).
- 2nd arch - Stapedial artery and hyoid artery. Second= stapedial
- 3rd arch - Common carotid artery and proximal part of internal carotid artery
- 4th arch - On left, aortic arch, on right, proximal part of right subclavian artery.
- 6th arch – Right and left pulmonary artery , ductus arteriosus

Muscles derivatives

- 1st arch - Muscles of mastication (temporalis, masseter, lateral and medial pterygoids), mylohyoid, anterior belly of digastric, tensor tympani, anterior 2/3 of tongue, tensor velipalatini
- 2nd arch - Muscles of facial expression, stapedius, stylohyoid, platysma, posterior belly of digastric
- 3rd arch - Stylopharyngeus
- 4th arch - most pharyngeal constrictors; cricothyroid, levatorvelipalatini
- 6th arch – all intrinsic muscles of larynx except cricothyroid

Neural crest derivatives

- 1st arch -Maxillary process (maxilla, zygomatic bone) Mandibular process (Meckel cartilage mandible, malleus and incus) , sphenomandibular ligament
- 2nd arch -Reichert cartilage: stapes, styloid process, lesser horn of hyoid, stylohyoid ligament Muscles of facial expression, stapedius, stylohyoid, platysma, posterior belly of digastric
- 3rd arch - Greater horn of hyoid
- 4th arch - Thyroid cartilage
- 6th arch - All other laryngeal cartilage

Ear Development

- External auditory meatus develops from - 1st brachial cleft
- Auditory tube and tympanic cavity develops from - 1st pouch
- Pinna and auricle develops from - **1st and 2nd brachial arch**
- Air ossicles develops from- 1st and 2nd brachial arch
- Tragus of external ear derived from- 1st arch
- External and internal ear develops from ectoderm
- 1st part of human ear to reach adult size – inner ear

Genitals Embryology

Wolffian or mesonephric duct

- Male – Ductus deferens , epididymis , seminal vesicle
- Female – epophoron , Gartner's duct

CamScanner

Mesonephric tubules
- Male – paradidymis
- Female- epophoron , paroophoron

Mullerian or paramesonephric duct
- Male – Appendix of testis
- Females – uterus , cervix , tubes , upper vagina

Mullerian tubercle
- Males – Appendix of testis
- Females – Clitoris

Urogenital sinus
- Males – urinary bladder,urethra, prostate , prostatic utricle , bulbourethral glands
- Females-urinary bladder, urethra, paraurethral glands , Bartholin's glands , lower vagina

Urogenital folds
- Male – penis, urethra
- Females – labiaminora

Genital swelling
- Male – Scrotum
- Females – Labia majora

FETAL LANDMARKS
- 1st week- implantation of blastocyst
- 2nd week - (2 layers) bilaminar disc (hypoblast,epiblast)
- 3rd week - (3layers) epiblast invaginate forms primitive streak andectoderm,mesoderm, endoderm forms
- 4th week - 4 limbs
- 5th week - gut rotation start
- End of 5th week - definitive heart formed
- 6th week - fetal cardiac activity visible by Transvaginal ultrasound
- 7th week - fetal cardiac activity by transabdominal ultrasound
- 10th week - genitals confirmed

Cardiovascular postnatal derivatives

- Ductus arteriosus – Ligamentum arteriosum
- Ductus venosus – Ligamentum Arteriosum
- Left horn of Sinus venosus – Coronary sinus
- Foramen ovale- Fossa ovalis
- Allantois – Median umbilical ligament
- Umbilical arteries – Medial umbilical ligaments
- Umbilical vein – Ligamentum teres
- Notochord – Nucleus pulposus

Brain Development

Primary vesicle	Primary division	Subdivision	Adult structures
Forebrain Vesicle	Prosencephalon	Telencephalon	Cerebral hemispheres, basal ganglia
		Diencephalon	Thalamus, Hypothalamus, Retina
Midbrain vesicle	Mesencephalon	Mesencephalon	Midbrain
Hindbrain Vesicle	Rhombencephalon	Metencephalon	Pons, Cerebellum
		Myelencephalon	Medulla

Important events during Erythropoiesis

- Procrythroblast – synthesis of hemoglobin starts , nucleus and neucleoli present
- Early Normoblast – Nucleoli disappears
- Intermediate normoblast – Hemoglobin statts to appear
- Late normoblast- Nucleus disappear , Max Hb production
- Reticulocyte – Reticulum is formed , Max Hb concenteration
- Erythrocyte – Reticulumn disappears , Cells attains Biocoocavity

Random

- Placenta inner layer – Cytotrophoblast makes cells
- Placenta Chronic outer layer – Syncito – trophoblast secretes HCG
- Ureteric bud derived from caudal end of mesonephric duct
- Infant with absence of limbs – cause Amniotic bands
- In late pregnancy consists of -Syncitotrophoblast , Fetal endothelium
- Amniocentesis done after 14 weeks
- Chronic villus sampling done between 10 and 12 weeks
- AFP is increased in Neural tube defects and decreased in Down syndrome
- Embryonic period – 3-8 weeks
- Fetal period – 8 weeks onward
- CRL at 17 to 20 weeks – 13-17cm
- Age estimation at 5th and 12th weeks is done by - CRL
- Spermatogenesis controlled by – FSH + testosterone
- Ciliary epithelium , iris epithelium , optic vesicle and cup, retinal epithelium , optic nerve derived from – Neural ectoderm
- Conjunctival epithelium, corneal epithelium , lacrimal glands , tarsal glands and lens derived from – surface ectoderm
- In hypospadias defective urogenital folds associated with inguinal hernia and cryptorchidism
- In epispadias defective genital tubercle associated with exstrophy of bladder
- Mesoderm defect Cranially – Ectopic anal opening.
- Mesoderm defect caudual – Exstrophy of bladder.
- Right horn of Sinus venosus forms – Right atrium
- Left horn of sinus venosus forms – Coronary sinus
- Ductus venosus – Ligamentum venosum.
- Ductus arteriosus – Ligamentum arteriosum.
- Left umbilical vein – Ligamentum teres
- Right umbilical vein obliterates before so having no derivative.
- Umbilical arteries – Medial umbilical ligament.
- Urachus (Allontois) – Median umbilical ligament
- Most common remnant of allantois - **urachal cyst**
- Patent lumen of allontois - **urachal fistula**
- Patent local area of allontois - **urachal cyst**
- Patent lumen of allantois in inferior or superior part - **urachal sinus**
- **Mid line cleft lip** is failure of fusion of two medial nasal processes.
- **Unilateral cleft lip** failure of fusion of median nasal process with maxillary process.
- **Cleft palate** failure of fusion of lateral palatine process nasal septum and median palatine process
- **Cleft palate** is malformation of Palatine Shelves
- Extraembryonic mesoderm derived from - Epiblast
- Extraembryonic coelom derived from - **Hypoblast**
- Intraembryonic coelom derived from -Lateral plate mesoderm

CamScanner

- Adrenal cortex derived from - Mesoderm
- Adrenal medulla derived from - Neural crest cell
- Dura matter derived from - Mesoderm
- Pia and arachnoid matter derived from -Neural crest cell
- Schwan cell Derived from - Neural crest cell
- Oligodendrocytes derived from - Neural Tube
- Renal agenesis result from -Failure of ureteric bud to reach metanephric mesoderm (Langman)
- Two kideny with two ureter and pelvis Result from - Early division of ureteric bud (Langman)
- Hepatocyte Derived from – Endoderm
- Kuffer Cell Derived from – Mesoderm
- Transitional epithelium bladder derived from – Endoderm
- Adrenal Medulla Detived from – Neural crest cell
- Adrenal Cortex Derived from – Mesoderm
- Cells having telomerase acvtivity are germ cells
- Primodial germ cells derived from Epiblast > Ectoderm > Yolk sac endoderm
- Gamets are descendants of Primodial germ cells
- Primodial germ cells are derived from wall of yolk sac
- In embryo, primodial germ cells formed at 3rd week of development
- Primodial germ cells migrate to gonadal ridges in 6th week
- Oocyte wih flat epithileum is Primodial follicle
- Primary Oocyte Mature – at ovulation.
- At the time of ovulation ovum is Secondary oocyte.
- Secondary oocyte completes its secondary meiotic division nt time of fertilization after ovulation
- First meiotic division is completed before ovulation
- Secondary Oocyte formed under the influence of FSH
- After ovulation, the oocyte is in Prophase of 2nd meiotic division
- Haploid no. of chromosomes with haploid DNA are seen in Spermatids
- Primary oocyte after 1st maturation produes – One secondary oocyte and one polar body.
- Absense of limb is due to mal development of Lateral plate mesoderm

Newborn

- C – shaped Vertebral column
- Has Circular thoracic cavity(Oval shape in adult)
- Liver has 5% of body weight (largest organ)
- Sample taken from Radial Artery > posterior tibial artery > Dorsalis
- Blood volume is 85ml/kg
- Upper limb well developed than Lower limb
- Inner ear is of same size as in adult

EMBRYOLOGY

1- Which structure is derived from neuroectoderm?

A- Ciliary epithelium
B- Corneal epithelium
C- Trabecular meshwork
D- Iris
E- Superior Rectus

Ans: A

Explanation:

Neuroectoderm derivative

Optic Cup:

- Retina
- Dilator papillae
- Sphinter papillae
- Epithelium of iris and Cilliary body

Optic Stalk:

- Optic nerve

2- Molecule which is in involved in cell to cell adhesion, especially in logical cell adhesion molecule?

A- Selectin
B- Cadherin
C- Intergrin
D- Icam
E- Vcam

Ans: B

3- Umbilical artery carries:

A Deoxygenated blood to the placenta,
B Deoxygenated blood from the placenta
C Oxygenated blood to placenta.
D DeOxygenated blood to fetus.

Ans: A

Explanation:

- Umbilical artery carries deoxygenated blood from fetus towards placenta for nourishment
  Umbilical Vein carry oxygenated and nutrient rich blood back to fetus

4- A newborn is brought with lumbosacral swelling containing meninges without neural tissue. What is most likely diagnosis of this swelling?

A Spina bifida with Meningocele
B Meningomyelocele
C. Encephatocele
D. Meningomyeloencephatocele
E. Anencephaly

Ans: A

5- A Young man had a road side accident in which he suffered from Spinal cord injury. Some soft filling located in the center of the disc of spinal cord known as nucleus pulposus. It is derived from which structure?

A- Mesonephric Duct
B- Neural Tube
C- Notochord
D- MullerianDuct
E- Neural Crest

Ans: C

6- Derivatives of 1st pharyngeal arch:

A- Muscle of Face
B- Hyoid
C- Muscle of masticatioo
D- Thyroid
E- RLN

Ans: C

7- Primordial germ cells are formed at

A- The beginning of 5th Week
B- The end of 3rd Week
C- The end of 4th Week
D- Start of 4th Week
E- End of 6th Week

Ans: B

8- The epiblast and hypoblast meet at caudal ends at:

A- Cloacal membrane
B- Vitelline duct
C- Yolk sac
D- Extraepiploic membrane

Ans: A

9- During 3rd month of embryological period the cell which invade the epidermis originating from the neural crestare?

A- Melanin
B- Melatonin
C- Melanocyte
D- Opticdisc
E- Hemosiderin

Ans: C

Explanation:

- Melanocyte derived from neural crest cell which are distributed in epidermis and then secrete melanin.

10- Intraembryonic coelom is derived from which layer?

A- Lateral plate mesoderm
B- Paraxial meso.
C- Intermediate meso
D- Notochord
E- Neural crest cell

Ans: A

CamScanner

Explanation:
- Extraembryonic mesoderm derived from - Epiblast
- Extraembryonic coelom derived from – Hypoblast
- Intraembryonic coelom derived from - Lateral plate mesoderm

11- In newborn what is true?
A- C shaped vertebral column with inward chest
B- Oval thorax on cross section
C- Round thorax
D- Curved vertebrae
E- Curved Thorax
Ans: A

Explanation:
- C – shaped Vertebral column
- Has Circular thoracic cavity
- Liver has 5% of body weight (largest organ)
- Sample taken from Radial Artery > posterior tibial artery > Dorsalis
- Blood volume is 85ml/kg

12- Primary oocyte completes their first meiotic division:
A- Before ovulation
B- 3rd month of intra uterine life
C- 6th month of intra uterine life
D- Before fertilization
E- AtFertilization
Ans: A

Explanation:
- Primary Oocyte Mature – at ovulation.
- At the time of ovulation ovum is – Secondary oocyte.
- Secondary oocyte completes its secondary meiotic division at time of fertilization after ovulation.
- First meiotic division is completed before ovulation

13- The haploid no of chromosomes with haploid DNA is related to which of following?
A- Primary oocyte
B- Secondary oocyte
C- Primary spermatocytes
D- Spermatids
Ans: D

14- Neural crest cells are separated from which of the following?
A- Mesoderm
B- Neural Palate
C- NeuralTube
D- Neural Groove
E- Yolk Sac
Ans: C

15- Endocrine system develops from which of following?
A- 1st Arch
B- 2nd and 3rd Arch
C- 1st and 2nd Pouch
D- 2nd Pouch
E- 3rd and 4th Pouch
Ans: E(EA)

Explanation:
1st pouch derivative:
- Middle Ear cavity
- Mastoid air cell
- Eustachian tube

2nd pouch derivative:
- Palatine tonsile epithelial lining

3rd Pouch derivate:
- Ventral Wing – Thymus
- Dorsal Wing – Inferior Parathyroid

4th pouch derivative:
- Ventral Wing – Ultimopharyngeal body, Parafollicular C cells of thyroid
- Dorsal Wing – Superior Parathyroid

16- External ear derived from which of the following?
A- 1st arch
B- 2nd arch
C- 1st and 2nd arch
D- 3rd and 4th arch
E- 4th arch
Ans: C

17- Adrenal medulla is derived from:
A- Endoderm
B- Mesoderm
C- Ectoderm
D- Lateral plate mesoderm
E- Neural Crest Cell
Ans: E

Explanation:
- Adrenal cortex – Mesoderm
- Adrenal medulla – Neural crest cell

18- Derivative of 3rd pharyngeal pouch is:
A- Superior parathyroid
B- Thymus
C- Mastoid antrum
D- Thyroid gland
E- Adrenal gland
Ans: B

19- In fetal circulation, highest oxygen saturation in:
A- Umbilical artery
B- SVC
C- IVC
D- Umbilical vein
E- Aorta
Ans: D

Explanation:
- Max O2 – Pulmonary Capillaries
- Low O2 – SVC > Pulmonary Artery
- >Umbilical artery
- Highest O2 Saturation – Umbilical Vein

20- Metopic suture remnant in adult life is:
A- Nasion
B- Glabella
C- Supraciliary arches
D- Pterion
E- Bastion
Ans: B

21- Alcoholic mother with a baby with facial hypoplasia where does the defect lie:
A- First arch
B- Second arch
C- Third arch
D- Fourth arch
Ans: A

22- Which of the following is considered as embryonic connective tissue?
A- Bone
B- B Cartilage
C- Blood
D- Mesoderm and mesenchyme
Ans: D

23- Primary oocyte surrounded by which non cellular layer?
A- Theca interna
B- Theca externa
C- Corona radiata
D- Zona pellucida
Ans: D

Explanation:
- Non cellular layer – Zona pellucida
- Cellular layer – Corona radiata (Cumulus oophoros)

24- Remnant of gubernaculum in female includes:
A- Tunica vaginalis
B- Process vaginalis
C- Scrotal ligament
D- Ovarian ligament
E- Peritoneum
Ans: D (No Round ligament option)

Explanation:
Remnant of Gubernaculum in female
- Upper Part – Round ligament of ovary
- Lower Part – Round ligament of Uterus

Remnant of Gubernaculum in male
- Upper Part – Degenerate
- Lower Part (Gubernaculum Testis) – Scrotal ligament

25- External auditory meatus and lobules of ear develop from:
A- 1st and 2nd branchial arch
B- 2nd and 3rd branchial arch
C- 1st branchial cleft
D- 2nd branchial cleft
E- 4th branchial arch
Ans: C

Explanation:
- External auditory meatus – 1st cleft
- Pina or auricle – 1st and 2nd branchial arch
- Auditory canal or eustachian tube and tympanic cavity and mastoid air cells – 1st Pouch

26- Adrenal cortex is embryologically derived from:
A- Surface ectoderm
B- Endoderm
C- Mesoderm
D- Neural crest cells
E- Endoderm and mesoderm
Ans: C

27- Tympanic membrane derived from:
A- Ectoderm +Mesoderm
B- Endoderm +Mesoderm
C- Ectoderm +Endoderm
D- Mesoderm
E- Endoderm
Ans: C

28- Which of following is Foramen cecum derivative?
A- Thyroid
B- Thymus
C- Anterior pituitary
D- Posterior pituitary
E- Hypothalamus
Ans: A

29- Regarding parathyroid gland which statement is true?
A- Superior develop from 3rd and inferior from 4th arch
B- Basophilic staining of chief cells at 14 years
C- Lies between thyroid gland trachea
D- Supplied by Superior and inferior thyroid arteries
Ans: D

30- Ovum at the time of ovulation is:
A- Primary oocyte
B- Secondary oocyte
C- Tertiary oocyte
D- Graafian follicle
Ans: B

31- Cerebral aqueduct arises from:
A- Telencephalon
B- Diencephalon
C- Mesencephalon
D- Metencephlon
Ans: C

32- Bicornuate uterus is due to:
A- Defect of mesonephric duct
B- Failure of fusion of paramesonephric ducts
C- Abnormal division of mesonephric duct
D- Defect of tubule
E- Defect of wolfian duct
Ans: B

CamScanner

33- **Retina development in fetus**
A- Rods & Cones develop at 5 month
B- Ganglia present in fovea at birth
C- Rods develop at birth
D- Photoreceptor develop at 3, 4 month
Ans: B

34- **In fetus blood in carotid artery enters from:**
A- Pulmonary vein
B- Pulmonary artery
C- Ductus arteriosus
D- Aorta
Ans: D

35- **Which of the following will the best parameter to have estimation of fetal assessment?**
A- CRL at 8 weeks
B- Femur length at 28 weeks
C- Abdominal circumference at 18 weeks
D- Head circumference at 32 week
E- Biparietal diameter at 16 week
Ans: A

36- **What would be best accurate investigation for the antepartum fetal well being with lowest rate of false positive?**
A- Biophysical profile
B- Cardio Togo graph
C- Non stress test
D- Fetal kick count
E- Contraction stress test
Ans: A

37- **Epithelium of uterus and vagina derived from**
A- Endoderm+mesoderm
B- Endoderm
C- Ectoderm
D- Neural crest cell
Ans: A

Explanation:
- Upper part of vagina and uterus epithelium from mesoderm
- Lower part of vagina from endoderm

38- **Medial and median umbilical ligament logically arise from:**
A- Umbilical vein
B- Umbilical artery and urachus
C- Ductus venosus
D- Ductus arterosus
E- Umblical vein and urachus
Ans: B

Explanation:
- Ductus venosus – Ligamentum venosum
- Ductus arteriosus – Ligamentum arteriosum.
- Left umbilical vein – Ligamentum teres
- Right umbilical vein obliterates before birth having no derivative.
- Umbilical arteries – Medial umbilical ligament.
- Urachus (Allantois) – Median umbilical ligament.

39- **Which of following Ligament forms from Ventral mesogastrium?**
A- Hepatoduodenal
B- Spleno renal
C- Cardinal
D- Falciform ligament
E- Gastrodudenal
Ans: D

Explanation:
Ventral mesogastrium
- Falciform ligament

Dorsal mesogastrium
- Gastrosplenic ligament
- Splenorenal ligament

40- **Annular pancreas represents:**
A- Pancreatic head regression
B- Pancreatic neck suppression
C- Ventral bud fails to rotate
D- Beta cells of pancreas
Ans: C

41- **Rathkes' pouch develop from**
A- 1st phyrengeal arch
B- Stomodeum of fore gut
C- Neural crest cell
D- 6th phyrengeal pouch
Ans: B

42- **After ovulation, the oocyte is in which phase of cell cycle?**
A- Metaphase of Meiosis II
B- Prophase of first meiotic divisoon
C- Prophase of 2nd meiotic division
D- Metaphase of first meiotic division
E- Anaphase
Ans: C

43- **Which one carries Deoxygenated blood to placenta?**
A- Umblica vein
B- Umblical arteries
C- SVC
D- IVC
Ans: B

44- **Secondary ovum completes its second meiosis:**
A- At ovulation
B- At fertilization
C- Before ovulation
D- Before fertilization
Ans: B

Explanation:
- Primary Oocyte Mature – at ovulation.
- At the time of ovulation ovum is – Secondary oocyte.
- Secondary oocyte completes its secondary meiotic division at time of fertilization after ovulation.
- First meiotic division is completed before ovulation.

45- **Granulosn cells give rise to:**
A- 2nd Pollar body
B- Corona radiato
C- First polor body
D- 3rd polar body
Ans: B

46- **For the diagnosis of spina bifida in a fetus, amniotic fluid analysis will show increased levels of:**
A- BHCG
B- AFP
C- Estriol
D- Inhibin
Ans: B

47- **The pinna of ear is derived from:**
A- Neural crest cell
B- Endoderm
C- Mesoderm
D- Neuroectoderm
Ans: C

Explanation:
- Cartilage-Mesoderm
- Skin – Ectoderm

48- **A newborn born having some congenital anomaly, presented with tuft of hairs and dimple in sacral segment diagnosis:**
A- Spina bifida occulta
B- Hydrocephalous
C- Meningomyelocele
D- Myringimyelocele
Ans: A

49- **Ova enter which state instead of entering second meiosis?**
A- Diplotene
B- Zygotene
C- Pachytene
D- Anaphase
Ans: A

50- **Ligament formed from dorsal mesogastrium:**
A- Hepatoduodenal
B- Spleno renal
C- Cardinal
D- Appendix mesentary
E- Gastrodudenal
Ans: B

51- **Ductus arteriosus becomes:**
A- Foramen ovale
B- Ligamentum arteriosum
C- Hepatoduodenal ligament
D- Ligamentem teres
Ans: B

52- **Pulmonary vascular resistance of infant is similar to adult at which age?**
A- 1 week
B- 1 month
C- 1 year
D- 3 years
E- 5 years
Ans: A

53- **Tertiary villus contains:**
A- Yolk sac
B- Testicular vein
C- Maternal vein
D- Fetal vessels
Ans: D

54- **2 Years old girl presented with history of chronic constipation since birth is brought to the emergency department because of nausea and vomiting. Physical examination shows marked abdominal distention. Abdominal radiography reveals distended bowel loops with paucity of air in rectum. Rectal biopsy shows absence of ganglion cells. Which of the following is supplying theganglion?**
A- S1–S2
B- S2–S4
C- S3–S4
D- S4
Ans

55- **Villous surrounded by cytotrophoblast and syncytiotrophoblast is:**
A- Primary villous
B- 2ndary villous
C- Tertiary villous
D- None
Ans: A

56- **Urorectum septum seprates:**
A- Rectum and cocyx
B- Rectum and Urogenital sinus
C- Rectal sinus and Cocyx
D- Rectum and Anus
Ans: B

CamScanner

57- Structure from outer to inner villous core formed by:
A- Syncitio, Cyto, Connective tissue & Endothelium
B- Endothelium, Syncitio, Cyto
C- Cyto, Syncitio, Endothelium
D- Connective Tissue, Cyto, Syncitio
Ans: A

58- Patient presented with opening in anterior wall of SCM with pus like discharge coming out of it this problem occurred due to abnormality in
A- 1st pharangeal cleft
B- 2nd pharangeal cleft
C- 3rd pharangeal cleft
D- 4th pharangeal cleft
E- 5th pharangeal cleft
Ans: B

59- Primitive streak first appears at the beginning of
A- 1st week
B- 2nd week
C- 3rd week
D- 4th week
E- 5th week
Ans: C

Explanation:
Early fetal development
- 1st week- implantation of blastocyst
- 2nd week - (2 layers) bilaminar disc (hypoblast , epiblast)
- 3rd week - (3 layers) epiblast invaginate forms primitive streak and ectoderm , mesoderm endoderm forms
- 4th week - 4 limbs
- 5th week gut rotation start
- End of 5th week - definitive heart formed
- 6th week - fetal cardiac activity visible by Transvaginal ultrasound
- 7th week - fetal cardiac acuvity by transabdominal ultrasound
- 10th week - genitalias confirmed

60- Hypospadias due to abnormality of:
A- Urogenital Sinus
B- Urogenital Folds
C- Urachus
D- Bladder
E- Kidney
Ans: B

Explanation:
- In hypospadias defective urogenital folds associated with inguinal hernia and cryptorchidism
- In epispadias defective genital tuburcle associated with extrophy of bladder

61- Fetal Period begins at which week:
A- 10th Week
B- 3rd Week
C- 2nd Week
D- 9th Week
Ans: D

62- An 18 Years old girl with bicornuate uterus is most likely due to which of the following abnormality:
A- Paramesonephric duct
B- Mesonephric duct
C- Wolffian duct
D- Tubule
Ans: A

63- Liver is derived from:
A- Ventral foregut
B- Dorsal foregut
C- Midgut
D- Hindgut
Ans: A

Explanation:
- Foregut - Pharynx (vagus nerve only) and lower oesophagus (celiac artery only) to proximal duodenum; liver, gallbladder, pancreas, spleen (mesoderm)
- Midgut - Distal duodenum to proximal 2/3 of transverse colon
- Hindgut - Distal 1/3 of transverse colon to upper portion of anal canal

64- Cleft palate due to malformation of:
A- Palatine shelves
B- Maxillary prominence
C- Medial nasal prominence
D- Lateral nasal prominence
Ans: A

Explanation:
- Cleft palate due to malformation of palatine shelves
- Midline cleft lip is due to failure of fusion of 2 medial nasal processes
- Unilateral cleft lip is failure of fusion of median nasal process with maxillary process

65- Patent lumen of allantois forms:
A- Urachal sious
B- Urachal cyst
C- Umbilical vein
D- Urachal fistula
Ans: D

Explanation:
- Most common remnant of allantois - urachal cyst
- Patent lumen of allantois - urachal fistula
- Patent local area of allantois - urachal cyst
- Patent lumen of allantois in inferior or superior part - urachal sinus

66- Fetal component of placeota of formed by:
A- Chonome Frundosum
B- Functionalis Layer
C- Basalis Layer
D- Eodometrium
Ans: A

Explanation:
- Fetal component of placenta if formed by - chronic fundiosum
- Maternal component of placenta if formed by - decidua basalis

67- Tragus of external ear develops from
A- 1st arch
B- 1st cleft
C- 2nd arch
D- 2nd cleft
Ans: A

68- primary ooctyes enter meiosis during:
A- Intra uterine life
B- Puberty
C- Before fertilization
D- After Ovulation
Ans: A

69- Double ureter is due to:
A- Ureteric bud fails to reach
B- Ureteric bud fails to induce
C- Early division of Ureteric bud
D- Loss of mesoderm
Ans: C

70- Myelination of felus starts at
A- 3rd Month
B- 4th Month
C- 6th Month
D- 2 Years
E- 2 months
Ans: B

71- Meiosis is a type of cell division in which?
A- DNA synthesis takes place
B- Exchange of genetic material takes place in autosomes
C- One cell give rise to eight spermatozoa
D- Take place in somatic cells
Ans: B

72- Neural crest cells migrate to hindbrain to form:
A- Papillary muscle
B- Foramen Ovale
C- Right Atrium
D- Endocardial Cushion
Ans: D

73- Penetration of Coronn radiata is done by which of the following component of Sperm:
A- Hyaluronidase
B- Fibroclastase
C- Nucleases
D- Lysosome
Ans: A

74- Paramesonephric duct gives rise to which of the following?
A- Vasdeferens
B- Uterus + Fallopian tube
C- Whole Vagina
D- Only Uterus
Ans: B

75- Regarding tracheoesophageal fistula, which structure seporates them?
A- Bronchial bud
B- Laryngeal fold
C- Laryngotracheal groove
D- Thymus
Ans: C

76- Common remnant of allantois is formed as:
A- Urachal cyst
B- Uracbal sinus
C- Urachal fistula
D- Medial ligament
Ans: A

77- The developmental origin of pancreatic alpha, beta and delta cells is from:
A- Endoderm
B- Mesoderm
C- Splanchnic mesoderm
D- Ectoderm
Ans: A

78- Skeletal muscles develop from
A- Mesoderm
B- Endoderm
C- Ectoderm
D- Mesoderm and endoderm
E- Mesoderm and neural crest cells
Ans: A

Explanation:
- Skeletal muscle derived from - mesoderm
- Skeletal system derived from - mesoderm and neural crest cells.

79- Meckel's diverticulum is congenital malformation of
A- Stomach
B- Duodenum
C- Jejunum
D- Heum
E- Pancreas
Ans: D

80- Compactioa and segregation of inner cellular mass in development occurs after
A- 1st division
B- 2nd divisioo
C- 3rd division
D- 4th division
Ans D

CamScanner

81- Recurrent laryngeal nerve arches around which aortic arch?
A- 1st
B- 2nd
C. 3rd
D 4th
E- 6th
Ans: E

Explanation:
Mnemonic for nerves derivatives 5 7 9 10
- 1st arch - V3 (mandibular nerve)
- 2nd arch - 7 facial nerve
- 3rd arch - 9 glossopharageal
- 4th arch - 10 superior larangeal nerve
- 6th arch - 10 recurrent laiangeal nerve

82- Heuser's memebrane from hypoblast will make boundary of:
A- Exocoelomic cavity
B Intraniccoelom
C Amniotic cavity
D- chorionic cavity
Ans: B

83- Kupffer cells are derived from:
A- Ectoderm
B- Mesoderm
C- Endoderm
D- Mesenchym
E- Neural crest cell
Ans: B

Explanation:
- Kuffer cells from – Mesoderm
- Hepatocyte from – Endoderm

84- In a boy on examination a structure which fails to develop on the ventral surface of penis, what's the counterpart of structure in a girl?
A- Labia Majora
B- Labia Minora
C- Clitoris
D- Uterus
Ans: B

Explanation:
Urogenital folds make the ventral surface of penis and urethra in boy
Labia minora in a girl.

85- Baby boy presented with difficulty in feeding and regurgitation of milk from nose , on examination there is communication between oral and nasal cavity , what is diagnosis
A- Cleft lip and palate
B- Nasal fistulas
C- Labial fistulas
D- Sublingual cysts
Ans: A

86- Derivative of neural crest cells:
A- Melanocytes
B- Autonomic ganglia
C- Lens of eye
D- Cardiac chambers
Ans: B

87- Derivatives of 3rd brachial arch
A- Masseter
B- Temporalis
C- Coricothyroid muscle
D- Anterior belly of digastric
E- Stylopharyngeus
Ans: E

88- Palatine crypt is derived from
A- 1st brachial pouch
B- 2nd brachial pouch
C- 1st btachial arch
D- 2nd brachial arch
Ans: B

89- Ovaries develop from:
A- Paramesonephric duct
B Mesonephric duct
C- Gonads
D Gubernaculum
Ans: C

Explanation:
- Gonads give raise to Ovaries, ovarian follicles & rete ovarii in a female.

90- Salivary glands are derivatives of
A- Ectoderm
B Mesoderm
C- Endoderm
D- Neural crest cells
E- Endoderm + ectoderm
Ans: E

91- Counter part of labia majora in men:
A- Scrotum
B- Penis
C- Testis
D- Appendix testis
Ans: A

92- Patent ductus arteriosus is derivative of
A- 1st arch
B- 2nd arch
C- 3rd arch
D- 4th arch
E- Left 6th arch
Ans: E

93- Baby movements start at
A 2 months
B 4 months
C- 6 months
D- 8 months
Ans: A

Explanation:
- Fetal movement – At 2 month or 8 weeks
- Fetal Quickening – At 4-5 months

94- Somites develop from
A- Ectoderm
B- Endoderm
C- Paraxial mesoderm
D- Neural crest cells
Ans: C

95- First meiotic division starts at
A- Begins from fetal life
B- Begins in puberty
C- Begins during ovulation
D- Begins during fertilization
Ans: A

96- Which of the following brain vesicle first appears?
A- Telencephlon
B- Diencephelon
C- Mesencephelon
D- Metencephelon
E- Myelencephelon
Ans: C

97- Chromosome exchange between autosomes in
A- Meiosis
B- Mitosis
C- Binary Vision
D- Prophase
Ans: A

98- Germ cells in yolk sac arrive at:
A 2nd week
B- 2 to 4 week
C- 3 to 6 week
D- 4 to 6 week
E- 6 to 7 week
Ans: D

99- Genitourinary system is derived from:
A- Lateral Plate mesoderm
B- Epiblast
C- Hypoblast
D Intermediate mesoderm
Ans: D

100- Notochord arise from
A- Ectoderm
B- Endoderm
C- Mesoderm
D- Neural crest cells
Ans: C

101- Microtia is due to defect of
A- 1st branchial Arch
B- 2nd branchial Arch
C- 1st and 2nd brachial arch
D- 3rd and 4th branchial Arch
Ans: C

102- Istarchnamels
A- Mandibular
B- Hyoid
C- Facial
D- Occipital
Ans: A

103- Correct statement regarding oogenesis:
A- First meiotic division starts during fetal life
B- Secondary meiotic division completes just before fertilization
C- Graffian follicle contains primary oocyte
D- Adult ovary has columnar epithelium
Ans: A

104- Primary spermatocyte is divided by
A- Mitosis
B- Primary meiotic division
C- Secondary meiotic division
D- Spermiocytosis
Ans: B

105- The primary oocyte after first maturation division produces:
A- Two haploid cells
B Two equal sized cells
C Addition of DNA
D One secondary oocyte and polar body
Ans: D

106- No. Of occipital somites in human fetus
A- 4
B- 8
C- 12
D- 5
E- 10
Ans: A

Explanation:
- Occipital 4
- Cervical 8
- Thoracic 12
- Lumbar, sacral 5
- Coccygeal 8 to 10

107- Ist somite to develop in fetus
A- Occipital
B- Cervical
C- Thoracic
D- Lumbar
E- Sacral
Ans: A

Explanation:
- 1st - occipital
- Last - coccygeal

108- Derivative of 6th branchial arch:
A Laryngeal cartilage
B- Facial Bone
C- Thyroid
O Cricoid
E- Stylopharyngeus
Ans: D

CamScanner

109- Primary oocyte surrounded by zone pellucida, zona granulosa and fluid filled cavity is called:
A- Primary Follicle
B- Secondary Follicle
C- Tertary Follicle
D- Secondary oocyte
Ans: D

110- Thyroid is derived from
A- Ectoderm
B- Endoderm
C- Mesoderm
D- Neural crest cells
Ans: B

111- Erythropoiesis during 4th intrauterine months done in:
A- Liver
B- Spleen
C- Yolk Sac
D- Bone marrow
Ans: A
Explanation:
- Yolk sac - 3 to 8 weeks
- Liver - 6 weeks to birth
- Spleen - 10 to 28 weeks
- Bone marrow - 18 weeks to aduh

112- Tunica vaginalis is derived from
A- Peritoneum
B- External oblique muscles
C- Internal oblique muscle
D- Transversalis fascia
E- Transversalis muscle
Ans: A

113- Laryngotracheal groove develops in which week?
A- 4th Week
B- 5th Week
C- 6th Week
D- 3rd Week
Ans: A(KLM)

114- Antenatal checkup for down syndrome at 11th week of Gestation?
A- CVS
B- CT
C- MRI
D- Amniocentesis
Ans: A

115- Maxillary artery is derivative of which aortic arch?
A- 1st
B- 2nd
C- 3rd
D- 4th
E- 6th
Ans: A

116- Mullerian duct develops into?
A- Uterus & Vagina
B- Penis & Testis
C- Bladder
D- Prostate
Ans: A

117- All are neural crest cell derived except:
A- Vomer bone
B- Choroid and sclera of eye
C- Tunica media of great vessels
D- Olfactory epithelium
E- Vestibule & cochlea
Ans: C

118- Which of the following structure is derived from dorsal as well as ventral bud?
A- Liver
B- Gall bladder
C- Pancreas
D- Spleen
Ans: C

119- Corona radiata in secondary oocyte which layer forms it?
A- Granulosa
B- Primary oocyte
C- Theca external
D- Theca internal
Ans: A

120- About 5th aortic arch:
A- No derivatives to adult
B- Give rise to right subclavian artery
C- Give rise to ductus arteriosum
D- Give rise to larangeal canilages
Ans: A

121- Primordial germ cells derived from:
A- Ectoderm
B- Endoderm
C- Mesoderm
D- Neural crest cells
Ans: A
Explanation:
Derivatives of ectoderm
- Epidermis (hairs , nails)
- Nervous system
- Primodial germ cells
- Nervous system

122- True about amniotic membrane:
A- Derived from hypoblast
B- Derived from fetal ectoderm
C- Immunogenic
D- Non immunogenic
Ans: D

123- Cleft lip is caused by:
A- Failure of maxillary process to fuse with lateral nasal process
B- Failure of mandibular process
C- Failure of palatine shelves
D- Failure of nasal process
Ans: A

124- Umbilical vein has % of oxygen:
A- 20%
B- 30%
C- 40%
D- 60%
E- 80%
Ans: E

125- Which structure separates maternal and fetal blood at last stages?
A- Cytotrophoblast
B- Syncytiotrophoblasts
C- Cytotrophoblast and Syncytiotrophoblasts
D- Syncytiotrophoblast and fetal endothelium
Ans: D

126- Age estimation from 5th to 12th week is done through
A- Crown rump length
B- Parietal diameter
C- Abdominal circumference
D- Crown heel length
Ans: A
Explanation:
1st trimester- CRL
2nd trimester- BPD

127- CRL at 17- 20 weeks is
A- 13 to 17 cm
B- 20 to 22 cm
C- 25 to 30 cm
D- 30 to 35 cm
Ans: A

128- Spermiogenesis is:
A- Primary oocytes form secondary oocytes
B- Secondary oocytes form spermatids
C- Spermatid form spermatozoa
D- Primary spermatocytes forms spermatids
Ans: C

129- Median umbilical ligament is remnant of:
A- Urachus
B- Ductus venoses
C- umblicalartrey
D- umblicalvien
Ans: A

130- Fetal heart differs from adult heart by?
A- Left atrium has more pressure than right atrium
B- Septum primum and secundum fuse to complete separation between common atria
C- Fused endocardial cushions divide right and left atrioventricular canals
D- Sinus venosus carries blood from Pulmonary artery to arch of aorta
Ans: C

131- About Leydig cells:
A- Make sperm testis barrier
B- Mainly reside in semmiferous tubules
C- Have high level of SER
D- Cause sperm maturation
Ans: C

132- Cardiac defects in fetus of mother suffering from rubella infection, infection will Occur in which time
A- 2nd to 3rd week
B- 3rd to 4th week
C- 5th to 10th week
D- 10th to 12th week
Ans: C

133- Drinking of alcohol affects organogenesis during:
A- 1 to 3 weeks
B- 3 to 8 weeks
C- 7 to 12 weeeks
D- After 12 weeks
Ans: B

134- Ureteric bud is formed as a part of :
A- Mesonephric duct
B- Paramesonephric duct
C- Pronephros
D- Cloaca
E- Metanephros
Ans: A

135- About Somites
A- Arise from both side of notochord
B- Arise from lateral plate mesoderm
C- Arise from intermediate plate mesoderm
D- Forms the parietal region
Ans: A

136- Baby with some red structure coming out above public symphasis, frequently getting wet, O/E epispadia and incomplete closure of pubic symphysis:
A- Bladder exstrophy
B- Incomplete cephalocaudal folding
C- Incomplete lateral folding
D- Failed reinforcement of the cloacal membrane by underlying mesenchyme
Ans: A

137- Ectoderm will give rise to which organ system:
A- GIT
B- CNS
C- CVS
D- renal
E- endocrine
Ans: B

138- Collecting system of kidney derived from
A- Mesonephric duct
B- Paramesonephric duct
C- Ureteric bud
D- Mesonephric tubules
E- Paramesonephric tubules
Ans: C

CamScanner

139- Right subclavian artery derived from:
A- Aortic arch 1
B- Aortic arch 2
C- Aortic arch 3
D- Aortic arch 4
Ans: D

140- Oogonia undergoes mitosis in:
A- Post natal
B- Yolk sac
C- Prenatal after 3 months
D- Prenatal after 3 weeks
E- Prenatal 7 to 8 weeks
Ans: C

141- By the End of 5th week:
A- Definitive Heart Forms
B- Stomach rotates
C- Limbs bud appear
D- fetal movements start
E- fetal cardiac activity visible
Ans: A

142- Melanocytes derived from:
A- Dermis
B- Neural crest cells.
C- Mesoderm
D- Endoderm
Ans: B

143- Prenatal chromosomal abnormality detected in which week of pregnancy
A- 3 to 6 weeks
B- 6 to 8 weeks
C- 7 to 9 weeks
D- 10 to 12 weeks
E- 14 to 18 weeks
Ans: E

144- Oral (buccopharyngeal) membrane separates:-
A- Amniotic sac from yolk sac
B- Larynx from pharynx
C- Nasal cavity from oral cavity
D- Proctoderm from oral hindgut
E- Stomodaeum from foregut
Ans: E

145- Neural crest cells arise from:
A- Neural tube
B- Neural plate
C- Ectoderm
D- endoderm
E- Mesoderm
Ans: C

146- Smoking affect organogenesis during which period of gestation?
A- 3-8 weeks
B- 4-10 weeks
C- 12-15 weeks
D- 1-2 weeks
Ans: A

147- Myelination of peripheral nerves in fetus occurs in which month?
A- 2nd month
B- 4th month
C- 6th month
D- 8th month
Ans: B

Explanation
- Myelination of peripheral nerves in fetus occurs in - 4th month
- Myelination of cranial nerves in fetus occurs in - 6th month

148- Cortical oocyte release:
A- LH
B- FSH
C- Progesterone
D- Estrogen
E- Act as lysosomal vesicle
Ans: E

149- How many somite's present on 30 day?
A- 20
B- 30
C- 34-35
D- 40
Ans: C

Explanation:
The first pair of somite arise in occipital region at approximately 20th day of development, the new somites forms at the rate of 3 pairs per days, 34 to 45 at 30 day

150- 08 months old child having esophageal candidiasis, chest infection from pneumocystis carinii, thin thymus, diminished body Lymph nodes and no germinal centers in Lymph nodes, causes is:
A- Antibody to b and t cells
B- 3rd and 4th pharyngeal pouch defect
C- HIV
D- Failure of conversion of plasma cells to b cells
Ans: B

151- Derivative from 2nd pharyngeal arch:
A- Squamous part of temporal bone
B- Styloid part of temporal bone
C- Zygomatic bone
D- Maxilla
E- Palatine
Ans: B
Explanation:

Cartilage Derivatives of 2nd pharyngeal arch
- Reichert cartilage:
- Stapes, styloid process,
- Lesser horn of hyoid,
- Stylohyoid ligament

152- Patent ductus arteriosus associated with:
A- Maternal age
B- Prematurity
C- Drugs
D- Rheumatic fever
Ans: B

153- Vertebrae is derived from:
A- Sclerotome
B- Notocord
C- Dermatome
D- Neural crest cell
Ans: A

Explanation:
Somites subdivision into
- Sclerotome - gives rise to vertebrae of the vertebral column, mesenchymal or Embryonal connective tissue, rib cage and part of occipital bone
- Dermomyotome - gives rise to skeletal muscle, cartilage, tendon and skin of back

154- Left Umbilical Artery remnant is:
A- Median ligament
B- Medial ligament
C- Ligamentum teres
D- Urachus
Ans: B

Explanation:
- Left umbilical artery remnant - medial ligament
- Left umbilical vein remnant ligamentum teres

155- Hx of Child with constipation and failure to pass meconium, on examination colon is aganglionic. What is diagnosis ?
A- Hirschsprung disease
B- Cystic fibrosis
C- Ectopic anal opening
D- volvulus
Ans: A

Explanation:
Congenital megacolon characterized by lack of ganglion cells enteric nervous plexuses (Auerbach and Meissner plexuses) in distal segment of colon. Due to failure of neural crest cell migration. Associated with loss of function mutations in RET.

156- Fetus has?
A- 2 umbilical arteries
B- 2 umbilical veins
C- 1 umbilical artery
D- 3 viens
Ans: A

Explanation:
Umbilical cord has 2 arteries and 1 vein. Right umbilical vein disappeared, only left is left

157- 4th pouch derivative is
A- Eustitichian tube
B- Superior parathyroid
C- Inferior parathyroid
D- Thymus
E- Palatine tonsil
Ans: B

158- Optic groove appears on left side of forebrain on which day
A- 22 days
B- 28 days
C- 30 days
D- 36 days
Ans: A

Explanation:
- Optic groove - 22 days
- Optic vesicle - 28 days
- Lens vesicles - 30 days

159- Derivative of neuroectoderm
A- Sphincter pupillae muscles
B- Lens
C- Conjuctiva
D- Lacrimal glands
Ans: A

160- Chronic villi main component
A- decidua perital is
B- Decidua capsularis
C- Decidua feotalis
D- Chorionic plates
Ans: D

161- Neural crest cell derivative:
A- Melanocytes
B- Unipolar neuron
C- Adrenal Cortex
D- Hepatocytes
E- Thyroid
Ans: A

Explanation:
Neural crest derivatives
1. Autonomic ganglia
2. Melanocytes
3. Chromaffin cells
4. Enterochromaffin cells
5. Pia and arachnoid matter
6. Parafollicular cells of thyroid
7. Schwann cells
8. Endocardial cushion

162- Erythropoiesis occur in middle trimester mainly from?
A- Kidney
B- Spleen
C- Yolk sac
D- Bone marrow
E- Liver
Ans: E

CamScanner

163- Trigone of urinary bladder derived of which of following?
A- Endoderm
B- Mesoderm
C- Ectoderm
D- Neural crest cell
E- Neuroendoderm
Ans: B

Explanation:
- Bladder trigone from – Mesoderm
- Bladder transitional epithelium from – Endoderm

164- Rathkes pouch derived from
A- Endoderm
B- Mesoderm
C- Stomodium of foregut
D- Neural Crest cells
E- Neural Groove
Ans: C(Langman)

165- A fetus was aborted .it was sent to forensic lab -how can the viability be checked .tht for how long the fetus was viable?
A- Fetus weight 200g
B- Eyes laterally
C- Fetus CRL >250 mm
D- Absence of wrinkles
E- Absent toenails
Ans: C

166- A child born with urine coming out from umbilicus Doctor diagnosed this as patent lumen of allantois which results in which of following?
A- Urachal fistula (Patent Urachus)
B- Urachal cyst
C- Urachal sinus
D- Extrophy of bladder
E- Atrophy of bladder
Ans: A

167- Mullerien duct forms which of these?
A- Appendix vesiculosa
B- Paradidymis
C- Appendix epididymis
D- Appendix testes
Ans: D

168- Common midline deformity
A- Midline cleft lip
B- Cleft lip
C- Midline cleft lip with nasal involvement
D- Micrognathia
Ans: A

169- What is Aneuploidy?
A- All chromosomal abberations including deletions, duplication, trisomy ,etc
B- Chromosomal structural abberations
C- Trisomy
D- Chromosomal numerical abberations like monosomy, trisomy etc
Ans: D

170- Germinal cells in 3rd week migrate from
A- Endoderm
B- Ectoderm
C- Mesoderm
D- Neural crest cells
Ans: B

171- Left cleft palate due to malformation of
A- Palatine shelves
B- Maxillary prominence
C- Medial nasal prominence
D- Lateral nasal prominence
E- Incisive foramen
Ans: A

172- The primordial germ cells are derived from?
A- Ectoderm
B- Epiblast
C- Endoderm
D- Mesoderm
E- Neural crest cell
Ans: B

Explanation:
- Epiblast >Ectoderm>Yolk sac endoderm

173- 80 year male patient complain of watery discharge from umbilicus with 4 year history of Prostate enlargement with urethral obstruction and he got treatment for that what is your diagnosis ?
A- Malignancy
B- Patent urachus
C- Patent vitelline duct
D- Degenerative Duct
Ans: B

174- Space formed by extraembryonic splanchnic and somatopleuric mesoderm
A- Amniotic cavity
B- Blastocoele
C- Extrambryonic coelom
D- Intraembryonic cavity
Ans: C

175- Posterior lobe of the pituitary gland develops from
A- Diencephalon
B- Telencephalic vesicle
C- Surface ectoderm
D- Neural crest cells
E- Mesencephalon
Ans: A

176- Muscle derived from first pharyngeal arch is:
A- Masseter
B- Posterior belly of digastric
C- Stylohyoid
D- Stylopharyngeus
Ans: A(FA+KLM)

Explanation:
Muscles derivatives
- 1st arch - Muscles of mastication (temporalis, masseter, lateral and medial pterygoids), mylohyoid, anterior belly of digastric, tensor tympani, anterior 2/3 of tongue, tensor velipalatini
- 2nd arch - Muscles of facial expression, stapedius, stylohyoid, platysma, posterior belly of digastric
- 3rd arch - Stylopharyngeus
- 4th arch - most pharyngeal constrictors; cricothyroid, levatorvelipalatini
- 6th arch - all intrinsic muscles of larynx except cricothyroid

177- Primitive streak ectoderm and endoderm meet at:
A- Cloacal membrane
B- Vitelline duct
C- Yolk sac
D- Extraepiploic membrane
Ans: A

178- Human placenta has:
A- Amnion on its fetal side
B- Chorioallantoic placenta
C- Get separated along the stratum spongiosum
D- Get separated when there is rupture of many uterine arteries
E- Hemochoridal membrane
Ans: D (Prefer uterine muscles)

179- First pharyngeal arch derivative is:
A- Platysma
B- Stylopharyngeus
C- Mylohyoid
D- Stylohyoid
E- Cricothyroid
Ans: C(Kaplan +FA)

180- Pulmonary artery develops from which arch?
A- 3rd arch
B- 4th arch
C- 6th arch
D- 1st arch
Ans: C

181- Absence of limb is due to mal development of which of these?
A- Somites
B- Lateral plate mesoderm
C- Cushions
D- Ectoderm
Ans: B

182- Bones of skull and face derived from:
A- Neural crest cells
B- Lateral plate mesoderm
C- Endoderm
D- Autonomic ganglia
Ans: A

183- Gestational Sac is also called as:
A- Embryo
B- Fetus
C- Amniotic Sac
D- Development Sac
Ans: C

184- Aromatase secreted by?
A- Theca cell
B- Granulosa cell
C- Theca external
D- Theca internal
Ans: B

185- Corticospinal tract myelination starts at:
A- 28 Weeks
B- 36 Weeks
C- 40 Weeks
D- After Birth
Ans: B

Explanation:
Start during 36 weeks and completed after birth at 2 year

186- A newborn baby is noted to have a left unilateral cleft lip. There are no abnormalities of the baby's palate. Which of the following developmental defects accounts for this occurrence?
A- Failure of the left lateral palatine process to fuse with the median palatine process
A- Failure of the left maxillary prominence to unite with the left medial nasal prominence
B- Failure of the right and left medial nasal prominences to merge
D- Failure of the left maxillary process to fuse with the left medial nasal process
Ans: D

Explanation:
- Mid line cleft lip is failure of fusion of two medial nasal processes.
- Unilateral cleft lip failure of fusion of median nasal process with maxillary process.

187- Chorionic villus sampling done at which week?
A- 11 – 12 week
B- 14 – 16 week
C- 19 week
D- 20 week
E- 8 – 10 week
Ans: A (Ten teacher)

CamScanner

Explanation:
- CVS at – 11 week and 2% risk of miscarriage.
- Amniocentesis at – 15 week and 1% risk of miscarriage.
- Cordocentesis at – 20 weeks and 2-5% risk of miscarriage.

188- Pleuropericardial membrane fuse to form?
A- Visceral pleura
B- Peretal pleura
C- Fibrinous pericardium
D- Serous pericardium
Ans: C

189- Liver derived from which of these? ——
A- Midgut
B- Hindgut
C- Foregut
D- Retro gut
Ans: C

190- Regarding Meckel's Diverticulum, what is true:
A- It is remnant of embryonic yolk sac
B- Present in 5% population
C- It is 60 cm distal to ilioceal valve
D- Present in 20% population
Ans: A

191- Small tube on illium remant of
A- Ydk sac
B- Vitelline duct
C- Patent uracus
D- Remnant of urachus
Ans: B

192- Main organs of body laid down by which month:
A- 2
B- 4
C- 5
D- 6
E- 3
Ans: A

193- Remnant of paramesonephric duct in male is:
A- Appendix testis
B- Fallopn tube
C- Seminal vesicles
D- Ductus deference
Ans: A

194- Ureter is derived from :
A- Endoderm
B- Mesoderm
C- Outgrowth from mesonephric duct
D- Ectoderm
Ans: B

195- What is neurulation?
A- Formation of neural tube
B- Formation of notochord
C- Formation of streak
D- Formation of CNS
Ans: A

196- Morn reflex appers:
A- 3 months postnatal
B- 5months post natal
C- 3-5 month postnatal
D- Intrauterine after 8-9 months
Ans: D

197- Spina bifida occurs due to deficiency of
A- Mg
B- Ca
C- Iron
D- Folate
E- B6
Ans: D

198- Ligamentum teres is the remnant of which embryological structure?
A- Part of ductus arteriosus
B- Part of ductus venosus
C- Remnant of left umbilical vein
D- Present in margm of coronary ligament
E- Remnant of umbilical artery
Ans: C

Explanation:
- Ductus venosus – Ligamentum venosum.
- Ductus arteriosus – Ligamentum arteriosum.
- Left umbilical vein – Ligamentum teres
- Right umbilical vein obliterates before birth having no derivative.
- Umbilical arteries – Medial umbilical ligament.
- Urachus (Allantois) – Median umbilical Ligament

199- Abemhryonic pole is formed by ——
A- Decidua parietalis
B- Decidua basalis
C- Decidua capsularis
D- Decidua angularis
Ans: C

200- Corpus luteum Secretes mainly:
A- Progesterone
B- Inhibin
C- Estrogen, Progesterone and Inhibin
D- Estrogen
Ans: C

Explanation:
- Corpus luteum secrete – Progesterone, Estrogen and Inhibin
- Corpus luteum secrete to maintain Pregnancy – Progesterone

201- A patient present with primary amenorrhea and well developed secondary sexual characteristics Patient has breast but absent uterus it is due to abnormal development of:
A- Mesonephric duct
B- Paramesonephric duct
C- Genital tubercle
D- Mullerian tubercle
Ans: B

202- Functional remnant of mesonephric duct in male?
A- Ejaculatory duct
B- Seminal vesicles
C- Ductus deferens
D- Rete testis
Ans: C

203- Tragis and anti halix is derived from:
A- Ist pharyngeal pouch
B- Ist pharyngeal Arch
C- 2nd pharyngeal arch
D- 2nd pharyngeal arch
Ans: B

204- Development of anterior pituitary gland from:
A- Rathke's pouch from diencephalon
B- Outpuching from stomodeum
C- Evagination from telencephalon
D- Evagination from mesencephalon
Ans: B

205- Ear pinna and tragus develops from:
A- Ist and 2nd branchial arch
B- 2nd and 3rd branchial arch
C- Ist branchial cleft
D- 2nd branchial cleft
E- 4th branchial arch
Ans: A

Explanation:
- External auditory meatus – 1st cleft
- Pinna or auricle – 1st and 2nd branchial arch
- Auditory canal or eustachian tube and tympanic
- cavity and mastoid air cells – 1st Pouch
- Ear ossicles – 1st and 2nd brachial arch

206- Monozygotic twins can only differ in:
A- Melanocytes
B- Eye color
C- Hair color
D- Vascular changes
Ans: A

207- Pregnant lady has twin pregnancy on ultrasound she has common placenta but 2 amniotic sac what type of twins are?
A- Monochorionic monoamniotic
B- Monochorionic diamniotic
C- Diamniotic dichorionic
D- Identical twins
Ans: B

208- FSH is inhibited by inhibin, which is secreted by:
A- Sertoli cells
B- Leydig cells
C- Granulosa cells
D- Mullerian cells
E- Theca cells
Ans: A

209- A newborn baby is noted to have a Abnormality of lip due to Failure of the left maxillary process to fuse with the left medial nasal process this is:
A- Cleft palate
B- Soft palate abnormality
C- Unilateral cleft lip
D- Cleft hard palate
Ans: C

Explanation:
- Mid line cleft lip is failure of fusion of two medial nasal processes.
- Unilateral cleft lip failure of fusion of median nasal process with maxillary process.
- Cleft palate failure of fusion of lateral palatine process nasal septum and median palatine process

210- Primary villus consist of which cells?
A- Fetal endothelium
B- Mesoderm + Capillaries
C- Cytotrophoblast and syncytiotrophoblast
D- Cytotrophoblast +Capillaries
E- Capillaries
Ans: C

Explanation:
- Primary- Cytotrophoblast + syncytiotrophoblast
- Secondary-Cytotrophoblast +syncytiotrophoblast +Mesoderm
- Tertiary- Cytotrophoblast+syncytiotrophoblast +Capillaries

211- Which structure is formed from genital tubercle?
A- Labiamajora
B- Clitoris
C- Labia minora
D- Epididymis
E- Ductus deference
Ans: B

CamScanner

212- Formation of upper part of vagina by:
A- Lower fusion of Mullerian duct
B- Urogenital fold
C- Mesonephric duct
D- Anorectal septum
E- Metanephros
Ans: A

213- During pregnancy the lumen of uterine cavity is obliterated by fusion of:
A- Decidua basalis & spongy layer
B- Decidua basalis & decidua capsularis
C- Decidua capsularis & decidua parietalis
D- Decidua parietalis & decidua basalis
E- Decidua capsularis & decidua basalis
Ans: C

214- Stratum functionalis formed by:
A- Compactum + spinosum
B- Basalis + spinosum
C- Lucidum
D- Corneum
Ans: A

215- Superior parathyroid derived from:
A- 1st pharyngeal pouch
B- 2nd pharyngeal pouch
C- 3rd pharyngeal pouch
D- 4th pharyngeal pouch
Ans: D
Explanation:
1st pouch derivative:
- Middle Ear cavity
- Mastoid air cell
- Eustachian tube

2nd pouch derivative:
- Palatine tonsils epithelial lining

3rd Pouch derivate:
- Ventral Wing – Thymus
- Dorsal Wing – Inferior Parathyroid

4th pouch derivative:
- Ventral Wing – Ultimopharyngeal body, Para follicular C cells of thyroid
- Dorsal Wing – Superior Parathyroid

216- Boy with undescended testis Testis complete their descent during which week
A- 20th
B- 28th
C- 42th
D- 44th
Ans: B

217- Twin pregnancy with two ovum. Which is correct?
A- Same placenta
B- Same amniotic sac
C- Separate amniotic sac
D- Same chorion
Ans: C

218- Contents of umbilical cord at birth:
A- Two umbilical arteries
B- Two umbilical vein
C- Allantois
D- Vitelline duct
E- Meckel's diverticulum
Ans: A

219- A patient has Microtia and maldevelopment of external auditory canal is due to defect of:
A- 1st branchial Arch
B- 2nd branchial Arch
C- 1st and 2nd brachial arch
D- 3rd and 4th branchial Arch
Ans: C

220- Eventration of diaphragm occurs due to improper fusion of:
A- Dorsal mesentery of the esophagus and pleuroperitoneal membrane
B- Dorsal mesenteric of esophagus and pleuro pericardial membrane
C- Ventral mesentery of esophagus and lateral body wall
D- Lateral muscular growth of diaphragm
E- Lateral muscles fusion with septum transversum
Ans: D

221- Derivative of 4th branchial arch is:
A- Laryngeal cartilage
B- Facial Bone
C- Thyroid
D- Cricoid
E- Stylopharyngeus
Ans: C

222- In 3rd week of gestation, which organ begins to appear:
A- Heart tube
B- External genitalia
C- Genital ridge
D- Spleen
Ans: A

223- Baby prefer feeder instead of mother breast due:
A- Cleft soft palate
B- Cleft hard palate
C- Cleft soft + hard palate
D- Cleft lip
Ans: A

224- Organ of corti develops from which embryonic layer?
A- Mesoderm
B- Endoderm + Ectoderm
C- Ectoderm
D- Neural crest
Ans: B

225- Dizygotic twins who share a fused placenta with vascular anastomosis are at risk of which of the following complications?
A- Twin-to-twin transfusion syndrome (TTTS)
B- Preterm labor
C- Placental abruption
D- Hydrops fetalis
E- Erythroblastosis fetalis
Ans: A

226- Which anatomical structure in the human body originates from two embryonic germ layers or parts?
A- Heart
B- Brain
C- Kidney
D- Liver
E- Pancreas
Ans: E
Explanation:
The pancreas has both endodermal and mesodermal origins. Its exocrine cells (acini) develop from the endoderm, while its endocrine cells (islets of Langerhans) have a dual origin, arising from both endodermal and mesodermal tissues.

227- Extra embryonic coelom derived from:
A- Epiblast
B- Hypoblast
C- Lateral plate mesoderm
D- Neural crest
E- Mesoderm
Ans: B
Explanation:
- Extra embryonic mesoderm derived from – Epiblast
- Extraembryonic coelom derived from – Hypoblast
- Intraembryonic coelom derived from – Lateral plate mesoderm

228- Upper part of vagina formed and canalized by?
A- Upper fusion of mesonephric duct
B- Lower fusion of mesonephric duct
C- Upper fusion of paramesonephric duct
D- Lower fusion of paramesonephric duct
Ans: D

229- Changes that occur after birth?
A- Ductus arteriosus converted into ligamentum arteriosum
B- Ductus venosus form Ligamentum teres
C- Umbilical artery form Median Umbilical ligament
D- Umbilical vein open
Ans: A

230- In 8-20 weeks of oogonia development what happen:
A- Follicle completely form
B- Mitotic division starts
C- Meiosis arrest
D- Cells proliferate
Ans: B

231- Clitoris develops from:
A- Wolffian duct
B- Mesonephric duct
C- Genital tubercle
D- Urogenital sinus
E- Mullerian duct
Ans: C

232- Cleft palate, TGA and TOF all are derivatives of:
A- Mesoderm
B- Endoderm
C- Neural crest cells
D- Epithelial lining
Ans: C

233- Origin of diaphragm:
A- Cervical somites
B- Septum transversum
C- Lateral Mesoderm
D- Thoracic somites
E- Lumber Somites
Ans: A

234- Infant with rudimentary hand and foot with irregular small bones, this is likely:
A- Gigantism
B- Phocomelia
C- Amelia
D- Micromelia
E- Congenital band foot syndrome
Ans: B

235- Thymus originates from:
A- 1st pharyngeal pouch
B- 2nd pharyngeal pouch
C- Endoderm of 3rd pharyngeal pouch
D- Ectoderm of 4th pharyngeal pouch
Ans: C

236- A patient came with underdeveloped Left face and chin, distorted external ear and ramus was abnormal on x-ray. Cause is:
A- Facial cleft
B- Mandibular dysostosis
C- Mandibular atonia
D- Cleft ear
Ans: B

237- Pronuclei cleavage after how many hours of conception?
A- 12 hours
B- 24 hours
C- 36 hours
D- 48 hours
Ans: B

CamScanner

238- Neural tube defects identified by maternal?
A- Karyotyping
B- AFP
C- RaisedHCG
D- Amniocentesis
Ans: B

239- Estraembryonic mesoderm is formed by:
A- Hypoblast
B- Epiblast
C- Lateral plate mesoderm
D- Intermediate Mesoderm
Ans: B

Explanation:
- Extraembryonic mesoderm: Epiblast
- Extraembryonic coelom: Hypoblast
- Intraembryonic coelom: Lateral Plate mesoderm

240- The fetal part of placenta is:
A- Cytotrophobast
B- Syncytiotrophoblast
C- Decidua Baselis
D- Decidua basalis & Chorion Frundosum
E- Extraembryonic Coelom
Ans: D

241- Fertilin at head of sperm helps in:
A- Acrosomial reaction.
B- Adherence of spenn head to ovum membrane
C- Movement of head towards the ovum
D- Acrosome removal
Ans: B

Explanation:
- Fertilin-Adherence of sperm to ovum
- Acrosin-acrusome reaction

242- The part of sperm containing proteolytic Enzymes to digest the zona pellucida is the:
A- Capacitor
B- Head
C- Corona
D- Acrosome
E- Cumulus
Ans: D

243- Hyoid bone is derived from which pharyngeal arch:
A- 1st
B- 2nd and 3rd
C- 4th
D- 6th
Ans: B

244- As a resident in paediatrics, you are called to see a new-born who has a unilateral Cleft lip and a unilateral cleft of the primary palate. This anomaly is most likely the result of:
A- Failure of fusion of the mandibular prominences
B- Failure of fusion of the medial nasal processes
C- Failure of fusion of the maxillary prominence with the medial nasal prominence
D- Failure of fusion of the lateral palatine processes with the septum
E- Failure of fusion of the paired lateral palatine process
Ans: C

245- Triple assessment for congenital fetal anomalies includes one of the following:
A- Estradione E2
B- Estrione E1
C- Estriol E3
D- All
Ans: C

Explanation:
- Estrogen in reproductive years--Estradiol (bi- girl and boy)
- Estrogen in pregnancy – Estriol (tri- mom, dad, child)
- Estrogen in menopause – Estrione (1- women becomes single again)
- Potency – estradiol > estrione > estriol

246- Amputation of limb pain is due to:
A- Nerve block
B- Phantom pain
C- Increase sensory supply
D- None
Ans: B

247- A two year old child presented with thin mucoid discharge from an opening on anterior border of sternocleidomastoid muscle in lower third of neck since birth. The origin of this anomaly is related:
A- 1st branchial cleft
B- 1st branchial pouch
C- 2nd branchial arch
D- 2nd branchial pouch
E- 3rd branchial cleft
Ans: C

248- Lower Vagina derived from:
A- Mesonephric duct
B- Urogenital sinus
C- Urogenital bulb
D- Genitle tubercle
Ans: B

Explanation:
Upper vagina - Paramesonephric duct (Mullerien duct)
Lower vagina- Urogenital sinus

In Doppler USG:
A- Finding modify by fetal presentation
B- Use to assesspulsitilty of fetal pulmonary artery
C- Pulsatility increase in growth restricted fetus
D- No change in pulsility in growth restricted fetus
Ans: C

249 Pregnant lady not taking fruits & Vegetables in her diet. Her baby will be at risk of?
A- Anencephaly
B- Fetal Renal agenesis
C- Down syndrome
D- Edward Syndrome
Ans: A

250 A lady is consulted for Amniocentesis for analysis of some chromosal abnormality in her child. This procedure can't be done before
A- 16 weeks
B- 10th weeks
C- 4th weeks
D- 22 Weeks
Ans: B

251 At 3rd week of gestation, mesoderm produces smooth muscles and capillaries in the villi. Type of villi is
A- Syncitiotrophoblast
B- Primary villous
C- Secondary villous
D- Tertiaty villous
Ans: D

252 Which one of the following is endodermal derivative?
A- Spleen
B- Tonsillar parenchyma
C- Gonads
D- Serosa of Peritoneum
E- Adrenal cortex
Ans: B

253 Left recurrent laryngeal nerve originates from which arch
A- 1st arch
B- 2nd arch
C- 4th and 6th arch
D- 5th arch
Ans: C

254 A mother had history of eating undercooked meat . Baby develops microcephaly and brain calcifications . There is microphthlmia too which organism is responsible for this
A- CMV
B- Toxoplasmosis
C- Treponema pallidum
D- Listeria
Ans: B

255 A 3 months baby born to a perfectly healthy mother presented with single palmar crease, Protruded tongue & Prominent epicanthal folds. Baby was diagnosed to have congenital heart disease at birth. The heart abnormality associated with this disease is derived from which structure in embryonic life?
A- Bulbus cordis
B- Truncus arteriosis
C- Neural Crest Cells
D- Primitive atria
E- Primitive ventricle
Ans: C

256 Primigravida Has history of reduced intake of fresh vegetables and juices. Her baby is at risk of developing neural tube defects what deficiency she is at risk of?
A- Vitamin B12
B- Folic acid
C- VitaminE
D- Calcium
Ans: B

Explanation
- Vegetables contain folic acid
- Animals meat contains vitamin B1

257 If unilateral ureteric bud not fused with mesonephric duct, Structure which fails to form is
A- Ureter
B- Glomerulus
C- PCT
D- Collecting tubules
Ans: A

258 Hemoglobin begins to appear at which stage?
A- Early normoblast
B- Intermediate normoblast
C- Late normoblast
D- Reticulocyte
Ans: B

CamScanner

Explanation:
- Hemoglobin synthesis starts at early
- Normoblast, prefer proerythroblast if present in options
- In intermediate normoblast hemoglobin starts to appear
- In late normoblast nucleus disappear
- Reticulocyte contains the highest amount of Hemoglobin

259 Meckel diverticulum is due to
A- Allantois
B- Yolksialk
C- Uachal sinus
D- Urachal fistula
Ans: B

260 Development of anterior pituitary gland from:
A. Rathke's pouch from diencephalon
B. Outpouching from stomodium
C. Evagination from telencephalon
D. Evagination from mesencephalon
Ans: B

261 A girl has a tender Mass which is cranially conected with umbilicus & Caudally connected with bladder. Wldch mass is tbis?
A- Horse shoe kidney
B- Urachalcyst
C- Urachal fistula
D- Bladder Exstrophy
E- Allantois
Ans: B

262 A pregnant lady with 5 weeks of gestational amenorrhea presented to you in the OPD. She was diagnosed with germen measles. Which of the following complications is the fetus most likely to have?
A- B/L cataract
B- Deafnes
C- Aorticopulmonary Heart Defect
D- Conjunctivitis
E- Mental Retardation
Ans: A

Explanation:
- Rubella in pregnancy complication overall – Deafness > Cataract
- Rubella in pregnancy complicauon Within 7 weeks – Cataract
- Rubella in pregnancy complication After 7 weeks – Deafness

263 Ureteric bud not reaching metonephric mesenchyme will lead to:
A- Ureter without kidney
B- Polycystic kidney
C- Renal agenesis
D- Kidney without Ureter
E- Pelvic Kidney
Ans: A

264 Stratum Functionalis shed during menstruation & parturition Consists of which of the following combination of Endometrial layers?
A- Stratum Compactum & Spongiosum
B- Stratum Compactum
C- Stratum Basalis with Spongiosum
D- Stratum Basalis with Compactum
Ans: A

265 Infant of diabetic mother has an increased risk of:
A- Neonatal jaundice
B- Macrocytic anemia
C- Hyperglycemia
D- ARDS
E- Hypercalcemia
Ans: C

266 Girl with 2 ureters & 2 kidneys due to which of the following abnormality in Pelvis?
A- Early division of Ureteric bud
B- Ureteric bud fails to reach metanephros
C- Urogenital sinus
D- Abnormality of PelviUreteric junction
E- Early division of mesonephros & metanephros
Ans: A

267 Extom esodermal fold closure defect will cause:
A- Exstrophy of bladder
B- Urachal Cyst
C- Urachal fistula
D- Sinus
E- Allantois
Ans: A

268 Tragus & Helix of External Ear derived from:
A- 1st branchial arch
B- 1st branchial pouch
C- 2nd branchial pouch
D- 1st branchial Cleft
Ans: A

269 Ostium secundum defect due to:
A- Increased cell death in osuum primum
B- Failure of endocardial cushion to fuse
C- Endocardial cushions
D- Increase no of primum
Ans: B

270 What happens in embryo at the "*End of 3rd week*":
A- Dorsal & Ventral Axis form
B- Lateral Folding occurs
C- Epiblast forms
D- Hypoblast forms
E- Formation of 2 Germ Layers
Ans: E

271 Right microtia und external ear & helix non canalization due to defect in:
A) 1st and 2nd pharyngeal arch
B) 1st and 2nd pharngral groove
C) 2od and 3rd pharyngeal arch
D) 2od and 3rd pharyngeal groove
E) 3rd and 4th pharyngeal arch
Ans: A

272 Adrenal cortex is embryologically derived from:
A- Surface ectoderm
B- Endoderm
C- Mesoderm
D- Neural crest cells
E- Endoderm and mesoderm
Ans: C

273 Gestational layers at 3rd week of Gestation?
A- Ectoderm. Endoderm & Mesoderm
B- Epiblast & Hypoblast
C- Ectoderm & Endoderm
D- Mesoderm & Ectoderm
Ans: A

274 Most abundant chorionic villi present:
A- Chorionic plate
B- Basal plate
C- Decidua parietalis
D- Capsularis
E- Chorion frondosum
Ans: A

275 Craniopharyngioma occurs from a structure that is embryologically derived from:
A- Stomodeum
B- Pharyngeal arch
C- Neural tube
D- Hypophysis
E- Infundibulum
Ans: A

276 4 year old child present with testicular swelling. AFP levels were done which were raised, so tumor was resected after which AFP levels dropped to normal. Child was suffering from which tumor?
A- Choriocarcinoma
B- Leydig cell tumor
C- Seminoma
D- Yolk sac tumor
Ans: D

277 Bicornuate uterus is due to:
A- Defect of mesonephric duct
B- Failure of fusion of paramesonephric ducts
C- Abnormal division of mesonephric duct
D- Defect of tubule
E- Defect of wolfian duct
Ans: B

Explanation:
Paramesonephric duct (mullerian duct) give raise to female genital structures like fallopian tube, uterus & upper 1/3rd of vagina. Better explanation

278 Child 6is born with normal antenatal history & Doppler On clipping the cord, What is the abnormality due to which a cardiologist is called:
A- One Umbilical Artery
B- 2 Umbilical Arteries
C- Oae Umbilical Vein
D- 2 Umbilical Veins
E- Single Allantoic duct
Ans: A

279 Mandibulofascial dysostosis occurs due to defect in:
A- 1st and 2nd Branchial arch
B- 1st Branchial arch
C- 1st Branchial Cleft
D- 2nd Branchial Cleft
E- 3rd & 4th Branchial arch
Ans: A

280 Coronary sinus develops from:
A- Right horn of sinus venosus
B- Left horn of sinus venosus
C- Right atrium
D- Right Ventricle
Ans: B

Explanation:
Cardio- Vascular Postnatal Derivatives:
- Ductus arteriosus – Ligamentum arteriosum
- Ductus venosus – Ligamentum Arteriosum
- Left horn of Sinus venosus – Coronary sinus
- Foramen ovale– Fossa ovalis
- Allantois – Median umbilical ligament
- Umbilical arteries – Medial umbilical ligaments
- Umbilical vein – Ligamentum teres
- Notochord – Nucleus pulposus

281 An experiment was conducted on mice to analyze sclerotome development, involving somites, somitomeres, and epimeres. The experiment led to the destruction of specific cells. If the mice survive until birth, which muscle will be absent due to its failure to derive from the somite?
A- Latissimus dorsi
B- Rhomboid
C- Serratus anterior
D- Longissimus
E- Pectoralis Major
Ans: D

CamScanner

Explanation:

The **longissimus** muscle, part of the erector spinae group, is derived from the epimere of somites. The destruction of cells involved in somite and epimere development would specifically affect the formation of muscles derived from the epimere, including the longissimus. Other muscles, like the **latissimus dorsi, rhomboid, serratus anterior, and pectoralis major**, are derived from the **hypomere**, which is unaffected in this case.

282 The liver is embryologically derived from which of the following?

A- Foregut
B- Midgut
C- Hindgut
D- Ectoderm
E- Mesoderm

Ans: A(KLM embryo)

Explanation:

The liver primordium appears in the middle of the third week as an outgrowth of the endodermal epithelium at the distal end of the foregut, this out growth,the hepatic diverticulum or liver bud ,consists of rapidly proliferating cells the penetrate the septum transversum, that is, the mesodermal plate between the pericardial cavity and the stalk of the yolk sac

283 Intraembryonic portion of Allantios remnant:

A- Urachal Fistula
B- Urachal cyst
C- Urachal sinus
D- Meckle's Diverticulum

Ans: A

Explanation:

- Most common remnant of allantois - urachal cyst
- Patent lumen of allantois - urachal fistula
- Patent local area of allantois - urachal cyst
- Patent lumen of allantois in inferior or superior part - urachal sinus

284 Maxillary artery is derivative of which aortic arch

A- 1st
B- 2nd
C- 3rd
D- 4th
E- 6th

Ans: A

Explanation:

Aortic Arch Derivatives

Aortic Arch	Derivative and Notes
1st	Part of maxillary artery (branch of external carotid). Mnemonic: 1st arch is maxillary.
2nd	Stapedial artery and hyoid artery. Mnemonic: Second = Stapedial.
3rd	Common carotid artery and proximal part of internal carotid artery. Mnemonic: C is the 3rd letter of the alphabet.
4th	On the left: Aortic arch. On the right: Proximal part of right subclavian artery. Mnemonic: 4th arch (4 limbs) = systemic.
6th	Proximal part of pulmonary arteries and (on left only) ductus arteriosus. Mnemonic: 6th arch = pulmonary and the pulmonary-to- systemic shunt (ductus arteriosus).

285 What type of tissue is critical for dividing the heart into four chambers and the outflow tract into pulmonary and aortic channels?

A. Aorticopulmonary septum
B. Endocardial cushions
C. Conus septum
D. Septum primum
E. Septum secondum

Ans: B

286 Microtia & Abnormality in External auditory meatus is due to.

A- 1st branchial Arch
B- 2nd branchial Arch
C- 1st and 2nd brachial arch
D- 3rd and 4th branchial Arch
E- 1st and 2nd brachial groove

Ans: C(Langman embryo)

Explanation:

Microtia involves defects of the external ear that range from small but well formed ears to absence of the ear (anotia). Because the external ear is derived from hillocks on the first two pharyngeal arches, which are largely formed by neural crest cells, this cell population plays a role in most external ear malformation

287 There is a mass on dorsum of tongue at the junction of anterior 2/3rd and posterior 1/3rd, which of the following is most likely the origin of tumour?

A- Thyroid
B- Ultimobronchial artery
C- Thymus
D- Parathyroid

Ans: A

288 Ductous arteriosus is derivative of

A- 1st pharyngeal arch
B- 2nd pharyngeal arch
C- 3rd pharyngeal arch
D- 4th pharyngeal arch
E- 6th pharyngeal arch

Ans: E

Explanation:

Sixth pharyngeal arch derivatives

Artery:
- Ductus Arteriosus
- Right and left pulmonary artery (proximal part)

Nerve:
- Recurrent laryngeal branch of vagus nerv

Muscles:
- All intrinsic muscles of larynx except cricothyroid muscle and Skeletal muscles of Esophagous

Cartilages:
- Thyroid cartilage
- Cricoid cartilage
- Arytenoid cartilage
- Corniculate cartilage
- Cuneiform cartilage

289 Ductous arteriosus is derivative of

A- 1st pharyngeal arch
B- 2nd pharyngeal arch
C- 3rd pharyngeal arch
D- 4th pharyngeal arch
E- 6th pharyngeal arch

Ans: E

Explanation:

Sixth pharyngeal arch derivatives

Artery:
- Ductous Arteriosus
- Right and left pulmonary artery (proximal part)

Nerve:
- Recurrent laryngeal branch of vagus nerv

Muscles:

All intrinsic muscles of larynx except cricothyroid muscle and Skeletal muscles of Esophagous

Cartilages:
- Thyroid cartilage
- Cricoid cartilage
- Arytenoid cartilage
- Corniculate cartilage
- Cuneiform cartilage

290 A derivative of the 2nd pharyngeal arch

A- Stylopharyngeous
B- Stapedius
C- Tensor palatine
D- Masseter
E- Mandibular nerve

Ans: B

Explanation:

Derivatives of second pharyngeal arch

Artery:

Stapedial artery

Nerve:

Facial nerve

Muscles:

Muscles of facial expressions,posterior belly of digastric,stylohyoid,stapedius

Ligament:

Stylohyoid ligament

Bones and cartilage:

Stylohyoid process of temporal bone,upper part of body of hyoid bone,Lesser horn of hyoid bone

291 The Organ of Corti is derived from membranous lybrinth which is formed by which of the following

A- Ectoderm and mesoderm
B- Endoderm
C- Nural Crest Cells
D- Ectoderm +endoderm
E- Mesoderm

Ans: A

292 During the embryo formation which of the following structure is formed by mesothelium and covers the lung bud

A- Visceral pleura of lungs
B- Costal pleura
C- Parietal pleura of lungs
D- Diaphragmatic pleura

Ans: A

293 Child is born with normal antenatal history & Doppler On clipping the cord, What is the abnormality due to which a cardiologist is called:

A- One Umbilical Artery
B- 2 Umbilical Arteries
C- One Umbilical Vein
D- 2 Umbilical Veins
E- Single Allantoic duct

Ans: A

Explanation:

- Normally, the umbilical cord contains two umbilical arteries and one umbilical vein.
- The presence of only one umbilical artery is a congenital anomaly often associated with cardiovascular malformations.
- This anomaly occurs due to the failure of one of the umbilical arteries to form or its regression during development

294 Vagina is derived from:

A- Mesonephric duct
B- Paramesonephric duct & Urogenital sinus
C- Urogenital bulb
D- Genitle tubercle

Ans: B

CamScanner

Explanation:

- Upper vagina – Paramesonephric duct(Mullerien duct)
- Lower vagina- Urogenital sinus

295 In Embryo, The liver & Gallbladder Outpouches at which week?
A- 8Weeks
B- 15 Weeks
C- 30Weeks
D- 90Weeks
Ans: A

296 Which of the following conditions can cause pulmonary hypoplasia in embryo
A- Diaphragmatichernia
B- Tracheoesophageal hernia
C- Respiratory distress syndrome
D- Skeletal deformaties
Ans: A

297 . Fetal CNS Appears at which week?
A- Beginning of 3rd week
B- Middle of 3rd week
C- End of 4th week
D- End of 5th week
Ans:A

298 Hb produced by yolk sac?
A- Gower
B- Portland
C- HbF
D- HbS
Ans:A

299 Terminal bronchioles Lung development in which phase?
A- Canalicular
B- Alveolar
C- Pseudocanalicular
D- none
Ans: A

300 Trigone of urinary bladder derived of which of following?
A- Endoderm
B- Mesonephric duct
C- Urogenital sinus
D- Neural crest cell
E- Neuroectoderm
Ans: B

Explanation:

- Bladder trigone from – Mesoderm or Mesoephric duct
- Bladder transitional epithelium from – Endoderm

301 A female pregnant lady presents in OPD having history of consuming alcohol during her pregnancy which of the following is potential side effect on baby (Medicine Feb 2025)
A- Risk of premature birth
B- No any effect of alcohol becoz it is not teratogenic
C- Alcohol only effects on the mother
D- Improved baby heath due to properties of alcohol
Ans: A

302 At which gestational week is nuchal translucency screening for Down syndrome typically performed? (Medicine Feb 2025)
A- 6–9 weeks
B- 10–14 weeks
C- 15–18 weeks
D- 20–24 weeks
Ans: B

303 A newborn presents with craniosynostosis, midface hypoplasia, and a high-arched palate. Which additional feature is most commonly associated with this condition? (Medicine Feb 2025)
A- Clubfoot
B- Syndactyly
C- Cleft lip
D- Polydactyly
Ans:B

304 Phocomelia is a congenital anomaly characterized by (Medicine Feb 2025)
A- Presence of flipper-like limbs
B- Fusion of limbs
C- Absence of limbs
D- Shortenmg of limbs
Ans: C

305 Hand-foot-genital syndrome is a rare genetic disorder characterized by: (Medicine Feb 2025)
A- Regression of the hand
B- Polydactyly of the hand
C- Syndactyly of the hand
D- Clubfoot
Ans: A

306 Which embryological remnant contributes to the formation of the utricle? (Medicine Feb 2025)
A) Septum transversum remnant
B) Wolffian duct remnant
C) Ureteric bud remnant
D) Müllerian duct remnant
Ans: D

307 Warfarin is widely use as anticoagulant, but it is teratogenic and can cause significant fetal malformation ,if taken during pregnancy what will be the teratogenic effect on the fetus: (Medicine Feb 2025)
A- Microcephaly
B- Cleft palate
C- Amelia
D- Nasal hypoplasia
Ans: D

Explanation:
Warfarin effects on fetus

- Nasal hypoplasia, agenesis corpus callosum, fetal bleeding, and death

308 During an anomaly scan, a fetus is noted to have prominent lateral ventricles, raising suspicion for a neural tube defect. Closure of the neuropore typically occurs on which day of fetal development? (Surgery Feb 2025)
A) Day 32
B) Day 28
C) Day 25
D) Day 30
Ans: B

309 Human chorionic gonadotropin (hCG) is primarily produced by which of the following embryological structures? (Surgery Feb 2025)
A) Decidua basalis
B) Ectoderm
C) Cytotrophoblast
D) Syncytiotrophoblast
E) Mesoderm
Ans: D

310 A 36-week pregnant woman develops deep vein thrombosis (DVT) and later suffers from left-sided hemiplegia. Which congenital anomaly is most likely present in the fetus?(Gynae & Obs Feb 2025)
A- Ventricular Septal Defect (VSD)
B- Secondum Atrial Septal Defect (ASD)
C- Primitive Atrial Septal Defect (ASD)
D- Patent Ductus Arteriosus (PDA)
E- Tetralogy of Fallot (TOF)
Ans: B

311 Why Diethylstilboestrol (DES) is contraindicated in pregnancy?(Gynae & Obs Feb 2025)
A- It can lead to feminization of male foetus
B- Cause miscarriage
C- Causes cervical cancer
D- Causes vaginal carcinoma
Ans: D

312 Atwhich week of embryonic development does the herniated intestinal loop return to the abdominal cavity? (Gynae & Obs Feb 2025)
A- 6th to 10week
B- 8th to 12 week
C- 10th to 14week
D- After 12th week
Ans:C

313 CT of a fetus shows one large ventricle with fused thalami. The defect most likely lies in which embryological structure? (Radiology Feb 2025)
A) Prosencephalon
B) Mesencephalon
C) Diencephalon
D) Diencephalon
Ans: A

314 Epispadias can be diagnosed on physical examination by:(Anesthesia Feb2025)
A- abnormal urogenital folds causing penis to look like a labia majora
B- bifid penis
C- urethral opening on the upper side of penis
D- urethral opening on the Lower side of penis
Ans:C

315 Which vitamin other than folate is thought to be responsible for NTDs: (Anesthesia Feb 2025)
A. Vitamin B12
B. Vit A Def
C. Vit A excess
D. Vit D Def
E. Vit D excess
Ans:A

CamScanner

HISTOLOGY QUICK HINTS

Simple Epithelium

Simple Squmous
- ✓ Line blood vessel(Endothelium)
- ✓ Line serous membrane i.e pericardium and peritoneum (Mesothelium)
- ✓ Corneal endothelium
- ✓ Lymph vessel
- ✓ Alveoli(Type 1 pneumocytes)
- ✓ Parietal layer of bowman capsule
- ✓ Loop of henely

Simple cuboidal
- ✓ Ovary
- ✓ Thyroid follicle
- ✓ Chroid plexus
- ✓ Pigment layer of retina
- ✓ PCT(Extensive brush border) DCT and CD
- ✓ Aveolar ducts and sacs
- ✓ Terminal and respiratory brinchioles

Simple Columnar
- ✓ Pre terminal bronchioles
- ✓ Uterus

Cilliated
- ✓ Fallopian Tubes

Non cilliated
- ✓ GIT(Stomach, Gall bladder and intestine)
- ✓ Rectum
- ✓ Endocervix
- ✓ Efferent ductules and ejaculatory ducts

Pseudostratified

Cilliated
- ✓ Nasal cavity and Nasopharynx
- ✓ Laryux (False vocal cords)
- ✓ Primary bronchi
- ✓ Trachea

Non Cilliated
- ✓ Membranous and penile urethra
- ✓ Prostate
- ✓ Ductus deference
- ✓ Epidydmis
- ✓ Seminal vesicle

Stratified Epithelium

Stratified SqumousKeratinized(Dry)
- ✓ Skin
- ✓ Dorsum tongue and Gingiva
- ✓ Lingual and Palatine tonsil
- ✓ Labia majora
- ✓ Anus(Below Hilton line)

Stratified Squmous non Keratinized(Moist)
- ✓ Mouth
- ✓ Orophaynx

- ✓ Esophagous
- ✓ Larynx(True Vocal Cords)
- ✓ Vagina
- ✓ Female urethra
- ✓ Corneal Epithelium
- ✓ Ectocervix
- ✓ Anus(Above Hilton line)

Stratified Cuboidal
- ✓ Lining duct of Sweat gland
- ✓ Mammary gland
- ✓ Ovarian follicle(Developing)

Stratified Columnar
- ✓ Bulbar and FornealConjuctiva
- ✓ Lining duct of Salivary gland

Transitional epithelium
- ✓ Renal Calcyces and Renal pelvis
- ✓ Prostatic urethra
- ✓ Ureter and Urinary bladder

SLIVARY GLANDS

Parotid
- Serous
- Thick capsule
- Ducts long and wide
- Acidophilic

Submandibular
- Mixed
- Have capsule
- Ducts short and narrow

Sublingual
- Mucinous
- Lacks capsule
- Basophillic
- Ducts absent

Random
- ✓ Lymphoid Tissue and Simple Cuboidal Epithelium – Payer patches
- ✓ Lymphoid Tissue and Stratified Squmous Epithelium – Palatine Tonsil
- ✓ Lingual and Palatine tonsil - Stratified Squmous epithelium
- ✓ Tubal Tonsil - PsuedostratifiedCilliated Columnar(Nasopharyngeal Cilliated)
- ✓ Adenoid or pharyngeal tonsil-PseudostratifiedCilliated Columnar respiratory epithelium
- ✓ Strong Layer of bowel is Submucosa
- ✓ Vagma lamia propria has rich Elastic tissues
- ✓ Ureter is star shaped and has Transitional epithelium
- ✓ Basophillia of cell due to ribosomes > RER
- ✓ Columnar epithelium + Clypts – Uterus
- ✓ Columnar epithelium + Cleft – Falloplan tube.
- ✓ Microtubules are part of centrioles
- ✓ Medullary rays present in Collecting tubules of cortex
- ✓ Epithileum changes due to state of activity– Thyroid
- ✓ Absent in axon hillock – RER

CamScanner

HISTOLOGY

1. Type of epithelium present in nasal vestibule?
A- Simple columnar
B- Stratified Columnar
C- Stratified Squamous
D- Non keratinised stratified squamous
E- Simple Cuboidal
Ans: C

2. An elderly obese patient with severe atherosclerosis developed acute abdominal pain, laparotomy was advised. On laparotomy small intestine will be identified with the help of which epithelial modifications?
A- Microvilli
B- Paneth Cells
C- M-Cells
D- Cilia
Ans: A

3. Regarding Cartilage:
A- Epiglottis is hyaline
B- Synovial Joint has fibrous cartilage
C- Appositional growth
D- Transitional growth
Ans: C

3- Clear cells on histology is which organ
A- Kidney
B- Lung
C- Liver
D- Brain
Ans: A

4- Transitional epithelium characteristic:
A- Dome Cells
B- Flat Cells
C- No change in cellular layer
D- Keratinized covering
Ans: A

5- Differeoce between Spleen and lymph node:
A- Arteriole
B- Splenic Sinusiods
C- APC
D- Afferent lymphatics
E- Splenic nodes
Ans: B

6- Eustachian tube epithelium is:
A- Pseudo stratified columnar ciliated
B- Pseudostraufied columnar with stereocilia
C- Simple cuboidal
D- Simple squamous
Ans: A

7- A histologicol section of a gland shows many acini lined with pseudostratified columnn arc pithelium embedded in stroma, with smooth muscle in it. What gland is dis? Histo
A- Prostate gland
B- Parotid gland
C- Submandibular gland
D- Seminal vesicle
E- Lacrimal gland
Ans: A

8- Which of the following structures contains no lymph nodes:
A- Palatine tonsils
B- Pharyngeal tonsils
C- Thymus
D- Spleen
Ans: C

9- Ewings sarcoma involves which of the followings:
A- Diaphysis
B- Metaphysis
C- Epiphysis
D- Epiphysial line
Ans: A

10- Which of the following has stratified cuboidal epithelium?
A- Ducts of Salivary Glands
B- Alveoli
C- Linings of Lungs
D- Esophagus
Ans: A
Explanation:
- Ducts of Salivary glands contain mainly columnar epithelium but stratified cuboidal epithelium can be found too.
- Stratified cuboidal epithelium specially found in the ducts of sweat glands.

11- Fibroblasts secrete which of the following:
A- Collagen Fibers
B- Elastin Fibers
C- Amorphous Ground Substance
D- Globulin
Ans: C
Explanation:
- Fibroblasts secrete amorphous ground substance.
- Fibrocartilage has collagen fibers

12- Which type of epithelium is present in stomach?
A- Stratified Squamous
B- Straufied Columnar
C- Simple Squamous
D- Simple columnar
E- Stratified cuboidal
Ans: D

13- Attachment of epithelium to basal membrane of gingiva by:
A- Desmosome
B- Hemidesmosome
C- Fibrillin
D- Myosin
Ans: B

14- Ureter epithelium is:
A- Transitiooal epithelium
B- Squamous epithelium
C- Simple Cuboidal Epithelium
D- Stratified squamous
Ans: A

15- Esophageal Varices are morphologically found in which layer of GIT:
A- Muscosa
B- Submucosa
C- Muscularis Externa
D- Serosa
Ans: B
Explanation:
- Esophageal varices are extremely dilated sub-mucosal veins in the lower third of the esophagus

16- Osteons are present in:
A- Spongy bone
B- Compact bone
C- Cartilages
D- Muscle Fibers
Ans: B
Explanation:
- Compact bone consists of closely packed osteons or harversian systems. The osteon consists of a central canal called the ostenic (Haversain) canal, which is surrounded by concentric rings (Lamellae) of matrix.

17- Lymphoid tissue covered with simple cuboidal epithelium is
A- Tubal Tonsil
B- Palatine Tonsil
C- Peyer's Patches
D- Appendix
Ans: C

18- Jugulodigastric lymph node drain
A- Palatine tonsil
B- Pharyngeal tonsil
C- Tubal tonsil
D- None of the above
Ans: A

19- About osteogenesis:
A- Newly laid uncalcified bone matrix is called Osteoid
B- Whole cartilage is replaced by bone
C- Articular surfaces covered by elastic cartilage
D- None of the above
Ans: A

20- Regarding histology of normal kidney:
A- Cuboidal epithelium in parietal layer of bowman capsule
B- Podocyte on visceral layer of bowman capsule
C- Dct longer then pct
D- Glomerolus has single arteriole
Ans: B

21- Reticular fibers are present in:
A- Dermis
B- Epidermis
C- Tonsils
D- Salivary Glands
Ans: C
Explanation:
- Tonsills> Dermis

22- A slide of a tissue taken from the oral cavity is viewed under the electron microscope and the substance shows acini and ducts, which structure is it?
A- Salivary gland
B- Pharyogeal tonsils
C- Palatine tonsils
D- Enamel
Ans: A

23- The strongest layer of the small intestine is?
A- Circular muscular layer
B- Mucosa
C- Sub mucosa
D- Serosa
E- Longitudinal layer
Ans: C

24- The presence of the small salivary glands is in which layer of oral mucosa?
A- Lamina rat
B- Lamina Propria
C- Lamina Lucida
D- Submucosa
Ans: D> B

25- Histology of Vagina:
A- Stratified columnar epithelium
B- Simple cuboidal epithelium
C- Stratified Squamous Epithelium
D- Simple Columnar Epithelium
E- Stratified cuboidal epithelium
Ans: C

26- Vagina has abundant:
A- Elastic Tissue
B- Elastic & Collagen Tissue
C- Hyaline Tissues
D- Hyaline & Elastic
Ans: A

CamScanner

27- Tubular structure with thick three layers of muscle; walls are Elastic and have adventitia around it. Which structure is this?
A- Vein
B- Muscular artery
C- Arteriole
D- Capillary
Ans: B

28- Stratified cuboidal epithelium is found in:
A- Ductsof sweat gland
B- Ducts of salivary gland
C- Vagina
D- Urethra
Ans: A

Explanatioa
- Stratified columnar epithelium -Salivary gland
- Stratified cuboidal epithelium - Sweat gland

29- Basophilia of cell due to
A- RER
B- SER
C- Nucleus
D- Cytoplasm
E- Mitochondria
Ans: A

Explanation
- Ribosomes > RER

30- Epithelium of oral surface of soft palate:
A- Stratified columnar epithelium
B- Stratified squamous non karatimzed epithelium
C- Stratified cuboidal epithelium
D- Pseudo stratified columnar epithelium
Ans: B

31- Epithelium of small intestine:
A- Simple columnar cilliated
B- Simple columnar non ciliated
C- Simple cuboidal
D- Simple squamous
E- Pseudostratified
Ans: B

32- Which of the following epitheljum is present on the surfaces of friction induced area and protect against mechanical injury
A- Stratified Squamous Keratinized
B- Stratified Squamous Non Keratinized
C- Stratified Columnar
D- Pseudostratified
E- Simple cuboidal
Ans: A

33- Corneal epithelium type:
A- Stratified squamous keratinized
B- Stratified squamous non keratinized
C- Simple columnar
D- Simple cuboidal
Ans: B

Explanation
- Corneal epithelium : Stratified squamous non - Keratinized
- Corneal endothelial : Simple squamous

34- Stratified squamous keratinized located in tongue on:
A- Fungiform papillae
B- Filliform papillae
C- Circumvellar papilloe
D- Foliate papillae
Ans: B

35- Clara cells present in:
A- Bronchi
B- Terminal Bronchioles
C- Primary bronchi
D- Primary bronchioles
E- alveolar duets
Ans: B

Explanation:
- Clara cells present in – Terminal bronchioles
- Goblet cells present in – Bronchi or Tertiary bronchus

36- Transitional epithelium of urinary bladder is derived from:
A- Endoderm
B- Ectoderm
C- Mesoderm
D- Endo-mesoderm
Ans: A

Explanation:
i. Trigone of bladder – Mesoderm
ii. Transition epithelium of Bladder - Endoderm

37- Which of the following lymphoid organ receives lymph via sub scapular sinus?
A- Tonsil
B- Lymph nodes
C- Spleen
D- Liver
Ans: B

38- Trachea is lined with:
A- Squamous epithelium
B- Pseudostraufied epithelium with goblet cells
C- Pseudostratified epithelium without goblet cells
D- Columoar epithelium
Ans: B

39- Pericytes are present in:
A- Liver
B- GBM
C- Blood vessels
D- Spleen
Ans: C

40- In inflammatory allergic nasal polyp what will be found on histology?
A- Eosinophils
B- Ciliated columnar epith
C- Squmous metaplasia
D- Anaplasia
Ans: A

41- Chromaffin cells tightly adhere in adrenal medulla?
A- Transitional
B- Mesothelium
C- Pseudostratified
D- Epitheloid cells
Ans: B

42- Histology shows abundant elastic tissue, non Keratinized stratified squamous epithelium but no mascularis mucosa . The most likely structure is
A- Hymen
B- Vagina
C- Uterus
D- Cervix
Ans: B

43- PCT epithelium
A- Stratified Columnar
B- Transitional
C- Simple Cuboidal
D- Simple Squmous
Ans: C

Explanation:
Simple cuboidal epithelium examples are
- Thyroid
- Terminal bronchioles
- Lens
- Pigment epithelium of retina
- PCT, DCT
- collecting ducts
- Ovaries
- Testes

44- Regarding Serous cells true is
A- Flat
B- Nuclei pushed to base
C- Eosinophilic granules
D- Basophilic granules
Ans: B>C

45- Histlogy shows tubular structure with pseudostratified epithelium and thick muscle wall. Most likely structure is:
A- Cervix
B- Ductus deferens
C- Prostate
D- Uterus
Ans: B

46- Lymphocytes from blood enter lymph node by:
A- Pericapilaryvenul and medulla
B- Efferent suc capsularis sinus
C- By filtration process
D- Subscapular afferent lymphatic channel
Ans: D

47- Most likely Histological feature of the compact bone is:
A- Most osteon are oriented in the long axis of the bone
B- Circumferential lamella form the osteon around the central canal
C- Haversian canals are obliquely oriented
D- All
Ans: B

48- Hyaline cartilage present in
A- Thyroid
B- Glenoid labrum
C- Ear pinna
D- Epiglottis
E- External auditory tube
Ans A

49- In chronic smoker what logical finding youwill observe in the lung?
A. Neutrophilia
B. Dec. elastase
C. Inc. collagen
D. Eosionophilia
Ans: A

Explanation:
- Neutrophilia
- Increase Ela
- Decrease alpha 1 antitrypsin

50- Pure mucinous glands are:
A- Submandibular
B- Sublingual
C- Parotid
D- Adrenal glands
E- Pineal glands
Ans: B

51- The GIT epithileum regenerates after how machtime
A- Ito 2 days
B- 2to 3 days
C- 3 to 7 days
D- 7 to 8 days
E- 9to 10 days
Aas C

52- Histological slide of salivary glands showing serous acini with mucinous acini, diagnosis is
A- Sub mandibular
B- Parotid
C- Lacrimal gland
D- Adrenal
Ans A

53- Absence of cartilage in respiratory and terminal ducts differentiates it from:
A- Conducting bronchioles
B- Terminal bronchioles
C- Trachea
D- None
Ans: C

54- Child with soft tissue tumor, in histology vimentin positive. Diagnosis is
A- Medulloblastoma
B- Ependymoma
C- Rhabdomyosarcoma
D- Leiyomyoma
Ans: C

55- Epithileum of skin
A- Stratified squamous Keratinized epithelium
B- Stratified squamous non Keratinized epithelium
C- Stratified cuboidal epithelium
D- Stratified columnar epithelium
E- Transitional epithileum
Ans A

56- Epithelium of conjuctiva
A- Stratified squamous Keratinized epithelium
B- Stratified squamous non Keratinized epithelium
C- Stratified cuboidal epithelium
D- Stratified columnar epithelium
E- Transitional epithileum
Ans D

57- Epithilcum of lingual tonsils
A- Stratified squamous Keratinized epithelium
B- Stratified squamous non Keratinized epithelium
C- Stratified cuboidal epithelium
D- Stratified columnar epithelium
E- Transitional epithileum
Ans: A

58- Pure serous glands are:
A- Submandibular
B- Sublingual
C- Parotid
D- Adrenal glands
E- Pineal glands
Ans: C

59- A structure having columnar epithelium with clefts in it and smooth muscle fibers
A- Body of uterus
B- Ovary
C- Cervix
D- Vagina
E- Fallopian tubes
Ans: E

60- Epithelium of pre-terminal bronchioles?
A- Pseudostratified squamous
B- Simple squamous epithelium
C- Simple cuboidal epithelium
D- Simple columnar epithelium
Ans: D

61- In histology slide serous acini with stratified epithelium in ducts seen in:
A- Parotid gland
B- Lacrimal gland
C- Sublingual gland
D- Sub mandibular gland
Ans: B

62- Pseudostratified columnar epithelium with cilia is present in
A- Esophagus
B- Pharynx
C- Trachea
D- Payerpatches
E- Larynx
Ans: C

63- No taste buds present on
A- Fungiformpapillae
B- Foliate papillae
C- Circumvallate papillae
D- Filliform papillae
A- Spongiform papillae
Ans: D

64- A patient presented after RTA, you are advised to make histology slide containing muscle fasciculus surrounded by connective tissue and the layer is termed as
A- Perimysium
B- Epimysium
C- Endomysium
D- Myofibril
E- Myocyte
Ans: A
Explanation:
- Epimysium – Enclose Entire muscle
- Endomysium – Enclose Single muscle fiber
- Perimysium – Enclose Bundle of muscle fiber (Fasciculus)
- Endoneurium – Individual nerve fiber
- Perineurium – Bundle of nerve fibers
- Epineurium – Entire nerve

65- Cilia is preseot in:
A- PCT
B- Stomach
C- Esophagus
D- Nasal vestibule
Ans: D

66- Abundant cilia present in:
A- Maxillary sinus
B- Fallopian tube
C- PCT
D- DCT
Ans: A

67- Which of following is connective tissue in brain?
A- Parietal Cells
B- Chief Cells
C- Peneath Cells
D- Oligodendiocytes
E- Basal Cells
Ans: D

68- Pars aervosa supporting cells:
A- Oligodendrocytes
B- Pituicytes
C- Kupfer cells
D- Astrocytes
Ans: B

69- Patient suffering from cervix pathology, pap smear done. And it showed desmoplasia. Characteristic of desmoplasia is
A- Proliferation of glands in connective tissue
B- Proliferation of smooth muscles in Connective tissue
C- Change in size and shape of cells
D- Change in polarity of cells
E- Proliferation of skeletal muscles in connective tissue
Ans: B

70- Absorption of fluid from intestinal epithelium depend upon
A- Sodium
B- Potassium
C- Sodium & glucose combined
D- Potassium & glucose combine
E- Paracellular junction
Ans: E

71- A patient has LRTI for many days. On histology of respiratory tree which of the following will be damaged?
A- Microvilli
B- Cilia
C- Plasmalemma Protein
D- Desmosome
E- Hemidesmosome
Ans: B

72- What type of epithelium has dome shaped cells on the apical surface?
A- Epitheloid tissue
B- Mesothelium
C- Endothelium
D- Pseudostratified
E- Transitional
Ans: E

73- Olfactory neurons are:
A- Non adapting
B- Slow adapting
C- Rapid adapting
D- Non Dividing
Ans: C

74- Mass of lymphoid tissues are covered with simple squmous epithelium is:
A- Palatine tonsil
B- Lingual tonsil
C- Payer patches
D- None
Ans: A
Explanation:
- Lymphoid Tissue and Simple Cuboidal
- Epithelium – Payer patches
- Lymphoid Tissue and Simple Squamous
- Epithelium – Palatine Tonsil

75- Condenser lense in light microscope
A- Present between object and eye piece histology
B- Magnify the object
C- Magnify eye piece
D- Concentre light into cone light onto Specimen
Ans: D

76- Histology of a slide shows serous acini in connective tissue and duct this is related to
A- Tonsil
B- Sweat gland
C- Salivary glands
D- Pharynx
E- Larynx
Ans: C

77- Tubular structure with Small lumen and transitional epithelium with 3 layers of smooth muscle and Outer well developed adventitia related to
A- Ureter
B- Ilium
C- Bladder
D- Appendix
E- Fallopian tube
Ans: A

CamScanner

Explanation:
Ureter has 3 layers
- Tunica mucosa(Inner)
- Transitional epithelium
- Lamina propria of Connective tissue
- Upper 2/3rd
- Inner longitudinal
- Outer circular

Lower 1/3rd
1-Tunica muscularis(Middle)
- Inner longitudinal layer
- outer longitudinal layer
- Middle layer Circular

2-Tunica Serosa/Adventitia(Outer)
3-Thick adventitia

78- Stratified squamous epithelium is present in??
A- Nasopharynx
B- Subglottis
C- Trachea
D- Epithelium of parotid duct
Ans: D

Explanation:
- Nasophaymx -Pseudostratified
- Oropharynx -Stratified
- Epiglottis -Stratified
- Subglottis -Pseudostratified
- Trachea -Pseudostratified
- Duct of parotid glands - Stratified
- Organ lined by stratified squamous

79- A patient presented with abdominal pain. On endoscopy lesion found and loss of epithelium this is
A- Abscess
B- Ulcer
C- Edema
D- Inflammation
Ans: B

80- True regarding sweat gland:
A- Tubular structure
B- Absent in palms and soles
C- Stratified cuboidal epithelium
D- Sympathetic nicotonic and muscarinic receptors
Ans: A>C

81- Terminal bronchioles contain:
A- Clara cells
B- Goblet cells
C- M cells
D- Kulchitsky cells
Ans: A

Explanation:
- Clara cells present in – Terminal bronchioles
- Goblet cells present in – Bronchi or Tertiary bronchus

82- Histology of Macula densa is:
A- Flat cells
B- Columnar cells of afferent tubules
C- Dense Cuboidal Cells in PCT
D- Cuboidal cells in efferent tubules
E- Squamous cells in Periphery
Ans: B

83- Which intercellular junction is like a spot held between cell and the basement?
A- Hemi desmosome
B- Adhering junction
C- Desmosome
D- Gap junction
E- Tight junction
Ans: A

84- Example of non-keratinized stratified squamous tissue:
A- Trachea
B- Vagina
C- Male urethra
D- Sweat glands
E- Salivary glands
Ans: B

85- Hymen epithelium is lined by:
A- Simple cuboidal
B- Stratified columnar
C- Stratified squmous
D- Stratified cuboidal
Ans: C

86- Vagina epithelium is stratified squamous epithelium what is present along with it?
A- Collagen fibers
B- Highly elastic fibers and lamina propria
C- Propria and adventitia
D- Propria and Collagen
E- Elastic and Adevntia with collagen
Ans: B

87- Sinusoids in liver are lined by:
A- Endothelium with basal lamina
B- Venous Sinusoids
C- Simple squamous epithelium
D- Discontinued fenestrations and endothelium
E- Basement membrane
Ans: D

88- Tight cell of Adrenal gland parenchyma related to which of these:
A- Mesothelium
B- Ectodermal
C- Endothelium
D- Neuroderm
Ans: A

89- Histology slide shows drop shaped rete-ridges, nuclear hyperchromatism, nuclear pleomorphism- loss of polarity and areas of invasion by the malignant epithelial cells. The most likely diagnosis is
A- Squamous cell CA
B- Verrocous CA
C- Basal cell carcinoma
D- Transitional cell carcinoma
Ans: B

90- Goblet cells convert in to clara cells at:
A- Nasopharynx
B- Trachea
C- Bronchi
D- Terminal bronchioles
E- Larynx
Ans: D

91- Transitional epithelium characteristic is:
A- Superficial cells Dome shaped appearance
B- Flat Cells
C- No change in cellular layer
D- Keratinized covering
Ans: A

92- Regarding esophagous epithelium true is:
A- Upper 1/3rd has both striated and smooth
B- Entire esophagus has stratified sequmous
C- Upper 1/3rd has columnar
D- None
Ans: B

93- Which portion of upper GI tract has inner circular and outer longitudinal layers of smooth muscle and skeletal muscle respectively
A- Upper esophagus
B- Middle esophagus
C- Lower esophagus
D- Stomach
E- Gastroesophageal junction
Ans: B

94- Biopsy of specimen CA showing fibro vascular septa, and scattered cleilicntions giving like sand grain appearance. Which tissue most likely it is?
A- Lung
B- Colon
C- Breast tissue
D- Thyroid
Ans: C

95- Trachea epithelium is:
A- Pseudo stratified columnar ciliated
B- Pseudostratified columnar with stereocilia
C- Simple cuboidal
D- Simple squamous
Ans: A

96- Inverted papilloma histology finding will be:
A- Acanthosis keratosis
B- Invade basement membrane
C- Invade stroma
D- Parakeratosis
Ans: A

97- In a patient of GERD stomach biopsy done which muscles will be seen:
A- Striated
B- Oblique
C- Smooth
D- Active
Ans: C

98- On cross section of Seminiferous tubules you see:
A- Oval dead sperms
B- Wedge shaped arrangement of developing sperms
C- Round immotile sperms
D- Oval developed Sperms
Ans: B

99- Liver capsule histology show:
A- Loose connective tissue
B- Reticular tissue
C- Dense irregular connective tissue
D- False tissue
Ans: C

100- Which cells from dermis which digest, mobile and carry it to lymph:
A- Melanocytes
B- Merkel cells
C- Germinal cells
D- Basal cells
E- Langerhans cells
Ans: D

101- A woman had a polyp in the cervix. It was removed and histopathology showed a portion of the polyp covered by squamous epithelium. The change is:
A- Anaplasia
B- Hypertrophy
C- Metaplasia
D- Hyperplasia
E- Dysplasia
Ans: C

102- Cervix has squamous epithelium this is due to:
A- Anaplasia
B- Dysplasia
C- Metaplasia
D- Atrophy
E- Desmoplasia
Ans: C

103- Lung tissue is damaged having will contain:
A- Histiocytes
B- Dust cell
C- Dendritic cell
D- Histamine
E- Neutrophil
Ans: B

104- Spleen engulfs dead red and white cells by:
A- Red Pulp
B- White Pulp
C- Marginal Zone
D- Arterioles
Ans: A

CamScanner

Explanation:

- Splenic (immunological) function: White pulp
- Splenic (immunological) filtration: Red pulp
- APC portion of spleen: Marginal zone

105- Ectodermal dysplasia. Characteristic of the structure that will be affected?

A- More in palms and soles
B- Has stratified keratinized squamous epithelium
C- is thin in structure
D- Has tubular structure
Ans: B

106- A student observing a histology slide of a slide tubular structure with thick vascular wall and pseudo stratified epithelium most likely the slide is of which structure?

A- Seminiferous tubules
B- Epididymis
C- Ureter
D- Cervix
E- Vasdeferens
Ans: E

107- True regarding smooth muscle?

A- Striated
B- Multipinnate
C- Multinucleated
D- Don't fatigue
E- Can't sustain prolong and slow contraction
Ans: D

108. Artery layer from inner to outside is:

A- Tunica media, Intima and Adventitia
B- Tunica intima, media and adventitia
C- Tunica adventitia, media and intima
D- Tunica Medial, adventitia and intima
Ans: B

109- Difference between smooth and striated muscle is:

A- Desmin
B- Myosin
C- Ca-Calmodulin complex
D- Calcequestrin
Ans: C

Explanation:

- Common feature between smooth and skeletal muscle - Increase intracellular Ca before contraction
- Common feature between cardiac and skeletal muscle - Transverse striation
- Difference between Skeletal and smooth muscle - Ca Calmodulin complex in Smooth muscle
- Smooth muscles cause Slow sustained prolong contraction
- Cardiac muscle don't get tetanized because of long refractory period
- Smooth muscle has inner circular and outer longitudinal layer
- Common muscle contraction protein in Smooth muscle and skeletal muscle-Actin

110- Kidney consists of outer cortex and inner medulla from which epithelium renal parenchyma is formed?

A- Neurodermn
B- Ectodermal
C- Endothelium
D- Mesothelium
Ans: D

111- Ovary surface epithelium is lined by:

A- Simple cuboidal
B- Stratified columnar
C- Stratified squamous
D- Stratified cuboidal
Ans: A

112- Stratified squamous non-keratinized epithelium, abundant vessels and thick lamina propria with no glands, tissue is:

A- Vagina
B- Uterus
C- Faliopian tube
D- Cervix
E- Ureter
Ans: A

113- Epithelium of salivary gland derived from

A- Ectoderm
B- Endoderm
C- Mesoderm
D- Mesenchyme
Ans: A

114- Patient finger cut doctor told him not to be worried as all will be fine due to regeneration by:

A- Stratum Spinosum
B- Stratum Basale
C- Stratum granulosum
D- Stratum lucidum
Ans: B

115- Ductus deference different from others By:

A- Thick muscular 3 layers
B- Ciliated columnar epithelium
C- Non ciliated epithelium
D- Thin layer of muscles
Ans: A

116- Regarding pseudostratified epithelium:

A- All nuclei are at the same level
B- All cells are of same size
C- Composed of at least 2 layers of cells
D- All cells reach the same level
E- All cells reach basement Membrane
Ans: C

117- Histology slide shows drop shaped rete-ridges, nuclear hyperchromatism, nuclear pleomorphism. loss of polarity and areas of invasion by the malignant epithelial cells. The most likely diagnosis is

A- Squamous cell CA
B- Verrucous CA
C- Basal cell carcinoma
D- transitional cell carcinoma
Ans: B

118- Proerythrocyte have basophilia due to

A- Polyribosomes
B- Heparin & Histamine
C- Mitochondria
D- SER
Ans: A

119- Tightly compact cells of adrenal gland parenchyma with no surface exposed related to which of these?

A- Pseudostratified Epithelium
B- Ectoderm
C- Endothelium
D- Mesothelium
E- Transitional Epithelium
Ans: D

120. Histology slide shows Double layer Cuboidal epithelium on the basement membrane is characteristic of which of the following

A- PCT
B- DCT
C- Collecting tubules
D- Ducts of salivary glands
Ans: D

121- A patient histopathology report showing pleomorphism rete ridges loss of polarity and increased nuclear to cytoplasmic ratio what is diagnose?

A- Squamous cell Carcinoma
B- Verrucous Carcinoma
C- Teratoma
D- Adenocarcinoma
E- Bronchogenic Carcinoma
Ans: B

Verrucous carcinoma	Squamous cell carcinoma
Epithelium seldom shows dysplastic features	Epithelium shows high dysplasia
Elephant foot like rete ridges is seen	Elephant foot like rete ridges is not seen
Parakeratin plugging is present	Parakeratin plugging is usually absent Keratin pearls are seen
Breach in the basement membrane is absent	Breach in the basement membrane is present
Islands of dysplastic epithelium are not seen in connective tissue	Islands of dysplastic epithelium are seen in connective tissue

122- Unknown tissue on histology examination shows dense fibrovascular structure & multiple layers of mesothelium. Which tissue it could be?

A- Lung
B- Colon
C- Breast tissue
D- Thyoid
E- Intestinal stroma
Ans: A

123- On histology how would you differentiate PCT from DCT

A- Thicker and more pronounced brush Border
B- Thicker basement membrane in the DCT
C- Thicker Basement Membrane in the PCT
D- DCT has pores
E- PCT absorbs more water
Ans: A

124- A patient presented with complain of Weight loss, Heat intolerance & Diarrhea on & off. On microscopy, 2 layers of Tall crowded columnar cells with atypical nuclei over basement membrane seen. Most probable diagnosis?

A- Hurthle Cell Adenoma
B- Thyroid Adenoma
C- Colloid filled follicles
D- Thyroiditis
Ans: B

125- lymphocytes arrange in epithelial sheets in which of the following organ(Medicine Feb 2025)

A- Stomach
B- Thymus
C- Lymph node
D- Pancreas
E- Spleen
Ans: B

CamScanner

126- A structure of oral cavity with acini and lobales like arrangement with abundant connective tissue? (Medicine Feb 2025)
A- Salivary glands
B- Pharyngealtonsils
C- Muscles
D- Sweatglands
E- Larynx
Ans: A

127- On microscopy, high basal infoldings are observed in a structure associated with abundant transport activity.Which of the following structures is most likely responsible for this feature?(Medicine Feb 2025)
A- Microvilli
B- Cilia
C- Exocrine glands
D- Endocrine glands
E- Na^+/K^+ pump
Ans: A

128. Following epilhelfum has no basement membrane: (Sugery Feb 2025)
A- Ependyma
B- Transitional epnhelium
C- Squamous Epithelium
D- Columnar Epithelium
Aas: A

129- Longitudinal striation are seen on microscopy in: (Sugery Feb 2025)
A- Basal laminae
B- Reticular fibers
C- Elastic fibers
D- Fibroblast
E- Collagen fibers
Ans: E
Explanation:
Lamellar appearance-Elastic
Longitudinal appearance-Collagen

130- Pigment deposit in which layer of epithellum(Gynae & Ohs Feb 2025)
A- Stratum corneum
B- Straium basal
C- Stratum lucidum
D- Stratun spinosum
Ans: B

131- In a patient diagnosed with steatohepatitis, which of the folluwing histological findings is most characteristic in liver cells? (Radiology Feb 2025)
A- Bilirubin deposits
B- Fatty acid accumulation
C- Glycogen inclusions
D- Protein aggregates
Ans: B

132- Patient undergo Barium swallow & small appearance in left abdomen feature of which of these?(Radiology Feb 2025)
A- Jejunum
B- Ileum
C- Stomach
D- Gall bladder
Ans: A

133- A patient underwent oophorectomy and was found to have salpingitis on examination. What is the epithelium of the affected organ? (Radiology Feb 2025)
A - Simple columnar ciliated
B - Simple columnar non-ciliated
C - Simple cuboidal
D - Stratified epithelium
Ans: A

GENERAL ANATOMY QUICK HINTS

Skeletal Muscle classification

A) Parallel Muscles
1)Quadrangular muscles
- ✓ Four equal side present
- ✓ E.g Gluteus maximus, Thyrohyoid and Hypoglossus

2)Strap musclex
- ✓ e.gSartorius , Sternohyoid and infrahyoid

3)Strap with tendinous insertion
- ✓ e.g Rectus abdominus

4)Fusiform muscles
- ✓ Spindle shaped
- ✓ e.g Bicep brachi, Palmaris longus Brachioradialis and Digastic belly

B)Oblique Museles
1)Triangular muscles
- ✓ e.gPactoralismajor , Adductor longus and magous

2)Circular muscles
- ✓ e.g Orbicularis oculu and oris

3)Pennate muscles
- ✓ Feather like

a) Unipeonate
- ✓ Flexor pollicis longus ,Solues and Tibialis posterior

b) Bipennate
- ✓ e.g Rectus femoris and dorsal interossiae

c)Multipeonate(Strongest)
- ✓ e.g Deltoid and Subscapularis

d)Circumpennate
- ✓ e.g Tibialis Anterior

By Action Classification

1)Prime Mover
- ✓ Active in imitation and maintenance
- ✓ Quadricep in Extension of knee joint
- ✓ Brachialis in Flexion of elbow joint

2)Antagonist
- ✓ It opposes the action when prime mover contract
- ✓ Bicep femoris opposes action of quadricep

3)Synergistic
- ✓ Nullify unwanted effect prime mover
- ✓ e.g Deltoid during abduction

4)Fixator
- ✓ Stabalize the position of Joint to move prime mover
- ✓ e.g Rotator cuff muscles help in stabalization of head of humerus in glenoid cavity helping trapezius to cause overhead abduction

Bone Classification

Long bone
- ✓ Clavicle , Femur , Tibia and Humerus

Short bone
- ✓ Eight Carpals
- ✓ Seven Tarsals

Long -Short bone
- ✓ Meta Carpal , Meta tarsal

CamScanner

Flat bone
- ✓ Scapula , Skull ,Sternum and Ribs

Irregular bone
- ✓ Vertebrae , Hip bone ,Maxillary and Zygomatic

Sesamoid bone
- ✓ Patella and pissi form

Pneumatic bone
- ✓ Frontal , Ethmoidal ,Sphenoid , Maxillary and Facial bones

Accessory bone
- ✓ Cervical rib

Joint Classification

1)Fibrous Joint
- ✓ Where bones are seprated only by connective tissue and very limited movement occur
- ✓ **a)Suture(Synarthrosis)** - Immovable
- ✓ b)Gomphosis -Mandiible and maxilla(Teeth and Socket joint)
- ✓ c)Syndesmosis(Amplarthrosis) -Slightly moveablee.g Inferior Tibio fibular joint and Middle radio ulnar joint

2)Cartilagenous joint

Primary cartilagenous joint (Synchondrosis)
- ✓ Where byaline cartilage and bone meets
- ✓ Present in developing axial skeleton- Temporary +Immovable e.g
- ✓ 1st Sternocostal joint
- ✓ Sphenooccipital joint
- ✓ Costochondral joint
- ✓ Between epiphysis and Diaphysis oflong bone

Secondary cartilageoousjoiot (Symphysis)
- ✓ Where articular surface covered by Hyaline lamina and fibrocartilage in between
- ✓ Present in axial bone and Sacrococygeal bonee.g
- ✓ Intervertebraldiscs
- ✓ Symphysis pubis
- ✓ Manubriosternaljoint

3)Synovial Joint
- ✓ Diarthrosis-Highly movable
- ✓ **Synovial ball and socket joint** – Shoulder jomt
- ✓ Synovial hinge joint – Elbow and Interpharyngeal jomt
- ✓ Synovial pivot Joint - Superior and inferior radioulnar
- ✓ Synovial condyloid joint – Wrist and Metacarpophalangeal joint
- ✓ Synovial saddle Joint - Carpometacarpal joint

Ossification

Intramembranous
- ✓ Embryonic mesenchyme -Bone tissue

Examples
- ✓ Clavicle
- ✓ Bones of face(Maxilla ,Zygomatic ,Nasal , Lacrimal and Vomer)
- ✓ Bones of vault of skull(Frontal , Parietal)
- ✓ Subperiosteal bones

Intracartilagenous
- ✓ Mesenchymatous sheath
- ✓ Ethmoid and Inferior nasal concha
- ✓ All short bones
- ✓ All long bones except Clavicle
- ✓ Irregular bone

Membranous -Cartilagenous
- ✓ Mandible ,Temporal ,Occipital & Sphenoid

Ossification Centres

Diaphysis (Shaft-Primary)
- ✓ 8th week of intrauterine life to 10 weeks after birth
- ✓ e.gCarpals , Tarsal and Ear ossicle

Epiphysis (End-Secondary)
- ✓ At the age of 1 or 2 year
- ✓ Esception - Lower end of femur which is present at birth

a) Pressure Epiphysis -Articular end of all bones
b) Traction EpiphysisTubcrosities of humerus&Trochanteries of Femur
c)Atavistic EpiphysisMedial end of Clavicle&Coracoid process of Scapula

Metaphysis
- ✓ Active growing part of shaft close to epiphyseal cartilage

Cartilages

Elastic Cartilage
- ✓ Ear pinna +Epiglottis +External auditory tube

Fibrocartilage
- ✓ Intervertebral disc +Menisci of knee +Acetabulum and Glenoid labrum

Hyaline Cartilage
- ✓ Larynx +Trachea +Nasal cartilage +Costal +Articular cartilage
- ✓ Cricoid +Thyroid and Arytenoid

Sesamoid Cartilage
- ✓ Present in Ala of nose>Larynx

Random
- ✓ **Epimysium** – Enclose Entire muscle
- ✓ **Endomysium** – Enclose Single musclefiber
- ✓ **Perimysium** – Enclose Bundle of musclefiber (Fasciculus)
- ✓ **Endoneurium** – Individual nerve fiber
- ✓ **Perineurium** – Bundle ofnerve fibers
- ✓ **Epineurium** – Entire nerve
- ✓ Sympathetic preganglionic fibers innervate all except – Sekeltalmuscles
- ✓ Fibroblast Secrete – Amorphous Ground Substance
- ✓ Fibrocartilage has – Rich Collagen
- ✓ Tubular structure with three layer thick muscle and adventitia andinternal lamina - Muscular artery
- ✓ Structure with smooth muscles longitudinally arrange in adventitia –Large Size Vein
- ✓ Difference between epiphysis of boys and girls is – 3 years
- ✓ Linear growth of bone is affected if following structure is fractured - Epiphyseal plate
- ✓ Cartilage is – Avascular
- ✓ AV anastomosis occurs in all except – Brain
- ✓ muscle attached to more than one joint and prevents the excessive movement of proximal joint is- fixator
- ✓ Sabaceous glands are derived from - Root of hair follicle
- ✓ End artery present in - Central retinal artery > Spleen > Heart
- ✓ True End artery /Anatomical – Retinal artery
- ✓ Functional end Artery – Heart
- ✓ Small blood vessels in the wall ofblood vessels are called– Vasa vasorum
- ✓ Zone of veil is rich in - Fibroblasts
- ✓ Pin point depression on the surface of bone is - Fovea
- ✓ Bunion – bony hump that forms on the joint of base of toe
- ✓ Inion – Posteroinferior part of the Occipital bone on the external surface
- ✓ Ischio-pubie ramus fuse at the age of - 14 years
- ✓ Two types of ossification seen in – Mandible
- ✓ Not a modification of deep fascia - Platysma

CamScanner

GENERAL ANATOMY

1- Type of cartilage in costal cartilage:
A- Hyaline cartilage
B- Elastic cartilage
C- Fibrocartilage
D- Articular
E- Saddle
Ans: A

2- About bone what is true?
A- Osteoblasts in how ships lacunae
B- Appositional growth
C- Alakaline Phosphatase released by Osteoclast
D- Intramembranous ossification by cartilage model
E- Osteocyte form bone
Ans: B

3- Secondary cartilaginous joint are lined by:
A- Hyaline cartilage
B- Bone
C- Fibrocartilage
D- Articular surfaces
E- Ligament
Ans: C

Explanation:
- Primary crtilagenous joint (Synchondrosis) – Hyaline cartilage
- Secondary Cartilagenous joint (Symphysis) - Fibrocartilage

4- Tubular structure with thick three layers of muscle; walls are Elastic and have adventitia and internal lamina around it. Which structure is this?
A- Venule
B- Muscular artery
C- Arteriole
D- Capillary
Ans: B

Explanation:
- Tubular structure with three layer thick muscle and adventitia and internal lamina – Muscular artery
- Structure with smooth muscles longitudinally arrange in adventitia – Large Size Vein

5- Manubrio sternal joint type is:
A- Primary cartilaginous
B- Secondary cartilaginous
C- Syndesmosis
D- Ball and socket
Ans: B

6- Scrotum drains in
A- Superficial inguinal lymph nodes
B- Internal iliac lymph nodes
C- Superior mesenteric lymph nodes
D- Paraaortic lymph nodes
E- Coeliac lymph nodes
Ans: A

Explanation
External iliac lymph nodes
Medial horizontal inguinal
a) Scrotum
b) Skin of penis
c) Uterus (internal + external > internal iliac > external iliac)
d) 1/3rd distal anal canal
Vertical superficial inguinal
a) Buttock
b) Medial leg
c) Thigh
d) Perineum
Internal illiac lymph nodes
- Cervix
- Uterus (internal + external > internal iliac > external iliac)
- Middle 1/3rd of vagina
- Lower part of rectum
- Urethra
- Prostate
- Penis deep structures
- Seminal vesicles

7- Body cavity divided into ventral and dorsal. Which one of these is the dorsal
A- Cranial
B- Abdominal
C- Thoracic
D- Pelvic
E- Abdonunopelvic
Ans: A

Explanation:
- Dorsal – Cranial and Spinal cavity
- Ventral – Thoracic, Abdominal, Pelvic cavity

8- Difference between epiphysis of boys and girls is:
A- 9Months
B- 3M
C- 1 year
D- 6M
E- 3 years
Ans: E

9- A muscle that is attached to more than one joint and prevents the excessive movement of proximal joint is called?
A- Primemover
B- Fixator
C- Agonist
D- Antagonist
Ans: B

10- Intervertebral disc joint is:
A- Symphysis joint
B- Secondary cartilngenous joint
C- Primary cartilagenous joint
D- Syndesmosis
Ans: B

Explanation:
Primary cartilagenous Joint
- 1st Sternocostal joint
- Between epiphysis and Diaphysis of long bone

Secondary cartilagenous Joint
- Intervtebral discs
- Symphysis pubis
- Manubriosternal joint

11- A man Crossing road he looks right then left side while driving car this movement caused by vertebrae having which type joint?
A- Pivot joint
B- Condyloid joint
C- Synovial joints
D- Biaxial ellipsoid
E- Uniaxial ellipsoid
Ans: A

Explanation:
- Atlanto axial joint: Right and left movement and No pattern movement (As we say No by shaking Head). It is pivot joint.
- Atlanto occipital Joint: Up and down movement and Yes pattern movement. It is Biaxial Synovial Ellipsoid joint.

12- Hyaline cartilage joins which of the following bones?
A- Chondrosternal
B- Manubriosternal
C- Symphysis pubis
D- Interverteberal
Ans: A

13- Sabaceous glands are derived from
A- Root of hair follicle
B- Shaft of hair follicle
C- Cortex of hair follicle
D- Cuticle of hair follicle
Ans: A

14- Tip of tongue drains in
A- Submental
B- Sub mandibular
C- Deep cervical
D- Superior mesenteric lymph nodes
Ans: A

Explanation:
- Tip of toogue – submental
- Ant 2/3rd – Submandibular
- Post 1/3rd – Deep cervical

15- Fibrocartilage is present in:
A- Primary cartilaginous joints
B- Larynx
C- Intervertebral disc
D- Epiglottis
E- Amorphous ground substance
Ans: C

Explanation:
- Fibroblast Secrete – Amorphous Ground Substance
- Fibrocartilage has – Rich Collagen
- Fibrocartilage present in -
a) Intervertebral disc
b) Glenoid labrum
c) Acetabular Labrum
d) Menisci of knee

16- Regarding primary cartilaginous joints true is:
A- Mobile
B- Present in appendicular skeleton
C- Covered by fibrous cartilage
D- Present in All joint
E- Permanent
Ans: B(Only suitable)

17- Sternocostal joint is:
A- Primary cartilelagenous
B- Secondary cartilaginous
C- Syndesmosis
D- Gomphosis
Ans: A

18- Kidney's lymph drainage in
A- Paraaortic
B- External iliac lymph nodes
C- Deep inguinal lymph nodes
D- Coeliac lymph nodes
E- Submandibular lymph nodes
Ans: A

19- Sesamoid cartilage is present in?
A- Larynx
B- Ala of nose
C- Vertebral space
D- Trachea
E- Ear
Ans: B>A

CamScanner

Explanation:
- Hyaline cartilage – Larynx + articular surfaces of Synovial joints + Trachea
- Elastic cartilage – Ear pinna, External Auditory meatus, Epiglottis
- Sesamoid cartilage – Ala of nose > Larynx
- Sesamoid bone – Patella

20- About synchondrosis what is true?
A- Joint cavity is present
B- Bone ends are covered by hyaline cartilage
C- Synovial joint
D- Cover by periosteum
E- Bones within muscle tissue
Ans: B

21- Lower 1/3rd of Oesophagus drains in
A- Deep cervical lymph nodes
B- Superior mediastinal lymph nodes
C- Posterior mediastinal lymph nodes
D- Celiac lymph nodes
Ans: D

Explanation:
- Upper 1/3rd – Deep cervical
- Middle 1/3rd – Superior and posterior mediastinal
- Lower 1/3rd – Celiac

22- Which is formed by membranocartilagenous ossification?
A- Frontal
B- Nasal
C- Occipital
D- Sphenoid
E- Zygomatic
Ans: D>C

23- The joint between first and second vertebrae is:
A- Pivot
B- Axial
C- Hinge
D- Ellipsoid
Ans: A

24- Cervical joints are which type of joints:
A- Pivot
B- Axial
C- Hinge
D- Synovial
Ans: D

25- Joint between the vertebral bodies is:
A- Primary cartilageous
B- Secondary cartilageous
C- Plane
D- Pivot
Ans: B

26- End arteries present in:
A- Central retinal artery
B- Heart
C- Spleen
D- Liver
Ans: A

Explanation:
- Overall – Central retinal artery > Spleen > Heart
- True End artery /Anatomical – Retinal artery
- Functional end Artery – Heart

27- Elastic cartilage present in:
A- Epiglottis
B- Trachea
C- Knee joint
D- Intervertebral discs
Ans: A

28- What are chondrocytes?
A- Part of Bone
B- Mature cartilage
C- Mature bone
D- Immature cartilage
Ans: B

29- Descending colon lymphatic drainage
A- Celiac
B- Superior mesenteric
C- Inferior mesenteric
D- Post mediastinal
Ans: C

Explanation:
- Stomach – Coeliac lymph nodes
- Duodenum – coeliac (upper part) + superior mesenteric (lower part)
- Jejunum – Superior mesenteric
- Ileum – Superior mesenteric
- Appendix – superior mesenteric
- Transverse colon – superior mesenteric (proximal 2/3rd) + inferior mesenteric (distal 1/3rd)
- Descending colon – inferior mesenteric
- Sigmoid colon – inferior mesenteric
- Gall bladder – Celiac
- Spleen – Celiac
- Pancreas – Celiac + superior mesenteric

30- In long bones from secondary center of ossification what is formed?
A- Epiphyseal plate
B- Epiphysis
C- Metaphysis
D- Diaphysis
Ans: B (Rd Last)

Explanation:
- Primary center form Diaphysis
- Secondary center from Epiphysis

31- Individual muscle fiber is wrapped into
A- Endomysium
B- Perimysium
C- Epimysium
D- Endoneurium
Ans: A

Regarding osteogenesis which is correct?
A- Osteoid formation
B- Membranous ossification model in cartilage bones
C- Osteocytes secrete alkaline phosphate
D- Osteoblast are multinucleated
E- Trabecula
Ans: A

Characteristic feature of cartilage:
A- Intramembranous ossification
B- Does not undergo maturation
C- Everywhere covered by Perichondrium
D- Contain abundant elastic fibers
Ans: C

Syndesmosis is a type of
A- Secondary cartilageous
B- Primary cartilageous
C- Fibrous
D- None
Ans: C

Explanation:
- Synchondrosis – Primary Catilagnous
- Symphysis – Secondary Cartilagnous joint

35- Which of the following is false about costovertebral joints?
A- Head of the rib is attached to one vertebra
B- Head is attached to international disc
C- Neck is attached to the tip of transverse process
D- Joint is covered by capsule
E- It is a synovial type joint
Ans: C (Tubercle of the rib is attached to the transverse process)

36- Intervertebral joint is of which type?
A- Elastic Joint
B- Hyaline Joint
C- Cartilaginous joint
D- Fibrous joint
Ans: C

37- Structure with longitudinal muscles in adventitia is?
A- Large sized vein
B- Muscular artery
C- Medium vein
D- Small size vein
Ans: A

38- Primary cartilaginous joint includes:
A- Symphysis Pubis
B- 1st chondrosternal
C- Vertebral
D- Interphalangeal
Ans: B

39- Zone of veil is rich in
A- Fibroblasts
B- Plexus of capillaries
C- Macrophages
D- Both fibroblasts and macrophages
Ans: A

40- In newborn long bone length increase due to:
A- Osteoblast
B- Primary epiphyseal plate
C- Appositional Growth on cartilaginous epiphyseal plate
D- Osteoclast
E- Osteophyte
Ans: C

41- Ossification of parietal bone, which to ossify last?
A- Superior temporal margin
B- Inferior temporal margin
C- Tuberosity
D- Angle
Ans: D

42- Small blood vessels in the wall of blood vessels are known as
A- Vasa Vasorum
B- Nervivasorum
C- Vasa nervosum
D- None of the above
Ans: A

43- Primary cartilaginous Joint:
A- Costochondral Joint
B- Teeth & Jaw
C- Inferior tibiofibular joint
D- Symphysis pubis
E- Sutures of skull
Ans: A

44- Loss of posterior curvature of back in infant, Called
A- Lordosis
B- Kyphosis
C- Syndesmosis
D- Kyphoscoliosis
Ans: A

45- Sphenoid bone is
A- Irregular bone
B- Flat bone
C- Shortbone
D- Longbone
E- Pneumatic bone
Ans: E

46- Outer sheath of the nerve is called:
A- Endoneurium
B- Perineurium
C- Epineurium
D- None of the above
Ans: C

CamScanner

47- Which of the following is the feature of long bone?
A- Contact surfaces are covered with elastic cartilages
B- Has a central marrow cavity lined with periosteum?
C- Has a central marrow cavity lined with endosteum?
D- None of the above
Ans: C

48- Strongest Muscles Arcbitecture:
A- Unipennate
B- Bipennate
C- Multipennate
D- All of the aboove
Ans: C

49- Which of the following ossifies last?
A- Medial epicondyle
B- Lateral Epicondyle
C- Olecrenon
D- Trochlea
Ans: B

Explanation:

Capitellum	1
Radial head	3
Medial epicondyle	5
Trochlea	7
Olecranon process	9
Lateral epicondyle	11

50- What is true about a new born?
A- Lower limbs are stronger than upper limbs
B- Can hold neck
C- C-Shaped vertebral column
D- All the four limbs are equal in size
Ans: C

51- Wrist joint is an example of:
A- Hinge
B- Ellipsoid
C- Pivot
D- Synovial
Ans: B

52- Elastic cartilage is found in:
A- Epiglottis
B- Caryax
C- Ala of nose
D- Thyroid cartilage
Ans: A

Explanation:
- Epiglottis
- Ear pinna
- External auditory tube

53- Lymph drainage from back of skin at T10 vertebra to:
A- Axillary lymph nodes
B- Posterior mediastinal nodes
C- Superficial inguinal nodes
D- Deep inguinal lymph nodes
Ans: A

Explanation:
- Lymphatic drainage of skin behind T10 – Posterior axillary lymph nodes
- Lympbatic drainage of back above the crest – Posterior axillary lymph nodes
- Lymphatic drainage of back below the crest – Lateral group of superficial inguinal lymph nodes

54- Muscles are connected to bones via:
A- Ligaments
B- Tendons
C- Joints
D- Cartilage
E- Fasciae
Ans: B

55- Pin point depression on the surface of bone is called
A- Passage
B- Meatus
C- Foramen
D- Fovea
Ans: D

56- Intervertebral discs:
A- Make 1/ 4th of the length of vertebral column
B- Made of hyaline cartilage
C- Something about annulus fibrosis composition
D- Something about size of discs during day and night
Ans: A

57- Diaphysis of long bone is
A- Formed by Enchondral ossification
B- Weekest pan of bone
C- Formed by memberanous ossification
D- Secondaty centre fiom diaphysis
Ans: A

58- Bunion is:
A- Bony prominence
B- Infiected bursa
C- Blood filled bursa
D- Tumor of compact bone
Ans: A

Explanation:
- Bunion – bony hump that forms on the joint of base of toe
- Inion – Posteroinferior part of the Occipital bone on the external surface

59- First bone to ossify in intrauterine life:
A- Femur
B- Clavicle
C- Tibia
D- Fibula
E- Humerus
Ans: B

Condition in which the length of digits is lesser than normal
A- Polydactyly
B- Syndactyly
C- Brachydactyly
D- Clinodactyly
Ans: C

61- Bone having significant amount of red bone marrow in the adult
A- Femur
B- Humerus
C- Sternum
D- Tibia
Ans: C

62- Articular surface has which cartilage:
A- Hyaline
B- Elastic
C- Fibrous
D- None
Ans: A

63- Regarding blood supply of bones:
A- Small bones supplied by nutrient artery
B- Irregular bone supplied by nutrient artery
C- Flat bones bone supplied by nutrient
D- Shaft of long bone supplied by nutrient artery only
E- Ends of long bones supplied by epiphyseal arteries.
Ans: E

64- Articular cartilage most commonly?
A- Belongs to category of elastic cartilage
B- Can easily repair after injury
C- Cells orderly arranged in column
D- Covered by perichondrium
E- On epiphysis of long bones in synovial joints
Ans: E

65- Hyaline cartilage:
A- Present in nasal septum
B- Pinna
C- TMJ articulation
D- Epiglottis
E- Menisci of knee
Ans: A

66- Microscopic feature of compact bone:
A- Haversian canal arranged obliquely
B- Lacunae have osteoblast
C- Caversian canal are not interconnected collagen
D- Lamellae are regularly arranged
Ans: D

67- Ischio-pubic ramus fuse at the age of:
A- 7 years
B- 1 years
C- 24 years
D- 21 years
E- 14 years
Ans: A

68- Regularly placed lamella are seen on a histopathological slide. Such an arrangement is present in:
A- Cancellous bone
B- Compact bone
C- Dentine
D- Sesamoid bone
Ans: B

69- Which bone formed by primary ossification center?
A- Membranous
B- Epiphysis
C- Diaphysis
D- Metaphysis
E- Epiphysieal plate
Ans: C

70- Pneumatic bones are found in which area of body?
A- Face
B- Upper limbs
C- Vertebral discs
D- Lower limbs
Ans: A

71- Pivot joint is:
A- Wristjoint
B- Knee
C- Atlanto axial
D- Elbow joint
E- Ankle joint
Ans: C

72- About hyaline cartilage, which is true:
A- Collagen fibers are visible
B- Fibers are not visible
C- Both elastic and collagen fibers are present
Ans: B

73- Howship lacna ae contain:
A- Osteoclasts
B- Osteoblasts
C- Osteocytes
D- Geroncells
Ans: A

74- Superior radio ulnar joint type of joint:
A- Pivot
B- Hinge
C- Condyloid
D- Ellipsoid
Ans: A

75- Secondary cartilaginous joint is:
A- Presence of fibrocartilage disk between two bone
B- Present in skull
C- Is covered by hyaline cartilage
D- Highly moveable
Ans: A

76- Hyaline cartilage present in?
A- Corniculate
B- Cuneiform
C- Tracheal rung
D- Pinna
Ans: C

CamScanner

77- Two types of ossification seen in?
A- Mandible
B- Skull
C- Tibia
D- Humerus
Ans: A

78- Immovable joint
A- Syndesomosis
B- Diarthrosis
C- Symphysis
D- Hip joint
E- Carpometacarpal joint
Ans: A

79- Circumferential Lamella of bone is present in?
A- Compact bone
B- Spongybone
C- Both
D- None
Ans: A

80- New bone formation by:
A- Periosteum
B- Endosteum
C- Myosteum
D- Neural crest cells
Ans: A

81- Ear ossicles are example of
A- Flat bone
B- Irregular bone
C- Short bones
D- Long bones
Ans: B

82- In osteoporosis defect in
A- Osteoblasts
B- Osteoclasts
C- Osteocytes
D- Chondrocytes
Ans: B

83- Striated muscle and continuous rhythmical contractions which muscle is this?
A- Esophagus muscle
B- Skeletal muscle
C- Cardiac muscle
D- Smooth muscle
Ans: C

84- A young man presented with chest pain and dyspnea physician advised xray chest, which part is costocartilaginous in x-ray chest
A- Manubrosternal joint
B- Costochondral joint
C- Sternoclavicular joint
D- Xphisternum
Ans: B

85- Dermatome of lateral wrist is
A- C4
B- C5
C- C6
D- C8
E- T1
Ans: C

86- Regarding osteon true is?
A- Has Circumferential lamella
B- Haversion canal
C- Present in cartilage
D- Present in spongy bone
Ans: A

87- Joint which is Fibrocartilagenous and ampiarthrosis is:
A- Sternoclavicular
B- Acromioclavicular
C- Intervertebral
D- Distal Tibiofibular
Ans: D

88- Muscle in which fascicle arranged is right angle to long axis is
A- Oblique
B- Pennate
C- Parallel
D- Diagonal
Ans: C

89- Fracture of long bone will stop longitudinal growth
A- Epiphyseal plate
B- Epiphyseal line
C- Anatomical neck
D- Metaphysis
E- Diaphysis
Ans: A

90- Regarding Primary cartilagenous joint
A- Present in Trachea
B- Hyaline cartilage Connect 2 bones together
C- Present in pinna of ears
D- Fibrocartilage
Ans: B

91- Intervertebral disc tensile strength is due to
A- Fibrocartilagenous
B- Elasticity
C- Connection with manubrium
D- Disc flexibity
Ans: A

92- What is location of Compact bone
A- Suture between bones
B- Directly under periosteum
C- Both sides of Epiphysis
D- Medullary cavity
E- Epiphyseal cavity
Ans: B

Explanation:
- It is located in diaphysis of long bones and under periosteum

93- Regarding the pubic symphysis, what type of joint is?
A- Fibrous
B- Condyloid
C- Synovial
D- Primary Cartilaginous
E- Secondary Cartilaginous
Ans: E

Explanation
Primary cartilaginous joint
- 1st Sternocostal joint
- Between epiphysis and Diaphysis of long bone

Secoadary cartilaginous joint
- Intervtebral discs
- Symphysis pubis
- Manubriosternal joint

94- Immovable joints separated by ligament and membrane:
A- Syndesmosis
B- Synarthrosis
C- Primary cartilaginous
D- Synovial
Ans: B

95- Vertebral body symphysis have which of the following cartilage?
A- Fibrocartilage
B- Hyaline
C- Elastic
D- Articular
Ans: A

96- Bone beyond law of ossification is:
A- Humerus
B- Femur
C- Lower end of fibula
D- Tibia
E- Clavicle
Ans: C

97- Regarding bone formation true is:
A- Intramembranous bone from chondrocytes,
B- Bone increase in linear growth
C- Newly laid bone is called osteoid
D- Osteoblast in lacunae
Ans: C

98- Which bone has ossification centre at antenatal period?
A- Distal end of femur
B- Proximal end of tibia
C- Proximal end of humerus
D- Proximal Ulna
Ans: A

99- Bicep brachi is?
A- Non-twitch
B- Fast-twitch
C- Slow-twitch
D- Vety slow twitch
Ans: B

100- A young boy presents in orthodontic opd with spacing of his teeth and is unsure of his age. Which of the following will help in estimating his age?
A- Multiple radiographs
B- Assessing his nutritional status
C- Weight and height estimation
D- By radiography of jaw and looking for permanent teeth
Ans: A

101- Intervertebral disc has which type of cartilage that keeps it in place:
A- Fibrous
B- Hyaline
C- Synovial
D- Elliptical
Ans: A

102- Manubriosternal joint is: (Surgery Feb 2025)
A- Symphysis joint
B- Secondary cartilagenous joint
C- Primary cartilagenous joint
D- Syndesmosis
Ans: B

Explanation:
Primary cartilagenous joint
- 1st Sternocostal joint
- Between epiphysis and Diaphysis of long bone

Secondary cartilagenous joint
- Intervtebral discs
- Symphysis pubis
- Manubriosternal joint

BIOSTATISTICS QUICK HINTS

Case Control Study:
- Disease vs Non Disease
- Related to ODD Ratio

Cohort Study:
- Group with Risk Factors and Group without Risk Factors
- Related to Relative Risk
- Cause to Effect
- Forward Study

Cross Sectional Study:
- Disease and Risk Factors

Sensitivity (True Positive):
- Detect Disease and Rule out Disease (FA)

Specificity (True Negative):
- Detect Non Disease and Rule in Disease(FA)

Positive predictive value – The chance that the patient has condition if the diagnostic test is positive

Negative predictive value - The chance that the patient does not has condition if the diagnostic test is negative.

Mean – Sum of all value divided by total

Median – Middle num in a group of numbers

Mode – Most common repeated value in data

Attrition Bias – Related to follow up and Prognosis

Berkson Bias – Related to Different Exposure

Normal Distribution (Gaussian) Curve – Mean=Median=Mode

Positive Skew – Mean >Median >Mode

Negative Skew – Mean <Median <Mode

Confidence Interval – Mean and Standard Error

Confidence Limit – Standard Error and T value

Variance -Standard deviation plus mean

T Test – Mean of 2 groups

Anova Test – Mean of 3 or more groups

Chi Square – 2 by 2 Table and Categorical Data

Pie Chart – Related to Percentages

Confidentiality – Break When Patient Allows You

Incidence – no. of new cases occurring in defined population during specific period of time

Prevalence – both new and old cases in specific population at a given time

Primary prevention – to prevent disease before it occurs

Secondary prevention – early diagnosis and prompt treatmentof disease that has already occurred

Tertiary prevention – to soften the impact of ongoing illness that has lasting effect

Nominal - categorizes and labels variables e.g. presence or absence , black and white

Ordinal – ranks categorizes in order e.g. position in class (1st , 2nd , 3rd) , primary secondary and tertiary

Ratio scale – has known equal intervals and also has meaningful zero point e.g. height and weight., distance and length

Interval scale – the interval between adjacent values but no zero pint e.g. 1st horse , 2nd horse.

Single blind study – the participants in clinical trial does not know if they are receiving the placebo or real treatment

Double blind study – both the participants and doctors does not know which group got the placebo and which got the experimental treatment.

Triple blind study - randomized experiments in which the treatment intervention is unknown to the patient , the individual who administer the treatment or intervention, and person who assess the outcomes

Therapeutic Dose –
- Potency
- Dose of drug requires to produce 50% of that drug maximal effect

Therapeutic Index –
- Safety margin of drug
- Ratio of dose that produces toxic effect to dose which produces desirable clinical effects

Therapeutic Window –
- Range of Dose
- The range between minimum clinical effect and maximum toxic effect

Therapeutic Effectiveness –
- Efficacy
- Maximum response produced by drug

Measure of central tendency
- Mean
- Median
- Mode

Measure of dispersion
- Standard deviation
- Range
- Variance

CamScanner

BIOSTATISTICS

1- Difference among the values of Mean is related to
A- Standard deviation.
B- Standard error
C- Confidential limit
D- Confidence interval
Ans: A

2- Study of affected and non-affected is:
A- Cohort.
B- Case control
C- Cross sectional analysis
D- Prospective Study
E- Cross Sectional
Ans: B

Explanation:
Case Control Study:
- Diseases Vs No Disease
- Related to ODD Ratio

Cohort Study:
- Group with Risk Factors and Group without Risk Factors
- Related to Relative Risk
- Cause to Effect
- Forward Study

Cross Sectional Study:
- Disease and Risk Factors

3- Breaking a bad news to the patient in which of the followog?
A- In a formal session
B- In a hurried manner
C- Through written form
D- Shouldn't be told
E- Tell Everyone
Ans: A

4- Good doctor patient relationship requires:
A- Having sound medical knowledge
B- Updatingskills
C- Showauthority
D- Active listening
E- Passive listening
Ans: D

5- Mean is defined as:
A- Sum of All observation
B- Sum of Variance
C- Square root of Variance
D- Measure SD
E- Sum of All Observation divided by total no of observations
Ans: E

6- 2 groups of people were selected. One presented with vomiting, one without vomiting Data obtained in presence or absenceof vomiting is:
A- Ordinal
B- Nominal
C- Parametric
D- Case Control
E- Cohort
Ans: B

Explanation:
- Nominal – choosing between 2 or 3 variables eg presence or absence , man or woman , north or south .
- Ordinal – type of data in which the values follow a natural order eg primary >Secondary > Tertiary
- Ratio scale – type of variable measurement scale which is quantitative in nature , has the propeny of equal interval and possess a true zero point eg height in feet or inches , weight in kgs
- Interval scale - The distance between any two adjacent attributes is called an interval, and intervals are always equal. Eg 1st horse 2nd horse

7- Frequency Distribution related to:
A- Tells distribution of value appear in data
B- Tell distribution value which is missing
C- Percentage of values
D- Describe Variation in data
Ans: A

8- Vitamin A as prophylaxis given to a child is an example of?
A- Health Promotion
B- Specific Protection
C- Primary Prevention
D- Disability Limitation
E- Primordial Prevention
Ans: B

9- Standard deviation plus mean is:
A- Confidence interval
B- Confidence error
C- Sample Bias
D- Variance
Ans: D

Explanation:
- Confidence Interval – Mean and Standard Error
- Confidence Limit – Standard Error and T value
- Variance -Standard deviation plus mean

10- Patient is conscious admitted in ICU due to heart problem which thing disturbs him most?
A- Anxiety due to what is happen to me
B- Worried about hospital environment
C- He is calm and relaxes
D- Worried about Hospital staff
Ans: A

11- Incidence is defined as:
A- Number of new cases
B- Number of pre-existing cases
C- Number of old and new cases
D- Definition of the total population
E- Number of all epidemic cases
Ans: A

Explanation:
- Incidence – New cases
- Prevalence – Old +New cases

12- Death of mothers giving birth to a baby in relation to 100k normal live births is
A- Growth rate
B- Maternal mortality rate
C- Maternal mortality ratio
D- Maternal risk index
Ans: C

13- Standard devintion measures:
A- Confidence interval
B- Confidence error
C- Sample Bias
D- Variability among individual values
Ans: D

14- Hippocratic oath describes clearly which of the following?
A- Sexual boundaries
B- Advertisement
C- Doctor's Right
D- Confidentiality
Ans: D

15- A group with CHD and associated risk factors is compared to another group with no associated risk factors. What type of study is this?
A- Cohort
B- Cross sectional
C- Correlation
D- Retrospective
E- Case control
Ans: A

16- Confidence limit may be defined as:
A- Square root of variance
B- Standard error of mean with T value
C- Mean coincide with code
D- Mode and SE
E- SD and Variance multiple
Ans: B

Explanation:
- Confidence interval – Mean and standard error
- Confidence limit – Standard error of mean and T value

17- The most important predictor assesses compliance therapy of patient:
A- Doctors perception of the disease
B- Patients own perception of a severity of disease
C- Patients perception of his role in community
D- Patient role in community
Ans: B

18- Statistical average applied to the measurement of population is
A- Mean
B- Mode
C- Median
D- Standard deviation
Ans: A

19- The label on a drug got removed accidently such that the doctor knows nor the patient study is
A- Single blind
B- Double blind
C- Triple blind
D- None of the above
Ans: B

Explanation:
- **a single blind study**, the patient in the clinical trial do not know if they are receiving the placebo or the real treatment.
- **In a double-blindstudy**, both the participants and the doctor do not know which group got the placebo and which got the experimental treatment
- **Triple-blind studies** are randomized experiments in which the treatment intervention is unknown to the patient , the individual who administer the treatment or intervention, and person who access the outcomes

20- Test which excludes completely non affecte d person is?
A- Sensitivity
B- Specificity
C- Prevelance
D- Incidence
E- Accuracy
Ans: B

Explanation:
Sensitivity (true positive)
- Detect disease and rule out disease (FA)
- Associated with true positive and false negative

Specificity (true negative)
- Detect non disease and rule in disease (FA)
- Associated with true negative and false positive

21- Chi square chart used for which of following?
A- Nominal Data
B- Categorical data
C- Ordinal data
D- Mean of two
Ans: B

Explanation:
- T Test – Mean of 2 groups
- Anova Test – Mean of 3 or more groups
- Chi Square – 2 by 2 Table and Categorical Data
- Pie Chart – Related to Percentages

22- Male and Female patient divided into groups then subgroup which type of samplag it is?
A- Simple Random sampling
B- Stratified Random sampling
C- Mixed Sampling
D- Random Population
Ans: B

CamScanner

23- In a study, 40% woman have received HRT and 20% have not received HRT, best way to represent such study is:
A- Barchart
B- Piechart
C- Histogram
D- Chi square
E- Scatter
Ans: B

24- Intervention before occurrence of disease lesion is:
A- Primary prevention
B- Secondary prevention
C- Tertiary prevention
D- Specific protection
Ans: A (FA)
Explanation:
- Occurrence of disease lesion mean the lesion that cause disease bas not occurred yet so before disease Primary
- Primary - Prevent disease before it occurs i.e HPV vaccination
- Secondary - Early diagnose and treatment i.e Pap smear
- Tertiary - Treatment to reduce complication i.e Chemotherapy
- Quaternary - Avoid unnecessary intervention to minumze incidental harm.

25- Most repeated value in data is:
A- Mean
B- Median
C- Mode
D- SD
E- Variance
Ans: C

26- While doing statistical study positive predictive value is affected by?
A- Remission of cases
B- Incidence
C- Prevalence
D- Variance
Ans: C

27- Regarding prevalence what is true?
A- New cases
B- Old cases
C- Old+New cases
D- Epidemic
Ans: C

28- Pap smear comes in category of:
A- Primary prevention
B- Secondary prevention
C- Tertiary prevention
D- Specific prevention
E- Quaternary prevention
Ans: B(FA)

29- Early diagnosis and treatment is:
A- Primary prevention
B- Secondary prevention
C- Tertiary prevention
D- Quaternary prevention
E- Specific prevention
Ans: B(FA)

30- In a community with population of 1000000 (1 Million), there were 100000 females in child bearing age and 10000 children were born live in the year 2000. A total of 50 women died due to pregnancy and related causes. The maternal mortality rate of this community is:
A- 5/1000 live births
B- 50/1000 live births
C- 5/10000 population
D- 50/1000 females
E- 5/1000 females
Ans: C

31- A study is conducted to evaluate the rates on antibiotics of same effect produced by different pharmaceutical company and rate of different drugs are 1.5 1.7 2.7 3.4 9.0. what is the measure of central tendency will used
A- Weighted mean
B- Mode
C- Median
D- Mean
Ans: A

32- Alpha value 0.001 in statistics represents what?
A- Chance of incorrectly rejecting the null hypothesis is 1 out of 1000
B- Variation
C- Insignificant
D- Chance of correctly rejecting the null hypothesis is 1 out of 1000
Ans: D

33- The standard normal distribution
A- Is skewed to left
B- Has mean 1.0
C- Has variance 1.0
D- Has standard deviation 0.0
Ans: C

34- Disease monitoring is done by
A- Predictive value
B- Screening
C- Diagnosis
D- Prospective study
Ans: A

35- Probability of difference in two means checked by which test?
A- Variability
B- Significance
C- Frequency
D- Ratio
Ans: B

36- Positive predictive value formula:
A- Test positive ÷ True positive
B- True positive ÷True positive + False negative
C- Truepositive ÷ Truepositive - False positive
D- True positive ÷ True positive +False positive
Ans: D (FA)

37- Therapeutic index of drug indicates:
A- Potency
B- Safety
C- Efficacy
D- Dose
Ans: B
Explanation:
- Therapeutic Dose – Potency
- Therapeutic Index – Safety
- Therapeutic Window – Range of Dose
- Therapeutic Effectiveness – Efficacy

38- Of women with neonates getting tetanus 19 had not taken tetanus toxoid and 40 whose babies did not take tetanus 30 bas taken two tetanus toxoid shots during pregnancy:
A- 10
B- 11
C- 9
D- 8
E- 7
Ans: C

39- Data on 2 groups of diabetics was collected to look at the male and female pattern of diabetes females had a mean random blood sugar level of 200+ 50mg%, and males have a mean RBS level of 205+ 10mg%.the result reveals that
A- Men have a higher median value of lower standard deviation compared to women
B- Men have more variability of RBS in their group
C- There is no difference in the RBS of men and women
D- Women have a lower median and higher SD in their group
E- Women have more variability of RBS in their group
Ans: D

40- Result of positive test came positive and negative came negative this is related to:
A- Accuracy
B- Sensitivity
C- Likelyhood ratio
D- Specificity
E- True positive
Ans: A

41- Which of the following goes from cause to effect
A- Cohort
B- Case control
C- Cross sectional
D- Experimental study
Ans: A
Explanation:
- Cause to effect -cohort
- Effect to cause ... case control

42- Distribution of values in given data is
A- Mean
B- Median
C- Mode
D- Frequency
Ans: D

43- A study was done in which group with exposure & group with non-exposure studied which study is carried out?
A- Cross Sectional
B- Case Control
C- Cohort
D- Randomized trial
E- Sequential trial
Ans: C

44- P value of drug is significant if less than:
A- 0.1
B- 0.008
C- 0.05
D- 0.02
E- 1.5
Ans: C

45- For prevention of disease, what is best measure?
A- Individual opinion regarding disease
B- Establishing health education
C- Askin Relatives
D- Asking patient
Ans: B

46- Measure of dispersion is
A- Mode
B- Mean
C- Standard deviation
D- Median
Ans: C
Explanation:
Measure of central tendency
- Mean
- Median
- Mode

Measure of dispersion
- Standard deviation
- Range
- Variance

47- Kaplan – Meier curve indicates:
A- Incidence of disease
B- Demography
C- Severity of disease
D- Drug side effects
E- Survival of Patient
Ans: E

CamScanner

48- Standarddeviation is:
A- Square of Mean
B- Square Root of Variance
C- Square of Variance
D- Square of Mode
Ans: B

49- Positive predictive value is:
A- Proportion of true positive in all positive
B- Same as sensitivity
C- Same as specificity
D- None
Ans: A

50- Normal distribution curve is used to determine:
A- Mean and standard deviation
B- Mean and sample size
C- Confidence limit
D- Confidence interval
Ans: A

51- Which one has chance of High Stress
A- Type B Personality
B- Type A Personality
C- Type C Personality
D- Type D personality
Ans: B

52- Test for ruling out true negative:
A- Sensitivity
B- Specificity
C- Positive predictive value
D- Negative predictive value
Ans: B
Explanation:
- Sensitivity–True Positive
- Specificity– True Negative

53- Lack of communication between doctor and patient or hurried approach may lead to:
A- Incompliance
B- Mistrust
C- Aggressiveness
D- Personal protection
Ans: B

54- Cohort study includes study of:
A- Disease vs non disease
B- Group with exposure
C- Group with exposure and group with non-exposure
D- Group with non-exposure
Ans: C

55- Confidence interval shows:
A. Mean and standard error
B. Standard Error and T value
C. T value
D. Standard deviation
Ans: A

56- Normal distribution curve:
A- Mean>Mode
B- Mode>Mean
C- Mean = Mode
D- Mean =Median =Mode
Ans: D

57- Randomization of study subjects in a clinical trial is most helpful for controlling for which of the following?
A- Placebo effect
B- Recall bias
C- Non-compliance
D- Effect modification
E- Confounding
Ans: E

58- Maternal mortality rate how much increased in Pukistan?
A. 100 times
B. 1000 times
C. 10 times
D. 10000 times
Ans: A

59- Chi square use to measure:
A. Statistical
B. Specificity
C. Standered deviation
D. Sensitivity
E. Catogorical data
Ans: E>A

60- A Research has been done on 2 different groups. the research rejects the null hypothesis, it means
A- There is huge difference between 2 groups
B- There is no difference between 2 groups
C- Irrelevant hypothesis
D- Irrelevant observation
Ans A

61- Two tail test is a method in which critical area of distribution is?
A. Three sided
B. Two Sided
C. One sided
D. Four sided
Ans: B
Explanation:
Two Tailed test is a method in which the critical of a distribution is two-sided and tests whether sample is greater than or less than a certain range values. It is used in null-hypothesis testing for statistical significance.

62- Central value of serial data:
A. Mean
B. Median
C. Average
D. Mode
Ans: B

63- Data from smaller study on one group of people is combined with data from larger study what type of data is this:
Case control
A. Randomised control trial
B. Cohort
C. Meta analysis
D. Ans: D

64- Study done on Patient follow up result has great bias?
Non-compliance
A. Sampling error
B. Attrition
C. None
D. Ans: C

65- True positive detected by:
A Sensitivity
B Specificity
C PPD
D Variance
Ans: A
Explanation:
- Sensitivity – True positive
- Specificity – True Negative

66- Chi Square test associated with:
A 4 by 4 table
B 2 by 2 table
C Proportion
D 5×5 table
Ans: B

67- When a test is performed in a diseased person and person is positive for that then the test is?
A- Sensitive
B- Specific
C- Positive Predictive Value
D- True Negauve
E- True Positive
Ans: E

68- Referral System:
A- Two way communication between health facilities
B- Higher Hospitals are better
C- To decrease burden
D- For higher procedure
Ans: A

69- A team of professionalises, for the research purpose, selected smoker people and divides as group A and group B, after some time, group A people diagnosed with bronchogenic carcinoma, there are chances of development of carcinoma in the other group also, this type of study is called:
A- Cohort study
B- Case control study
C- Observational study
D- Cross sectional study
Ans: A

70- Two groups of patients given hemorrhoidal treatment and their effect is seen with time, it's:
A- Prospective Cohort Study
B- Case Control Study
C- Randomized Control Study
D- None of the Above
Ans: C

71- 500 patients exposed to smoking Vs other subjects are not which type of study is this to see the effect:
A. Case Control
B. Cohort
C. RCT
D. Cross sectional
Ans: B

72- What should be the pharmaceutical & doctor interaction purpose?
A- Hospital welfare
B- Staff welfare
C- Should be entertained for patient's benefit
D- Earning purpose
Ans: C

73- A doctor was offered a chance of travel in exchange for taking part in upcoming discussion of a drug in the hospital, what should be the response of the doctor?
A- Accept it
B- Refuse Politely
C- Inform hospital administration
D- None of the above
Ans: B

74- A doctor in his clinical or hospital can practice an effective management by:
A. Evidence based management
B. Good and effective communication skills
C. Providing guided information
D. Showing empathy and sympathy towards patient.
Ans: B

75- Confidentiality shouldn't be breached in situation:
A. An HIV
B. An adult male sexually abusing daughter
C. A girl told you she has hid 100 tablets to commit suicide
D. A women told you she is depressed and occasionally she has suicidal thoughts
E. None of the above
Ans: E (FA Step 2)

76- Which laboratory test best separate those who have disease from those who don't have disease?
A- Sensitivity
B- Specificity
C- True positive
D- True negative
E- PPV
Ans: A

CamScanner

77- A patient crying to tell you about her sister death, what should be your response?
A. Take your time
B. Don't worry everything will be fine with time
C. Take her out
D. Call the nurse
Ans: A

78- Mid value, in upper and lower limit is called:
A- Median
B- Mean
C- Mode
D- Standard deviation
Ans: A

79- The number of new cases of breast cancer per 100000 women in a year is expressed as:
A- Rate
B- Incidence
C- Prevalence
D- Proportion
E- Ratio
Ans: B

80- The primary use of the standard error of the mean is in calculating the:
A- Confidence interval
B- Error rate
C- Standard deviation
D- Variance
Ans: A

81- In a group of Diseased people a test is performed which tells about true negative from affected people is known as:
A- Positive predictive value
B- Negative prediction value
C- Probability
D- Sensitivity
E- Specificity
Ans: E
Explanation:
- True positive =Sensitivity
- True negative=Specificity

82- About standard deviation true is:
A. Statistic that measures the dispersion of a data set relative to its mean on either sides.
B. Calculated as the square root of mean
C. Prevalence
D. Not a main measure of variability
Ans: A

83- In a medical research some doctors comparing two group of people and checking the relation of a disease with its Risk factors: Which type of study?
A. Cross sectional data
B. Case Control
C. Cohort
D. Cross sectional Analysis
E. Probability
Ans: C

Explanation:
- Case control: Disease and non-disease.
- Cohort: Group with risk factor and group without risk factor.
- Cross sectional: Risk with disease

84- Mean median mode same in:
A- Normal distribution curve
B- Confidence Interval
C- Standard deviation
D- Frequency polygon
Ans: A

85- Study conducted to check temp change with general anesthesia over time best way to calculate result:
A. Student T test
B. Chi square
C. Anova
D. Regression analysis
Ans: D

86- Social support to patient is provided by:
A. Family members
B. Nursing staff
C. Edhi foundation
D. NGO
E. Social workers
Ans: A

87- Seductive female patient came near to you, what will you do?
A. Call in nurse
B. Dont examine her
C. Examine her
D. Shout
Ans: A

88- Regarding Medical Ethics:
A. Moral code of conduct of doctor professional life
B. study of legal aspects of doctor's professional life
C. Is covered by hoppocratic oath
D. regulated by PMDC
Ans: A

89- A Patient was brought into the Emergency Department and his family wanted to accompany him. What is the most appropriate response?
A. Physician should discourage the most patient and attendants against departure
B. Only patient should be allowed in the ER
C. Physiological support should be provided patients and attendants in the Emergency Department
Ans: B

90- Good factor for determining disease progression:
A. Sensitivity
B. Specificity
C. Predictive value
D. Cohort
Ans: C

91- Confidentiality can be breached when:
A. Patient has treated previously with some unknown drugs
B. Patient is from some other country
C. Cannot afford
D. When he allows to do so.
E. Insurance claim
Ans: D>E

92- Yellow fever in non-endemic area:
A. Epidemic
B. Sporadic
C. Endemic
D. Pandemic
Ans: A

93- Primary prevention for hyperlipidemia:
A- Avoid oily foods
B- Statin administration
C- Beta blockers
D- Diuretics
Ans: A

94- A pharma representative has come to you and is offering you a free 3 day trip to Thailand. He tells you that there will be an academic panel discussion in your hospital about a newly launched drug and wants you to take part in it:
A. Accept the offer
B. Politely decline the offer
C. Do what your colleagues will do
D. Ask your hospital administration what to do
Ans: B

95- In a population, a group of people with a particular feature are represented by:
A. Prevalence
B. Incidence
C. Distribution
D. Occurrence
Ans: D

96- Calculate Median 20,20,30,25,40,45:
A. 27.5
B. 25.3
C. 78
D. 22
Ans: A

97- Dr patient rapport is maintained by:
A- Open endended questions
B- Using Patients own words
C- Using stressful environment
D- Polite behaviour at bed side
Ans. D

98- Type A personality develop cardiac problem due to:
A- Stress of social environment
B- Sedentary lifestyle
C- Vigorous speech
D- Aggressiveness
Ans: A

99- Regarding doctor and pharmacist interaction:
A. Health promotion through interaction with pharmaceuticals
B. For betterment of institution
C. Taking extra privileges for institute
D. All of the above
Ans: A

100- A man comes and complains about receptionist behaviour while other patients and staff have no complain from him what is the cause?
A- Apologise patient and talk to receptionist
B- Refer him to psychiatrist
C- Fire the receptionist
D- Do nothing
Ans: A

101- Measures of dispersion are
A. Mean and mode
B. Mean and median
C. Variance and mean
D. Variance and standard deviation
Ans: D

102- You did a study and it rejected null hypothesis it mean
A. There is difference
B. There is no difference.
C. Study of research is not valid.
D. Your research is not powerful enough
Ans: A

103- Sample taken from 2 group of people which type of sampling is this ?
A. Simple random sampling
B. Stanfied random sampling
C. Mixed Sampling
D. Random population
Ans: A

104- What is the definition of Reliability?
A. Extent to which a procedure can give repeated results
B. Extent to which a procedure is still good as it started
C. Means reproducibility
D. Reproduce false result
Ans: A

105- Equal chance of each person being selected in a study is:
A. Random sampling
B. Stratified sampling
C. Mixed Sampling
D. Random Population
E. Case control
Ans: A

106- In statistics, positively skewed means
A- Left
B- Right
C- Upper
D- Lower
Ans: B

CamScanner

107- Regarding Prevclance true is:
A- New cases
B- Old Cases
C- Epidemic
D- All Cases
Ans: D(No option of Old +New)

108- What type of data is ASA Classification?
A- Continuous
B- Parametric
C- Interval
D- Ratio
E- Ordinal
Ans: E

109- Correlation coefficient R value perfect relation between 2 variables
A- +1
B- -1
C- +12
D- -2
Ans: A

110- Surgeon treated 200 patients of hemorrhoids, he randomly divides the patients surgically treated and pharmacologically treated groups. After 1 year he access the patient and find that surgically treated patient has better outcome type of study is:
A- Case control study
B- Cohort study
C- Prospective cohort
D- Randomized control trial
Ans: D

111- Pregnant lady with history of smoking taken to study its affect on IHD to identify risk factor what type of study is this?
A- Case control
B- Cross section
C- Cohort
D- Prospective
E- Variance
Ans: B

Explanation:
Case control study:
- Disease vs Non disease
- Related to ODD Ratio

Cohort study:
- Group with risk factors and group without risk factors
- Related to relative risk
- Cause to effect
- Forward study

Cross sectional study:
- Disease and risk factor

112- You will investigate disease by test would be likely called:
A- Sensitivity
B- Specificity
C- Precise
D- Accurate
E- Variance
Ans: A

Explanation:
Sensitivity (true positive)
- Detect disease and rule out disease (FA)
- Associated with true positive and false negative

Specificity (true negative)
- Detect non disease and rule in disease (FA)
- Associated with true negative and false positive

113- Most common electrical hazard in hospital equipments is:
A- Difference in ground potential of two devices
B- An inproperly attached lead of ECG
C- Malfunctioning of External pacemaker
D- Conversion of 3 prong plug into 2 prong plug without a ground
E- Current leak in the grounding Plate of Ectrocautry
Ans: D

114- New anti hypertensive drug going to test/investigate by which technique
A- Sequential trial
B- Placebo
C- Case control study
D- Double blind
Ans: A

115- Study involved to rule out causes of rare disease is:
A- Cohort
B- Case control
C- Clinical trials
D- Retrospective cohort
E- Prospective study
Ans: B

116- Statistical Analysis of studies Done now a days
A- To accept the Placebo
B- Accuracy
C- Mean and S.D
D- Errors
E- Eliminate observer bias
Ans: E

117- Your supervisor ask you to make a test which u can apply on poor and average socioeconomic person the test should have which charac teristics?
A- Cost effective
B- Not specific
C- Always show positive result
D- Positive in all
Ans: A

118- Child birth is example of which of following?
A- Positive Feed back
B- Negative Feed back
C- Passive
D- Immune response
E- Primary inhibition
Ans: A

CamScanner

119- **Randomization is:**
A- Generating Random sequence and selecting random population
B- Selcect groups
C- Irregular selection of sample
D- Selecting stratified population
Ans: **A**

120- **Regarding Two tail test**
A- Decreases Critical value of 't'
B- Equal chance of rejection on both sides
C- Sample of Population is variable
D- Sample mean equal to Population mean
Ans: **B**

121- **Population of true negative among all those who are actually true negative is**
A- Sensitivity
B- Specificity
C- Positive predictive value
D- Negative predictive value
Ans: **D**

122- **Main objective for screening test for cervical cancer is:**
A- Proper compliance of treatment
B- Early diagnose and treatment
C- Late treatment
D- Late diagnose
Ans: **B**

123- **Test which detect & rule out disease is called as?**
A- Sensitivity
B- Specificity
C- Prevalence
D- Incidence
E- Accuracy
Ans: **A**

Explanation:
Sensitivity (true positive)
Detect disease and rule out disease (FA)
Associated with true positive and false negative
Specificity (true negative)
Detect non disease and rule in disease (FA)
Associated with true negative and false positive

124- **Mean in large sample**
A- Always equal to mode
B- More than median
C- Numerical greater than SD
D- Represent nonnal distribution
Ans: **D**

125- **T test used to compare:**
A- Means of Three group
B- Means of Two group
C- One mean
D- 2 by 2 Tables
E- Percentages
Ans: **B**

Explanation:
- T Test – Mean of 2 groups
- Anova Test – Mean of 3 or more groups
- Chi square – 2 by 2 Table and categorical data
- Pie chart – Related to percentages

126- **Which factor should be most important in descriptive studies :**
A- Age
B- Sex
C- Social limits
D- Smoking
E- Nativity
Ans: **B**

127- **Study of 200 guest with vomiting and diarrhea some guest presents with symptoms after 2 days study involve in this case is:**
A- Case control
B- Cohort
C- Cross sectional
D- Meta- analysis
Ans: **B**

128- **Regarding prevalence true is:**
A- New cases
B- Old Cases
C- Epidemic
D- All Cases
Ans: **D (No option of old + new)**

129- **A study done on woman who used to drink alcohol during antenatal period to study the effect of alcohol on baby weight which type of study is this**
A- Prospective
B- Retrospective studies
C- Cohort
D- Case control
Ans: **A**

130- **Study that claim to Decrease the effect of environment on genetics:**
A- Adaptation study
B- Case control
C- Cohort
D- Cross sectional
E- Descriptive study
Ans: **E**

131- **To check the status of vitamin A in a community, the most cost effective method of assessing is?**
A- Clinical assessment
B- Anthropometric
C- Biochemistry
D- Dietary Analysis
Ans: **D**

CamScanner

132- **Sum of values/total number of values is called:**
A- Mode
B- Median
C- Mean
D- Gaussian
E- Positive skew
Ans: C

133- **Statistical data can be arranged categorically by which method:**
A- T test
B- Chi square
C- Anova test
D- P test
Ans: B

134- **Regarding sensitivity of test true is:**
A- Isolate those not having any disease
B- Isolate those having disease and test is positive
C- Isolate those having negative test
D- Isolate false positive result
Ans: B

135- **Which of the following is true regarding Normal distribution curve:**
A- Has central convex peak with concave tail
B- Positive skewing, peak is on right side
C- Positive skewing, peak is on left side
D- None of the above
Ans: A

136- **In Sequential trial true is**
A- Single blind study investigator doesn't know either drug or placebo given
B- Single blind study subject doesn't know either drug or placebo given
C- Maximum answer to questions
D- Maximum questions should be asked
Ans: B

137- **Meta analysis done which shows small studies have more literature influence than large ones which affect over all result this is**
A- Publication bias
B- Observer bias
C- Reader bias
D- File drawer affect
Ans: D

138- **Mode is defined as:**
A- Sum is divided by total no
B- Total no divided by sum
C- Most commonly observation value
D- Least value in All values
Ans: C

139- **Biostatistics deal with:**
A- Presentation of data
B- Analysis and interpretation of data
C- Data entry
D- None
Ans: B

140- **The study of p denotes?**
A- Type I and A error
B- Probability
C- Percentile
D- P value< 0.01
E- Percentage
Ans: B

141- **There were 2 drug groups. They were classified as group A and B but doctors knew name of the drugs. Such study is called?**
A- Single blinded
B- Double blinded
C- Cross sectional
D- Case control
Ans: A

142- **Arithmetic average of population is:**
A- Mode
B- Median
C- Mean
D- Standard deviation
Ans: C

143- **A study was done to determine the importance of smoking as a risk factor for developing lung cancer 500 smokers with the disease and 500 healthy matched non-smokers were evaluated. The type of study is?**
A- Case control
B- Cohort
C- Correlation
D- Cross sectional
Ans: D

144- **Regarding Sensitivity true is:**
A- Percentage of Non Diseased and positive
B- Percentage of Non Diseased and negative
C- Percentage of Diseased and positive
D- Percentage of Diseased and negative
Ans: C

145- **Population of true positive among all those who are actually true positive is:**
A- Sensitivity
B- Specificity
C- Positive predictive value
D- Negative predictive value
Ans: C

CamScanner

146- **Smokers were included in a study on cessation therapy, 20 Volunteers were given therapy. At the end calculated number of cigarettes consumed by 40 smokers. & noticed 40 patients were smoking 40 packs. What is missing in this study?**
A- Hypothesis
B- Random
C- Dependent Factor
D- Independent factor
Ans: D

147- **True positive among diseased with positive test:**
A- Specificity
B- Sensitivity
C- Positive Predictive valuc
D- Negative Predictive value
Ans: B

148- **Private sector hospitals cater**
A- 30%
B- 55%
C- 60%
D- 40%
E- More than 60%
Ans: E

149- **A group of diseased persons is compared with a group of non diseased persons to see association with a factor . Which type of study is this ?**
A- Cohort
B- Cross sectional
C- Case Control
D- Randomized control
Ans: C

150- **Regarding measures of Central tendency, Which of the following is in the middle having equal number of values on both sides?**
A- Mode
B- Mean
C- Variance
D- Median
Ans: D

151- **Main objective for screening test for Tumor is:**
A- Proper compliance of treatment
B- Early diagnose of tumor
C- Late treatment of tumor
D- Late diagnose tumor
E- Early treatment of tumor
Ans: B

152- **Cohort in Epidemiology is defined as:**
A- Study of Population in a city
B- Study of Country
C- Study of a case or Sample
D- Incidence rate
E- Used to describe variability
Ans: C

153- **Maternal mortality is maternal deaths per**
A- 100000 live births
B- 100000 dead births
C- 1000 live births
D- 1000 dead births
E- 100 live births
Ans: A

154- **A Research has been done on 2 different groups. the research rejects the null hypothesis, it means**
A- There is huge difference between 2 groups
B- There is no difference between 2 groups
C- Irrelevant hypothesis
D- Study of Research is not valid
E- Your research is not powerful enough
Ans: A

155- **In an Epidemic, First investigation u will do is:**
A- Collection of samples
B- See which population is at risk
C- Make a Correct diagnosis
D- Report First Case
E- Account First Case
Ans: D

156- **Regarding prevalence what is true?**
A- New cases
B- Old cases
C- Old + New cases
D- Epidemic
Ans: C

157- **Data of 25 with 95% confidence interval and SD 2.5 what will be normal range**
A- 22.5
B- 27.5
C- 22.5-27.5
D- 25
Ans: C

158- **After the birth of a baby the perinatal mortality rate and Still birth can be calculated in:**
A- Death within 1 month
B- Death within 1 year
C- Death within 1 week
D- Death within 1 day
Ans: C

CamScanner

159- In Sequential trial, true is:
A- Single blind study investigator doesn't know either drug or placebo given
B- Single blind study subject doesn't know either drug or placebo given
C- Maximum answer to questions
D- Maxumum questions should be asked
Ans: B

Explanation:
- ***Single blind study*** – the participants in clinical trial does not know if they are receiving the placebo or real treatment
- ***Double blind study*** – both tbe participants and doctors does not know which group got the placebo and which got the experimental treatment.
- ***Triple blind study*** - randomized experiments in which the treatment intervention is unknown to the patient , the individual who administer the treatment or intervention, and person who access the outcomes

160- Which In statistical analysis, the synonym for "Universe" is:
A- World
B- Population
C- Sample
D- Dataset
E- Group
Ans: B

161- A group of 500 people with CHD were compared to another group without CHD, smoking was found as a risk factor for CHD, what type of study is this?
A- Cohort
B- Cross sectional
C- Correlation
D- Retrospective
E- Case control
Ans: A

Explanation:
Case control study:
- Disease vs Non Disease
- Related to ODD Ratio

Cohort Study:
- Group with Risk Factors and Group without Risk Factors
- Related to Relative Risk
- Cause to Effect
- Forward Study

Cross Sectional Study:
- Disease and Risk Factors

162- A prospective cohort study involves:
A- Comparing individuals with a disease to those without the disease to identify risk factors
B- Observing a group of individuals with a condition over time to assess treatment outcomes
C- Tracking exposed and non-exposed groups over time to measure the development of a disease
D- Analyzing historical data to determine the correlation between a risk factor and a disease
E- Conducting a cross-sectional survey to estimate the prevalence of a condition at a specific point in time
Ans: C

163- Patient keeps crying about her sister who passed away. What is the most appropriate response from the doctor?
A- Take your time
B- Don't cry. People lose their loved ones all the time.
C- She was too young.
D- It's better to stay busy and not think about it.
E- You need to move on and be strong.
Ans: A

164- If there are 250 people with hypertension in population of 1000 and 50 new added what will be initial prevelance
A- 250/1000
B- 50/1000
C- 250/750
D- 500/1000
Ans: A

165- A prospective cohort study involves:
A- Comparing individuals with a disease to those without the disease to identify risk factors
B- Observing a group of individuals with a condition over time to assess treatment outcomes
C- Tracking exposed and non-exposed groups over time to measure the development of a disease
D- Analyzing historical data to determine the correlation between a risk factor and a disease
E- Conducting a cross-sectional survey to estimate the prevalence of a condition at a specific point in time
Ans: C

166- Mode is defined as?
A- Most repeated value
B- Same as Mean
C- On Left Side of Mean
D- On left side of Median
Ans: A

Explanation:
- **Mean** – Sum of all values divided by total number of values
- **Median** – Middle number in a group of numbers
- **Mode** – Most common repeated value in data

167- A study is conducted to investigate hypertension (HTN) in diseased and non-diseased individuals to identify the associated risk factors. What type of study design is this?
A- Case-control
B- Cohort
C- Cross-sectional
D- Randomized controlled trial
Ans: C

168- Ability of the Test that is able to correctly RULE OUT NON DISEASED individuals
A- Specificity
B- Sensitivity
C- Accuracy
D- Precise
E- Positive predictive value
Ans: A

CamScanner

Explanation:
Sensitivity (true positive)
- Detect disease and rule out disease (FA)
- Associated with true positive and false negative

Specificity (true negative)
- Detect non disease and rule in disease (FA)
- Associated with true negative and false positive

169- Maternal mortality is maternal deaths per:
A- 100,000 live births
B- 100,000 dead births
C- 1,000 live births
D- 1,000 dead births
E- 100 live births
Ans: A

170- Which measure reflects both the efficacy of therapy and progression of a disease
A- Sensitivity
B- Specificity
C- Accuracy
D- Predictive value
Ans: D

171- Which of the following study design is best suited for comparing individuals with and without risk factors to assess the development of specific outcome
A- Case control study
B- Cross section
C- Cohort study
D- Prospective
E- Variance
Ans: C

Explanation:
Case control study:
- Disease vs Non disease
- Related to ODD Ratio

Cohort study:
- Group with risk factors and group without risk factors
- Related to relative risk
- Cause to effect
- Forward study

Cross sectional study:
- Disease and risk factors

172- Which health model focuses on the patient's perception of their disease and the influence of the doctor's persuasion?(Radiology Feb 2025)
A- Health Belief Model
B- Biopsychosocial Model
C- Social Cognitive Theory
D- Transtheoretical Model
Ans: A

173- The mean hemoglobin value of a population is 10.6 gm% with a standard deviation (SD) of 2 gm%. What is the hemoglobin value below which 5% of the population falls? (Medicine Feb 2025)
A - 6.67 gm%
B - 7.35 gm%
C - 9 gm%
D - 8.6 gm%
Ans: D

174- The ages (in years) of 10 heads of families are recorded as follows: 35, 42, 38, 40, 45, 39, 41, 44, 36, 43 What is the mean age of these individuals?(Medicine Feb 2025)
A- 41.0
B- 38.5
C- 40.5
D- 39.5
E- 42.5
Ans: C

175- A 55-year-old patient is diagnosed with pancreatic cancer and asks about the prognosis. How should the doctor counsel the patient?(Surgery Feb 2025)
A- Similar prognosis to breast cancer
B- Potential for cure with surgery
C- Poor prognosis with limited treatment options
D- High 5-year survival rate
Ans: C

176- Most specific indicator for increased fertility rate inPakistan(Gynae & Obs Feb 2025)
A- Net fertility rate
B- Gross fertility rate
C- Gross reproductive rate
D- Specific age rate
Ans: A

177- A research study aims to include the maximum possible population, ensuring every eligible individual is counted. What type of study is this?(Gynae & Obs Feb 2025)
A- Pilot study
B- Cross-sectional study
C- Cohort study
D- Census
Ans: D

CamScanner

BEHAVIORAL SCIENCES

1- Justice on medical ethics is:
A- Let patient decide about treatment
B- Equity in providing medical resources to all patients equally.
C- Equity to staff working
D- Equity to Doctor working
Ans: B

2- Which of the following is the correct sequence of medical Ethics?
A) Autonomy, Justice & Consent
B) Autonomy, Non-maleficence & Consent
C) Autonomy, beneficence, Non-Maleficence & Justice
D) Autonomy & Justice
Ans: C

3- A married patient in the ward diagnosed as HIV and request you not to tell this news to his wife. What will the doctor about confidentiality?
A) Persuade him to tell his wife, if refuses then inform the wife
B) Don't inform the wife
C) Inform the Police
D) Do nothing
Ans: A

4- A 48 years old lady at last stage of Ca fibroid and she tells you not to tell her family, her son asks about her mother condition & disease what you will do?
A. Tell something
B. Tell Nothing.
C. Inform the son
D. Inform the whole family
Ans: B

5- Components of informed consent include:
A- Written explained procedure risks benefits and alternative method
B- Explaining just risk
C- Explainimg just procedure
D- Explaining Alternatives
E- Written explained procedure risks benefits
Ans: A

6- Emergency Department protocol is:
A- Patient Stay out
B- Relative Stay inside
C- Doctor Stay out
D- Only Patient Allowed inside
Ans: D

7- Confidentiality can be breached only:
A- If patient allows you
B- If friend allows
C- If parents visit doctor
D- If parents allows
E- In emergency
Ans: A

8- A patient is suffering from fatal disease, who should be informed?
A- The family not the patient
B- The patient not the family
C- Hide some information from the patient
D- Provide crisp, clear information to the Patient
E- Tell nothing to patient
Ans: D

9- An elderly patient comes to your clinic and complains about staff being rude. He also feels the receptionist is rude. How will you handle the solution?
A- Refer the patient for psychiatric evaluation
B- Apologize to patient and ask the receptionist to change her behavior.
C- Tell the patient to forgive
D- Fire receptionist
Ans: B

10- A good doctor is recognized by :
A- Pleasant Behavior and Bedside Manners
B- Punctuality
C- Well-dressed
D- Availability to Patients
Ans: A

11- Information care session is for:
A- Take informed consent for the procedure the patient will undergo
B- Clear the myths and misconceptions of the patient and relatives about the disease
C- Tell the patient and family about new advances in treatment of the disease
D- Take infornations from the family and friends of the patient about the disease
E- Tell the patients about the facilities available to in the hospital for the treatment of the disease
Ans: B

12- In a natural world, an animal is injured, what is the characteristic feature
A- Rest/immobility
B- Exercise
C- Overeating
D- Mobility
Ans: A

CamScanner

13- AJK earthquake leading to death of his uncle & now in depression due to:
A- Social Crisis
B- Situational Crisis
C- Emotional Crisis
D- Developmental Crisis
E- None
Ans: B

14- A patient after cardiac surgery would require ventilator in ICU. What do you do so that he doesn't feel depressed about this situation?
A- Explain him the need and cause of ventilator
B- Stop him from talking to staff
C- Family counseling
Ans: A

15- Sociology is branch of
A- Medical sciences
B- Bebavoiural sciences
C- Biological sciences
D- Both A and B
Ans A

16- Psychological stress is an example of
A- Economic crisis
B- Developmental crisis
C- Social crisis
D- None
Ans: A

17- Regarding sickness
A- Doctors perception of the disease
B- Patients perception of a disease
C- Patients perception of his role in community
D- Patient role in community
Ans: D
Explanation:
Sickness – Societal Perspective that is Patient role in community and community perception of patient role.
Illness – Patient Perspective of Symptoms.
Disease – Professional Perspective that is doctor diagnose of disease

18- Breaking bad news, Should ideally be
A- Attending doctor should tell in exclusive formal session
B- Should tell on bed side
C- In front of All family members
D- All staff involve in patient care
Ans: A

19- The best way to start conversation with a patient is:
A- Ask his name, age, address etc
B- Ask directly about presenting complaint
C- Ask open ended questions
D- Ask leading questions
E- Ask closed ended questions
Ans: A

20- Flight or fright response is the responsibility of which system
A- Somatic nervous system
B- Central nervous system
C- Parasympathetic division of ANS
D- Sympathetic division of ANS
Ans D

21- Confidentiality can be breached in
A- HBV
B- AIDS
C- HEV
D- TB
E- Typhoid
Ans B

22- Negative reinforcement means
A- To extinguish behaviour
B- Demonstrating learning in the absence of reinforcement
C- Application of learning principles to change behaviour
D- Bringing behaviour under stimulus control
Ans C

23- First step between doctor and patient relationship should be
A- Informed working
B- Mutual trust
C- Mutual respect
D- Mutual benefit
Ans B

24- Referral system is for
A- Better management
B- Avoid load
C- Patient satisfaction
D- Patient overcrowding
Ans A

25- Which factor strengthens patient and doctor relationship
A- High social skills
B- High professional skils
C- Logical answers to questions
D- Active listening
Ans D

CamScanner

26- Term euphoria means
A- Elated mood
B- Depressive mood
C- Aggressive mood
D- Blunted mood
Ans A

27- In order to disclose news regarding fatal disease
A- Patient should know first
B- Relatives should know first
C- Information should be hidden
D- None
Ans A

28- The Sick role (patient role) involves?
A. Being excused from various obligations
B. Being blamed for being ill
C. Commitment to get unwell
D. Commitment to not follow medical advice
E. Commitment to not take treatment
Ans A

29- Classical conditioning technique used to eliminate phobias is used in
A- Generalization
B- Operantconditioning
C- Spontaneousrecovery
D- Systematic desensitization
Ans: D

30- Behavioural modifications involves
A- Solving problems through insight
B- Bringing behavior under stimulus control
C- Demonstrating learning in the absence of reinforcement
D- Application of learning principles to Change behaviour
Ans: D

31- Sohail is a final year medical student and while reading through the medical documents of a psychiatric patient feels puzzled by the term "alexithymia" which of the following best describes this state
A- Tendency to explode in violent out bursts
B- Difficulty talking about and expressing emotions
C- Tendency to express only positive emotions
D- Tendency to get overwhelmed by Negative emotions
Ans: B

32- A competent 30 years old lady who is 38 weeks pregnant refuses to have cesarean delivery despite the fact that without surgery, the fetus could die. Both her surgeon and psychiatrist have failed to convince her to have the surgery The most appropriate action for her surgeon to take at this time is to
A- Deliver the child vaginally
B- Get a court order in favor of surgery
C- Tell the patient that she criminally Proscuted if child dies
D- Get permission from her husband
Ans: A

33- Patients are most likely to comply with the medical advice for which of the following reasons
A- The illness has serious symptoms
B- The doctor is elderly
C- The illness is chronic
D- The doctor has taken time to provide Information care to patient
Ans: D

34- A female patient comes to the doctor clinic wearing revealing clothes. She comes up very close to the doctor and starts asking him personal questions in a seductive tone .Wbat would be the appropriate response by the doctor?
A- Refuse to examine her
B- Call in a nurse
C- Use open end questioning technique
D- Ask about her personal life
Ans: B

35- Contlict resolution invloves:
A- Dealing with difficult issues sooner rather Than later
B- Taking regular physical exercise
C- Not expressing your expectations.
D- Giving vent to feelings by debate
Ans: A

36- A common misconception about counselling is that it:
A- Involves giving direct advice to clients.
B- Is done exclusively bypsychologists.
C- Is synonymous with psychotherapy.
D- is most effective in psychiatric patients.
Ans: A

37- With regard to counselling, the best statement is:
A- It is done by trained counsellors.
B- It is about giving the best possible advice.
C- It is not an ordinary conversation
D- It is a technique to help people help themselves
Ans: D

CamScanner

In behavioural sciences the bio-psycho - social(BPS) model of health care is best decribed as:
The management of psychological and social issues of patients.
Biological aspects of disease being more important than psychosocial aspects.
Use of social and psychological factors alongside the biological aspects of the illness.
A method in which a patient should be seen by a psychologist and a socialworking.
Ans: C

A father scolds his son when he hits his little sister the son stops hitting the sister this change in the child behaviours is a result of:
Punishment
Negative reinforcement
Positive reinforcement
Shaping
Ans: A

The basic skill of active listening which is the cornerstone of effective communication is:
Comprehend the underlying meaning of patient's spoken words and giving due attention to their feelings and literal meanings as well.
Making a diagnostic formulation of the patients as he speaks.
Clarify what the patient relates without being pate malistic.
Evaluate the effect that transference is having on the doctor - patient relationship.
Understand both what the patient and the physician are saying and the undercurrents of unspoken feelings between the two.
Ans: E

Informed consent is important because:
It enables the participant to understand vital information Hospital
It provides the participant with all information regarding risks benefits and alternatives
It enables the investigator to recruit participant at his clinic
It provides clinical research
Ans: B

Nosocomial infection can be prevented by nurse by:
Not asking attendant to hold tray while delivering medicines
Not throwing gloves on the floor
Proper hand washing
Frequent use of hand sanitizer
Nosocomial infection cannot be prevented
Ans: C

43- A boy continuously failing in exam he is doing anger to his parents this type of defense response is called:
A- Suppression
B- Repression
C- Rationalism
D- Displacement
E- Projection
Ans: D

44- A Child admitted in peads ward with permanent disability or chronic illness Parents of children with permanent disabilities will likely to have:
A- Depression
B- Repression
C- Denial
D- Anxiety
E- Displacement
Ans: A

45- On initial patient interview, least likely thing to be done is:
A- Project an image of authority
B- Duplication of questions
C- Open ended questions
D- State what you already know about presenting complain
E- Ask him reason for coming
Ans: A

46- Doctor provides effective management by:
A- Updated Skills
B- Ideal clinic
C- By Effective communication
D- Evidence based management
Ans: C

47- Patient experiences stress of hospitalization due to?
A- Stigmatization
B- Structure and functioning of hospital
C- Fear of being handicapped
D- Loss of self esteem
Ans: C

48- A doctor was offered a chance of travel in exchange for taking part in upcoming discussion of a drug in the hospital, what should be the response of the doctor?
A- Accept it
B- Refuse Politely
C- Inform hospital administration
D- None of the above
Ans: B

CamScanner

49- A disoriented old patient was brought in emergency by his wife complains of right flank pain vomiting. Diagnose of acute appendicitis was made and urgent appendectomy was suggested. Patient didn't give consent for surgery next step would be:
A- Take court order
B- Do Surgery
C- Take consent from wife
D- Take consent of other doctor
Ans: C

50- A Dr is fluent in Speaking frequently appears on Tv shows. A company approached to advertise their products on TV. What is he doing if he agree
A- Ethical
B- Unethical
C- Beneficience
D- It is allowed legally
Ans: B

51- A diabetic man comes to the physician saying he and his wife are having problem in bed. Next step to be taken by the physician
A- Councel the patient that its common in DM
B- Go to sex therapist
C- Advise labs
D- Ask the patient what kind of bed problem they are having
Ans: D

52- In order to avoid complications during procedure?
A- To know about disease
B- Informed consent
C- Remain in limit of professional competence
D- Avoid Lethal cases
Ans: C

53- A patient is diagnosed as a case of pancreatic carcinoma, family wants not to disclose this bad news to patient as he is already dying. What should dr. Do?
A- Tell patient nothing
B- Counsel family about necessity of telling truth to the patient
C- Give family time to discuss among themselves
D- Tell his brother that it will be dishonesty with patient family and medical staff
Ans: D

54- A patient presented to you with chest pain what question will give you maximum information?
A- Tell me about pain
B- Ask about family history
C- How's the pain
D- Point the location of pain
Ans: A

55- To prevent iatrogenic infections in ICU we should:
A- Wear gloves
B- Use extensive hand washing after examining every patient
C- Sterilize used instruments
D- Wear mask
Ans: B

56- Behavioural changes are produced in society by:
A- Peer seeder
B- Health education
C- Clinical assessment
D- Family
Ans: A

57- Patient diagnosed with terminal ovarian cancer. Told you not to tell their family. In a few days his son and daughter come to your clinic and ask you about the patient what do you.
A- Tell them nothing
B- Refer to another doctor
C- Give them some info
D- Refuse to meet them
E- Tell them to mind their own business and let the patient decide what he wants to do
Ans: A

58- Cluster Type A personality disorder patients are prone to:
A- Competitive drive
B- Physiological stress
C- Hostility induced CAD
D- CVA
Ans: B

59- Justice in Medical ethics?
A- Principle of equity
B- Refusing to content
C- No harm
D- Harm to patient
Ans: A

60- Hippocratic oath describes clearly which of the following?
A- Sexual boundaries
B- Advertisement
C- Doctor's Right
D- Confidentiality
Ans: D

CamScanner

Medical Ethics:
A- Study of Moral aspects of doctor's professional life
B- Study of Legal aspects of doctor's professional life
C- Code of Conduct of doctor's professional life
D- Covered by Hippocratic Oath
E- Regulated by PMDC
Ans: A

A female doctor was offered by cosmetic company for a commercial it is:
A- Unethical
B- Criminal negligence
C- Refuse Grant and do Ad something
D- Check and confirm quality of product
E- Politely refuse and take no benefit
Ans: E

Main component of good communication is:
A- Active listening
B- Punctual
C- Well Dressed
D- Good vocabulary
Ans: A

Best example of verbal communication skills is:
A- Arrange training & research seminar
B- Competence in presentation
C- Fluency
D- Training session & research
Ans: B

Good medical management of patient is possible by:
A- His personality
B- Way of communication
C- Approach of patient
D- Good communication with patient
E- Punctuality of patient
Ans: D

A patient has VDRL test 1:30 for his job appointment but be denied any sexual activity and even his examination is totally unremarkable. How will you manage the patient?
A- Ask him it is dangerous
B- Ask him don't worry test can be false positive
C- PCR syphilis antigen
D- Ask him test is accurate and go for treatment
Ans: B

67- CA pancreas patient is admitted in ward his brother is not letting you tell the patient that the patient has cancer because according to his brother it would kill the patient even faster at the evening the patient's family is going to come to hospital to discuss and we'll have a conference together what will you do?
A. Give family time to discuss among themselves
B. Tell his brother that it will be dishonesty with patient family and medical staff
C. Will ask him to mind his own business
D. None
Ans: B

68- Policeman tested for drugs and opium and cannabinoids were found in urine. The first psychological response would be:
A- Delusion
B- Denial
C- Depressive mood
D- Rationalization
Ans: B

69- Group therapy in which people are encouraged to learn from each other's behaviour is called?
A- Interpersonal learning
B- Learning on your own
C- Imitation
D- Displacement
Ans: A

70- Good doctor patient relationship requires:
A- Having sound medical knowledge
B- Updating skills
C- Show authority
D- Active listening
E- Passive listening
Ans: D

71- A pilot comes to your clinic and complaints about fits and you diagnose him as a case of Epilepsy and he requests you not to reveal his diagnosis as he can lose his job so regarding Confidentiality what will you do?
A- Keep diagnosis secret and advise the pilot to take medicine regularly
B- Inform the authority because passenger's lives are at risk
C- Inform authority so that appropriate steps can be taken
D- Keep the diagnosis secrete
Ans: C

CamScanner

72- Patient is conscious admitted in ICU due to heart problem which thing disturbs him most?
A- Anxiety due to what is happening to me
B- Worried about hospital environment
C- He is calm and relaxes
D- Wotried about Hospital staff
Ans: A

73- How a dr can treat patients properly?
A- Active listening
B- By having knowledge recent changes about diagnosis and treatment
C- Through investigations
D- Asking direct questions
Ans: A

74- A female patient presents with personality confilcts. Which of the following objective test should be perfomed for diagnosing his personality disorder
A- Minnesota multiphasic personality inventory therapy
B- Million clinical multiaxial inventory theorpy
C- Themati appreciation test
D- Rorschach inkblot test
E- Sentence completion test
Ans: B

75- Patient diagnosed as a case of aids:
A- Give Complete details to the patient so that he can manage on his Ease
B- Doctor should let family know about the disease
C- Tell family and patient
D- Don't inform anyone
Ans: C

76- A patient was detected HIV positive. What will be your response?
A- Immediately counsel the patient and attendants
B- Cousel the patient only
C- Hide from family upon patient will
D- Dont tell anyone
Ans: A

77- Patient is admitted in ICU & kept on mechanical ventilator. He is anxious & depresse D- What will the doctor advice?
A- No visit of family members
B- Counsel regarding the need For ventilation
C- Need To prevent infections
D- Stop him from talking to staff
Ans: B

78- Which of the following physical diseases can arise from stress?
A- Cardiovascular diseases and psychiatric disorders
B- Respiratory infections and diabetes
C- Autoimmune disorders
D- Musculoskeletal disorders and neurological conditions
E- Skin conditions and metabolic syndrome
Ans: A

79- Pilot has epilepsy, doesn't want to inform the authorities what should you do
A- Counsel him that it can danger the life of passengers and he should inform authorities if he does not then you should inform authorities
B- Inform authorities by yourself
C- Do Nothing
D- Treat him Secretly
Ans: A

80- A school implements a health education program to prevent the spread of infectious diseases. The program includes teaching students through where trained students influence their classmates' behaviors. Which of the following approaches is being utilized
A- Peer seeder
B- Health education
C- Clinical assessment
D- Family
Ans: A

81- wife overheard her husband saying that the boy living next door is in love with her. She develops a strong belief in this idea and tries to meet the boy and talk to him, but he avoids coming out of his house. This avoidance causes her significant sadness and preoccupation. What is the most likely mental state of the wife?
A- Delusion
B- Depression
C- Bipolar Disorder
D- Schizophrenia
E- Schizoaffective Syndrome
Ans: A

82- How can the true relationship between a doctor and patient be developcd(Medicine & Gynae Feb 2025)
A- Respect the patient dignity
B- Provide the honest and truthful information about the disease
C- Offer reassurance regarding their condition
D- Good medical knowledge
Ans: B

83- Doctor and Patient have no proper communication due to. What is affecting the doctor and patient relation?(Surgery Feb 2025)
A- Casual attitude and hurried approach
B- Misconception
C- Trust
D- Formal approach
Ans: A

CamScanner

PHARMACOLOGY QUICK HINTS

- DOC for T. Solium – **Praziquental > Niclosamide > Albendazole**
- DOC for C. Difficile – **Metronidazole > Vancomycin (Levinson)**
- DOC for mild C. Difficile – **Metronidazole (Levinson)**
- DOC for Severe and resistant C.Difficile – **Vancomycin (Levinson)**
- DOC for Travller Diarrhea – **Norfloxacin > Diphenoxylate**
- 1st Line in AF -- **Beta Blockers (Davidson)**
- For Rate control in AF -- **Beta Blockers & Digoxin (Davidson)**
- For **Rhythm** Control in **AF with no Structural Heart Disease – Flecainide (Davidson)**
- For Rhythm Control in **AF with IHD or Structural heart disease – Amidarone (Davidson)**
- DOC For Cardiogenic Shock – **Dopamine & Dobutamine**
- DOC for Hypotension Unrecordable BP -- **Dopamine**
- DOC for Anaphylactic Shock – **Adrenaline (Epinephrine)**
- DOC for **Pseudomonas** – Ceftazidime
- DOC for **UTI by Pseudomonas** -- Ciprofloxacin
- DOC for OCD – **1st line Fluxetine(SSRI) >Clomipramine(Among TCA)**
- DOC for SAH – **Nimodipine**
- DOC for acute Pancreatitis – **Pethidine(Davidson) > Morphine**
- DOC for Post-Surgery Analgesia in **Asthma** Patient – **Pethidine (Oxford Anastbesia Book)**
- DOC for Post-Surgery Analgesia– **Ketorolac > Pethidine**
- Drug in morning Sickness –**Pyridoxine**
- Drug in motion Sickness – **Scopolamine >Meclizine**
- Drug in Mountain Sickness – **Acetazolamide**
- DOC for Meningitis **Adults** – **Ceftriaxone** > Cefotaxime
- DOC for Meningitis in **Baby** – **Pencillin G**
- DOC in endometriosis – **Medroxy progesterone > Leuprolide > Danazole (Ten Teacher)**
- DOC for Pregnancy induced HTN – **Labetalol >Methyl dopa**
- DOC for **Pregnancy Hypertensive Emergency** – **Hydralazine > Labetalol**
- DOC for **Eclampsia** – $MgSO_4$
- DOC in Uterine Atony -- **Oxytocin > Ergometrine (Ten Teacher)**
- Anti-Thyroid in 1st Trimester– **PTU**
- Anti-Thyroid in 2nd & 3rd Trimester – **Methimazole**
- Anti-Thyroid in Thyroid strom in any trimester -**PTU**
- Crosses Placenta and affect Fetus – **Methimazole > PTU**
- Don't Cross Placenta – **Thyroxin**
- **Elderly** Diabetic – **Tolbutamide**
- **Obese** Diabetic – **Metformin**
- **Non Obese** Diabetic – **Sulfonylurea**
- Organophosphate poisoning Antidote – **Pralidoxime**
- Organophosphate poisoning Symptoms Reversal –**Atropine**
- Drug in Liver Decompensation used – **Lorazepam &Oxazepam**
- Drug in liver Disease Pre operatively – **Fentanyle**
- Drug Contraindicated in Liver Disease – **Pentazocin > Paracetamol**
- Hepatic Encephalopathy Progress by – **Diuretic >Paracetamol**
- **NM Blocker in Asthma –Suxamethonium > Cisatracurium**
- **NM Blocker in Liver disease – Atracurium**
- Pancuronium Eliminated by -- **Kideny (80 percent)**
- Rocuronium Eliminated by – **Liver (75-90 percent) & Kidney**

CamScanner

- ✓ Diazepam Act through – **Interferon**
- ✓ Morphine Release – **Histamine**
- ✓ Terbutaline cause – **Fetal Hypoglycemia and Maternal Hyperglycemia**
- ✓ **Analgesic** effect of TCA – **1-2 weeks (Davidon)**
- ✓ **Antidepressent** effect of TCA — **3-4 weeks**
- ✓ Safe Analgesic dose NO – **25 ppm**
- ✓ Safe Analgesic dose NO **In 8h – 25 ppm**
- ✓ Safe Analgesic dose NO **In 24h – 100 ppm**
- ✓ Morphine Decrease -- **Apnea Threshold**
- ✓ Local Anasthesia cross Placenta by – **Simple Diffusion**
- ✓ Scrulfate doesn't Let Cimetidine to absorb
- ✓ Cimetidine Decrease Scrulfate Metabolism
- ✓ More Local Anesthetic in Blood in – **Intercostal Block**
- ✓ Delayed Respiratory Depression – **Morphine >Fentanyl**
- ✓ Therapeutic Index Determine – **Drug Safety**
- ✓ Potency Determine -- **Dose**
- ✓ Benzodiazepine Cause Hypotension in – **Hypovolumia > Old age**
- ✓ Highly **Selective** COX2 – **Celecoxib**
- ✓ Highly **Potent** COX2 – **Meloxicam**
- ✓ **Irreversible** COX 1 & COX 2 inhibitor – **Aspirin**
- ✓ **Reversible** COX 1 & COX 2 inhibitor – **NSAID**
- ✓ **Low** dose Aspirin inhibit – **TXA2**
- ✓ Cardiotoxic – **Bupivacaine**
- ✓ Priaprism by – **Trazodon**
- ✓ Gingival Hyperplasia by – **Phenytoin**
- ✓ Pulmonary Fibrosis by – **Methotrexate**
- ✓ Cardiomegalay by– **Adriamycin**
- ✓ Kernicterus by – **Sulphonamide**
- ✓ Reversible Oligospermia by– **Salfasalazine**
- ✓ Indirect Hyperbilirubinemia by – **Methyldopa**
- ✓ Orange urine by – Rifampicin
- ✓ Gout by – **Pyrazinamide**
- ✓ Methmoglobenemia by – **Procain**
- ✓ Red Man Syndrome by – **Vancomycin**
- ✓ Grey Man Syndrome by – **Amidaron**
- ✓ Gray Baby Syndrome by – **Chloramphenicol**
- ✓ Aluminum hydroxide (No receptor in Body) cause – **Constipation**
- ✓ Magnesium Hydroxide cause -- **Diarrhea**
- ✓ **Low** estrogen OCP cause – **Hepatic Adenoma**
- ✓ **High** Estrogen OCP **Prolong/Long** term use cause in post menopausal – **Endometrial CA**
- ✓ **Estrogen** Containing OCP **Increase risk** of – **Thromboembolism(DVT)**
- ✓ **Mixed HRT** containing both Estrogen and Progesterone cause – **Breast CA(Robins) > DVT**
- ✓ Digoxin Toxicity increase by – **Hypokalemia & Alkalosis**
- ✓ Digoxin Toxicity Cause – **Hperkalemia**
- ✓ Thiazide cause – **Hypokalemia> Hyperglycemia > Hyperlipidemia> Hyper uricemia >Hyper calcemia**
- ✓ **Thrombocytopenia by** – Heparin > Quinidine > Thiazide > Chloramphenicol
- ✓ Diazepam Side effect – **Loss of Beat to beat Variabili**[illegible]

CamScanner

Thiopental – Action Terminated by Redistribution in Tissue and fat(FA)

ctamine

- Profound Analgesia
- Anasthetic in Asthma
- Cause Bronchodilation
- Raised ICP(Avoided in Head Injury)
- Used in Burn Patient and Haemodynamically Unstable
- Increase HR and BP (Sympathomimetic)

bothane

- Increase Cerebral Blood Flow
- Cause Malignant Hyperthermia
- Cause Skeletal Muscle Contractions
- Dissociates on Light

upivacaine

- First Sign of toxicity – Perioral paresthesia > Ringing in Ear
- Intermediate Sign – Hypotension
- Late Sign of toxicity – Arrhythmias
- Serious Side effect Arrhythmia
- Safe Dose 150mg
- Rupivacain preferred over it because of Less CNS toxic

CamScanner

PHARMACOLOGY

1- Antipsychotic effect of phenothiazine due to:
A- Block muscarinic receptors in corpus striatum
B- Block dopamine receptors in corpus striatum
C- Block dopamine receptors in limbic system
D- Block adrenergic receptors
E- Block Serotonin receptors in limbic system
Ans: C

2- Nifedipine causes refractory hypotension when given with halothane due to:
A- Causes tachycardia
B- Causes vasoconstriction
C- Has long action when given orally
D- Has synergetic effect on calcium channels
Ans: D > C

3- Which fibres sensation will be lost first after administration of local anaesthetic agent?
A- A delta
B- B fibers
C- C fibers
D- A beta
Ans: C

4- Drug given in HOCM:
A- Verapamil
B- Diltiazem
C- Amlodipine
D- Nifedipine
Ans: A

5- Patient with Hypotension, shouldnot give benzodiazepine in which case?
A- Hypovolemic
B- Obese
C- Age > 65
D- Pregnancy
Ans: A

6- Gonorrhoea DOC is
A- Penicillin G
B- Ceftriaxone
C- Gentamycin
D- Niclosamide
Ans: B

7- Narcotic with the lowest pKa is:
A- Sufentanil
B- Morphine
C- Fentanyl
D- Meperidine
Ans: B (Alfentanil > Remifentanil > Morphine >Sufentanil>Fentanil> Meperidine)

8- Propranolol acts on:
A- Muscarinic receptors
B- Beta 1 receptors
C- Beta 2 receptors
D- Alpha receptors
Ans: B > C (Although it is a non-selective beta blocker and acts on both B1 and B2)

9- Class III anti-arrythmics include:
A- Procainamide
B- Disopyramide
C- Flecainide
D- Quinidine
E- Dofetilide
Ans: E (Other drugs of this group are Amiodarone, Ibutilide and Sotalol)

10- A drug is given by error that causes further increase in calcium level in blood. The drug is:
A- Loop diuretic
B- Thiazide diuretic
C- Calcitonin
D- Etodine
Ans: B (Thiazide diuretics cause Hypercalcemia while Loop diuretics are used in Hyperclacemia)

11- Most beneficial drug in the event of acute coronary syndrome:
A- Heparin
B- Warfarin
C- Aspirin
D- Streptokinase
E- Atorvastatin
Ans: C

12- Pregnant lady gets pain, swelling & redness in the left leg. Which drug should be prescribed to prevent the adverse complications?
A- Aspirin
B- Clopidogrel
C- Warfarin
D- Heparin
Ans: D (IV Heparin)

13- Treatment of Nausea and Vomiting:
A- H1 Blockers Only
B- Steroides
C- Metochlorpomide is less effective in cytotoxic induced emesis as compared to Ondasteron
Ans: C

14- Anti-manic effect of lithium takes how much time:
A- 10 days
B- 15 days
C- 5 days
D- 21 days
Ans: A(7-10 days)

CamScanner

Which of the following has bronchodilator effect?
Albuterol
Ipratropium
Ipratropium
Atenolol
Ans: A

Regarding Esmolol:
Increase elimination by renal failure
Increase conc in hepatic failure
Is not cardio selective
Decreased elimination in renal failure
Ans: D

Dose of streptomycin in 45 yers old 45 kg wt:
75g./kg
3gm/kg
0.75 to 1gm
Acc to plasma level
Ans: C

Patient with backpacks, diarrhea, fatigue. Stool culture shows binucleate organism with 5 flagella. Which drug you'll give?
Stibogluconate
Metronidazole
Sulphadoxine
Quanidine
Ans: B

Which one does not cause gynaecomestia?
Griseofulvin
Androgen
Spironolactone
Ketoconazole
Digoxin
Ans: B

Explanation:
- Drug doesnot cause gynaecomastia is Androgen
- Digoxin , Giersofluvin , Cimitidine , Ketoconazole , Sironolactone cause gynaecomastia

DOC of status epilepticus is which of the following?
Topiramate
Ethosuximide
Lamotrigine
Lorazepam
Oxazepam
Ans: D

Aspirin overdose antidote is
Bicarbonate
Naloxone
Glucose
Nacl
Cacl2
Ans: A

Explanation:
- Aspirin or salicylate overdose – $NaHCO_3$
- TCA overdose treatment – $NaHCO_3$
- Opioids overdose treatment – Nalaxone.

22- Female patient on HRT having risk of which of the following:
A- Ovarian CA
B- Endometrial ca
C- Breast CA
D- Headache
E- Thromboembolism
Ans: E

Explanation:
- Low estrogen OCP cause – Hepatic Adenoma
- High Estrogen OCP Prolong/Long term use in post-menopausal – Endometrial CA
- Estrogen Containing OCP Increase risk of – Thromboembolism(DVT)
- HRT increase Risk of – DVT (Thromboembolism)
- Mixes HRT containing both estrogen and progesterone cause – Breast CA (Robins)

23- A young farmer while working in field became unconscious & starts frothing from mouth, which of the following will also be present?
A- Dry Skin
B- Flaccid Paralysis
C- Bilateral pinpoint pupil
D- Dilated pupil
E- Babinski positive
Ans: C

24- Female with severe abdominal pain diagnosed as a acute biliary colic given morphine as analgesic. What additional drug beside morphine will provide good analgesic relief?
A- Pethidine
B- Hyosine butylbromide
C- Diazepam
D- Amoxicillin
E- Paracetamol
Ans: B(Davidson)

Explanation:
- Drug used for Abdominal pain and Billiary colic – Hyoscine
- Drug used for Acute pancreatitis – Pethidine >Morphine
- Drug used post-operative – Ketorolac >Pethidine
- Drug Used Post-operative in asthmatics – Pethidine

25- A patient with plasmodium vivax, on anti-malarial drug, presented with jaundice and dark urine, which drug is responsible:
A- Chloroquine
B- Doxycycline
C- Artemether
D- Arsinate
Ans: A

CamScanner

26- **DOC in heart failure is**
A- Dopamine
B- NE
C- Epinephrine
D- Atropine
Ans: A

27- **Which of the following increases blood pressure?**
A- Alpha 1 agonist
B- Beta2 agonist
C- Alpha 2 agonist
D- M3 agonist
Ans: A

28- **Dicyclomine act on which receptor**
A- 5HT3
B- M3
C- D2
D- D1
E- 5HT2
Ans: B

29- **Androgen cause bone growth up to limit:**
A- Cause epiphyseal plate closure
B- Cause atrophy of bone
C- Cause diphysis closure
D- Cause hypertrophy of bone
Ans: A

30- **Most appropriate route for antidote:**
A- IM
B- IV
C- S/C
D- Oral
E- Rectal
Ans: B

31- **Treatment of MRSA is:**
A- Penicillin
B- Fusidic acid
C- Gentamycin
D- Co-amoxiclav
E- Azithromycin
Ans: B

Explanation:
Vancomycin >Cotrimaxol>Fusidic acid

32- **Hepatic encephalopathy occurs due To which drug?**
A- Brufen
B- Paracetamol
C- Aspirin
D- Diclofenac
E- Moloxicam
Ans: B

Explanation:
- Hepatic encephalopathy caused by – Paracetamol
- Hepatic encephalopathy progress/Woarsen by – Diuretic

33- **Patient of pheochromocytoma for BP control what should be given?**
A- Alpha blockers
B- Beta blockers
C- Alpha & beta blocker
D- Captopril
E- Lisinopril
Ans: C

34- **Mechanism of action of PTU is**
A- Convert iodine to tyrosine
B- Inhibits Thyroid hormone synthesis
C- Encourage Synthesis of thyroxine
D- Increase T4
E- Increase Blood flow
Ans: B

Explanation:
- PTU Block thyroid peroxidase
- TU Inhibit oxidation of Iodide
- PTU Inhibit organification of Iodine
- PTU inhibit thyroid harmone synsthesis

35- **Mechanism of action of captopril:**
A- Decrease Angiotensin 1
B- Decrease Angiotensin 2
C- Increase Angiotensin 2
D- Increase Renin
Ans: B

36- **Naturally occurring anti thrombotic:**
A- Streptokinase
B- Enoxaparin
C- Heparin
D- Plasminogen
E- Fibrin
Ans: C

Explanation:
- Natural antithrombin – Heparin
- Natural thrmobolytic – Plasminogen

37- **Side effect of aspirin is**
A- Coma
B- Alkalosis
C- Diarrhea
D- Constipation
Ans: B

38- **Which of following is used for Reversal of warfarin toxicity immediately?**
A- Vitamin K
B- FFP
C- Protamine
D- Blood

CamScanner

anation:
Immediate – FFP
Long acting antidote – Vitamin K

What is the side-effect of Morphine?
Hypotension
Rashes
Diarrhea
Constipation
: D

Patient on ATT with big toe swelling most likely due to:
Rifampicin
Streptomycin
Ethambutol
Pyrazinamide
Isoniazid
: D

anation:
Isoniazid – Peripheral neuropathy
Rifampicin – Red/Orange Urine
Ethambutol – Optic neuritis
Pyrazinamide– Hyperuricemia (Gout)

Patient was taking some medicines On ECG it showed 2 p waves and then QRS complex what is the mechanism:
Drug induced
Heart failure
Digoxin toxicity
Arrythmias
: A

Which ATT drug causes peripheral tingling sensation?
Rifampicin
Ethambutol
Isoniazid
Pyrazinamide
Streptomycin
: C

Drug of choice for traveler's diarrhea is
Diphenoxylate
Loperamide
Ceftriaxone
Metronidazole
Azithromycin
: A

anation:
Norfloxacin >Diphenoxylate

Pseudo membrane colitis DOC is:
Azithromycin
Ofloxacin
Vancomycin
Pencillin
Ciprofloxacin
: C (No metronidazole option)

Explanation:
- DOC for C. Difficile – Metronidazole > Vancomycin (Levinson)
- DOC for mild C. Difficile – Metronidazole (Levinson)
- DOC for Severe and resistant C.Difficile – Vancomycin (Levinson)

45- Diabetic patient presented with morning hyperglycemia due to poorly control Diabetes.Now, Suitable management will be
A- Regular Insulin
B- Short Acting Insulin
C- Long Acting Insulin
D- Regular + Intermediate Insulin Twice
E- NPH
Ans: D

46- Which drug decreases triglyceride levels the most?
A- Rosuvastatin
B- Cholestyramine
C- Niacin
D- Atorvastatin
E- Fenofibrate
Ans: E

Explanation
- **Best lower triglycerides**
- Fibrates > niacin > statins
- **Best lower LDL cholesterol**
- Statins > Ezetimibe > Bile resins > niacin
- **best raise HDL**
- Niacin > fibrates > statins > fish oil

47- Thrombocytopenia is caused by:
A- Quinidine
B- Thiazide
C- Insulin
D- ACEI
E- Chloremphenicol
Ans: A

Explanation:
Heparin > Quinidine > Tbiazide > Chloramphenicol

48- A patient was having inflammatory bowel disease and diagnosed acute inflammatory bowel disease which of the following is the treatment of acute ulcerative colitis?
A- IV Corticosteriods
B- Sulfasalazine
C- Salicylates
D- Aminophyline
E- Doxyfyllin
Ans: A

CamScanner

Explanation:
- In Acute or Severe Ulcerative Colitis: IV corticosteroids.
- In other or chronic cases 5 Amino Salicylates, sulfasalazine being a prototype

49- Drug that increases gastric emptying and increases lower esophageal sphincter tone?
A- Anticholinergic
B- Metachlopromide
C- Loperamide
D- Cimetidine
E- Fimotidine
Ans: B

50- Patient with suspicion of drug intake presented to ER with deep respiratory rate of 6/mins the most likely drug responsible is:
A- Aspirin
B- Morphine
C- Nalbuphine
D- Pentazocine
E- Phenobarbitone
Ans: B

51- A Patient Presented with billiary colic pain. He was Given Dicyclomine at which receptor it act by which it reduces Smooth muscle contraction and relieves abdominal pain?
A- M1
B- M2
C- M3
D- B1
E- B2
Ans: C (Katzung)

Explanation:
- It blocks M1 and M3
- Antispasmodic M3
- Ant Secretory M1

52- A 40 year old housewife is suffering from gastric ulcer and Toothache A safe drug to give her relief from Toothache would be:
A- Aspirin
B- Ibuprofen
C- Indomethacin
D- Paracetamol
E- Diclofenac
Ans: D

53- A patient having rheumatic heart disease with associated mitral stenosis what prophylaxis before dental surgery should be given?
A- Azithromycin
B- Ampicillin
C- Ceftriaxone
D- Ciprofloxacin
E- Ofloxacin
Ans: B(Kaplan)

54- DOC for Meningitis in old Age is:
A- Ceftriaxone
B- Cefotaxime
C- Amoxcillin
D- Ampicillin
E- Ciprofloxacin
Ans: A

55- A farmer while spraying pesticides to the fields developed the signs and symptoms of toxicity alongwith increased secretions. What is used for the organophosphate poisoning?
A- Atropine
B- Barbiturate
C- Naloxone
D- Lidocaine
E- Procain
Ans: A (No pralidoxime option)

Explanation:
- For Symptoms Reversal – Atropine
- Specific Antidote – Pralidoxime

56- Patient taking ATT develop joint pain and uric acid level 12. Which drug must be stopped?
A- Isoniazid
B- Rifampicin
C- Ethambutol
D- Pyrazinamide
E- Streptomycin
Ans: D

Explanation:
- Isoniazid – Peripheral neuropathy
- Rifampicin – Orange Color urine
- Ethambutol – Optic neuritis
- Pyrazinamide – Hyperuricemia

57- Dopamine half-life 2 min, Steady state reached in how much time?
A- 9 min
B- 36 min
C- 12 min
D- 14 min
E- 5 min
Ans: A

Explanation:
- Steady state: 9 min
- Half-life: 2 min

58- Local anesthetic affects which of the following fibers first?
A- A fibers
B- B fibers
C- C fibers
D- A delta
E- A beta
Ans: C

CamScanner

planation:
Type A>B>C affected by – Pressure
Type B>A>C affected by – Hypoxia
Type C >B>A affected by – Anesthesia

A patient with acute cholelithiasis which pain killer should be given?
Morphine
Paracetamol
WeakMeu 2 Agonist
Pethidine
ns: D

Digoxin toxicity caused by:
Hyperkalemia
Hypocalcemia
Loop Diuretic
Spiranolactone
ns: C

planation:
Digoxin toxicity caused by – Hypokalemia, Alkalosis and drug causing hypokalemia
Digoxin toxicity itself cause – Hyperkalemia

Drug absorption following oral route is increased if drug is:
Lipophobic
Hydrophilic
Lipophilic
Having First Pass effect
Hydrophilic and Lipophobic
ns: C

Tachyphylaxis is:
Diminished response to a drug slowly
A drug interaction between two similar types of drugs
Diminished response to a drug rapidly
Drug Interaction of 3 Drugs
Increase Response to Drugs
ns: C

A patient of myasthenia gravis is being treated with Neostigmine and Atropine but is still symptomatic. Test dose of Edrophonium relieves symptoms. What is a reasonable approach for future management:
Increase Neostigmine dose
Decrease Neostigmine dose
Increase Atropine dose
Decrease Atropine dose
Replace Atropine with Edrophonium
ns: A

64- **A 45 year patient on digoxin therapy for CCF develop sign and symptoms of digoxin toxicity blood analysis show digoxin level to be at 4 nanogram/ml.digoxin plasma half-life 36 hours.how long should digoxin be withheld so that plasma levels fall to a safe and therapeutically effective concentration of 1 nanogram/m?**
A- 48hrs
B- 36hrs
C- 60hrs
D- 72hrs
E- 92hrs
Ans: D

Explanation:
- Digoxin total is 4 and Half life is 36h
- After One half life digoxin will be half from 4 to 2
- In another half life from 2 to 1
- Two half life used 36+36=72h

65- **A lady presented with painful vesicles on skin with clear fluid filled lesions. What is the treatment of choice?**
A- Amphotericin b
B- Acyclovir
C- Vancomycin
D- Ciprofloxacin
E- Nystatin
Ans: B (HSV)

66- **A 53 year old lady is concerned about her strong family history of Breast Cancer and IHD. Her sister died of MI She is also concerned about osteoporosis, which prophylaxis drug will you give for post-menopausal related osteoporosis:**
A- Calcium and Vitamin D
B- Bisphosphonates
C- Combined hormonal replacement therapy
D- Raloxifene
E- Iron
Ans: D

67- **Which Drug is safe in Liver decompensation disease?**
A- Diazepam
B- Oxazepam
C- Fentanyl
D- Phenobarbital
E- Lidocaine
Ans: B(FA)

Explanation:
Lorazepam, oxazepam and Temazepam Safe in liver disease

68- **Drug treatment of choice in patient with chronic liver disease who present with acute upper GI hemorrhage would be:**
A- Inj. Octreotide
B- Inj. Transxamic acid
C- Inj. Vitamin k
D- Inj. Omeprazole
E- Inj. Cobalamine
Ans: A

CamScanner

Explanation:
- DOC is Terlipressin >Octreotide
- In IHD Patient DOC is -Octreotide

69- Unconscious patient Presented with pinpoint pupils not responding to naloxone probably cause of his Condition is:

A- Heroine
B- Hashish
C- Morphine
D- Phenobarbitone
E- Codien
Ans: D

Explanation:
Nalaxone is antidote for opioids not for Barbiturates like phenobarbitone.

70- An elderly obese male was started on IV gentamicin BD post laparotomy. Which of the following is disturbed?

A- Distribution
B- Excretion
C- Absorption
D- Metabolism
E- Protein synthesis
Ans: A

Explanation:
- Obese – Distribution
- Non obese – Excretion

71- Female presented with galactorrhoea and pituitary mass, high prolactin level bromocriptine was given and galactorrhoea subsided MOA of bromocriptine:

A- Block action of prolactin on breasts
B- Inhibit release of prolactin from anterior Pituitary
C- Inhibit release of prolactin from hypothalamus
D- Binds to dopamine receptors and inhibits Pituitary prolactin secretion
E- Inhibit dopamine
Ans: D(Katzung)

72- A patient had used Carbonic anhydrase inhibitors for 4 weeks. What will be the effect?

A- Alkaline Urine
B- Increase HCO_3 in blood
C- Decrease PH of blood
D- Decrease HCO_3 in urine
E- Decrease PH of urine
Ans: A(FA)

Explanation:
Diuretics adverse effects
- **Acetazolamide** – Drowsiness , Alkalination of urine , Hepatic encephalopathy , Hyperchloremic acidosis
- **Thizides** - Hypokalemia > Hypergycemia > Hyperlipidemia > Hyperuricemia > Hypercalcemia
- **Spironolactone** – Hyperkalemia , Gynecomastia
- **Loop diuretics** – Hypokalemic metabolic alkalosis , hyperuricemia , Hypomagnesemia

73- A patient has been taking anti-tuberculous therapy for MDR-TB. His drugs regimen contains 6 drugs. The patient eventually develops difficulty in distinguishing red & green colours. Which of the following drugs is responsible for this effect?

A- Amiodrone
B- Pyrazinamide
C- Rifampicin
D- Ethambutol
E- Ciprofloxacin
Ans: D

Explanation:
- Isoniazid – Peripheral neuropathy
- Rifampicin – Orange Color urine
- Ethambutol – Optic neuritis

74- Drug of choice for tenia solium is

A- Albendazole
B- Vancomycin
C- Metronidazole
D- Prizaquental
E- Ciprofloxacin
Ans: D

75- Corneal Opacity is side effect of Which drug

A- Ethambutol
B- Chlorpromazine
C- Choloroquine
D- Thioridazine
E- Isoniazid
Ans: C

Explanation:
- Corneal opacity – Chloroquine
- Retina deposit – Thioridazine
- Lens deposit – Chlorpromazine

76- NSAID safe in lactating mother:

A- Toradol
B- Ibuprofen
C- Naproxen
D- Ketamine
E- Ketorolac
Ans: B

CamScanner

Analgesic effect of TCA is seen after?
1-2 weeks
5-6 weeks
10 days
6 days
4 week
Ans: A(Davidson)

Explanation:
Analgesic effect – 1-2 weeks
Antidepressant effect – 3-4 weeks

Patient was taking warfarin and after monitoring INR 2-3 is in normal range but then patient took another drug for chest infection due to which INR increase to 5 what is that drug?
A- Rifampicin
B- Clarithromycin
C- Penicillin
D- Ibuprofen
E- Naproxen
Ans: B

Which anti HIV drug causes pancreatitis and peripheral neuroptby?
A- Ropinavir
B- Tenofovir
C- Lemivudine
D- Diadanosine
E- Zidovudine
Ans: D

Patient after chemotherapy has nausea and vomiting which anti emetic Dr. will give?
A- Itopride
B- Metoclopromide
C- Domeperidone
D- Dimenhydrinate
E- Ondansetrone
Ans: E

Patient started warfarin has petechiac and ecchymosis due to deficiency of:
A- Protein M
B- Protein C deficiency
C- Factor 10
D- Factor 9
Ans: B

50-years female, diabetic for 20 years, abdominal distension after meals due to diabetic gastroparesis, which of the following is most suitable drug for treatment?
A- Metoclopramide
B- Omeprazole
C- Sucralfate
D- Ondensteron
E- Bismith
Ans: A

83- Patient is preparing for inguinal hernia after giving anaesthesia Surgery done. Nurse came Running and told Doctor that patient having respiratory distress and cyanosed this is due to:
A- Pancurium
B- Halothane
C- Rocurium
D- Sexamethonium
Ans: B

84- Patient given Antibiotic for 2 months now patient has fever and GIT symptoms like loose stool what other examination findings will be most likely:
A- Grey patch on Trachea
B- Pseudomembrane with white patch
C- Membranous Heart
D- Atrophic
Ans: B

85- Irreversible inhibitor of platelets is:
A- Paracetamol
B- Aspirin
C- Ibuprofen
D- Acetylcystiene
E- Diclofenac
Ans: B

86- Cimctidine interaction with warfarin:
A- Increase hepatic clearance of warfarin
B- Decrease hepatic clearance of warfarin
C- Increase half-life of warfarin
D- Decrease half-life of warfarin
Ans: B

87- Patient taking oral anti-coagulant test to monitor oral anti-coagulant warfarin is:
A- PT, APTT, INR
B- Platelets Count
C- ESR
D- CT
E- BT
Ans: A

Explanation:
- Heparin – APTT
- Warfarin – INR >PT

88- A patient presented with acute left ventricular failure & dyspnea which of the following is the drug of choice?
A- IV Furosemide
B- ACEI
C- ARBs
D- Beta blockers
E- Digoxin
Ans: A

CamScanner

Explanation:
This is case of Pulmonary Edema due to left ventricular failure & in acute condition of having dyspnea we give IV Lasix (Furosemide).

89- Which of the following is H2 blocker?
A- Cetirizine
B- Fexofenadine
C- Diphenhydrinate
D- Cimetidine
E- Carbamazepine
Ans: D

90- Patient known case of gastric ulcer now presents in OPD with complain of joint pain DOC will be:
A- Meloxicam
B- Ibuprofen
C- Celecoxib
D- Diclofenac
Ans: C

Explanation: The patient suffers from peptic ulcer that's why we can selectively give CoX-2 inhibitors for pain that's celecoxib.

91- Which of following 5HT antagonist used in patient with diarrhea?
A- Alosetrone
B- Diphenoxylate
C- Domiperidone
D- Omeparazole
E- Itopride
Ans: A

Explanation:
Alosetrone is 5HT3 antagonist and used in functional bowel disease.

92- DOC for primary generalized epilepsy and myoclonic seizures:
A- Phenytoin
B- Phenobarbital
C- Valproic acid
D- Tolbutamide
Ans: C

Explanaion:
- **Myoclonic seizure** - valproic acid , 2nd line – clonazepam
- **Absence seizures** – 1st line – Ethosuxamide , 2nd line – Valproic acid
- **Tonic clonic seizures** – phenytoin , carbamazepines , valproic acid

93- Catecholamine causes which of the following?
A- Vasoconstriction
B- Vasodilation
C- Decrease resistance
D- Miosis
Ans: A

94- Patient with chloroquine resistant falciparum malaria next drug given is:
A- Primaquine
B- Artemether with combination
C- Doxycycline
D- Azithromycin
Ans: B

95- For maximum effect to surpass bioavailabilty drug given via which route?
A- Orally
B- Sub lingual
C- Rectal
D- As a dermal patch
Ans: B

96- Heart (SA node) and uterine smooth muscle are supplied by adrenergic receptor are:
A- A1 and A2
B- B1 and A1
C- B1 and B2
D- B2 and B3
E- B1 and M1
Ans: C

97- Which drug causes tachycardia when given in usual dose?
A- Isosorbide dinitrate
B- Ca channel blockers
C- Propranolol
D- Paracetamol
E- Naloxone
Ans: A

98- Drug of choice for Cryptococcus meningitis:
A- Acyclovir
B- Amphotericin B
C- Penicillin G
D- Cefotaxime
E- Azithromycin
Ans: B

99- Diazepam relaxes skeletal muscle by acting on:
A- Cerebral cortex
B- Interneuron
C- NMJ
D- Muscle directly
E- Anterior horn
Ans: B

100- Which of the following decreases triglyceride level by decreasing the availability of fatty acids?
A- Statin
B- Gemfibrozil
C- Atorvastatin
D- Febuxostate
E- Cimetidine
Ans: B

CamScanner

Bioavailability of drug means:
Amount of drug reaching in systemic circulation in active form
Amount of drug eliminated
Amount of drug absorb
Amount that bypass liver
A

Old age woman with history of IHD presented with irregular heart beat and abnormal QRS complex. What is the drug of choice for her in Post MI?
Amiodarone
Lidocaine
Digoxin
Beta blockers
Verapamil
B

Multiple inactive and active forms of which drug?
Pencillin
Diazepam
Cephalosporin
Cetirizine
Chloremphenicol
B

Lithium should be stopped when?
When its level exceeds 1.2mmol
Coarse tremors
Nasuea and vomiting
Hypothyroidism
B

A patient after taking an analgesic overdose having hyperventilation, tachycardia and metabolic acidosis most likely drug responsible is:
Ketamine
Ibuprofen
Acetyl Salicyclic toxicity
Diclofenac
Paracetamol
C

NSAID that inhibits prostaglandins synthesis by acting on COX-2 rather than COX-1:
Aspirin
Meloxicam
Brufen
Corticosteroid
Diclofenac
B

107- 13 year old child present to the hospital emergency department with acute severe asthma having severe bronchoconstriction the most appropriate immediate treatment is:
A- Inhaled chromoglycate
B- Inhaled corticosteroid
C- Inhaled Albuterol
D- IV aminophylline
E- IV Albuterol
Ans: C

108- Anticoagulant warfarin action interacts with:
A- Carboxylation of Vit. K factors (2, 7, 9, 10)
B- Increase factor 2, 7, 9, 10
C- Factor 11
D- Thrombin
Ans: A

109- Regarding glucoronidation true is:
A- Increase absorption.
B- Increase solubility of drug there by its excretion
C- Is phase I reaction
D- For Lipid Soluble drugs
Ans: B

110- To treat acetaminophen poisoning which antidote is used?
A- Glutathione
B- Glutamine
C- HCO_3
D- N Acetyl cystem
E- Nalaxone
Ans: D (Katzung)

111- GLP I agonist and anti-diabetic is:
A- Pioglitazone
B- Rosizlitazone
C- Metformin
D- Exenatide
Ans: D

112- Regarding parkinson disease treatment:
A- Levodopa start early to decreased severity of disease
B- Give anticholinergics before giving levodopa
C- Delay giving Levodopa
D- Carbidopa with Dopamine Best Treatment
Ans: A

113- Airway resistance reduced via which receptor?
A- Beta 2 adrenergic receptors stimulator
B- Beta 1 adrenergic receptor stimulator
C- Alpha 2 receptor agonist
D- Alpha 1 receptor agonist
Ans: A

CamScanner

114- Elderly non diabetic hypertensive male was prescribed ace inhibitor and beta blocker. For hyperlipidemia statins given. Later diagnosed with Tb and ATT started. It was found that his ALT was raised. Which drug is safe to continue?

A- NSAID
B- Isoniazid
C- Pyrazinamide
D- Beta blocker
E- Statin
Ans: D

115- A patient came with Multiple sclerosis sign and symptoms now present with bed wetting which drug to give:

A- Oxybutynin
B- Methacholine
C- Carbamazepine
D- Phenytoin
E- Chlorpromazine
Ans: A

116- Which pharamcological agent when given in excess of higher doses cause grade 4 encephalopathy?

A- Amphetamine
B- Paracetamol
C- Nitrate
D- Flumezanil
E- Streptomycine
Ans: B

Explanation:
- Hepatic encephalopathy caused by – Paracetamol
- Hepatic encephalopathy progress/Woarsen by – Diuretic

117- Diabetic patient diagnosed with hypertension, which anti-hypertensive drug should be given initially:

A- Parazocin
B- Methyldopa
C- Hydralazine
D- Lisinopril
E- Propanolol
Ans: D

118- Patient brought to ER unconscious there is breathing problem Empty bottle of Aspirin found which one eliminate aspirin from body?

A- Bicarbonate administration
B- NH4Cl administration
C- IV hydration
D- Diuretic administration
E- Gastric lavage
Ans: A

119- All are chloropromazine side effect except

A- Porphyria
B- Convulsion
C- Cholestatic jaundice
D- Constipation
Ans A

120- Rational drug design is

A- Alteplase
B- Insulin
C- Acetazolamide
D- Gene therapy
Ans: A

121- Regarding pharmacokinetics, true is:

A- Reversal of hydralazine induced tachycardia with propranolol
B- Reversal of morphine induced CNS depression with naloxone
C- Increased toxicity of methotrexate with aspirin
D- Increased peripheral side effects of levodopa with carbidopa
Ans: C

122- Antidiabetic drug which causes sneezing and nasal congestion?

A- Metformin
B- Sitagliptin
C- Exenitide
D- Dapagliflozin
E- Insulin
Ans: B

123- 42-year-old para 3 reported heavy cycle menstrual bleeding for last 6 months her clinical examination is unremarkable she had recent a D&C histopathology showed early secretory phase endometrium. What is the first line treatment?

A- Antifibrinolytic agent
B- GnRHanalouges
C- Mefenamic acid
D- Danazol
Ans: C

124- A patient presented with fever neck stiffness and irritation. . Diagnose of bacterial meningitis was made. Which drug should be given?

A- Ceftriaxone
B- Cefotaxime
C- Amoxcillin
D- Ampicillin
E- Ciprofloxacin
Ans: A

CamScanner

What decreases penicillin excretion from kidney?
Probenecid
Erythromycin
Gentamicin
Benzathin penicillin
Penicillin G
s: A

A Patient presented with severe asthma FEVI less than 50 and he is cyanosed treatment given B2 agonist but not working what is next treatment?
Octerotide
Ipratropiwn
Broncbodilator
Steroid
Bronchodilator +steroid
s: B

Hemorrhagic cystitis is the side effect of which of following drug?
Cyclophosphomide
Methotraxate
Busulpban
Cisplatin
5 FU
s: A (Katzung)

A student came with pale nasal mucosa, nasal congestion and sneezing.O/E, Inflamed edematous nasal mucosa seen. He is having these symptoms since 3 months which among them will be effective now?
A. Fexofenadine
B. Montelocast
C. Ranitidine
D. Cimetidine
E. Nasal Corticosteroid
Ans: E

Max safe effective dose of local anesthetic could be achieved without epinephrine is:
A. Prilocain 150
B. Lidocaine 200
C. Bupivicainc 50
D. Rupivicaine 300mg
Ans: B

Leptin mechanism of action is:
A. GS
B. GI
C. Open ion channel
D. Close ion channel
E. Enzyme linked Receptor
Ans: E

Explanation:
Enzyme Linked Receptor has Harmone binding site outside and Enzyme Binding site inside. When Harmone bind Extracellualr portion of Receptor then Enzyme inside immediately activated this Docs not Required G Proteins e.g Leptin Receptor.

131- A patient already on sildenafil citrate for erectile dysfunction which drug should not be given for Lowering BP?
A- Nitrates
B- Hydralazine
C- Metoprolol
D- B blocker
E- Azithromycin
Ans: A

132- Which drug causes constipation?
A- Digoxin
B- Quinine
C- Chloroquine
D- Diamorphine
Ans D

133- Main advantage for using esmolol in anesthetic practice is due to:
A- No effect on intracranial pressure
B- No rebound hypertension
C- Reduction in plasma renin activity
D- Selective beta blocker activity
E- Short duration of action
Ans: E

134- Which of the following is Post op analgesic in asthmatics for Pain management?
A- Pethidine
B- Ketorolac
C- PCM
D- Brufen
E- Morphine
Ans: A (Oxford)

Explanation:
- Overall Ketorolac > Pethidine
- In Asthmatics Pethidine is safest analgesic (Oxford)

135- Which inhalation anesthetics cause greater cerebral blood flow increase?
A- Isoflurane
B- Halothane
C- Cocaine
D- Procain
E- Bupivacain
Ans: B

CamScanner

Decrease in vascular resistance increase cerebral blood flow in following order

- Halothane> Desflurane >Isoflurane >Sevoflurane

136- Benzodiazepines, Barbiturates and other Anti-convulsant work by acting on which Neurotransmitter?

A- GABA
B- Glutamate
C- Acetylcholine
D- Glycine
E- Epinephrine
Ans: A

137- Absolute contra indication of propofol:

A- Known hypersensitivity
B- Hypertension
C- Seizures
D- Hypotension
E- Infarct
Ans: A

138- Which of the following fluroquinolones is the drug of choice in case of Chlamydia infection?

A- Gemifloxacin
B- Nalidixic acid
C- Ciprofloxacin
D- Moxifloxacin
E- Ofloxacin
Ans: E

139- Therapeutic use of calcitonin is

A- Hyperparathyroidism
B- Paget's disease
C- Osteoporosis
D- Rickets
E- Osteopetrosis
Ans: B

140- Child presented with neck stiffness, fever, Headache and upper limb rash. What should be treatment in this patient?

A- 1st generation cephalosprin
B- 2nd generation cephlosporin
C- 3rd generation cephlosporin
D- Benzylpencillin
E- Vancomycin
Ans: D

141- Patient Has given Injection pencillin after which He develop SOB bronchoconstriction what should be immediate drug to be given for pencillin allergy:

A- IV ceftriaxone
B- IV Theophyllin
C- IV Dopamine
D- IM Nor Epinephrine
E- IM Epinephrine
Ans: E

Explanation:

- Cardiogenic shock – Dopamine & dobutamine
- Anaphylactic shock (Penicillin induced) – Adrenaline (Epinephrine)
- Septic shock – Nor adrenaline(Nor epinephrine)
- Cardiac arrest – Adrenaline
- Bradycardia – Atropine

142- Which of the following types of drugs will have maximum bioavailability?

A- Drugs with high first-pass metabolism.
B- Highly hydrophilic drugs.
C- Largely hydrophobic, yet soluble in Water
D- Chemically unstable drugs.
E- Drugs that are P-Glycoprotein substrates
Ans: C

143- A man present with hypercalcemia due to hyperparathyroidism which of following drug can increase calcium level more?

A- Iron
B- Thiazides diuretic
C- Osmotic agents
D- Loop diuretics
E- Spirano lactone
Ans: B

Explanation:

- Thiazide Diuretic is Ca saving increase Reabsorption of Ca from urine result in Hypercalcemia
- Loop Diuretic is Ca Wasting causing increase excretion of Calcium result in Hypocalcemia

---

144- Patient with anesthesia lignocaine mixed with adrenaline is given for hernia sac repair after patient went into respiratory depression and shock this is due to:

A- Local reaction of drug
B- Vasovagal response
C- Drug entered subarachnoid space
D- Drug in sabdeural spase
E- Systemic toxic effect of drug
Ans: E

145- Tamoxifen used for breast cancer risk will be:

A- Breast atrophy
B- Endometrial hyperplasia
C- Carcinoma in contralateral breast
D- Breast cyst
Ans: B

146- In appropriate dose of dopamine that increase renal flow:

A- Dose of 2-5 ug/kg/min
B- Dose of 5-10 ug/kg/min
C- Dose 10 ug/kg/min
D- Dose 15 ug/kg/min
Ans: A

CamScanner

Safety margin of drug can be assessed by:
- Therapeutic index
- Variability
- Bioavailability
- Therapeutic window
- Therapeutic effectiveness

Ans: A

Explanation:
- Therapeutic Dose – Potency
- Therapeutic Index – Safety
- Therapeutic Window – Range of Dose
- Therapeutic Effectiveness – Efficacy

148- Longest acting insulin is:
A- Glargine
B- Bovine ultralente
C- NPH
D- Regular Insulin
E- Lispro
Ans: B (Davidson)

Explanation
- Rapid acting - insulin aspart, insulin lispro ,insulin glulisine
- Intermediate acting-Humulin® NPH
- Long acting – insulin glargine , insulin detmir

149- A Patient has multiple drug allergies now he has been given Xylocain what will occur now?
A- Rash
B- Mild tachycardia
C- Fever
D- Mild Syncope
Ans: D

150- Chlorpromazine most common toxic effect is:
A- Anxiety
B- Hallucinations
C- Dystonia
D- Constipation
Ans: C

151- Hypoglycemic effect of sulponylurea is increased by:
A- Aspirin
B- OCP
C- Thiazide
D- Phenyl butazone
E- Steriods
Ans: D

152- Class III antiarrhythmic drug is:
A- Timolol
B- Labetalol
C- Carvidilol
D- Sotalol
E- Clarythromycin
Ans: D

Explanation:
Class I Agents (Na channel blockers)
Group IA – Quinidine, Procainamide, Disopyramide, Imipramine , Amiodarone
Group IB – Lidocaine, Mexiletine, Phenytoin
Group IC – Flecainide, Encainide , Propafenone
Class II agents (Beta blockers)
Metoprolol, Atenolol, Esmolol , Propranolol
Class III Agents (K+ Channel blockers)
Breytilium, Ibutilide, Amiodarone , Sotalol
Class IV Agants (Ca channel blockers)
Verapamil, Diltiazem, Amiodarone

153- Best time for IV prophylactic administration of antibiotics is:
A- 6h before surgery
B- 12h before surgery
C- After the surgery
D- On first dressing
E- On operating table
Ans: E

154- Drug causing skin blisters?
A- Calcium channel blocker
B- Beta blocker
C- Digoxin
D- Sulfonamides
E- Furosemide
Ans: D

155- A patient came with poisoning with signs of opioid like poisoning, when given nalaxone, the symptoms improve. What can be the probable cause?
A- Diuretic
B- Phenothiazine
C- Phenobarbitone
D- Alcohol
E- Pentazocin
Ans: E

Explanation:
- Nalaxone is antidote for opioids and opioids like poisoning and pentazocin is opioid.

156- NO max limit for 8 hours is
A- 20ppm
B- 80ppm
C- 100ppm
D- 50ppm
E- 200ppm
Ans: A (Prefer 25)

Explanation:
- Safe Analgesic dose NO – 25 ppm
- Safe Analgesic dose NO In 8h – 25 ppm
- Safe Analgesic dose NO In 24h – 100ppm

157- A women who take benzodiazepines under goes surgery
A- Require more dose of anesthesia induction or duration
B- Less dose needed
C- Change of anesthesia needed
D- No change needed
Ans: A

CamScanner

158- Tramadol mechanism of action is
A- Alpha agonist
B- Weak meu receptors agonist
C- Strong meu receptors agonist
D- Intermediate nieu receptors agonist
E- Beta agonist
Ans: B(FA)

Explanation:
- Morphine – Strong Meu agonist
- Tramadol – Weak Meu agonist

159- A 30 year old women diagnosed case of prolactinoma was prescribed bromocrptine the mechanism of action of bromocriptine in the treatment of practinoma is:
A- Direct inhabiting the prolactin release from pituitary
B- Enhance the activity of dopamine
C- Inhibit the prolactin release from hypothalamus
D- Inhibit Dopamine
Ans: B (Katzung)

160- Lucovorin is antidote for:
A- Paracetamol
B- Cyclosporin
C- Methotrexate
D- Trustuzumab
E- Cyclophosphamide
Ans: C(Katzung)

161- 3 day after delivery severe pain at episiotomy site mother is also lactating DOC will be
A- Ibuprufen
B- Neproxen
C- Piroxicam
D- Morphine
E- Pethidine
Ans: A

162- Actinomycin D act by:
A- Attach to rRNA and inhibit poly merase
B- Activate rRNA
C- Prevent RNA Synthesis
D- Prevent DNA Synthesis
Ans: C

163- Function of letrozole clomiphene citrate is:
A- Stimulate ovulation
B- Release of GnRH
C- Inhibit FSH
D- Stop GnRH
E- Inhibit LH
Ans: B>A(Katzung)

Explanation:
- Clomiphene is a nonsteroidal compound. By selectively blocking estrogen receptors in the pituitary, clomiphene reduces negative feedback and increases FSH and LH output.
- The increase in gonadotropins stimulates ovulation

164- 1gm lignocaine 2 percent vial will contain:
A- 50 ml
B- 100ml
C- 25ml
D- 5ml
Ans: A

165- Which of following Chemo drug causes cardiomyopathy?
A- Adriamycin
B- Bleomycin
C- Cylcosporin
D- Methotrexate
E- Cisplatin
Ans: A (FA)

166- Non contraceptive benefit of OCP is:
A- Protection from ovarian cancer
B- Protection from breast cancer
C- Protection from cervical cancer
D- Protection from Vaginal cancer
Ans: A

167- Dopamine receptor characteristic feature:
A- D2 subtypes are pharmacologically same
B- D1 receptor cause serotonin release
C- D1 act via adenylate cyclase
D- D1 cause extrapyramidal symptoms
Ans: C

168- Caesium is radioactive substance used for radiotherapy caesium 137 half-life is:
A- 10Y
B- 20Y
C- 30Y
D- 40Y
Ans: C

169- Insulin injection given in DKA, most immediate response is:
A- Increased blood potassium
B- Increased urinary ketones
C- Hyperglycemia
D- Increase CO_2
E- Increase PH
Ans: E

CamScanner

A man after RTA got a head injury which is to be stitched 10 inch wound/laceration which anesthesic agent will best for suturing the wound?
250 ml of 2% lignocaine with adrenaline
4.5% with adrenalin
250 ml of 0.5% lignocaine with adrenaline
150 ml lignocain
Plain lignocain
A

Narrow therapeutic index seen in
Desipramine
Penicillin
Lithium
Diazepam
C

There is risk of nausea and vomiting in patient which anaesthetic drug can be used preoperatively?
Propofol
Ketamine
Diazepam
Nitric oxide
A

DOC for partial seizures in neonates:
Carbamazepine
Teril
Ethosuximide
Phenobarbital
D

Furosemide is DOC in:
Acute pulmonary edema
MI
Shock
Stroke
A

H2 receptor blocker is not of therapeutic value in which condition:
Uncomplicated ulcer
Esophagitis
Mendelson syndrome
Zollinger ellison syndrome
D

Potency of volatile anesthestic depends on:
Mac
Lipid solubility
Albumin
Water solubility
B

MAO and TCA common effect and Interaction is:
Physical dependence
Toxicity related with certain foods
Insomnia
Hypoglycemia
B

178- A women has tooth extraction & she was prescribed calcium, multivitamins & antibiotic. She was already on candesartan. candesatran effects efficacy of which antibiotic?
A- Metronidazole
B- Amoxicillin
C- Ciprofloxacin
D- Erythrocin
E- Oxytetracyclin
Ans: E

179- Severe hyperkalemia associated With which of following
A- Suxamethonium given in recent burn
B- Metabolic alkalosis
C- Increase secretion of Na
D- Increase Secretion of HCO3
E- Increase Secretion of H ions
Ans: A

180- Metabolic acidosis caused by which of the following?
A- Acetazolamide given for glaucoma
B- Furosamide
C- Thiazide
D- Spironolactone
Ans: A

181- MOA of theophylline is:
A- Phosphodiesterase inhibition
B- Alpha agnosit
C- ACE inhibitor
D- Venodilator
E- Bronchial constriction
Ans: A

182- Spectrophotometer obeys which of the following law?
A- Beer lambert law
B- Boyles law
C- Henry law
D- Dalton law
E- Ohm law
Ans: A

183- Volatile anesthetic with CA cbanel blocker given can cause which of following?
A- Hypotension
B- Hypertension
C- Hyperthermia
D- Hypoxia
E- Septic shock
Ans: A

184- Side effect of first-generation histamine H1 antagonists is:
A- Aplastic anemia
B- Vomiting, tinnitus, decreased hearing
C- Sedation
D- Gastric ulcers and upper gastrointestinal bleeding
Ans: C

CamScanner

185- Cabergoline MOA is:
A- B1 agonist
B- B2 agonist
C- D1 agonist
D- D2 agonist
Ans: D

186- Mechanism of action of acetazolamide is:
A- Increase H+ secretions
B- Decrease Na/K activity
C- Decrease H+ secretions and increase Na/K activity.
D- Increase Na secretions
E- Decrease NA secretion
Ans: C

187- Opioid induce vomiting through which of the following?
A- 5HT2
B- D2
C- D1
D- Chemoreceptor trigger zone
Ans: D

188- In treatment of SAH, which CCB can be used?
A- Nifedipine
B- Verapamil
C- Diltiazem
D- Nimodipine
Ans: D

189- A Patient underwent surgery DOC for 3rd Post op moderate pain is which of following?
A- Sublingual buprenorphine
B- Morphine
C- Fentanyl
D- Ketorolac
Ans: D

190- Competitive neuromuscular blocker safe in renal impairment function:
A- Rapacurium
B- Pancuronium
C- Atracurium
D- Rocuronium
Ans: C

191- Longest acting NM blocker is:
A- Doxacuriun
B- Panocurium
C- Cisatracurium
D- Suxamethonium
Ans: B

192- Methemoglobinemia caused by which of following drug?
A- Pilocarpine
B- Cocaine
C- Procaine
D- Rupivacain
Ans: C(Prefer Prilocain)

193- You have given a dose of suxamethonium in a patient now you have to give another dose; you are very cautious regarding second dose because of:
A- Hyperkalemia
B- Histamine release
C- Malignant hyperthermia
D- Bradycardia
E- Muscle fasciculations
Ans: D (Katzung)
Explanation:
- Hyper kalemia and malignant hyper thermia common side effect
- For 2nd Dose bradycardia repeatedly observed especially in neonate or in 2nd dose in less than five minutes.

194- Sulphonmaide act on bacteria by inhibiting synthesis of which of following?
A- Inhibit cell wall synthesis
B- Inhibit synthesis of folic acid
C- Inhibit folinic acid
D- Inhibit protein synthesis
Ans: B

195- Gentamycin contraindicated in which of the following?
A- Patient with renal impairment
B- Liver failure
C- Gastritis
D- Hepatitis
Ans: A

196- Which one is bactericidal?
A- Penicillin
B- Macrolide
C- Sulphonamide
D- Clindamycin
E- Carbapenam
Ans: A

Bacteriostatic	Bacteriocidal
Chloramphenicol	Aminoglycoside
Clindamycin	Cephalosporin
Erythromycin	Fluoroquinolones
Sulfamethoxazole	Pencillin
Tetracycline	Metronidazole
Trimethoprim	Vancomycin

197- Sevoflurane with nitrous oxide give how much MAC?
A- 0.66
B- 0.88
C- 0.43
D- 0.89
Ans: A

CamScanner

Paramagnetic cylinder used for what?
A- N_2O
B- CO_2
C- Halothane
D- Oxygen
Ans: D

199- Why isoflurane used in neurosurgery?
A- It does not produce epileptic activity on EEG
B- Can be used at high concentration without raising ICP
C- It does cause High Blood flow
D- It quickly metabolize
Ans: A

200- Person developed influenza and flu in winter season. Drug suitable for flue is?
A- Acyclovir
B- Amantadine
C- Oseltamavir
D- Valcyclovir
Ans: C

201- Half-life of a drug 10 hours when will it reach steady state at?
A- 40 hour
B- 60 hour
C- 70 hour
D- 30 hour
E- 20 hour
Ans: A (4-5 half-life)

202- Initiation of labor can be inhibited by giving:
A- Oxytocin
B- LH
C- Progesterone antagonist
D- Prostaglandin E2 antagonist
E- FSH
Ans: D

203- Pre operatively patient was given metachlopromide for nausea but it didn't work what will you give post operatively?
A- Ondasetron
B- Metachloromide
C- Hydralazine
D- Omeperazole
Ans: A

204- The drug use a prophylactic for acute mountain sickness?
A- Feurosemide
B- Acetazolamide
C- Mannit
D- Ondasetron
Ans: B

205- Drug of choice in meningitis:
A- Penicillin G
B- Benzylpenicillin
C- Cefazolin
D- Azitheomycin
Ans: A

206- Which of the following drug is a procarcinogen?
A- Cyclophosphamide
B- Cyclosporin
C- Gentamycin
D- Azitheomycin
Ans: A

207- Which antibiotic work by inhibiting bacterial cell wall?
A- Chloramphenicol
B- Aminoglycosides
C- Penicillins
D- None
Ans: C

208- Which of the following exerts its effect on kidneys?
A- Clonidine
B- Propronalol
C- Guanethidine
D- Bumetanide
Ans D

209- Patient taking Lithium immediately stop lithium when patient has?
A- Polydipsia
B- Hypothyroidism
C- Fine tremors
D- Polyphagia
Ans: C

210- Epinephrine is not given for hypotension in a patient who is already taking?
A- Lithium
B- Amitriptyline
C- Chlorpromazine
D- Diazepam
E- Imipramine
Ans: B>E

211- Child with fever. Doctor prescribed Acetaminophen 500 mg qid given. What will be the effect to eliminate this drug?
A- Glucorinadation
B- Oxidation
C- Methylation
D- Water conjugation
Ans: A

CamScanner

Explanation:
- **Glucoronidation** – Morphine , Acetaminophen , Diazepan
- **Acetylation** – Sulphonamides , Isoniazid
- **Methylation** – Dopamine , Epinephrine , histamine
- **Water conjugation** – Carbamezepine
- **Glutatbione conjugation** – Ethacrynic acid
- **Glycine conjugation** – Salicylic acid

212- Amoxicillin is given in combination with clavulanic acid because:
A- Activate Beta Lactamase
B- Inhibit Beta Lactmase
C- Decrease its effect
D- Better Absorption
Ans: B

213- Which one Act through adenyl cyclase?
A- Histamine
B- Salbutamol
C- Ipratromium
D- NO
Ans: B

214- A patient presented with fever neck stifness and irritation. Diagnose of Fungal meningitis was made. Which drug should be given?
A- Ceftriaxone
B- Cefotaxime
C- Pemcillin
D- Amphotericin
Ans: D

215- Bronchodilation is via B2 by:
A- Ipratropium
B- Salbutamol
C- Atenolol
Ans: B

216- Which one of the Following drug can cause Thyroid problem?
A- Cyclosporine
B- Cyclophosphamide
C- Lithium
D- Ampicillin
Ans: C (FA)

217- A patient having Big toe swelling and Pain from months which Drug can be helpful in this?
A- Allopurinol
B- Steroid
C- Morphine
D- None
Ans: A

218- Cephalosporin mechanism of action:
A- Inhibit Protien
B- Inhibits transpeptidase
C- Inhibit Lipid
D- Inhibit Mycolic acid
Ans: B

219- Drug interfering with Diabetes therapy:
A- Loop diuretic
B- Hydrochlorothiazide
C- Captopril
D- Spiranolactone
Ans: B

220- A 32 years old G2+P1+0 presented with Gestational Amenorrhea of 33 weeks. She complains of severeheadache and vomiting. Her Bp is 180/90mmHg. She also has history of Fits during last pregnancy. Which antihypertensive drug you will immediately give to this patient?
A- MgSo4
B- Hydralazine
C- Methyl Dopa
D- Captopril
E- Diuretic
Ans: B (Ten Teachers)

Explanation:
- DOC in pregnancy induced HTN – Labetalol >Methyldopa
- DOC in Hypertensive Emergency – Hydralazine >Labetalol
- For Eclampsia – MgSO4
- In this question asking drug to immediate lower BP so Hypertensive emergency asked so Hydralazine.

221- Permethrin 1 percent used in school epidemic:
A- Influenza
B- Dermatitis
C- Scabies
D- Fungal infection
Ans: C

222- Bromocriptine given to hyperprolactinemia pt MOA:
A- Decrease prolactin secretion from hypothalamus
B- Decrease prolactin secretion from Ant pituitary
C- Agonist to dopamine receptor
D- Antagonist to dopamine receptor
Ans: C>B (Katzung)

Explanation:
It is Dopamine agonist thus will decrease prolactin release from anterior pituitary.

223- Longest acting local anesthesia:
A- Bupivacaine
B- Ropivacaine
C- Prilocaine
D- Bupivacaine with adrenaline
Ans: D

CamScanner

Gentamycin given 80 years old after abdominal surgery what will be affected?
Distribution n metabolism
Excretion
Absorption
Ans: B
Explanation:
If obese patient, then – Distribution

Aspirin decreases fever by decrease in:
Prostaglandins
Leukotriens
Histamine
Infection
Ans: A

Loop diuretic act on
DCT
Thick ascending limb
CD
CCD
Ans: B
Explanation:
- Osmotic diuretics – Mannitol, Urea, Glycerol – PCT
- Carbonic Anhydrase inhibitors - Acetazolamide – PCT
- Loop Diuretic- Furosemide, Ethacrynic acid – Thick ascending limb
- Thiazide Diuretic – Hydrochlorothiazide's – Early DCT
- Potassium sparing diuretics - Spironolactone – CD

227- **A patient know diabetic presented in emergency with high glucose and in hypoglycemic coma what type of insulin should be given immediately?**
A- Lante insulin
B- NPH insulin
C- Regular insulin
D- Glargine
Ans: C

228- **Retinal Deposit seen due to which drug?**
A- Chloroquine
B- Thioridazine
C- Chlorpromazine
D- Chlorpheramine
Ans: B
Explanation:
- Corneal Opacity – Chloroquine
- Retina Deposit – Thioridazine
- Lens Deposit – Chlorpromazine

229- **Shortest acting benzodiazepine:**
A- Alprazolam
B- Temazepam
C- Triazolam
D- Midazolam
Ans: D (D >C)

Explanation:
Long Acting – Diazapam , Clonazepam , Quazepam
Intermediate acting – Temazepam, Alprazolam
Short acting – Lorazepam, Estazolam
Shotest acting – Midazolam , Triazolam

230- **Anti-anginal drug that causes constipation and edema**
A- Hydralazine
B- Nitroglycerin
C- Hydralazine
D- Propronalol
Ans A

231- **Antibiotic given for gram positive organism:**
A- Vancomycin
B- Pencillin
C- Ceftriaxone
D- Sulphonamide
Ans: B

232- **Diclofenac acts on:**
A- COX – 1
B- COX – 2
C- COX – 3
Ans: B >A

233- **Atropine MOA is:**
A- Block Acetylcholine
B- Increase Acetyl cholinesterase
C- Increase Elastase
Ans: A

234- **10 year old child came with his mother in od with complain of itching and redness of eyes. Diagnosis of herpes simplex keratitis was made. What is the treatment of choice in this patient?**
A- Acyclovir
B- Valcyclovir
C- Triflouridine
D- Gamcyclovir
Ans: C

235- **Which of the following selectively inhibits COX – 2?**
A- Ibuprofen
B- Aspirin
C- Meloxicam
D- Diclofenac
Ans: C (No option of celecoxib)

236- **DOTS stand for:**
A- Directly observed treatment short course
B- Directly observed therapy
C- Distant observation treatment standards
Ans: A

CamScanner

237- A45 year old obese male with RBS of 390mg/dl and no other complication got diagnosed with DM2. It's his first visit to the physician. What drug should be started on in addition to dietary and lifestyle modification?

A- Insulin and sulfonylurea
B- Sulfonylurea only
C- Biguanides
D- Biguanides and sulfonylurea
E- Insulin
Ans: C

238- Hepatic granuloma is caused by

A- Alcohol
B- Cimitidene
C- Amidarone
D- Metronidazole
Ans C

239- Drug contraindicated in CLD:

A- Oxazepam
B- Pentazocain
C- Barbiturate
D- Lorazepam
Ans: B

Explanation:

- Safe in Liver disease – LOT (Lorazepam, Oxazepam and Temazepam)
- Contraindictaed in CLD – Pentazocin >PCM

240- Drug used for angina which is not a vasodilator?

A- Nitroglycerine
B- Metoprolol
C- Propanolol
Ans: B

241- Frequent side effects of theophylline?

A- Seizures
B- Nausea and vomiting
C- Diarrhea
D- Rash
Ans: B (Katzung)

242- Patient has urea 150, creatinine 2.0 which drug is contraindicated?

A- Azithromycin
B- Ciprofloxacin
C- Gentamycin
D- Amoxicillin
Ans: C

243- Which drug has no receptor?

A- Aluminum hydroxide
B- Magnesium Sulphate
C- Itopride
D- Cimetidine
Ans: A

244- DOC for CHF:

A- Furosemide
B- Nitrates
C- Beta blocker
D- Salbutamol
Ans: A

245- Atropine will act on:

A- Decrease sweat gland secretion
B- Mydriasis
C- Increase Swear gland Secretion
D- Increase GIT secretion
Ans: A

246- The most likely mechanism of action of cyclosporine following organ transplantation:

A- Blocks tissue responses to inflammatory mediators
B- Increases production of NK cells
C- Inhibits differentiation of T cell
D- Interferes with antigen recognition
E- Stimulates production of NK cells
Ans: C

247- Red man syndrome occur due to:

A- TertraCycline
B- Vancomycin
C- Amoxicillin
D- Azithrimycin
Ans: B

Explanation:

- Gray Baby Syndrome - Chloramphenicol
- Grey Man Syndrome – Amidarone
- Red Man Syndrome – Vancomycin

248- Side effects of anti hyperlipidemic:

A- Nause
B- Rash
C- GI Disturbance
D- Sedation
Ans: C

249- A pregnant lady has mitral stenosis. To prevent atrial fibrillation, treatment is:

A- Heparin IM
B- Heparin IV
C- Oral antigulant
D- Heparin and oral antigulant
Ans: B

250- Aspirin overdose side effect:

A- Hypothermia
B- Alkalosis
C- Diarrhea
D- Death
Ans: B

251- HTN in pregnancy which Drug is DOC:

A- Methyl dopa
B- Captopril
C- Labetalol
D- Hydralazine
Ans: C>A

CamScanner

Aspirin toxicity what to give in order to increase urinary execration of aspirin:
Phosphate
Bicorbonate
NH4
Sodium
B

Half-life indicates:
Rate of Elimination of drug
Bioavailability
Drug reaching urine
Rate of formation of drug
A

Long term use of pyrazinamide is associated with increased risk of:
Hepatitis
Optic neuritis
Gout
Peripheral neuropathy
C

For the treatment of diabetic gastroperesis, which drug is most useful?
Prokinetics
Anti diarrheals
Octreotide
PPIs
A

Stimulation of beta adrenergic causes:
Vasoconstriction
Bronchoconstriction
Cardiac acceleration
Cardiac deceleration
C

Acidic drugs bind with:
Alpha 1 Glycoprotein
Albumin
Globulin
Heptoglobulin
Fibrinogen
B

What is the mechanism of action of loop diuretics?
Carbonic acid anhydrase inhibitor
Inhibit the reabsorption of sodium
Inhibit luminal Na K Cl Co transport
Increase reabsorption of sodium
C

Explanation:
on ascending limb of loop of Henley and the apical transport of sodium potassium chloride thus decreasing ECF, blood pressure cardiac output.

Why TB drugs are given in combination with other drugs?
To increase potency
To avoid resistance
To increase efficacy
To decrease side effects
B

260- Thiazide diuretics act on:
A- PCT
B- Early DCT
C- TAL
D- Collecting duct
Ans: B

Explanation:
- Acetazolamide – PCT
- Loop Diuretic – Thick ascending limb
- Thiazide Diuretic – Early DCT
- Spiranolactone – CD

261- Oral anticoagulant:
A- Heparin
B- Warfarin
C- Streptokinase
D- Vitamin K
Ans: B

262- Pain in cancer patients is controlled by:
A- Aspirin
B- Paracetamol
C- Morphine
D- NSAIDS
Ans: C

263- Common side effect of protamine sulphate:
A- Hypotension
B- Dizziness
C- Vomiting
D- Comma
Ans: A

Explanation:
Side effect-Hypotension
High level Toxicity - Bleeding

264- The earliest sign of lignocaine toxicity:
A- Dizziness
B- Tinnitus
C- Altered sensorium
D- Tachcardia
Ans: B

265- Drug induced SLE is the feature of:
A- Penicilline
B- Pethidine
C- Hydralazine
D- Propythiouracil
Ans: C

266- Side effect of tri cyclic antidepressants:
A- Chorea
B- Athetosis
C- Ataxia
D- Hallucinations
Ans: D

267- Which one of the following is not epileptogenic
A- Fluxoetine
B- Amitrypline
C- Imipramine
D- None
Ans: A

CamScanner

268- Women taking estrogen she is at risk of development:
A- Ovarian CA
B- Breast CA
C- Thromboembolism
D- Endometrial hypertrophy
Ans: C

269- Women taking mix hormone replacement therapy for some gynecological problem now she will be at risk of:
A- Endometrial CA
B- Breast CA
C- Ovarian CA
D- Cervix CA
Ans: B

Explanation:
- High Estrogen OCP Long term use in Post-menopausal cause – Endometrial CA
- Estrogen Containing OCP Increase risk of – Thromboembolism(DVT)
- HRT (Mixed) cause – Breast CA(Robins) > DVT

270- Mechanism of action of Spironolactone:
A- Decrease Potassium level
B- Aldosterone antagonist
C- Aldosterone agonist
Ans: B

271- Barbiturates contraindicated in:
A- Anxiety
B- Porphyria
C- Severe Insomnia
D- Depression
Ans: B

272- Anaphylactic shock after blood transfusion:
A- IV NE
B- IM adrenaline
C- Subcutaneous Adrenaline
Ans: B

273- Hydrochlorothiazide side effect is
A- Hyperkamelia
B- Hyper uricemia
C- Hypematremia
D- Hypocalcemia
E- Hypokalemia
Ans: E

Explanation:
- Hypokalemia > Hypergycemia > Hyperlipidemia > Hyperuricemia > Hypercalcemia

274- Female taking treatment of acne newborn infected cause is likely:
A- B12
B- Folic acid
C- Retinoic acid
D- Calcium
Ans:

275- Heparin requires a natural anticoagulant factor:
A- Factor X
B- Antithrombin 3
C- Anti thrombin 2
D- Factor 8
Ans: B

276- Site of sympathetic alpha receptor:
A- Lungs
B- Iris
C- Kidney
D- Liver
Ans: B

277- Characteristic of MRSA:
A- Sensitive to vancomycin
B- Sensitive to penicillin
C- Sensitive Azithromycin
Ans: A

278- Glyceryl nitrate causes which of the following?
A- Throbbing headache
B- Tachycardia
C- Vasoconstriction
D- Postural hypotension
Ans A

279- Steroid cause decrease in:
A- Neutrophil
B- Lymphocytes
C- Mast cell
D- Basophil
Ans: B

280- Which diuretic decrease urine calcium?
A- Loop
B- Thiazide
C- Torsemide
Ans: B

Explanation:
- Loop diuretic – Ca wasting (Increase in urine)
- Thiazide diuretic – Ca saving (Decrease in urine)

281- Therapeutic effect of loop diuretics:
A- Low blood volume
B- Low blood pressure
C- Decrease heart rate
Ans: A

282- Which of the following drug will lead to myocardial depression, when given before ketamine anesthesia?
A- Lithium.
B- NO
C- Morphine
D- Propanolol
Ans: D

CamScanner

Drug used in treatment of hirsutism:
Antiandrogens
Cryptoterone acetate
Diacrone
Estrogen
B

Mechanism of action of oral contraceptive pills is:
Inhibiting ovulation
Inducing endometrial atrophy
Increasing cervical mucus hostility
Inducing endometritis
Inhibiting prolactin
A

Post menopause women present with breast carcinoma is treated by:
Aromatase inhibitor
Tamoxifen
Metformin
Tolbutamide
A

A 40 years old man by keeping in mind that he is diagnosed case of Ischemic Heart Disease which antihypertensive you choose which also have vasodilatory property?
Isosorbide Dinitrate
Metaprolol
Nifidipine
Verapamil
B

Explanation:
Beta blockers are first choice in Hypertensive patient with ANGINA. In case of Hypertensive with Chronic renal failure Diuretics are first line therapy.

A Lady with Galactorrhea, Amenorrhea, Hypogonadism Diagnosed as Hyperprolactinoma what is it's treatment?
Bromocriptine
Levothyroxine
Insulin
Vit. D
A

Explanation: Bromocriptine is Dopamine (D2) Agonist which shrinks macroadenomas.
Levothyroxine

Why rupivacaine preferred bupivacaine?
Less Toxic
Shorter duration of Action
Long Duration effect
Causes Sedation
A

397- How total peripheral resistance is increased?
A- By sympathetic stimulation via Apha I receptors.
B- By sympathetic stimulation of B2 receptors
C- Parasympathetic Activation
D- Increasing Stroke Volume
Ans: A

398- An epileptic lady who currently on phenytoin has become pregnant .She is concerned about her medication in Pregnancy. Which of the following is correct?
A- Add lithium
B- Switch phenytoin
C- Increase dose of phenytoin
D- Add valproic acid
E- Replace with barbiturates
Ans: E

399- Theophylline, isopranaline side effect:
A- Tachycardia
B- Bradycardia
C- Hypertension
D- Hyperglycemia
Ans: A

400- Epinephrine decreases:
A- Heart rate
B- Contractility of heart
C- Basal metabolic rate
D- Cutaneous vascular dilation
E- Serum glucose concentration
Ans: D

401- Example of drug-receptor interaction:
A- Bradycardia by atenolol
B- Diuresis by mannitol
C- Protamine sulphate antagonism to heparin
Ans: A

402- Which of the following is used for spinal Anesthesia in a pregnant lady?
A- Bupivacaine
B- Rupvicaine
C- Lidocaine
D- Adrenaline
Ans: B

Explanation: Rupvicaine is used for spinal Anesthesia in a pregnant lady as its less cardio toxic.

403- Which of the following is a pro drug?
A- Enalapril
B- Clonidine
C- Salmeterol
D- Acetazolamide
Ans: A

CamScanner

Explanation: ACEI drugs are mostly prodrugs

404- **Short acting anti diabetic drug:**
A- Tolbutamide
B- Glargine
C- Bovine
D- Ultralente
Ans: A

405- **Cimetidine time of action if given intravenously:**
A- 10 – 45 Minutes
B- 45 – 60 Minutes
C- 60 – 90 Minutes
D- More than 90 Minutes
E- Within 5 minutes
Ans: A

Explanation:
- Time of Action: 10 – 45 Minutes
- Peak of action: 45 – 90 Minutes

406- **MOA of clonidine:**
A- Alpha 1 Antagonist
B- Alpha 2 Antagonist
C- Alpha 1 Agonist
D- Alpha 2 Agonist
Ans: D

407- **Methemoglobinemia side effect of which local anesthetic?**
A- Bupvicaine
B- Rupvicaine
C- Prilocaine
D- Lignocaine
Ans: C

408- **Which of the following drug will worsen angina?**
A- Propranolol
B- Vasopressin
C- Theophylline
D- ACEI
Ans: B

Explanation: Vasopressin > Theophyline > Propronolol.

409- **Highest chances of bleeding after some procedure:**
A- LMWH prophylaxis
B- Heparin after 1 hour of the procedure
C- Warfarin with normal INR
D- Antiplatelet
Ans: A

410- **MOA of PTU:**
A- Decrease thyroxin synthesis
B- Increase thyroxin synthesis
C- Increase rT3
D- Decrease TSH
Ans: A

411- **Why is glycopyrrolate preferred over atropine?**
A- Glyocpyrolate has faster onset of action than atropine
B- Glycopyrolate metabolizes more quickly than atropine
C- Atropine has faster action
D- None
Ans: A

412- **Following least likely causes hemolysis in G6PD patient**
A- Fava beans
B- Ciprofloxacin
C- Primaquine
D- Penicillin
Ans D

413- **Drugs which are excreted by active renal tubular secretion include?**
A- Benzyl penicillin
B- Streptomycin
C- Ethy alcohol
Ans: A

414- **Due to prolonged use of diuretics characteristic change in blood seen is?**
A- Dec. K
B- Dec. Na
C- Dec. Cl
D- Dec. Mg
Ans: B

415- **Hyperchloremic metabolic acidosis?**
A- Loop diuretic
B- Hydrochlorthiazide
C- Acetazolamide
D- Mannitol
Ans: C

416- **Ketamine used in burn dressing?**
A- It causes analgesia
B- Causes hypotension
C- Can be given IV
D- It doesn't causes addiction
Ans: A

417- **What is drug of choice for TIVA?**
A- Propofol
B- Midazolam
C- Triazolam
D- Prilocaine
Ans: B

418- **Best intercostal block for rib fracture is:**
A- Bupivacaine
B- Lignocaine
C- Prilocaine
D- Propofol
Ans: A

CamScanner

Adrenaline should not be used with lignocaine in which of following areas that causes. Ischemic injury?
Upper limb
Lower limb
Penis
Abdomen
Thigh
ns: C

Dose of atropine in bradycardia is:
1 mg
2 mg
0.5 mg
1.5 mg
ns: C

Best beta blocker in bronchogenic asthma patients?
Bisoprolol
Propranolol
Metoprolol
Carvidolol
ns: A

Mechanism of action of nerve gas in military war is:
Acetylcholine esterase inhibitor
Acetylcholine inhibitor
Pseudo choline inhibitor
None
Ans: A

Which of following drug is competitive antagonist of acetylcholine receptors?
Atropine
Cyclizine
Dopamine
Epinephrine
Ans: A

Action of Norepinephrine is terminated after being released from presynaptic terminal?
Reuptake
Metabolism by COMT
Metabolism by MAO
Diffusion into post synaptic space
Ans: A

Sympathetic supply of vessel is by:
Beta 1 adrenergic
Beta 2 adrenergic
Cholinergic
Muscarinic
Nicotinic
Ans: B

Hypotension after spinal anesthesia is due to:
Hypovolemic
Loss of vasomotor tone
Gain of vasomotor tone
Hypoglycemia
Ans: B

427- Labetalol acts on:
A- Alpha 1
B- Beta 1
C- Alpha + Beta receptor
D- Gamma
Ans: C

428- Volume of distribution is not affected by:
A- Age
B- Gender
C- Cardiac failure
D- Pregnency
E- Liver disease
Ans: B

429- Histamine releasing opioid:
A- Morphine
B- Tramdol
C- Codeine
D- Pethidine
E- ketorolac
Ans: A

430- Morphine is used in:
A- Biliary colic
B- Terminal cancer pain
C- Cor pulmonale
D- Alcohol intoxication
Ans: B

431- Antihypertensive acting directly on SA node:
A- Verapamil
B- Nifidipine
C- Amiloride
D- Foursemide
Ans: A

432- Common btw diazepam and chlorpromazine:
A- Sedation
B- Extrapyramidal side effects
C- Parkinsnism
D- Dependence
E- Skeletal ms relaxation
Ans: A

433- Alpha agonistic activity will cause?
A- Contraction of radial muscles of iris
B- Relaxation of radial muscles of iris
C- Increase renin release
D- Increase insulin release
Ans: A

434- First factor that goes in Vit K deficiency:
A- Factror 7
B- Factor 9
C- Factor 10
D- Factor 1
Ans: A

CamScanner

435- **Alpha-2-agonist used in ICU for sedation:**
A- Clonidine
B- Phentolamine
C- Phenoxybenzamine
D- Prazosin
E- Dexmedetomidine
Ans: E

436- **Edrophonium most common adverse effect:**
A- Diaphoresis
B- Dry mouth
C- Nausea
D- Euphorea
E- Sweating
Ans: C

437- **A man with Bp of 200/100mmHg and glucose level of 200mg/dl, which drug you will give:**
A- Linisopril
B- Furosamide
C- Amlodipine
D- Propanolol
Ans: A (doc in diabetes is ace inhibitor)

438- **Glucocorticoides does:**
A- Deamination of Amino Acids
B- Dec uptake of Amino acid in liver
C- Dec glucose utilization
D- Inc fatty Acid in blood
E- Inc protein Anabolism
Ans: C

439- **Osmotic drugs act on:**
A- PCT
B- DCT
C- CCT
D- CD
Ans: A

440- **Which drug cause Hypoglycemia most rapidly:**
A- NPH
B- Glibenclamide
C- Metformin
D- Insulin lente
Ans: B

441- **Class III Antiarrhythmics:**
A- Amiodarone
B- Quinidine
C- Lidocaine
Ans: A

442- **Which of the following is enzyme inducer?**
A- Chloramazepam
B- Phenobarbital
C- Gentamycin
D- Moxifloxacin
Ans: B

443- **Short half life means:**
A- Reaches stable dose quickly
B- Rapid clearance
C- Bioavailability
D- Freely filtered in glomeruli
Ans: B

444- **Drug of choice in actinobacterbounei:**
A- Imipenem
B- Tetracycline
C- Niclosamide
D- Prazequentil
Ans: A

445- **Rivastigmine:**
A- Acetylcholine estrase inhibitor
B- Mao inhibiter
C- Comt inhibitor
D- Prolactin inhibitor
Ans: A

446- **Skin pressed with sharp needle for sometime, redness due to:**
A- Histamine
B- Kinin
Ans: A

447- **Drug which affects thyroxine level:**
A- Potassium iodide
B- Prophylthiouracil
C- Propranolol
D- Iodine
Ans: B

448- **Cimetidine frequent side effect:**
A- Hepatic enzyme inhibition
B- Nausea vomiting
C- GERD
D- Heart burn
Ans: A

449- **All antisychotic same in:**
A- Antiemetic effect
B- Efficacy
C- Potency
Ans: A

450- **Drug excretion depends upon:**
A- Glomerular filtration
B- Fat soluble drugs increase
Ans: A

451- **Epinephrine do vasoconstriction by acting on which receptor?**
A- Beta 1
B- Beta 2
C- Alpha 1
D- Alpha 2
Ans: C

CamScanner

Nitroglycerin not given orally because:
Extensive 1st pass effect
Bioavailibility is low
Cant absorbed from gut
A

Substance causing peripheral neuropathy & degeneration of Myclin in CNS:
Lead
Asbestos
Silicosis
Berilium
Co
A

A 4 yr old boy got meningitis plus rash which antibiotic you should give?
Third generation cephalosporin
Second generation cephalosporin
First generation cephalosporin
Benzylpenicillin
Erythromycin
D

True about laxatives:
Lactuloseis digested by gut bacteria
Ispaghol husk is bulk forming laxative
Senna stimulates GI within 30 minutes
Lactulose is a sugar
Excessive use can lead to metabolic alkalosis & colonic atony
B

Aspirin and other NSAIDS work by acting on:
Lipoxygenase
Cyclooxygenase
HMG Co A reductase inhibitor
B

Drug used to treat Endometriosis:
Danazole
Flutamide
Tamoxifen
Ketoconazole
A

Theophyline interaction with which causes decrease its clearance:
Adenosine
Cimitidine
Beta bloker
Litium
A

MgSO4 action inhibited by:
Na
$CaCl_2$
K
B

460- Thiazides decrease clearance of:
A- Class 2 antidepressants
B- Phenothiazide antipsychotics
C- TCA
D- Lithum
Ans: D

461- Which drug if given intravenous causes 60% thrombophlebitis?
A- Oxazepam
B- I/v diazepam
C- Midazolam
D- Triazolam
Ans: B

462- One of the following is not Peicillinase Susceptible?
A- Cloxacilllin
B- Penicillin
C- Amoxicillin
D- Piperacillin
Ans A

463- Natural anticoagulant secreted by mast cell:
A- Heparin.
B- Plasminogen.
C- Warfiarin
D- Fibrin
Ans: A

464- A pregnant diabetic lady gave a birth to a child apgar score 4 and 6 in 1 and 5 min. Child with respiratory distress. What will you give patient before delivery to prevent the condition?
A- Hydrocortisone
B- Testosterone
C- Prostaglandin
D- Estrogen
Ans: A

465- 25 year old lady using some med presents with bradycardia, dec preload skin and increased peripheral vascular resistance the drug used is:
A- Epinephrine
B- Nor Epinephrine
C- Phenylephrine
D- Dopamine
E- Nifidipine
Ans: C

466- Nerve block for upper abdominal viscera:
A- Epidural
B- Celiac block
C- Lumbar sympathetic
D- Biers block
Ans: B

CamScanner

467- **Least likely cause of Pseudomembranous Colitis:**
A- Amikacin + Clavulanate
B- Clindamycin
C- Cefotaxime
D- Vancomycin
Ans D

468- **Patient with pulmonary edema treated with a vasodilator that also causes decrease in preload:**
A- Ace inhibitors
B- Sodium nitroprusside
C- Glyceryl Tr nitrate
D- Hydralazine
Ans: C

469- **HIV positive patient with chest infection is treated with:**
A- Folate synthesis inhibitor
B- Cell wall synthesis inhibitor
C- Protein synthesis inhibitor
Ans: A

470- **VEGFR inhibitor can be given in treatment of which of the following cancers of lung:**
A- Small cell carcinoma
B- Non-small cell carcinoma
C- Adenocarcinoma
D- Squamous carcinoma
E- Atypical carcinoid
Ans: B

471- **Minimum absorption of drug from its site of absorption, for its desirable effect occurs if:**
A- It undergoes extensive first pass metabolism
B- It makes active metabolites in liver
C- It has high renal clearance
D- Because drug has narrow therapeutic index
E- If it's used for local action
Ans: E

472- **A pregnant lady has presented to you with DVT. Regarding warfarin which is true?**
A- Not to be given in pregnancy
B- It is antagonized by vitamin k
C- It is rapidly antagonized by ffp's
Ans: A

473- **Verapamil MOA on heart:**
A- SA node automaticity
B- Increases intracellular calcium
C- Increases AV nodal delay
D- Decreases AV nodal delay
Ans: C

474- **Regarding adrenergic receptors:**
A- Parasympathetic postganglionic
B- Sympathetic postganglionic to SA node
C- Postganglionic to sweat glands
D- Preganglionic to sweat glands
E- Parasympathetic post ganglionic to skeletal muscles
Ans: B

475- **MOA of vancomycin:**
A- Acts on human cells but not bacterial cells
B- Converts DHF to THF
C- Causes change in bacterial component
Ans: C

476- **Antiarrhythmic class IC:**
A- Quinidine
B- Flecainide
C- Disopyramide
D- Lidocaine
Ans: B

477- **Which of the following is closely related with pharmacokinetics of drug?**
A- Adverse effects
B- Dose of the drug
C- Therapeutic index
D- Mechanism of action
E- Excretion of drug
Ans: E

478- **Halothane Anesthesia given to patient before surgery. His temperature rises and other symptoms. What was the cause?**
A- Skeletal muscles heat production
B- Malignant hyperthermia
C- It's a side effect of halothane
D- Halothane directly affect the set point of hypothalamus
Ans: A

479- **Ipratropium is preferred on B2 agonist in which:**
A- Status Asthamaticus
B- Chronic Asthma
C- Chronic bronchitis
D- Acute Asthma
Ans: C

480- **Histamine action is inhibited by:**
A- Cimetidine
B- Omeprazole
C- Lansoprazole
Ans: A

481- **Nor epinephrine acts on:**
A- Adrenergic
B- Beta
C- Beta 2
D- D1
E- D2
Ans: A

CamScanner

Which of the following drug is distributed mostly in body?
Mannitol
Cholroquine
Lidocaine
Captopril
Losartan
Ans: A

Before starting warfarin therapy what must be tested?
PT
APTT
CT
BT
Platelet count
Ans: A

Clonidine acts by:
Centrally acting alpha2 receptors
Centrally acting alphal receptors
Peripherally acting alpha2 receptors
Peripherally acting alpha2 receptors
Ans: A

Theophylline dose should be kept low in children because of:
High metabolic capacity
Absent liver
Low metabolism capacity of children
Absent spleen
Ans. C

MOA of tetracycline?
DNA dependant protein synthesis Inhibitor
30s blocker
70s blocker
cell wall inhibitor
Aminocyl t-RNA blocker
Ans. E

70 kg man drug volume of distribution in 8 KG what is correct?
Distribution in whole body water
Distributed in esf
Concentration is high in blood
Decrease protein binding
Ans. C

TCA not to be given with?
MAOI
Beta blocker
Cheese food
Caffeine
Ans: A

Mode of action of vancomycin?
Folic acid inhibitor
It acts on pathway unique to bacteria
It is metabolized by human cell but not bacteria
B

490- Juice inhibiting hepatic enzyme?
A- Grape fruit juice
B- Apple juice
C- Lemon juice
D- Orange juice
Ans. A

491- Steady state become double when
A- Loading dose double with continuous infusion
B- Drug given double
C- Drug given quadruple
Ans. A

492- For the closure of PDA which drug should be administered
A- Indomethacin
B- Prostaglandin
C- Epoprostrol
Ans: A

493- A person has severe big toe pain for last 15 days. Physician prescribed him Anti gout drug. Mechanism of action of Allopurinol is to inhibit:
A- G6PD
B- Xanthine dehydrogenase
C- Xanthine oxidase
D- Amylase
Ans. C

494- An epileptic child came to pediatrician with complain of depression. Anti-Depressant in epileptic child is:
A- Valproate
B- Amitriptyline
C- Olanzapine
D- Resperidone
E- Fluoxetine
Ans: E

495- Mechanism of action of NSAIDs is:
A- Inhibits COX I
B- Inhibits COX II
C- Inhibits prostacyclin
D- Inhibit arachnidonic acid
Ans: D

496- Side effects of botulism toxin intake?
A- Respiratory paralysis
B- CKD
C- Acute pain
D- Respiratory infection
Ans: A

CamScanner

497- A patient is taking aspirin for his heart problem. Which one of the following is the exact mechanism of action of Aspirin?

A- Decrease synthesis of prostaglandin only
B- Decrease synthesis of thromboxane A2 only
C- Decrease synthesis of TX A2 and PGs.
D- Decrease the production of COX2 only
Ans. C

498- Which of the following are not involved in renin inhibition?

A- ARBS
B- ACE
C- Aliskiren
D- CCB
Ans. D

499- Treatment of Obsessive-Compulsive Disorder:

A- Clomipramine
B- Penicillin
C- Aminoglycosides
D- Oxytocin
Ans. A

500- Short acting benzodiazepine:

A- Diazepam
B- Halothane
C- Phenobarbitone
D- Triazolam
Ans. D

501- Anthrax drug of choice:

A- Aminoglycosides
B- Penicillin
C- Penicillamine
D- Ciprofloxacin
Ans. D

502- Uses of H2 blocker (Cimetidine) before C section:

A- Volume plus acidity of gastric content decrease
B- Volume plus acidity of gastric content increase
C- Secretions increases
D- Volume increases
Ans. A

503- Drug not given in myasthenia gravis

A- Ceftriaxone
B- Chlorpromazine
C- Cephalosporin
D- Gentamycin
Ans: D

504- Side effects of recombinant human growth hormone therapy include:

A- Proliferative retinopathy
B- Aplastic anaemia
C- Leukemia
D- Creutzfeldt-Jacob disease
E- Benign Intracranial hypertension
Ans: E

505- A patient having CVP line in subclavian vein he develops fever and gram staining show gram positive cocci Drug of choice is:

A- Amoxicillin + clavulanic acid
B- Vancomycin
C- Ceftazidime
D- Imepenam
E- Piperacillin + Tazobectam
Ans: B

506- Drug leading to hyponatremia in SIADH

A- Na valproate
B- Carbamazepine
C- Phenytoin
D- Ethosuximide
E- Topiramate
Ans: B(FA)

507- Drug of choice for cardiogenic shock is:

A- Epinephrine
B- Nor epinephrine
C- Dopamine and Dobutamine
D- Atropine
Ans: C

Explanation:

- Cardiogenic shock – Dopamine & dobutamine
- Anaphylactic shock (Penicillin induced) – Adrenaline
- Septic shock – Nor adrenaline
- Cardiac arrest – Adrenaline
- Bradycardia – Atropine

508- A patient presented to you is a known case of mitral stenosis . and he is having chest pain. His all labs are normal BP is normal no trop raise ECG is normal which drug will you be choose for his chest pain

A- Digoxin
B- Beta blocker
C- Diueretics
D- Nitrates
E- Ketorolac
Ans:

CamScanner

509- Nocardia lung abscess treatment is
A- Trimethoprim SMX
B- Ceftriaxone
C- Apmhotericine
D- Flucanzole
E- Ciprofloxacin
Ans: A

510- A patient with diazepam overdose antidote is
A- Flumazenil
B- Barbiturate
C- Acetylcholine
D- Atropine
E- Epinephrine
Ans: A

511- Patient of staph aureus with skin abscess and high grade fever treatment by
A- Moxcillin
B- Arbencillin
C- Cloxacillin
D- Penicillin G
E- Pencillin V
Ans: C

512- Drug that gives mortality benefit in acute coronary syndrome
A- Beta blocker
B- Ca channel blocker
C- Aspirin
D- Clopidogrel
E- Renin inhibitor
Ans: A

513- Father brought his daughter diagnosed with typhoid what prophylaxis can be given to father
A- Ciprofloxacin 500mg once Weekly for 2 weeks
B- Ciprofloxacin 750mg BD for 4 Weeks
C- Chlorenphenicol
D- Cefixime
E- Trimethorpim/Sulfamethoxazole
Ans: B

514- A patient came in Unconsiousness pulsless state IV line not maintained ETT passed and CPR started. Which drug given through ETT is ineffective
A- Nalaxone
B- Lignocain
C- Diazepam
D- Norepinephrine
E- Epinephrine
Ans: D

515- Treatment of GB syndrome is
A- IV immuniglobulins
B- Steroids
C- Plasmapharesis
D- Splenectomy
Ans: C

516- Which drug is secreted in saliva
A- Streptomycin
B- Amikacin
C- Amoxillin
D- Erytbromycin
E- Clindamycin
Ans: D

517- 6-month baby diagnosed with whooping cough(Pertussive) drug given for this is
A- Meronem
B- Erythromycin
C- Ampicillin
D- Cefixime
E- Ciprofloxacin
Ans: B

518- The drug useful in the treatment of an acute attack of migrain after paracetamol inffective is?
A- Colchicin
B- Propranolol
C- Sumatriptan
D- Ergotamine
E- Diazepam
Ans: C

519- Thiazide diuretic cause hypotension by
A- Negative Na receptor
B- Increase Sodium delivery
C- Decrease Cardiac output
D- Increase Cardiac output
Ans: C

520- Hemodynamically unstable patient, anaesthesia induction DOC is:
A- Etomidate
B- Diazepam
C- Lorazepam
D- Oxazepam
Ans: A

521- A girl during exercise getting dyspnea presents to the emergency with wheezing. She developed breathlessness during aerobic class on presentation, chest wheezing was present and spo2 was 97 percent What is the sultable treatment
A- Inhaled beta 2 agonist
B- Inhaled theophylline
C- Inhaled ipratropium bromide
D- IV steroid
Ans: A

CamScanner

522- Salbutamol act on
A- Non selective B2
B- Selective B2
C- Non selective B1
D- Selective B1
E- Non selective B3
Ans: B

523- Patient came In OPD with recurrent calcium stones what will you give for treatment ?
A- Acetazolamide
B- Mannitol
C- Loop diuretics
D- Potassium sparing diuretic
E- Thiazide diuretics
Ans: E

524- Patient diagnosed case of migraine with aura using paracetamol and ibuprofen but symptoms are not resolving what should be your next step ?
A- Propanole
B- Cetrizine
C- Sumatriptan
D- Atenolol
Ans: C

525- A patient is knows case of CKD which drug is contraindicated to be used in this patient
A- Azithromycin
B- Paracetamol
C- Gentamycin
D- Clithromycin
E- Ibuprofen
Ans: C

526- Use of Diuretic causes loss of which of following
A- Potassium
B- Sodium
C- Magnesium
D- Phosphate
Ans: B

527- Muscle Relaxant which contain Steroid Structure is
A- Acetylcholine
B- Procain
C- Rocuronium
D- Lidocain
Ans: C(Big Katzung)

Explanation:
Non Depolirizing muscle relaxant has steroid structures include
- Rocuronium
- Pancuronium
- Pipecuronium
- Vecuronium

528- Antibiotic interacting with vitamin k and causing hypo prothrombinemia and bleeding
A- Procain penicillin
B- Cefazolin
C- Amoxicillin
D- Metronidazole
Ans: B

529- A man had pain in both the knees since 3 years which used to get worsened in the evening. He was taking ibuprofen to get pain relief but developed heart burn. What to do
A- Advise him intra articular steroid injections
B- Replace oral ibuprofen with ointment
C- Continue taking ibuprofen along with H2 blocker
D- Switch ibuprofen to indomethacin
E- Switch ibuprofen to Paracetamol
Ans: E

530- NSAID cause gastric ulcer by blocking:
A- Leukotriens
B- Platelets
C- Prostaglandins
D- Prostacyclin
Ans: C

531- A Patient Having Dyspnea presented in emergency with Breathlessness and and having Wheeze and given Ipratropium Bromide what is mechanism of it in Asthma
A- Anti cholinergic preventing antigen antibody reaction
B- Anti cholinergic preventing the action of inflammatory mediations
C- Anti muscarinic preventing bronchoconstriction
D- Antinicotinic preventing inflammation
Ans: C

532- Patient have restlessness bronchospasm and Difficulty in breathing after 10 mins of Lidocaine infusion due to
A- Cardiac Shock
B- Septic Shock
C- Allergic reaction
D- Hypovulemia
Ans: C

CamScanner

533- Local anasthesia Toxicity causes which of the following:
A- Hypertension
B- Bradycardia
C- Cardiac arrest
D- Perioral Parasthesia
Ans: D

534- Half life is
A- Time constant to full drug elimination
B- Time constant to half of the drug elimination
C- Time needed for drug absorption
D- Time needed for drug distribution
Ans: B

535- Maligant hyperthermia occurs due to which of the following:
A- Procain
B- Lidocain
C- Bupivacain
D- Succinylcholine
Ans: D

536- Hyperkalemia associated with
A- Succinylcholine
B- Procain
C- Lidocain
D- Ropivacain
Ans: A

537- Cimetidine Peak action is at
A- 60-90 min
B- 40-60 min
C- 100-120 min
D- 20-30 min
Ans: A
Explanation:
- Half life - 2h
- Onset -30 min
- Peak -45 to 90 min
- Duration - 4 to 5 h

537- Patient lying in OT During Anasthesia Patient develop SVT, DOC will be
A- Beta blocker
B- Ca channel blocker
C- Nifedipine
D- Amidarone
Ans: B

538- Warfarin monitoring is done by
A- APTT
B- BT
C- PT
D- Factor XII
Ans: C

539- Respiratory depression is caused mainly by which opioid receptor.
A- Delta
B- Kappa
C- Meu
D- Epsilon
Ans: C(Morphinc)

540- Percentage of oxygen in a mixture of 2% halothane and air is:
A- 20.4%
B- 15.4
C- 90
D- 80
E- 60
Ans: A

541- Alkalization of urine is helpful in toxicity of:
A- Morphine
B- Phenobarbitone
C- Spironolactone
D- Acetaminophen
Ans: B

542- Drug given in 70 year old Female with influenza is
A- Acyclovir
B- Valacyclovir
C- Ciprofloxacin
D- Ofloxacin
Ans: A

543- In Hyperkalemia drug which is Aldosterone antagonist and Contraindicated is
A- Furosamide
B- Hydrochlorothiazide
C- Spiranolactone
D- Mannitol
Ans: C

544- 16-year-old girl taking hydrocortisone not tolerating now will prescribe prednisolone. What dose should be given now she was taking hydrocortisone 20mg morning 10mg night.
A- 10mg
B- 2.5 mg
C- 7.5 mg
D- 5mg
E- 1mg
Ans: C

CamScanner

Explanation:
- Taking total Hydrocortisone 20mg morning +10mg night =30mg
- 1mg Prednisolon equal to 4mg Hydrocortisone it means 0.25mg prednisolone equal to 1mg Hydrocortisone
- Hence, **0.25 x 30=7.5**

545- Patient k/c of schizophrenia was in motionless state already on clozapine and was stable, stopped taking it month before. Now not taking any food or anything since one week. What could be the best treatment?
A- Restart clozapine
B- Antidepressants
C- Depot anti-psychotics
D- Shift to ECT
Ans: A

546- Which Antiemetic in parkinson's patient post cholecystectomy should be used?
A- Metaclopromide
B- Diphenhydramine
C- Omeprazole
D- Citrizine
Ans: B

547- Patient came with high B.P Management of pheochromocytoma is
A- Catecholamine
B- Esmolol
C- Phentolaminc
D- Dopamine
Ans: C

548- Which drug Binds to thrombin , despite of antithrombin 3 deficiency
A- LMWH &Streptokinase
B- Heparin
C- Warfarin &Heparin
D- Bivalirudin & Argatroban
Ans: D

Explanation:
Direct thrombin inhibitor
- Bivalirudin
- Argatroban
- Dabigatran
- Melagatran

Activate antithrombin 3 and inhibit factor 10
- Heparin
- LMWH

549- Patient Presented with rheumatic fever & Endocarditis. On discharge the drug to be prescribed for long term treatment to prevent recurrence would be?
A- Ceftriaxone
B- Procainamide Penicillin
C- Azithromycin
D- Benzathine Penicillin
E- Chloramphenicol
Ans: D

Explanation:
- Benzathine pencillin 1.2 million units IM monthly or Phenoxymethylpencillin orally 250mg 12hourly
- If allergic to pencillin Sulfadiazine or Erythromycin may be used

550- Ace inhibitors is given to a patient It increase renin & bradykinin By What mechanism bradykinin increase by this drug
A- Inhibit conversion of ang 1 to ang 2
B- Inhibit kallikrein mechanism
C- Stimulate kallikrein mechanism
D- By vasoconstriction
Ans: C

551- 65-year Elderly person present was started on certain drugs now he presented with acute complain of confusion and paradoxical agitation which drug cause it?
A- Citalopram
B- Fluoxitine
C- Amitriptyline
D- Fluoxamine
E- Benzodiazepine
Ans: E

552- Morphine attaches to which of the following receptors?
A- Alpha
B- Beta 2
C- M2
D- Meu
E- M3
Ans: D

Explanation:
- Morphine - Strong meu receptor
- Tramadol - Weak meu receptor

553- A homosexual person having foul smelling diarrhea flatulance O/E bowel sound exaggerated with no finding of any mass. Which drug should we start
A- Metronidazole
B- Mebendazole
C- Ciprofloxacin
D- Cefixime
Ans: A

554- A lady was given some injection on 14th day of menstrual cycle because of which her menstruation was absent Cause is
A- Inhibition of estrogen
B- Inhibition of FSH
C- Inhibition of prostaglandin E2
D- Inhibition Prostacycline
E- Inhibit Beta HCG
Ans: E

CamScanner

555- A 35 years old man died suddenly autopsy finding was normal toxicology shows cocaine and its metabolite in blood cause of death is
A- Myofibral disarray
B- Contractile band
C- Myocarditis
D- Pericarditis
Ans: B

556- Exogenous steroid intake will decrease which of the following:
A- TSH
B- Lymphocytes
C- FSH
D- GnRH
E- ACTH
Ans: E

557- A person took some medicine after which he developed high grade fever, tachycardia and muscle fatigue. Which receptors or ions are involved in this mechanism?
A- Na/k pump
B- Ca sarcoplasm
C- Ryanodine receptors
D- Dihydropyridine receptors
E- Acetylcholine gated ion channels
Ans: C

558- Administration of glucocorticoids cause decrease in:
A- Potassium level
B- Hepatic gluconeogenesis
C- Lipolysis
D- Peripheral glucose uptake into cells
E- Fatty acid uptake by liver
Ans: D

559- A 24-year-old male presented with fever, mild abdominal pain and had history of eating from restaurant. On examination physician noted mild splenomegaly and temperature pulse dissociation. Investigations were sent and he was labelled as a probable case of enteric fever. What is the drug of choice for such patient?
A- Ciprofloxacin
B- Ampicillin
C- Ofloxacin
D- Azithromycin
E- Ceftriaxone
Ans: A

560- Side effect of ACE inhibitors is:
A- Hyperkalemia
B- Hypokalemia
C- Hypercalcemia
D- Hyperglycemia
E- Hypocalcemia
Ans: A

561- Example of pharmacokinetic interaction among drugs is:
A- Shortening of action of procaine by adrenaline
B- Increased peripheral toxicity of levodopa with carbidopa
C- Increased toxicity of aspirin by methotrexate
D- Prevention of nitro-glycerine induced tachycardia by propranolol
E- Blockade of acetylcholine receptors by atropine
Ans: C

562- In diabetics, Insulin secretion is inhibited by:
A- Glucagon
B- Beta blockers
C- Epinephrine
D- Secretin
Ans: B

563- MOA of methyldopa:
A- Act on alpha receptors and vessels
B- Act on beta receptors in CNS
C- Inhibit non epinephrine on post ganglionic receptors
D- Alpha receptor agonist in CNS
E- Central dopaminergic agonist
Ans: D

564- Essential tremor treatment?
A- L dopa
B- Propanolol
C- Carbidopa
D- Amantadine
Ans: B

565- Which IV drug Causes increase abdominal movements?
A- Angiotensin
b- Bradykinin
C- Renin
D- Bethinicol
Ans: D

566- A Patient was diagnosed with Hypertension and treated with diuretic few months later patient present with big toe swelling and pain which drug is responsible?
A- Acetazolamide
B- Loop diuretic
C- Thiazide diuretic
D- Captopril
E- Propanolol
Ans: C

CamScanner

Explanation:
- Thiazide diuretic cause Hyperuricemia so lead to big toe swelling

567- Diabetic patient having CKD with leg ulcer which antibiotic to be given with dose adjustment?
A- Cephlaosporin
B- Co Trimoxazole
C- Meropenam
D- Imipenam
E- Linezolid
Ans: C

568- Which of following is Potassium sparing diuretic?
A- Thiazide
B- Loop
C- Amiloride
D- Furosamide
E- Mannitol
Ans: C

569- Good affect of aspirin in pregnancy is:
A- Cause Platelets aggregation
B- Cause Vasodilation
C- Inhibit platelets aggregation
D- Inhibit prostacyclin
Ans: C

570- Which opioid when given alone causes the most decrease in contractility of heart?
A- Fentanyl
B- Morphine
C- Pethidine
D- Imipramine
Ans: B

571- Patient is taking warfarin and started to bleed. What is treatment of it?
A- Heparin
B- Aspirin
C- TPA
D- Fibrinogen
Ans: D

572- Patient was taking carbamazepine started on another drug and noticed his seizure episodes increased this is due to which drug?
A- Amoxicillin
B- Tetracycline
C- Phenobarbitone
D- Chloremphenicol
E- Digoxin
Ans: C

573- A patient presented with crohn disease. for her treatment of remission corticosteroids are given what is best for maintenance of remission of her disease:
A- Methotrexate
B- Mesalamine
C- Azathioprine
D- Bedosinide
E- Ciprofloxacin
Ans: C

574- Patient having recurrent UTI, on culture green colony fruity smell which drug to use?
A- Metronidazole
B- Cefixime
C- Ciprofloxacin
D- Sulfonamide
E- Azithromycin
Ans: C

Explanation:
- This is pseudomonas infection
- For Pseudomonas DOC is - Ceftazidime
- For Pseudomonas UTI DOC is - Ciprofloxacin

575- Ace inhibitor given to patient what will happen?
A- Decrease renin and Bradykinin
B- Decrease angiotensin 2 and bradykinin
C- Increase renin and decrease bradykinin
D- Increase angiotensin 2 Decrease bradykinin
E- Increase bradykinin decrease angiotensin 2
Ans: E

576- Simvastatin MOA is:
A- Decrease intrahepatic cholesterol synthesis
B- Decrease triglycerides synthesis
C- Decrease intestinal cholesterol absorptio
D- PPAR alpha activation
Ans: A

577- Which of the following drug transiently depletes the Nor epinephrine stores:
A- Clonidine
B- Reserpine
C- Yuhimbine
D- Amphetamine
Ans: A

578- A boys having fever for which he took antibiotics after which he developed cola color urine the site of damage is:
A- Proximal tubule
B- Basement membrane
C- Glomerulus
D- DCT
E- CCD
Ans: B

579- Beta 2 agonist given to asthma patient Increase in FEV1 is:
A- 5 %
B- 12%
C- 15%
D- 20%
E- 10%
Ans: B(Davidson)

CamScanner

580- First pass metabolism occurs in:
A- GIT
B- Liver
C- Spleen
D- Kidney
Ans: B

581- An IDDM patient is suffering from hypertension the drug to be used with caution is:
A- Propranolol
B- Frusemide
C- Captopril
D- Verapamil
Ans: A

582- Cytotoxic drug paclitaxel is classified in which class?
A- Alkylating
B- Microtubule inhibitor
C- Anti metabolite
D- Acetylating
Ans: B

583- Young teen girl taking Danazol for endometriosis due to which side effect she stop taking danazol:
A- Hirsuitism
B- Depression
C- Weight gain
D- Hot flushes
E- Deepning of voice
Ans: E

Explanation:
- Increase in male characteristics like deepening of voice and increase in facial and body hair(Hirsuitism) alarming fro women so they stop taking this drug

584- Cisplatin mechanism of action:
A- Inhibit RNA
B- Cross link DNA
C- Inhibit protein synthesis
D- Act on nucleus
Ans: B

585- Hexamethylmelamine is an alkylating agent used in ovarian cancer. Its preferred route of administration is.
A- Intramuscular
B- Intravenous infusion
C- Intraperitoneal
D- Oral
Ans: A

586- Which drug is used in headache and contraindicated in peripheral vascular disease?
A- Aspirin
B- Ergometrine
C- Celecoxib
D- Sumatriptan
Ans: A

587- Patient with increase T3 Increase T4, dec TSH, what should be given:
A- Radioiodide
B- B blocker
C- PTU
D- Surgery
Ans: B

588- Cimetidine causes which of following
A- Decrease hepatic clearance
B- Agranulocytosis
C- Acne
D- Acidity
Ans: B

589- A lady presented with 42 HR, 90% O2 saturation and chest pain, After O2 what should be given?
A- Epmephrine
B- Atropine 0.3 mg IV
C- Adrenaline
D- Atropine 5mg IV
Ans: B

590- Drug of choice for atrial fibrillation rhythm cardioversion is:
A- Amiodarone
B- Flecainide
C- Sotalol
D- Captipril
Ans: A

Explanation:
- Post MI for general Arrythmia DOC is – Lidocain
- For rate control in AF – Beta blockers & Digoxin (Davidson)
- For rhythm control in AF with no Structural Heart Disease – Flecainide (Davidson)
- For Rhythm Control in AF with IHD or Structural heart disease – Amidarone (Davidson)

591- Dose of Paracetamol in 10kg child:
A- 75mg
B- 100mg
C- 125mg
D- 200mg
Ans: B

CamScanner

592- Cis atracurium is preferred over atracurium due to advantage of:

A- Rapid onset
B- Short duration of action
C- Less histamine release
D- Less cardiodepressant
Ans: C

593- Known diabetic patient on oral hypoglycemic drug came in emergency with low blood glucose Drug causing it:

A- Glibenclamide
B- Acarbose
C- Metformin
D- Insulin
Ans: A

594- Treatment for Raynaud phenomenon is:

A- CCB
B- Clonidine
C- Beta blocker
D- Phentolamine
Ans: A

595- Short acting local anesthetics suitable for C-section ?

A- Prilocaine
B- Lidocaine
C- Bupivacain
D- Mupivacain
Ans: A

596- Patient was known case of hypertension diagnosed to have thyroid problem which drug should be prescribed?

A- Metoprolol
B- Lisinopril
C- Thiazide
D- Valsartan
Ans: A

597- Patient known Case of hypertension came with complain of severe pain. What will be the treatment?

A- Diclofenac
B- Morphine
C- Pethidine
D- Aspirin
Ans: D

598- Patient was prescribed with antihypertensive presented with complain of cough which drug has this adverse effect?

A- Losartan
B- Captopril
C- Lisinopril
D- Amiloride
Ans: B

599- Patient known case of hypertension was prescribed antihypertensive present after few months with complain of burning and tingling sensation in feets what is cause of his complain?

A- Amiloride
B- Furosamide
C- Thiazide
D- Spiranolactone
Ans: C

Explanation :

- Due to thiazide induce hyperglycemia that cause numbness and tingling

600- Patient taking Omeprazole for Git disturbance having Joint space narrowing, Interphalangesl and distal pharyngeal swelling.Treatment should be:

A- Acetaminophen 1000mg tds
B- Prednisone 2.5mg
C- Morphine
D- Tramadol
E- Naproxen
Ans: A

601- Nature of Ergometrine is

A- Steroid
B- Alkaloid
C- Peptiglycan
D- Glucosidic
Ans: B

602- Diabetic patient having CKD with leg ulcer which antibiotic to be given with out dose adjustment

A- Cephlaosporin
B- Co Trimoxazole
C- Meropenam
D- Imipenam
E- Linezolid
Ans: E

Explanation:

- Without dose adjustment in CKD - Linezolid
- With dose adjustment in CKD - Meropenam >Imipenam

603- Poor wound healing by which of these

A- Control DM
B- Fruits
C- Steroids
D- Proteins
Ans: C

604- Prolonged use of corticosteroids

A- Worsen DM
B- Osteoblastic activity
C- Anemia
D- Malnutrition
Ans: A

CamScanner

605- **Heparin removes fat from plasma because it:**
A- Activate lipoprotein lipase
B- Release of lipoprotem lipase fron liver
C- it has negative charge
D- it has positive charge
Ans: A

606- **Theophylline causes more effects in children due to:**
A- Increase metabolism
B- Decrease excretion
C- Increase receptors
D- Decrease receptors
Ans: B

607- **Patient taking Isoniazid, Rifampicin, Pyrazinamide, ethambutol and Pyrodoxine for TB. Now presented with raised bilirubin and Deranged LFT. What to do now**
A- Stop Isoniazid, Rifampicin and add Strepromycin
B- Stop all and give second line only
C- Stop all and wait
D- Stop all and re introduce one by one after monitoring
Ans: D

608- **Side effect that is common to theophylline, nitroglycerine, isoprenaline and anti-histamine is:**
A- Throbbing headache
B- Postural hypotension
C- Reflex tachycardia
D- Gastric acid secretion
Ans: C

609- **Malignant hyperthermia patient, which inhaled anaesthetic to use:**
A- Sevoflurane
B- N2O
C- Isoflurane
D- Enflurane
Ans: B

610- **Which of the following is histamine releasing muscle relaxant?**
A- Tubocurarine
B- Rocuronium
C- Vecuronium
D- Cisatracurium
Ans: A

611- **A Patient has history of malignant hyperthermia during previous anesthesia, which muscle relaxant is contraindicated?**
A- Doxacurium
B- Panocurium
C- Cisatracurium
D- Suxamethonium
Ans: D

612- **If suxamethonium is contraindicated what will you give for rapid intubation?**
A- Doxacurium
B- Panocurium
C- Cisatracurium
D- Rocuronium
Ans: D

613- **Sulfonamides are given as first line treatment for:**
A- Nocardiasis
B- Rickettsial infections
C- Herpes
D- HPV
Ans: A

614- **DOC for Air sickness is**
A- Mannitol
B- Acetazolamide
C- Pyrodoxine
D- Mecolzine
Ans: D
Explanation:
- Drug in morning Sickness – Pyridoxine
- Drug in motion Sickness – Scopolamine >Meclizine
- Drug in Mountain Sickness – Acetazolamide
- Drug in Air Sickness Mecolzine

615- **Which Antiemetic has 5HT3 MOA**
A- Diphenhydramine
B- Metaclopromide
C- Ondansetron
D- Citrizine
Ans: C

616- **Drug contraindicated in CLD:**
A- Lorazepam
B- Aspirin
C- Paracetamol
D- Pentazocin
Ans: D > C
Explanation:
- Lorazepam and oxazepam can be given but pentazocin can't be given

617- **Enterococeus faecalis DOC is:**
A- Vancomycin
B- Ampicillin
C- Sulfonamide
D- Trimethoprim
E- Ceftazidime
Ans: B

618- **Heparin act by which of these?**
A- Thrombin
B- Factor 10
C- Anti Thrombin 3
D- Factor 8
Ans: C

CamScanner

Explanation:

- Heparin Inhibit – Factor Xa
- Heparin Act by – Anti-thrombin 3

619- A patient was taking glucocorticoid rapid withdrawal will cause:

A- Suppression of adrenal cortical system
B- Rapid decrease in ACTH
C- Increase hypertension
D- Decrease TSH
Ans: A

620- Primaquinine anti schizontocidal acts by which mechanism:

A- Inhibit dihydrofolate reductase
B- Act as antimetabolite for peraaminobenzoid acid to decrease folic acid synthesis
C- Activate DNA
D- Inhibit proteins
Ans: A

621- Which drug has maximum first pass metabolism by oral route:

A- Streptomycin
B- Atropine
C- Adrenaline
D- Benzylpencillin
E- Nitroglycerine
Ans: E

622- Effect of mannitol in CHF:

A- It causes cerebral edema
B- It precipitates pulmonary edema
C- It cause AKI
D- It has no effect
Ans: B

623- A Hostellite after sexual contact develops sores on genitals,palms & soles.What is the likely treatment:

A- Ciprofloxacin
B- Chloremphenicol
C- Pencillin
D- Ofloxacin
Ans: C

624- Best thrombolytic agent?

A- Heparin
B- Tissue thromboplastin
C- Tissue Plasmogen activator
D- Streptokinase
Ans: C

625- Patient having traveler's diarrhea not responding to antidiarrheal drugs, which drug should be given?

A- Metronidazole
B- Erythromycin
C- Norfloxacin
D- Chloramphenicol
E- Doxycycline
Ans: C

626- Pregnant lady 10 week pregnant aspirin given what is the beneficial affect of aspirin

A- Inhibition of cycloxygenase pathway
B- Platelates change
C- ADP antagonist
D- Plateletes activator
Ans: A

627- Pregnant lady G2P1 with history of DVT in previous pregnancy now 8th week gestation presents to you. Which drug is given in pregnancy for dvt safely:

A- Warfarin
B- Plasminogen
C- IV Heparin
D- Aspirin
E- Enoxaparin
Ans: C

628- Diarrhea and metallic taste in mouth associated with which antidiabetic drug?

A- Metformin
B- Acarbose
C- Glipizide
D- Sulfonylurea
Ans: A

629- A patient presented with pneumonia treated with beta lactamase remains hospital for 3 day symptoms resolved but developed diarrhea treatment should be for diarrhea

A- Metronidazole
B- Gentamycin
C- Doxycycline
D- Ceftriaxone
E- Sulfamethoxide
Ans: A

630- A patient taking some drugs now same dose of drug is not effective what is possible mechanism

A- Dependance
B- More excretion
C- Decrease absorption
D- Tolerance
Ans: D

631- Physostigmine leads to

A- Increase aldosterone
B- Increase cortisol
C- Increase catecholamine from adrenal medulla
D- Increase Growth harmones
Ans: C

CamScanner

632- A lady with post menopausal osteoporosis H/O breast CA in family which drug to be given?
A- Mixed OCP
B- Progesterone
C- Estrogen
D- Bisphosphonates
E- SERM
Ans: E

633- A patient presented with painful right big toe. He was diagnosed to have gout and doctor advised him Allopurinol. Which factor will affect the availability of allopurinol
A- LDH
B- Albumin
C- ACTH
D- CRP
Ans: B

634- A female was diagnosed with pulmonary TB. She has been taking OCP for 2 years. She suddenly started vomiting and Her Beta HCG came positive. Which of the following drug caused OCP failure?
A- Isoniazid
B- Pyrazinamide
C- Rifampicin
D- Ethambutol
Ans: C

635- 8 weeks pregnancy with affected disorder drug given should be:
A- Lithium
B- Valporate
C- Haloperidol
D- Escitalopram
Ans: D

636- Rapid sequence intubation has to be done in pregnant female. Which drug crosses placenta and affect fetus
A- Heparin
B- Vecurium
C- Sexamuthonium
D- Citalopram
Ans: B

637- A Baby delivers at 32 weeks now having with respiratory distress, for lung maturity what drug could have given to mother antenatally?
A- Dexamethasomne
B- Hydrocortoisone
C- Cyclosporin
D- Betamethasone
Ans: D

638- A 28 week pregnant lady present with premature contractions nifedpine was given whats the mechanism of action of nefidipine in premature of labour:
A- Oxytocin antagonist
B- Calcium Channel Blocker
C- Increase Gnrh
D- Prolactin agonist
E- Prolactin antagonist
Ans: B

639- Short acting anesthetic suitable for hysterectomy:
A- Prilocaine
B- Lidocaine
C- Bupivacain
D- Mupivacain
Ans: A

640- Anasthetic which Decreases blood flow to liver is:
A- Halothane
B- Isoflurane
C- Nitric oxide
D- Pentazocin
Ans: A

641- Safe drug in pregnancy with epileptic seziures
A- Lamotrigine
B- Phenytoin
C- Benzodiazipne
D- Phenobarbitone
Ans: A

642- Safe drug for malaria in pregnancy is
A- Artemether
B- Mefloquinine
C- Lumfantrine
D- Doxycycline
Ans: B

643- Anesthetic agent that dissociates in light:
A- Isoflurane
B- Propofol
C- Halothane
D- Sevoflurane
Ans: C

644- Person working in pharmaceutical company of nitroglycerin. He complains of headache on the 1st day of the week. What is this phenomenon:
A- Tolerance
B- Tachyphylaxis
C- Allergy
D- Idiosyncrasy
Ans: A

CamScanner

645- Epinephrine given slowly cause
A- Increase TPR
B- Decrease TPR
C- Increase in diastolic contraction
D- Increase Vessel relaxation
Ans: A

646- Patient develop SVT during anasthesia doc is
A- Lignocain
B- Amlodipine
C- Fleceinide
D- Captopril
E- Adenosine
Ans: E

647- Which local anesthetic agent can cause decrease oxygen saturation and cyanosis when injected locally?
A- Prolcalpine
B- Procain
C- Prilocian
D- Bupivacain
Ans: C

648- Charles law of gases states the relation of volume of gas with a variant. The law applies when
A- Pressure is held constant
B- Temperature is held constant
C- Pressure vary
D- Pressure increase and temperature decrease
Ans: A

649- Treatment of MRSA is:
A- Penicillin
B- Vancomycin
C- Gentamycin
D- Co-amoxiclav
E- Azithromycin
Ans: B

650- Which antibiotic interferes with Neuromuscular transmission? ---
A- Sulfadiazine
B- Cephalosporin
C- Pencillin
D- Aminoglycoside
Ans: D
Explanation:
• Aminoglycoside block NM transmission

651- Child presented with dyspnea after playing, most immediate remedy is: —
A- Epinephrine
B- Inhaled nebulizer salbutamol
C- Oral salbutamol
D- Ipratropium
Ans: B

652- Apatient has bradycardia and low bp. On investigation has low t3 t4 and increased tsh, how will you manage the patient?
A- Levothyroxine
B- Propylthiouracil
C- Methimazole
D- Iodine
Ans: A

653- Paracetamol poisoning can be reversed with?
A- NAHCO3
B- Acetylcysteine
C- Naloxone
D- Atropine
Ans: B

654- 20 years old boy with rheumatic valvular heart disease has been running a low grade fever for the last two weeks. In addition to a pansysotlic murmur, he is found to have splenomegaly and clubbing, the treatment should be:
A- Injection Cefotaxime + Metronidazole
B- Injection Ceftriaxone
C- Injection Penicillin
D- Injection Penicillin + Gentamycin
E- Injection Ciprofloxacin
Ans: D

655- Drug with short half life and given in infusion is
A- GnRH
B- Oxytoxin
C- Dopamine
D- Cortisol
Ans: C

656- Patient came in day care he is anxious which drug should be given
A- Haloparidol
B- Droperidol
C- Norepinephrine
D- Propanolol
E- Captopril
Ans: D

657- Digoxin toxicity caused by:
A- Hyperkalemia
B- Hypocalcemia
C- Thiazide Diuretic
D- Spiranolactone
Ans: C

CamScanner

Explanation:
Digoxin toxicity caused by – Hypokalemia, Alkalosis and drug causing hypokalemia
Digoxin toxicity itself cause – Hyperkalemia

658- **A 45 year patient is on hypertensive drugs, presented with increase LFT and indirect bilirubin, which drug is responsible?**
A- Captopril
B- Hydralazibe
C- Labetalol
D- Propanolol
E- Methyldopa
Ans: E

659- **Patient is taking warfarin and started to bleed. What is treatment of it?**
A- Heparin
B- Aspirin
C- TPA
D- Fibrinogen
E- Vitamin K
Ans: E>D

660- **A patient taking warfarin 5mg daily what should be checked?**
A- APTT
B- PT
C- BT
D- CT
Ans: B (INR>PT)

661- **A 10 year boy diagnosed with tape worm infestation the drug of choice is:**
A- Ciprofloxacin
B- Menendazole
C- Niclosamide
D- Metronidazole
E- Azithromycin
Ans: C

662- **Metabolic acidosis caused by which of following?**
A- Aldosterone
B- Furosamide
C- Thiazide
D- Spironolactone
E- Carbonic Anhydrase inhibitor
Ans: E

663- **Indication to stop combined oral contraceptive pills?**
A- Hemorrhage
B- Headache
C- Cervical CA
D- Metaplasia
E- Migraine
Ans: E

Explanation: According to MRCOG guidelines OCPs are contraindicated in migraine.

664- **Which drug increases the release of catecholamines from adrenal medulla?**
A- Physostigmine
B- Phenylephrine
C- Propranolol
D- Prazocin
E- Pbenoxybenzamine
Ans: A

665- **Drug that does not decrease potassium work like inhibitor of aldosterone**
A- Thiazide diuretic
B- Bumetunide
C- Spiranolactone
D- Furosamide
Ans: C

678- **Antibiotics given after meal due to**
A- Increase bioavailability
B- Decrease GI disturbance
C- Increase GI disturbance
D- Increase Excretion
Ans: B

666- **Drug of choice for Failing heart is:**
A- Epinephrine
B- Nor epinephrine
C- Dopamine
D- Atropine
Ans: C

667- **Which drug increase heart rate, blood pressure and cardiac output?**
A- Etomidate
B- Morphine
C- Propofol
D- Pethidine
E- Ketamine
Ans: E

668- **Liver necrosis in higher dose caused by:**
A- Brufen
B- Paracetamol
C- Aspirin
D- Diclofenac
E- Moloxicam
Ans: B

669- **A patient presented with acute pulmonary edema & dyspnea which of the following is the drug of choice?**
A- IV Furosemide
B- ACEI
C- ARBs
D- Beta blockers
E- Digoxin
Ans: A

CamScanner

670- Opioids act on:
A- Alpha agonist
B- Meu receptors agonist
C- Kappa receptors agonist
D- Internediate kappa receptors agonist
E- Beta agonist
Ans: B(FA)

Explanation:
Morphine – Strong Meu agonist
Tramadol – Weak Meu agonist

671- Antibiotic for bacteriods fragilis is
A- Cefixime
B- Azithromycin
C- Clindamycin
D- Chloremphenicol
Ans: C

672- Patient brought to ER unconscious there is breathing problem Empty bottle of Aspirin found how antidote will act:
A- Decrese tubular excretion of aspirin
B- Increase tubular excretion of aspirin
C- Increase aspirin absoption
D- Decrese aspirin absorption
Ans: B

673- Most common risk of giving steroids to diabetic patients is?
A- Cataract
B- Glaucoma
C- Deranged glycemic control
D- Risk of infections
Ans: C

674- Antacid that slows gastric emptying and constipation:
A- Aluminium hydroxide
B- Magnesium hydroxide
C- Omeprazole
D- Itopride
Ans: A

675- To prevent transplacental transmission of HIV DOC is:
A- Abacavir
B- Lamivudine
C- Zidovudine
D- Amantadine
Ans: C

676- A patient is on long term steroid therapy he will be having:
A- Mast cell degranulation
B- Basophilia
C- Neutropenia
D- Lymphopenia
Ans: D

Explanation:
Steroids cause:
- Lymphopenia
- Eoasinopenia
- Neutrophilia

677- Drug via oral route having aqueous absorption?
A- Digoxin
B- Ephiderin
C- Phenobarbital
D- Diazepam
E- Carbamezipeine
Ans: A

678- A Patient presented with ingestion of something in drowsy condition, mild depression of respiration on duty doctor manage it with NaHCO3 what he has ingested?
A- Dizepam
B- Digoxin
C- Phenobarbitone
D- Pyrimethamine
E- Morphine
Ans: C

679- Why cimetidine and sucralfate should be administered at about 2bours of gap in patient of peptic ulcer?
A- Because sucralfate inhibits cimetidine absorption
B- Because Scrulfate decrease Cimetidine metabolism increasing its toxicity
C- Because of Hypothermia Risk
D- Because of Hypoglycemia Risk
E- Because of Hyperglycemia Risk
Ans: A

Explanation:
Sucrulfate doesn't let cimetidine to absorb
Cimetidine decrease scrulfate metabolism

680- MOA of Ondansetron:
A- 5HT3 antagonist
B- H2 Blocker
C- 5HT2 antagonist
D- H1 Blocker
Ans: A

681- A diabetic patient having Hypertension treatment will be:
A- Metoprolol
B- Captopril
C- Furosemide
D- Hydrochlorothiazide
Ans: B

CamScanner

682- A Dental patient on steroid went to surgeon what will be first treated:
A- Hypercalcemia
B- Hyperglycemia
C- Hypocalcemia
D- Moon face
E- Hyperkalemia
Ans: B

683- Therapeutic window of drug indicates:
A- Potency
B- Effective blood concentration
C- Efficacy
D- Safety
Ans: B (Only Suitable)

Explanation:
- Therapeutic Dose – Potency
- Therapeutic Index – Safety
- Therapeutic Window – Range of Dose
- Therapeutic Effectiveness – Efficacy

684- Which of the following drug is actively secreted by kidneys?
A- Mannitol
B- Streptomycin
C- Rifampin
D- Metronidazole
Ans: B

685- Colleagues complain about a 30 Year old woman who forges signs on imp documents and search for belongings of others in their absence. Has joined another company and started smoking. He has history of taking some drugs what test would you do for psychiatric evaluation?
A- Urine screening for toxicology
B- B HCG
C- Thyroid
D- Cortisol
E- GH
Ans: A

686- Peripheral neuropathy secondary to isoniazid is reversed/prevented by?
A- Cobalamine
B- Folic acid
C- B6
D- B1
E- B9
Ans: C

687- Anasthetic that causes bronchodilation in asthma:
A- Pethidine
B- Ketamine
C- Propofol
D- Halothane
Ans: B

688- Drug absorption in GIT depend on:
A- Concentration gradient
B- Positive charge
C- Lipid solubility
D- Ionic solvent
E- Negative charge
Ans: C

689- Which anesthetic undergoes massive metabolism?
A- Sevoflurane
B- Halothane
C- Isoflurane
D- Enflurane
Ans: B

690- About Sodium Cromolyn true is:
A- Used in COPD
B- Used for Asthma
C- Prevent antigen associated with mast cell degranulation
D- Used for Fever
Ans: C

691- A patient was taking aspirin as advised by his cardiologist. Surgeon wants to operate on his inguinal henia. How many days prior to surgery aspirin should be stopped?
A- 4-6 days
B- 7-9 days
C- 10-12 days
D- 13-14 days
E- 1-2 days
Ans: B

692- A schizophrenic patient having galactorrhea and Hyperprolactinoma due to which of these
A- Phenothiazines
B- Macroprolactinoma
C- Micro prolactinoma
D- Pituitary tumor
Ans: A

693- Patient for caudal block Dr want to give more anasthesia which will be used
A- Etidocaine
B- Procaine
C- Lidocaine
D- Bupivacaine
E- Rupivacaine
Ans: D

694- Aspirin mechanism of action in pregnant lady is:
A- COX Inhibitor
B- Prostacyclin inhibitor
C- Prostaglandin synthesis
D- COX Stimulates
Ans: A

CamScanner

695- **Anticongulant in vitro and in body is**
A- TPA
B- Warfiarin
C- Vit K
D- Alteplase
E- Heparin
Ans: E

696- **A female had unprotected sex and she is now having a chances of being pregnant so which post coital oral contraceptive should be used?**
A- Hystrectomy
B- Levonorgestrel
C- Raloxifene
D- Stilbistrol
Ans: B

697- **A female with white discharge but fishy odour and diarrhea.Treatment?**
A- Doxycycline
B- Fluconazole
C- Doxylamine
D- Procainamide
E- Metronidazole
Ans: E

698- **Mgso4 acting on NMDA cause of inhibition in seizures**
A- Inhibitor of acetylcholine
B- Inhibitor of potassium entry
C- Inhibitor of sodium entry
D- Inhibitor of Calcium entry
Ans: D

699- **Local anasthesia injected at which location**
A- Lower border of ribs
B- Upper border of ribs
C- Upper ICS
D- Lateral border of ribs
Ans: B

700- **True about ace inhibitor:**
A- Cause formation of Ag 2
B- Decrease Ag I
C- Inhibit formation of Ag 2
D- Inhibit Bradykinin
Ans: C

701- **Side effect of epidural anaesthesia is:**
A- Hypotension
B- Urinary retention
C- Headache
D- Vomiting
Ans: A

702- **Post-operative analgesia in acute pancreatitis is**
A- Ketorolac
B- Paracetamol
C- Morphine
D- Pethidine
E- Ketamine
Ans: D

Explanation:
- Drug used for abdominal pain and biliary colic – Hyoscine
- Drug used for Acute pancreatitis -Pethidine > Morphine
- Drug used post-operative Ketorolac >Pethidine
- Drug used post-operative in asthmatics - Pethidine
- Anesthetic in Asthmatics – Ketamine

703- **A male patient known case of renal failure, presented with sign and symptoms of upper respiratory tract infection, which of the following antibiotics, safe for this patient:**
A- Azithromycin
B- Ciprofloxacin
C- Gentamycin
D- Norfloxacin
E- Streptomycin
Ans: A

704- **Which one decrease Thyroid harmones and increase TSH:**
A- Verapamil
B- ACEI
C- Propanolol
D- Iodine
Ans: C

705- **Verapamil affect is**
A- Increase AV conductance
B- Decrease AV conductance
C- Increase Blood pressure
D- Reduce Cardiac blood flow
Ans: B

706- **MAC in inhalational anesthesia related to**
A- Oil gas coefficient
B- Blood gas coefficient
C- Mean arterial coefficien
D- Mixture of both
Ans: A

707- **N2O act by**
A- Steroid hormone
B- Camp
C- CGMP
D- Nucleus
Ans: C

CamScanner

708- Hallucinations occur with Ketamine it can be prevented by
A- Nitrate
B- Ketamine with atropine
C- Ketamine with Haloperidol
D- Hydralazine
Ans: B

709- Which drug causes Malignant byperthermia
A- NO
B- Cisatracurium
C- Halothane
D- Dantrolene
Ans: C

710- A multigravida patient after 6 weeks postpartum present with leg pain and upon examination and investigation case of recurrent thrombophlebitis diagnosed what drug should be given
A- Warfarin
B- Warfarin and Heparin
C- Heparin
D- Enoxaparin
Ans: C

711- Contraindication to local anesthesia in eye procedures:
A- Retinal detachment
B- Penetrating injury to eye
C- Procedures less than 60 minutes
D- Glaucoma
Ans: B

712- Patient taking some drugs for Kidney problem. He is getting obese and buffnlo hump which drug he is taking
A- Cyclophosphamide
B- Cisplatin
C- Prednisolone
D- Gentamycin
Ans: C

713- Which anesthetic undergoes extensive metabolism
A- Sevoflurane
B- Halothane
C- Isoflurane
D- Enflurane
Ans: B

714- A patient undergoing GA but has severe vomiting not responding to normal medication whar will you give?
A- Ondasetronc
B- Maxonal
C- Cimetidine
D- Famotidine
Ans: A

715- A patient taking thiazide diuretic for 10 weeks. What will be the effect?
A- No requirement for salt intake restriction salt
B- Dietary potassium won't be required
C- Resultant vasodilation
D- Decrease cardiac output
Ans: D

716- Cimetidine mechanism of action is:
A- H1 antagonist
B- H2 antagonist
C- H1agonist
D- H2 agonist
E- D1 agonist
Ans: B

717- Patient present with rheumatic fever and Endocarditis on discharge the drug to be prescribed for long term treatment to prevent recurrence would be :
A- Ceftriaxone
B- Procainamide pencillin
C- Azithrimycin
D- Chloremphemcol
E- Sulfionamide
Ans: B

718- Patient got malaira third time despite using mosquito nets and repellents Which of following anti malarial drug is used for chloroquine resistant uncomplicated falciparum malaria
A- Pyrimethamine
B- Doxycycline
C- Artemesin with combination
D- Mefloquine
E- Primaquine
Ans: C

719- Naloxone is used in following thing
A- Barbiturate overdose
B- Morphine poisoning
C- Diazepam overdose
D- Aspirin poisoning
Ans: B

720- Which of the following drug causes tachycardia at normal dose?
A- Morphine
B- Pethidine
C- Alfentanyl
D- Diclofenac potassium
E- Propanolol
Ans: B

CamScanner

721- Cholesterol gallstones may be dissolved by oral treatment with:
A- Chenodeoxycholic acid
B- DE hydrochloric acid
C- Lovastatin
D- Monoctanion
Ans: A

722- A patient is known case of migraine associated with aura. Following are prophylaxis of migraine given to this patient:
A- Sodium Valproate
B- Propranolol
C- Paracetamol
D- Cetirizine
E- Chlorphenaramine
Ans: B

723- Drug of choice in 49 year old male patient with Hypertension and Dyspnoea is:
A- Captopril
B- Metoprolol
C- Hydralazine
D- Propranolol
Ans: B

724- B6 is given with which of the following?
A- Pyrazinamide
B- Isoniazid
C- Ethambutol
D- Rifampicin
Ans: B

725- Halothane causes rise in temperature up to 105F mechanism is:
A- Heat generation by skeletal muscle contraction
B- Acting on Hypothalamus
C- Acting on Liver
D- Act on thalamus
Ans: A

726- Which one of the following lacks vasodilator property used for angina treatment?
A- Nitro-glycerine
B- Verapamil
C- Propranolol
D- Hydralazine
Ans: B

727- Mifepristone given to terminate pregnancy, it is:
A- Antihypertensive
B- Antiprogestrin
C- Steroid
D- Anti carcinogen
Ans: B

728- Sensitive area of brain to inhalational anaesthesia is:
A- Cerebellum
B- Reticular activating system
C- Hypothalamus
D- Thalamus
Ans: B

729- A woman with infection took antibiotic for two weeks develop pancytopenia what is the cause:
A- Myelodysplastic syndrome
B- Aplastic Anaemia
C- Erythroblastemia
D- Megaloblastic anaemia
Ans: B

730- A patient of Age 50 years known Diabetic and he is chain smoker having BP 180/95 Drug of choice for BP is:
A- Nimodipine
B- Captopril
C- B blocker
D- Propranolol
Ans: B

731- Halothane is given as general anaesthetic and poor analgesia, what should be added:
A- Desflurane
B- Isoflurane
C- Nitric oxide
D- Morphine
Ans: C

732- Neostigmine mechanism of action is:
A- Inhibit Acetyl transferase
B- Inhibit Acetylcholinesterase
C- Promote Acetyltransferase
D- Activate Acetylcholinesterase
Ans: B

733- Thiopental action terminated in 15 min by:
A- Excretion via kidney
B- Excretion via liver
C- Redistribution in tissue
D- Redistribution in Blood
Ans: C

734- Pka of lignocaine is 7.9 and body PH is 6.9 how much drug will be ionized:
A- 90%
B- 99%
C- 50%
D- 20%
E- 1%
Ans: A

CamScanner

Explanation:

- Drug is usually a weak base will be more ionized when PH value lower than it's Pka. As pH is 1 unit lower than Pka so ratio of ionized to non-ionized is 90:10

735- Amongst the drugs given, which one is known to cause fluid retention?

A- Ergometrine
B- Misoprostol
C- Mefiprestone
D- Oxytocin
E- Prostaglandin
Ans: D

736- Antimicrobial for amoebic liver abscess is:

A- Ciprofloxacin
B- Tinidazole
C- Ceftriaxone
D- Pencillin
Ans: B

737- Extensive first pass metabolism is of which drug:

A- Tubocurarine
B- Adrenaline
C- Streptomycin
D- Benzyl penicillin
Ans: B

738- Renal papillary necrosis occur due to:

A- Paracetamol
B- Thalassemia
C- Lead
D- NSAIDs
E- Hypertension
Ans: D

Explanation:

Causes of Renal papillary necrosis

- Sickle cell disease or trait
- Acute pyelonephritis
- Analgesics (eg, NSAIDs)
- Diabetes mellitus

A known case of diabetes and myxoedema which anti-hypertensive should be given:

A- Amlodipine
B- Nifidipine
C- Captopril
D- Propranolol
Ans: C

739- Dapsone given to lady for erythema nodosum. Now she has decrease Hb, MCV 110 retic count 16%:

A- Megaloblastic anemia
B- Drug induced destruction of RBC
C- Malaria
D- Sickle cell anemia
Ans: B

740- Pregnant female of 9 week pregnancy came with hypertension 180/90 DOC is:

A- Nifedipine
B- Methyl dopa
C- Captopril
D- MgSO4
E- Diuretic
Ans: B

Explanation:

- DOC in pregnancy induced HTN – Labetalol >Methyldopa
- DOC in Hypertensive Emergency – Hydralazine >Labetalol
- For Eclampsia – MgSO4

741- Drugs having short half-life:

A- Are extensively bound to plasma proteins
B- Are freely filtered through glomeruli
C- Have low therapeutic index
D- Have low volume of distribution
E- Reach steady state concentration quickly
Ans: E

742- Which of the following has pronounced bad effect on kidney:

A- Cyclosporine
B- Cyclophosphamide
C- Cisplatin
D- Azithromycin
E- Bleomycin
Ans: C

Explanation:

- Cisplatin is both anti-cancer & Nephrotoxic drug

743- Isoniazid cannot be metabolized due to deficiency of?

A- An acetyl transferase
B- Pseudo cholinesterase
C- Xanthine oxidase
D- Amine oxidase
E- Hyaluronidase
Ans: A

744- Propranolol contraindicated in:

A- Raynaud's phenomenon
B- Asthma
C- Pregnancy
D- Anxiety
Ans: B

745- How many vaporizers or vaporizer dial settings are equivalent to 1 mL of isoflurane in a typical anesthesia machine?

A- 50 vaporizers
B- 100 vaporizers
C- 150 vaporizers
D- 200 vaporizers
Ans: D

CamScanner

746- Patient with liver cirrhosis came for cholecystectomy. No any other comorbid. Muscle relaxant of choice?
A- Cisatracurium
B- Suxamethonium
C- Rocuronium
D- Pancuronium
Ans: A

747- What is the approximate percentage range of calcium hydroxide ($Ca(OH)_2$) typically found in soda lime, a common absorbent used in anesthesia machines?
A- 25-50%
B- 50-75%
C- 75-90%
D- 90-100%
Ans: C

748- Salbutamol, a bronchodilator commonly used in the treatment of asthma, can lead to which electrolyte imbalance when used excessively?
A- Hyperkalaemia
B- Hyponatremia
C- Hypokalaemia
D- Hypernatremia
Ans: C

749- Which of the following medications, is commonly used for maintenance therapy in Crohn's disease to reduce inflammation and prevent flare-ups?
A- Antibiotics
B- Steroids
C- Nonsteroidal anti-inflammatory drugs (NSAIDs)
D- Azathioprine
E- Salfasalazinc
Ans: D

750- In pregnant women with gestational diabetes, metformin is often prescribed. What is one of the metabolic effects of metformin in these patients?
A- Increased fat utilization
B- Decreased insulin production
C- Enhanced glucose synthesis
D- Elevated blood pressure
Ans: A

751- In anaesthesia, when using balanced anaesthesia techniques, what percentage of anaesthesia is typically allocated to activate both α (alpha) and γ (gamma) receptors?
A- 50% each
B- 75% α receptor and 25% γ receptor
C- 25% α receptor and 75% γ receptor
D- 100% α receptor
Ans: A

752- Which intravenous (IV) local anaesthetic agent is commonly associated with fewer systemic side effects and is often used for minor surgical procedures?
A- Lidocaine
B- Bupivacaine
C- Propofol
D- Ketamine
E- Prilocaine
Ans: A

753- Phase I depolarizing block related to:
A- Tetanic contractions
B- Reversible by antagonist
C- Fasciculation's
D- Reversed by pyridostigmine
Ans: C

754- A patient after taking some drug went unconscious and also have increase salivation and Bradycardia and which drug should be given to antagonize symptoms:
A- Pralidoxime
B- Atropine
C- Epinephrine
D- Norepinephrine
Ans: B

755- Which of the following Anti-Tb drug causes disturbance in hepatic function?
A- Rifampicin
B- Ethambutol
C- Streptomycin
D- INH
Ans: A

756- Akathisia by antipsychotic treatment would be:
A- Benzotropine
B- Beta blocker
C- Alpha blocker
D- Diazepam
Ans: B

757- Common side effect of TCA and mao inhibitors?
A- Physical affect
B- Toxicity with certain foods
C- Insomnia
D- Weight loss
Ans: B

758- A patient after RTA has BP 80mmhg and heart rate 45 which drug should be given to increase heart rate:
A- Metoprolol
B- Captopril
C- Atropine
D- Digoxin
E- Propranolol
Ans: C

CamScanner

Patient ABG showing PCo2=25, PO2=50 PH 7.42 and HCO3=11 mcq/L. Most likely cause:
Morphine overdose
COPD
Haemothorax
Aspirin toxicity
Ans: D

Explanation:
Aspirin toxicity Causes hyperventilation result in early respiratory alkalosis which is compensated by Metabolic acidosis

Selective Cox-2 inhibitor is:
Meloxicam
Aspirin
Ibrufen
Steroid
Ans: A

Benzodiazepine and Flumezanil have 7 membered component which are common in both is:
Azole ring
Acefyl ring
Diazepine ring
B ring
Ans: C

DOC for community acquired pneumonia is:
Cefotaxime
Ceftriaxone + Clarithromycin
Sulphonamide
Ciprofloxacin -Azithromycin
Ans: B

Propylthiouracil helps in hyperthyroidism via:
Inhibit iodide pump
Block the synthesis of thyroid hormone
Block the synthesis of thyro globulin
Inhibits hormone release
Control hypothalamic temp set point
Ans: B

MOA of adenosine in SVT is:
Block SA node
AV block
Increase sympathetic rate
Parasympathetic block
Ans: B

Induction of ovulation after pituitary craniopharyngioma resection, which drug will be effective for induction of ovulation?
Pulsatile GnRh
HCG followed by GnRh
Clomiphene citrate
Danazole
Ans: B

Which ATT drug is contraindicated in pregnancy? :
A- INH
B- Rifampicin
C- Streptomycin
D- Pyrazinamide
Ans: C

Patient is diabetic, Hypertensive, also has heart disease, prophylaxis of drugs will be?
A- Heparin
B- Aspirin
C- Clopidogrel
D- Aspirin + clopidogrel
E- Dabigatran
Ans: D

A Child had history of drinking from rusty pipe presents with anaemia wrist drop constipation and peripheral neuropathy it is caused by:
A- Organophosphate poisoning
B- Arsenic poisoning
C- Lead poisoning
D- Aspirin poisoning
Ans: C

Therapeutic dose of drug indicates:
A- Potency
B- Safety
C- Efficacy
D- Dose
Ans: A

Explanation:
- Therapeutic Dose – Potency
- Therapeutic Index – Safety
- Therapeutic Window – Range of Dose
- Therapeutic Effectiveness – Efficacy

Female came with schizophrenia Bp 110/70 using drug (phenothiazine) for this now presented with milky discharge from nipples what's the cause?
A- Microprolactinoma
B- Macroprolactinoma
C- Drug induced
D- Pheochromocytoma
Ans: C

What is Placebo effect:
A- Doctor know the drug
B- Subject doesn't know the drug
C- Subject know the drug
D- It is actual treatment
Ans: B

CamScanner

772- **Dobutamine opposed by:**
A- Norepinephrine
B- Propanolol
C- Labetalol
D- Propranolol
Ans: C

773- **Patient has respiratory depression due to involvement of opioids act on which receptor:**
A- Alpha agonist
B- Week meu receptors agonist
C- Strong meu receptors agonist
D- Intennediate meu receptors agonist
E- Beta agonist
Ans: C (FA)

Explanation:
Morphine – Strong Meu agonist
Tramadol – Weak Meu agonist

774- **Sympathomimetic drug is which one following:**
A- Propanolol
B- Amphetamines
C- Nabivolol
D- Alfazocin
Ans: B

775- **A Parkinson patient taking Levodopa Side effect will be:**
A- Hypertension
B- Glaucoma
C- Orthostatic Hypotension
D- Mood changes
Ans: C

776- **Anasthesia contraindicated in 70% burn is:**
A- Ketamine
B- Lidocaine
C- Suxamethonium
D- Prilocain
Ans: C

777- **Chlorothiazide most common side effect:**
A- Hypematremia
B- Hypoglycemia
C- Hyperkalemia
D- Hypercalcemia
E- Hyperuricemia
Ans: E

Explanation:
Hypokalemia > Hyperglycemia > Hyperlipidemia > Hyper uricemia > Hyper calcemia

778- **Patient has sinusitis and nasal congestion with fungal infection treatment is:**
A- Itraconazole
B- Amphotericin B
C- Amoxicillin
D- Azithromycin
Ans: B

779- **A man working in factory has neuronal degenaration due exposure to:**
A- Organophosphate poisoning
B- Arsenic poisoning
C- Lead poisoning
D- Aspirin poisoning
Ans: C

780- **Patient on steroid has poor wound healing due to:**
A- Increase fibroblast
B- Decrease collagen deposition
C- Decrease neutrophils
D- Increase lymphocytes
Ans: B

781- **Safe drug preoperatively for chronic liver disease is:**
A- Diazepam
B- Alprazolam
C- Fentanyl
D- Phenobarbital
E- Lidocaine
Ans: C (FA)

782- **DOC for trichomonas is:**
A- Ampicillin
B- Metronidazole
C- Aztreonem
D- Imipenem
Ans: B

783- **Pencillin Anaphylactic reaction characteristic feature is :**
A- Bronchodilation
B- Hypertension
C- Bronchospasm
D- Bradycardia
Ans: C

784- **Meningitis due to strep pneumonia in 1 year old child DOC will be:**
A- Penicillin G
B- Benzylpenicillin
C- Cefazolin
D- Azitheomycin
Ans: A

CamScanner

Alcoholic person develop hepatic cirrhosis diuretic of choice to relieve edema and ascites:
Furosemide
Spironolactone
Thiazide
Acetazolamide
B

Patient diagnosed with DM was prescribes an oral hypoglycemic agent now BSR 30 what could be the drug responsible :
Metformin
Exenetide
Glimepiride
Acarbose
C

Which one is not given orally b/c of highly first pass effect, inactivation by liver? :
Morphine
Tubocurare
Benzyl penicillin
Streptomycin
Adrenaline
E

A woman took too many tablets of acetaminophen, what will happen to her liver after 3 days? :
Nothing
Severe necrosis
Acute congestion
Regeneration
B

After transfusion, acute reaction occur management is:
Nor adrenaline
Dopamine
Theophylline
Adrenaline
D

A pregnant with blood sugar 300 came to hospital. What should we give?
Insulin
Metformin
Glargine
Glitazone
Insulin + Sulfonylurea
A

791- Nitro-glycerine mediates its vasodilator action through?
A- Phosphodiesterase inhibition
B- Alpha blockade
C- Beta blockade
D- Both alpha and beta blockade
E- CGMP
Ans: E

792- A 75 year old male recently diagnosed with diabetes. Which of the following treatment is preferred?
A- Insulin
B- Metformin
C- Tolbutamide
D- Empagliflozin
Ans: C

793- Easiest way to measure clearance of drug?
A- Plasma half life
B- Inulin clearance
C- Excretion
D- Absorption
Ans: A

794- Post menopausal women present with breast carcinoma DoC:
A- Tamoxifen
B- Bisphosphonate
C- Raloxifen
D- Danazole
Ans: A

Explanation:
- For Breast CA in premenopausal women and also in selected post menopausal women - Tamoxifen
- For Breast CA in postmenopausal women Only Aromatase inhibitors
- In prevention of breast cancer in high risk Women (Strong family history , risk of IHD and osteoporosis) - -Raloxifen
- Low estrogen OCP cause – Hepatic Adenoma
- High Estrogen OCP Prolong/Long term use cause in post menopausal – Endometrial CA
- Estrogen Containing OCP Increase risk of – Thromboembolism(DVT) HRT (Mixed) cause – Breast CA(Robins) > DVT

795- A lady with lupus on steroids how to overcome long term toxicity of steroids:
A- Increase the dose of steroid
B- Divide the dose into multiple to avoid toxicity
C- Give single dose
D- Change steroid
Ans: B

CamScanner

796- Extrapyramidal side effects of chlorpromazine is:
A- Clasp knife rigidity
B- Exaggerated reflexes
C- Decrease muscle tone
D- Hypertonia
Ans: C

797- Anticoagulant in Atrial fibrillation is:
A- Clopidogrel
B- Aspirin
C- Amiodarone
D- Aspirin + Clopidogrel
E- Warfarin
Ans: E

798- Patient for burn with family history of one member died due to general anaesthesia contraindicated anesthesia in this patient is :
A- Fentanyl
B- Propofol
C- Suxamthonium
D- Ketamine
Ans: C

Explanation:
Succinylcholine (also known as suxamethonium) is generally avoided in burn patients due to the risk of an exaggerated response known as "burn-induced hyperkalemia." Burn injuries can cause the release of potassium from damaged cells, and succinylcholine can further increase potassium levels in the bloodstream, potentially leading to dangerous hyperkalemia and cardiac arrhythmias.

799- In Atrial fibrillation patient which should we give?
A- Propanolol
B- Digoxin
C- Flecainide
D- Verapamil
Ans: B

800- In SLE nephritis treatment given will be:
A- Prednisone
B- Prednisolone + Azathioprine
C- Prednisone+ methotrexate
D- Methotrexate
Ans: B

801- Morphine mechanism of action is:
A- Alpha agonist
B- Week meu receptors agonist
C- Strong meu receptors agonist
D- Intermediate meu receptors agonist
E- Beta agonist
Ans: C (FA)

Explanation:
Morphine – Strong Meu agonist
Tramadol – Weak Meu agonist

802- Patient with exercise induced asthma treatment is:
A- Epinephrine
B- Inhaled nebulizer salbutamol
C- Oral salbutamol
D- Ipratropium
Ans: B

803- Neuroleptic analgesia by?
A- Droperidol with fentanyl
B- Ketamine
C- Haloperidol
D- Histamine
Ans: A

804- Alpha-2- agonist is:
A- Clonidine
B- Phentolamine
C- Phenoxybenzamine
D- Prazosin
Ans: A

805- A patient after subtotal thyroidectomynow present with palpitations pulse is 102.Treatment is?
A- Digoxin
B- Dilitiazem
C- Propanolol
D- Lidocaine
Ans: C

806- Management of DVT in a women with leg pain and swelling?
A- Loprin+ warfarin
B- Warfarin
C- Aspirin
D- Clopidrogel
Ans: A

807- Beclomethasone inhaler cause oral thrush which is prevented by?
A- Amphotericin
B- Phenol
C- Rinse the mouth with water
D- Chlorhexidine
Ans: C

808- Side effects of phenytoin is:
A- B2 deficiency
B- Hair loss
C- Hypernatremia
D- Hirsutism
Ans: D

CamScanner

809- Patient presented with gum bleeding and swelling cause is?

A- Phenytoin
B- Carbamazepine
C- Topiramate
D- Lamotrigine
Ans: A

810- In personal with normal airway abnormality which muscle relaxant is given? :

A- Ketamine
B- Lidocaine
C- Suxamethonium
D- Prilocain
Ans: C

811- Patient exposed to cold present with pain and redness of fingers treatment given will be:

A- Nifedipine
B- Verapamil
C- Propanolol
D- Metorprolol
Ans: A

812- Which of the following penicillin is active against pseudomonas:

A- Penicillin G
B- Cloxacilin
C- Piperacillin
D- Amoxicillin
Ans: C

Explanation:

- Anti pseudomonas Pencillin -Pipercillin and Ticarcillin
- Anti pseumonas Aminoglycosides - Gentamycin and Amikacin
- DOC for Pscudomonas -Ceftazidime
- DOC for Pseudomonas UTI -Ciprofloxacin

813- Which one of Following drug can cause hypothyroidism

A- Cyclosporine
B- Cyclophosphamide
C- Lithium
D- Ampicillin
Ans: C (FA)

814- A young female diagnose with MDR Tb and taking 2nd line anti Tb drugs. After taking drugs she has developed enlarge thyroid and antithyroid antibodies Due to which drug he has developed thyroid problem (hypothyroidism)?

A- Amikacin
B- Ethionamide
C- Cycloserine
D- Pyrazinamide
E- Leflunamide
Ans: B

815- Maintenance drug for myasthenia gravis:

A- Atropine
B- Adrenaline
C- Dantrolene
D- Physostigmine
Ans: D (No option of Pyridostigmine)

816- Patient present with rheumatic fever single dose of which drug should be given?

A- Benzyle pencillin
B- Benzathine pencillin
C- Azithrimycin
D- Chloremphenicol
E- Sulfonamide
Ans: B (Davidson)

817- Digoxin toxicity caused by:

A- Hypermagnesemia
B- Hyperkalemia
C- Hypematremia
D- Hypercalcemia
E- Hypomagnesemia
Ans: E >D

Explanation:

Digoxin toxicity caused by

- Hypokalemia
- Hypomagnesemia
- Hypercalcemia
- Alkalosis &Drug causing hypokalemia
- Digoxin toxicity itself cause Hyperkalemia

818- To differentiate between myasthenia crisis and cholinergic crisis which drug used:

A- Edrophonium
B- Physostigmine
C- Pyridostigmine
D- Neostigmine
E- Ecothiophate
Ans: A

Explanation:

- Neostigmine is acetylcholinestrase inhabitor means increases the concentration of acetlycholine in cleft cause cholinergic crisis which opposes the mysthenic crisis.
- Endrophonium is given to the patient if condition reverse than it is myasthenia crises then increase neostigmine dose.

819- Pethidine is preferred over Morphine because:

A- Fast acting
B- Less addictive potential
C- Less potent analgesic
D- More constipation
Ans: A

CamScanner

CamScanner

820- Pregnant lady devcloped Tb taking anti tb now developed bilateral vision loss which drug is responsible

A- Isoniazid
B- Rifampicin
C- Ethionamide
D- Pyrazinamide
E- Streptomycin
Ans: C(No etbambutol option)

821- Coagulation of blood in vitro can be prevented by using?

A- Warfarin
B- Heparin
C- Sodium chloride
D- Aspirin
Ans: B

822- Best block in which drug concentration is highest in blood?

A- Spinal
B- Dural
C- Intercostal block
D- Subarachnoid
Ans: C

823- Beirs block uses which mostly?

A- Bupivacain
B- Halothane
C- Mepivacaine
D- Prilocain
Ans: D

824- An immunocompromised patient presented with white patches in oral cavity and cheilosis. What is the treatment of choice?

A- Griseofulvin
B- Nystatin
C- Amphotericin B
D- Penicillin
Ans: B

825- Local anesthesia with highest protein binding & cardiotoxicity?

A- Bupivacaine
B- Lignocaine
C- Prilocain
D- Cocain
Ans: A

826- Mechanism of action of sulfonylurea?

A- Increase insulin synthesis
B- Increase insulin release
C- Increase insulin distribution
D- Decrease insulin in skeletal muscles
Ans: B

827- A drug given for chronic use needs close monitoring because?

A- Low Therapeutic index
B- Drug bound to protein
C- High filteration rate
D- Reach steady state faster
Ans: A

828- Temperature at which pressure becomes equal to atmospheric pressure and liquids starts vaporizing:

A- Boiling point
B- Latent heat of vaporization
C- Evaporation
D- Latent heat of fusion
Ans: A

829- Which of the following narcotic when given epidural causes delayed respiratory depression?

A- Morphine
B- Fentanyl
C- Pethidine
D- Xylocaine
E- Ketamine
Ans: A

830- Drug causing pupillary constriction, Increased git secretions along with bradycardia?

A- Acetylcholine
B- Atropine
C- Norepinephrine
D- Epinephrine
E- Morphine
Ans: A

831- Pain in Terminally ill cancer patient with bone metastasis is controlled by giving morphine along with the following drug to reduce side effects?

A- Diazepam
B- Paracetamol
C- Tricyclic antidepressent
D- Pethidine
E- Cyclizine
Ans: A

832- Morphine along with the following drug to reduce side effects?

A- Diazepam
B- Paracetamol
C- Tricyclic antidepressent
D- Pethidine
E- Cyclizine
Ans: A

CamScanner

833- A patient had citrate toxicity & he underwent blood transfusion, After that Heart activity increased. Which vasopressor agent can be given in this case?

A- Dopamine
B- Calcium
C- Epinephrine
D- Atropine
Ans: C

834- Dopamine causes affect in how much time of given in IV form

A- 9 min
B- 36 min
C- 12 min
D- 14 min
E- 5 min
Ans: A

Explanation:
- Steady state: 9 min
- Half-life: 2 min

835- Adrenal gland releases secretion with the help of which receptor

A- Muscarinic cholinergic
B- Nicotinic cholinergic
C- Adrenergic beta 1
D- Muscuranic adrenergic
E- Adrenergic beta 2
Ans: B

836- Which drug prevent IgE to bind mast cells

A- Antihistamines
B- Cromolyn
C- NSAID
D- Histamine
E- Theophyllin
Ans: B

837- A pregnant female is experiencing dysuria and increased urinary frequency. Her urinalysis shows increased WBC and positive nitrites. What is the most appropriate treatment?

A- Ofloxacin
B- Amikacin
C- Amoxillcin clauvanate
D- Clithrimycin
E- Sulfonamide
Ans: C

838- Plasmodium vivax patient treated by doctor correctly thrice in three months came again with chills, next best treatment to give

A- Primaqune
B- Arthemeter
C- Mefloquine
D- Azithromycin
Ans: A

839- Girl gave birth to Still birth child Cabergoline suppress lactation by decreasing prolactin by its action on

A- D2 receptor agonist
B- D2 receptor antagonist
C- D1 receptor agonist
D- D1 receptor antagonist
Ans: A

840- TCA mode of action is

A- Inhibit acetylcholine reuptake
B- Inhibit norepinephrine and serotonin reuptake in presynaptic terminal
C- Increase norepinephrine uptake in synaptic Cleft
D- Inhibit Dopamine uptake in synapses
Ans: B

841- A couple came back from egypt, developed sore throat, yellow sputum with nausea abdominal pain and diarrhea. Which drug you will give for the causative agent

A- Clarithromycin
B- Cephradine
C- Amoxicillin
D- Acyclovir
E- Oxofloxacin
Ans: A

842- An old man came from Thailand having severe restless having scrotal pain ,discharge or swelling Also has history of sexual activities. What will be the treatment

A- Cipro 500mg PO e Azithro 1g OD
B- Cipro 500mg PO e Doxicyclin 500 mg BD for 7 days
C- Tetracyclin
D- Ceftriaxone 250mg IM e Azithro 1g OD
Ans: A

843- An aged man, known case of hypertensive , was on clonidine , run short of it , now presents with increased BP 190/110 shaed with no symptoms, what step should be taken ?
A- Admit the patient and give nitroglycerin
B- Restart Clonidine and again check BP after 12 to 24 hrs
C- Start ACEI
D- Start Beta blockers
Ans: B

844- Which of the following anti psychotic drug causes hallucinations elate mania
A- Alprazolam
B- Lithium
C- Diazepam
D- Phenytoin
E- Olanzapine
Ans: E

845- Which anti TB drug's dose is adjusted when GFR is below 30
A- Rifampicin
B- Isoniazid
C- Pyrazinamide
D- Streptomycin
Ans: A

846- Low dose epinephrine cause vasodilation by acting on
A- Beta 1 receptors
B- Beta 2 receptors
C- Alpha 2 receptors
D- Alpha 1 receptors
E- D1 receptors
Ans: B

847- An aged man presents with increased Heart rate, increased Cardiac Output, decreased peripheral vascular resistance. Which of the following pressor he is taking ?
A- Dopamine
B- Epinephrine
C- Nor epinephrine
D- Phenylepbrine
Ans: C

848- During surgery pateint was given anaesthesia with 5mg thiopental Soon after the induction pateint bp dropped to 70/40 and tachycardia. What is the mechanism behind this?
A- Laryngospasm
B- Anaphylaxis
C- Decresed sympathetic
D- Decresed parasympathetic
E- Decreased venous return
Ans: B

849- Anasthesia given in epidural block goes to
A- Ventral horn
B- Dorsal horn
C- Neuron
D- None
Ans: B

850- Hyperkalemia is caused by which diuretic?
A- Thiazide
B- Loop
C- Spiranolactone
D- Mannitol
Ans: C

851- 9 years old boy admitted for surgery complain of dry mouth, examination shows white patches on mouth, difficult to eat and swallow what should be treatment?
A- Griseofulvin
B- Nystatin
C- Miconazole
D- Doxycycline
Ans: C

852- Which antihypertensive drug is given to Asthmatic & IHD patient during surgery?
A- IV hydralazine
B- IV Nitroglycerine
C- IV Nitrate
D- CCB
Ans: B

853- Antibiotic acting on bacterial cell wall:
A- Pencillin
B- Tetracyclin
C- Erythromycin
D- Miconazole
Ans: A

854- Which anesthetic drug will increase heart rate?
A- Morphine
B- Fantanyl
C- Alfantanyl
D- Pethidine
E- Ketamine
Ans: D

855- Epinephrine receptor on adrenal medulla
A- a1
B- a2
C- B1
D- B2

856- What type of receptors are present in adrenal gland for the secretion of cortisol?
A- Beta Adrenergic type 2
B- Alpha Adrenergic
C- Beta Adrenergic type 1
D- Baroreceptors
Ans: B

857- Phase I reaction is?
A- Methylation
B- Oxidation
C- Glucronidation
D- Acetylation
Ans: B

858- Succinylcholine is used during anesthesia as skeletal muscle relaxant It can cause prolong action in individuals having congenital absence of:
A- Acetyl cholinesterase
B- Pseudocholine esterase
C- Phosphorylase
D- Succinyl cholinesterase
E- Plasma cholinesterase
Ans: B

859- Patient was prescribed with Antihypertensive captopril & atenolol.Now presented with complain of cough, What has to be done now?
A- Give remedy for cough
B- Stop Captopril
C- Adjust the dose of the drugs
E- Stop Both drugs
Ans: B

860- Vinblastine Mechanism of Action
A- Inhibition of secretory proteins from RER to Golgi
B- Inhibition of secretory proteins from golgi to RER
C- Inhibition of molecules from Lysosomes to RER
D- Activate molecules from Golgi to RER
Ans: A

861- Which of the following Antihypertensive drug is given Intraoperatively to immediately lower the BP?
A- Hydralazine
B- Glyceryl trinitrate
C- Metoprolol
D- Captopril
E- Methyldopa
Ans: B

862- Patient given epidural with lidocaine & adrenaline & develops respiratory depression with 2 minutes of injection. Underlying reason for this reaction is?
A- Drug reaches subarachnoid space
B- Allergic reaction
C- Drug causing systemic toxicity
D- Drug reaching epidural space
Ans: B

863- A patient has redness at mandible, pain on chewing relieve in 4 min by
A- Diclofenac
B- Carbamezapine
C- Amitryptaline
D- Erythromycin
Ans: B

864- Antihypertensive causing hypertriglyceridemia
A- Furosamide
B- Atenolol
C- Hydralazine
D- Captopril
Ans: B

865- A patient taking anti arythmic drug which leads to hypothyroidism which drug it is
A- Fleicanide
B- Amidarone
C- Digoxin
D- Lithium
Ans: B

866- DOC for tonic clonic seizure is
A- Carbamazepine
B- Terbutaline
C- Ethosuximide
D- Phenobarbital
E- Valproate
Ans: E

867- Propofol and fentanyl given to patient before muscle relaxant opiod regidity seen. What to give
A- Morphine
B- Naloxone
C- Sodium bicarbonate
D- Acetylcystein
Ans: B

868- Why high dose of non depolarizing muscle relaxant given in burns
A- Increase no of receptors
B- High proteins binding
C- High lipid solubility
D- Decrease proteins binding
Ans: B

CamScanner

869- What is true about amide local anasthetic
A- Bind to alpha Glycoprotein
B- Cardiotoxic
C- Bind to Hb molecule
D- Only bind to acids
Ans: A

870- A patient has polyuria polydipsia and diagnosed as central diabetes inspidus what should be given
A- Tolbutamide
B- Desmopressin
C- Colchicine
D- Glutamate
Ans: B

871- An old male present with belching and discomfort after fatty meal what should be given
A- Anticholinergic
B- Metachlopromide
C- Loperamide
D- Cimetidine
E- Fimotidine
Ans: B

872- Which of the following antiarthmetic drug will cause Cns toxicity and also effect the cardiac system.
A- Lidocaine
B- Phenytoin
C- Amiodrone
D- Verapamil
Ans: A

873- Best muscle relaxant to use for rapid sequence intubation in a person with normal anatomy if succinylcholine is contraindicated:
A- Atracurium
B- Vecuronium
C- Pancuronium
D- Rocuronium
Ans: D

874- Theophylline metabolism is decreased by:
A- Cetirizine
B- Fexofenadine
C- Diphenhydrinate
D- Cimetidine
E- Carbamazepine
Ans: D

875- Venturi affect uses which principle
A- Leplace law
B- Delton
C- Bernoulli principle
D- Conada principle
Ans: C

876- In Venturi apparatus when 2 venturi surfaces are together, substance sticking to side. This is
A- Venturi effect
B- Coanda affect
C- Leplace effect
D- Delton effect
Ans: B

877- If hyperbaric pressure decreases, what will increase.
A- Vapour pressure
B- Vapour pressure in the chamber
C- Latent Heat of Vaporization
D- Latent volume
Ans: A

878- If there's a leak in the system what order will create least hypoxia?
A- N2O,O2,Air
B- O2, Air, N20
C- N2o,O2,N20
D- N2 , CO2
Ans: B

879- Which gas law states that the "The total pressure exerted by a mixture of non-reacting gases is equal to the sum of the partial pressures of individual gases"?
A- Henry's law
B- Dalton's law
C- Boyle's law
D- Fick's law
Ans: B

880- A 10 year boy diagnosed with tape worm infestation the drug of choice is:
A- Ciprofloxacin
B- Mencndazole
C- Niclosamide
D- Metronidazole
E- Pyarentel pamoate
Ans: C

881- Ace inhibitor given to patient what will happen?
A- Decrease renin and Bradykinin
B- Decrease angiotensin 2 and bradykinin
C- Increase renin and decrease bradykinin
D- Increase angiotensin 2 Decrease bradykinin
E- Increase angiotensin and renin
Ans: B (Only Suitable)

CamScanner

Drug distributed through aqueous diffusion?
Morphine
Phenobarbitone
Naloxone
Flumazenil
Digoxin
E

Antidote for opium is
Ethanol
Aspirin
Naloxone
Acetylcystein
Flumezanil
C

A patient diagnosed with atrial fibrillation. How will you manage the patient if he is hemodynamically unstable
Amiodarone
Flecainide
Sotalol
Lidocain
Cardioversion
A

A patient has complex partial seizure. How will you treat this patient
Levitracecum
Ethosuximide
Carbamezapine +Primidon
Valproat
C

A 60 years old patient presented with high grade fever headache and Kerning sign positive . On LP CSF glucose was 40 and Neutrophils were raised . Which drug should be given?
Ceftriaxone
Cefotaxime
Amoxcillin
Gentamycin
Amphotericin
A

A patient on warfarin therapy which of following drug dose should be adjusted
Gentamycin
Heparin
Cimetidine
Macrolides
C

888- 8 weeks pregnancy with affected disorder drug given should be:
A- Lithium
B- Valporate
C- Haloperidol
D- Escitalopram
Ans: D

889- Tricyclic antidepressants prescribed to patient Analgesic effect of TCA is seen after?
A- 4 weeks
B- 5 days
C- 10 days
D- 1 week
E- 6 weeks
Ans: D(Davidson)

Explanation:
- Analgesic effect – 1-2 weeks
- Antidepressant effect – 3-4 weeks

890- 53 years old woman diagnosed case of schizophrenia being managed with anti psychotics complains of a dry mouth, constipation, blurred vision, urinary retention and feeling tired. Which drug is most likely causing the symptoms?
A- Clozapine
B- Prochlorperazine
C- Chlorpromazine
D- Thioridazine
Ans: D

891- A patient presented with signs & symptoms of aspirin toxicity. To reduce the symptoms, HCO3 was infused. What is the mechanism by which HCO3 reduces the toxicity of aspirin?
A- Reduces absorption of aspirin
B- Increases the absorption of HCO3
C- Increases the absorption of aspirin
D- Reduced excretion of HCO3
Ans: A

892- DOTS stand for
A- Directly observed treatment short course
B- Directly observed therapy short course
C- Distant observation treatment standards
D- Dissiminatingly Observed treatment
E- Distant treatment Observation
Ans: A

893- Low dose Aspirin inhibits:
A- Prostacyclin
B- Thromboxane A2
C- Cox 2 synthesis
D- Cox 3
E- Platelet formation
Ans: B

CamScanner

894- Drug of choice in prinzmetal angina
A- Isosorbide dinitrate
B- Nitroprusside
C- Metoprolol
D- Beta blocker
Ans: B

895- Which of the following produces maximum vasoconstriction?
A- Bupivacain
B- Cocaine
C- Procaine
D- Rocurium
E- Prilocaine
Ans: B

896- Which drug is not given orally because of extensive first pass metabolism?
A- Labetalol
B- Nifedipine
C- Betablocker
D- Nsaids
E- Adrenaline
Ans: E

897- A patient wants analgesia for painfree labour. What will you give?
A- Halotbanc
B- Desflurane
C- Isoflurane
D- NO
E- Sevoflurane
Ans: D

898- Mechanism of action of "LOCAL ANESTHETIC":
A- Blocks sodium channel in ionized form
B- Block Potassium channel
C- Works in unionized fonn
D- Block calcium channel
E- Block Chloride channels
Ans: A

899- Pregnant patient has history of fits. You give MgSO4, she develops CNS depression, Depressed Reflexes, Hypotension & Bradycardia. What will you give the patient for Hypotension & Bradycardia?
A- Labetalol
B- Bicarbonate
C- 5% calcium lactate
D- Epinephrine
E- Calcium Chloride
Ans: E

Explanation:
- Respiratory depression in this patient indicates magnesium toxicity which is managed by 10% Calcium gluconate IV, hydration, respiratory and cardiac support(Calcium Gluconate not in options)

900- Patient with chronic renal failure presented in opd with discharge from ear physician advised his dr to prescribe drug in lower dose.
A- Penicillin
B- Gentamicin
C- Erythromycin
D- Chloremphenicol
Ans: B

901- During surgery patient was given anaesthesia with 5mg thiopental Soon after the induction pateint bp dropped to 70/40 and tachycardia. What is the mechanism behind this?
A- Laryngospasm
B- Anaphylaxis
C- Decresed sympathetic
D- Decresed parasympathetic
E- Decreased Cardiac output
Ans: B

902- Hyperkalemia is caused by which diuretic?
A- Thiazide
B- Loop
C- Spiranolactone
D- Mannitol
Ans: C

903- OCPs are discontinued in a 20 Years old female due to the following clinical manifestation?
A- Migraine
B- Cervical Neoplasia
C- Tension Headache
D- Cluster Headache
E- Vaginal bleeding
Ans: A

904- Young girl p0+2 with 5 weeks pregnancy bp 110/70 pulse 80 beta HCG 3000 with right sided ovarian mass. best treatment option
A- Mixed regimen of methotrexate
B- Single doseof systemic methotrexate
C- Local dose of methotrexate
D- Right salpingectomy
E- Right salpingotomy
Ans: A

CamScanner

905- Pregnant lady diagnosed with hyperthyroidism at 20 weeks of Gestation. Drug of choice will be?

A- Propylthiouracil
B- Beta Blocker
C- Wait until delivery
D- Thyroidectomy
E- Thyroxine
Ans: A

Explanation:

- Anti-Thyroid in 1st Trimester – PTU
- Anti-Thyroid in 2nd & 3rd Trimester – Methimazole
- Anti-Thyroid for Thyroid Storm -PTU
- Crosses Placenta and affect Fetus – Methimazole > PTU

906- Egnent female presents with Deceeased milk production. After evaluation, doctor came to know that she is taking some drugs. Which of the following drugs cause Decreased prolactin?

A- Dopamine
B- Nsaids
C- Antibiotics
D- Metoclopramide
Ans: A

907- Nifedipine was given to a pregnant lady for preterm labor. what is its mechanism of action?

A- Calcium channel blocker
B- Promote uterine strength
C- Promote vaginal contractions
D- Antibacterial
E- Potassium channel blocker
Ans: A

908- A non pregnant Female presented with galactorrhea. Drug of choice in this case should be:

A- Levothyroxin
B- Bromocriptine
C- Insulin
D- Vitamn D
Ans: B

909- Which ATT drug cause orange color urine

A- INH
B- Rifainpicin
C- Streptomycin
D- Pyrazinamide
Ans: B

910- Patient presented with gum hypertrophy and swelling cause is?

A- Phenytoin
B- Carbamazepine
C- Topiramate
D- Lamotrigine
Ans: A

911- Hypertrichosis is caused by

A- Topiramate
B- Carbamazepine
C- Methimazole
D- Phenytoin
Ans: D

912- Doc for air sickness is

A- Mannitol
B- Acetazolamide
C- Pyrodoxine
D- Cyclizine
Ans: D

Explanation:

- Drug in morning Sickness – Pyridoxine
- Drug in motion Sickness – Scopolamine >Meclizine
- Drug in Mountain Sickness – Acetazolamide
- Drug in Air Sickness Mecolzine > Cyclizine

913- Patient was taking carbamazepine started on another drug and noticed his seizure episodes increased this is due to which drug?

A- Amoxicillin
B- Tetracycline
C- Phenobarbitone
D- Chloremphenicol
E- Digoxin
Ans: C

914- Which of the following increases metabolism of drugs:

A- Carbamazepine
B- Phenobarbital
C- Cimetidine
D- Sucralfate
Ans: B

915- A patient develops decreased heart rate after induction of Anesthesia. Drug of choice in this case will be:

A- Epinephrine
B- Nor epinephrine
C- Dopamine and Dobutamine
D- Atropine
Ans: D

CamScanner

916- Patient having recurrent UTI due to pseudomonas drug of choice will be
A- Metronidazole
B- Cefixime
C- Ciprofloxacin
D- Sulfonamide
E- Azithromycin
Ans: C

Explanation:
- Anti pseudomonas Pencillin -Pipercillin and Ticarcillin
- Anti pseumonas Aminoglycosides - Gentamycin and Amikacin
- DOC for Pseudomonas -Ceftazidime
- DOC for Pseudomonas UTI -Ciprofloxacin

917- Patient of IHD went for angiography having bleeding . PT and APTT normal but BT raised this is due to
A- Warfarin
B- Heparin
C- Enoxaparin
D- Aspirin
Ans: D

918- Digoxin toxicity caused by:
A- Hyperkalemia
B- Hypocalcemia
C- Hypokalemia
D- Spiranolactone
Ans: C

Explanation:
Digoxin toxicity caused by
- Hypokalemia
- Hypomagnesemia
- Hypercalcemia
- Alkalosis & Drug causing hypokalemia
- Digoxin toxicity itself cause – Hyperkalemia

919- A patient develops Anaphylactic shock after blood transfusion treatment should be:
A- IVNE
B- IM adrenaline
C- Subcutaneous Adrenaline
D- IV atropine
Ans: B

920- Thiazide like diuretic will cause?
A- Hyperkalemia
B- Hypokalemia
C- Hypernatremia
D- Hyponatremia
E- Hypoglycemia
Ans: B

Explanation:
- Thiazide cause – Hypokalemia> Hyperglycemia > Hyperlipidemia>
- Hyper uricemia >Hyper calcemia >Hyponatremia

921- A patient presented in shock with having increase heart rate; decrease BP and peripheral edema. Whatto give?
A- Dopamine
B- Adrenaline
C- Norepinephrine
D- Atropine
Ans: C

922- Which antimetabolite can be used for non-neoplastic purposes?
A- Azathioprine
B- Cytarabine
C- 5 Flurouracil
D- Mercaptopurine
Ans: A

Explanation:
- Methotrexate is anti-metabolite that has non-neoplastic functions as well such as used in termination of ectopic pregnancy.
- Azathoprine which is anti-metabolite and has non neoplastic & immunosuppressive properties.

923- An epileptic lady who currently on pbenytoin has become pregnant. She is concerned about her medication in pregnancy. Which of the following is correct?
A- Add lithium
B- Replace With Valproic acid
C- Increase dose of phenytoin
D- Add valproic acid
E- Replace with barbiturates
Ans: E

924- Which of the following increases metabolism of drugs:
A- Carbamazepine
B- Phenobarbital
C- Cimetidine
D- Sucralfate
Ans: B

925- A patient on MAO inhibitors is given 1st dose of barbiturate. What will happen due to interaction of these two:
A- Coma
B- Insomnia
C- Euphoria
D- Potentiation of Antidepressants Effects
E- Liver injury
Ans: D

CamScanner

926- A patient was taking antiepiletics for his epilepsy disorder. He noticed Hypertrophy of Gingiva alongwith one episode of bleeding from mouth. Most likely cause of this:
A- Sodium valporate
B- Benzodiazepene
C- Phenytoin
D- Carbamazepine
Ans: C

927- A Man is in ICU because of Toxicity of Tricyclic depressrants which is most likely:
A- Convulsions
B- QT Prolongation
C- Coma
D- Hypertension
Ans: A

928- CT brain of patient shows cyst with multiple daughter cysts, which of the following is the DOC ?
A- Pyrantel Pamoate
B- Niclosamide
C- Albendazole
D- Mebendazole
E- Metronidazole
Ans: C

Explanation:
- Cyst with daughter cyst in brain by – Tenia Echinococcus
- Neurocysticercosis caused by – Tenia solium

929- Early Pulmonary Anthrax, Drug of choice:
A- Aminoglycosides
B- Penicillin
C- Penicillamine
D- Ciprofloxacin
Ans. D

930- In an ICU patient with CVP line in subclavian vein for the past 10 days is on parenteral nutrition. He developed fever, blood culture showed clusters of gram positive cocci the infection is most likely treated by:
A- Amoxicillin + clavulanic acid
B- Vancomycin
C- Ceftazidime
D- Imepenam
E- Piperacillin + Tazobectam
Ans: B

931- A 40-year-old teacher presents with tremors and poor handwriting. There was no rigidity and the movement was intact. There is family history of similar problems. What is your drug of choice?
A- Bromocriptine
B- Propranolol
C- Fluoxetine
D- Imipramine
Ans: B(Benign Essential tremor)

932- A patient, who is known case of RA is started on DMARDS .He now presents with history of SOB and CXR reveals bilateral infiltrates. Which drugs is most likely responsible?
A- Cyclophosphamide
B- Methotrexate
C- Daunorubicin
D- Cycloserine
Ans: B

933- Which drug needs alkanization of urine to excrete out of body?
A- Morphine
B- Phenobarbitone
C- Spironolactone
D- Acetaminophen
E- Amphetamine
Ans: B

934- A Patient presented with ingestion of something in drousy condition, mild depression of respiration on duty doctor manage it with NaHCO3 what he has ingested
A- Dizepam
B- Digoxin
C- Phenobarbitone
D- Pyrimethamine
E- Morphine
Ans: C

935- Aspirin inhibits which of the following for analgesic purpose?
A- Thromboxane A2
B- Prostaglandin
C- LTB4
D- COX2
E- Prostacyclin
Ans: B

CamScanner

936- A 32 year old female present in ER with Headache, dyspnea, palpitations, impounding doom .She is lethargic and anxious. Examination reveals Cold & clammy skin, BP 230/160, HR 58.Investigation show a K+Level of 3.5mEq/L. Which of the following will provide immediate control?

A- Alphal Blocker
B- Beta2 blocker
C- Alpha 2 blocker
D- Beta 1 blocker
E- Aldosterone antagonists
Ans: A

937- A patient using steroid for very long time he is at risk of:

A- Hypoglycemia
B- Hypokalemia
C- Osteogenisis
D- Osteoprosis and fracture
E- Stomach Ulcer
Ans: D

938- Patient on second line anti TB drugs. Which drug causes depression and suicidal thoughts?

A- Cycloserine
B- Amikacin
C- Ethionamide
D- Linezolid
E- Moxifloxacin
Ans: A

939- A pregnant lady was presented in ER with raised bp. Methyldopa was given. What is the mechanism of action of methyldopa?

A- Blocks Neurotransmitter
B- Block Sympathetic CNS
C- Acts on central alpha 2 receptors
D- Direct relaxation of Arteriolar smooth muscle
E- Stimulation of Adrenergic ending at postganglionic fibers
Ans: C

940- A Patient on ATT drugs stops without consulting doctor, which one drug when stop has deliteruous effect

A- Strepomycin
B- Ethambutal
C- Pyrazinamide
D- INH
E- Rifampicin
Ans: A

941- First initial management for DKA?

A- IV insulin +Normal saline
B- Oxygen inhalation
C- Bicarbonate administration
D- Diuretic
Ans: A

942- Known diabetic patient on oral hypoglycemic drug came in emergency with low blood glucose 30mg/dl Drug causing it:

A- Glebeinclaimide
B- Acarbose
C- Metformin
D- Insulin
E- Thiazolindiandione
Ans: A

943- In aggressive and disturbed Child drug given would be

A- Haloperidol
B- Clomipramine
C- TCA
D- Caebamezapine
Ans: A

944- Patient on ATT with Swelling of ankle most likely due to:

A- Rifampicin
B- Streptomycin
C- Ethambutol
D- Pyrazinamide
E- Isoniazid
Ans: D

Explanation:

- *Isoniazid* – Peripheral neuropathy
- *Rifampicin* – Red/Orange Urine
- *Ethambutol* – Optic neuritis
- *Pyrazinamide* – Hyperuricemia(Gout)

945- Which of the following has both Alpha and Beta adrenergic properties?

A- Isopretrenol
B- Albuterol
C- Epinephrine
D- Metpretrenol
Ans: C

946- A 48-year-old male presented with complain of severe headache and blurring of vision, doctor performed the LP, he found that the CSF is blood stained, In treatment of SAH, which CCB can be used?

A- Nifedipine
B- Verapamil
C- Diltiazem
D- Nimodipine
Ans: D

CamScanner

947- A young boy has sorethroat, Myalgia, Cough & cervical lymphadenopathy. Which antibiotic is contraindicated for him?
A- Amoxicillin
B- Erythromycin
C- Amikacin
D- Ciprofloxacin
Ans: A

Explanation:
- Infectious mononucleosis rash aggravated by takin amoxillin

948- In Terminal cancer, Morphine is given along with which of the following to reduce side effects?
A- Codeine
B- Naloxone
C- Paracetamol
D- Hyoscine
Ans: C

949- 26-year-old female presented with complain of her fingers turning white then blue then red when exposed to cold. What is the ideal treatment for her problem?
A- Amlodipine
B- Propranolol
C- Ramipril
D- Rifampicin
E- Valsartan
Ans: A

950- Which of the following drugs causes pedal edema?
A- Amlodipine
B- Erythromycin
C- Metronidazole
D- Cephalosporin
Ans: A

951- To treat acetaminophen poisoning which antidote is used?
A- Glutathione
B- Glutamine
C- HCO3
D- N Acetyl cysteine
E- Nalaxone
Ans: D (Katzung)

952- Which of the following medications is commonly used to stabilize cardiac membranes in cases of severe hyperkalemia?
A- Insulin
B- Calcium gluconate
C- Sodium bicarbonate
D- Beta-agonists
Ans: B

953- A patient with diabetes mellitus presents with the complaint of the worst headache of their life. Which of the following treatments would be most appropriate for this condition?
A- Nifedipine
B- Nimodipine
C- Verapamil
D- Propranolol
Ans: B

954- 6-month baby diagnosed with whooping cough (Pertussive) drug given for this is?
A- Meronem
B- Erythromycin
C- Ampicillin
D- Cefixime
E- Ciprofloxacin
Ans: B

955- Anasthetic that causes malignant hyperthermia:
A- Cisatracurium
B- Ketamine
C- Propofol
D- Halothane
E- NO
Ans: D

956- Which muscle relaxant should generally be avoided in burn patients?
A- Succinylcholine
B- Lidocaine
C- Pancuronium
D- Vecuronium
E- Atracurium
Ans: A

957- Patient came in ER, bp 90/40, heart rate 40, what will you give?
A- Atropine
B- Norepinephrine
C- Dobutamine
D- Dopamine
Ans: A

958- Which of the following antiarrhythmic medications is known to cause hypothyroidism?
A- Lidocaine
B- Lithium
C- Amiodarone
D- Sotalol
E- Quinidine
Ans: C

CamScanner

959- The Wheatstone bridge in anesthesia is used to measure:
A- Blood pressure
B- Voltage fluctuations in electrical circuits resistance
C- Respiratory rate
D- Temperature of the patient
Ans: B

960- Which of the following inhalational anesthetics is most likely to increase intracranial pressure (ICP) more than others?
A- Halothane
B- Isoflurane
C- Enflurane
D- Desflurane
Ans: A

Explanation:
- Order of Decrease in Cerebral Vascular risitance & Increase in Cerebral Blood flow is → Halothane > Desflurane > Isoflurane > Sevoflurane
- Order of decrease in O2 Consumption in CNS → Sevoflurane > Isoflurane > Desflurane > Halothane

961- Which antidiabetic medication should be stopped before surgery due to the risk of causing lactic acidosis?
A- Sitagliptin
B- Insulin
C- Metformin
D- Sulfonylurea
Ans: C

962- Which of the following drugs has both positive inotropic and positive chronotropic effects?
A- Glucagon
B- Digoxin
C- Amiodarone
D- Epinephrine
E- Norepinephrine
Ans: D

963- DOC for Acinetobacter baumannii?
A- Imipenem
B- Cephalosporin
C- Gentamicin
D- Vancomycin
Ans: A

964- The plasma half-life of a drug depends on:
A- Elimination from the body
B- Hepatobiliary blood flow
C- First pass metabolism by the GIT
D- Volume of distribution
E- Plasma protein binding
Ans: A

965- Suxamethonium contraindicated in burns patient because of risk of?
A- Hypokalemia
B- Hypercalcemia
C- Hyperkalemia
D- Hypocalcemia
Ans: C

966- A patient who is smoker and known case of diabetes and myxedema presented with bp 150/110, what should be given?
A- Amlodipine
B- Nifedipine
C- Captopril
D- Propranolol
Ans: C

967- Patient with anesthesia lignocaine mixed with adrenaline is given, he has no history of allergy or other disease, develops light headedness, perioral paresthesia, slurring of speech. What happened to this patient?
A- Local reaction of drug
B- Vasovagal response
C- Drug entered in sabarachenoid spase
D- Drug in sabdeural spase
E- CNS toxicity
Ans: A

968- Which of the following medications is most appropriate for treating hypertension in a patient with COPD?
A- Atenolol
B- Propranolol
C- Metoprolol
D- Pindolol
Ans: C

969- A 70-year-old male is prepared for inguinal surgery. Which of the following is the most potent local anesthetic to be used in this patient?
A- Bupivacaine
B- Lidocaine
C- Mepivacaine
D- Ropivacaine
E- Chloroprocaine
Ans: A

970- Which of the following is the most appropriate initial treatment for pheochromocytoma?
A- Phenoxybenzamine
B- Atropine
C- Alpha-1 blockers
D- Beta-blockers
E- Alkaloids
Ans: A

CamScanner

971- Best muscle relaxant to use for rapid sequence intubation in a person with normal anatomy if succinylcholine is contraindicated:
A- Atracurium
B- Vecuronium
C- Pancuronium
D- Rocuronium
Ans: D

972- Patient given suxamethonium as anaeathesia, docsn't recover from it, reason?
A- Deficiency of acetylcholinesterase
B- Deficiency of pseudocholinesterase
C- Deficiency of MAO
D- Deficiency of Plasma cholinesterase
Ans: B

973- Aspirin is used to alleviate arthritis pain primarily due to its action in decreasing which of the following?
A- Cox 2 inhibitor
B- Prostaglandin (PG)-mediated vasodilation
C- Histamine release
D- Leukotriene production
E- Nitric oxide (NO) levels
Ans: B

974- What is the primary function of the Pitzello machine in anesthesia?
A- To analyze the composition of anesthetic gases
B- To monitor the patient's vital signs during surgery
C- To administer intravenous fluids
D- To calibrate anesthesia delivery equipment
E- To control the temperature of the operating room
Ans: A

975- Which of the following best describes Charles's Law?
A- $V \propto T$
B- $V \propto P$
C- $T \propto P$
D- $V \propto T$
Ans: A

976- Which law relates to pressures and densities in flow meters?
A- Poiseuille's Law
B- Charles's Law
C- Graham's Law
D- Hagen's Principle
Ans: A

977- Which anesthetic cause hyperthermia:
A- Halothane
B- Desflurane
C- Isoflurane
D- Enflurane
Ans: A

978- A patient experiences very low heart rate during surgery. What is the most appropriate treatment?
A- Atropine
B- Theophylline
C- Calcium
D- Epinephrine
Ans: A

979- Which of the following Antihypertensive drug is given Intraoperatively to immediately lower the BP?
A- Hydralazine
B- Glyceryl trinitrate
C- Metoprolol
D- Captopril
E- Methyldopa
Ans: B

980- A patient on phenytoin is planned for surgery. What should be the next step regarding phenytoin management?
A- Stop phenytoin before surgery as it interacts with the metabolism of other drugs in the liver
B- Continue phenytoin and monitor blood levels
C- Switch to an alternative anticonvulsant medication
D- Increase the dose of phenytoin to ensure adequate seizure control during surgery
Ans: B

981- A patient with ischemic heart disease presents with ventricular tachycardia (VT) with a QRS duration of 140-200 ms. Which of the following treatments is most appropriate treatment?
A- Amiodarone
B- Flecainide
C- Digoxin
D- Lidocaine
Ans: A

982- Vapor pressure is directly related to which of the following?
A- Number of molecules
B- Temperature of the container
C- Specific gravity
D- Surface tension
Ans: B

CamScanner

983- A steep dose-response curve typically indicates which of the following?
A- Small change in dose leading to a high response
B- Drug excretion
C- Area under the curve
D- Steady-state concentration
Ans: A

984- Cell wall synthesis inhibitor is:
A- Aminoglycosides
B- Cephalosporin
C- Penicillin
D- Ciprofloxacin
E- Fluoroquinolones
Ans: C

985- A patient developed buccal swelling and tachycardia after taking a drug. What is the most appropriate treatment to administer now?
A- Dopamine
B- Epinephrine
C- Norepinephrine
D- Atropine
Ans: B

986- Sterilization of OT walls after surgery?
A- 1% hypochlorite
B- 3% hypochlorite
C- Glutaraldehyde
D- Soap and water
E- 1% phosphoenol
Ans: A

987- What is the mode of action of ipratropium?
A- Prevents antigen-antibody reaction
B- Acts on muscarinic receptors and prevents vasodilation in inflammation
C- Acts on muscarinic receptors and prevents bronchoconstriction
D- Acts as a beta-agonist to relax bronchial smooth muscle
Ans: C

988- Which of the following is an antagonist for morphine?
A- Naloxone
B- Flumazenil
C- Carbamazepine
D- Diazepam
Ans: A

989- If doctors find no flow of oxygen from a checked E-tank, which of the following is the most likely cause?
A- Tank is empty
B- Respiratory tube blocked/kinked
C- Valve is not properly attached to cylinder
D- There is a defect in the valve
Ans: C

990- Aldosterone antagonists primarily act on which part of the nephron?
A- Distal Convoluted Tubule
B- Collecting Duct
C- Cortical Collecting Tubule
D- Proximal Convoluted Tubule
Ans: B

991- How does a breathing monitor typically monitor breathing?
A- By detecting changes in blood oxygen levels and converting them to electrical signals
B- By detecting mechanical movement and converting it to electrical signals
C- By measuring heart rate variability and converting it to electrical signals
D- By analyzing changes in body temperature and converting them to electrical signals
Ans: B

992- Side effect of thiazide diuretics?
A- Hyperkalemia
B- Hypercalcemia
C- Hypocalcaemia
D- Hypokalemia
E- Hyperglycemia
Ans: D

993- Gentamicin is contraindicated in which of the following conditions due to its potential for exacerbating the condition?
A- Chronic Kidney Disease (CKD)
B- Chronic Liver Disease (CLD)
C- Diabetes Mellitus
D- Portal Hypertension
E- Asthma
Ans: A

994- Aspirin is used to alleviate arthritis pain primarily due to its action in decreasing which of the following?
A- Bradykinin
B- Prostaglandin (PG)-mediated vasodilation
C- Histamine release
D- Leukotriene production
E- Nitric oxide (NO) levels
Ans: B

CamScanner

995- Propylthiouracil is drug of choice for:
- Graves' disease
- Graves' disease in SLE
- Graves' disease in pregnancy
- Thyrotoxicosis
- Liver disease

Ans: C (Davidson)

Explanation:
Propylthiouracil is preferred drug of choice in 1st trimester. Carbimazole is associated rarely with embryopathy, particularly skin defect, aplasia cutis.
In Liver disease its contraindicated because of reported hepatitis...
In Graves' disease and multi nodular goiter Carbimazole are drug of choices

996- Patient given suxamethonium as anaesthesia, doesn't recover from it, reason is
- Deficiency of acetylcholinesterase
- Deficiency of pseudocholinesterase
- Deficiency of MAO
- Deficiency of Plasma cholinesterase

Ans: B

997- Patient is diabetic and conscious for weight loss on antidiabetic which drug she is using
- Metformin
- Glibinclamide
- Tulbutamude
- Sulfonylurea

Ans: A

998- Abciximab mechanism of action is
- Block Glycoprotein 2a
- Block glycoprotein IIb/IIIa
- Activate glycoprotein IIb
- Inhibit IIIa

Ans: B

999- In aggressive and disturbed Child drug given would be
- Haloperidol
- Clomipramine
- TCA
- Caebamezapine

Ans: A

1000- Paracetamol intoxication is reversed by:
- N acetyl cysteine
- Codeine
- Naloxone
- Phenobarbitone

Ans: A

1001- A patient ,Known smoker, diagnosed case of Myxedema and DM, With BP recorded as 170/110mmHg,Which drug to Give for His Hypertension?
- A- Levothyroxine
- B- Propranolol
- C- Captopril
- D- Methimazole

Ans: C

1002- Mechanism of action of aspirin in myocardial infarction is
- A- Inhibition of thromboxane synthesis
- B- Inhibition of cyclooxygenase enzyme
- C- Inhibition of prostacyclin synthesis
- D- Inhibition of formation of free radicals

Ans: A

1003- Drop in temperature after giving GA to patient due to:
- A- Loss of skeletal muscle tone
- B- Decreased activity of Na+/K+ pump
- C- Peripheral activity of Anterior pituitary
- D- Decreased Cardiac Activity
- E- Decreased BMR

Ans: A

1004- A patient with corneal opacity is being evaluated for potential causes. Which medication is most commonly associated with corneal deposits leading to this condition?
- A- Ethambutol
- B- Chlorpromazine
- C- Choloroquine
- D- Ethionamide
- E- Thioridazine

Ans: C

Explanation:
- Corneal opacity – Chloroquine
- Retina deposit – Thioridazine
- Lens deposit – Chlorpromazine

1005- A female diabetic patient came to OPD presenting with BP = 100/80, Pulse = 110, Glucose = 40. She came 2 days earlier when the doctor suggested a new antihypertensive, which she started 2 days ago.Which drug is likely responsible?
- A- Pentazocin
- B- Hydralazine
- C- Propranolol
- D- Hydrochlorothiazide
- E- Methyldopa

Ans: C

CamScanner

Explanation:
Propranolol, a non- selective beta- blocker, can cause hypoglycemia by inhibiting glycogenolysis and masking hypoglycemia symptoms like tremors and palpitations. In this diabetic patient, hypoglycemia (glucose = 40) and recent initiation of an antihypertensive strongly suggest propranolol as the cause.

1006- Which of the following drugs is associated with pulmonary fibrosis as a side effect?
A. Vincristine
B. Cyclophosphamide
C. Cisplatin
D. Bleomycin
E. Doxorubicin
Ans: D

1007- A patient on Anti-Parkinson drugs develops discoloration of Urine. Which drug is most likely responsible for this?
A- Levodopa
B- Carbidopa
C- Entacapon
D- Amantadine
Ans: C

1008- MOA of Vancomycin:
A- Acts on human cells but not bacterial cells
B- Converts DHF to THF
C- Causes change in bacterial component
D- Converts DHF to THF
Ans: C

1009- A 50 year old male patient with a history of asthma is using a beclomethasone inhaler for long time ,he presents with whitish membrane in mouth what u will advice to him
A- Rinse mouth after use
B- Continue inhaler without rising
C- Discontinue inhaler
D- Use inhaler at night to avoid this
E- Amphotericin
Ans: A

1010- A 45 year old patient presents with diarrhea, and vomiting on DRE rectum was smooth and warm on sigmoidoscpy no mass was present, but rectal mucosa was inflammed which of the following is appropriate treatment
A- 5 aminosalicyclic acid
B- Topical Steriods
C- IV Antibiotics
D- Only follow up
E- Enema with salazine
Ans: A

1011- A 37-year-old female at 37 weeks of gestation reports progressively reduced fetal movements. Fetal heart rate is 140 bpm. What is the most appropriate next step?
A- Immediate Cesarean section
B- Continuous fetal heart rate monitoring for 6 hours
C- Ultrasound assessment, including a biophysical profile
D- Wait & Watch
Ans: C

1012- Anaphylactic sock treatment.
A- Anti-Histamines
B- Fresh blood transfusion
C- Blood Transfusion
D- Dopamine
Ans: A

1013- How does histamine stimulate the release of gastric acid in the stomach?
A- By increasing cAMP in parietal cells
B- By activating H+/K+ ATPase directly
C- By increasing intracellular calcium levels
D- By stimulating acetylcholine release
E- Efflux of Potassium
Ans: A

1014- Drug used to treat Opioid dependance:
A- Naloxone
B- Methadone
C- Fluoxetine
D- Benzodiazepenes
Ans: B

1015- Drug-Drug interaction occur
A- With drug only
B- Pharmacodynamic only
C- Pharmacokinetic only
D- Pharmacodynamic and Pharmacokinetic both
Ans: D

1016- The most effective concentration of alcohol diluted in water for disinfection is
A- 70-80%
B- 60%
C- 30%
D- 50%
Ans: A

1017- DOC for Clostridium Perfringes:
A- Clindamycin
B- Tetracycline
C- Ciprofloxacin
D- Azithromycin
E- Amoxicillin
Ans: A

CamScanner

1018- A presented with Fever & Neck Stiffness. Labs Reveal protein levels of 200-400, Glucose : 10, Increased Neutrophils. Gram staining shows gram positive diplococci in clusters. Most suitable Treatment option will be:
A- Ceftriaxone +Vancomycin
B- Ceftraixone+Azithromycin
C- Ciprofloxacin+Ceftriaxone
D- Cefepime+Vancomycin
Ans: A

1019- 50 years old Patient diagnosed case of SLE Lupus Nephritis with DPGN WHO Class IV- Most suitable treatment combination
A- Azathioprine +IV cyclophosphamide
B- Methotrexate+ Prednisolone
C- Prednisolone +Azathioprine
D- Prednisolone
E- Azathioprine
Ans: A

1020- Alpha 1 antagonist used in hypertension:
A- Doxazocin
B- Clonidine
C- Propranolol
D- Atenolol
Ans: A

Explanation:
Doxazosin is an alpha-1 adrenergic antagonist that relaxes vascular smooth muscle, leading to vasodilation and a reduction in blood pressure. It is commonly used for hypertension and benign prostatic hyperplasia

1021- Bacteriostatic drug for Tuberculosis:
A- Rifampicin
B- Pyrizinamide
C- Syreptomycin
D- INH
E- Paraaminosalicylic acid
Ans: D

Explanation:
Bactericidal vs. Bacteriostatic TB Drugs

Drug	Type	Mechanism
Rifampicin (RIF)	Bactericidal	Inhibits RNA synthesis
Isoniazid (INH)	Bactericidal /Static	Inhibits mycolic acid synthesis
Pyrazinamide (PZA)	Bactericidal	Disrupts energy production and membrane
Streptomycin (STM)	Bactericidal	Inhibits protein synthesis
Ethambutol (EMB)	Bacteriostatic	Inhibits cell wall synthesis

INH (Isoniazid) can act as a bacteriostatic agent against *Mycobacterium tuberculosis* in resting bacteria, though it is bactericidal against actively dividing bacteria.

1022- A patient went for tooth extraction. She was advised some antibiotic along with multivitamins & calcium supplements. She was also taking candesartan tablet. Effectiveness of which antibiotic will be affected in this case?
A- Oxytetracycline
B- Amoxicillin
C- Metronidazole
D- Ciprofloxacin
Ans: A

Explanation:
Oxytetracycline, a tetracycline-class antibiotic, binds to calcium, forming insoluble complexes in the gastrointestinal tract. This reduces its absorption and effectiveness when taken alongside calcium supplements. Other antibiotics listed are not significantly affected by calcium

1023- Antacid available readily & used commonly at home without Prescription is which one of the following?
A- Calcium carbonate
B- Sodium bicarbonate
C- Magnesium Trisilicate
D- Magnesium Oxide
Ans: B

1024- You are a House Officer working in Gynae Emergency. A patient comes to You at gestational age of 40wks with irregular uterine contractions. What will you do?
A- Oxytocin
B- Progesterone
C- Estrogen
D- Tranexamic acid
E- LH
Ans: A

1025- A Patient presented with severe asthma FEV1 less than 50 and he is cyanosed treatment given Salbutamol and Salmeterol but not working what is next treatment?
A- Octreotide
B- Monteluekast
C- Theophylline
D- Zafirlukast
E- Ipratropium
Ans: E

1026- A laboratory technician presents with dry mouth, keratitis, and nasal septum perforation. What is the most likely diagnosis?
A- Acute arsenic poisoning
B- Chronic lead poisoning
C- Acute lead poisoning
D- Acute mercury toxicity
E- Chronic mercury toxicity
Ans: E

1027- A female patient with no prior medical history presents with jerky movements in her left arm for the past two weeks with no history of loss of consciousness. Which drug is the most appropriate treatment?
A - Carbamazepine
B - Ethosuximide
C- Phenytoin
D- Propranolol
Ans: A

CamScanner

Explanation:

- The patient presents with **jerky movements in her left arm** without loss of consciousness, which is characteristic of **focal (partial. seizures**, particularly **focal motor seizures.**
- **Carbamazepine** is the first- line treatment for **focal seizures** as it effectively stabilizes neuronal membranes by blocking voltage-gated sodium channels.

1028- Low concentration epinephrine from Adrenal medulla causes Vasodilation via:

A- B1 adrenergic
B- B2 adrenergic
C- Cholinergic
D- M2
Ans: B

Explanation:

Tissue Distribution of Adrenergic Receptors

Receptor	Tissue	Effect(s)
α1	Vascular smooth muscle Visceral smooth muscle	Vasoconstriction Smooth muscle contraction
α2	Pancreas Presynaptic terminals Salivary glands	Inhibition of insulin secretion Inhibition of neurotransmitter release Inhibition of salivary secretion
β1	Heart Kidney	↑ heart rate, contractility ↑ renin secretion
β2	Bronchioles Cardiac muscle Liver Arterial smooth muscle Pancreas	Bronchodilation ↑ heart rate, contractility Glycogenolysis, glucose release Vasodilation Stimulation of insulin secretion
β3	Adipose	↑ lipolysis

1029- A patient presents with a laceration on the foot, and gram-positive cocci are identified. Which is the most appropriate drug for treatment?

A - Gentamicin
B - Penicillin
C - Amoxicillin/Clavulanic acid
D- Ciprofloxacin
E- Cloxacillin
Ans: C

1030- A 65-year-old patient presents to the emergency department with severe hyperkalemia confirmed on laboratory tests. Which of the following treatments is most effective in lowering serum potassium levels?

A. Insulin
B. Epinephrine
C. Beta Adrenergic blocker
D. Alpha Adrenergic
E. Aldosterone Antagonist
Ans: A(Clinical nephrology textbook)

Explanation:

Treatment of Hyperkalemia

Mechanism	Therapy
Stabilize cell membrane potential	IV calcium gluconate (10 mL of 10% solution)
Shift K into cells	Inhaled β_2- agonist (e.g., salbutamol) IV glucose (50 mL of 50% solution. and insulin (10 U Actrapid) IV sodium bicarbonate (100 mL of 8.4% solution)
Remove K from body	IV furosemide and normal saline Ion exchange resin (e.g., Resonium) orally or rectally Dialysis

1031- Lithium mood stabilizer effect takes place in how much duration?

A- 2 to 3 weeks
B- 4 weeks
C- 8 Weeks
D- 16 Weeks
Ans: A

1032- Reduction in prostate size is achieved by inhibiting which enzyme?

A- 5- alpha reductase
B- Testosterone
C- DHT
D- Cortisol
Ans: A

1033- Female patient presented with complains of Increased urinary frequency, Burning micturition & Hesitancy. There is no history of Any Vaginal discharge. Urine Culture Exam shows Gram negative rod. Most suitable drug for her condition is?

A- Gentamicin
B- Metronidazole
C- Ceftriaxone
D- Penicillin
Ans: C

CamScanner

1034- A patient presents with painful swelling of the big toe, and uric acid crystals are identified, leading to a diagnosis of gout. The patient is prescribed allopurinol 300 mg. Which of the following factors will most likely affect the bioavailability of allopurinol?

A- Alpha-1 acidic glycoprotein
B- Albumin
C- Triglycerides
D- Cholesterol
Ans: A

1035- Tamoxifen is given to a patient who is having Ca Breast. Keeping in mind that Tamoxifen has both Estrogenic and Anti Estrogenic effects. What would be the possible side effect:

A. Infertility
B. Endometrial hyperplasia
C. Facial hair
D. Contralateral Breast carcinoma
Ans: B

Explanation:

- Tamoxifen is selective estrogen receptor modulator.
- **Anti-Estrogenic action:** Reduce breast tumor size and causes hot flushes.
- **Estrogenic Action:** Endometrial proliferation, reduces cholesterol and anti resorptive effect on bones

1036- Patient came In OPD with recurrent calcium stones what will you give for treatment?

A- Acetazolamide
B- Mannitol
C- Loop diuretics
D- Potassium sparing diuretic
E- Thiazide diuretics
Ans: E

1037- 72-year-old patient was started on an antidepressant. After 3 days, he developed urinary retention and constipation. Which of the following antidepressants is most likely responsible for these side effects?

A- Amitryptyline
B- Sertraline
C- Paroxetine
D- Clozapine
Ans: A (Katzung)

Explanation:

- It is a tricyclic antidepressant (TCA) known for its strong anticholinergic properties.
- Anticholinergic effects include **urinary retention, constipation,** dry mouth, and blurred vision.
- Anticholinergic effects are perhaps the most common. These effects result in dry mouth, constipation, urinary retention, blurred vision, and confusion. They are more common with tertiary amine TCAs such as **amitriptyline and imipramine** than with the secondary amine TCAs desipramine and nortriptyline.
- The potent α-blocking property of TCAs often results in orthostatic hypotension.
- H 1 antagonism by the TCAs is associated with weight gain and sedation.
- The TCAs are class IA antiarrhythmic agents and are arrhythmogenic at higher doses.
- Sexual effects are common, particularly with highly serotonergic TCAs such as clomipramine

1038- The drug of choice for gas gangrene is

A- Clindamycin
B- Ciprofloxacin
C- Norfloxacin
D- Doxycycline
Ans: A(Levinson microbiology)

Explanation:

- Penicillin G plus clindamycin is the treatment of choice.
- Wounds should be cleaned and debrided. Incision and drainage of focal lesions should be done.
- Penicillin may be given for prophylaxis. There is no vaccine

1039- How does histamine stimulate the release of gastric acid in the stomach?

A- By increasing cAMP in parietal cells
B- By activating H+/K+ ATPase directly
C- By increasing intracellular calcium levels
D- By stimulating acetylcholine release
E- Efflux of Potassium
Ans: A

1040- "Tricyclic Antidepressants" work by:

A- Increasing serotonin in neural tissue
B- Inhibit Amine Uptake in presynaptic terminal
C- Inhibit RE-uptake of Nor Epinephrine
D- Highly selective Blockade of Dopamine Receptor
Ans: C(Katzung)

CamScanner

Explanation:
The TCAs resemble the SNRIs in function, and their antidepressant activity is thought to relate primarily to their inhibition of 5-HT and norepinephrine reuptake

1041- Patient developed hypoxia and drowsiness during bronchoscopy due to sedation. How to Reverse this?
A- Flumazenil
B- Naloxone
C- Atropine
D- Opoids
Ans: A

1042- A female Patient was given thiopental sodium 5mg/kg for induction and suddenly patient developed pain in hand and carpospasam. In addition to immediately diluting the already given drug what further you can do
A- Give IV lignocaine
B- Give Epinephrine
C- IM Amidaron
D- IV Atropine
Ans: A

1043- 120kg female gravidal para1 with history of extensive gastrointestinal reflex is now planned for emergency lower segment cesarean section. Before intubation patient is decided to given a cover for her problem
A- IV omeprazole
B- Intra venous ranitidine
C- Intravenous aluminium hydroxide
D- Oral Sodium Citrate
E- Aluminium Hydroxide
Ans: A

1044- A 35-year-old IV drug user presents with fever and is suspected of having infective endocarditis. Blood cultures reveal Gram-positive cocci in clusters. What is the drug of choice for treating this condition?
A- Cloxacillin
B- Ciprofloxacin
C- Cefepime
D- Ceftriaxone
Ans: A

1045- A patient on digoxin undergoes a preoperative assessment. Which ECG finding would indicate the need to discontinue digoxin before surgery?
A- Premature Ectopic beats from ventricle
B- Third degree heart block
C- Sinus Bradycardia
D- Delerium
E- Ventricular origin Extrasystole
Ans: B(Katzung)

Explanation:
Effects of Digoxin on Electrical Properties of Cardiac Tissue:

Tissue or Variable	Effects at Therapeutic Dosage	Effects a Toxic Dosa
Sinus node	↓ Rate	↓ Rate
Atrial muscle	↓ Refractory period	↓ Refractory period, arrhythmias
Atrioventricular node	↓ Conduction velocity, ↑ Refractory period	↓ Refractory period, arrhythmias
Purkinje system, ventricular muscle	Slight ↓ Refractory period	Extrasystole tachycardia, fibrillation
Electrocardiogram	↑ PR interval, ↓ QT interval	Tachycardia, fibrillation, arrest at extremely hi dosage

1046- 24 years old female, 82 kgs weight 5, height on two random occasions h BSL was 165 and 153 she had a stro family history of diabetes what wou you do for her
A- Just wait and watch
B- Ask her to do diet and reduce weight
C- Start regular insulin immediately
D- Oral hypoglycemics
E- Oral hypoglycemic+insluin
Ans: B

1047- A patient with Type I Diabetes Mellitu (DM1) experiences persistent mornir hyperglycemia. Which insulin regimen most appropriate to manage tb condition?
A- Long-acting insulin twice daily
B- Intermediate- acting insulin twice daily
C- Regular insulin combined with intermediate- acting insulin twice daily
D- Ultra-short-acting insulin before meals
E- Short-acting insulin before meals
Ans: C

Explanation:
- Persistent morning hyperglycemia in Type 1 DM can occur due to the dawn phenomenon (early morning rise in blood glucose due to increased counter-regulatory hormones) or insufficient basal insulin overnight.
- The combination of regular insulin (to manage postprandial glucose levels) and intermediate-acting insulin (to provide basal control) twice daily helps address both fasting and postprandial glucose

1048- Critical temperature of oxygen is:
A- +30
B- +60
C- -116
D- +45
Ans: C(Ajay Yadav Anasthesia)

CamScanner

Explanation:
- It is the temperature below which a gas can be stored in liquid form.
- Any gas can be stored in liquid form below its critical temperature.
- The critical temperature of oxygen is -119°C, therefore oxygen reservoirs storing oxygen in liquid form has to maintain a temperature below -119°C

1049- You are working in a DHQ, there is no central gases supply and people rely on E- cylinders. You are using oxygen at the rate of 5L. how long will it last?
A- 80-90 minutes
B- 90-110 minutes
C- 130-140 minutes
D- 60-70 minutes
Ans: B

Explanation:
To calculate the duration of an E- cylinder of oxygen at a given flow rate, use the following formula:
Duration (minutes) = (Cylinder Pressure (PSI) × Conversion Factor) / Flow Rate (L/min)
- Key Values for an E- cylinder:
- Full Cylinder Pressure: 2000 PSI
- Conversion Factor for E- cylinder. 0.28 L/PSI
- Flow Rate: 5 L/min
- Calculation:
- Total Oxygen Available:
- 2000 PSI × 0.28 L/PSI = 560 Liters
- Duration:
- 560 Liters / 5 L/min = 112 minutes
- The E- cylinder will last approximately 90-110 minutes at a flow rate of 5 L/min.

050- CM5 configuration mcAns:
A- Indifferent lead to left arm
Indifferent lead at V5 area
Indifferent lead to right arm
Indifferent lead to Right atrium
Ans: B

Explanation:
CM5 configuration is commonly used in cardiac monitoring (e.g., telemetry or stress testing) to focus on detecting ischemic changes or arrhythmias.
M5 Configuration:
The positive electrode (active lead) is placed at the V5 position (5th intercostal space, left anterior axillary line).
The negative electrode (indifferent lead) is placed on the right shoulder or right arm

051- A patient with pheochromocytoma is administered propofol for induction. Which muscle relaxant should be given to facilitate intubation?
Atracurium
Vecuronium
Rocuronium
Pancuronium
B

1052- A 65-year-old cardiac patient with left bundle branch block (LBBB), a heart rate of 70 bpm, and blood pressure of 140/90 mmHg requires induction of anesthesia. Which induction agent is the most appropriate?
A- Etomidate
B- Ketamine
C- Propofol
D- Thiopental
Ans: A

Explanation:
- Etomidate is the induction agent of choice for patients with compromised cardiac function or those requiring hemodynamic stability.
- It has minimal effects on heart rate, blood pressure, and myocardial oxygen demand, making it suitable for patients with LBBB and a cardiac condition

1053- A 4 year old boy collapsed in emergency, in initial resuscitation of airway an ETT of 4.5 is done by on call resident. The flow between the ETT tube and micro constriction is laminar flow. The Resistance of Laminar Flow of tube is related to:
A- Radius
B- Density
C- Velocity
D- Viscosity
Ans: A

1054- After passing radial arterial line, arterial BP monitoring follows which principal?
A- Wheatstone bridge
B- Allen's test
C- Boyle law
D- Principle Test
E- Dampmg Law
Ans: A

1055- Asthmatic patient develop SOB usually after physical activity what should be given?
A- Short acting inhaled beta agonist before exercise
B- Oral Prednisolone
C- Mast Cell stabilizer
D- Epinephrine
Ans: A

1056- young female patient presented to emergency with 2 days history of severe Occipital cluster headache and visual disturbance. You gave her a medicine and sent her home. 2 hours later she again presented in emergency with a compliant of shortness of breath . What's the responsible drug for this
A- Propranolol
B- Thiopental
C- Diclofenac
D- Steroid
Ans: A

CamScanner

1057- After undergoing inguinal hernia repair, a patient receives an epidural injection of 15 ml lignocaine with adrenaline for postoperative pain management. Within 2 minutes, the patient develops sudden hypotension. What is the most likely cause of this complication?

A- Drug injected into the subarachnoid space
B- Allergic reaction
C- Systemic toxicity
D- Drug injected into the subdural space
E- Vasovagal response
Ans: C

1058- A 72 years old male patient known case of diabetes type 2 , started on a new oral hypoglycemics regime 2 days ago, now he presented in emergency in unconscious state with sweating, his stat blood sugar levels are 30mg/dl. What's the drug he is taking for 2 days.

A- Exenatide
B- Tolbutamide
C- Glimipride
D- Metformin
Ans: C

1059- After local anesthesia, Patient developed light headedness, perioral paresthesia due to.

A- CNS toxicity
B- Allergic reaction
C- Impending cardiovascular collapse
D- Local Drug reaction
Ans: B

1060- 45 years female is electively planned for hernioplasty, during perioperative Anesthesia assessment she gave the history of allergic reaction during her hysterectomy to bupivacine and ropivacine. Which drug is safe to use in this patient?

A- Lidocaine
B- Prilocaine
C- Mepivacaine
D- Etidocaine
Ans: A

1061- A 67 years female planned for hernioraphy, she is a known case of CCF the choice of short acting anesthetic in her would be?

A- Mivacurium
B- Atracurium
C- Etomidate
D- Bupivacaine
Ans: C

1062- A 77 years male [illegible] chronic liver disease. He has a history of 46 pack years, now also a patient of COPD, is planned for a elective surgery. The choice of Muscle relaxant In this patient is:

A- Atracurium
B- Cisatracurium
C- Succinylcholine
D- Ropivacine
Ans: B

Explanation.

- **Metabolism.** Cisatracurium is metabolized via **Hofmann elimination**, a non-enzymatic process that does not depend on liver or kidney function. This makes it ideal for patients with liver or renal impairment.
- **Hemodynamic stability.** Cisatracurium has minimal cardiovascular effects, making it safe for patients with CCF.
- **COPD.** It avoids the histamine release associated with atracurium, which could exacerbate bronchospasm in COPD patients

1063- Diuretic of choice in neuro surgery patients is?

A- Loop diuretics
B- Osmotic diuretics
C- Mannitol
D- Thiazide Diuretics
Ans: C

1064- Difference between Nor- adrenaline and adrenaline is that the later:

A- Decreases Skin Vasodilation
B- Increases TPR
C- Increases Heart rate more significantly than noradrenaline
D- Decreases Skeletal muscle resistance
E- Increases Myocardial Contraction
Ans: C

1065- A drug reported to have Vmax measured in 8liters of plasma in a 70kg man based on this information how this drug likely distributed in the body

A- Distribute In Ecf only
B- Distribute in ICF only
C- Distribute in whole body evenly
D- Distribute in plasma only
Ans: A

1066- A 22 year old female patient presents in gynae OPD with complain of dysmenorrhea after the clinical evaluation indomethacin was prescribed what is the primary mechanism by which indomethacin relieve her pain

A- By reducing prostaglandins F2
B- By reducing bradykinin levels
C- By inhabiting Lipooxygenase
D- By increasing uterine blood flow
Ans: A

CamScanner

1067- A 30 year old female patient undergoing dental extraction process she also has the history of gastric ulcer and which of the following analgesic would be safe to give her after dental process
A- Aspirin
B- Ibuprofen
C- Indomethacin
D- Paracetamol
E- Diclofenac
Ans: D

1068- A patient undergoing surgery, anesthetiologists give ketamine and propofol Despite many attempts intubation was failed anesthiologists noticed that patient has developed opioid induced stiffness and respiratory distress what is the next step in management for
A- Continue intubation
B- Give muscle relaxants
C- Give midazolam
D- Give naloxone
E- Increase the dose of anaesthetic drugs
Ans: D

1069- 14 years old Child diagnosed with Meningitis had CSF Culture positive for strep pneumoniae, Drug to be given for treatment?
A- Clindamycin
B- Tetracycline
C- Fluoroquinolone
D- Penicillin
Ans: D(No option of Ceftriaxone)

1070- Barbiturates cause:
A- Increased sleep latency,
B- Decreased sleep latency
C- Increase REM sleep duration
D- Changes in NREM sleep stages 2 & 3
Ans: B

Explanation:
- Barbiturates decrease sleep latency (time taken to fall asleep) by enhancing GABAergic activity in the brain, leading to sedation. However, they also reduce REM sleep duration and cause changes in NREM sleep stages

1071- Drug given to patient with Local complex partial seizures:
A- Carbamazepine +Promidine
B- Carbamazepine Only
C- Levetiracetum
D- Sodium Valproate
E- Ethionamide
Ans: A

1072- Patient is diagnosed case of TB & has been on ATT drugs from past 2 months. He has developed Jaundice now & deranged LFTs on Investigations. What will be your next line of management?
A- Stop all 4 drugs and observe
B- Stop all drugs and restart 1 by 1
C- Stop INH and rifampin and given moxifloxacin
D- Stop INH, Rifampin & give moxifloxacin in combination with streptomycin
Ans: B

Explanation:
- When a patient on anti- tuberculosis treatment (ATT) develops jaundice and deranged liver function tests (LFTs), the next step involves stopping all hepatotoxic drugs to allow liver recovery.
- After the LFTs normalize, the drugs are reintroduced one by one to identify the culprit drug causing hepatotoxicity

1073- A Man was sitting in cold bath, developed chest pain diagnosed as stable angina, which medicine should be given for long term management:
A- Nitroglycerin
B- Calcium channel blockers
C- Beta blockers
D- ACEI
E- ARBS
Ans: B

1074- A patient with bee sting presented to OPD with facial edema and developing difficulty in breathing .Most appropriate step in primary management:
A- Anti-Histamine
B- Adrenaline
C- Atropine
D- Dobutamine
1075- Ans: B

1076- 70-year-old patient with a history of myocardial infarction (6 months ago) who underwent a stent procedure presents with a blood pressure of 200/120 mmHg, despite being on Lisinopril, Atorvastatin, and Metoprolol. His morning blood pressure is recorded as 120/70 mmHg, which drops upon standing from a lying position. Which drug is most likely responsible for this blood pressure variability?
A- Lisinopril
B- Metoprolol
C- Atorvastatin
D- None of these
Ans: B

CamScanner

1077- Patient is infected with both schistosoma hematobium and tenia solium which of the following drug with cover both of his infections

A- Nicolosamide
B- Albendazole
C- Praziquintal
D- Metronidazole
E- Mebendazole
Ans: C

1078- Nitrofurantoin is used as first line treatment in which of the following conditions

A- Prostitis
B- Hepatic abcesses
C- Uncomplicated cystitis
D- Complicatef UTI
E- Epidydamitis
Ans: C

1079- Methotrexate disturbs absorption of which one:

A- Copper
B- Folate
C- Iron
D- Cobalamin
Ans: B

Explanation:
Methotrexate inhibits dihydrofolate reductase, an enzyme required for the synthesis of tetrahydrofolate, a form of folate necessary for DNA synthesis. This results in folate deficiency, leading to impaired cell division and other complications

1080- Young teen girl taking Danazol for endometriosis due to which side effect she stop taking danazol:

A- Hirsuitism
B- Depression
C- Weight gain
D- Hot flushes
Ans: A

1081- Post-Operative complication of Epidural Block?

A- Hypotension
B- Urinary retention
C- Headache
D- Vomiting
Ans: A

1082- A pregnant woman (C0P3) is prescribed aspirin by her doctor. The beneficial effects of aspirin in this case occur primarily through which mechanism?

A- COX inhibition
B- Anti-inflammatory effects
C- Pain relief
D- Factor X inhibition
E- Glycoprotein IIb/IIIa inhibition
Ans: A

1083- MAO inhibitors Contraindicated with

A- Pethidine
B- Fentanyl
C- Morphine
D- Codeine
Ans: A(Katzung)

Explanation:

- MAOIs are associated with two classes of serious drug interactions. The first of these is the pharmacodynamic interaction of MAOIs with serotonergic agents including SSRIs, SNRIs, and most TCAs along with some analgesic agents such as meperidine.
- These combinations of an MAOI with a serotonergic agent may result in a **Life threatening serotonin syndrome.**
- The serotonin syndrome is thought to be caused by overstimulation of 5-HT receptors in the central gray nuclei and the medulla.
- Symptoms range from mild to lethal and include a triad of cognitive (delirium, coma), autonomic (hypertension, tachycardia, diaphoreses), and somatic (myoclonus, hyperreflexia, tremor) effects.

1084- Digoxin toxicity is increased by which of the following?

A- Chlorothiazide
B- Propanolol
C- Aspirin
D- Heparin
Ans: A

Explanation:
Hydrochlorothiazide leads to hypokalemia & hypercalcemia both of them worsens digitalis toxicity

1085- Patient is a case of ITP given IVIG. What is the mechanism of action Of IVIG?

A- Competitively binds to receptors on macrophages
B- FC receptor binding
C- Inhibits t-lymphocytes
D- inhibits B cells to produce antibody
Ans: A

1086- An elderly patient is prescribed a drug. What is the most likely outcome due to age-related changes in pharmacokinetics and pharmacodynamics?

A- Toxicity at therapeutic levels
B- Frequent small doses are more effective
C- Increased drug metabolism
D- Reduced drug absorption
Ans:

CamScanner

1087- A patient presented with Central chest pain relieved by Nitroglycerine. It acts as a:

A- Bronchial constriction
B- Increased Resistance Vasodilation
C- Increased Resistance Capacitance
D- Vasodilation of Resistant Vessel
E- Phosphodiesterase inhibition

Ans: D

1088- Medical student living in hostel has unprotected sex with prostitutes, now presents with painless testicular lesion and ulcer. After a week, symptoms subside, then present with maculopapular rash. What is the treatment?

A- Erythromycin
B- Penicillin G
C- Ciprofloxacin
D- Ceftriaxone

Ans: B

1089- Patient of TB on ATT. Combination of drugs given due to:

A- To increase effectiveness
B- To increase resistance against bacteria
C- To decrease Cost of treatment
D- To increase plasma half life of Drugs

Ans: A

1090- A patient presented with paralysis of Half limb within half hour of onset & diagnosed as a case of Non-Hemorrhagic stroke. Management?

A- Thrombolysis
B- Antiplatelet drugs
C- Anti-Coagulant drugs
D- Statins

Ans: A

1091- MOA of Itraconazole:

A- Inhibit ergosterol synthesis in Fungal cell membrane
B- Inhibit ergosterol synthesis in Fungal cell wall
C- Inhibition of Protein synthesis
D- Inhibition of Nucleic acid

Ans: A

1092- Patient is on benzodiazipine & 7 days later a cholecystectomy is planned. Patient is at the risk of which of the following due to benzodiazipine during surgery?

A- Arryhthmias
B- Seizures
C- Rigidity
D- Longer time to induce anesthesia
E- No Risk

Ans: A

1093- A patient admitted to the ICU for the past 7 days showed improvement with IV meropenem treatment. However, after some time, the patient developed diarrhea. Pseudomonas was identified in the culture. Next Step of management?

A- IV metronidazole
B- Manage symptomatically
C- Add Doxycycline
D- Oral vancomycin

Ans: A

Explanation:
The development of diarrhea after IV meropenem treatment and the identification of Pseudomonas in the culture suggest the possibility of Clostridium difficile infection (CDI) or another superimposed infection causing antibiotic-associated diarrhea

1094- Solubility of a drug increases if:

A- large molecular size
B- lipid soluble
C- Ionized form
D- Negatively charged

Ans: B

1095- Female taking a bunch of antihypertensives now presented with b/L deafness. which drug is responsible?

A- Lisinopril
B- Metoprolol
C- Loop diuretics
D- Thiazide diuretics

Ans: C(Katzung)

Explanation:
- Loop diuretics occasionally cause dose-related hearing loss that is usually reversible.
- It is most common in patients who have dimmished renal function or who are also receiving other ototoxic agents such as aminoglycoside antibiotics

1096- Treatment of Stable Angina:

A- Relieved with Rest
B- Sildenafil
C- Nitrates
D- B-Blockers

Ans: A

1097- Pregnant lady para0+3 at 10 weeks of Gestation, aspirin given.-What is the beneficial effect of aspirin?

A- Inhibition of cyclooxygenase pathway
B- Transform platelets
C- ADP antagonist
D- Platelets activator
E- Inhibits glycoprotein IIB-IIIa

Ans: A

CamScanner

1098- **Epidural anesthesia given at which site:**
A- L5-S1
B- S1,S2,S3
C- L4-L5
D- L3-L6
Ans: C

1099- **A 36 year old male of Lebanese ancestry is being treated for plasmodium vivax malaria. He experiences severe fatigue, back pain and darkened urine. Which one of the following antimalarial drug is most likely to have caused his symptoms?**
A- Pyrimethamine.
B- Artemisinin.
C- Chloroquine.
D- Quinine.
E- Primaquine
Ans: E

1100- **Patient known asthmatic already on Salbutamol & Dexamethasone but Symptoms not relieved. Next step of management would be:**
A- Formetrol
B- Ipratropium
C- Prednisolone
D- Montelukast
Ans: B

1101- **A patient undergoing anti-TB treatment develops increased yellow-colored urine. Which drug is most likely responsible?**
A- Amikacin
B- Isoniazid
C- Cycloserine
D- Moxifloxacin
Ans: B(Prefer Rifapentine and rifampin)

1102- **A 60 year old male presents with chronic heart failure presents with symptoms of volume overload including severe peripheral edema and SOB and basal crypts on lab findings there was low potassium which of the following drug should be prescribed which of the following will treat the culprit**
A- Loop diuretics
B- Spiranolactone
C- Thiazide
D- Mannitol
Ans: B

1103- **Which of the following TB drug is contraindicated in pregnancy**
A- Isoniazid
B- Streptomycin
C- Ethambutol
D- Rifampicin
E- Pyrazinamide
Ans: B

1104- **Complete Effect of TCA on patient**
A- 14 days
B- 10 days
C- 21-30 days
D- 60 days
E- 7 days
Ans: C(not mention anti depressant or analgesic effect)

Explanation:
- Analgesic effect – 1-2 weeks
- Antidepressant effect – 3-4 weeks

1105- **Pregnant women at 34 weeks of gestation with decreased fetal movements ,CTG was normal fetal heart rate was 140 what is next step in management**
A- Ask her to maintain kick chart for 48hrs
B- Perform USG
C- Repeat CTG after 2 hours
D- Induce labour
E- Fetal HR monitor after 6 hour
Ans: B

1106- **To reduce the peripheral side effects of levodopa in Parkinson's disease, which of the following drug is commonly added**
A- Amatidine
B- Carbidopa
C- Bromocriptine
D- Sclegiline
E- Pramipexole
Ans: B

1107- **Basic drugs bind preferentially with:**
A- Albumjn
B- Alpha lglycoprotein
C- Beta globuljn
D- Triglycerides
Ans: B

Explanation:
- Acidic drugs bind with albumin
- Basic drugs bind with Alpha I glycoproteins

1108- **Which of the following Cardioselective Beta blocker has also some sympathomimetic activity**
A- Metoprolol
B- Carvidolol
C- Acebutolol
D- Propranolol
E- Atenolol
Ans: C(katzung)

1109- **Function of metabolities of arachidonic acid pathway**
A- Phagocytosis
B- Vasoconstriction
C- Vasodilation
D- Inflammation
Ans: D

CamScanner

1110- Norepinephrine causes
A- Vasoconstriction and lipolysis
B- Mydriasis and cycloplegia
C- Bronchodilation and hypotension
D- Decreased heart rate and diuresis
Ans: A

1111- Which of the following increases the metabolism of drugs
A- Carbamazepine
B- Phenobarbital
C- Cimetidine
D- Sucralfate
Ans: B

1112- Which of the following is MOA of Tetracycline
A- Inhibition of bacterial cell wall synthesis
B- Inhibition of Bacterial DNA synthesis
C- Inhibition of bacterial protein synthesis
D- Disruption of bacterial cell membrane integrity
E- Inhibition of folic acid synthesis
Ans: C

1113- Which of the following is MOA of parazocin
A- Alpha 1 Adrenergic anatagonist
B- Alpha 2 Adrenergic antagonist
C- Beta 1 Adrenergic antagonist
D- Beta 2 adrenergic Antagonist
E- Alpha 1 Adrenergic agonist
Ans: A

1114- Sulfa drugs Inhibits which of the following metabolic process
A- Tetrahydofolate synthesis
B- Glycolysis
C- Protein synthesis
D- Fatty acid metabolism
Ans: A

1115- Which of the following is anti-muscarinic systemic effect
A- Decrease heart rate
B- Increase heart rate
C- Increase saliva production
D- Increase GIT activity
Ans: B

1116- Hypomangnesemia is potential side effect of which of the following drug
A- Cisplastin
B- Mthotrexate
C- Azathioprin
D- Lisinopril

1117- Which of the following drug is used to control the heart rate in Atrial fibrillation
A- Labetolol
B- Digoxin
C- Propranolol
D- CCBs
E- Alpha blockers
Ans: C
Explanation:
- Beta blockers are first line treatment in A-fib
- Digoxin is second line treatment in A-fib

1118- How long should the pregnaney be avoided after stopping methotrexate
A- 1 month
B- 2 month
C- 3 month
D- 4 monnth
E- 6 months
Ans: C(Ten teachers)
Explanation:
Methotrexate is medical management of ectopic pregnancy,when patient is taking this it is important to advice her to avoid sexual intercourse during treatment and so avoid conceiving for 3 months after methotrexate treatment because the risk of teratogenicity

1119- A 50 year old male patient with a history of asthma is using a beclomethasone inhaler for long time ,he presents with whitish membrane in mouth what u will advice to him
A- Rinse mouth after use
B- Continue inhaler without rising
C- Discontinue inhaler
D- Use inhaler at night to avoid this
Ans: A

1120- Dose of venofer in iron deficiency
A- 1350mg
B- 1000mg
C- 987mg
D- 865mg
Ans: A (1500mg)

1121- A patient being diagnosed for myasthenia gravis would be expected to show improved neuromuscular function after being treated with:
A- Donepezil
B- Edrophonium
C- Atropine
D- Neostigmine
Ans: D

CamScanner

1122- Neostigmine mechanism of action is:
A- Inhibit Acetyl transferase
B- Inhibit Acetylcholinesterase
C- Promote Acetyltransferase
D- Activate Acetylcholinesterase
Ans: B(Katzung)

Explanation:
Acetylcholinesterase is the primary target of Neostigmine but butyryl cholinesterase is also inhibited. Acetylcholinesterase is an extremely active enzyme. In the initial catalytic step, acetylcholine binds to the enzyme's active site and is hydrolyzed, yielding free choline and the acetylated enzyme. In the second step, the covalent acetyl-enzyme bond is split, with the addition of water (hydration). The entire process occurs in approximately 150 microseconds. All the cholinesterase inhibitors increase the concentration of endogenous acetylcholine at cholinoceptors by inhibiting acetyl- cholinesterase.

1123- A presented with Fever & Neck Stiffness.Labs Reveal protein levels of 200-400, Glucose : 10, Increased Neutrophils. Gram staining shows gram positive diplococci in clusters.Most suitable Treatment option will be:
A- Ceftriaxone +Vancomycin
B- Ceftraixone+Azithromycin
C- Ciprofloxacin+Ceftriaxone
D- Cefepime+Vancomycin
Ans: A

1124- Drug absorption in the gastrointestinal (GI) tract generally follows which type of kinetic order? (Medicine Feb 2025)
A- Zero-order kinetics
B- First-order kinetics
C- Second-order kinetics
D- Michaelis-Menten kinetics
Ans: : B

1125- A patient presents 10 days post-myocardial infarction (MI) with fever and chest pain. Bilateral lung fields are clear, and ECG shows no new changes. What is the most appropriate treatment?(Medicine Feb 2025)
A - Increase dose of anti-anginal drug
B - Anti-inflammatory medication
C - Aspirin
D - Nitroglycerin
Ans: B

1126- In an unconscious, pulseless patient who has been intubated and is receiving CPR, which of the following drugs is ineffective when administered via the endotracheal tube (ETT)?(Medicine Feb 2025)
A - Naloxone
B - Diazepam
C - Lidocaine
D - Norepinephrine
E - Epinephrine
Ans: B

1127- Cyclophosphamide mechanism action: (Medicine Feb 2025)
A: Cross linking of strands of DNA & RNA
B: Inhibiting protein synthesis
C: Stimulate protein sysnthesis
Ans: A

1128- A female patient with a history psychiatric illness goes jogging an subsequently develops a medic emergency. Which drug is most likel responsible for this condition (Medicine Feb 2025)
A - Lithium
B - Haloperidol
C - Clozapine
D - Fluoxetine
Ans: A

1129- Maximum bioavailability of Druv vi which route? (Medicine Feb 2025)
A- IM
B- Sublingual
C- Per rectal
D- Oral
E- Subcutaneous
Ans: B

1130- A patient presents with aspirin (salicylate) toxicity, which is characterized by metabolic acidosis and respiratory alkalosis. Which of the following treatments is most appropriate to help manage the acid-base disturbance?(Medicine Feb 2025)
A- Calcium gluconate infusion
B- Sodium chloride infusion
C- Sodium bicarbonate infusion
D- (Potassium chloride infusion
Ans: C

1131- What is the most likely cause of pulmonary infiltrates in a patient with Hodgkin's lymphoma being treated with the ABVD regimen? (Medicine Feb 2025)
A- Bleomycin
B- Vinblastine
C- Adriamycin (Doxorubicin)
D- Dacarbazine
Ans: A

1132- Which of the following enzymes is commonly found in snake venom?(Medicine Feb 2025)
A- Proteases and Peptidases
B- Collagenases and Hyaluronidase
C- Phospholipase A2
D- All of the above
Ans: D

CamScanner

1133- A 20-week pregnant woman is taking neomercazole (carbimazole) for hyperthyroidism. What is the most appropriate treatment adjustment? Medicine Feb 2025)

A- Stop medication immediately
B- Continue the same treatment
C- Switch to propylthiouracil (PTU)
D- Increase dosage
Ans: C

1134- A 35-year-old woman presents with a history of recurrent deep vein thrombosis (DVT) and pulmonary embolism (PE). Laboratory tests reveal the presence of lupus anticoagulant and anticardiolipin antibodies. Which of the following medications is most appropriate for long-term anticoagulation in this patient?(Medicine Feb 2025)

A- Warfarin
B- Heparin
C- Aspirin
D- Rivaroxaban
Ans: A

1135- Which of the following antihypertensive drugs can cause hypoglycemia (low glucose)? (Medicine Feb 2025)

A- Hydrochlorothiazide
B- Losartan
C- Propranolol
D- Atenolol
Ans: C

1136- Vancomycin is typically dosed at: (Medicine Feb 2025)

A- 500 mg/m²
B- 10-15 mg/kg
C- 1 mg/kg
D- 5 mg/kg
Ans: B

1137- Why is a lower dose of theophylline recommended in infants? (Medicine Feb 2025)

A- Increased metabolism of theophylline
B- Increased number of adenosine receptors
C- Reduced excretion of theophylline
D- Increased sensitivity to theophylline
Ans: C

1138- Which DPP-4 inhibitor is the safest choice for patients with renal impairment? (Medicine Feb 2025)

A- Saxagliptin
B- Alogliptin
C- Linagliptin
D- Sitagliptin
Ans: C

1139- What is the primary mechanism of action of carbamazepine? (Medicine Feb 2025)

A- Calcium channel blocker
B- Sodium channel blocker
C- GABA receptor agonist
D- Potassium channel blocker
Ans: B

1140- A young boy diagnosed with absence seizures is prescribed Ethosuximide. What is its primary mechanism of action? (Medicine Feb 2025)

A- Inhibits sodium channels
B- Enhances GABA receptors
C- Blocks T-type calcium channels
D- Activates GABA type B receptors
E- Potentiates potassium channels
Ans: C

1141- A child diagnosed with attention deficit hyperactivity disorder (ADHD) is being treated with methylphenidate but is unable to tolerate it. Which alternative medication should be considered? (Medicine Feb 2025)

A- Atomoxetine
B- Clonidine
C- Adderall
D- Ritalin
E- Amphetamine
Ans: A

1142- What is the likely effect on blood glucose levels when metformin is combined with hydrochlorothiazide? (Surgery Feb 2025)

A- No effect
B- Variable effect
C- Hypoglycemia
D- Hyperglycemia
Ans: D

1143- What is the typical dosing range for Vancomycin in clinical practice?(Surgery Feb 2025)

A- 500 mg/m²
B- 1 mg/kg
C- 10-15 mg/kg
D) 5 mg/m²
Ans: C

1144- Carbamazepine and calcium channel blockers (CCBs) have different effects on the cytochrome P450 (CYP450) enzyme system.What is their effect on CYP450?(Surgery Feb 2025)

A- Induction
B- Inhibition
C- No effect
D- Substrate
Ans: A

CamScanner

1145- Which of the following drug is contraindicated in lactating mothers?(Gynae & Obs Feb 2025)
A- Codeine
B- Cephalexin
C- Paracetamol
D- Erythromycin
Ans: A

1146- A aged man, known case of hypertension, was on clonidine, run short of it, now presents with increased BP of about 200/110 with no symptoms, what next step should be taken? (Gynae & Obs Feb 2025)
A- Admit the patient and give nitro-glycerine
B- Restart clonidine and again check BP after 12 to 24 hours
C- Start ACE inhibitors
D- Start beta blockers
E- Start Hydralazine
Ans: B

1147- A man presents with chest pain for 3 hours, positive troponin I, and ECG findings, initial management of the patient is: (Gynae & Obs Feb 2025)
A- Aspirin + Prepare for thrombolysis
B- Aspirin + UFH + thrombolytic
C- Aspirin + Call cardiologist for PCI
D- Aspirin + CABG
Ans: C

1148- What is the typical volume of distribution (Vd) for most drugs?(Gynae & Obs Feb 2025)
A- Less than 4 liters
B- Approximately 10 liters
C- Less than 10 liters
D- 10 Litres
Ans: B

1149- Which of the following is therapeutic dose of MgSO4?(Gynae & Obs Feb 2025)
A- 8-10 mg/dL
B- 4-8 mg/dL
C- 10-13 mg/dL
D- >13 mg/dL
Ans: B

1150- A female patient on antipsychotic medication presents with amenorrhea which of the following antipsychotic drug is responsible for her condition? (Gynae & Obs Feb 2025)
A- Olanzapine
B- Haloperidol
C- Risperidone
D- Aripipirazole
E- Chlopromazine
Ans: C

1151- Metformin Side Effect(Radiology Feb 2025)
A- Diarrhea & Gas
B- Increased Metabolism by Cytochrome p450
C- weight gain
D- Cannot be used with sulphonylurea and insulin
Ans: A

1152- Campylobacter jejuni drug of choice in bloody diarrhoea leading to Enterocolitis? (Radiology Feb 2025)
A- Azithromycin
B- Ciprofloxacin
C- Penicillin
D- Ceftriaxone
Ans: B

1153- Which DPP-4 inhibitor does not require dose modification and is primarily excreted in the stool? (Radiology Feb 2025)
A- Linagliptin
B- Vildagliptin
C- Teneligliptin
D- Saxagliptin
Ans: A

1154- Which antiarrhythmic drug exerts its effects on both the sinoatrial (SA) and atrioventricular (AV) nodes of the heart? (Radiology Feb 2025)
A- Propranolol
B- Sotalol
C- Amiodarone
D- Atenolol
Ans: C

1155- A patient presents with muscle pain and difficulty standing. Which medication is most likely responsible? (Radiology Feb 2025)
A - Corticosteroids
B - Colchicine
C - Beta-blockers
D - Atorvastatin
Ans: D

1156- Captopril is a commonly used antihypertensive drug. A frequently observed side effect with prolonged use is a persistent dry cough, sometimes accompanied by wheezing. What is the most likely cause of this cough? (Radiology Feb 2025)
A - Increase in plasma levels of bradykinin
B - Idiosyncratic reaction to the drug
C - Decrease in blood pressure
D - Decrease in angiotensin levels in the plasma
Ans: A

CamScanner

1157- A patient was injected with FDG-18 (Fluorodeoxyglucose-18). Which radionuclear test is most likely being performed? (Radiology Feb 2025)

A- Positron Emission Tomography (PET) scan
B- Thyroid scintigraphy
C- Bone scan (Tc-99m)
D- Ventilation-perfusion (V/Q) scan
Ans: A

1158- A patient presents with decreased appetite and weight gain, and you prescribe an SSRI. Which of the following is the most bothersome side effect for the patient? (Radiology Feb 2025)

A- Sexual dysfunction
B- Weight gain
C- Insomnia
D- Tachycardia
E- Headache
Ans: A

1159- Lignocaine overdose?(Anesthesia Feb 2025)

A. 1% lignocaine solution has 100mg of drug in 100ml of preparation.
B. Causes fever, uticarua and laryngeal edema.
C. Causes perioral paresthesia, convulsions that last for several hours.
D. Is averted by using 2% solutions daily.
E. Is managed by hydrocortisone
Ans. C

1160- EEG at 1.0 Mac of Isofluranc (Anesthesia Feb 2025)

A- 0.3
B- 0.5
C- 1.2
D- 1.5
Ans: B

1161- A patient undergoes neuromuscular monitoring using the Train-of-Four (TOF) method. Based on the number of 4 twitches observed, what is the estimated percentage of neuromuscular blockade? (Anesthesia Feb 2025)

A- 70% NM blockage
B- 75% NM blockage
C- 80% NM blockage
D- 90% NM blockage
Ans: A

1162- A patient presents with low back pain and loss of lumbar lordosis. What is the initial treatment? (Anesthesia Feb 2025)

A- NSAIDs and physiotherapy
B- Immediate MRI and surgical consultation
C- Oral corticosteroids
D- Bed rest for 2 weekys
Ans: A

1163- A patient is in a state of shock. Which volatile anesthetic agent should be avoidcd?(Anesthesia Feb 2025)

A- Sevoflurane
B- Desflurane
C- Isoflurane
D- Halothane
Ans: D

1164- Which chemotherapeutic agent is used in an intrapleural injection for treating pleural plaques? (Anesthesia Feb 2025)

A- Cyclophosphamide
B- Adriamycin
C- Streptomycin
D- Cisplatin
Ans: D

1165- A patient was brought to OT for operation for acute intestinal obstruction, aneasthetist is considering IV h2 blocker. What might be the reason? (Anesthesia Feb 2025)

A- increase LES tone
B- has no effect on gastric fluid already present in stomach
C- increase pH of the gastric fluid already present
D- decreases ph of gastric fluid already present
Ans: C

1166- A Gardner presents with pinpoint pupils, diaphoresis, and urinary incontinence. What is the most appropriate immediate treatment? (Anesthesia Feb 2025)

A- Gastric lavage
B- Activated charcoal
C- Atropine
D- Supportive care only
Ans: C

1167- What is the main concern associated with N2O as an anaesthetic? (Anesthesia Feb 2025)

A- abdominal distension
B- nausea and vomiting
C- Diffusion into Air Filled Spaces
D- no effect on abdominal distension
Ans: C

CamScanner

1168- Which drug inhibits tetrahydrofolate (THF) synthesis? (Anesthesia Feb 2025)

A- Methotrexate
B- Trimethoprim
C- Pyrimethamine
D- Sulfonamides
Ans: A

1169- Patient with glaucoma, which drug is contraindicated ? (Anesthesia Feb 2025)

A- Atropine
B- Timolol
C- Acetazolamide
D- Pilocarpine
Ans: A

1170- Patient under GA having seizures and arrhythmia. First step of management ? (Anesthesia Feb 2025)

A- Diazepam
B- Propofol
C- Betablockers
D- Lignocaine
Ans: B

1171- Cytotoxic drug paclitaxel is classified in which class? (Anesthesia Feb 2025)

A- Alkylating
B- Microtubule inhibitor
C- Anti metabolite
D- Acetylating
Ans: B

1172- If significant GIT bleeding has occurred during surgery, which inhalational anesthesia should be given that has a high blood-gas coefficient? (Anesthesia Feb 2025)

A- N20
B- Halothane
C- Sevoflurane
D- Desflurane
Ans: B

1173- True Regarding Vapor Pressure: (Anesthesia Feb 2025)

A- Proportional to the temperature of the container
B- Proportional to the temperature of the liquid itself
C- Inversely proportional to external pressure
D- Unaffected by temperature
Ans: B

1174- True regarding Resistance through a tube during Suction: (Anesthesia Feb 2025)

A- 90° Right Angle increases resistance significantly
B- Straight tubes offer the least resistance
C- Resistance is inversely proportional to the radius
D- Longer tubes decrease resistance
Ans: A

1175- "A patient presents with a complaint of pain. On examination, dilated, tortuous blue veins are observed. The patient is already taking NSAIDs. What should be given next? (Anesthesia Feb 2025)

A- Clopidogrel
B- Vitamin D
C- Calcium
D- Lifestyle modifications
E- Warfarin
Ans: B

1176- $5HT_3$ antagonist given to a patient for diarrhea. What drug would this be?(Anesthesia Feb 2025)

A- Diphenoxylate
B- Dicyclomine
C- Loperamide
D- Alosetrone
Ans: D

1177- A patient taking Risperidone develops tremors and rigidity. What is the cause (Anesthesia Feb 2025)

A- D_1 antagonist in mesolimbic pathway
B- D_2 antagonist in nigrostriatal pathway
C- D_2 antagonist in tuberoinfundibular pathway
D- Serotonin $5HT_2A$ blockade
E- Increased cholinergic activity
Ans: B

1178- A patient presents with a bee sting. The doctor is looking for his emergency kit with injectable epinephrine. What is the doctor trying to prevent? (Anesthesia Feb 2025)

A- Local reaction
B- Systemic anaphylaxis
C- Delayed hypersensitivity
D- Angioedema
Ans. B

1179- A patient was brought to ER. He had no pulse or breathing. CPR was started and he was intubated. No IV line maintained. Which of the following drugs is ineffective through ETT? (Anesthesia Feb 2025)

A- Naloxone
B- Epinephrine
C- Diazepam
D- Lidocaine
Ans: C

1180- A young boy with absence seizures was prescribed Ethosuximide. What is its mechanism of action? (Anesthesia Feb 2025)

A- Activates GABA type B receptors
B- Enhances GABA receptors
C- Inhibits T-type Ca^{2+} channels
D- Blocks Na^+ channels
E- Inhibits NMDA receptors
Ans: C

1181- A steep dose-response curve indicates which of the following?" (Anesthesia Feb 2025)

A- Increased blood absorption and high concentration
B- Very high potency
C- Narrow therapeutic index
D- High receptor reserve
Ans: C

CamScanner